A 67-year-old man comes to the office due to dark urine, pale-appearing stools, and progressive yellowing of his eyes over the last few weeks. He also reports unintentional weight loss, but has had no night sweats, abdominal pain, bloody stools, or vomiting. He has no chronic medical conditions and takes no medication. Vital signs are within normal limits. Scleral icterus is present. The neck is supple. No lymphadenopathy or skin abnormalities are present. There is no hepatosplenomegaly. Laboratory results are as follows:

Total bilirubin	7.2 mg/dL
Alkaline phosphatase	398 U/L

CT scan of the abdomen reveals a pancreatic mass compressing the common bile duct and the pancreatic duct. This patient's disease process is most likely caused by a mutation affecting which of the following genes?

- A. *APC*
- B. *BCL2*
- C. *BRAF*
- D. *c-MYC*
- E. *KRAS*

Submit

https://t.me/USMLEWorldStep1

A 67-year-old man comes to the office due to dark urine, pale-appearing stools, and progressive yellowing of his eyes over the last few weeks. He also reports unintentional weight loss, but has had no night sweats, abdominal pain, bloody stools, or vomiting. He has no chronic medical conditions and takes no medication. Vital signs are within normal limits. Scleral icterus is present. The neck is supple. No lymphadenopathy or skin abnormalities are present. There is no hepatosplenomegaly. Laboratory results are as follows:

Total bilirubin	7.2 mg/dL
Alkaline phosphatase	398 U/L

CT scan of the abdomen reveals a pancreatic mass compressing the common bile duct and the pancreatic duct. This patient's disease process is most likely caused by a mutation affecting which of the following genes?

- A. *APC* (9%)
- ✗ B. *BCL2* (5%)
- C. *BRAF* (21%)
- D. *c-MYC* (9%)
- ✓ E. *KRAS* (53%)

Incorrect
Correct answer
E

53%
Answered correctly

02 mins, 29 secs
Time Spent

2023
Version

Explanation

Common bile duct obstructions increase conjugated bilirubin in the bloodstream, leading to jaundice and dark-colored urine; they also prevent bilirubin from entering the digestive tract, which results in clay-colored (acholic) stools. The vast majority (>85%) of obstructing pancreatic masses are due to **pancreatic ductal adenocarcinoma**.

https://t.me/USMLEWorldStep1

Common bile duct obstructions increase conjugated bilirubin in the bloodstream, leading to jaundice and dark-colored urine; they also prevent bilirubin from entering the digestive tract, which results in clay-colored (acholic) stools. The vast majority (>85%) of obstructing pancreatic masses are due to **pancreatic ductal adenocarcinoma**.

The major genomic abnormality in pancreatic ductal adenocarcinoma is ***KRAS*-activating mutation**, which allows tumor cells to grow and divide without input from the cellular milieu due to aberrant activity that relays a continuous growth signal to the nucleus. Because *KRAS* mutations are one of the earliest oncogenic mutations in pancreatic adenocarcinoma, tests for *KRAS* abnormalities are being developed to help with early detection. Many colorectal cancers and non–small cell lung cancers also have *KRAS*-activating mutations.

(Choice A) Germline mutations in the adenomatous polyposis coli *(APC)* tumor suppressor gene are associated with familial adenomatous polyposis (FAP). FAP causes innumerable colon polyps and colon cancer. Patients typically have hematochezia.

(Choice B) *BCL2* produces a protein that sits on the outer membrane of mitochondria and controls cell survival and apoptosis. *BCL2*-activating mutation is common in follicular lymphoma. Although patients with follicular lymphoma often have large abdominal masses, almost all cases are marked by significant peripheral lymphadenopathy and B symptoms (eg, night sweats).

(Choice C) *BRAF* is a protooncogene that produces a protein involved in growth signal transduction from the cell membrane to the interior of the cell. *BRAF* mutations are most strongly associated with malignant melanoma.

(Choice D) *c-MYC* is a protooncogene overexpressed in Burkitt lymphoma, which usually presents with a facial mass (eg, endemic African form) or with ascites and multi–organ involvement (eg, sporadic form). An isolated pancreatic mass with common bile duct obstruction is far more likely to be pancreatic adenocarcinoma.

Educational objective:
Oncogenesis in pancreatic ductal adenocarcinoma is almost always due to an early activating mutation in the *KRAS* oncogene, which produces a constitutively active protein that allows for uncontrolled proliferation of tumor cells.

https://t.me/USMLEWorldStep1

Comm
colore
stools.
adenc

The m
tumor
growth
adeno
cancer

(Choi
with fa
typical

(Choi
and ap
lymph
lymph

(Choi
memb

(Choi
mass
pancre

Educa
Oncog
KRAS
cells.

Exhibit Display

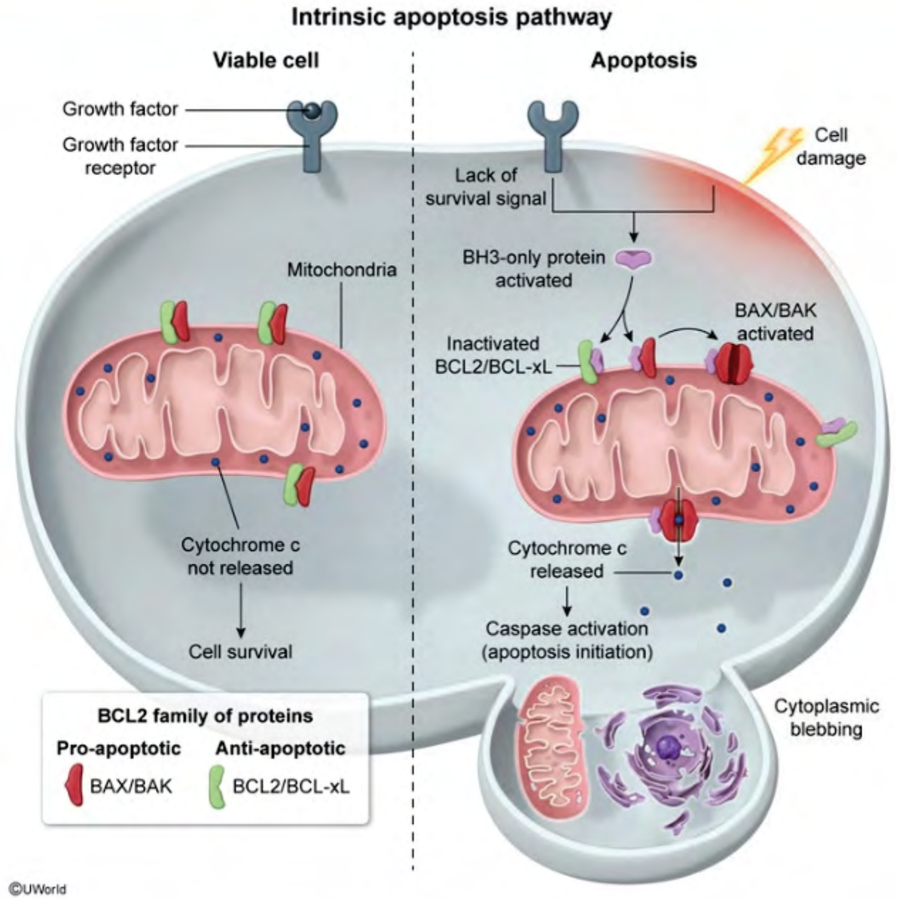

Zoom In Zoom Out Reset New | Existing My Notebook

https://t.me/USMLEWorldStep1

A 62-year-old man comes to the office for the evaluation of jaundice. Medical history is significant for uncontrolled type 2 diabetes mellitus and morbid obesity. He does not use tobacco, alcohol, or illicit drugs. There is no family history of liver disease. Vital signs are within normal limits. BMI is 47 kg/m^2. Mild scleral icterus is present. Heart and lung sounds are normal. The abdomen is nontender and nondistended. Trace bilateral lower extremity edema is present. Laboratory studies reveal elevated transaminases. A liver biopsy is obtained, and trichrome staining shows the following:

Which of the following cells is directly responsible for the histologic finding indicated by the arrow?

- A. Cholangiocytes
- B. Hepatocytes
- C. Kupffer cells
- D. Sinusoidal endothelial cells
- E. Stellate (Ito) cells

Submit

https://t.me/USMLEWorldStep1

A 62-year-old man comes to the office for the evaluation of jaundice. Medical history is significant for uncontrolled type 2
history
and lu
is pres
shows

Exhibit Display

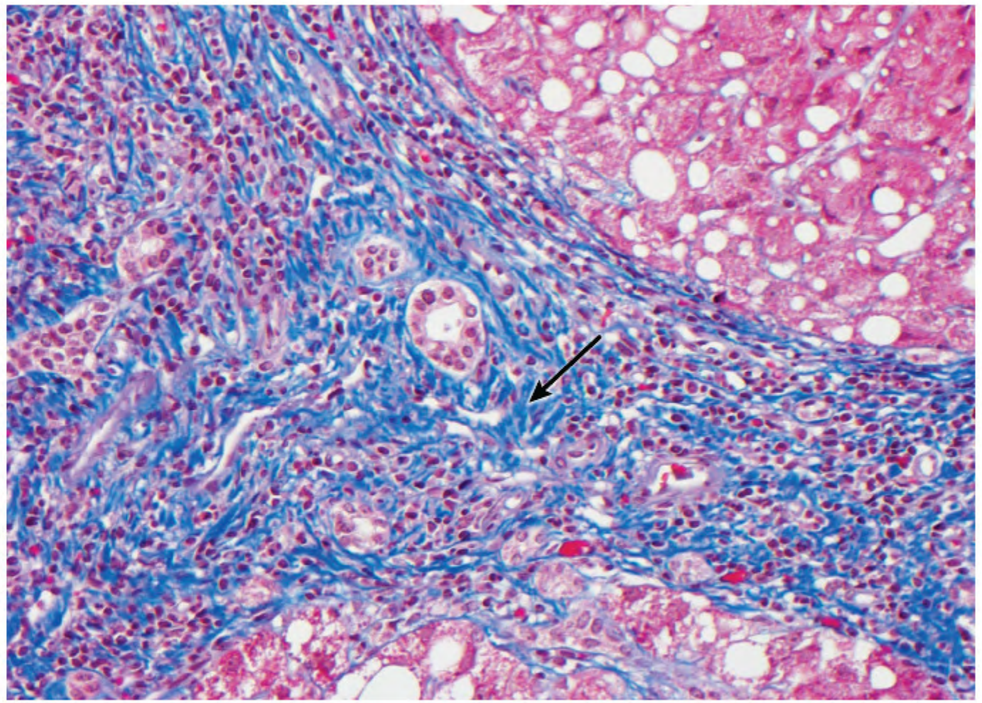

©UWorld

Zoom In | Zoom Out | Reset | New | Existing | My Notebook

Which

B. Hepatocytes

https://t.me/USMLEWorldStep1

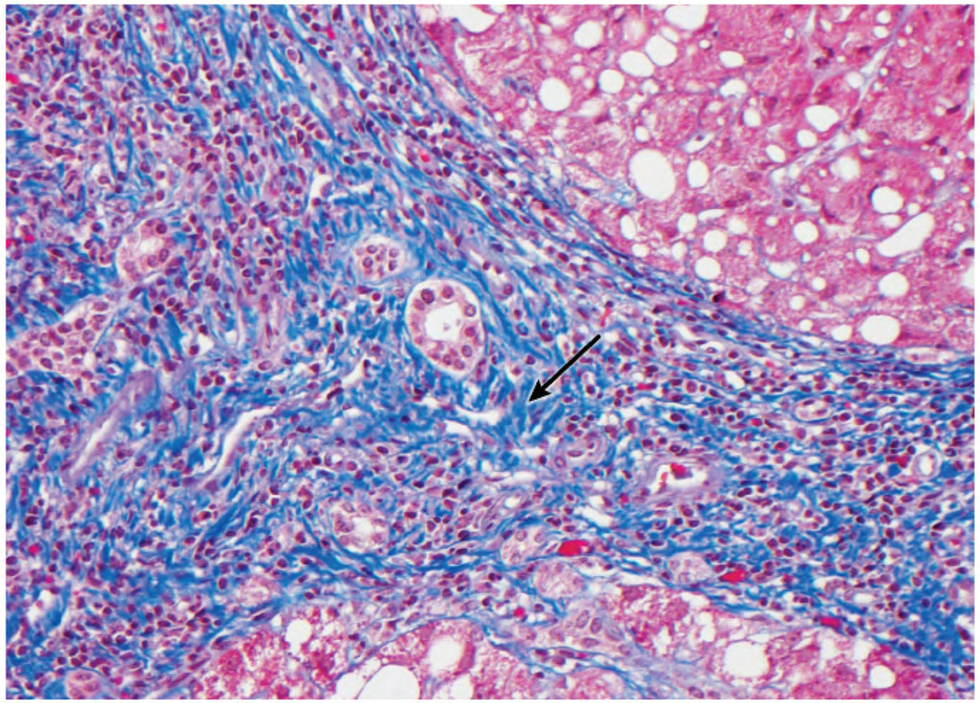

Which of the following cells is directly responsible for the histologic finding indicated by the arrow?

- A. Cholangiocytes
- B. Hepatocytes
- C. Kupffer cells
- D. Sinusoidal endothelial cells
- E. Stellate (Ito) cells

Submit

https://t.me/USMLEWorldStep1

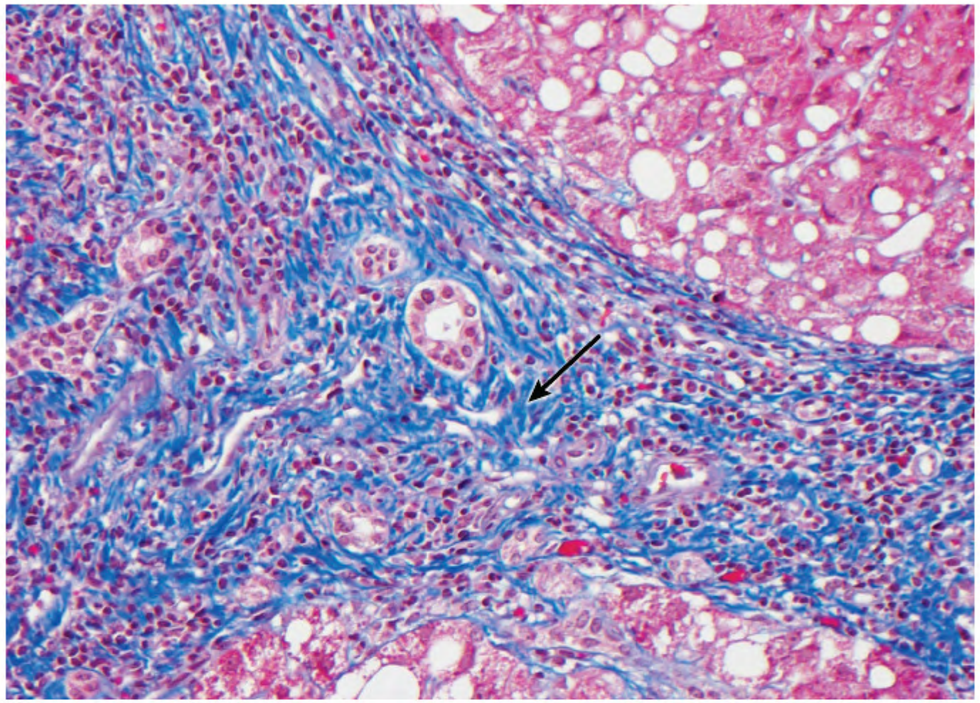

Which of the following cells is directly responsible for the histologic finding indicated by the arrow?

- A. Cholangiocytes (2%)
- B. Hepatocytes (5%)
- ✗ C. Kupffer cells (18%)
- D. Sinusoidal endothelial cells (8%)
- ✓ E. Stellate (Ito) cells (64%)

Incorrect
Correct answer
E

64%
Answered correctly

22 secs
Time Spent

2023
Version

https://t.me/USMLEWorldStep1

Explanation

Primary cells of the liver	
Cell type	**Function**
Cholangiocyte	• Bile duct epithelial cell • Transports solutes and electrolytes into bile
Hepatocyte	• Protein, cholesterol & bile synthesis, gluconeogenesis • Drug and fatty acid metabolism
Kupffer cell	• Macrophages within hepatic sinusoids • Phagocytosis of bacteria and RBCs
Stellate cell	• Quiescent phase: vitamin A storage • Activated phase: transform into myofibroblast to secrete collagen (primary cell involved in hepatic fibrosis)
RBC = red blood cell.	

This patient with diabetes mellitus and morbid obesity has **hepatic cirrhosis**, likely due to long-standing nonalcoholic fatty liver disease (NAFLD). Cirrhosis is the end stage of multiple liver diseases and is characterized by replacement of normal lobular architecture with regenerating nodules separated by bridging fibrous septa.

Cirrhosis can be visualized histologically as **thickened collagenous bands** (which stain blue with Masson trichrome stain) separating clusters of hepatocytes. Fat infiltration (ie, hepatic steatosis, visible as clear vacuoles within the parenchyma) is commonly seen in both alcohol-induced fatty liver disease and NAFLD. In response to chronic injury, **stellate (Ito) cells** in the space of Disse are activated and transform into **myofibroblasts** capable of proliferating, promoting chemotaxis, and **producing collagen** in large quantities. This leads to progressive scar formation and cirrhosis.

Manifestations of cirrhosis include jaundice, scleral icterus, spider angiomas, and elevated liver enzymes. Evidence of abnormal hepatic synthetic function (eg, abnormal coagulation parameters, hypoalbuminemia) and

https://t.me/USMLEWorldStep1

This patient with diabetes mellitus and morbid obesity has **hepatic cirrhosis**, likely due to long-standing nonalcoholic fatty liver disease (NAFLD). Cirrhosis is the end stage of multiple liver diseases and is characterized by replacement of normal lobular architecture with regenerating nodules separated by bridging fibrous septa.

Cirrhosis can be visualized histologically as **thickened collagenous bands** (which stain blue with Masson trichrome stain) separating clusters of hepatocytes. Fat infiltration (ie, hepatic steatosis, visible as clear vacuoles within the parenchyma) is commonly seen in both alcohol-induced fatty liver disease and NAFLD. In response to chronic injury, **stellate (Ito) cells** in the space of Disse are activated and transform into **myofibroblasts** capable of proliferating, promoting chemotaxis, and **producing collagen** in large quantities. This leads to progressive scar formation and cirrhosis.

Manifestations of cirrhosis include jaundice, scleral icterus, spider angiomas, and elevated liver enzymes. Evidence of abnormal hepatic synthetic function (eg, abnormal coagulation parameters, hypoalbuminemia) and thrombocytopenia are also common.

(Choice A) Cholangiocytes are epithelial cells within the bile duct system. They transport ions and solutes into bile as it travels through the canaliculi.

(Choice B) Hepatocytes are located in the liver parenchyma and have many functions, including protein synthesis and storage, fatty acid metabolism, gluconeogenesis, cholesterol synthesis, and drug metabolism.

(Choice C) Kupffer cells are macrophages that reside within hepatic sinusoids. They are indirectly involved in fibrogenesis because they generate cytokines (ie, TNF-alpha) to assist in the activation of stellate cells; however, their primary function is bacterial phagocytosis and the clearance of red blood cells.

(Choice D) Sinusoidal endothelial cells, which line hepatic sinusoids, are fenestrated cells that filter solutes out of the blood and into hepatocytes. They assist in the removal of metabolic waste and other macromolecules from circulation.

Educational objective:
Stellate (Ito) cells are the primary cells involved in hepatic fibrosis. In response to hepatic injury, the stellate cells are activated and transform into myofibroblasts capable of proliferating, promoting chemotaxis, and producing large quantities of collagen. Collagen stains blue with Masson trichrome stain.

https://t.me/USMLEWorldStep1

Cirrhosis can be visualized histologically as **thickened collagenous bands** (which stain blue with Masson trichrome stain) separating clusters of hepatocytes. Fat infiltration (ie, hepatic steatosis, visible as clear vacuoles within the parenchyma) is commonly seen in both alcohol-induced fatty liver disease and NAFLD. In response to chronic injury, **stellate (Ito) cells** in the space of Disse are activated and transform into **myofibroblasts** capable of proliferating, promoting chemotaxis, and **producing collagen** in large quantities. This leads to progressive scar formation and cirrhosis.

Manifestations of cirrhosis include jaundice, scleral icterus, spider angiomas, and elevated liver enzymes. Evidence of abnormal hepatic synthetic function (eg, abnormal coagulation parameters, hypoalbuminemia) and thrombocytopenia are also common.

(Choice A) Cholangiocytes are epithelial cells within the bile duct system. They transport ions and solutes into bile as it travels through the canaliculi.

(Choice B) Hepatocytes are located in the liver parenchyma and have many functions, including protein synthesis and storage, fatty acid metabolism, gluconeogenesis, cholesterol synthesis, and drug metabolism.

(Choice C) Kupffer cells are macrophages that reside within hepatic sinusoids. They are indirectly involved in fibrogenesis because they generate cytokines (ie, TNF-alpha) to assist in the activation of stellate cells; however, their primary function is bacterial phagocytosis and the clearance of red blood cells.

(Choice D) Sinusoidal endothelial cells, which line hepatic sinusoids, are fenestrated cells that filter solutes out of the blood and into hepatocytes. They assist in the removal of metabolic waste and other macromolecules from circulation.

Educational objective:
Stellate (Ito) cells are the primary cells involved in hepatic fibrosis. In response to hepatic injury, the stellate cells are activated and transform into myofibroblasts capable of proliferating, promoting chemotaxis, and producing large quantities of collagen. Collagen stains blue with Masson trichrome stain.

References

- Molecular pathogenesis of hepatic fibrosis and current therapeutic approaches.
- Physiology of cholangiocytes.

https://t.me/USMLEWorldStep1

Stellate cell	• Activated phase: transform into myofibroblast to secrete collagen (primary cell involved in hepatic fibrosis)
RE	

This p
nonalc
by rep

Cirrho
trichro
within
chroni
prolife
format

Manife
Evider
thromb

(Choi
bile as

(Choi
and st

(Choi
fibroge
their p

(Choi
the blo
circulation.

Educational objective:

Exhibit Display

Cirrhosis due to nonalcoholic fatty liver disease

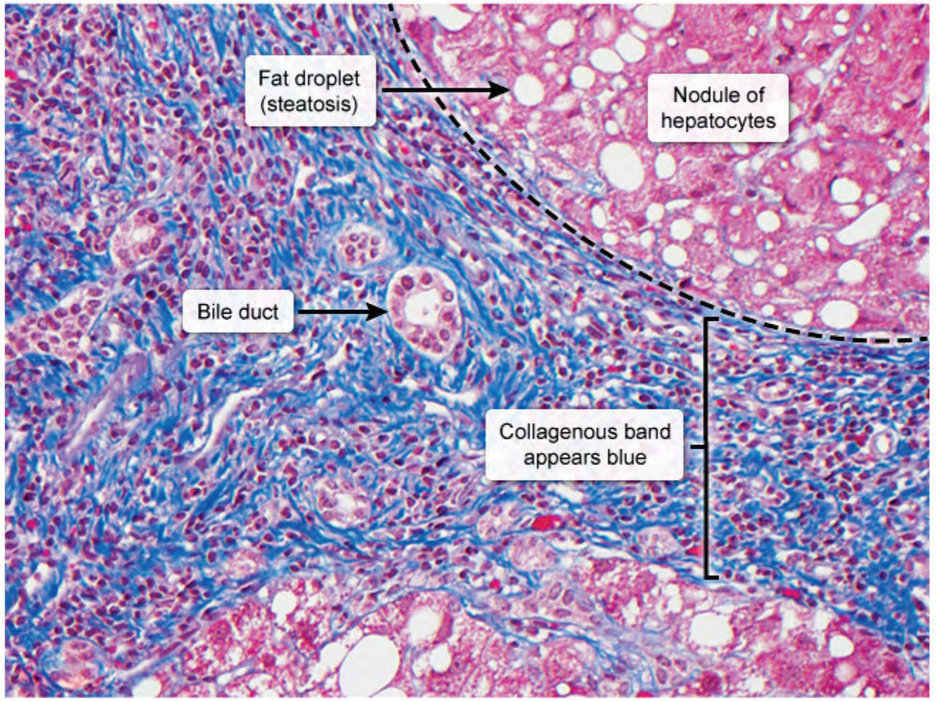

©UWorld

Trichrome stain

Zoom In | Zoom Out | Reset | New | Existing | My Notebook

https://t.me/USMLEWorldStep1

Stellate cell	• Activated phase: transform into myofibroblast to secrete collagen (primary cell involved in hepatic fibrosis)
RE	

This p
nonalc
by rep

Cirrho
trichro
within
chroni
prolife
format

Manife
Evider
thromb

(Choi
bile as

(Choi
and st

(Choi
fibroge
their p

(Choi
the blo
circulation.

Educational objective:

Exhibit Display

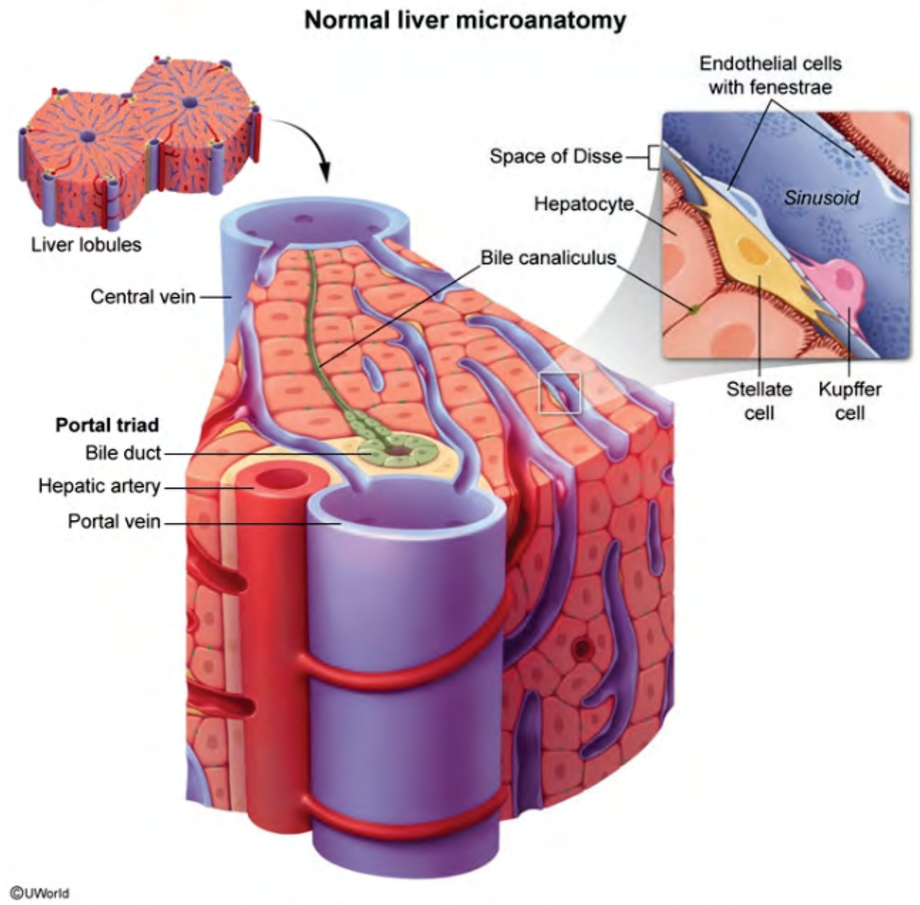

Zoom In | Zoom Out | Reset | New | Existing | My Notebook

https://t.me/USMLEWorldStep1

A 32-year-old male with anorexia and fatigue is found to have persistently elevated serum alanine aminotransferase (ALT) and aspartate aminotransferase (AST) levels. He is also positive for HBsAg. Which of the following best describes the mechanism of liver injury in this patient?

- A. Direct viral cytotoxic effect with hepatocyte necrosis
- B. Antibody response to viral antigens on the cell surface with antibody-mediated cell damage
- C. Circulating viral antigen-antibody complexes with small vessel deposition and immunologic vessel injury
- D. Antigen mimicry with generation of self-antigen recognizing CD4+ T lymphocytes that damage hepatocytes
- E. CD8+ T lymphocyte response to viral antigens on the cell surface resulting in hepatocyte damage

Submit

https://t.me/USMLEWorldStep1

A 32-year-old male with anorexia and fatigue is found to have persistently elevated serum alanine aminotransferase (ALT) and aspartate aminotransferase (AST) levels. He is also positive for HBsAg. Which of the following best describes the mechanism of liver injury in this patient?

- A. Direct viral cytotoxic effect with hepatocyte necrosis (26%)
- B. Antibody response to viral antigens on the cell surface with antibody-mediated cell damage (12%)
- ✗ C. Circulating viral antigen-antibody complexes with small vessel deposition and immunologic vessel injury (3%)
- D. Antigen mimicry with generation of self-antigen recognizing CD4+ T lymphocytes that damage hepatocytes (4%)
- ✓ E. CD8+ T lymphocyte response to viral antigens on the cell surface resulting in hepatocyte damage (53%)

Incorrect
Correct answer
E

53%
Answered correctly

03 secs
Time Spent

2023
Version

Explanation

Hepatitis B virus infection progresses through two phases: the proliferative phase and the integrative phase.

In the proliferative phase, the entire virion and all related antigens of the episomal HBV DNA are present. On the hepatocyte cell surface, viral HBsAg and HBcAg are expressed in conjunction with the major histocompatibility complex (MHC) class I molecules. This expression serves to activate the cytotoxic CD8+ T lymphocytes, which respond by destroying the infected hepatocytes. Note that the virion itself does not have a cytopathic effect.

In the integrative phase, the HBV DNA is incorporated into the host genome of those hepatocytes that survived the immune response. Infectivity ceases and liver damage tapers off when the antiviral antibodies appear and viral replication stops. The risk of hepatocellular carcinoma, however, remains elevated because of the HBV DNA that

https://t.me/USMLEWorldStep1

Hepatitis B virus infection progresses through two phases: the proliferative phase and the integrative phase.

In the proliferative phase, the entire virion and all related antigens of the episomal HBV DNA are present. On the hepatocyte cell surface, viral HBsAg and HBcAg are expressed in conjunction with the major histocompatibility complex (MHC) class I molecules. This expression serves to activate the cytotoxic CD8+ T lymphocytes, which respond by destroying the infected hepatocytes. Note that the virion itself does not have a cytopathic effect.

In the integrative phase, the HBV DNA is incorporated into the host genome of those hepatocytes that survived the immune response. Infectivity ceases and liver damage tapers off when the antiviral antibodies appear and viral replication stops. The risk of hepatocellular carcinoma, however, remains elevated because of the HBV DNA that has been integrated into the host genome.

(Choice A) Hepatitis B virus has no direct cytotoxic effect.

(Choice B) Host antibody HBsAb neutralizes HBV infectivity by binding to the viral surface antigen HBsAg and preventing the antigen from interacting with hepatocyte receptors. Note that this neutralization occurs before the virus enters the hepatocyte, and therefore would not be associated with hepatocellular damage.

(Choice C) Antigen-antibody complexes cause some of the early symptoms of hepatitis B virus infection (eg, arthralgias, arthritis, and urticaria) as well as some of the chronic complications (eg, immune complex glomerulonephritis, cryoglobulinemia, vasculitis). These complexes are not responsible for hepatocellular damage, however.

(Choice D) The pathogenesis of autoimmune hepatitis (not hepatitis B infection) involves antigen mimicry with generation of self-antigen recognizing CD4+ T lymphocytes that damage hepatocytes.

Educational Objective:
Hepatitis B virus does not have a cytotoxic effect itself; however, the presence of viral HBsAg and HBcAg on the cell surface stimulate the host's cytotoxic CD8+ T lymphocytes to destroy infected hepatocytes.

Pathophysiology	Gastrointestinal & Nutrition	Hepatitis b
Subject	System	Topic

Copyright © UWorld. All rights reserved.

https://t.me/USMLEWorldStep1

A 46-year-old woman comes to the office with persistent diarrhea, weight loss, and abdominal pain. Her diarrhea started several months ago. She has no fever, melena, or hematochezia. The patient has not traveled outside of the country and has not drunk from any untreated freshwater sources. She has had no recent hospitalizations or antibiotic use. Her sister has a history of celiac disease. Upper endoscopy reveals postbulbar duodenal and jejunal ulcers. This patient most likely has a tumor secreting which of the following molecules?

- A. Gastrin
- B. Glucagon
- C. Insulin
- D. Serotonin
- E. Somatostatin
- F. Vasoactive intestinal polypeptide

Submit

https://t.me/USMLEWorldStep1

A 46-year-old woman comes to the office with persistent diarrhea, weight loss, and abdominal pain. Her diarrhea started several months ago. She has no fever, melena, or hematochezia. The patient has not traveled outside of the country and has not drunk from any untreated freshwater sources. She has had no recent hospitalizations or antibiotic use. Her sister has a history of celiac disease. Upper endoscopy reveals postbulbar duodenal and jejunal ulcers. This patient most likely has a tumor secreting which of the following molecules?

- ✓ A. Gastrin (73%)
- ✗ B. Glucagon (0%)
- C. Insulin (0%)
- D. Serotonin (3%)
- E. Somatostatin (1%)
- F. Vasoactive intestinal polypeptide (20%)

Incorrect
Correct answer
A

73%
Answered correctly

03 secs
Time Spent

2023
Version

Explanation

Zollinger-Ellison syndrome

https://t.me/USMLEWorldStep1

A 46-year-old woman comes to the office with persistent diarrhea, weight loss, and abdominal pain. Her diarrhea started
the co
antibio
jejunal

Inco
Corre
A

Expl

Exhibit Display

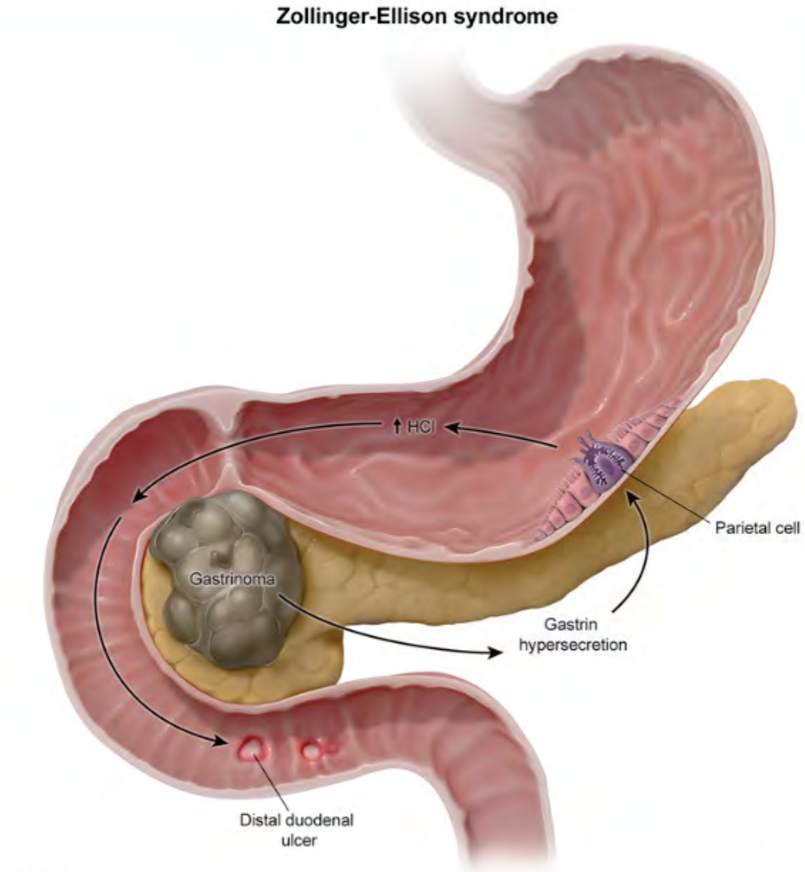

Zoom In Zoom Out Reset New | Existing My Notebook

https://t.me/USMLEWorldStep1

This patient's clinical presentation is highly suggestive of **Zollinger-Ellison syndrome** (ZES). ZES is caused by gastrin-secreting neuroendocrine tumors (**gastrinomas**) that are most commonly located in the small intestine or pancreas. The gastrin produced by these tumors stimulates gastric acid production, often resulting in multiple **peptic ulcers** that can be located **beyond the duodenal bulb** and are often refractory to therapy. Patients typically experience **abdominal pain** and acid reflux. They may also have **diarrhea** as gastric acid damages intestinal epithelial cells and inactivates pancreatic enzymes, preventing proper nutrient absorption.

The diagnosis of gastrinoma is made by measuring basal and stimulated gastrin levels (secretin stimulation test). Patients with ZES should undergo testing (eg, serum calcium, prolactin level) to exclude **multiple endocrine neoplasia type 1** due to the strong association between these conditions.

(Choice B) Glucagonomas are rare pancreatic alpha-cell tumors that present with diabetes mellitus and a raised erythematous rash that typically affects the groin (necrolytic migratory erythema).

(Choice C) Insulinomas are pancreatic beta-cell tumors that secrete insulin autonomously, regardless of blood glucose levels. As a result, patients usually have high circulating insulin/C-peptide levels and symptoms of hypoglycemia (eg, tremor, confusion).

(Choice D) Carcinoid syndrome is most frequently caused by neuroendocrine tumors originating in the small intestine that have metastasized to the liver. These tumors secrete products such as serotonin and bradykinin, resulting in diarrhea, episodic flushing, right-sided valvular heart disease, and wheezing.

(Choice E) Somatostatinomas are rare tumors of the pancreatic D cells that present with diabetes mellitus (diminished insulin secretion), cholelithiasis (inhibition of cholecystokinin release), and diarrhea/steatorrhea (inhibition of pancreatic enzyme/bicarbonate secretion).

(Choice F) Vasoactive intestinal polypeptide is secreted by VIPomas, rare neuroendocrine tumors of the pancreas. Patients typically have diarrhea that persists with fasting, achlorhydria, and hypokalemia.

Educational objective:
Zollinger-Ellison syndrome is caused by gastrin-secreting tumors (gastrinomas) involving the small intestine or pancreas. Patients typically have peptic ulcers (often beyond the duodenal bulb), abdominal pain/acid reflux, and diarrhea. The condition is frequently associated with multiple endocrine neoplasia type 1.

https://t.me/USMLEWorldStep1

The mother of a 7-year-old boy calls the clinic due to a 3-day history of diarrhea. The patient initially had nausea with vomiting on the first day but has since been able to keep down crackers soaked in apple juice. He now has voluminous watery diarrhea several times per day. Several other children in his classroom have also been ill with similar symptoms. The physician schedules the family to come to the office in 2 days and recommends an oral rehydration solution in the meantime. The solution contains dextrose and sodium in equimolar amounts, as well as a small amount of potassium and citrate. Which of following best describes the role of dextrose?

- A. Correction of metabolic acidosis
- B. Creation of high osmolarity in the gut lumen
- C. Enhancement of sodium absorption
- D. Prevention of osmotic lysis of enterocytes
- E. Provision of total caloric requirements

Submit

https://t.me/USMLEWorldStep1

The mother of a 7-year-old boy calls the clinic due to a 3-day history of diarrhea. The patient initially had nausea with vomiting on the first day but has since been able to keep down crackers soaked in apple juice. He now has voluminous watery diarrhea several times per day. Several other children in his classroom have also been ill with similar symptoms. The physician schedules the family to come to the office in 2 days and recommends an oral rehydration solution in the meantime. The solution contains dextrose and sodium in equimolar amounts, as well as a small amount of potassium and citrate. Which of following best describes the role of dextrose?

- A. Correction of metabolic acidosis (4%)
- ✗ B. Creation of high osmolarity in the gut lumen (11%)
- ✓ C. Enhancement of sodium absorption (56%)
- D. Prevention of osmotic lysis of enterocytes (9%)
- E. Provision of total caloric requirements (18%)

Incorrect
Correct answer
C

56%
Answered correctly

04 secs
Time Spent

2023
Version

Explanation

Oral rehydration solution	
Glucose	• Enhances sodium absorption through cotransport • Provides trivial calories
Sodium	• Determines the intravascular volume status (major extracellular osmole)
Potassium	• Replaces diarrheal potassium loss
Citrate	• Converts to bicarbonate to buffer metabolic acidosis

https://t.me/USMLEWorldStep1

Oral rehydration solution	
Glucose	• Enhances sodium absorption through cotransport • Provides trivial calories
Sodium	• Determines the intravascular volume status (major extracellular osmole)
Potassium	• Replaces diarrheal potassium loss
Citrate	• Converts to bicarbonate to buffer metabolic acidosis
Total osmolality ≈ 300 mOsm/L.	

This patient has acute diarrhea likely due to viral gastroenteritis. Because he is able to tolerate intake by mouth (ie, no severe nausea or ongoing vomiting), an **oral rehydration solution** (ORS), such as Pedialyte, is an appropriate treatment. Acute diarrhea causes loss of total body water and electrolytes, which places patients at risk for several complications:

- **Hypovolemia** is due to intestinal loss of **sodium**, the major extracellular osmole that maintains circulating volume status. Sodium is absorbed at the gut brush border by 1:1 **cotransport with glucose** via sodium-glucose luminal cotransporter-1 (SGLT-1) lining the apical surface of enterocytes. Therefore, all ORSs contain sodium and dextrose (ie, D-glucose) in **equimolar amounts**.
- **Metabolic acidosis** (with normal anion gap) is due to loss of bicarbonate in diarrheal secretions. ORSs typically contain **citrate**, which is metabolized to bicarbonate in the liver, providing a buffering capacity to help correct the acidosis **(Choice A)**.
- **Hypokalemia** is due to loss of potassium-rich diarrheal secretions. ORSs typically contain a modest amount of potassium, quickly absorbed by passive diffusion in the small intestine.

Solutions such as fruit juices that have high sugar content (eg, glucose ≥50 g/L) are generally avoided because they may induce a superimposed osmotic diarrhea. The total osmolality of ORSs is designed to be roughly isotonic to the gut lumen **(Choice B)**.

https://t.me/USMLEWorldStep1

appropriate treatment. Acute diarrhea causes loss of total body water and electrolytes, which places patients at risk for several complications:

- **Hypovolemia** is due to intestinal loss of **sodium**, the major extracellular osmole that maintains circulating volume status. Sodium is absorbed at the gut brush border by 1:1 **cotransport with glucose** via sodium-glucose luminal cotransporter-1 (SGLT-1) lining the apical surface of enterocytes. Therefore, all ORSs contain sodium and dextrose (ie, D-glucose) in **equimolar amounts**.

- **Metabolic acidosis** (with normal anion gap) is due to loss of bicarbonate in diarrheal secretions. ORSs typically contain **citrate**, which is metabolized to bicarbonate in the liver, providing a buffering capacity to help correct the acidosis **(Choice A)**.

- **Hypokalemia** is due to loss of potassium-rich diarrheal secretions. ORSs typically contain a modest amount of potassium, quickly absorbed by passive diffusion in the small intestine.

Solutions such as fruit juices that have high sugar content (eg, glucose ≥50 g/L) are generally avoided because they may induce a superimposed osmotic diarrhea. The total osmolality of ORSs is designed to be roughly isotonic to the gut lumen **(Choice B)**.

(Choice D) Dextrose is provided at 5% (eg, D5W) for *intravenous fluids* to prevent osmotic swelling and hemolysis of red blood cells, which would occur with true free water. However, enterocytes are already bathed in a rich mucous layer containing osmoles; they do not lyse even when drinking pure water.

(Choice E) Because the concentration of dextrose in ORSs is limited, they provide only a trivial caloric content (eg, 75 kcal/L). Caloric deprivation is well tolerated during acute illnesses such as gastroenteritis; patients can safely fast for several days. However, hydration and intravascular volume status must be maintained.

Educational objective:
Oral rehydration solutions contain equimolar amounts of dextrose (glucose) and sodium, which are absorbed through intestinal cotransport to maintain intravascular volume status. They also contain potassium to compensate for gastrointestinal losses, and citrate to buffer metabolic acidosis.

Pharmacology	Gastrointestinal & Nutrition	Acute diarrhea
Subject	System	Topic

https://t.me/USMLEWorldStep1

This patient has acute diarrhea likely due to viral gastroenteritis. Because he is able to tolerate intake by mouth
(ie, no
approp
risk fo

- H
  v
  g
  s
- M
  ty
  c
- H
  o

Solutio
they m
to the

(Choi
of red
mucou

(Choi
(eg, 75
safely

Educa
Oral rehydration solutions contain equimolar amounts of dextrose (glucose) and sodium, which are absorbed through intestinal cotransport to maintain intravascular volume status. They also contain potassium to compensate

Exhibit Display

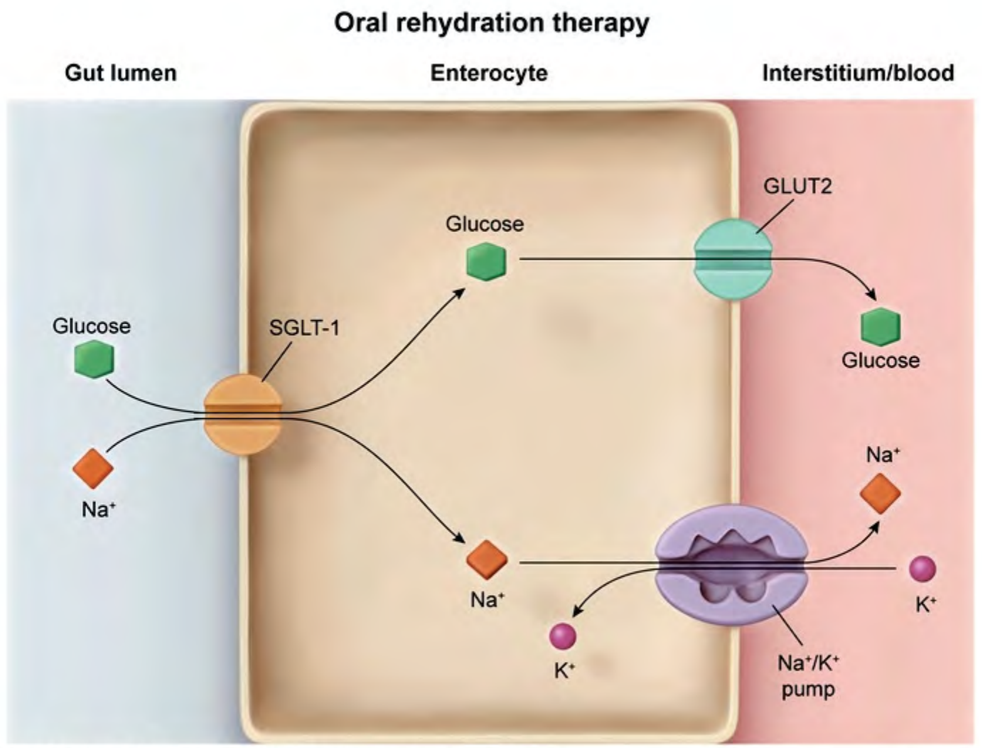

GLUT2 = glucose transporter 2; SGLT-1 = sodium-glucose cotransporter 1.

©UWorld

Zoom In Zoom Out Reset New | Existing My Notebook

A 23-year-old man comes to the office with a 2-week history of malaise, loss of appetite, and vague abdominal pain. The patient has had no nausea, vomiting, changes in bowel habits, dysuria, urinary frequency, or hematuria. He had an appendectomy for acute appendicitis at age 15; medical history is otherwise unremarkable. The patient does not use tobacco or alcohol and has had no recent travel. Physical examination reveals normal bowel sounds and no guarding or rebound tenderness. Abdominal CT scan obtained as part of this patient's evaluation is shown in the image below:

The structure indicated by the arrow originates from the same embryologic germ layer as which of the following tissues?

- A. Adrenal medulla
- B. Liver
- C. Salivary glands
- D. Skeletal muscle
- E. Thymus

Submit

https://t.me/USMLEWorldStep1

A 23-year-old man comes to the office with a 2-week history of malaise, loss of appetite, and vague abdominal pain. He has
does r
and no
in the

Exhibit Display

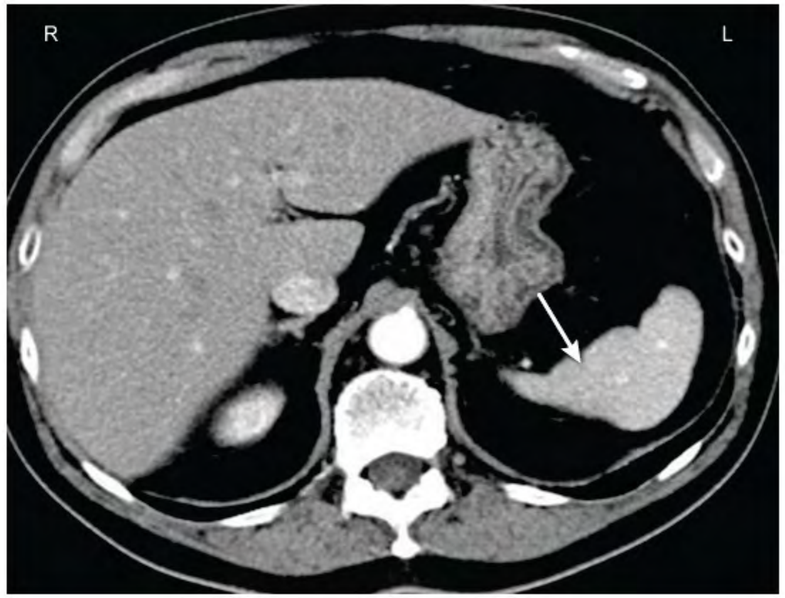

Zoom In | Zoom Out | Reset | New | Existing | My Notebook

The st
tissues

C. Salivary glands
D. Skeletal muscle

https://t.me/USMLEWorldStep1

and no guarding or rebound tenderness. Abdominal CT scan obtained as part of this patient's evaluation is shown in the image below:

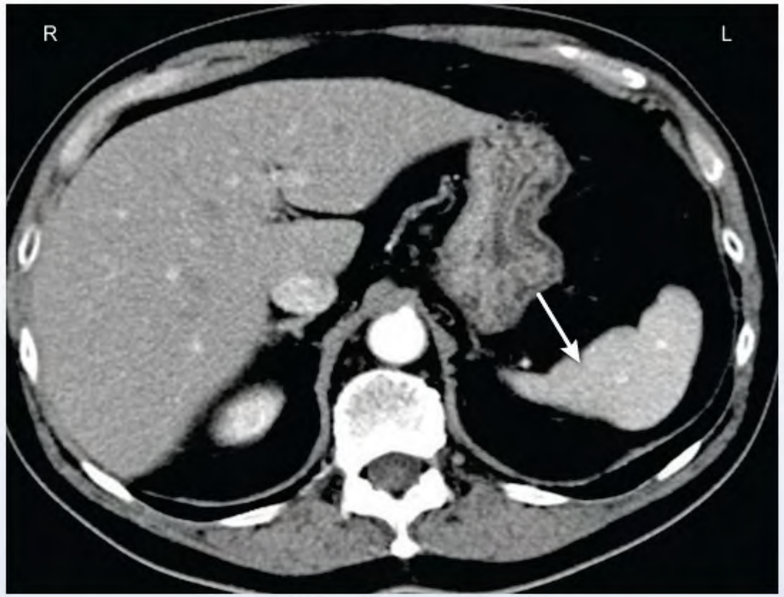

The structure indicated by the arrow originates from the same embryologic germ layer as which of the following tissues?

- A. Adrenal medulla
- B. Liver
- C. Salivary glands
- D. Skeletal muscle
- E. Thymus

Submit

https://t.me/USMLEWorldStep1

and no guarding or rebound tenderness. Abdominal CT scan obtained as part of this patient's evaluation is shown in the image below:

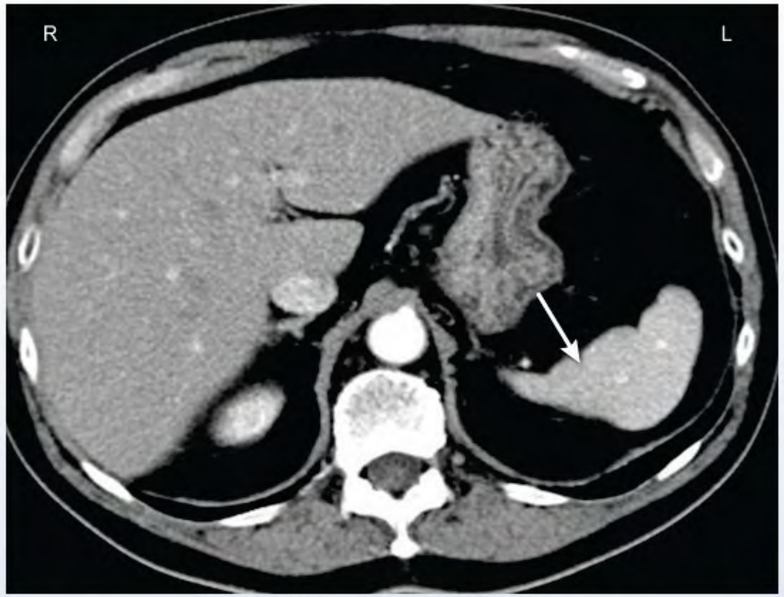

The structure indicated by the arrow originates from the same embryologic germ layer as which of the following tissues?

- A. Adrenal medulla (12%)
- B. Liver (29%)
- ✗ C. Salivary glands (4%)
- ✓ D. Skeletal muscle (34%)
- E. Thymus (19%)

Incorrect
Correct answer
D

34%
Answered correctly

14 secs
Time Spent

2023
Version

https://t.me/USMLEWorldStep1

Explanation

Embryologic derivatives		
Ectoderm	Surface ectoderm	• Anterior pituitary (Rathke pouch) • Lens & cornea • Inner ear sensory organs, olfactory epithelium • Nasal & oral epithelial linings, salivary glands • Epidermis, sweat & mammary glands
	Neural tube	• Brain & spinal cord • Posterior pituitary, pineal gland • Retina
	Neural crest	• Neural ganglia, adrenal medulla • Schwann cells; pia & arachnoid mater • Aorticopulmonary septum & endocardial cushions • Branchial arches (bones & cartilage) • Skull bones • Melanocytes
Mesoderm		• Muscles (skeletal, cardiac & smooth) • Connective tissue, bone & cartilage • Serosal linings (eg, peritoneum) • Cardiovascular & lymphatic system • Spleen & hemopoietic cells • Kidney & ureters, internal genitalia • Adrenal cortex
		• Gastrointestinal tract, liver, pancreas • Lungs

https://t.me/USMLEWorldStep1

Ectoderm		• Nasal & oral epithelial linings, salivary glands • Epidermis, sweat & mammary glands
	Neural tube	• Brain & spinal cord • Posterior pituitary, pineal gland • Retina
	Neural crest	• Neural ganglia, adrenal medulla • Schwann cells; pia & arachnoid mater • Aorticopulmonary septum & endocardial cushions • Branchial arches (bones & cartilage) • Skull bones • Melanocytes
Mesoderm		• Muscles (skeletal, cardiac & smooth) • Connective tissue, bone & cartilage • Serosal linings (eg, peritoneum) • Cardiovascular & lymphatic system • Spleen & hemopoietic cells • Kidney & ureters, internal genitalia • Adrenal cortex
Endoderm		• Gastrointestinal tract, liver, pancreas • Lungs • Thymus, parathyroids, thyroid follicular cells • Middle ear epithelium • Bladder & urethra • Parafollicular (C) cells*

*Formerly thought to be of neural crest origin.

The arrow on this patient's abdominal CT scan is pointing to the **spleen**, a large, wedge-shaped lymphatic organ in

https://t.me/USMLEWorldStep1

Endoderm	• Lungs • Thymus, parathyroids, thyroid follicular cells • Middle ear epithelium • Bladder & urethra • Parafollicular (C) cells*
*Formerly thought to be of neural crest origin.	

The arrow on this patient's abdominal CT scan is pointing to the **spleen**, a large, wedge-shaped lymphatic organ in the **left posterosuperior** aspect of the abdominal cavity. By convention, CT scans are presented such that the patient's left is on the reader's right (imagine that the patient is supine with the feet directed toward the viewer).

Most intrabdominal organs are derived from the endoderm and include the small and large intestines, liver, and pancreas **(Choice B)**. However, the spleen is unique because it is derived from condensed mesenchymal tissue in the **dorsal mesentery**. Mesenchymal tissue arises from the **mesoderm** and is characterized by loosely associated cells surrounded by the extracellular matrix.

Other derivatives of the mesoderm include **muscle** (skeletal, cardiac, smooth), **bone**, and **kidney**.

(Choice A) The adrenal cortex is derived from the mesoderm, similar to the spleen. In contrast, the adrenal medulla arises from neural crest cells (derived from the ectoderm).

(Choice C) Salivary glands are derived from the surface ectoderm.

(Choice E) The thymus is derived from the endoderm.

Educational objective:
The spleen is a large, wedge-shaped lymphatic organ in the left posterosuperior aspect of the abdominal cavity. In contrast to the endodermal origin of most other abdominal organs, the spleen is derived from the mesoderm in the dorsal mesentery. Other mesoderm-derived tissues include muscle, bone, and kidney.

Embryology (Subject) | Gastrointestinal & Nutrition (System) | Embryologic derivatives (Topic)

Copyright © UWorld. All rights reserved.

https://t.me/USMLEWorldStep1

- Lungs

Exhibit Display

Spleen on CT abdomen

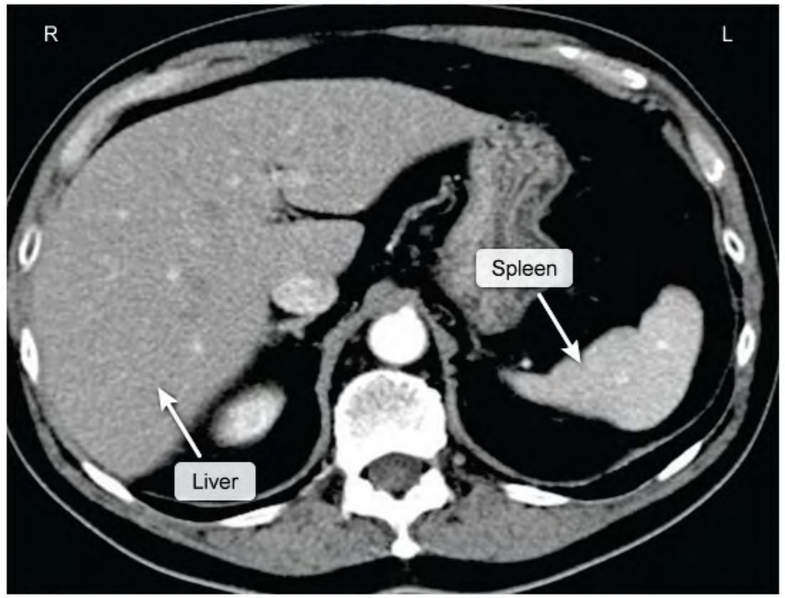

©UWorld

Zoom In | Zoom Out | Reset | New | Existing | My Notebook

The ar
the lef
patien

Most i
pancre
the do
associ

Other

(Choi
medul

(Choi

(Choi

Educa
The sp
contra
dorsal

Embryo
Subject

Copyright © UWorld. All rights reserved.

https://t.me/USMLEWorldStep1

A 60-year-old woman comes to the clinic due to worsening dyspepsia and unintentional weight loss over the past 3 months. Vital signs are normal. There is no cervical or inguinal lymphadenopathy. Abdominal examination shows mild epigastric tenderness. Complete blood count and serum chemistry results are normal. CT scan of the abdomen reveals gastric mucosal thickening but no evidence of abdominal lymphadenopathy or hepatosplenomegaly. Endoscopy shows nodular gastric folds, and biopsy shows proliferation of small, clonal, mucosa-associated B cells expressing the CD20 antigen. Which of the following microbe-induced mechanisms is the most likely underlying cause of the findings seen in this patient?

- A. Chronic immune stimulation
- B. E6 protein–mediated P53 inhibition
- C. Evasion of immune response
- D. Initiation of somatic hypermutation
- E. Integration of microbial genome into host genome

Submit

https://t.me/USMLEWorldStep1

A 60-year-old woman comes to the clinic due to worsening dyspepsia and unintentional weight loss over the past 3 months. Vital signs are normal. There is no cervical or inguinal lymphadenopathy. Abdominal examination shows mild epigastric tenderness. Complete blood count and serum chemistry results are normal. CT scan of the abdomen reveals gastric mucosal thickening but no evidence of abdominal lymphadenopathy or hepatosplenomegaly. Endoscopy shows nodular gastric folds, and biopsy shows proliferation of small, clonal, mucosa-associated B cells expressing the CD20 antigen. Which of the following microbe-induced mechanisms is the most likely underlying cause of the findings seen in this patient?

- ✓ A. Chronic immune stimulation (50%)
- B. E6 protein–mediated P53 inhibition (11%)
- C. Evasion of immune response (18%)
- D. Initiation of somatic hypermutation (11%)
- E. Integration of microbial genome into host genome (8%)

Correct | 50% Answered correctly | 03 secs Time Spent | 2023 Version

Explanation

This patient's gastric nodules composed of small clonal B cells are indicative of an extranodal marginal zone lymphoma involving mucosa-associated lymphoid tissue (**MALT lymphoma**). This form of non-Hodgkin lymphoma arises from post–germinal center memory B cells, which typically express the markers found on all B cells (eg, CD19, CD20), as well as mature B-cell markers (eg, CD22).

Most MALT lymphomas are thought to arise due to **chronic immune stimulation** from bacterial, viral, or autoimmune conditions. The most common trigger for gastric MALT lymphoma is ***Helicobacter pylori* infection**, which leads to local recruitment and proliferation of antigen-specific T and B lymphocytes. Over time, chronic

https://t.me/USMLEWorldStep1

This patient's gastric nodules composed of small clonal B cells are indicative of an extranodal marginal zone lymphoma involving mucosa-associated lymphoid tissue (**MALT lymphoma**). This form of non-Hodgkin lymphoma arises from post–germinal center memory B cells, which typically express the markers found on all B cells (eg, CD19, CD20), as well as mature B-cell markers (eg, CD22).

Most MALT lymphomas are thought to arise due to **chronic immune stimulation** from bacterial, viral, or autoimmune conditions. The most common trigger for gastric MALT lymphoma is ***Helicobacter pylori* infection**, which leads to local recruitment and proliferation of antigen-specific T and B lymphocytes. Over time, chronic immune stimulation results in the emergence of a **monoclonal B-cell** line that proliferates excessively in the presence of *H pylori* antigens. This cell line eventually accumulates genetic abnormalities that allow it to proliferate in an **antigen-independent fashion**, resulting in spread away from the local site of infection.

Because most cases of gastric MALT lymphoma are tightly linked to *H pylori* infection, antimicrobial treatment can often result in complete remission of early-stage disease due to elimination of the bacterial antigens driving tumor proliferation.

(Choices B and E) Certain human papillomavirus (HPV) serotypes cause epithelial cancers of the head, neck, cervix, and anus. Oncogenesis is mediated via production of the viral protein E6, which degrades host P53 protein, a promoter of cell repair after DNA damage and negative regulator of the cell cycle. HPV also integrates into the host genome, resulting in DNA damage that contributes to oncogenesis.

(Choice C) Epstein-Barr virus (EBV) is a lymphotropic, oncogenic virus associated with certain B- and T-cell lymphomas. In latent EBV infection, episomal EBV DNA generates low levels of viral proteins that allow it to evade the host immune response. The viral proteins also activate proliferation-promoting and antiapoptotic host genes, leading to oncogenesis in a minority of cases.

(Choice D) Within B cells, somatic hypermutation at the variable region of the immunoglobulin gene allows the generation of diverse antibodies. Hypermutation allows for B-cell production of high-affinity immunoglobulins against the immunizing antigen; they are not a cause of oncogenesis in MALT lymphomas (which arise from post-germinal center memory B cells).

Educational objective:

https://t.me/USMLEWorldStep1

autoimmune conditions. The most common trigger for gastric MALT lymphoma is ***Helicobacter pylori* infection**, which leads to local recruitment and proliferation of antigen-specific T and B lymphocytes. Over time, chronic immune stimulation results in the emergence of a **monoclonal B-cell** line that proliferates excessively in the presence of *H pylori* antigens. This cell line eventually accumulates genetic abnormalities that allow it to proliferate in an **antigen-independent fashion**, resulting in spread away from the local site of infection.

Because most cases of gastric MALT lymphoma are tightly linked to *H pylori* infection, antimicrobial treatment can often result in complete remission of early-stage disease due to elimination of the bacterial antigens driving tumor proliferation.

(Choices B and E) Certain human papillomavirus (HPV) serotypes cause epithelial cancers of the head, neck, cervix, and anus. Oncogenesis is mediated via production of the viral protein E6, which degrades host P53 protein, a promoter of cell repair after DNA damage and negative regulator of the cell cycle. HPV also integrates into the host genome, resulting in DNA damage that contributes to oncogenesis.

(Choice C) Epstein-Barr virus (EBV) is a lymphotropic, oncogenic virus associated with certain B- and T-cell lymphomas. In latent EBV infection, episomal EBV DNA generates low levels of viral proteins that allow it to evade the host immune response. The viral proteins also activate proliferation-promoting and antiapoptotic host genes, leading to oncogenesis in a minority of cases.

(Choice D) Within B cells, somatic hypermutation at the variable region of the immunoglobulin gene allows the generation of diverse antibodies. Hypermutation allows for B-cell production of high-affinity immunoglobulins against the immunizing antigen; they are not a cause of oncogenesis in MALT lymphomas (which arise from post-germinal center memory B cells).

Educational objective:
Helicobacter pylori is associated with gastric MALT lymphoma due to chronic stimulation of the immune response; the continuous cell division predisposes to accumulation of mutations that result in aberrant B-cell proliferation. Treatment of *H pylori* can induce remission in the majority of cases of early-stage gastric MALT lymphomas.

References

- MALT lymphoma: epidemiology, clinical diagnosis and treatment

https://t.me/USMLEWorldStep1

An 87-year-old woman comes to the office to discuss treatment for colon cancer, which was recently diagnosed by colonoscopy. CT scan was negative for metastatic disease. The patient has no other medical conditions, and family history is unremarkable. She does not drink alcohol. Vital signs are normal. A chemotherapy regimen containing a medication that is primarily metabolized by the liver is chosen for therapy. Because of the patient's age, the physician is considering adjusting the dose to prevent adverse effects. Which of the following parameters is likely to be the most similar between this patient and a healthy 40-year-old individual?

- A. Hepatic concentration of cytochrome P-450
- B. Liver blood perfusion
- C. Rate of hepatic regeneration
- D. Serum aminotransferase levels
- E. Size of the liver

Submit

https://t.me/USMLEWorldStep1

An 87-year-old woman comes to the office to discuss treatment for colon cancer, which was recently diagnosed by colonoscopy. CT scan was negative for metastatic disease. The patient has no other medical conditions, and family history is unremarkable. She does not drink alcohol. Vital signs are normal. A chemotherapy regimen containing a medication that is primarily metabolized by the liver is chosen for therapy. Because of the patient's age, the physician is considering adjusting the dose to prevent adverse effects. Which of the following parameters is likely to be the most similar between this patient and a healthy 40-year-old individual?

- ✗ A. Hepatic concentration of cytochrome P-450 (14%)
- B. Liver blood perfusion (19%)
- C. Rate of hepatic regeneration (5%)
- ✓ D. Serum aminotransferase levels (34%)
- E. Size of the liver (24%)

Incorrect
Correct answer
D

34%
Answered correctly

03 secs
Time Spent

2023
Version

Explanation

Effect of aging on the liver	
Anatomic changes	• Decreased liver size/mass ◦ Due to decreased hepatic perfusion
Physiologic changes	• Decreased regenerative capacity • Decreased activity of cytochrome P-450 system • Decreased protein (eg, albumin, clotting factors) synthesis
	• Increased hepatocyte size

https://t.me/USMLEWorldStep1

Effect of aging on the liver	
Anatomic changes	• Decreased liver size/mass ◦ Due to decreased hepatic perfusion
Physiologic changes	• Decreased regenerative capacity • Decreased activity of cytochrome P-450 system • Decreased protein (eg, albumin, clotting factors) synthesis
Histologic changes	• Increased hepatocyte size • Increased polyploidy • Accumulation of lipofuscin (brown atrophy)

A number of **age-related changes** take place in the liver that impair its ability to metabolize drugs. These changes place elderly individuals, such as this patient, at higher risk for drug-related toxicity. Normal age-related changes include the following:

- **Decreased liver mass**, which is largely explained by the **decrease in hepatic blood flow** that occurs with aging, can impair metabolism because the liver is unable to take up as much drug from the systemic circulation as it once could.
- **Decreased cytochrome P-450** expression and concentration slows the rate of hepatic metabolism of numerous drugs (eg, some antineoplastic agents).
- **Reduced rate of hepatic regeneration** impairs the liver's ability to recover after injury.

Although the liver's metabolic capabilities generally decline with age, **aminotransferase levels are unchanged** in healthy elderly individuals. Elevations in liver enzymes should therefore raise suspicion for undiagnosed hepatic disease or hepatotoxin exposure. Small variations may be seen in bilirubin, alkaline phosphatase, and gamma-glutamyltransferase levels, but they are generally minimal.

(Choices A, B, C, and E) Concentration of cytochrome P-450 and the liver's perfusion, regenerative capabilities, and size are all decreased in the elderly compared to younger individuals.

https://t.me/USMLEWorldStep1

	• Decreased protein (eg, albumin, clotting factors) synthesis
Histologic changes	• Increased hepatocyte size • Increased polyploidy • Accumulation of lipofuscin (brown atrophy)

A number of **age-related changes** take place in the liver that impair its ability to metabolize drugs. These changes place elderly individuals, such as this patient, at higher risk for drug-related toxicity. Normal age-related changes include the following:

- **Decreased liver mass**, which is largely explained by the **decrease in hepatic blood flow** that occurs with aging, can impair metabolism because the liver is unable to take up as much drug from the systemic circulation as it once could.
- **Decreased cytochrome P-450** expression and concentration slows the rate of hepatic metabolism of numerous drugs (eg, some antineoplastic agents).
- **Reduced rate of hepatic regeneration** impairs the liver's ability to recover after injury.

Although the liver's metabolic capabilities generally decline with age, **aminotransferase levels are unchanged** in healthy elderly individuals. Elevations in liver enzymes should therefore raise suspicion for undiagnosed hepatic disease or hepatotoxin exposure. Small variations may be seen in bilirubin, alkaline phosphatase, and gamma-glutamyltransferase levels, but they are generally minimal.

(Choices A, B, C, and E) Concentration of cytochrome P-450 and the liver's perfusion, regenerative capabilities, and size are all decreased in the elderly compared to younger individuals.

Educational objective:
A number of changes occur in the liver with aging that can affect drug metabolism. Typical changes include decreased liver mass and blood flow, decreased cytochrome P-450 expression and concentration, and reduced hepatic regeneration after injury. However, hepatic aminotransferase levels are unchanged.

References

- Liver physiology and liver diseases in the elderly.

https://t.me/USMLEWorldStep1

A 42-year-old man comes to the office due to increased abdominal girth associated with a 9-kg (19.8-lb) weight gain over the past month. He drinks a liter of vodka daily and denies smoking or using intravenous drugs. Blood pressure is 110/70 mm Hg. The abdomen is moderately distended, and a fluid wave is elicited. Multiple spider angiomas are present. Laboratory studies reveal thrombocytopenia, hypoalbuminemia, a normal sodium level, and an elevated PT. An upper endoscopy is performed, which shows no esophageal or gastric varices. Pharmacotherapy aimed at inhibiting which of the following should be considered for this patient?

- A. Aldosterone
- B. Alpha-adrenergic receptors
- C. Angiotensin
- D. Antidiuretic hormone
- E. Prostaglandins

Submit

https://t.me/USMLEWorldStep1

A 42-year-old man comes to the office due to increased abdominal girth associated with a 9-kg (19.8-lb) weight gain over the past month. He drinks a liter of vodka daily and denies smoking or using intravenous drugs. Blood pressure is 110/70 mm Hg. The abdomen is moderately distended, and a fluid wave is elicited. Multiple spider angiomas are present. Laboratory studies reveal thrombocytopenia, hypoalbuminemia, a normal sodium level, and an elevated PT. An upper endoscopy is performed, which shows no esophageal or gastric varices. Pharmacotherapy aimed at inhibiting which of the following should be considered for this patient?

- ✓ A. Aldosterone (48%)
- B. Alpha-adrenergic receptors (6%)
- C. Angiotensin (14%)
- D. Antidiuretic hormone (22%)
- E. Prostaglandins (9%)

Correct | 48% Answered correctly | 03 secs Time Spent | 2023 Version

Explanation

This patient with abdominal distension and a fluid wave has **ascites**. His heavy alcohol use and evidence of chronic liver disease (eg, spider angiomas, thrombocytopenia, hypoalbuminemia, elevated PT) suggest the ascites developed due to **alcohol-associated cirrhosis**.

In cirrhosis, portal hypertension leads to splanchnic vasodilation, which decreases the effective arterial volume and lowers the systemic blood pressure. Renal perfusion is reduced, leading to activation of the renin-angiotensin-aldosterone system (RAAS), which promotes vasoconstriction (due to angiotensin) and fluid and sodium retention by the kidneys (due to aldosterone). Although this improves systemic blood pressure and renal perfusion, due to the altered hemodynamics in patients with cirrhosis (eg, elevated hydrostatic pressure due to portal hypertension,

https://t.me/USMLEWorldStep1

This patient with abdominal distension and a fluid wave has **ascites**. His heavy alcohol use and evidence of chronic liver disease (eg, spider angiomas, thrombocytopenia, hypoalbuminemia, elevated PT) suggest the ascites developed due to **alcohol-associated cirrhosis**.

In cirrhosis, portal hypertension leads to splanchnic vasodilation, which decreases the effective arterial volume and lowers the systemic blood pressure. Renal perfusion is reduced, leading to activation of the renin-angiotensin-aldosterone system (RAAS), which promotes vasoconstriction (due to angiotensin) and fluid and sodium retention by the kidneys (due to aldosterone). Although this improves systemic blood pressure and renal perfusion, due to the altered hemodynamics in patients with cirrhosis (eg, elevated hydrostatic pressure due to portal hypertension, low oncotic pressure due to hypoalbuminemia) it ultimately results in third spacing of fluid with edema and ascites.

Spironolactone, an **aldosterone antagonist**, is used to interrupt this cycle. It induces natriuresis without blocking the critical vasoconstrictive effects of angiotensin. Spironolactone is typically used with furosemide (a loop diuretic) to increase the efficacy of natriuresis and prevent electrolyte disturbances.

(Choices B and C) Patients with cirrhosis have low mean arterial pressure due to splanchnic vasodilation and are dependent on the RAAS to help normalize blood pressure and renal perfusion. ACE inhibitors (eg, lisinopril) and angiotensin receptor blockers blunt this critical response and promote organ hypoperfusion. Likewise, blockade of alpha-adrenergic receptors would cause widespread vasodilation with decreased systemic blood pressure, worsening renal perfusion and causing additional fluid accumulation.

(Choice D) Antidiuretic hormone (ADH) levels are increased in cirrhosis, which contributes to the development of hypervolemic hyponatremia. Although ADH inhibitors (eg, tolvapatan) have been used to treat severe hyponatremia in cirrhosis, they are not indicated in patients with normal sodium levels.

(Choice E) Nonsteroidal anti-inflammatory drugs inhibit prostaglandin production, which can cause renal vasoconstriction and may precipitate gastrointestinal bleeding. These medications should be avoided in patients with cirrhosis due to impaired renal perfusion at baseline and high risk of variceal bleeding.

Educational objective:
Ascites in cirrhosis develops from hemodynamic changes related to portal hypertension. Splanchnic vasodilation decreases the systemic vascular resistance, which causes activation of the renin-angiotensin-aldosterone system and promotes vasoconstriction and sodium and water retention. Spironolactone, an aldosterone antagonist, is

https://t.me/USMLEWorldStep1

In cirrhosis, portal hypertension leads to splanchnic vasodilation, which decreases the effective arterial volume and lowers the systemic blood pressure. Renal perfusion is reduced, leading to activation of the renin-angiotensin-aldosterone system (RAAS), which promotes vasoconstriction (due to angiotensin) and fluid and sodium retention by the kidneys (due to aldosterone). Although this improves systemic blood pressure and renal perfusion, due to the altered hemodynamics in patients with cirrhosis (eg, elevated hydrostatic pressure due to portal hypertension, low oncotic pressure due to hypoalbuminemia) it ultimately results in third spacing of fluid with edema and ascites.

Spironolactone, an **aldosterone antagonist**, is used to interrupt this cycle. It induces natriuresis without blocking the critical vasoconstrictive effects of angiotensin. Spironolactone is typically used with furosemide (a loop diuretic) to increase the efficacy of natriuresis and prevent electrolyte disturbances.

(Choices B and C) Patients with cirrhosis have low mean arterial pressure due to splanchnic vasodilation and are dependent on the RAAS to help normalize blood pressure and renal perfusion. ACE inhibitors (eg, lisinopril) and angiotensin receptor blockers blunt this critical response and promote organ hypoperfusion. Likewise, blockade of alpha-adrenergic receptors would cause widespread vasodilation with decreased systemic blood pressure, worsening renal perfusion and causing additional fluid accumulation.

(Choice D) Antidiuretic hormone (ADH) levels are increased in cirrhosis, which contributes to the development of hypervolemic hyponatremia. Although ADH inhibitors (eg, tolvapatan) have been used to treat severe hyponatremia in cirrhosis, they are not indicated in patients with normal sodium levels.

(Choice E) Nonsteroidal anti-inflammatory drugs inhibit prostaglandin production, which can cause renal vasoconstriction and may precipitate gastrointestinal bleeding. These medications should be avoided in patients with cirrhosis due to impaired renal perfusion at baseline and high risk of variceal bleeding.

Educational objective:
Ascites in cirrhosis develops from hemodynamic changes related to portal hypertension. Splanchnic vasodilation decreases the systemic vascular resistance, which causes activation of the renin-angiotensin-aldosterone system and promotes vasoconstriction and sodium and water retention. Spironolactone, an aldosterone antagonist, is used to induce natriuresis and resolve ascites without blocking the critical vasoconstrictive effects of angiotensin.

References

- Introduction to the revised American Association for the Study of Liver Diseases practice guideline

https://t.me/USMLEWorldStep1

Exhibit Display

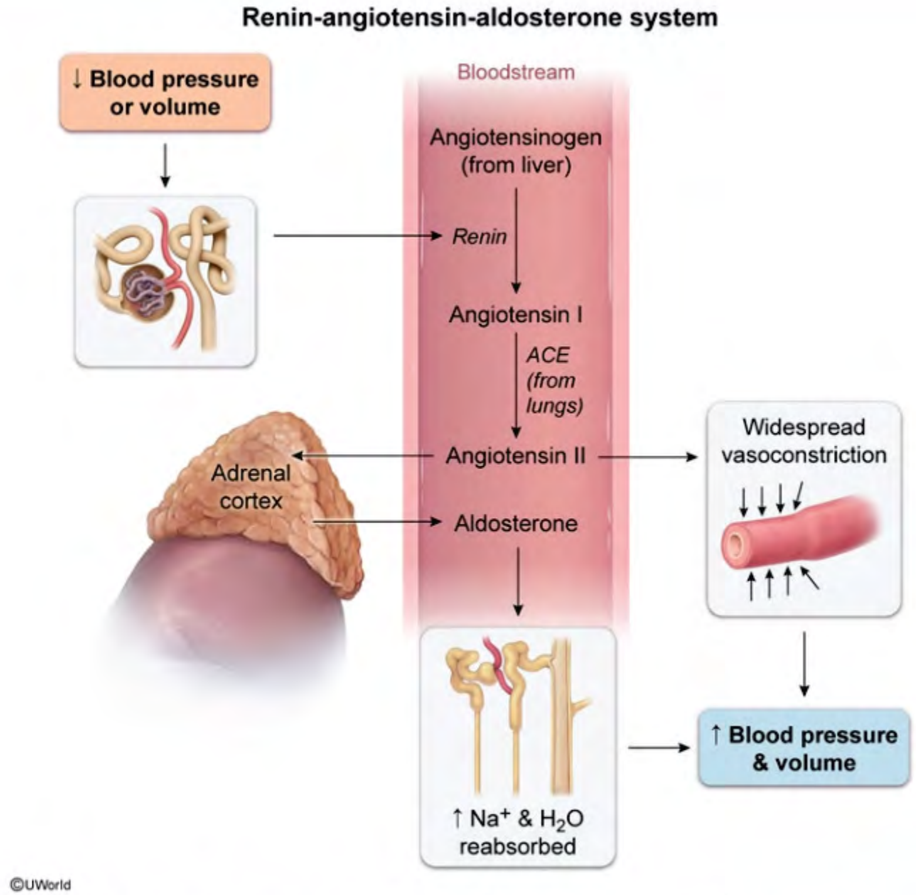

Zoom In | Zoom Out | Reset | New | Existing | My Notebook

This p
chroni
develo

In cirr
lowers
aldost
by the
the alt
low on

Spiro
the cri
to incr

(Choi
depen
angiot
of alph
worse

(Choi
hyperv
hypon

(Choi
vasoc
with cirrhosis due to impaired renal perfusion at baseline and high risk of variceal bleeding.

https://t.me/USMLEWorldStep1

An investigator is studying weight regulation using experimental mouse models. Knockout mice are created with a homozygous mutation in the gene coding for the leptin receptor. This mutation prevents the receptor from binding leptin and initiating its normal signaling cascade. The knockout mice are allowed to feed at will, and their body mass index (BMI) and serum leptin levels are measured and compared with control mice. On the graph below, area C represents the normal relationship between BMI and leptin in a control mouse.

Which of the following areas represents the expected relationship between BMI and serum leptin levels in a leptin receptor mutant mouse?

- A. A
- B. B
- C. C
- D. D
- E. E

Submit

https://t.me/USMLEWorldStep1

An inv
homoz
leptin
mass i
area C

Which
recept

Exhibit Display

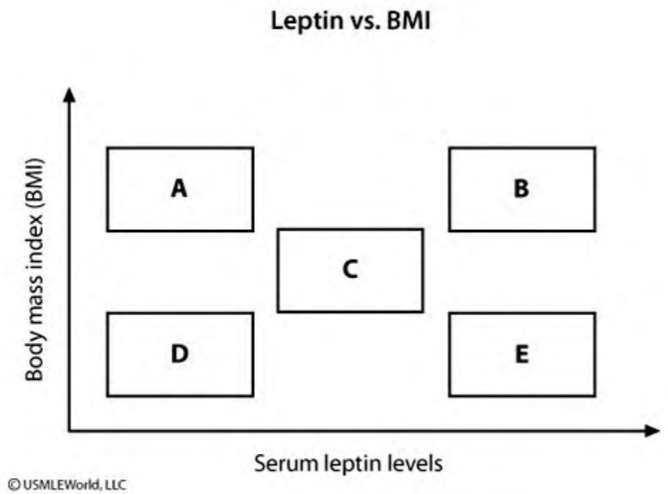

Zoom In
Zoom Out
Reset
New | Existing
My Notebook

D. D
E. E

homozygous mutation in the gene coding for the leptin receptor. This mutation prevents the receptor from binding leptin and initiating its normal signaling cascade. The knockout mice are allowed to feed at will, and their body mass index (BMI) and serum leptin levels are measured and compared with control mice. On the graph below, area C represents the normal relationship between BMI and leptin in a control mouse.

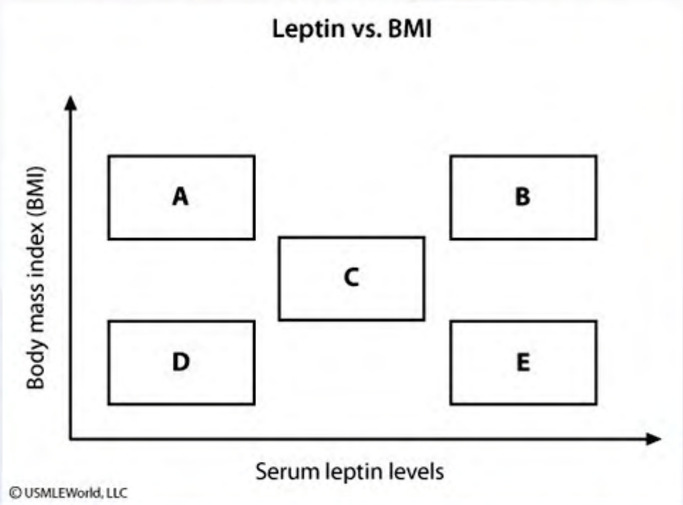

Which of the following areas represents the expected relationship between BMI and serum leptin levels in a leptin receptor mutant mouse?

- A. A
- B. B
- C. C
- D. D
- E. E

Submit

https://t.me/USMLEWorldStep1

homozygous mutation in the gene coding for the leptin receptor. This mutation prevents the receptor from binding leptin and initiating its normal signaling cascade. The knockout mice are allowed to feed at will, and their body mass index (BMI) and serum leptin levels are measured and compared with control mice. On the graph below, area C represents the normal relationship between BMI and leptin in a control mouse.

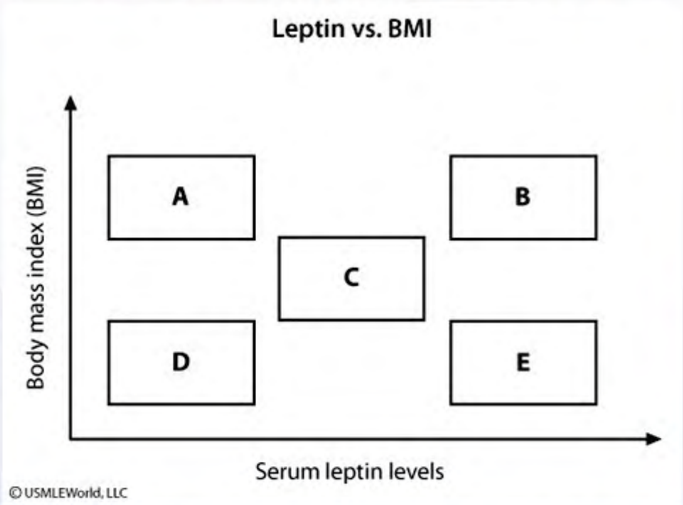

Which of the following areas represents the expected relationship between BMI and serum leptin levels in a leptin receptor mutant mouse?

- ✗ A. A (15%)
- ✓ B. B (68%)
- C. C (1%)
- D. D (3%)
- E. E (10%)

Incorrect
Correct answer
B

68%
Answered correctly

11 secs
Time Spent

2023
Version

https://t.me/USMLEWorldStep1

Explanation

Leptin is a protein hormone that plays an important role in regulating appetite and metabolism. It is produced primarily in adipocytes, and large fat cells produce more leptin than small ones. Serum leptin concentrations are highly correlated with body fat content.

Leptin decreases food intake in the following important ways:

1. Leptin decreases the production of neuropeptide Y, a potent appetite stimulant, in the arcuate nucleus of the hypothalamus.
2. Leptin stimulates the production of proopiomelanocortin (POMC) in the arcuate nucleus. Alpha-melanocyte-stimulating hormone (alpha-MSH) is produced by cleavage of POMC and inhibits food intake.

The knockout mouse described is homozygous for a mutation in the gene encoding the leptin receptor (db/db), resulting in ineffective leptin signaling. As a result, these mice become hyperphagic and profoundly obese. As leptin production is normal in these mice, leptin levels are elevated due to the increased lipocyte mass. In contrast, mice that are homozygous for a mutation resulting in impaired leptin production (ob/ob) also become hyperphagic and profoundly obese, but their leptin levels are low **(Choice A)**.

Human obesity resulting from mutations in the leptin receptor and the leptin gene has been described. However, most obese individuals do not have either of these mutations. Instead, it is thought that the sustained elevation in leptin levels from the enlarged fat stores results in leptin desensitization. Thus, obese individuals become resistant to the effects of leptin in a manner similar to the development of insulin resistance in type 2 diabetes.

(Choice D) Low leptin and low BMI correlate with low adipocyte stores and may be seen after prolonged starvation.

(Choice E) With intact receptor signaling, elevated leptin levels (ie, from exogenous leptin administration) would result in weight loss.

Educational objective:
Leptin is a protein hormone produced by adipocytes in proportion to the quantity of fat stored. Leptin acts on the arcuate nucleus of the hypothalamus to inhibit production of neuropeptide Y (decreasing appetite) and stimulate

https://t.me/USMLEWorldStep1

primarily in adipocytes, and large fat cells produce more leptin than small ones. Serum leptin concentrations are highly correlated with body fat content.

Leptin decreases food intake in the following important ways:

1. Leptin decreases the production of neuropeptide Y, a potent appetite stimulant, in the arcuate nucleus of the hypothalamus.
2. Leptin stimulates the production of proopiomelanocortin (POMC) in the arcuate nucleus. Alpha-melanocyte-stimulating hormone (alpha-MSH) is produced by cleavage of POMC and inhibits food intake.

The knockout mouse described is homozygous for a mutation in the gene encoding the leptin receptor (db/db), resulting in ineffective leptin signaling. As a result, these mice become hyperphagic and profoundly obese. As leptin production is normal in these mice, leptin levels are elevated due to the increased lipocyte mass. In contrast, mice that are homozygous for a mutation resulting in impaired leptin production (ob/ob) also become hyperphagic and profoundly obese, but their leptin levels are low **(Choice A)**.

Human obesity resulting from mutations in the leptin receptor and the leptin gene has been described. However, most obese individuals do not have either of these mutations. Instead, it is thought that the sustained elevation in leptin levels from the enlarged fat stores results in leptin desensitization. Thus, obese individuals become resistant to the effects of leptin in a manner similar to the development of insulin resistance in type 2 diabetes.

(Choice D) Low leptin and low BMI correlate with low adipocyte stores and may be seen after prolonged starvation.

(Choice E) With intact receptor signaling, elevated leptin levels (ie, from exogenous leptin administration) would result in weight loss.

Educational objective:
Leptin is a protein hormone produced by adipocytes in proportion to the quantity of fat stored. Leptin acts on the arcuate nucleus of the hypothalamus to inhibit production of neuropeptide Y (decreasing appetite) and stimulate production of alpha-MSH (increasing satiety). Mutations in the leptin gene or receptor result in hyperphagia and profound obesity.

References

https://t.me/USMLEWorldStep1

A 54-year-old man with a history of hepatitis C infection is brought to the emergency department by his wife after several episodes of vomiting bright red blood. He is admitted to the hospital and the appropriate treatment is initiated. During morning rounds the next day, the patient is disoriented and cannot identify the month or his current location. Physical examination shows significant abdominal distention and gynecomastia. Repetitive flicking motions of the hands are seen when the patient is asked to outstretch his arms and dorsiflex his wrists. Which of the following is most likely contributing to this patient's altered mental status?

- A. Accumulation of blood urea nitrogen
- B. Bacterial infection of the meninges
- C. Decreased gamma-aminobutyric acid receptor stimulation
- D. Increased absorption of nitrogenous substances by the gut
- E. Occlusion of the middle cerebral artery

Submit

https://t.me/USMLEWorldStep1

A 54-year-old man with a history of hepatitis C infection is brought to the emergency department by his wife after several episodes of vomiting bright red blood. He is admitted to the hospital and the appropriate treatment is initiated. During morning rounds the next day, the patient is disoriented and cannot identify the month or his current location. Physical examination shows significant abdominal distention and gynecomastia. Repetitive flicking motions of the hands are seen when the patient is asked to outstretch his arms and dorsiflex his wrists. Which of the following is most likely contributing to this patient's altered mental status?

- A. Accumulation of blood urea nitrogen (46%)
- ✕ B. Bacterial infection of the meninges (0%)
- C. Decreased gamma-aminobutyric acid receptor stimulation (8%)
- ✓ D. Increased absorption of nitrogenous substances by the gut (43%)
- E. Occlusion of the middle cerebral artery (0%)

Incorrect
Correct answer
D

43%
Answered correctly

04 secs
Time Spent

2023
Version

Explanation

Hepatic encephalopathy	
Precipitating factors	• Drugs (eg, sedatives, narcotics) • Hypovolemia (eg, diarrhea) • Electrolyte changes (eg, hypokalemia) • ↑ Nitrogen load (eg, GI bleeding) • Infection (eg, pneumonia, UTI, SBP) • Portosystemic shunting (eg, TIPS)

https://t.me/USMLEWorldStep1

Hepatic encephalopathy	
Precipitating factors	• Drugs (eg, sedatives, narcotics) • Hypovolemia (eg, diarrhea) • Electrolyte changes (eg, hypokalemia) • ↑ Nitrogen load (eg, GI bleeding) • Infection (eg, pneumonia, UTI, SBP) • Portosystemic shunting (eg, TIPS)
Clinical presentation	• Sleep pattern changes • Altered mental status • Ataxia • Asterixis
Treatment	• Correct precipitating causes (eg, fluids, antibiotics) • ↓ Blood ammonia concentration (eg, lactulose, rifaximin)
GI = gastrointestinal; **SBP** = spontaneous bacterial peritonitis; **TIPS** = transjugular intrahepatic portosystemic shunt; **UTI** = urinary tract infection.	

This patient with cirrhosis (hepatitis C infection, abdominal distention, gynecomastia) most likely developed **hepatic encephalopathy** due to his recent **gastrointestinal (GI) bleed**. Hepatic encephalopathy refers to a reversible decline in neurologic function that occurs due to failure of the liver to metabolize waste products such as ammonia. Ammonia is normally produced by the GI tract as a result of enterocytic catabolism of glutamine and colonic bacterial catabolism of dietary protein. GI bleeding causes **increased nitrogen delivery** to the gut in the form of hemoglobin, which is then converted into ammonia and absorbed into the bloodstream. The ammonia then enters the liver through the portal vein and is detoxified to urea.

In chronic liver failure, hepatocyte dysfunction and the shunting of blood through portosystemic collaterals impair the liver's detoxification ability. This leads to **accumulation of ammonia** and other neurotoxins in the circulation, causing altered amino acid transport across the blood-brain barrier, impaired neurotransmitter metabolism, and depressed cerebral glucose metabolism. These and other factors result in **increased inhibitory**

https://t.me/USMLEWorldStep1

Clinical presentation	• Ataxia • Asterixis
Treatment	• Correct precipitating causes (eg, fluids, antibiotics) • ↓ Blood ammonia concentration (eg, lactulose, rifaximin)
GI = gastrointestinal; **SBP** = spontaneous bacterial peritonitis; **TIPS** = transjugular intrahepatic portosystemic shunt; **UTI** = urinary tract infection.	

This patient with cirrhosis (hepatitis C infection, abdominal distention, gynecomastia) most likely developed **hepatic encephalopathy** due to his recent **gastrointestinal (GI) bleed**. Hepatic encephalopathy refers to a reversible decline in neurologic function that occurs due to failure of the liver to metabolize waste products such as ammonia. Ammonia is normally produced by the GI tract as a result of enterocytic catabolism of glutamine and colonic bacterial catabolism of dietary protein. GI bleeding causes **increased nitrogen delivery** to the gut in the form of hemoglobin, which is then converted into ammonia and absorbed into the bloodstream. The ammonia then enters the liver through the portal vein and is detoxified to urea.

In chronic liver failure, hepatocyte dysfunction and the shunting of blood through portosystemic collaterals impair the liver's detoxification ability. This leads to **accumulation of ammonia** and other neurotoxins in the circulation, causing altered amino acid transport across the blood-brain barrier, impaired neurotransmitter metabolism, and depressed cerebral glucose metabolism. These and other factors result in **increased inhibitory neurotransmission** (eg, γ-aminobutyric acid [GABA]) and **impaired excitatory neurotransmitter release** (eg, glutamate, catecholamines).

In patients with hepatic encephalopathy, lowering of blood ammonia levels is typically accomplished with oral administration of a disaccharide (eg, **lactulose**). Bacterial action on lactulose results in acidification of colonic contents, which then converts absorbable ammonia into nonabsorbable ammonium ions, trapping it in the stool and thereby increasing fecal nitrogen excretion.

(Choice A) Accumulation of blood urea nitrogen (BUN) is suggestive of renal failure, heart failure, or dehydration. In healthy patients, GI bleeding can also cause a rapid increase in BUN. However, this patient has cirrhosis, which is associated with decreased BUN because ammonia cannot be efficiently converted to urea by the failing liver.

https://t.me/USMLEWorldStep1

enters the liver through the portal vein and is detoxified to urea.

In chronic liver failure, hepatocyte dysfunction and the shunting of blood through portosystemic collaterals impair the liver's detoxification ability. This leads to **accumulation of ammonia** and other neurotoxins in the circulation, causing altered amino acid transport across the blood-brain barrier, impaired neurotransmitter metabolism, and depressed cerebral glucose metabolism. These and other factors result in **increased inhibitory neurotransmission** (eg, γ-aminobutyric acid [GABA]) and **impaired excitatory neurotransmitter release** (eg, glutamate, catecholamines).

In patients with hepatic encephalopathy, lowering of blood ammonia levels is typically accomplished with oral administration of a disaccharide (eg, **lactulose**). Bacterial action on lactulose results in acidification of colonic contents, which then converts absorbable ammonia into nonabsorbable ammonium ions, trapping it in the stool and thereby increasing fecal nitrogen excretion.

(Choice A) Accumulation of blood urea nitrogen (BUN) is suggestive of renal failure, heart failure, or dehydration. In healthy patients, GI bleeding can also cause a rapid increase in BUN. However, this patient has cirrhosis, which is associated with decreased BUN because ammonia cannot be efficiently converted to urea by the failing liver.

(Choice B) Bacterial meningitis presents with altered mental status, fever, nuchal rigidity, headache, and photophobia. In addition, asterixis (flapping tremor) is specific for metabolic encephalopathies.

(Choice C) The altered mental status seen in hepatic encephalopathy is due to increased (not decreased) activity of the GABA neurotransmitter system. This enhanced activity is caused by increased GABA receptor affinity and alterations in neurosteroid synthesis rather than increased GABA production.

(Choice E) The middle cerebral artery is the largest cerebral artery and the one most commonly involved in cerebrovascular accidents. This patient's presentation is suggestive of hepatic encephalopathy rather than stroke.

Educational objective:
Hepatic encephalopathy is caused by increased levels of ammonia and other neurotoxins in the circulation that lead to increased inhibitory neurotransmission and impaired excitatory neurotransmitter release. Hepatic encephalopathy is frequently precipitated by a stressor (eg, gastrointestinal bleeding, infection) that increases blood ammonia levels.

https://t.me/USMLEWorldStep1

A 14-year-old boy is brought to the physician by his mother due to chronic diarrhea and failure to gain weight appropriately. He has a history of recurrent respiratory infections, and prior sputum cultures have been positive for *Pseudomonas aeruginosa*. His younger brother died from a severe respiratory infection at age 9. Which of the following agents is most likely to improve this patient's condition in the long term?

- A. Antimotility agents
- B. Gluten-free diet
- C. Metronidazole
- D. Octreotide
- E. Pancreatic lipase
- F. Sulfasalazine

Submit

https://t.me/USMLEWorldStep1

A 14-year-old boy is brought to the physician by his mother due to chronic diarrhea and failure to gain weight appropriately. He has a history of recurrent respiratory infections, and prior sputum cultures have been positive for *Pseudomonas aeruginosa*. His younger brother died from a severe respiratory infection at age 9. Which of the following agents is most likely to improve this patient's condition in the long term?

- A. Antimotility agents (2%)
- B. Gluten-free diet (6%)
- ✗ C. Metronidazole (5%)
- D. Octreotide (5%)
- ✓ E. Pancreatic lipase (71%)
- F. Sulfasalazine (8%)

Incorrect
Correct answer
E

71%
Answered correctly

03 secs
Time Spent

2023
Version

Explanation

Features of cystic fibrosis	
Pathogenesis	• Autosomal recessive mutation (**ΔF508**) impairs CFTR function • Decreased water content causes **thick, viscous mucus**: ◦ Chronic airway obstruction ◦ Gastrointestinal malabsorption
	• Chronic, productive cough

https://t.me/USMLEWorldStep1

Explanation

Features of cystic fibrosis	
Pathogenesis	• Autosomal recessive mutation (**ΔF508**) impairs CFTR function • Decreased water content causes **thick, viscous mucus**: ◦ Chronic airway obstruction ◦ Gastrointestinal malabsorption
Clinical manifestations	• Chronic, productive cough • Recurrent **sinopulmonary infections** (eg, *Staphylococcus aureus*, *Pseudomonas aeruginosa*, & *Burkholderia cepacia* complex) • **Pancreatic insufficiency** • Male infertility (bilateral absence of vas deferens)
Diagnosis	• Elevated sweat chloride levels • Nasal potential difference measurements • Genetic testing for *CFTR* mutations
CFTR = cystic fibrosis transmembrane conductance regulator.	

This young patient has a history of recurrent respiratory infections caused by *Pseudomonas aeruginosa*, chronic diarrhea, and failure to thrive. These findings, along with a family history of early sibling death from pulmonary infection, suggest a diagnosis of cystic fibrosis. Steatorrhea and failure to thrive occur as a result of malabsorption due to obstructive fibrosis and progressive insufficiency of the exocrine pancreas. Pancreatic lipase

https://t.me/USMLEWorldStep1

This young patient has a history of recurrent respiratory infections caused by *Pseudomonas aeruginosa*, chronic diarrhea, and failure to thrive. These findings, along with a family history of early sibling death from pulmonary infection, suggest a diagnosis of cystic fibrosis. Steatorrhea and failure to thrive occur as a result of malabsorption due to obstructive fibrosis and progressive insufficiency of the exocrine pancreas. Pancreatic lipase supplementation is likely to improve this patient's condition by enhancing macronutrient and vitamin absorption.

(Choice A) Agents that decrease gastrointestinal motility (eg, opiates such as loperamide) can help decrease the volume of diarrhea by slowing intestinal transit time and allowing greater net fluid resorption. However, antimotility agents would not improve the deficiencies in nutrient absorption.

(Choice B) A gluten-free diet is the mainstay of treatment for celiac sprue but would be unlikely to help this patient's malabsorption.

(Choice C) Metronidazole is effective only for diarrhea due to infectious causes (eg, giardiasis). This patient's diarrhea is more likely due to malabsorption secondary to cystic fibrosis.

(Choice D) Octreotide is a somatostatin analogue that decreases gut motility, blood flow, and endocrine and exocrine pancreatic function. Octreotide decreases secretion of pancreatic enzymes into the intestine and could therefore aggravate this patient's malabsorptive diarrhea and associated nutritional deficiencies.

(Choice F) 5-aminosalicylates (eg, sulfasalazine, mesalamine) are used to treat inflammatory bowel diseases such as Crohn's disease and ulcerative colitis. They work by inhibiting cytokine, prostaglandin, and leukotriene synthesis during inflammation. This patient's diarrhea and weight loss are not caused by inflammation.

Educational objective:
In a young Caucasian patient, the combination of recurrent respiratory infections with *Pseudomonas aeruginosa*, diarrhea, and failure to thrive suggests a diagnosis of cystic fibrosis. Cystic fibrosis causes steatorrhea and failure to thrive due to malabsorption secondary to pancreatic insufficiency, which can be corrected by pancreatic enzyme supplementation.

Pharmacology	Gastrointestinal & Nutrition	Cystic fibrosis
Subject	System	Topic

https://t.me/USMLEWorldStep1

A 54-year-old man is evaluated for episodic abdominal discomfort, bloating sensation, and flatulence along with occasional diarrhea. He has neither visible blood in the stool nor unexplained weight loss. The patient has tried avoiding dairy products, but his symptoms did not improve. On examination, there is mild epigastric tenderness on deep palpation. Stool occult blood testing is positive. Endoscopic evaluation reveals an area of nodular hyperemic mucosa, which is biopsied. Histopathologic evaluation shows hyperplasia affecting branched, tubular submucosal glands containing alkaline secretions. This patient's biopsy specimen was most likely taken from which of the following gastrointestinal sites?

- A. Antrum of the stomach
- B. First part of the duodenum
- C. Fundus of the stomach
- D. Midpart of the jejunum
- E. Terminal ileum
- F. Transverse colon

Submit

https://t.me/USMLEWorldStep1

A 54-year-old man is evaluated for episodic abdominal discomfort, bloating sensation, and flatulence along with occasional diarrhea. He has neither visible blood in the stool nor unexplained weight loss. The patient has tried avoiding dairy products, but his symptoms did not improve. On examination, there is mild epigastric tenderness on deep palpation. Stool occult blood testing is positive. Endoscopic evaluation reveals an area of nodular hyperemic mucosa, which is biopsied. Histopathologic evaluation shows hyperplasia affecting branched, tubular submucosal glands containing alkaline secretions. This patient's biopsy specimen was most likely taken from which of the following gastrointestinal sites?

- ✗ A. Antrum of the stomach (6%)
- ✓ B. First part of the duodenum (73%)
- C. Fundus of the stomach (3%)
- D. Midpart of the jejunum (6%)
- E. Terminal ileum (6%)
- F. Transverse colon (3%)

Incorrect
Correct answer
B

73%
Answered correctly

03 secs
Time Spent

2023
Version

Explanation

This patient's gastrointestinal biopsy demonstrates submucosal glands, a characteristic microscopic feature of the duodenum. The integrity of the duodenal mucosa depends on the complete and rapid neutralization of hydrochloric acid in gastric contents. This is accomplished by **alkaline secretions** from 2 primary sources:

- **Submucosal (Brunner) glands** secrete copious amounts of alkaline mucus. These glands are most numerous in the first part of the **duodenum** (near the pylorus) but may be found intermittently up to the ampulla of Vater. The ducts of these glands pass through the muscularis mucosa and terminate in the

https://t.me/USMLEWorldStep1

Explanation

This patient's gastrointestinal biopsy demonstrates submucosal glands, a characteristic microscopic feature of the duodenum. The integrity of the duodenal mucosa depends on the complete and rapid neutralization of hydrochloric acid in gastric contents. This is accomplished by **alkaline secretions** from 2 primary sources:

- **Submucosal (Brunner) glands** secrete copious amounts of alkaline mucus. These glands are most numerous in the first part of the **duodenum** (near the pylorus) but may be found intermittently up to the ampulla of Vater. The ducts of these glands pass through the muscularis mucosa and terminate in the mucosal crypts (crypts of Lieberkühn).
- The epithelial cells of the pancreatic ductules and ducts produce watery secretions containing high concentrations of bicarbonate ions. The strongly alkaline **pancreatic secretions** are then emptied into the duodenum at the ampulla.

Bicarbonate secretion from the submucosal glands is induced by tactile stimulation of the duodenal mucosa and increased parasympathetic activity following meals. In addition, the presence of acid in the duodenum causes the release of **secretin** from the mucosa, which stimulates bicarbonate secretion from the submucosal glands and pancreas.

Excess gastric acid secretion (eg, caused by antral *Helicobacter pylori* infection) can eventually lead to **hyperplasia** of the submucosal glands, imparting a nodular appearance endoscopically. Increasing levels of gastric acid may ultimately overwhelm the mucosal defense systems, resulting in duodenal mucosal injury (eg, epigastric discomfort, bloating, flatulence, bleeding).

(Choices A and C) The antrum of the stomach contains numerous mucosal pyloric glands that secrete copious mucus for protection. The body and fundus of the stomach contain mucosal oxyntic glands that secrete gastric acid. However, submucosal glands are not present in the stomach.

(Choice D) The mucosal villi and crypts in the jejunum contain goblet cells (secrete mucus) and enterocytes (secrete water and electrolytes); these secretions have only minimal bicarbonate content. Submucosal glands are not present in the jejunum.

https://t.me/USMLEWorldStep1

numerous in the first part of the **duodenum** (near the pylorus) but may be found intermittently up to the ampulla of Vater. The ducts of these glands pass through the muscularis mucosa and terminate in the mucosal crypts (crypts of Lieberkühn).

- The epithelial cells of the pancreatic ductules and ducts produce watery secretions containing high concentrations of bicarbonate ions. The strongly alkaline **pancreatic secretions** are then emptied into the duodenum at the ampulla.

Bicarbonate secretion from the submucosal glands is induced by tactile stimulation of the duodenal mucosa and increased parasympathetic activity following meals. In addition, the presence of acid in the duodenum causes the release of **secretin** from the mucosa, which stimulates bicarbonate secretion from the submucosal glands and pancreas.

Excess gastric acid secretion (eg, caused by antral *Helicobacter pylori* infection) can eventually lead to **hyperplasia** of the submucosal glands, imparting a nodular appearance endoscopically. Increasing levels of gastric acid may ultimately overwhelm the mucosal defense systems, resulting in duodenal mucosal injury (eg, epigastric discomfort, bloating, flatulence, bleeding).

(Choices A and C) The antrum of the stomach contains numerous mucosal pyloric glands that secrete copious mucus for protection. The body and fundus of the stomach contain mucosal oxyntic glands that secrete gastric acid. However, submucosal glands are not present in the stomach.

(Choice D) The mucosal villi and crypts in the jejunum contain goblet cells (secrete mucus) and enterocytes (secrete water and electrolytes); these secretions have only minimal bicarbonate content. Submucosal glands are not present in the jejunum.

(Choices E and F) Bicarbonate is secreted by epithelial cells in the ileal villi and colonic crypts to neutralize acid produced by colonic bacteria. Submucosal glands are not present in these locations.

Educational objective:
Gastric acid is neutralized by bicarbonate from the submucosal (Brunner) glands of the duodenum and from pancreatic duct secretions. Chronic overproduction of gastric acid can lead to hyperplasia of the submucosal glands.

https://t.me/USMLEWorldStep1

Explanation

This p
duode
hydroc

- S
  n
  a
  m
- T
  c
  d

Bicarb
increa
releas
pancre

Exces
hyper
gastric
epigas

(Choi
mucus
acid.

(Choi
(secrete water and electrolytes); these secretions have only minimal bicarbonate content. Submucosal glands are not present in the jejunum.

Exhibit Display

Normal duodenum

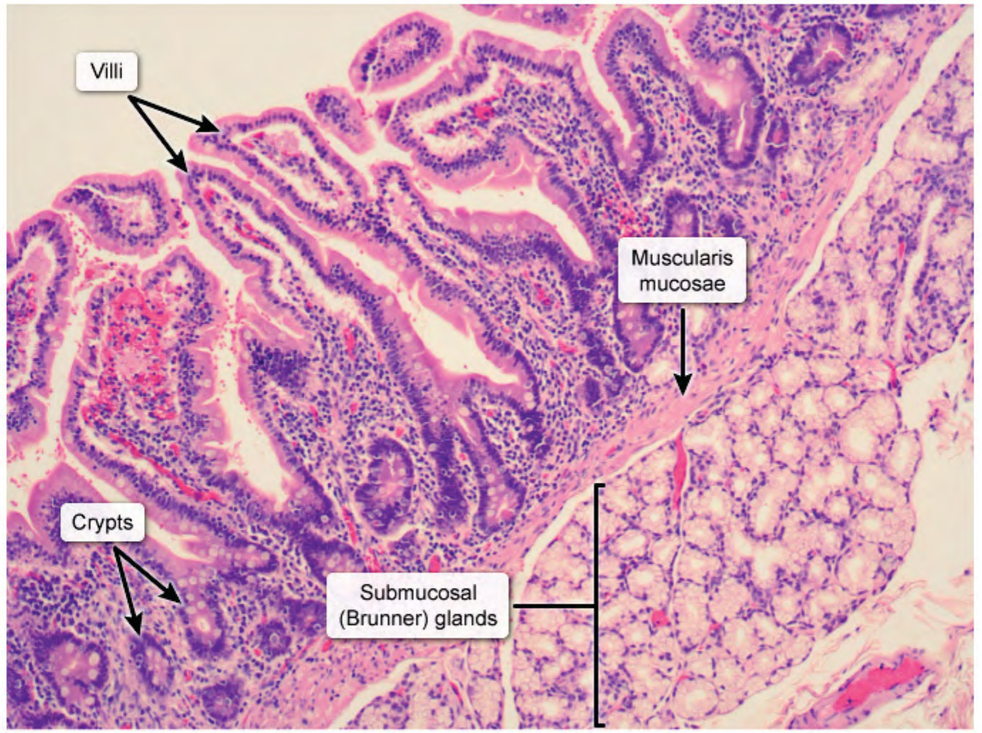

©UWorld

Zoom In | Zoom Out | Reset | New | Existing | My Notebook

https://t.me/USMLEWorldStep1

Researchers studying embryologic development observe a disruption in the differentiation of the endoderm within the gastrointestinal system of a developing fetus. Which of the following processes is most likely to be affected?

- A. Intestinal relaxation
- B. Pancreatic enzyme production
- C. Peritoneal layer formation
- D. Salivary gland secretion
- E. Splenic filtration

Submit

https://t.me/USMLEWorldStep1

Researchers studying embryologic development observe a disruption in the differentiation of the endoderm within the gastrointestinal system of a developing fetus. Which of the following processes is most likely to be affected?

- A. Intestinal relaxation (17%)
- ✓ B. Pancreatic enzyme production (41%)
- C. Peritoneal layer formation (21%)
- D. Salivary gland secretion (9%)
- E. Splenic filtration (9%)

Correct

41% Answered correctly

03 secs Time Spent

2023 Version

Explanation

Embryologic derivatives		
Ectoderm	Surface ectoderm	• Anterior pituitary (Rathke pouch) • Lens & cornea • Inner ear sensory organs, olfactory epithelium • Nasal & oral epithelial linings, salivary glands • Epidermis, sweat & mammary glands
	Neural tube	• Brain & spinal cord • Posterior pituitary, pineal gland • Retina
		• Neural ganglia, adrenal medulla • Schwann cells; pia & arachnoid mater

https://t.me/USMLEWorldStep1

Embryologic derivatives		
Ectoderm	Surface ectoderm	• Anterior pituitary (Rathke pouch) • Lens & cornea • Inner ear sensory organs, olfactory epithelium • Nasal & oral epithelial linings, salivary glands • Epidermis, sweat & mammary glands
	Neural tube	• Brain & spinal cord • Posterior pituitary, pineal gland • Retina
	Neural crest	• Neural ganglia, adrenal medulla • Schwann cells; pia & arachnoid mater • Aorticopulmonary septum & endocardial cushions • Branchial arches (bones & cartilage) • Skull bones • Melanocytes
Mesoderm		• Muscles (skeletal, cardiac & smooth) • Connective tissue, bone & cartilage • Serosal linings (eg, peritoneum) • Cardiovascular & lymphatic system • Spleen & hemopoietic cells • Kidney & ureters, internal genitalia • Adrenal cortex
Endoderm		• Gastrointestinal tract, liver, pancreas • Lungs • Thymus, parathyroids, thyroid follicular cells • Middle ear epithelium • Bladder & urethra

https://t.me/USMLEWorldStep1

Ectoderm	Surface ectoderm	• Inner ear sensory organs, olfactory epithelium • Nasal & oral epithelial linings, salivary glands • Epidermis, sweat & mammary glands
	Neural tube	• Brain & spinal cord • Posterior pituitary, pineal gland • Retina
	Neural crest	• Neural ganglia, adrenal medulla • Schwann cells; pia & arachnoid mater • Aorticopulmonary septum & endocardial cushions • Branchial arches (bones & cartilage) • Skull bones • Melanocytes
Mesoderm		• Muscles (skeletal, cardiac & smooth) • Connective tissue, bone & cartilage • Serosal linings (eg, peritoneum) • Cardiovascular & lymphatic system • Spleen & hemopoietic cells • Kidney & ureters, internal genitalia • Adrenal cortex
Endoderm		• Gastrointestinal tract, liver, pancreas • Lungs • Thymus, parathyroids, thyroid follicular cells • Middle ear epithelium • Bladder & urethra • Parafollicular (C) cells*

*Formerly thought to be of neural crest origin.

https://t.me/USMLEWorldStep1

Endoderm	• Thymus, parathyroids, thyroid follicular cells • Middle ear epithelium • Bladder & urethra • Parafollicular (C) cells*
*Formerly thought to be of neural crest origin.	

Gastrulation marks the beginning of the embryonic stage of development and establishes three distinct cell layers (eg, ectoderm, mesoderm, endoderm) from which **all tissues and organs** are **derived**.

The gastrointestinal system is derived from components of each of the following cell layers:

- **Ectoderm**: The ectoderm is composed of surface ectoderm, neural tube, and neural crest cells. The surface ectoderm gives rise to the oral epithelial linings and salivary glands **(Choice D)**. The neural crest gives rise to neural ganglia, including enteric ganglion cells. These cells are responsible for intestinal relaxation, and failure of neural crest cell migration to the distal colon during embryonic development leads to Hirschsprung disease **(Choice A)**.
- **Mesoderm**: The peritoneum and spleen are derivatives of the mesoderm **(Choices C and E)**, which also gives rise to the smooth muscle component of the intestinal tract.
- **Endoderm**: Gastrointestinal derivatives of the endoderm include the **liver**, **pancreas**, and epithelial lining.

Therefore, in this fetus with disrupted endoderm differentiation, **pancreatic enzyme production** is likely to be affected. Other structures that could be affected in a patient with disrupted endoderm differentiation include the **respiratory tract**, thymus, parathyroid glands, and bladder/urethra.

Educational objective:
All tissues and organs are derived from the following distinct cell layers: ectoderm, mesoderm, and endoderm. Derivatives of the endoderm include the gastrointestinal tract, liver, and pancreas.

Embryology	Gastrointestinal & Nutrition	Embryologic derivatives
Subject	System	Topic

Copyright © UWorld. All rights reserved.

https://t.me/USMLEWorldStep1

Endoderm	• Thymus, parathyroids, thyroid follicular cells • Middle ear epithelium

Exhibit Display

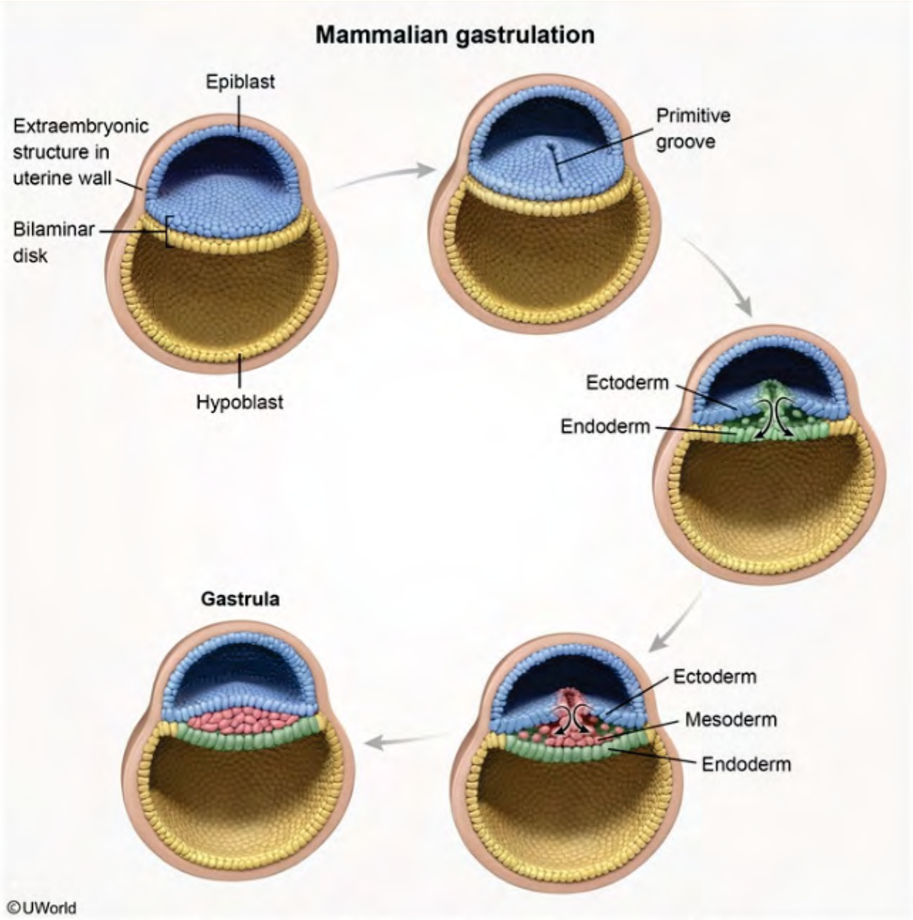

Zoom In | Zoom Out | Reset | New | Existing | My Notebook

Gastru
(eg, ec
The ga
• E
e
n
fa
d
• M
g
• E
Theref
affecte
respir
Educa
All tiss
Deriva

Embryo
Subject

Copyright © UWorld. All rights reserved.

https://t.me/USMLEWorldStep1

A 65-year-old man comes to the office due to pain, redness, and swelling in his right calf. The patient is diagnosed with cellulitis and clindamycin is initiated. A few days after starting treatment, he develops watery diarrhea and abdominal cramps. The patient is hospitalized, and a complete blood count reveals leukocytosis. The toxin responsible for this patient's condition most directly affects which of the following components of intestinal mucosal cells?

- A. Apical ion transport
- B. Cell membrane integrity
- C. Cytoskeleton integrity
- D. Mitochondrial energy production
- E. Ribosomal protein synthesis

Submit

https://t.me/USMLEWorldStep1

A 65-year-old man comes to the office due to pain, redness, and swelling in his right calf. The patient is diagnosed with cellulitis and clindamycin is initiated. A few days after starting treatment, he develops watery diarrhea and abdominal cramps. The patient is hospitalized, and a complete blood count reveals leukocytosis. The toxin responsible for this patient's condition most directly affects which of the following components of intestinal mucosal cells?

- ✗ A. Apical ion transport (28%)
- B. Cell membrane integrity (19%)
- ✓ C. Cytoskeleton integrity (42%)
- D. Mitochondrial energy production (1%)
- E. Ribosomal protein synthesis (8%)

Incorrect
Correct answer
C

42%
Answered correctly

03 secs
Time Spent

2023
Version

Explanation

***Clostridioides difficile* colitis**	
Risk factors	• Recent antibiotic use • Hospitalization • Gastric acid suppression (eg, PPI)
Pathogenesis	• Disruption of intestinal flora → *C difficile* overgrowth • Toxins A & B disrupt cytoskeleton integrity & stimulate inflammation • Pseudomembrane formation
	• Profuse watery diarrhea (most common)

https://t.me/USMLEWorldStep1

Explanation

***Clostridioides difficile* colitis**	
Risk factors	• Recent antibiotic use • Hospitalization • Gastric acid suppression (eg, PPI)
Pathogenesis	• Disruption of intestinal flora → *C difficile* overgrowth • Toxins A & B disrupt cytoskeleton integrity & stimulate inflammation • Pseudomembrane formation
Clinical presentation	• Profuse watery diarrhea (most common) • Leukocytosis (~15,000/mm^3) • Fulminant colitis/toxic megacolon
Diagnosis	• Stool PCR for *C difficile* genes* • Stool EIA for *C difficile* toxin & glutamate dehydrogenase antigen
Treatment	• Oral fidaxomicin or oral vancomycin • IV metronidazole added for fulminant disease
*Genes specific to toxigenic strains are assessed. **EIA** = enzyme immunoassay; **IV** = intravenous; **PCR** = polymerase chain reaction; **PPI** = proton pump inhibitor.	

Clostridioides difficile is part of the gut's normal microbial flora in 2%-3% of healthy adults and approximately 70% of healthy infants. The administration of **antibiotics** (eg, **clindamycin**, fluoroquinolones, broad-spectrum penicillin) that are lethal to other commensal gut organisms can result in ***C difficile* colitis** due to an unchecked replication of pathogenic strains of *C difficile*.

These strains produce **toxin A** and **toxin B**, which act synergistically, although toxin B is significantly more virulent. The toxins bind specific receptors on intestinal mucosal cells and are internalized, allowing them to inactivate the Rho-regulatory proteins involved in the maintenance of actin cytoskeletal structure. The result is

https://t.me/USMLEWorldStep1

EIA = enzyme immunoassay; **IV** = intravenous; **PCR** = polymerase chain reaction; **PPI** = proton pump inhibitor.

Clostridioides difficile is part of the gut's normal microbial flora in 2%-3% of healthy adults and approximately 70% of healthy infants. The administration of **antibiotics** (eg, **clindamycin**, fluoroquinolones, broad-spectrum penicillin) that are lethal to other commensal gut organisms can result in ***C difficile* colitis** due to an unchecked replication of pathogenic strains of *C difficile*.

These strains produce **toxin A** and **toxin B**, which act synergistically, although toxin B is significantly more virulent. The toxins bind specific receptors on intestinal mucosal cells and are internalized, allowing them to inactivate the Rho-regulatory proteins involved in the maintenance of actin cytoskeletal structure. The result is **loss of cytoskeleton integrity**, leading to cell rounding/retraction, disruption of intercellular tight junctions, and increased paracellular intestinal fluid secretion (eg, watery diarrhea). Both toxins also have **inflammatory effects** (eg, neutrophil recruitment) and can induce apoptosis, resulting **pseudomembrane** formation.

(Choice A) Apical ion transport is most directly affected by the cholera toxin (main exotoxin of *Vibrio cholerae*) through activation of adenylate cyclase, which leads to decreased salt reabsorption and increased transport of sodium and chloride out of the gut mucosal cell. Apical ion transporters are indirectly affected by *C difficile* toxins due to loss of cell polarity (secondary to cytoskeletal dysfunction).

(Choice B) Loss of cell membrane integrity is characteristic of alpha toxin lecithinase, one of many exotoxins released by *Clostridium perfringens*. *C perfringens* can cause transient, watery diarrhea. However, it is most frequently associated with clostridial myonecrosis (ie, gas gangrene), a rapidly progressive form of fasciitis associated with penetrating injury by soil-contaminated objects.

(Choice D) Mitochondria are the primary source of ATP in human cells. Cyanide and nucleoside reverse transcriptase inhibitors are examples of drugs associated with mitochondrial toxicity.

(Choice E) Ribosomal protein synthesis is inhibited by Shiga and Shiga-like toxins. Shiga toxin is the main exotoxin released by *Shigella* species; Shiga-like toxin (ie, verotoxin) is produced by enterohemorrhagic *Escherichia coli* (eg, O157:H7). These toxins cause inflammatory diarrhea (eg, fever, pain, blood) 3-4 days after the ingestion of contaminated food or water.

Educational objective:

https://t.me/USMLEWorldStep1

virulent. The toxins bind specific receptors on intestinal mucosal cells and are internalized, allowing them to inactivate the Rho-regulatory proteins involved in the maintenance of actin cytoskeletal structure. The result is **loss of cytoskeleton integrity**, leading to cell rounding/retraction, disruption of intercellular tight junctions, and increased paracellular intestinal fluid secretion (eg, watery diarrhea). Both toxins also have **inflammatory effects** (eg, neutrophil recruitment) and can induce apoptosis, resulting **pseudomembrane** formation.

(Choice A) Apical ion transport is most directly affected by the cholera toxin (main exotoxin of *Vibrio cholerae*) through activation of adenylate cyclase, which leads to decreased salt reabsorption and increased transport of sodium and chloride out of the gut mucosal cell. Apical ion transporters are indirectly affected by *C difficile* toxins due to loss of cell polarity (secondary to cytoskeletal dysfunction).

(Choice B) Loss of cell membrane integrity is characteristic of alpha toxin lecithinase, one of many exotoxins released by *Clostridium perfringens*. *C perfringens* can cause transient, watery diarrhea. However, it is most frequently associated with clostridial myonecrosis (ie, gas gangrene), a rapidly progressive form of fasciitis associated with penetrating injury by soil-contaminated objects.

(Choice D) Mitochondria are the primary source of ATP in human cells. Cyanide and nucleoside reverse transcriptase inhibitors are examples of drugs associated with mitochondrial toxicity.

(Choice E) Ribosomal protein synthesis is inhibited by Shiga and Shiga-like toxins. Shiga toxin is the main exotoxin released by *Shigella* species; Shiga-like toxin (ie, verotoxin) is produced by enterohemorrhagic *Escherichia coli* (eg, O157:H7). These toxins cause inflammatory diarrhea (eg, fever, pain, blood) 3-4 days after the ingestion of contaminated food or water.

Educational objective:
Pathogenic *Clostridioides difficile* can proliferate due to loss of commensal gut flora following the use of broad-spectrum antibiotics (eg, clindamycin). *C difficile* toxins A and B stimulate an inflammatory reaction and disrupt the actin cytoskeletal structure, resulting in pseudomembranous colitis characterized by crampy abdominal pain, watery diarrhea, and leukocytosis.

Microbiology	Gastrointestinal & Nutrition	Clostridioides difficile infection
Subject	System	Topic

https://t.me/USMLEWorldStep1

A 27-year-old woman in her 2nd trimester of pregnancy comes to the office due to constipation. Her stools have become increasingly hard and pellet-like over the past few weeks; bowel movements before then were always regular. She also has mild crampy abdominal pain and bloating, both of which improve after defecation. Medical history and family history are both unremarkable. This is the patient's first pregnancy and has so far been uncomplicated. On physical examination, the abdomen appears gravid but nontender. Which of the following best explains this patient's symptoms?

- A. Decreased colonic smooth muscle activity
- B. Decreased parasympathetic input to the colon
- C. Impaired relaxation of pelvic floor muscles
- D. Thickening of intestinal secretions
- E. Thinning of the rectovaginal septum

Submit

https://t.me/USMLEWorldStep1

A 27-year-old woman in her 2nd trimester of pregnancy comes to the office due to constipation. Her stools have become increasingly hard and pellet-like over the past few weeks; bowel movements before then were always regular. She also has mild crampy abdominal pain and bloating, both of which improve after defecation. Medical history and family history are both unremarkable. This is the patient's first pregnancy and has so far been uncomplicated. On physical examination, the abdomen appears gravid but nontender. Which of the following best explains this patient's symptoms?

- ✓ A. Decreased colonic smooth muscle activity (36%)
- ✗ B. Decreased parasympathetic input to the colon (16%)
- C. Impaired relaxation of pelvic floor muscles (33%)
- D. Thickening of intestinal secretions (8%)
- E. Thinning of the rectovaginal septum (5%)

Incorrect
Correct answer
A

36%
Answered correctly

05 secs
Time Spent

2023
Version

Explanation

Common gastrointestinal adaptations in pregnancy

	Adaptation	Complication
Esophagus	• Progesterone decreases LES tone	• GERD
Gallbladder	• Estrogen increases cholesterol secretion into bile • Progesterone reduces gallbladder motility	• Cholelithiasis • Cholecystitis
Intestines	• Progesterone decreases colonic smooth muscle activity and decreases fasting MMCs in the small intestine	• Constipation • Bloating

https://t.me/USMLEWorldStep1

Common gastrointestinal adaptations in pregnancy		
	Adaptation	**Complication**
Esophagus	• Progesterone decreases LES tone	• GERD
Gallbladder	• Estrogen increases cholesterol secretion into bile • Progesterone reduces gallbladder motility	• Cholelithiasis • Cholecystitis
Intestines	• Progesterone decreases colonic smooth muscle activity and decreases fasting MMCs in the small intestine • Gravid uterus mechanically impedes small intestine transit	• Constipation • Bloating • Flatulence
Rectum	• Gravid uterus increases venous pressure	• Hemorrhoids
LES = lower esophageal sphincter; **GERD** = gastroesophageal reflux; **MMC** = migrating myoelectric complex.		

Pregnancy has multiple effects in the gastrointestinal tract due to increasing levels of progesterone and estrogen as well as the effects of a gravid uterus on surrounding structures. **Constipation** is particularly common in pregnant patients and is largely due to the effects of **progesterone**, which has been shown to **reduce colonic smooth muscle activity**. Progesterone also prevents the release of motilin, a hormone responsible for stimulating the fasting migrating myoelectric complex, which normally helps propel undigested food from the small intestines into the colon. Constipation may be exacerbated in later stages of pregnancy as the gravid uterus increases pressure on the small intestine, slowing intestinal transit.

Other common gastrointestinal alterations in pregnancy include reduced lower esophageal sphincter pressure (promoting gastroesophageal reflux) and gallbladder stasis (increasing the likelihood of developing gallstones). Hemorrhoids are also common and result from a rise in pressure within the rectal venous system due to the gravid uterus.

(Choice B) The parasympathetic nervous system stimulates peristalsis and gastrointestinal motility. Reduced parasympathetic input to the colon can lead to constipation; however, this typically occurs with neurologic disorders (eg, spinal cord injury, multiple sclerosis).

https://t.me/USMLEWorldStep1

smooth muscle activity. Progesterone also prevents the release of motilin, a hormone responsible for stimulating the fasting migrating myoelectric complex, which normally helps propel undigested food from the small intestines into the colon. Constipation may be exacerbated in later stages of pregnancy as the gravid uterus increases pressure on the small intestine, slowing intestinal transit.

Other common gastrointestinal alterations in pregnancy include reduced lower esophageal sphincter pressure (promoting gastroesophageal reflux) and gallbladder stasis (increasing the likelihood of developing gallstones). Hemorrhoids are also common and result from a rise in pressure within the rectal venous system due to the gravid uterus.

(Choice B) The parasympathetic nervous system stimulates peristalsis and gastrointestinal motility. Reduced parasympathetic input to the colon can lead to constipation; however, this typically occurs with neurologic disorders (eg, spinal cord injury, multiple sclerosis).

(Choice C) Defecatory dysfunction results from an inability to relax pelvic floor muscles, which prevents proper evacuation of stool from the rectal vault. Although this can occur after trauma (eg, traumatic vaginal delivery), it is not a physiologic change that occurs during pregnancy.

(Choice D) Thickened intestinal secretions can cause constipation; however, this is typically seen in patients with cystic fibrosis, which affects water and electrolyte transportation. Patients with cystic fibrosis are typically diagnosed in infancy and have recurrent respiratory infections and failure to thrive.

(Choice E) Rectoceles occur when the rectum herniates into the vaginal canal through a thinned rectovaginal septum. Although they also cause constipation, rectoceles typically occur in elderly individuals with a history of multiple vaginal deliveries, not during pregnancy. Patients often report needing to manually compress the vagina to induce bowel movements.

Educational objective:
Constipation is common during pregnancy and results from the inhibitory effect of progesterone on colonic smooth muscle contractions and the fasting migrating myoelectric complex. Other common pregnancy-related changes of the gastrointestinal system include decreased lower esophageal sphincter pressure (leading to gastroesophageal reflux) and gallbladder stasis (leading to gallstone formation).

https://t.me/USMLEWorldStep1

A 50-year-old woman comes to the emergency department with severe upper abdominal pain. The pain started suddenly and is sharp and colicky. She has also vomited several times throughout the day, including once while in the emergency department. The patient describes several prior episodes of similar abdominal pain that resolved spontaneously without treatment. Her other medical problems include complicated appendicitis when she was 22 years old. Her temperature is 37.8 C (100 F) and pulse is 112/min. Abdominal examination shows cessation of inspiration with deep palpation of the right upper quadrant. Laboratory assessment shows a serum bilirubin of 0.8 mg/dL and a serum alkaline phosphatase of 100 U/L. Initial imaging studies are equivocal. Which of the following diagnostic test results would be most specific for acute cholecystitis?

- A. Distended duodenum on upper gastrointestinal series
- B. Echogenic structures inside the gallbladder on abdominal ultrasound
- C. Failed gallbladder visualization on radionuclide biliary scan
- D. Increased serum aspartate and alanine aminotransferase levels
- E. Opacities in the right subcostal area on abdominal x-ray

Submit

https://t.me/USMLEWorldStep1

A 50-year-old woman comes to the emergency department with severe upper abdominal pain. The pain started suddenly and is sharp and colicky. She has also vomited several times throughout the day, including once while in the emergency department. The patient describes several prior episodes of similar abdominal pain that resolved spontaneously without treatment. Her other medical problems include complicated appendicitis when she was 22 years old. Her temperature is 37.8 C (100 F) and pulse is 112/min. Abdominal examination shows cessation of inspiration with deep palpation of the right upper quadrant. Laboratory assessment shows a serum bilirubin of 0.8 mg/dL and a serum alkaline phosphatase of 100 U/L. Initial imaging studies are equivocal. Which of the following diagnostic test results would be most specific for acute cholecystitis?

- ✗ A. Distended duodenum on upper gastrointestinal series (2%)
- B. Echogenic structures inside the gallbladder on abdominal ultrasound (53%)
- ✓ C. Failed gallbladder visualization on radionuclide biliary scan (33%)
- D. Increased serum aspartate and alanine aminotransferase levels (3%)
- E. Opacities in the right subcostal area on abdominal x-ray (7%)

Incorrect
Correct answer
C

33%
Answered correctly

03 secs
Time Spent

2023
Version

Explanation

Acute cholecystitis is caused by gallstone obstruction of the **cystic duct** in more than 90% of cases. Ingestion of fatty foods then stimulates contraction of the gallbladder against the impacted stone, resulting in severe colicky pain. Mechanical disruption of the gallbladder mucosa and release of inflammatory mediators (eg, lysolecithin, prostaglandins) cause the obstructed gallbladder to become inflamed and edematous. As blood supply to the distended organ becomes compromised, secondary bacterial infection frequently develops. Potential complications include gangrene and perforation, with subsequent formation of a pericholecystic abscess or generalized peritonitis

https://t.me/USMLEWorldStep1

Explanation

Acute cholecystitis is caused by gallstone obstruction of the **cystic duct** in more than 90% of cases. Ingestion of fatty foods then stimulates contraction of the gallbladder against the impacted stone, resulting in severe colicky pain. Mechanical disruption of the gallbladder mucosa and release of inflammatory mediators (eg, lysolecithin, prostaglandins) cause the obstructed gallbladder to become inflamed and edematous. As blood supply to the distended organ becomes compromised, secondary bacterial infection frequently develops. Potential complications include gangrene and perforation, with subsequent formation of a pericholecystic abscess or generalized peritonitis.

Ultrasonography is the **preferred** initial imaging test for the diagnosis of acute cholecystitis; however, nuclear medicine hepatobiliary scanning (ie, cholescintigraphy) can be an alternate means when ultrasonography is **inconclusive**. During a hepatobiliary scan, a radiotracer is administered intravenously and is preferentially taken up by hepatocytes and excreted into bile. Images of the tracer as it moves through the hepatobiliary system and intestine are then obtained for up to several hours after injection.

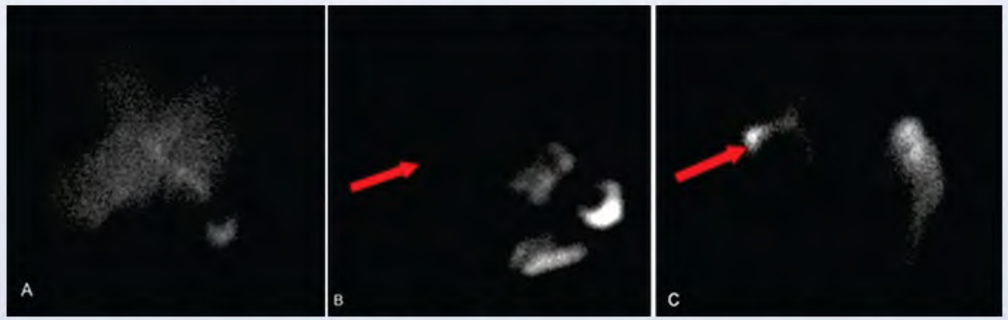

In patients with a patent cystic duct, the gallbladder will be seen as the radiotracer accumulates and concentrates within (image C). In acute or chronic cholecystitis, the radiotracer will be taken up by the liver with progressive excretion into the common bile duct and proximal small bowel, but the **gallbladder will not be visualized** due to the obstruction (image A and B).

(Choice A) Distended duodenum on an upper gastrointestinal series would be suggestive of small-bowel obstruction (as seen with gallstone ileus).

https://t.me/USMLEWorldStep1

Explanation

Acute
fatty fo
pain.
prosta
disten
compli
genera

Ultras
medici
incon
up by
intesti

In pati
within
excret
the ob

(Choice A) Distended duodenum on an upper gastrointestinal series would be suggestive of small-bowel obstruction (as seen with gallstone ileus).

Exhibit Display

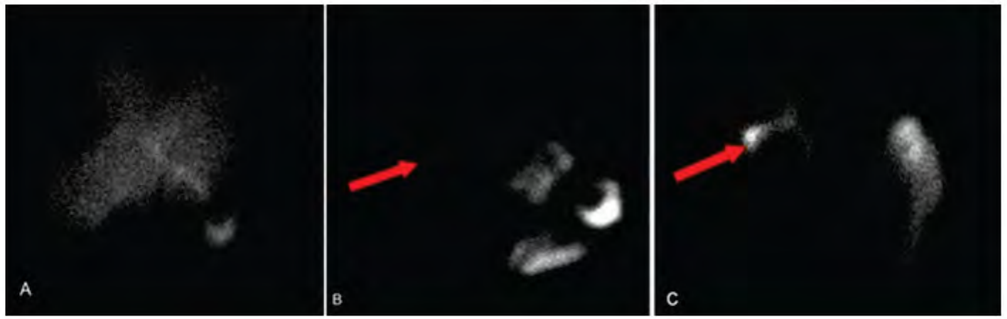

Zoom In | Zoom Out | Reset | New | Existing | My Notebook

https://t.me/USMLEWorldStep1

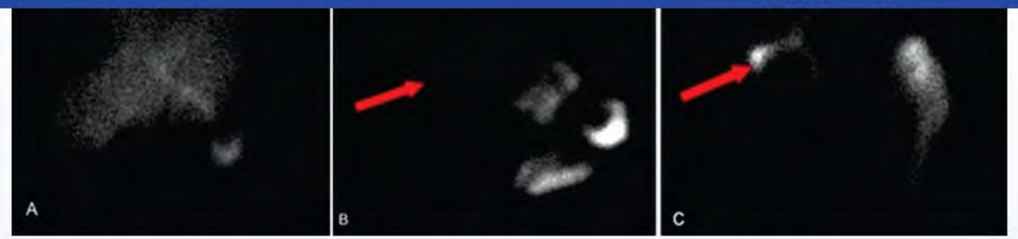

In patients with a patent cystic duct, the gallbladder will be seen as the radiotracer accumulates and concentrates within (image C). In acute or chronic cholecystitis, the radiotracer will be taken up by the liver with progressive excretion into the common bile duct and proximal small bowel, but the **gallbladder will not be visualized** due to the obstruction (image A and B).

(Choice A) Distended duodenum on an upper gastrointestinal series would be suggestive of small-bowel obstruction (as seen with gallstone ileus).

(Choice B) The presence of echogenic structures within the gallbladder on ultrasound can be suggestive of acute cholecystitis in the setting of fever and abdominal pain, but it is not diagnostic. Cholelithiasis can also cause more benign biliary colic, or be an incidental asymptomatic finding in the setting of other abdominal pathology. Ultrasound findings more specific for acute cholecystitis include gallbladder wall thickening, pericholecystic fluid, and a positive sonographic Murphy sign.

(Choice D) Mild increases in serum aspartate and alanine aminotransferase levels can occur in acute cholecystitis, but they are nonspecific and do not aid the diagnosis.

(Choice E) Most patients have insufficient calcium in their gallstones to be visualized on an abdominal x-ray.

Educational objective:
Acute cholecystitis is most often caused by gallstones obstructing the cystic duct. The diagnosis can be made by identifying signs of gallbladder inflammation (eg, wall thickening, pericholecystic fluid) on ultrasonography. When ultrasound is inconclusive, nuclear medicine hepatobiliary scanning (ie, cholescintigraphy) can be used to assess cystic duct patency and make the diagnosis.

References

- A systematic review and meta-analysis of diagnostic performance of imaging in acute cholecystitis.

https://t.me/USMLEWorldStep1

A 65-year-old man with a history of hypertension, type 2 diabetes mellitus, and tobacco smoking comes to the office reporting mild back pain. Abdominal examination reveals a bruit, but no pulsatile mass is palpated. Femoral and pedal pulses are symmetric. The patient is sent for ultrasound and is found to have a large infrarenal abdominal aortic aneurysm. Open aneurysm repair is performed. During the procedure, the inferior mesenteric artery is ligated, the diseased portion of the aorta is dissected, and a graft is placed from below the renal arteries to the bifurcation of the aorta. Collateral circulation from which of the following vessels is most likely responsible for preventing ischemia of the descending colon?

- A. Celiac trunk
- B. External iliac artery
- C. Inferior vena cava
- D. Internal iliac artery
- E. Portal vein
- F. Renal artery
- G. Superior mesenteric artery

Submit

https://t.me/USMLEWorldStep1

A 65-year-old man with a history of hypertension, type 2 diabetes mellitus, and tobacco smoking comes to the office reporting mild back pain. Abdominal examination reveals a bruit, but no pulsatile mass is palpated. Femoral and pedal pulses are symmetric. The patient is sent for ultrasound and is found to have a large infrarenal abdominal aortic aneurysm. Open aneurysm repair is performed. During the procedure, the inferior mesenteric artery is ligated, the diseased portion of the aorta is dissected, and a graft is placed from below the renal arteries to the bifurcation of the aorta. Collateral circulation from which of the following vessels is most likely responsible for preventing ischemia of the descending colon?

- A. Celiac trunk (2%)
- B. External iliac artery (6%)
- C. Inferior vena cava (0%)
- ✗ D. Internal iliac artery (20%)
- E. Portal vein (1%)
- F. Renal artery (2%)
- ✓ G. Superior mesenteric artery (65%)

Incorrect
Correct answer
G

65%
Answered correctly

04 secs
Time Spent

2023
Version

Explanation

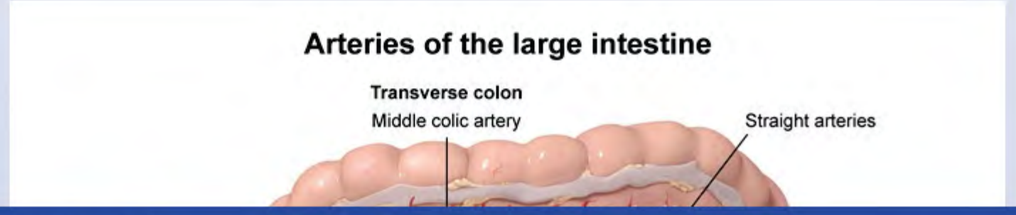

https://t.me/USMLEWorldStep1

A 65-year-old man with a history of hypertension, type 2 diabetes mellitus, and tobacco smoking comes to the office
and pe
abdom
artery
the bif
prever

Exhibit Display

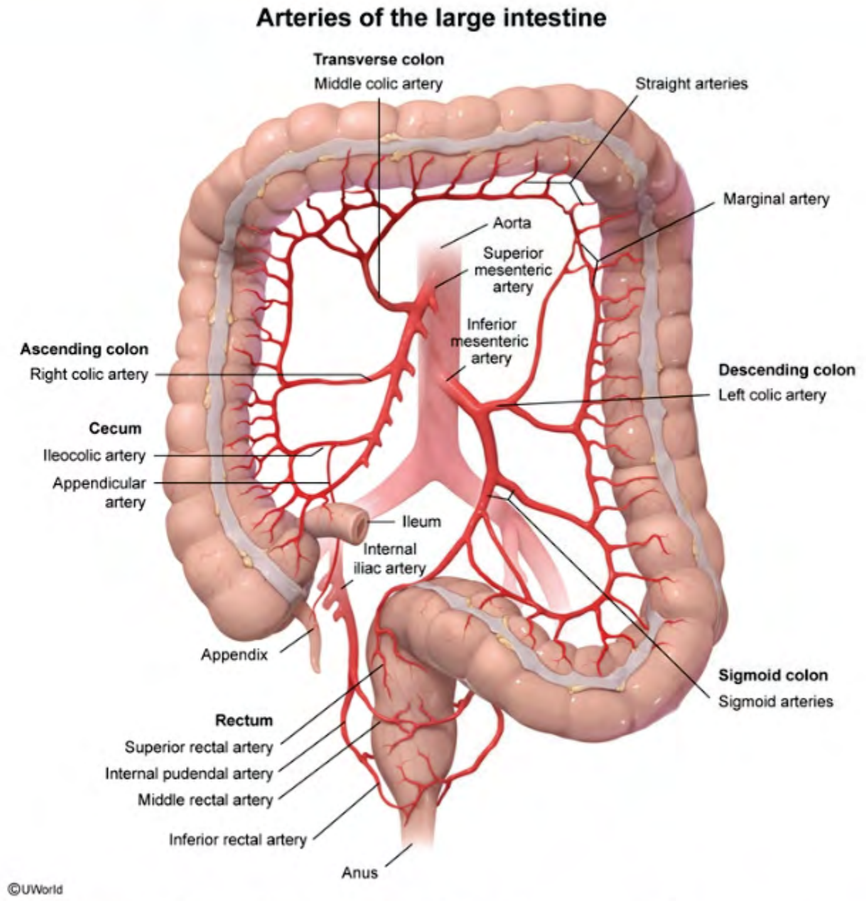

Zoom In | Zoom Out | Reset | New | Existing | My Notebook

https://t.me/USMLEWorldStep1

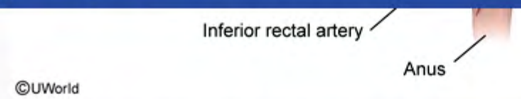

The gastrointestinal tract receives its blood supply from 3 main arteries:

- Celiac trunk
- **Superior mesenteric artery** (SMA)
- **Inferior mesenteric artery** (IMA)

The celiac trunk supplies the stomach, part of the duodenum, gallbladder, liver, spleen, and pancreas **(Choice A)**. The SMA and IMA are the 2 main vessels supplying the small and large intestines and are connected by a pair of anastomoses: the **marginal artery** of Drummond, which is the principal **anastomosis**, and the inconsistently present arc of Riolan (mesenteric meandering artery). These anastomoses protect the intestines from ischemia and, due to the marginal artery, the IMA is not always reconnected during aortic aneurysm repair.

(Choice B) The external iliac artery supplies the inferior epigastric artery and the deep circumflex iliac artery before becoming the femoral artery. Although the inferior epigastric artery anastomoses with the superior epigastric artery, these provide blood supply to the abdominal wall, not the intestines.

(Choices C and E) The inferior vena cava (IVC) has little role in the direct drainage of the intestines except from the rectum, which partially drains via the middle and inferior rectal veins into the internal iliac veins. The remainder of the venous drainage occurs via the superior and inferior mesenteric veins, which drain into the portal vein. After perfusing the liver, the portal vein drains into the IVC via the hepatic veins.

(Choice D) The internal iliac artery supplies part of the rectum via the middle rectal artery. An anastomosis exists between the superior and middle rectal arteries, which can help prevent rectal ischemia after IMA occlusion. However, the SMA is more likely to prevent ischemia in the descending colon due to its proximity and the extensive collateral arcades between the SMA and IMA.

(Choice F) Although the renal arteries arise from the abdominal aorta just inferior to the SMA, they do not provide collateral circulation to the intestines.

Educational objective:

The superior mesenteric artery and inferior mesenteric artery are the 2 main vessels supplying the small and large

https://t.me/USMLEWorldStep1

- Celiac trunk
- **Superior mesenteric artery** (SMA)
- **Inferior mesenteric artery** (IMA)

The celiac trunk supplies the stomach, part of the duodenum, gallbladder, liver, spleen, and pancreas **(Choice A)**. The SMA and IMA are the 2 main vessels supplying the small and large intestines and are connected by a pair of anastomoses: the **marginal artery** of Drummond, which is the principal **anastomosis**, and the inconsistently present arc of Riolan (mesenteric meandering artery). These anastomoses protect the intestines from ischemia and, due to the marginal artery, the IMA is not always reconnected during aortic aneurysm repair.

(Choice B) The external iliac artery supplies the inferior epigastric artery and the deep circumflex iliac artery before becoming the femoral artery. Although the inferior epigastric artery anastomoses with the superior epigastric artery, these provide blood supply to the abdominal wall, not the intestines.

(Choices C and E) The inferior vena cava (IVC) has little role in the direct drainage of the intestines except from the rectum, which partially drains via the middle and inferior rectal veins into the internal iliac veins. The remainder of the venous drainage occurs via the superior and inferior mesenteric veins, which drain into the portal vein. After perfusing the liver, the portal vein drains into the IVC via the hepatic veins.

(Choice D) The internal iliac artery supplies part of the rectum via the middle rectal artery. An anastomosis exists between the superior and middle rectal arteries, which can help prevent rectal ischemia after IMA occlusion. However, the SMA is more likely to prevent ischemia in the descending colon due to its proximity and the extensive collateral arcades between the SMA and IMA.

(Choice F) Although the renal arteries arise from the abdominal aorta just inferior to the SMA, they do not provide collateral circulation to the intestines.

Educational objective:
The superior mesenteric artery and inferior mesenteric artery are the 2 main vessels supplying the small and large intestines. They are connected by a pair of anastomoses: the marginal artery of Drummond, which is the principal anastomosis, and the inconsistently present arc of Riolan (mesenteric meandering artery).

References

https://t.me/USMLEWorldStep1

- Celiac trunk
- S
- In

The ce
The SI
anasto
preser
and, d

(Choi
before
epigas

(Choi
the rec
of the
perfus

(Choi
betwe
Howev
collate

(Choi
collate

Educa
The su
intesti
anastomosis, and the inconsistently present arc of Riolan (mesenteric meandering artery).

References

Exhibit Display

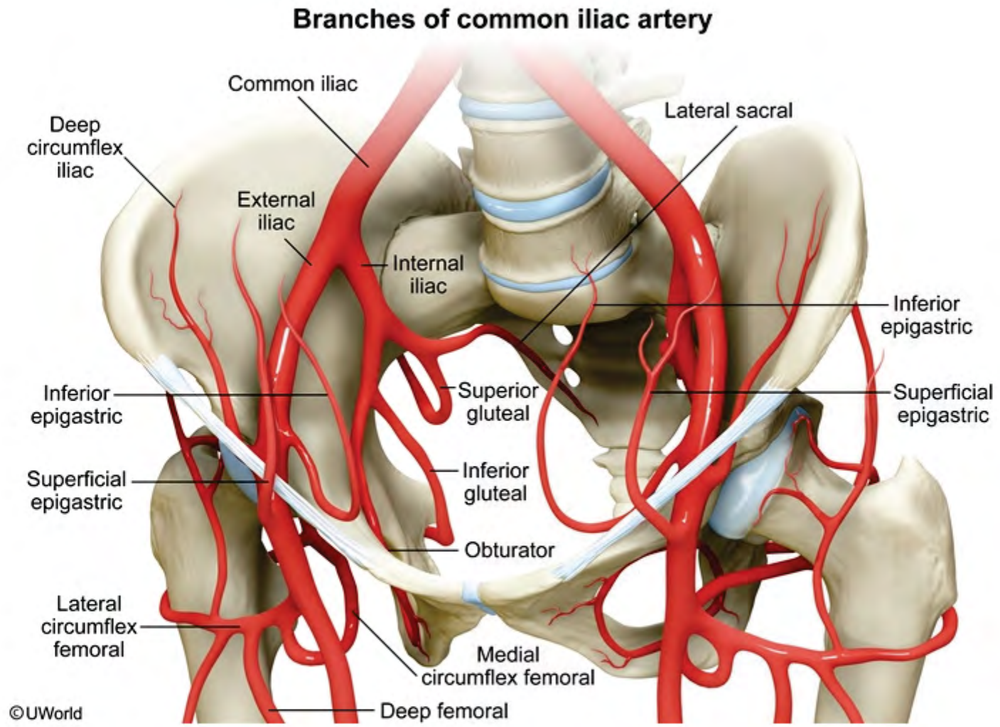

Zoom In | Zoom Out | Reset | New | Existing | My Notebook

https://t.me/USMLEWorldStep1

- Celiac trunk
- **S**
- **In**

The ce
The SI
anasto
preser
and, d

(Choi
before
epigas

(Choi
the rec
of the
perfus

(Choi
betwe
Howev
collate

(Choi
collate

Educa
The su
intesti
anastomosis, and the inconsistently present arc of Riolan (mesenteric meandering artery).

References

Exhibit Display

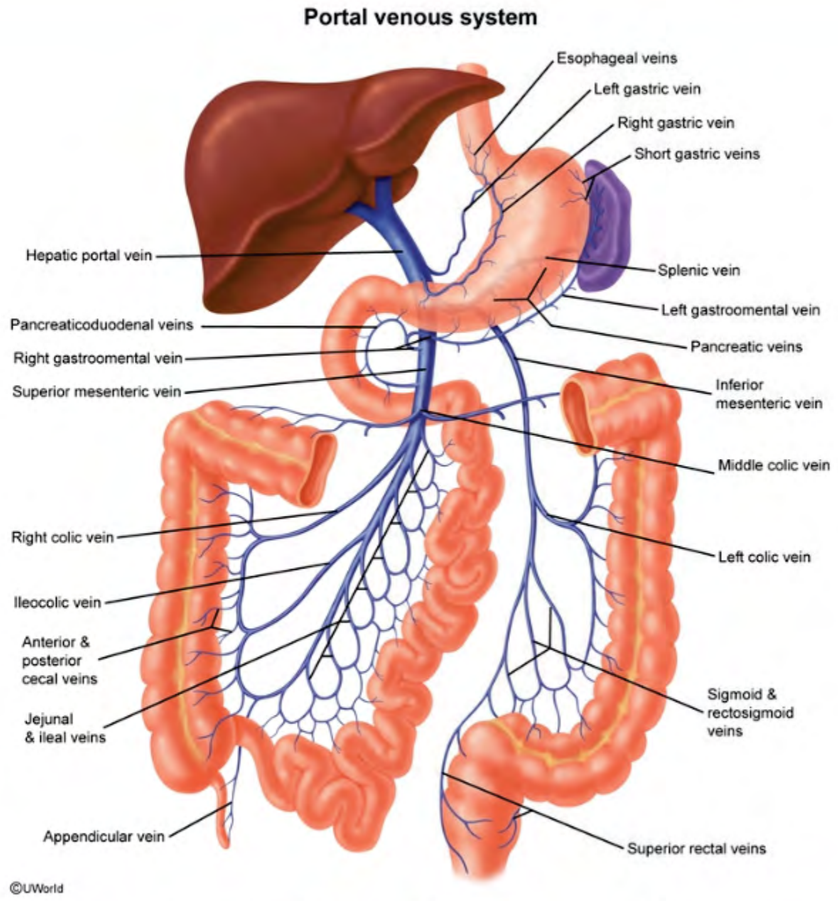

Zoom In | Zoom Out | Reset | New | Existing | My Notebook

https://t.me/USMLEWorldStep1

A 23-year-old man is referred to the gastroenterology clinic due to a 3-year history of recurring abdominal pain accompanied by cramps and diarrhea. The patient has noticed an increased frequency of episodes lately with worsening pain. He also says that his urine occasionally appears dark brown and his urine stream sometimes sputters. Imaging studies reveal a colovesical fistula. Biopsy obtained during colonoscopy shows chronic ileocolitis with discontinuous transmural inflammation and noncaseating granulomas. When given the diagnosis of Crohn disease, the patient becomes skeptical and says, "There's no way I'm getting a colostomy bag." He then refuses treatment and pursues a second opinion once his symptoms subside. A second biopsy demonstrates reduced inflammation in regions of previously active ileocolitis. An increase in which of the following cytokines is most likely responsible for this patient's clinical regression?

- A. IL-1
- B. IL-5
- C. IL-10
- D. IL-12
- E. Interferon gamma
- F. Tumor necrosis factor–alpha

Submit

https://t.me/USMLEWorldStep1

A 23-year-old man is referred to the gastroenterology clinic due to a 3-year history of recurring abdominal pain accompanied by cramps and diarrhea. The patient has noticed an increased frequency of episodes lately with worsening pain. He also says that his urine occasionally appears dark brown and his urine stream sometimes sputters. Imaging studies reveal a colovesical fistula. Biopsy obtained during colonoscopy shows chronic ileocolitis with discontinuous transmural inflammation and noncaseating granulomas. When given the diagnosis of Crohn disease, the patient becomes skeptical and says, "There's no way I'm getting a colostomy bag." He then refuses treatment and pursues a second opinion once his symptoms subside. A second biopsy demonstrates reduced inflammation in regions of previously active ileocolitis. An increase in which of the following cytokines is most likely responsible for this patient's clinical regression?

- A. IL-1 (0%)
- ✗ B. IL-5 (1%)
- ✓ C. IL-10 (72%)
- D. IL-12 (6%)
- E. Interferon gamma (9%)
- F. Tumor necrosis factor–alpha (8%)

Incorrect
Correct answer
C

72%
Answered correctly

04 secs
Time Spent

2023
Version

Explanation

https://t.me/USMLEWorldStep1

A 23-year-old man is referred to the gastroenterology clinic due to a 3-year history of recurring abdominal pain
accom
worse
sputte
ileocol
Crohn
refuse
reduce
most li

Exhibit Display

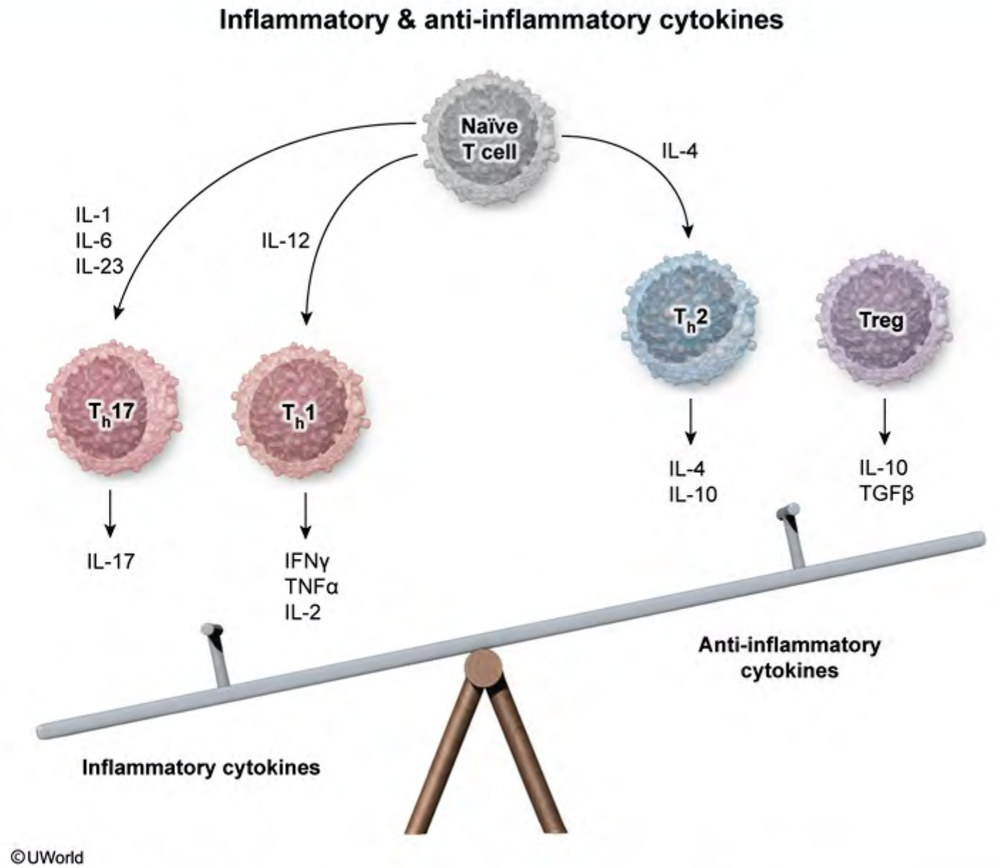

Zoom In | Zoom Out | Reset | New | Existing | My Notebook

https://t.me/USMLEWorldStep1

©UWorld

The balance of pro- and anti-inflammatory cytokines in the intestinal mucosa is essential for homeostasis. Overproduction of proinflammatory cytokines leads to pathology such as that observed in inflammatory bowel diseases. Among the listed choices, **IL-10** is the only cytokine with **anti-inflammatory** properties. IL-10 reduces production of proinflammatory T_H1 cytokines (IL-2 and interferon gamma) and major histocompatibility complex class II expression (important for antigen presentation and T-helper cell response). It also inhibits activated dendritic cells and macrophages. These effects of IL-10 result in the attenuation of cellular-mediated immunity with some enhancement of the humoral response, leading to a protective effect in Crohn disease.

(Choice A) IL-1, produced by macrophages and epithelial cells, has proinflammatory properties such as endothelium activation, increased chemokine expression (promoting leukocyte recruitment), and induction of fever. IL-1β is important for differentiation of T_H17 cells.

(Choice B) IL-5 is secreted by T_H2 cells and promotes the humoral response by stimulating differentiation of B cells and increasing IgA production. It also promotes the growth and differentiation of eosinophils and is implicated in the pathogenesis of many allergic diseases (eg, asthma).

(Choice D) IL-12 is secreted by macrophages and induces differentiation of T_H1 cells and activation of natural killer cells.

(Choice E) Interferon gamma is secreted by T_H1 cells and promotes proinflammatory pathways by activating macrophages, increasing antigen presentation, and inducing the death of epithelial cells.

(Choice F) Tumor necrosis factor–alpha, produced by macrophages, natural killer cells, and T cells, is a proinflammatory mediator that promotes leukocyte recruitment and activates the endothelium (increases expression of adhesion molecules).

Educational objective:
Of the cytokines released in the setting of tissue injury, IL-10 plays important anti-inflammatory and immunomodulatory roles, especially in the pathogenesis of inflammatory bowel disease. IL-10 attenuates the immune response through the inhibition of T_H1 cytokines, reduction of major histocompatibility complex class II

https://t.me/USMLEWorldStep1

Overproduction of proinflammatory cytokines leads to pathology such as that observed in inflammatory bowel diseases. Among the listed choices, **IL-10** is the only cytokine with **anti-inflammatory** properties. IL-10 reduces production of proinflammatory T_H1 cytokines (IL-2 and interferon gamma) and major histocompatibility complex class II expression (important for antigen presentation and T-helper cell response). It also inhibits activated dendritic cells and macrophages. These effects of IL-10 result in the attenuation of cellular-mediated immunity with some enhancement of the humoral response, leading to a protective effect in Crohn disease.

(Choice A) IL-1, produced by macrophages and epithelial cells, has proinflammatory properties such as endothelium activation, increased chemokine expression (promoting leukocyte recruitment), and induction of fever. IL-1β is important for differentiation of T_H17 cells.

(Choice B) IL-5 is secreted by T_H2 cells and promotes the humoral response by stimulating differentiation of B cells and increasing IgA production. It also promotes the growth and differentiation of eosinophils and is implicated in the pathogenesis of many allergic diseases (eg, asthma).

(Choice D) IL-12 is secreted by macrophages and induces differentiation of T_H1 cells and activation of natural killer cells.

(Choice E) Interferon gamma is secreted by T_H1 cells and promotes proinflammatory pathways by activating macrophages, increasing antigen presentation, and inducing the death of epithelial cells.

(Choice F) Tumor necrosis factor–alpha, produced by macrophages, natural killer cells, and T cells, is a proinflammatory mediator that promotes leukocyte recruitment and activates the endothelium (increases expression of adhesion molecules).

Educational objective:
Of the cytokines released in the setting of tissue injury, IL-10 plays important anti-inflammatory and immunomodulatory roles, especially in the pathogenesis of inflammatory bowel disease. IL-10 attenuates the immune response through the inhibition of T_H1 cytokines, reduction of major histocompatibility complex class II expression, and suppression of activated macrophages and dendritic cells.

References

- Role of cytokines in inflammatory bowel disease.

https://t.me/USMLEWorldStep1

A 21-year-old woman at 18 weeks gestation comes to the office for a routine prenatal visit. A quadruple screen reveals an elevated maternal serum alpha-fetoprotein. Sonographic imaging of the fetus shows an anterior abdominal wall defect with herniation of bowel contents adjacent to the umbilicus. No covering membrane is identified. Color Doppler ultrasound imaging shows a normal 3-vessel cord inserting medial to this defect. The remainder of the anatomical survey is unremarkable. Which of the following is the most likely cause of these fetal findings?

- A. Congenital umbilical hernia
- B. Gastroschisis
- C. Hirschsprung disease
- D. Meckel diverticulum
- E. Omphalocele

Submit

https://t.me/USMLEWorldStep1

A 21-year-old woman at 18 weeks gestation comes to the office for a routine prenatal visit. A quadruple screen reveals an elevated maternal serum alpha-fetoprotein. Sonographic imaging of the fetus shows an anterior abdominal wall defect with herniation of bowel contents adjacent to the umbilicus. No covering membrane is identified. Color Doppler ultrasound imaging shows a normal 3-vessel cord inserting medial to this defect. The remainder of the anatomical survey is unremarkable. Which of the following is the most likely cause of these fetal findings?

- A. Congenital umbilical hernia (3%)
- ✓ B. Gastroschisis (83%)
- C. Hirschsprung disease (0%)
- D. Meckel diverticulum (1%)
- E. Omphalocele (10%)

Correct | 83% Answered correctly | 03 secs Time Spent | 2023 Version

Explanation

Pediatric abdominal wall defects		
Diagnosis	**Pathophysiology**	**Clinical features**
Congenital umbilical hernia	• Incomplete closure of umbilical ring (fascial opening)	• Benign, reducible protrusion • Defect covered by skin • Midline (umbilical cord at apex)
		• Sac containing bowel ± other abdominal organs

https://t.me/USMLEWorldStep1

Pediatric abdominal wall defects		
Diagnosis	**Pathophysiology**	**Clinical features**
Congenital umbilical hernia	• Incomplete closure of umbilical ring (fascial opening)	• Benign, reducible protrusion • Defect covered by skin • Midline (umbilical cord at apex)
Omphalocele	• Abnormal gut rotation without physiologic reduction back into abdominal cavity	• Sac containing bowel ± other abdominal organs • Defect covered by peritoneum (no skin, fascia, muscle) • Midline (umbilical cord at apex)
Gastroschisis	• Full-thickness abdominal wall defect	• Eviscerated bowel • Not covered by membrane • Located to the right of midline/umbilicus

This fetus has an **anterior abdominal wall defect** with herniation of bowel contents. These findings suggest one of 2 possible diagnoses that differ based on location and covering membrane:

- Omphaloceles occur due to abnormal gut rotation and failed physiologic return of bowel to the abdominal cavity during embryonic development. Omphaloceles have herniated bowel contents confined to the umbilical cord sac, which results in a midline defect with an associated peritoneal covering **(Choice E)**.
- **Gastroschisis** is a congenital anomaly caused by disrupted or defective abdominal wall formation. Because the underlying etiology is a full-thickness abdominal wall defect, the fetal bowel eviscerates into the amniotic cavity **without a covering membrane**. The herniation is adjacent to the umbilicus (ie, **paraumbilical**), and the umbilical cord insertion site is usually normal and separate from the defect.

Because fetal bowel produces alpha-fetoprotein (AFP), fetuses with gastroschisis (no covering membrane) have direct AFP leakage into the amniotic fluid. The high concentration of amniotic fluid AFP is absorbed into the

https://t.me/USMLEWorldStep1

This fetus has an **anterior abdominal wall defect** with herniation of bowel contents. These findings suggest one of 2 possible diagnoses that differ based on location and covering membrane:

- Omphaloceles occur due to abnormal gut rotation and failed physiologic return of bowel to the abdominal cavity during embryonic development. Omphaloceles have herniated bowel contents confined to the umbilical cord sac, which results in a midline defect with an associated peritoneal covering **(Choice E)**.
- **Gastroschisis** is a congenital anomaly caused by disrupted or defective abdominal wall formation. Because the underlying etiology is a full-thickness abdominal wall defect, the fetal bowel eviscerates into the amniotic cavity **without a covering membrane**. The herniation is adjacent to the umbilicus (ie, **paraumbilical**), and the umbilical cord insertion site is usually normal and separate from the defect.

Because fetal bowel produces alpha-fetoprotein (AFP), fetuses with gastroschisis (no covering membrane) have direct AFP leakage into the amniotic fluid. The high concentration of amniotic fluid AFP is absorbed into the maternal circulation, resulting in abnormally **elevated maternal serum AFP levels**. Omphaloceles, by comparison, do not elevate amniotic fluid or maternal serum AFP levels as highly because the fetal bowel remains covered by peritoneum.

(Choice A) In contrast to gastroschisis, congenital umbilical hernias (caused by failed closure of the umbilical fascial ring after birth) are midline defects covered by subcutaneous tissue and skin. They are typically benign and easily reducible.

(Choice C) Hirschsprung disease occurs due to failure of neural crest cell migration. Patients have an aganglionic sigmoid colon/rectum that cannot relax (eg, bowel obstruction, megacolon). It does not present with eviscerated bowel in utero.

(Choice D) Meckel diverticulum results from failure of obliteration of the vitelline (omphalomesenteric) duct; the diverticulum can contain ectopic, acid-secreting gastric mucosa that ulcerates adjacent small bowel. Therefore, the most common presentation is painless lower gastrointestinal bleeding in early childhood. There is no associated herniation of bowel contents.

Educational objective:
Gastroschisis is a congenital abdominal wall defect characterized by herniation of uncovered bowel (ie, no

https://t.me/USMLEWorldStep1

cavity during embryonic development. Omphaloceles have herniated bowel contents confined to the umbilical cord sac, which results in a midline defect with an associated peritoneal covering **(Choice E)**.

- **Gastroschisis** is a congenital anomaly caused by disrupted or defective abdominal wall formation. Because the underlying etiology is a full-thickness abdominal wall defect, the fetal bowel eviscerates into the amniotic cavity **without a covering membrane**. The herniation is adjacent to the umbilicus (ie, **paraumbilical**), and the umbilical cord insertion site is usually normal and separate from the defect.

Because fetal bowel produces alpha-fetoprotein (AFP), fetuses with gastroschisis (no covering membrane) have direct AFP leakage into the amniotic fluid. The high concentration of amniotic fluid AFP is absorbed into the maternal circulation, resulting in abnormally **elevated maternal serum AFP levels**. Omphaloceles, by comparison, do not elevate amniotic fluid or maternal serum AFP levels as highly because the fetal bowel remains covered by peritoneum.

(Choice A) In contrast to gastroschisis, congenital umbilical hernias (caused by failed closure of the umbilical fascial ring after birth) are midline defects covered by subcutaneous tissue and skin. They are typically benign and easily reducible.

(Choice C) Hirschsprung disease occurs due to failure of neural crest cell migration. Patients have an aganglionic sigmoid colon/rectum that cannot relax (eg, bowel obstruction, megacolon). It does not present with eviscerated bowel in utero.

(Choice D) Meckel diverticulum results from failure of obliteration of the vitelline (omphalomesenteric) duct; the diverticulum can contain ectopic, acid-secreting gastric mucosa that ulcerates adjacent small bowel. Therefore, the most common presentation is painless lower gastrointestinal bleeding in early childhood. There is no associated herniation of bowel contents.

Educational objective:
Gastroschisis is a congenital abdominal wall defect characterized by herniation of uncovered bowel (ie, no covering membrane) located adjacent to the umbilicus. It can be diagnosed on fetal ultrasound, and the condition is associated with abnormally elevated maternal serum alpha-fetoprotein levels.

Embryology Gastrointestinal & Nutrition Gastroschisis

https://t.me/USMLEWorldStep1

skin, fascia, muscle)
- Midline (umbilical cord at apex)

Exhibit Display

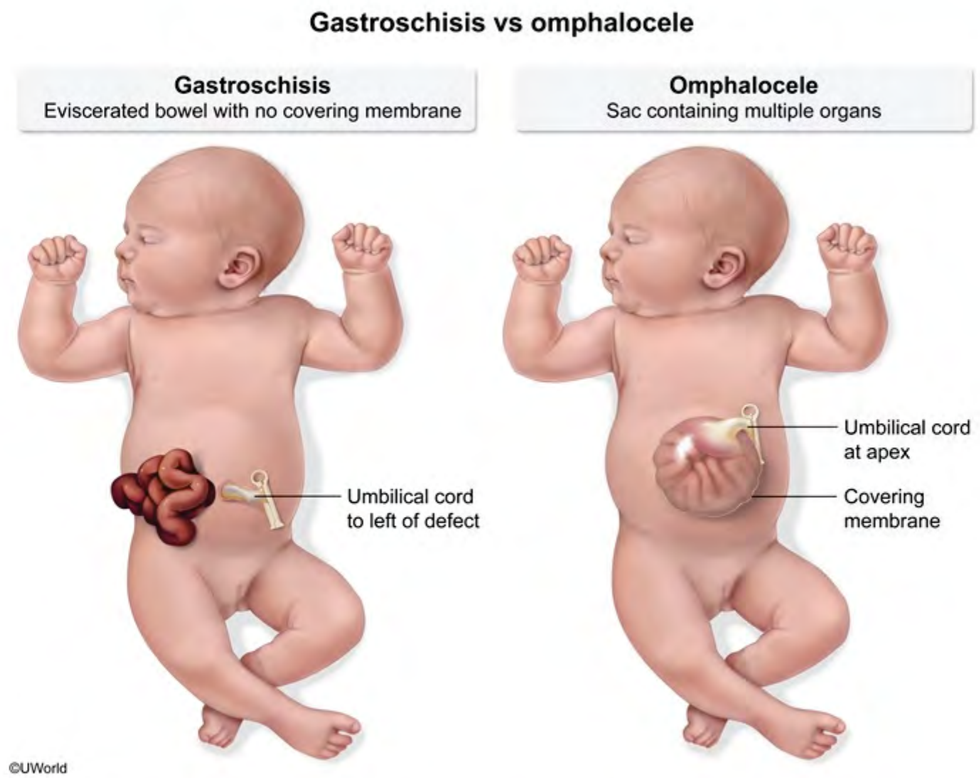

Zoom In Zoom Out Reset New | Existing My Notebook

This fe
of 2 po
- C
- G

Becau
direct
matern
compa
covere

(Choi
fascial
easily

(Choi
sigmoi
bowel in utero.

https://t.me/USMLEWorldStep1

skin, fascia, muscle)
- Midline (umbilical cord at apex)

Exhibit Display

Maternal serum α-fetoprotein screening	
↑ MSAFP	↓ MSAFP
• Open neural tube defects (eg, anencephaly, open spina bifida) • Ventral wall defects (eg, omphalocele, gastroschisis) • Multiple gestation	• Aneuploidies (eg, trisomy 18 & 21)
MSAFP = maternal serum α-fetoprotein.	

New | Existing | My Notebook

This fe
of 2 po
- C
ca
c
- **G**
th
ca
th

Becau
direct
matern
compa
covere

(Choi
fascial
easily

(Choi
sigmoi
bowel in utero.

https://t.me/USMLEWorldStep1

Gastroschisis	• Full-thickness abdominal wall defect	• Not covered by membrane • Located to the right of

Exhibit Display

Maternal serum α-fetoprotein screening

↑ MSAFP	↓ MSAFP
• Open neural tube defects (eg, anencephaly, open spina bifida) • Ventral wall defects (eg, omphalocele, gastroschisis) • Multiple gestation	• Aneuploidies (eg, trisomy 18 & 21)

MSAFP = maternal serum α-fetoprotein.

New | Existing | My Notebook

This fe
of 2 po
- C
  c
  c
- **G**
  th
  c
  th

Becau
direct
matern
compa
covere

(Choi
fascial
easily

(Choi
sigmoi
bowel

(Choi
diverti

most common presentation is painless lower gastrointestinal bleeding in early childhood. There is no associated

https://t.me/USMLEWorldStep1

Gastroschisis	• Full-thickness abdominal wall defect • Not covered by membrane • Located to the right of

Exhibit Display

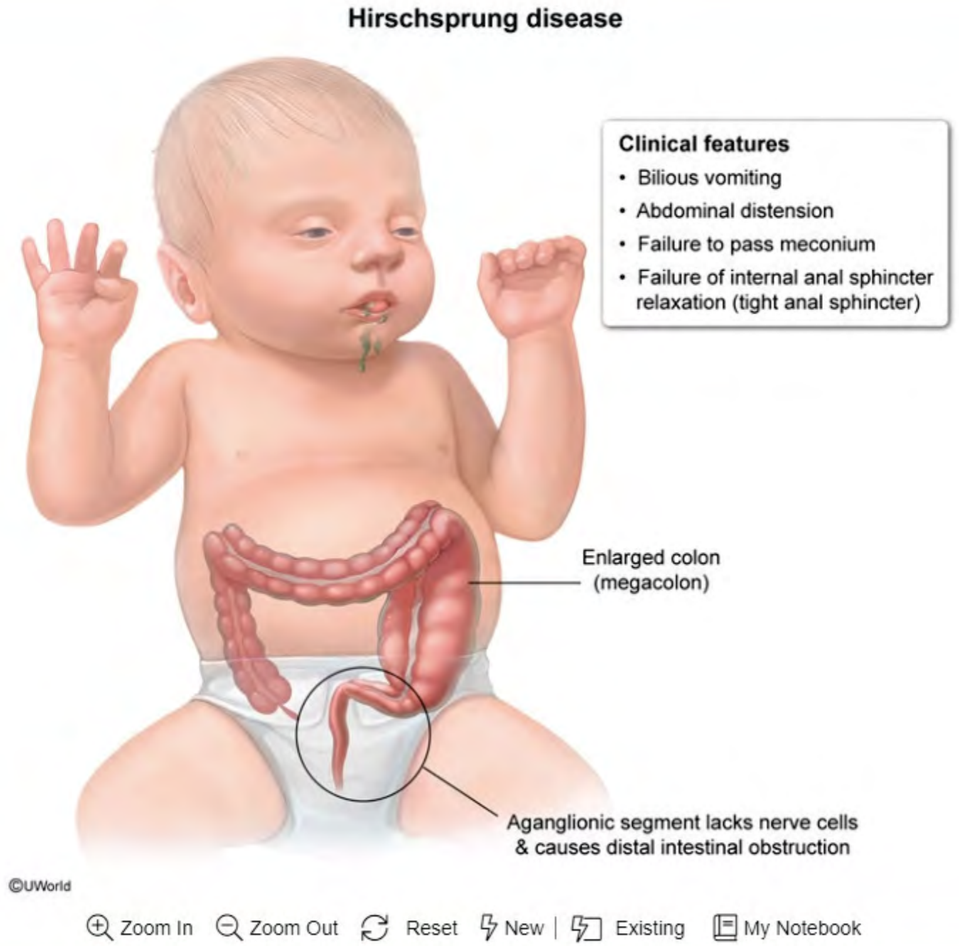

Zoom In | Zoom Out | Reset | New | Existing | My Notebook

This fe
of 2 po
- C
  c
  c
- G
  th
  c
  th

Becau
direct
matern
compa
covere

(Choi
fascial
easily

(Choi
sigmoi
bowel

(Choi
diverti

most common presentation is painless lower gastrointestinal bleeding in early childhood. There is no associated

https://t.me/USMLEWorldStep1

This fetus has an **anterior abdominal wall defect** with herniation of bowel contents. These findings suggest one of 2 possible diagnoses that differ based on location and covering membrane:

- C
  c
  c
- **G**
  th
  c
  th

Becau
direct
matern
compa
covere

(Choi
fascial
easily

(Choi
sigmoi
bowel

(Choi
diverti
most c
hernia

Educa

Gastroschisis is a congenital abdominal wall defect characterized by herniation of uncovered bowel (ie, no

Exhibit Display

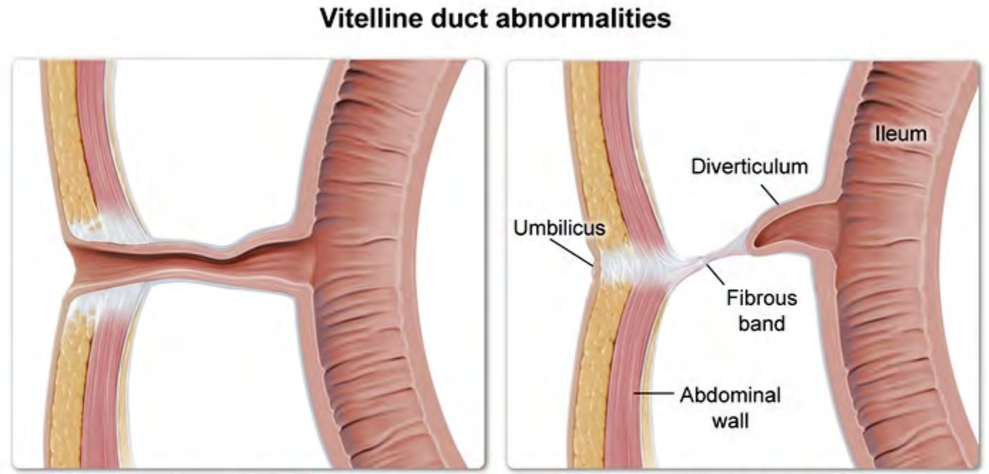

Zoom In | Zoom Out | Reset | New | Existing | My Notebook

https://t.me/USMLEWorldStep1

A 63-year-old man comes to the office due to several months of dysphagia, fatigue, occasional chest discomfort, and indigestion. He has a history of hypertension and takes amlodipine. The patient smokes 1 or 2 cigars daily. His blood pressure is 140/80 mm Hg. Physical examination is normal. An endoscopic evaluation with esophageal biopsy is performed. The histopathology of the specimen is shown in the image below.

Which of the following is the most likely cause of this patient's dysphagia?

- A. Benign tumor with slow growth
- B. Malignancy with probable poor prognosis
- C. Metaplasia with increased risk of adenocarcinoma
- D. Motor dysfunction with increased risk of carcinoma
- E. Reflux esophagitis with high risk of metaplasia

Submit

https://t.me/USMLEWorldStep1

A 63-year-old man comes to the office due to several months of dysphagia, fatigue, occasional chest discomfort,
and in
His blo
biopsy

Exhibit Display

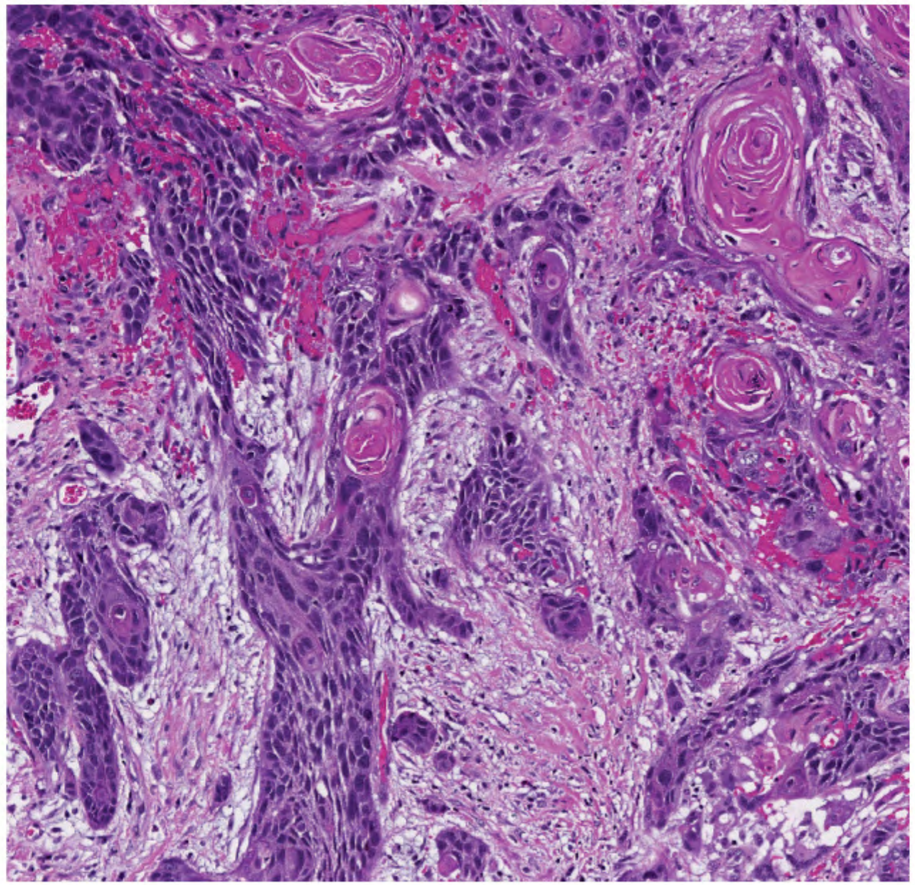

Zoom In | Zoom Out | Reset | New | Existing | My Notebook

Which

A. Benign tumor with slow growth

https://t.me/USMLEWorldStep1

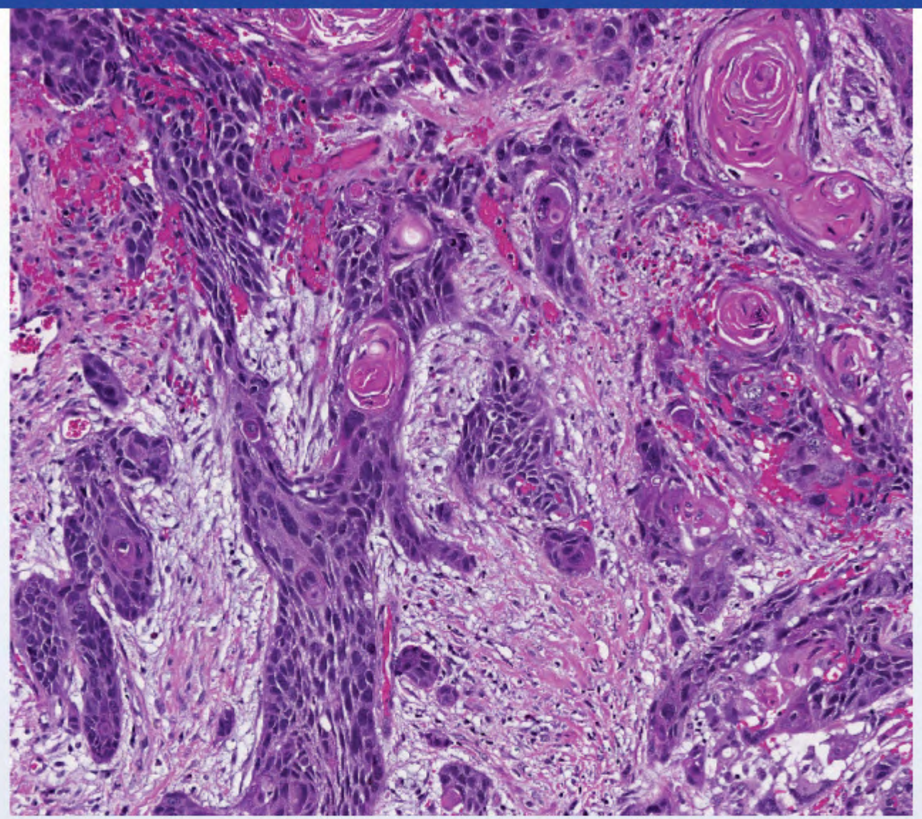

Which of the following is the most likely cause of this patient's dysphagia?

- A. Benign tumor with slow growth
- B. Malignancy with probable poor prognosis
- C. Metaplasia with increased risk of adenocarcinoma
- D. Motor dysfunction with increased risk of carcinoma
- E. Reflux esophagitis with high risk of metaplasia

https://t.me/USMLEWorldStep1

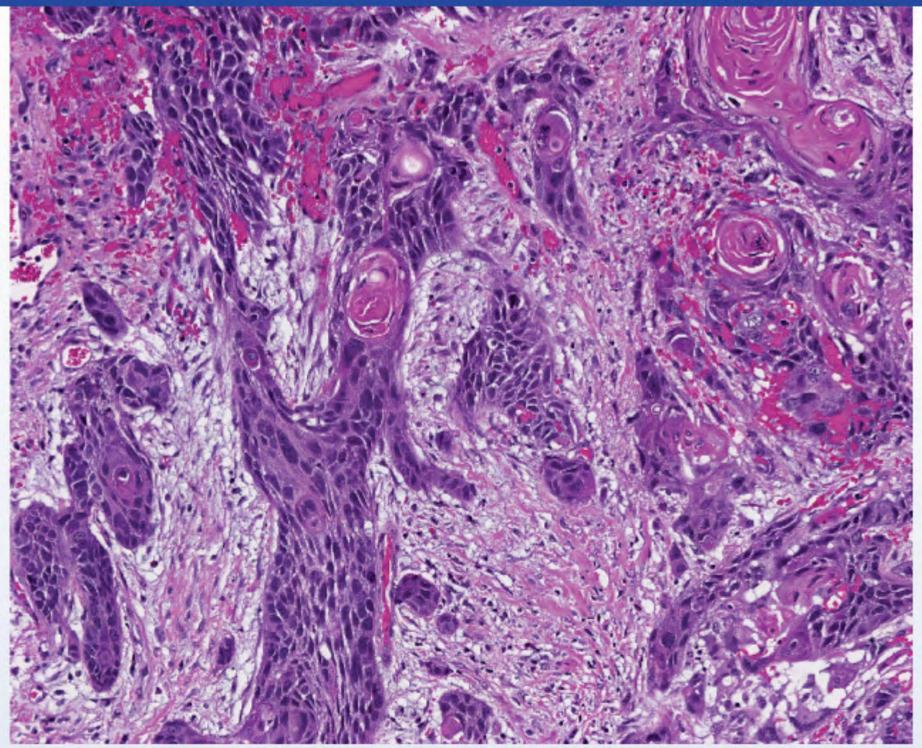

Which of the following is the most likely cause of this patient's dysphagia?

- A. Benign tumor with slow growth (1%)
- ✓ B. Malignancy with probable poor prognosis (78%)
- C. Metaplasia with increased risk of adenocarcinoma (12%)
- D. Motor dysfunction with increased risk of carcinoma (3%)
- E. Reflux esophagitis with high risk of metaplasia (3%)

Correct

78%
Answered correctly

42 secs
Time Spent

2023
Version

https://t.me/USMLEWorldStep1

Explanation

Exhibit Display

Squamous cell carcinoma

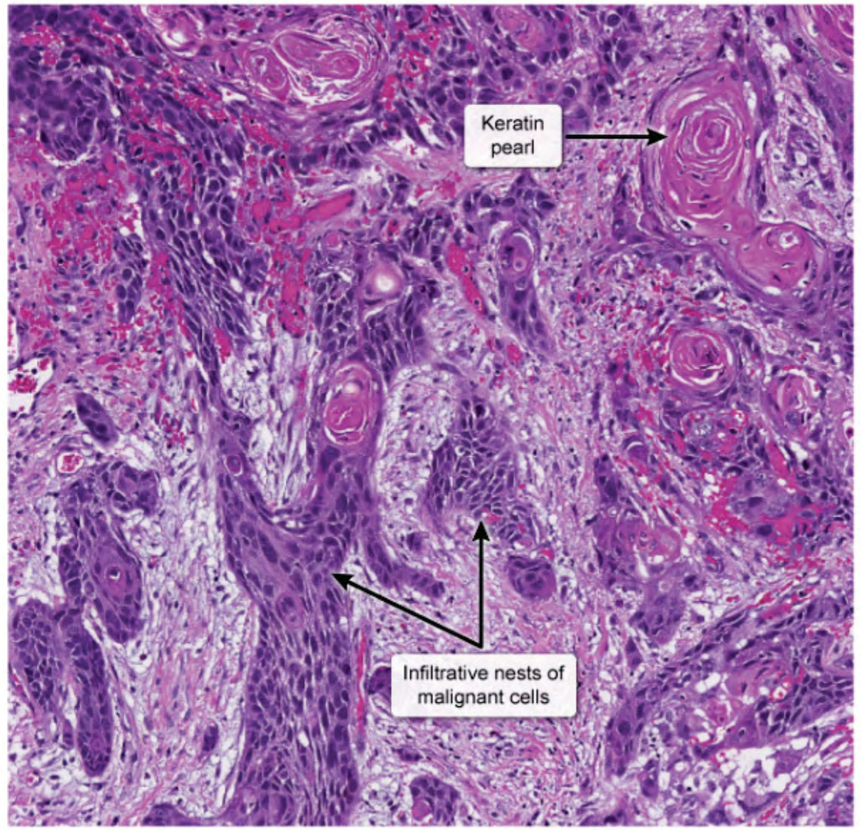

©UWorld

Zoom In | Zoom Out | Reset | New | Existing | My Notebook

This p
featur
and distinct borders (compared to normal esophagus). Areas of **keratinization** are identified (keratin pearls). The

https://t.me/USMLEWorldStep1

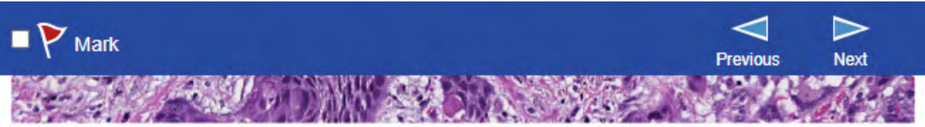

©UWorld

This patient's biopsy is consistent with **esophageal squamous cell carcinoma** (SCC). The histopathologic features of this condition include solid nests of neoplastic squamous cells with abundant eosinophilic cytoplasm and distinct borders (compared to normal esophagus). Areas of **keratinization** are identified (keratin pearls). The presence of intercellular bridges is also characteristic of squamous differentiation.

Most cases of esophageal SCC occur in men age >50 with a history of prolonged smoking and alcohol use. Patients typically present with solid food **dysphagia** as the tumor gradually obstructs the esophageal lumen, which can progress to liquid dysphagia. Retrosternal discomfort/burning and significant **weight loss** are also common. Chronic gastrointestinal blood loss may result in iron deficiency anemia with fatigue. The **prognosis** for esophageal cancer is **generally poor** as many patients present with incurable locally advanced or metastatic disease.

(Choice A) Benign tumors of the esophagus (most commonly leiomyomas) are rare and slow growing. On light microscopy, leiomyomas consist of fascicles of spindle cells with variable amounts of fibrosis.

(Choices C and E) Reflux esophagitis commonly occurs due to gastroesophageal reflux disease and is characterized histologically by elongation of the papillae, basal cell hyperplasia, and intraepithelial eosinophils. Repeated epithelial injury caused by reflux esophagitis may lead to Barrett esophagus, which is characterized by intestinal metaplasia with goblet cells. Barrett esophagus is a premalignant condition that significantly increases the risk of esophageal adenocarcinoma.

(Choice D) Achalasia is an esophageal motility disorder characterized by failed relaxation of the lower esophageal sphincter resulting in food retention, dilation of the esophageal body, and symptoms of solid/liquid dysphagia. Achalasia increases the risk of squamous cell carcinoma of the esophagus.

Educational objective:
The histopathologic features of esophageal squamous cell carcinoma include solid nests of neoplastic squamous cells with abundant eosinophilic cytoplasm and distinct borders. Areas of keratinization and the presence of intercellular bridges are also characteristic. Patients typically present with progressive solid and eventually liquid dysphagia and weight loss.

https://t.me/USMLEWorldStep1

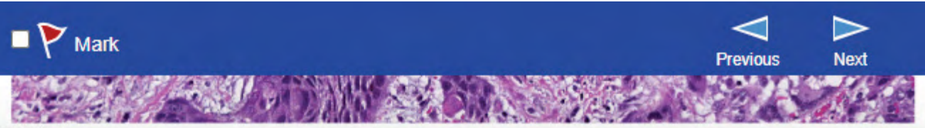

©UWorld

This p
feature
and di
preser

Most c
Patien
can pr
Chron
esoph
diseas

(Choi
micros

(Choi
charac
Repea
intesti
the ris

(Choi
sphinc
Achala

Educa
The hi
cells w
intercellular bridges are also characteristic. Patients typically present with progressive solid and eventually liquid dysphagia and weight loss.

Exhibit Display

Normal esophagus

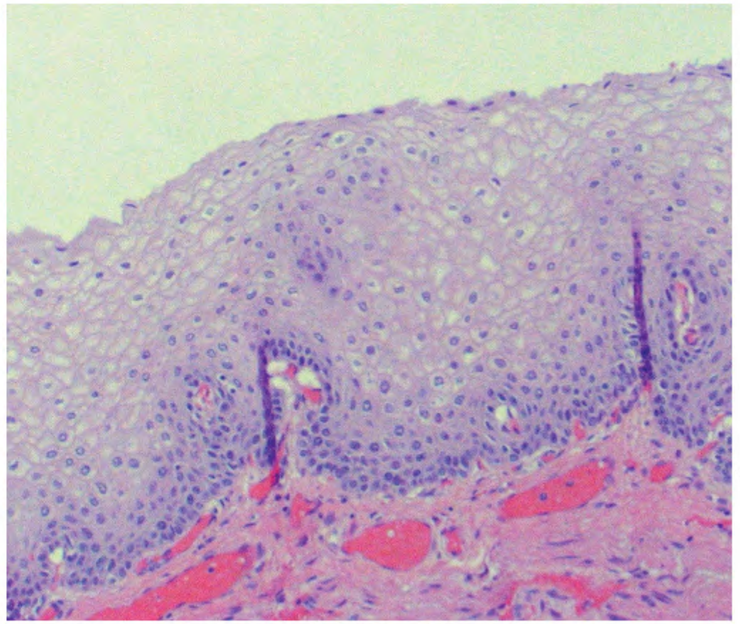

Nonkeratinized stratified squamous epithelium

©UWorld

Zoom In | Zoom Out | Reset | New | Existing | My Notebook

https://t.me/USMLEWorldStep1

©UWorld

This p
feature
and di
preser

Most c
Patien
can pr
Chron
esoph
diseas

(Choi
micros

(Choi
charac
Repea
intesti
the ris

(Choi
sphinc
Achala

Educa
The hi
cells w
intercellular bridges are also characteristic. Patients typically present with progressive solid and eventually liquid dysphagia and weight loss.

Exhibit Display

Leiomyoma

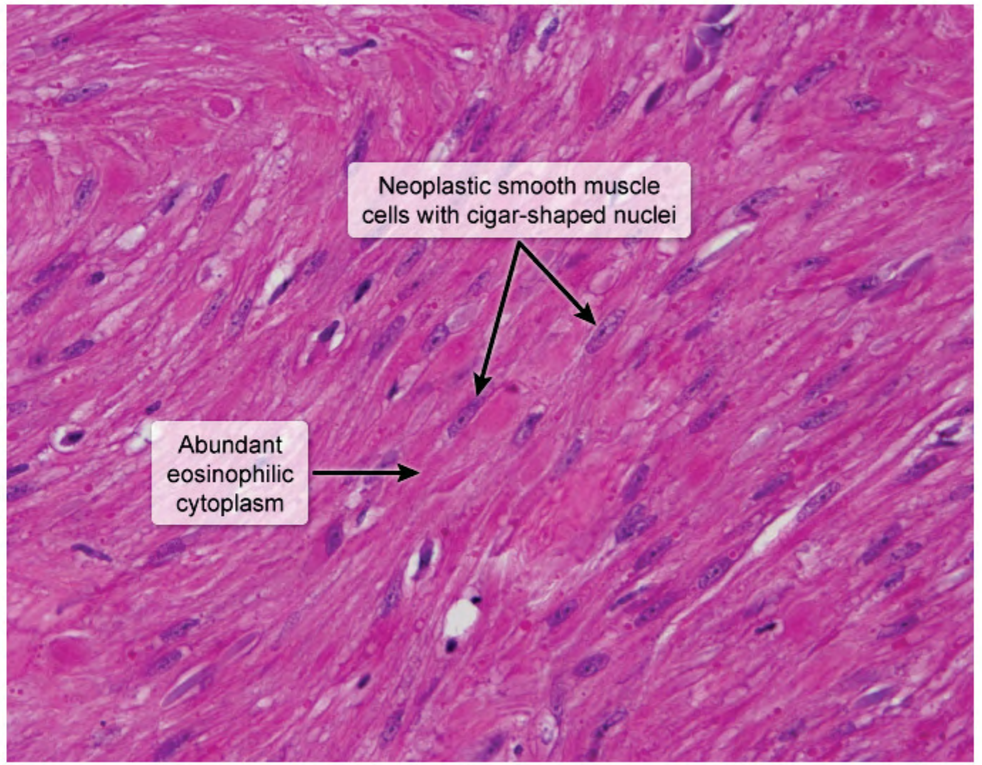

©UWorld

Zoom In | Zoom Out | Reset | New | Existing | My Notebook

https://t.me/USMLEWorldStep1

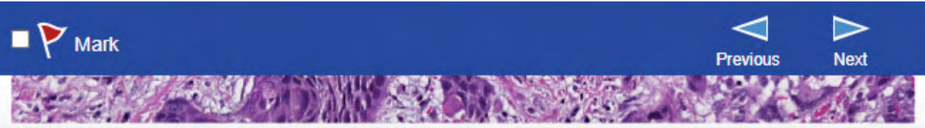

©UWorld

This p
feature
and di
preser

Most c
Patien
can pr
Chron
esoph
diseas

(Choi
micros

(Choi
charac
Repea
intesti
the ris

(Choi
sphinc
Achala

Educa
The hi
cells w
intercellular bridges are also characteristic. Patients typically present with progressive solid and eventually liquid dysphagia and weight loss.

Exhibit Display

Reflux esophagitis

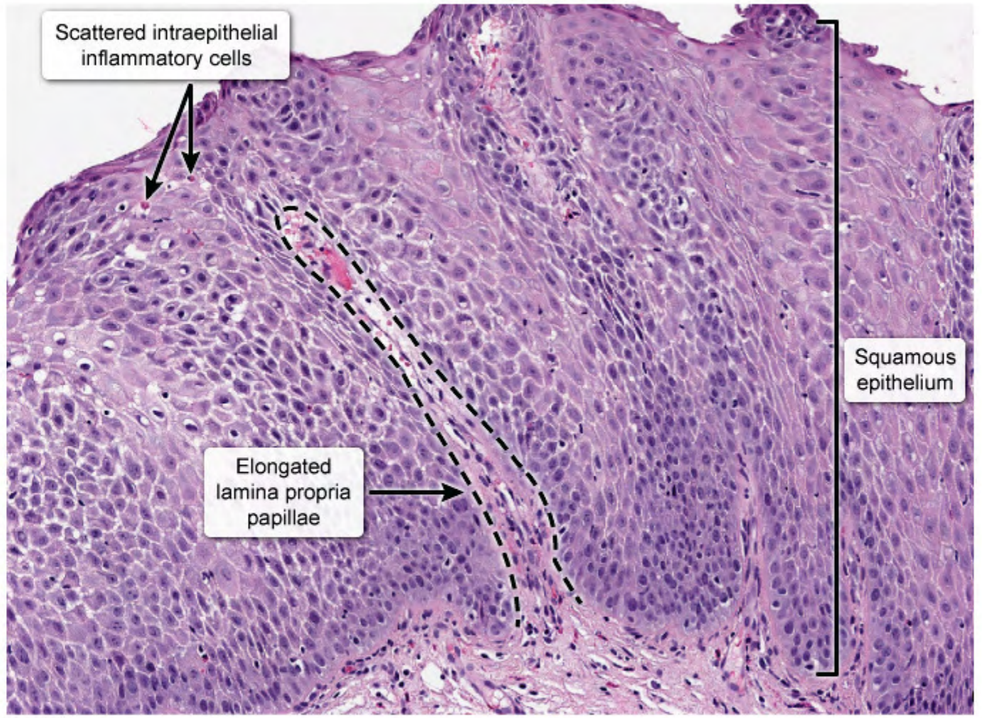

©UWorld

Zoom In | Zoom Out | Reset | New | Existing | My Notebook

https://t.me/USMLEWorldStep1

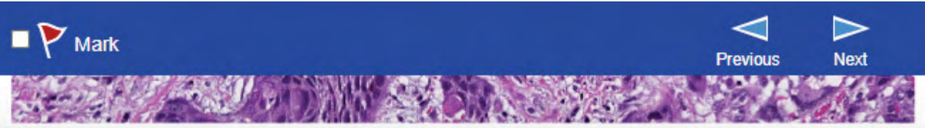

©UWorld

This p
feature
and di
preser

Most c
Patien
can pr
Chron
esoph
diseas

(Choi
micros

(Choi
charac
Repea
intesti
the ris

(Choi
sphinc
Achala

Educa
The hi
cells w
intercellular bridges are also characteristic. Patients typically present with progressive solid and eventually liquid dysphagia and weight loss.

Exhibit Display

Barrett esophagus

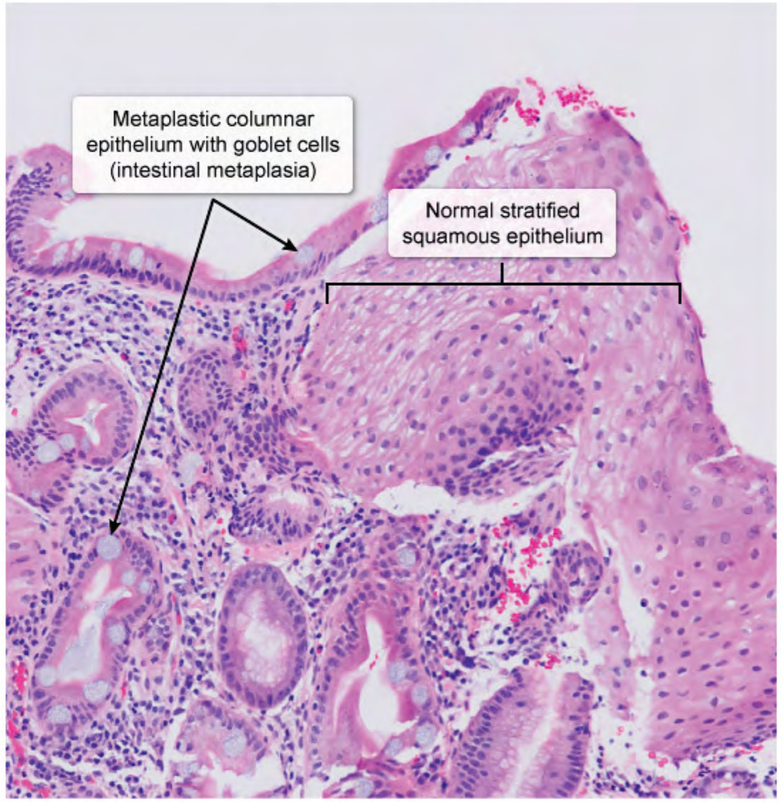

©UWorld

Zoom In | Zoom Out | Reset | New | Existing | My Notebook

https://t.me/USMLEWorldStep1

A 5-month-old boy is brought to the emergency department due to poor feeding, weakness, and complete loss of extremity muscle tone. He has had no fever or vomiting, but stool frequency has decreased. Vaccinations are up to date, and there is no significant medical history. The patient receives formula as his sole source of nutrition except for occasional fruit juice and honey. Physical examination reveals an alert but floppy infant who has a weak cry and diminished gag reflex. Which of the following is most likely to confirm the diagnosis in this patient?

- A. Cerebrospinal fluid culture
- B. Serum IgM antibody concentration
- C. Stool test for toxin assay
- D. Urine test for amino acids
- E. Urine test for glucose and ketones

Submit

https://t.me/USMLEWorldStep1

A 5-month-old boy is brought to the emergency department due to poor feeding, weakness, and complete loss of extremity muscle tone. He has had no fever or vomiting, but stool frequency has decreased. Vaccinations are up to date, and there is no significant medical history. The patient receives formula as his sole source of nutrition except for occasional fruit juice and honey. Physical examination reveals an alert but floppy infant who has a weak cry and diminished gag reflex. Which of the following is most likely to confirm the diagnosis in this patient?

- ✗ A. Cerebrospinal fluid culture
- B. Serum IgM antibody concentration
- ✓ C. Stool test for toxin assay
- D. Urine test for amino acids
- E. Urine test for glucose and ketones

Incorrect
Correct answer
C

Collecting Statistics

03 secs
Time Spent

2023
Version

Explanation

Infant botulism	
Pathogenesis	• Ingestion of *Clostridium botulinum* spores (eg, environmental dust/soil, honey) • Spores colonize the immature gastrointestinal tract & produce toxin • Toxin inhibits presynaptic acetylcholine release
Clinical presentation	• Age <12 months • Constipation, poor feeding, hypotonia • Oculobulbar palsies (eg, absent gag reflex, ptosis) • Symmetric, descending paralysis

https://t.me/USMLEWorldStep1

Explanation

Infant botulism	
Pathogenesis	• Ingestion of *Clostridium botulinum* spores (eg, environmental dust/soil, honey) • Spores colonize the immature gastrointestinal tract & produce toxin • Toxin inhibits presynaptic acetylcholine release
Clinical presentation	• Age <12 months • Constipation, poor feeding, hypotonia • Oculobulbar palsies (eg, absent gag reflex, ptosis) • Symmetric, descending paralysis
Diagnosis	• Classic presentation • Confirmation by stool *C botulinum* spores or toxin

This 5-month-old patient has consumed **honey**, a food notorious for contamination with ***Clostridium botulinum*** spores. Because infants have an immature digestive system compared to older children/adults, the pathogenic bacteria are more likely to germinate, colonize, and produce **botulinum toxin**, which is absorbed systemically and blocks the release of acetylcholine from cholinergic presynaptic terminals. In contrast, adult foodborne botulism usually results from ingestion of the preformed toxin (eg, contaminated canned foods).

The first manifestation of **infant botulism** is usually **constipation** followed days to weeks later by **weakness**, lethargy, and **reduced feeding**. In severe cases, infants can have a weak suck and cry, diminished gag reflex, and symmetric, descending **flaccid paralysis** (including extremities) with loss of head control that can cause the infant to appear floppy. Mental status is typically normal, as in this alert child, and fever is rare.

The diagnosis of infant botulism is clinical, but identification of *C botulinum* spores or **toxin in stool** is confirmatory. Treatment with botulinum antibodies is started before confirmatory testing is complete.

(Choice A) Bacterial meningitis can cause poor feeding, weakness, and hypotonia; cerebrospinal fluid (CSF) culture is diagnostic. In this patient, meningitis is less likely than botulism because of the lack of fever or bulging

https://t.me/USMLEWorldStep1

	• Confirmation by stool *C botulinum* spores or toxin

This 5-month-old patient has consumed **honey**, a food notorious for contamination with ***Clostridium botulinum*** spores. Because infants have an immature digestive system compared to older children/adults, the pathogenic bacteria are more likely to germinate, colonize, and produce **botulinum toxin**, which is absorbed systemically and blocks the release of acetylcholine from cholinergic presynaptic terminals. In contrast, adult foodborne botulism usually results from ingestion of the preformed toxin (eg, contaminated canned foods).

The first manifestation of **infant botulism** is usually **constipation** followed days to weeks later by **weakness**, lethargy, and **reduced feeding**. In severe cases, infants can have a weak suck and cry, diminished gag reflex, and symmetric, descending **flaccid paralysis** (including extremities) with loss of head control that can cause the infant to appear floppy. Mental status is typically normal, as in this alert child, and fever is rare.

The diagnosis of infant botulism is clinical, but identification of *C botulinum* spores or **toxin in stool** is confirmatory. Treatment with botulinum antibodies is started before confirmatory testing is complete.

(Choice A) Bacterial meningitis can cause poor feeding, weakness, and hypotonia; cerebrospinal fluid (CSF) culture is diagnostic. In this patient, meningitis is less likely than botulism because of the lack of fever or bulging fontanelle plus the history of honey ingestion. If obtained, CSF culture in botulism is normal.

(Choice B) Hyper-IgM syndrome primarily increases the risk for recurrent sinopulmonary and opportunistic infections (eg, *Pneumocystis jiroveci*), neither of which has been seen in this previously healthy child. Enteroviral meningoencephalitis risk is also increased in this condition, but patients are usually febrile with altered mental status (eg, lethargy).

(Choice D) Certain inborn errors of metabolism (eg, maple syrup urine disease) can manifest with hypotonia, weakness, and poor feeding; urine amino acids and/or ketones are typically elevated. In contrast to this case, however, symptom onset is usually in the neonatal period, vomiting is a typical finding, and paralysis would not be expected.

(Choice E) Ketonuria with glucosuria can occur in diabetic ketoacidosis, but this diagnosis would be extremely unlikely in a young infant and would not cause complete loss of tone.

Educational objective:

https://t.me/USMLEWorldStep1

bacteria are more likely to germinate, colonize, and produce **botulinum toxin**, which is absorbed systemically and blocks the release of acetylcholine from cholinergic presynaptic terminals. In contrast, adult foodborne botulism usually results from ingestion of the preformed toxin (eg, contaminated canned foods).

The first manifestation of **infant botulism** is usually **constipation** followed days to weeks later by **weakness**, lethargy, and **reduced feeding**. In severe cases, infants can have a weak suck and cry, diminished gag reflex, and symmetric, descending **flaccid paralysis** (including extremities) with loss of head control that can cause the infant to appear floppy. Mental status is typically normal, as in this alert child, and fever is rare.

The diagnosis of infant botulism is clinical, but identification of *C botulinum* spores or **toxin in stool** is confirmatory. Treatment with botulinum antibodies is started before confirmatory testing is complete.

(Choice A) Bacterial meningitis can cause poor feeding, weakness, and hypotonia; cerebrospinal fluid (CSF) culture is diagnostic. In this patient, meningitis is less likely than botulism because of the lack of fever or bulging fontanelle plus the history of honey ingestion. If obtained, CSF culture in botulism is normal.

(Choice B) Hyper-IgM syndrome primarily increases the risk for recurrent sinopulmonary and opportunistic infections (eg, *Pneumocystis jiroveci*), neither of which has been seen in this previously healthy child. Enteroviral meningoencephalitis risk is also increased in this condition, but patients are usually febrile with altered mental status (eg, lethargy).

(Choice D) Certain inborn errors of metabolism (eg, maple syrup urine disease) can manifest with hypotonia, weakness, and poor feeding; urine amino acids and/or ketones are typically elevated. In contrast to this case, however, symptom onset is usually in the neonatal period, vomiting is a typical finding, and paralysis would not be expected.

(Choice E) Ketonuria with glucosuria can occur in diabetic ketoacidosis, but this diagnosis would be extremely unlikely in a young infant and would not cause complete loss of tone.

Educational objective:
Infant botulism can result from the consumption of honey, which frequently contains *C botulinum* spores. Symptoms include constipation, mild weakness, lethargy, poor feeding, and, in severe cases, flaccid paralysis. The diagnosis can be confirmed by identification of *C botulinum* spores or toxins in the stool.

https://t.me/USMLEWorldStep1

presentation	• Oculobulbar palsies (eg, absent gag reflex, ptosis) • Symmetric, descending paralysis

Exhibit Display

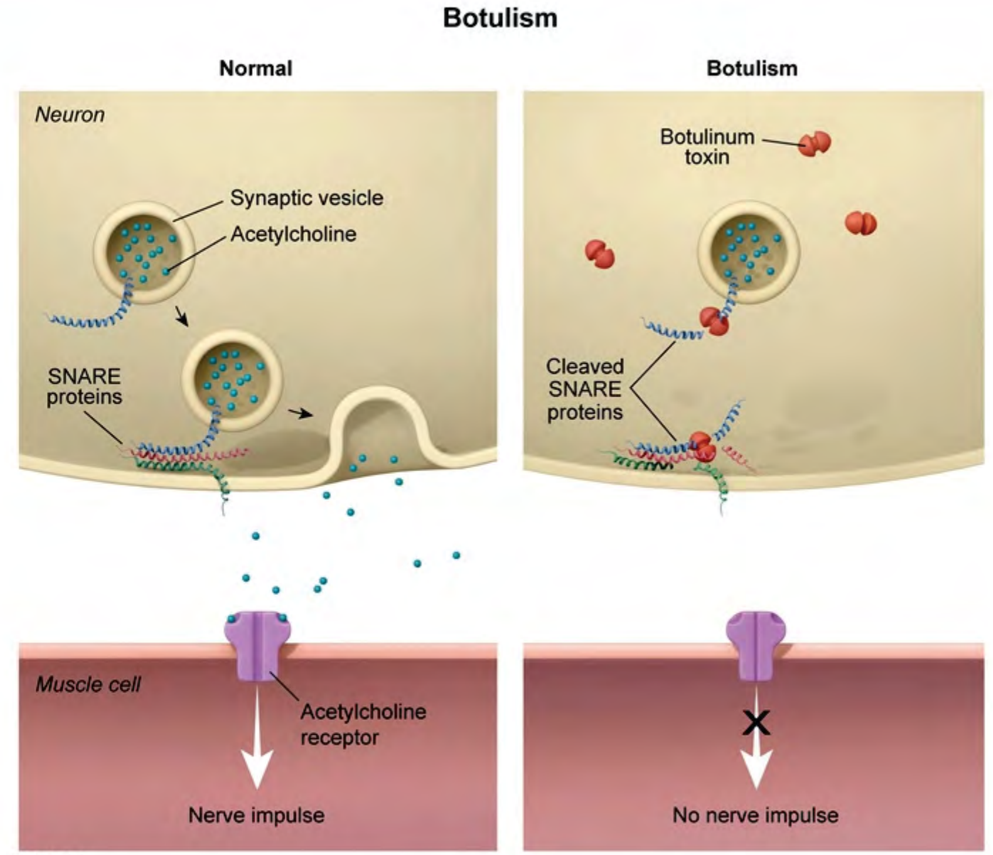

Zoom In | Zoom Out | Reset | New | Existing | My Notebook

This 5
spores
bacter
blocks
usually

The fir
letharg
symm
to app

The di
confirm

(Choi
culture
fontan

(Choi
infecti
menin
status

(Choi
weakn
howev
expected.

https://t.me/USMLEWorldStep1

A 32-year-old man comes to the office due to intermittent dysphagia for solids and liquids. He has no significant past medical history and does not use tobacco, alcohol, or illicit drugs. His father has a history of esophageal squamous cell carcinoma. Physical examination is unremarkable. The patient undergoes an esophageal manometric study that demonstrates periodic, simultaneous, and non-peristaltic contractions of large amplitude and long duration. Which of the following is the most likely pathogenesis of this patient's esophageal condition?

- A. Disruption of the gastroesophageal junction
- B. Eosinophil infiltration
- C. Impaired neural inhibition
- D. Mucosal outpouching through a muscular wall defect
- E. Obstruction from unregulated cell growth
- F. Smooth muscle atrophy and gut wall fibrosis

Submit

https://t.me/USMLEWorldStep1

A 32-year-old man comes to the office due to intermittent dysphagia for solids and liquids. He has no significant past medical history and does not use tobacco, alcohol, or illicit drugs. His father has a history of esophageal squamous cell carcinoma. Physical examination is unremarkable. The patient undergoes an esophageal manometric study that demonstrates periodic, simultaneous, and non-peristaltic contractions of large amplitude and long duration. Which of the following is the most likely pathogenesis of this patient's esophageal condition?

- A. Disruption of the gastroesophageal junction (6%)
- B. Eosinophil infiltration (2%)
- ✓ C. Impaired neural inhibition (77%)
- D. Mucosal outpouching through a muscular wall defect (3%)
- E. Obstruction from unregulated cell growth (3%)
- F. Smooth muscle atrophy and gut wall fibrosis (7%)

Correct

77%
Answered correctly

03 secs
Time Spent

2023
Version

Explanation

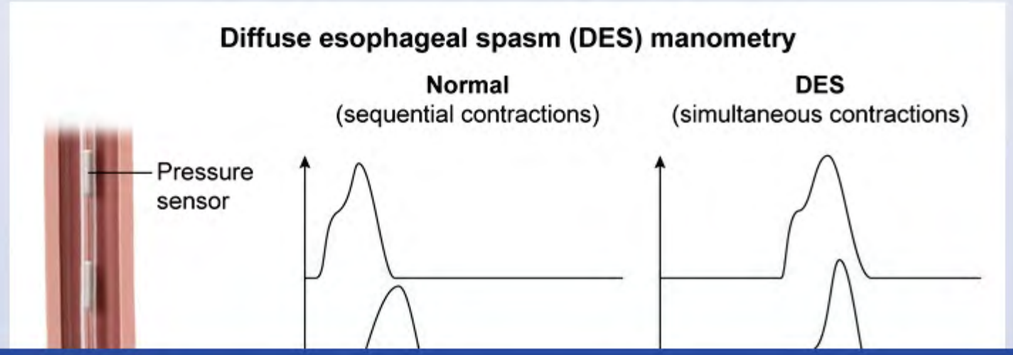

https://t.me/USMLEWorldStep1

A 32-year-old man comes to the office due to intermittent dysphagia for solids and liquids. He has no significant past m
squam
manor
and lo

Cor

Expl

Exhibit Display

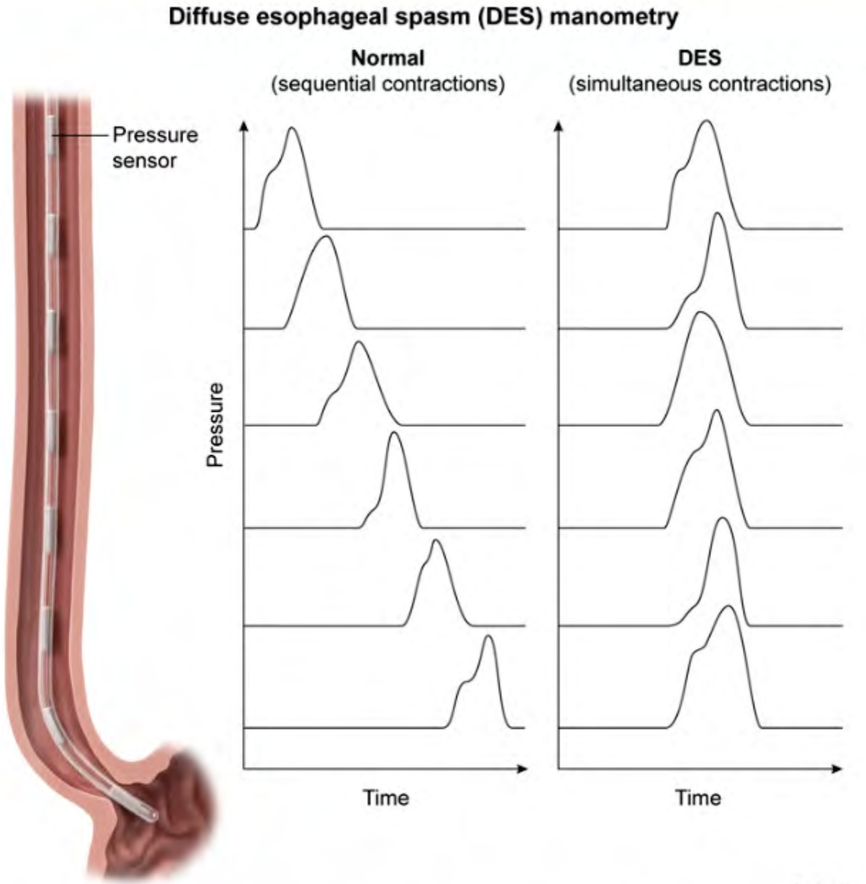

Zoom In Zoom Out Reset New | Existing My Notebook

https://t.me/USMLEWorldStep1

©UWorld

This patient's presentation is consistent with **diffuse esophageal spasm** (DES). Esophageal contractions are normally stimulated by esophageal distension from a food bolus. The contractions originate above the site of distension and propel the bolus downward in a coordinated fashion. In DES, several segments of the esophagus contract inappropriately at the same time, which appears as disorganized **non-peristaltic contractions** on esophageal manometry and "corkscrew" esophagus on barium esophagogram. Because the food bolus is inefficiently propelled toward the stomach, patients typically present with intermittent **solid/liquid dysphagia, chest pain**, heartburn, and food regurgitation. The pathogenesis of DES likely involves **impaired inhibitory neurotransmission** within the esophageal myenteric plexus.

(Choice A) Patients with sliding hiatal hernia often develop symptoms of gastroesophageal reflux (eg, heartburn, regurgitation, dysphagia) due to anatomic disruption of the gastroesophageal junction and impaired esophageal acid clearance. However, esophageal manometry is typically normal.

(Choice B) Eosinophilic esophagitis typically presents in atopic patients with solid food dysphagia and/or food impaction. Findings on esophageal manometry are nonspecific.

(Choice D) Zenker's diverticulum is a mucosal outpouching through an area of muscle weakness located in the wall of the hypopharynx (Killian triangle). The condition typically presents in elderly men with dysphagia, foul breath (halitosis), and food regurgitation.

(Choice E) Esophageal cancer typically presents with progressive solid food dysphagia and unintentional weight loss. Risk factors for squamous cell carcinoma include alcohol and tobacco use, whereas risk factors for adenocarcinoma include Barrett's esophagus, gastroesophageal reflux disease, smoking, and obesity.

(Choice F) Systemic sclerosis may involve the lower two-thirds of the esophagus, resulting in smooth muscle atrophy and gut wall fibrosis. Patients can develop dysphagia with acid reflux; however, manometry typically shows absent peristaltic waves with decreased lower esophageal sphincter tone.

Educational objective:
Diffuse esophageal spasm is characterized by periodic, simultaneous, and non-peristaltic contractions of the esophagus due to impaired inhibitory innervation within the esophageal myenteric plexus. Patients typically

https://t.me/USMLEWorldStep1

normally stimulated by esophageal distension from a food bolus. The contractions originate above the site of distension and propel the bolus downward in a coordinated fashion. In DES, several segments of the esophagus contract inappropriately at the same time, which appears as disorganized **non-peristaltic contractions** on esophageal manometry and "corkscrew" esophagus on barium esophagogram. Because the food bolus is inefficiently propelled toward the stomach, patients typically present with intermittent **solid/liquid dysphagia, chest pain**, heartburn, and food regurgitation. The pathogenesis of DES likely involves **impaired inhibitory neurotransmission** within the esophageal myenteric plexus.

(Choice A) Patients with sliding hiatal hernia often develop symptoms of gastroesophageal reflux (eg, heartburn, regurgitation, dysphagia) due to anatomic disruption of the gastroesophageal junction and impaired esophageal acid clearance. However, esophageal manometry is typically normal.

(Choice B) Eosinophilic esophagitis typically presents in atopic patients with solid food dysphagia and/or food impaction. Findings on esophageal manometry are nonspecific.

(Choice D) Zenker's diverticulum is a mucosal outpouching through an area of muscle weakness located in the wall of the hypopharynx (Killian triangle). The condition typically presents in elderly men with dysphagia, foul breath (halitosis), and food regurgitation.

(Choice E) Esophageal cancer typically presents with progressive solid food dysphagia and unintentional weight loss. Risk factors for squamous cell carcinoma include alcohol and tobacco use, whereas risk factors for adenocarcinoma include Barrett's esophagus, gastroesophageal reflux disease, smoking, and obesity.

(Choice F) Systemic sclerosis may involve the lower two-thirds of the esophagus, resulting in smooth muscle atrophy and gut wall fibrosis. Patients can develop dysphagia with acid reflux; however, manometry typically shows absent peristaltic waves with decreased lower esophageal sphincter tone.

Educational objective:
Diffuse esophageal spasm is characterized by periodic, simultaneous, and non-peristaltic contractions of the esophagus due to impaired inhibitory innervation within the esophageal myenteric plexus. Patients typically present with liquid/solid dysphagia and chest pain due to inefficient propulsion of food into the stomach.

References

- Distal esophageal spasm: an update.

https://t.me/USMLEWorldStep1

A 50-year-old man with a remote history of alcohol dependence is evaluated in the clinic for chronic diarrhea and weight loss. The patient has had bloating with daily loose stools for the past 2 years. His stool is described as greasy and malodorous. Pancreatic insufficiency is suspected despite normal abdominal imaging. The patient undergoes a test in which bicarbonate concentration is measured from duodenal aspirates as hormone A is infused intravenously. The data is plotted in the graph below.

Hormone A is most likely produced by which of the following cell types?

- A. Duodenal S cells
- B. Gastric G cells
- C. Pancreatic alpha cells
- D. Pancreatic beta cells
- E. Parenchymal hepatocytes
- F. Renal peritubular cells

Submit

https://t.me/USMLEWorldStep1

A 50-year-old man with a remote history of alcohol dependence is evaluated in the clinic for chronic diarrhea and weight
greasy
underg
intrave

Hormo

Sub

Exhibit Display

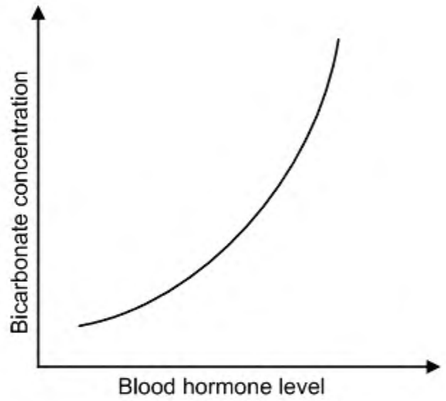

Zoom In Zoom Out Reset New | Existing My Notebook

https://t.me/USMLEWorldStep1

A 50-year-old man with a remote history of alcohol dependence is evaluated in the clinic for chronic diarrhea and weight loss. The patient has had bloating with daily loose stools for the past 2 years. His stool is described as greasy and malodorous. Pancreatic insufficiency is suspected despite normal abdominal imaging. The patient undergoes a test in which bicarbonate concentration is measured from duodenal aspirates as hormone A is infused intravenously. The data is plotted in the graph below.

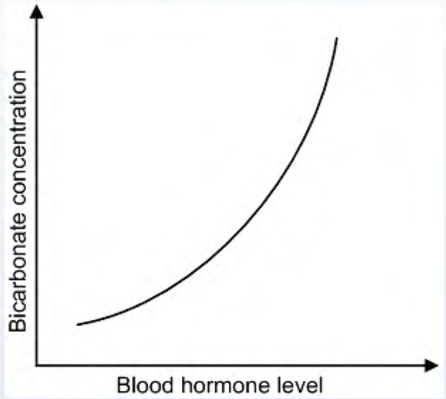

Hormone A is most likely produced by which of the following cell types?

- ✓ A. Duodenal S cells (81%)
- B. Gastric G cells (9%)
- ✗ C. Pancreatic alpha cells (5%)
- D. Pancreatic beta cells (1%)
- E. Parenchymal hepatocytes (0%)
- F. Renal peritubular cells (0%)

Incorrect
Correct answer
A

81%
Answered correctly

09 secs
Time Spent

2023
Version

https://t.me/USMLEWorldStep1

Important gastrointestinal hormones		
Hormone	**Actions**	**Secretion site**
Gastrin	• ↑ Gastric H^+ secretion	G cells (gastric antrum, duodenum)
Somatostatin	• ↓ Secretion of most GI hormones	D cells (pancreatic islets, gut mucosa)
Cholecystokinin	• ↑ Pancreatic enzyme & HCO_3^- secretion	I cells (small intestine)
Secretin	• ↑ Pancreatic HCO_3^- secretion • ↓ Gastric H^+ secretion	S cells (small intestine)
GIP	• ↑ Insulin release • ↓ Gastric H^+ secretion	K cells (small intestine)
Motilin	• ↑ GI motility	M cells (small intestine)
GI = gastrointestinal; **GIP** = gastric inhibitory peptide; **H^+** = hydrochloric acid; **HCO_3^-** = bicarbonate.		

Secretin is a hormone produced by **intestinal S cells** that **increases bicarbonate secretion** from the pancreas. Secretin stimulates the **exocrine pancreatic ductal cells** to release a high volume of **bicarbonate-rich and chloride-poor fluid** into the small bowel. The release of gastric acid into the duodenum is the most potent stimulus for secretin release, which begins as the duodenal pH drops below 5 and rises dramatically as the pH drops below 3. The sodium bicarbonate in the pancreatic secretions neutralizes the hydrochloric acid from the gastric contents in a reaction that produces sodium chloride and carbonic acid. Secretin has little to no effect on the secretion of enzymes from pancreatic acinar cells, which is instead under the control of cholecystokinin.

(Choice B) Gastrin is the major hormone secreted by G cells of the gastric antrum. Gastrin increases parietal cell acid production and therefore increases the amount of acid delivered from the stomach to the duodenum.

(Choices C and D) The endocrine pancreas is composed of glucagon-producing alpha cells, insulin-producing beta cells, and somatostatin-producing D cells. Insulin and glucagon help regulate blood glucose levels and metabolic homeostasis. Somatostatin inhibits the secretion of insulin, glucagon, gastrin, and most other

https://t.me/USMLEWorldStep1

Motilin	• ↑ GI motility	M cells (small intestine)

GI = gastrointestinal; **GIP** = gastric inhibitory peptide; **H^+** = hydrochloric acid; **HCO_3^-** = bicarbonate.

Secretin is a hormone produced by **intestinal S cells** that **increases bicarbonate secretion** from the pancreas. Secretin stimulates the **exocrine pancreatic ductal cells** to release a high volume of **bicarbonate-rich and chloride-poor fluid** into the small bowel. The release of gastric acid into the duodenum is the most potent stimulus for secretin release, which begins as the duodenal pH drops below 5 and rises dramatically as the pH drops below 3. The sodium bicarbonate in the pancreatic secretions neutralizes the hydrochloric acid from the gastric contents in a reaction that produces sodium chloride and carbonic acid. Secretin has little to no effect on the secretion of enzymes from pancreatic acinar cells, which is instead under the control of cholecystokinin.

(Choice B) Gastrin is the major hormone secreted by G cells of the gastric antrum. Gastrin increases parietal cell acid production and therefore increases the amount of acid delivered from the stomach to the duodenum.

(Choices C and D) The endocrine pancreas is composed of glucagon-producing alpha cells, insulin-producing beta cells, and somatostatin-producing D cells. Insulin and glucagon help regulate blood glucose levels and metabolic homeostasis. Somatostatin inhibits the secretion of insulin, glucagon, gastrin, and most other gastrointestinal hormones.

(Choice E) The liver parenchyma is not a significant source of circulating hormones that affect pancreatic exocrine function.

(Choice F) Renal peritubular cells are responsible for producing erythropoietin, a hormone that stimulates red blood cell production in the bone marrow.

Educational objective:
Secretin is produced by S cells in the duodenal mucosa in response to stimulation by intraluminal acidity. Secretin stimulates the release of bicarbonate-rich secretions from the exocrine pancreas, which is the major source of acid-neutralizing bicarbonate entering the duodenum.

References

- Secretin, 100 years later.
- Neurohormonal control of exocrine pancreas

https://t.me/USMLEWorldStep1

A 58-year-old man comes to the office with upper abdominal pain, fatigue, and anorexia. He says his symptoms began about a month ago and seem to be getting worse. The patient has a history of cirrhosis due to chronic hepatitis C. Physical examination shows cachexia and worsening ascites. Imaging studies reveal a large mass in the right hepatic lobe consistent with unresectable hepatocellular cancer. The patient is scheduled to undergo percutaneous embolization of the artery supplying the tumor. Contrast material administration into which of the following structures is most likely to visually enhance the artery prior to embolization?

- A. Celiac trunk
- B. Gastroduodenal artery
- C. Inferior mesenteric artery
- D. Inferior vena cava
- E. Splenic artery
- F. Superior mesenteric artery

Submit

https://t.me/USMLEWorldStep1

A 58-year-old man comes to the office with upper abdominal pain, fatigue, and anorexia. He says his symptoms began about a month ago and seem to be getting worse. The patient has a history of cirrhosis due to chronic hepatitis C. Physical examination shows cachexia and worsening ascites. Imaging studies reveal a large mass in the right hepatic lobe consistent with unresectable hepatocellular cancer. The patient is scheduled to undergo percutaneous embolization of the artery supplying the tumor. Contrast material administration into which of the following structures is most likely to visually enhance the artery prior to embolization?

- ✓ A. Celiac trunk (83%)
- ✗ B. Gastroduodenal artery (5%)
- C. Inferior mesenteric artery (0%)
- D. Inferior vena cava (3%)
- E. Splenic artery (1%)
- F. Superior mesenteric artery (5%)

Incorrect
Correct answer
A

83%
Answered correctly

03 secs
Time Spent

2023
Version

Explanation

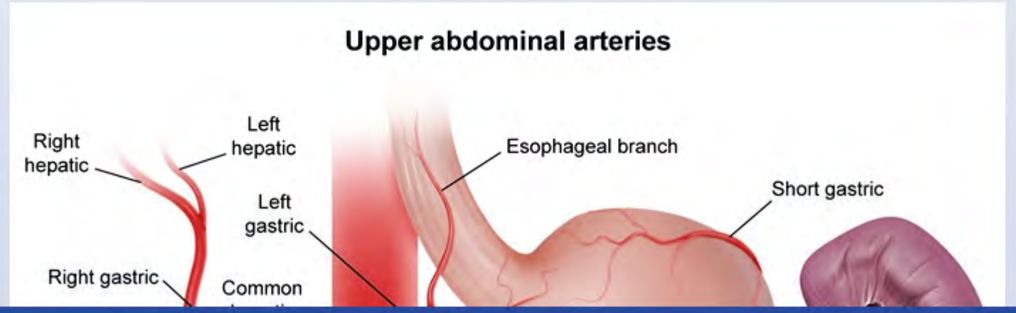

https://t.me/USMLEWorldStep1

Correct answer
A

83%
Answered correctly

03 secs
Time Spent

2023
Version

Exhibit Display

Expl

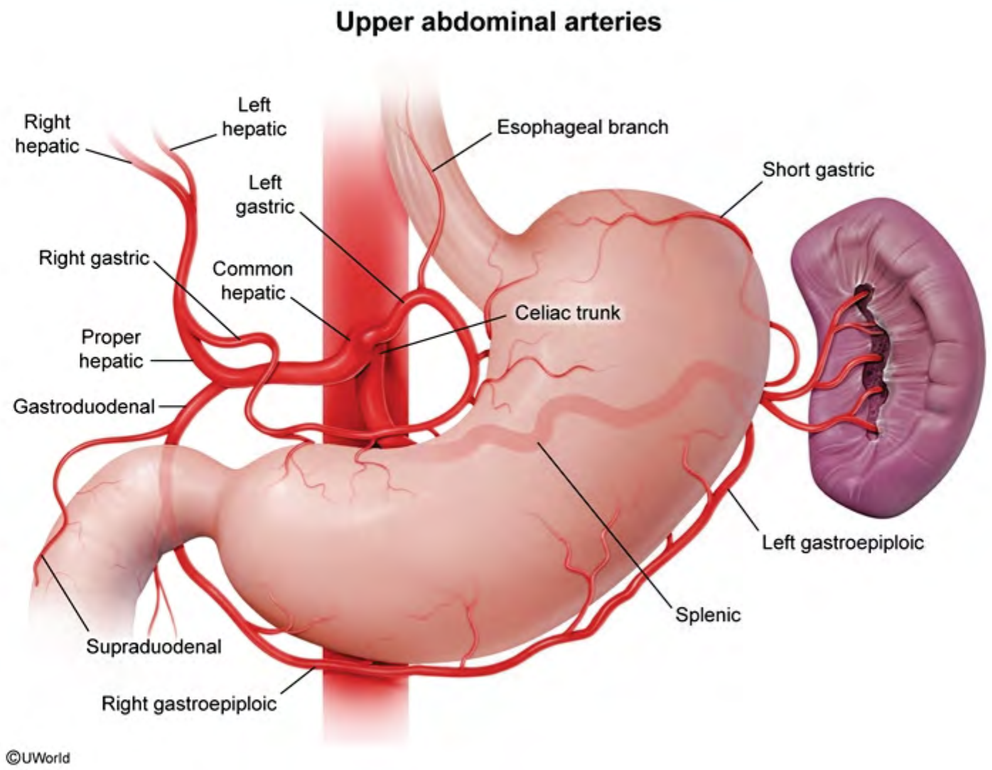

Zoom In | Zoom Out | Reset | New | Existing | My Notebook

The va
anteric
splenic
blood to the abdominal esophagus and upper stomach. The splenic artery and its branches (dorsal pancreatic, short gastric, left gastro-omental, and greater pancreatic arteries) provide blood to the spleen, the gastric fundus,

https://t.me/USMLEWorldStep1

The vascular supply to the upper abdomen mainly comes from the **celiac trunk** (celiac artery), which is the first anterior branch of the abdominal aorta. The celiac trunk branches into the left gastric, **common hepatic**, and splenic arteries. The left gastric artery further divides into the esophageal and stomach branches, which supply blood to the abdominal esophagus and upper stomach. The splenic artery and its branches (dorsal pancreatic, short gastric, left gastro-omental, and greater pancreatic arteries) provide blood to the spleen, the gastric fundus, and part of the pancreas **(Choice E)**.

The common hepatic artery further divides into the gastroduodenal and proper hepatic arteries. The gastroduodenal artery supplies blood to the pylorus, proximal duodenum, and pancreatic head **(Choice B)**.

The **proper hepatic** artery divides into the left and right hepatic arteries, which provide arterial blood supply to the liver and would perfuse this patient's right hepatic lobe mass.

(Choice C) The inferior mesenteric artery branches off the abdominal aorta at the L3 level (inferior to both the celiac trunk and superior mesenteric artery). This artery provides blood supply to the colon from the splenic flexure to the upper rectum (eg, descending and sigmoid colon).

(Choice D) The inferior vena cava (IVC) is formed by the union of both common iliac veins and drains blood from the lower part of the body to the right atrium. Other veins that empty into the IVC include the hepatic, renal, lumbar, and gonadal veins.

(Choice F) The superior mesenteric artery branches off the abdominal aorta inferior to the origin of the celiac trunk. The superior mesenteric artery supplies blood to part of the pancreas and the intestine from the lower part of the duodenum to the first two-thirds of the transverse colon.

Educational objective:
The celiac trunk is the first main branch of the abdominal aorta; it provides oxygenated blood to the spleen, stomach, liver, abdominal esophagus, and parts of the duodenum and pancreas. The proper hepatic artery branches off the common hepatic artery from the celiac trunk and provides arterial blood supply to the liver.

Anatomy	Gastrointestinal & Nutrition	Cardiovascular anatomy
Subject	System	Topic

Copyright © UWorld. All rights reserved.

https://t.me/USMLEWorldStep1

A 53-year-old man comes to the office for routine follow-up after a total gastrectomy. The patient was recently diagnosed with a gastric malignancy after several months of weight loss, fatigue, and anorexia. He underwent an uncomplicated total gastrectomy and has had no postoperative complications. This patient will require lifelong administration of which of the following substances?

- A. Gastric enzymes
- B. Hydrochloric acid
- C. Hydrolyzed dietary protein
- D. Medium-chain triglycerides
- E. Water-soluble vitamin

Submit

https://t.me/USMLEWorldStep1

A 53-year-old man comes to the office for routine follow-up after a total gastrectomy. The patient was recently diagnosed with a gastric malignancy after several months of weight loss, fatigue, and anorexia. He underwent an uncomplicated total gastrectomy and has had no postoperative complications. This patient will require lifelong administration of which of the following substances?

- A. Gastric enzymes
- ✗ B. Hydrochloric acid
- C. Hydrolyzed dietary protein
- D. Medium-chain triglycerides
- ✓ E. Water-soluble vitamin

Incorrect
Correct answer
E

Collecting Statistics

06 secs
Time Spent

2023
Version

Explanation

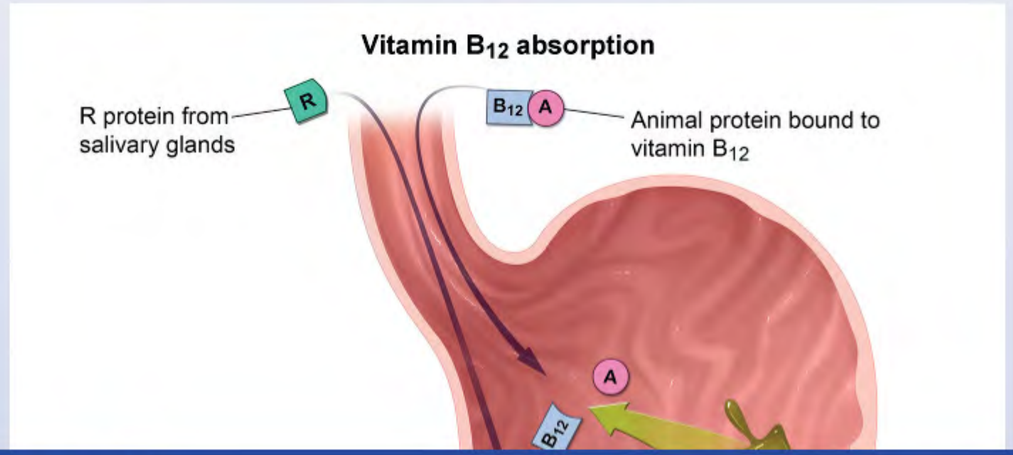

https://t.me/USMLEWorldStep1

A 53-year-old man comes to the office for routine follow-up after a total gastrectomy. The patient was recently diagnc
uncom
admin

Exhibit Display

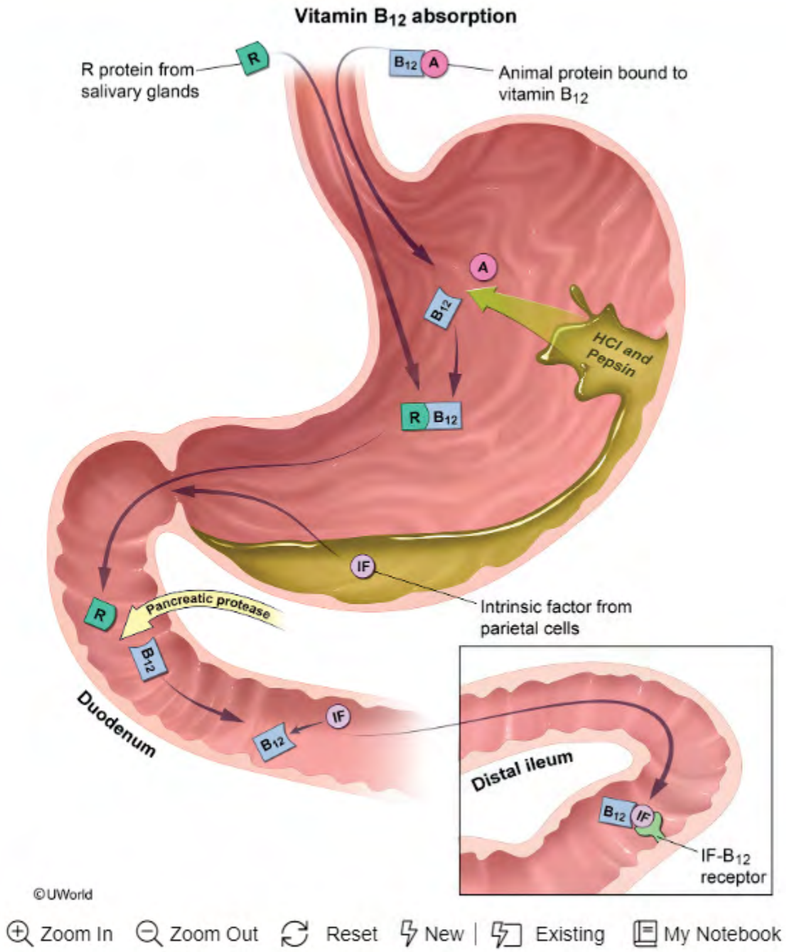

Zoom In | Zoom Out | Reset | New | Existing | My Notebook

Inco
Corre
E

Expl

https://t.me/USMLEWorldStep1

The stomach performs several important functions:

- **Protein digestion:** Gastric parietal cells and chief cells produce hydrochloric acid (HCl) and pepsinogen, respectively. HCl helps denature dietary protein (improving proteolysis) and converts pepsinogen to its active form, pepsin, which preferentially cleaves polypeptides at aromatic amino acid locations. However, patients can still digest protein after undergoing total gastrectomy because of the action of **pancreatic and intestinal proteases**, which degrade dietary proteins into basic amino acids in the small intestine; therefore, it is unnecessary to administer gastric enzymes, HCl, or hydrolyzed protein in these patients **(Choices A, B, and C)**.
- **Intrinsic factor (IF) secretion:** Parietal cells in the body and fundus of the stomach secrete IF, a glycoprotein that binds to vitamin B_{12}, a **water-soluble** vitamin. The vitamin B_{12}–IF complex is absorbed by enterocytes in the terminal ileum. In patients who have undergone a total **gastrectomy**, IF is no longer produced, and vitamin B_{12} cannot be absorbed enterally in an efficient manner (only ~1% of ingested vitamin B_{12} is absorbed without IF). Therefore, **lifelong administration** of B_{12} is required (eg, vitamin B_{12} injections).
- **Gastric reservoir:** The stomach also serves as a reservoir for ingested food. This function is lost after total gastrectomy, and accelerated emptying of hyperosmolar food boluses into the small bowel results in **dumping syndrome**, which is characterized by colicky abdominal pain, nausea, and diarrhea. Avoidance of large meals and low dietary intake of simple sugars improve these symptoms.

(Choice D) Medium-chain triglycerides can passively diffuse from the gastrointestinal lumen into enterocytes, but they are best absorbed after being degraded into monoglycerides and free fatty acids by lingual and pancreatic lipase. Supplementation is not necessary in patients with total gastrectomy.

Educational objective:
Intrinsic factor is a glycoprotein that is normally secreted by parietal cells in the stomach that is necessary for the majority (~99%) of vitamin B_{12} absorption in the ileum. Patients who have undergone a total gastrectomy require lifelong vitamin B_{12} supplementation due to inability to produce intrinsic factor.

Pathophysiology	Gastrointestinal & Nutrition	Gastrectomy
Subject	System	Topic

https://t.me/USMLEWorldStep1

A 46-year-old man comes to the office due to abdominal discomfort and diarrhea. The symptoms began 6 months ago, and he has now developed significant weight loss. The patient does not use tobacco or alcohol. Intestinal biopsy is performed, and a periodic acid–Schiff (PAS) stained section is shown in the image below:

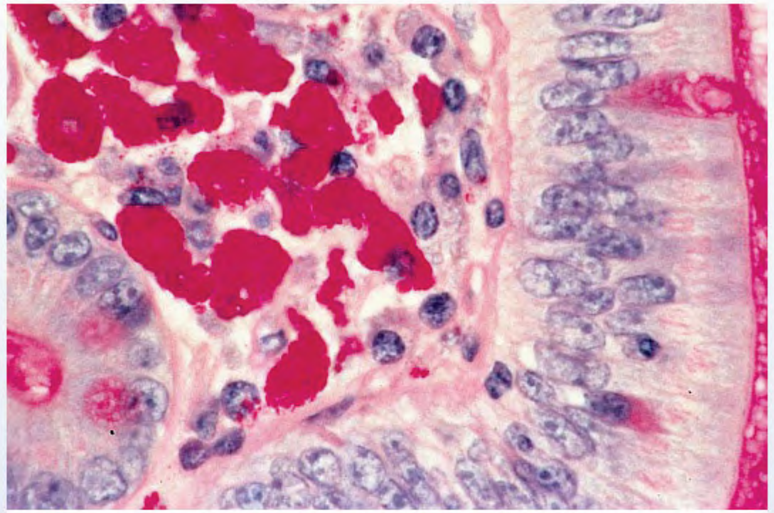

Displayed with permission from Springer Healthcare Ltd. © Copyright 1997, 2004 by Current Medicine

Which of the following is the most likely cause of this patient's symptoms?

- A. Chronic bacterial infection
- B. Immune-mediated gluten sensitivity
- C. Impaired lipoprotein formation
- D. Lactase deficiency
- E. Viral infection

Submit

https://t.me/USMLEWorldStep1

A 46-year-old man comes to the office due to abdominal discomfort and diarrhea. The symptoms began 6 months ago, and he has now developed significant weight loss. The patient does not use tobacco or alcohol. Intestinal biopsy is performed, and a periodic acid–Schiff (PAS) stained section is shown in the image below:

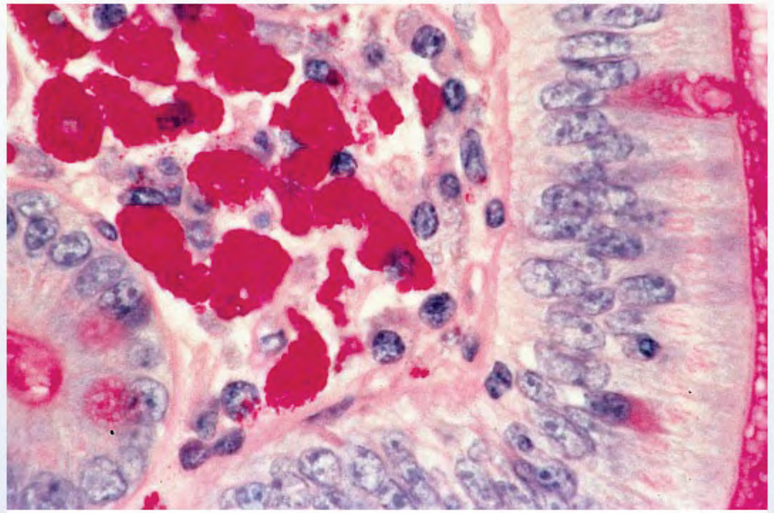

Displayed with permission from Springer Healthcare Ltd. © Copyright 1997, 2004 by Current Medicine

Which of the following is the most likely cause of this patient's symptoms?

- ✓ A. Chronic bacterial infection (64%)
- ✗ B. Immune-mediated gluten sensitivity (17%)
- C. Impaired lipoprotein formation (8%)
- D. Lactase deficiency (3%)
- E. Viral infection (4%)

Incorrect
Correct answer
A

64%
Answered correctly

09 secs
Time Spent

2023
Version

https://t.me/USMLEWorldStep1

A 46-year-old man comes to the office due to abdominal discomfort and diarrhea. The symptoms began 6 months ago, a
biopsy

Exhibit Display

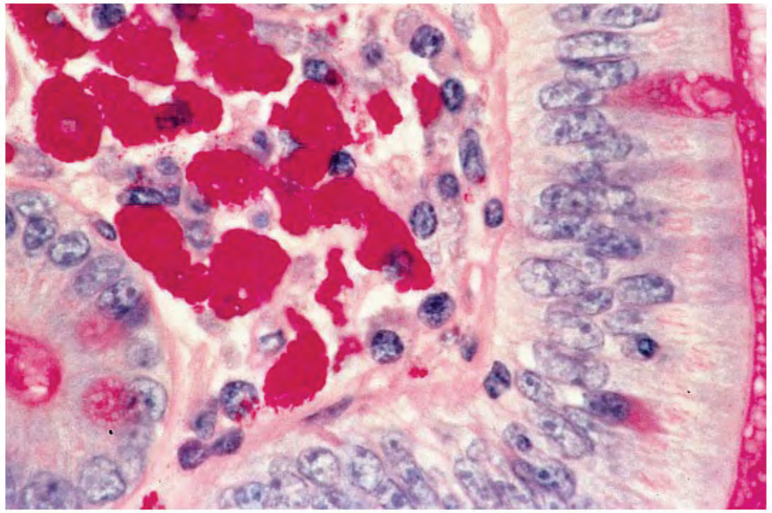

Displayed with permission from Springer Healthcare Ltd. © Copyright 1997, 2004 by Current Medicine

Zoom In | Zoom Out | Reset | New | Existing | My Notebook

Which

Incc
Correct answer
A

64%
Answered correctly

09 secs
Time Spent

2023
Version

https://t.me/USMLEWorldStep1

Explanation

This patient with abdominal pain and malabsorption has intestinal biopsy findings consistent with **Whipple disease**, a rare, systemic, **chronic bacterial infection** that most commonly presents in middle-aged men (age 40-60). It is caused by ***Tropheryma whipplei***, a gram-positive, rod-shaped actinomycete.

Following ingestion, the bacteria are engulfed by macrophages in the small intestine mucosa. *T whipplei* interferes with phagolysosome development and antigen presentation, allowing the organism to **replicate within macrophages** with minimal inflammatory response. Buildup of infected macrophages can block lymphatic channels, leading to **malabsorption** (eg, diarrhea, steatorrhea, weight loss, abdominal pain). *T whipplei* can also spread to the joints, causing arthralgia. In later stages of the disease, the infection can involve the central nervous system (eg, dementia) and heart (eg, endocarditis).

Diagnosis can be confirmed with biopsy of the small intestine. Microscopic examination of the lamina propria shows numerous **foamy macrophages** distended by bacilli that are characteristically positive for **periodic acid–Schiff** (PAS) stain. PAS stains polysaccharides in the *T whipplei* membrane, imparting a magenta color.

(Choice B) Celiac disease, an immune-mediated hypersensitivity to dietary gluten, can present with abdominal pain, diarrhea, and weight loss. However, biopsy of the small intestine would likely show villous atrophy, increased intraepithelial lymphocytes, and crypt hyperplasia.

(Choice C) Abetalipoproteinemia is caused by an inherited defect in formation of apolipoprotein B–containing lipoproteins. This results in impaired lipid transport, leading to fat accumulation within enterocytes. Although malabsorptive symptoms are seen, this disease presents during the first year of life, and intestinal biopsy shows enterocytes with clear cytoplasmic lipid vacuoles.

(Choice D) Lactase deficiency can cause abdominal pain and diarrhea following dairy consumption. However, microscopic examination of the small intestine typically shows no abnormalities.

(Choice E) Although viral gastroenteritis (eg, norovirus) often presents with abdominal pain and diarrhea, symptoms typically resolve within a week in immunocompetent patients. Intestinal biopsy may show inflammation in the lamina propria, but PAS-positive macrophages would not be expected.

Educational objective:

https://t.me/USMLEWorldStep1

macrophages with minimal inflammatory response. Buildup of infected macrophages can block lymphatic channels, leading to **malabsorption** (eg, diarrhea, steatorrhea, weight loss, abdominal pain). *T whipplei* can also spread to the joints, causing arthralgia. In later stages of the disease, the infection can involve the central nervous system (eg, dementia) and heart (eg, endocarditis).

Diagnosis can be confirmed with biopsy of the small intestine. Microscopic examination of the lamina propria shows numerous **foamy macrophages** distended by bacilli that are characteristically positive for **periodic acid–Schiff** (PAS) stain. PAS stains polysaccharides in the *T whipplei* membrane, imparting a magenta color.

(Choice B) Celiac disease, an immune-mediated hypersensitivity to dietary gluten, can present with abdominal pain, diarrhea, and weight loss. However, biopsy of the small intestine would likely show villous atrophy, increased intraepithelial lymphocytes, and crypt hyperplasia.

(Choice C) Abetalipoproteinemia is caused by an inherited defect in formation of apolipoprotein B–containing lipoproteins. This results in impaired lipid transport, leading to fat accumulation within enterocytes. Although malabsorptive symptoms are seen, this disease presents during the first year of life, and intestinal biopsy shows enterocytes with clear cytoplasmic lipid vacuoles.

(Choice D) Lactase deficiency can cause abdominal pain and diarrhea following dairy consumption. However, microscopic examination of the small intestine typically shows no abnormalities.

(Choice E) Although viral gastroenteritis (eg, norovirus) often presents with abdominal pain and diarrhea, symptoms typically resolve within a week in immunocompetent patients. Intestinal biopsy may show inflammation in the lamina propria, but PAS-positive macrophages would not be expected.

Educational objective:
Whipple disease is caused by a chronic infection with *Tropheryma whipplei*, a gram-positive bacterium that can affect multiple organ systems. It typically presents in middle-aged men with malabsorption and arthralgia. Intestinal biopsy characteristically shows foamy macrophages in the lamina propria filled with bacilli that are positive for periodic acid–Schiff stain.

References

- Clinical manifestations, treatment, and diagnosis of Tropheryma whipplei infections.

https://t.me/USMLEWorldStep1

Explanation

This p
diseas
60). It

Follow
with pl
macro
chann
spread
systen

Diagn
shows
Schiff

(Choi
pain, d
intraep

(Choi
lipopro
malab
entero

(Choi
micros

(Choi
sympt
in the lamina propria, but PAS-positive macrophages would not be expected.

Educational objective:

Exhibit Display

Whipple disease

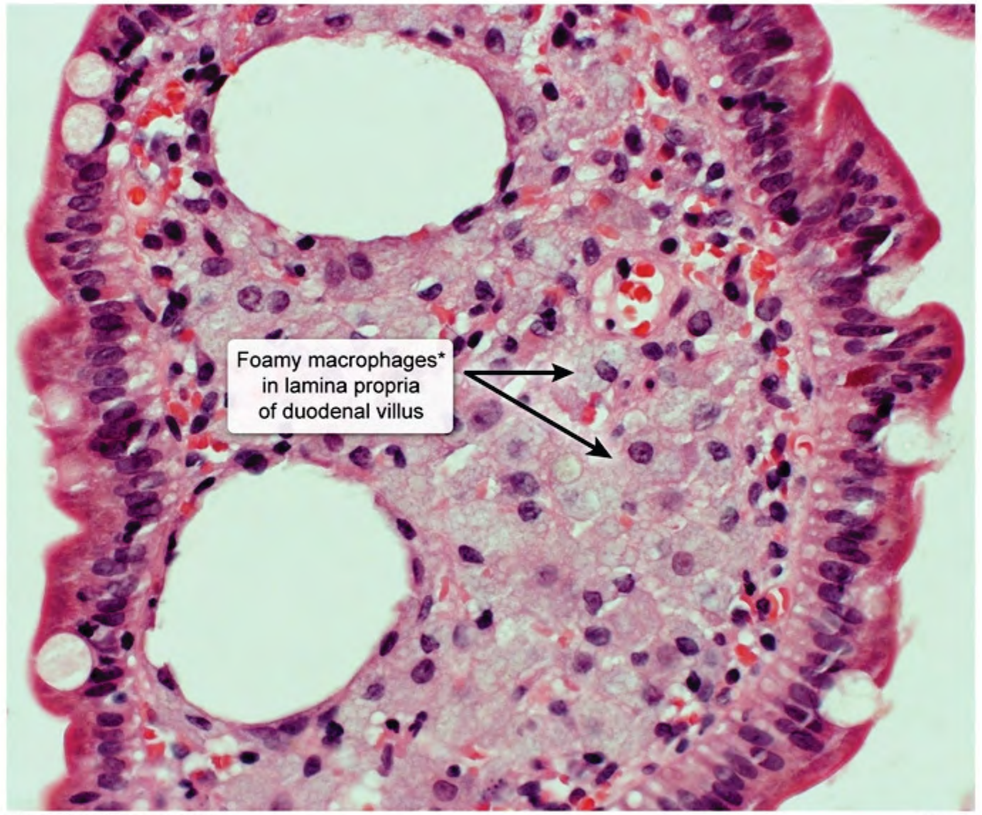

*Contain *Tropheryma whipplei*

©UWorld

Zoom In | Zoom Out | Reset | New | Existing | My Notebook

https://t.me/USMLEWorldStep1

Explanation

This p
diseas
60). It

Follow
with pl
macro
chann
spread
systen

Diagn
shows
Schiff

(Choi
pain, d
intraep

(Choi
lipopro
malab
entero

(Choi
micros

(Choi
sympt
in the lamina propria, but PAS-positive macrophages would not be expected.

Educational objective:

Exhibit Display

Whipple disease

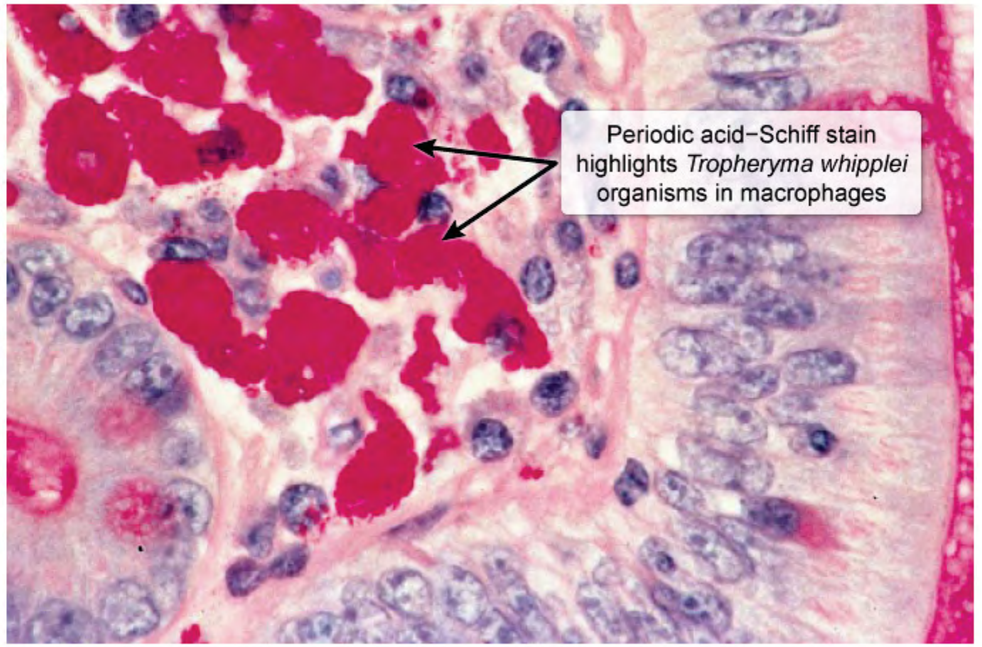

Displayed with permission from Springer Healthcare Ltd. © Copyright 1997, 2004 by Current Medicine

Zoom In | Zoom Out | Reset | New | Existing | My Notebook

https://t.me/USMLEWorldStep1

Explanation

This p
diseas
60). It

Follow
with pl
macro
chann
spread
systen

Diagn
shows
Schiff

(Choi
pain, d
intraep

(Choi
lipopro
malab
entero

(Choi
micros

(Choi
sympt
in the lamina propria, but PAS-positive macrophages would not be expected.

Educational objective:

Exhibit Display

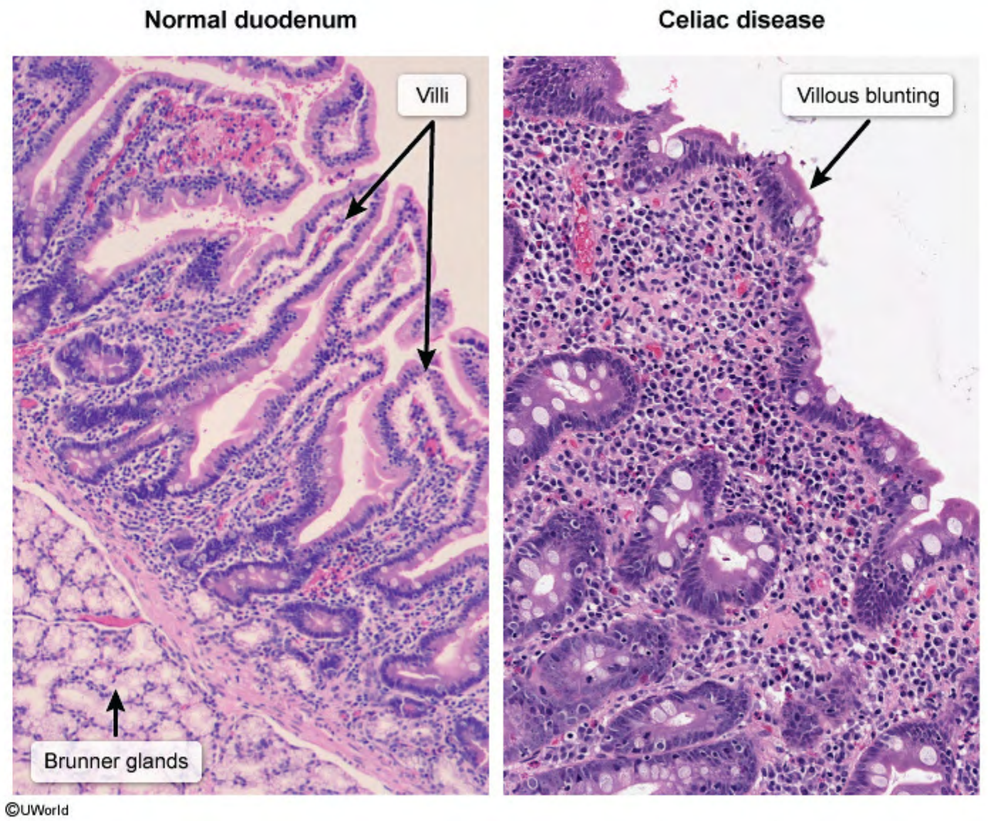

Zoom In Zoom Out Reset New | Existing My Notebook

https://t.me/USMLEWorldStep1

In an animal experiment, murine proerythroblasts are cultured in 2 different growth media; the first medium is folate deficient, whereas the second (control) is supplemented with additional folic acid. Both media contain high concentrations of erythropoietin. Over 48 hours, cells in the control media proliferate and differentiate into reticulocytes, whereas in the folate-deficient media, cell proliferation is minimal, with the majority of cells undergoing apoptosis. In another experiment, a substance is added to the folate-deficient media; this substance prevents apoptosis and permits proliferation of some of the proerythroblasts. Which of the following is the most likely substance added to the growth medium?

- A. Cobalamin
- B. Cytosine
- C. Glutamine
- D. Homocysteine
- E. Thymidine

Submit

https://t.me/USMLEWorldStep1

In an animal experiment, murine proerythroblasts are cultured in 2 different growth media; the first medium is folate deficient, whereas the second (control) is supplemented with additional folic acid. Both media contain high concentrations of erythropoietin. Over 48 hours, cells in the control media proliferate and differentiate into reticulocytes, whereas in the folate-deficient media, cell proliferation is minimal, with the majority of cells undergoing apoptosis. In another experiment, a substance is added to the folate-deficient media; this substance prevents apoptosis and permits proliferation of some of the proerythroblasts. Which of the following is the most likely substance added to the growth medium?

- A. Cobalamin (40%)
- ✗ B. Cytosine (2%)
- C. Glutamine (3%)
- D. Homocysteine (21%)
- ✓ E. Thymidine (31%)

Incorrect
Correct answer
E

31%
Answered correctly

03 secs
Time Spent

2023
Version

Explanation

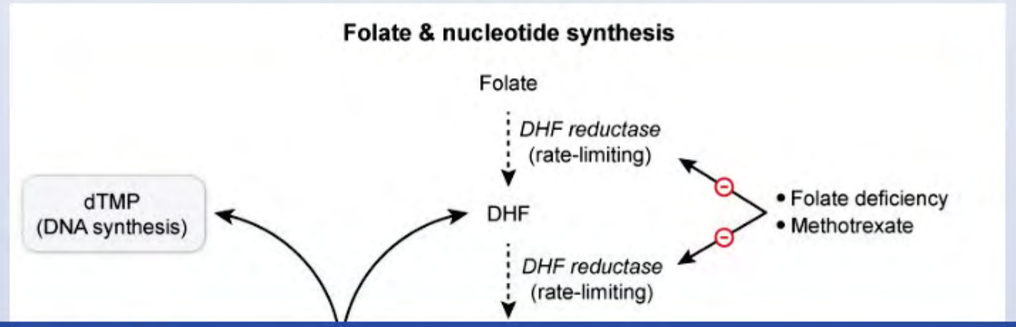

https://t.me/USMLEWorldStep1

In an animal experiment, murine proerythroblasts are cultured in 2 different growth media; the first medium is folate
deficie
concer
reticul
underg
prever
likely s

Incc
Corre
E

Expl

Exhibit Display

Folate & nucleotide synthesis

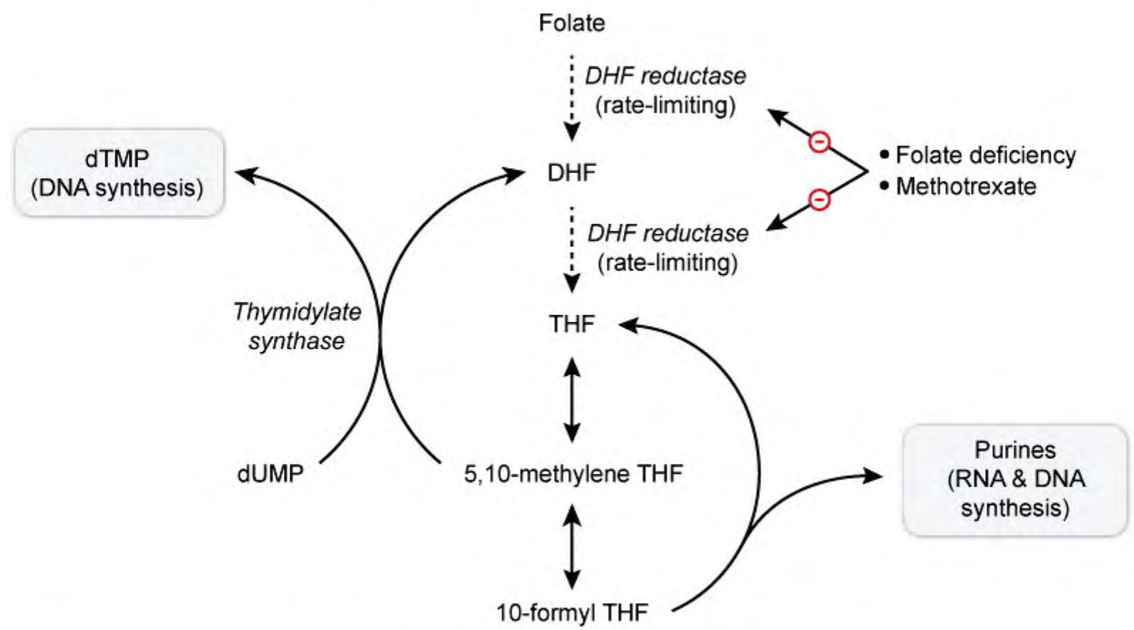

dTMP = deoxythymidine monophosphate; **dUMP** = deoxyuridine monophosphate; **DHF** = dihydrofolate; **THF** = tetrahydrofolate.

©UWorld

Zoom In | Zoom Out | Reset | New | Existing | My Notebook

DHF reductase
(rate-limiting)

https://t.me/USMLEWorldStep1

©UWorld

Folate derivatives are crucial in the synthesis of nucleic acids (particularly thymine), conversion of homocysteine to methionine, and generation of one-carbon carriers (eg, S-adenosylmethionine) for methylation reactions. All biochemical functions of folate require the reduced **tetrahydrofolate** form of the vitamin, which is synthesized by dihydrofolate reductase (a rate-limiting step in folate metabolism).

The enzyme **thymidylate synthase** is responsible for converting deoxyuridine monophosphate (dUMP) to deoxythymidine monophosphate (dTMP). Although most enzymes involved in one-carbon metabolism maintain folate in its active tetrahydrofolate form, thymidylate synthase is unique in that it oxidizes 5,10-methylenetetrahydrofolate to dihydrofolate. This makes **de novo thymidine synthesis** particularly susceptible to folate-deficient conditions because tetrahydrofolate must be continuously regenerated by dihydrofolate reductase.

In this experiment, inhibition of thymidylate synthase due to **deficient folate** increases the ratio of dUMP to dTMP, causing the incorporation of **uracil into DNA** in place of thymidine. This leads to excessive activation of DNA repair mechanisms, resulting in double-stranded DNA breaks and apoptosis. **Thymidine** supplementation reduces the metabolic folate demand, **preventing apoptosis** in folate-deficient cells.

(Choice A) Cobalamin is a necessary cofactor for methionine synthase, the enzyme that transfers a methyl group from 5-methyltetrahydrofolate to homocysteine, forming methionine and regenerating tetrahydrofolate. Cobalamin deficiency can cause folate to become trapped in 5-methyltetrahydrofolate form, resulting in secondary folate deficiency.

(Choice B) Cytosine is a pyrimidine base. Unlike thymine, it is not dependent on folate and can be synthesized in sufficient quantities under folate-deficient conditions.

(Choice C) Glutamine is a major source of nitrogen in the synthesis of purine and pyrimidine bases. However, glutamine supplementation would not ameliorate the cellular apoptosis induced by folate deficiency.

(Choice D) Homocysteine is an amino acid associated with endothelial cell injury and vascular inflammation. Levels are elevated in folate deficiency due to impaired conversion into methionine.

Educational objective:
Folate deficiency inhibits the synthesis of nucleic acids, particularly the formation of thymidine. This leads to defective DNA synthesis and increased apoptosis affecting hemopoietic cells (megaloblastic anemia). Thymidine

https://t.me/USMLEWorldStep1

biochemical functions of folate require the reduced **tetrahydrofolate** form of the vitamin, which is synthesized by dihydrofolate reductase (a rate-limiting step in folate metabolism).

The enzyme **thymidylate synthase** is responsible for converting deoxyuridine monophosphate (dUMP) to deoxythymidine monophosphate (dTMP). Although most enzymes involved in one-carbon metabolism maintain folate in its active tetrahydrofolate form, thymidylate synthase is unique in that it oxidizes 5,10-methylenetetrahydrofolate to dihydrofolate. This makes **de novo thymidine synthesis** particularly susceptible to folate-deficient conditions because tetrahydrofolate must be continuously regenerated by dihydrofolate reductase.

In this experiment, inhibition of thymidylate synthase due to **deficient folate** increases the ratio of dUMP to dTMP, causing the incorporation of **uracil into DNA** in place of thymidine. This leads to excessive activation of DNA repair mechanisms, resulting in double-stranded DNA breaks and apoptosis. **Thymidine** supplementation reduces the metabolic folate demand, **preventing apoptosis** in folate-deficient cells.

(Choice A) Cobalamin is a necessary cofactor for methionine synthase, the enzyme that transfers a methyl group from 5-methyltetrahydrofolate to homocysteine, forming methionine and regenerating tetrahydrofolate. Cobalamin deficiency can cause folate to become trapped in 5-methyltetrahydrofolate form, resulting in secondary folate deficiency.

(Choice B) Cytosine is a pyrimidine base. Unlike thymine, it is not dependent on folate and can be synthesized in sufficient quantities under folate-deficient conditions.

(Choice C) Glutamine is a major source of nitrogen in the synthesis of purine and pyrimidine bases. However, glutamine supplementation would not ameliorate the cellular apoptosis induced by folate deficiency.

(Choice D) Homocysteine is an amino acid associated with endothelial cell injury and vascular inflammation. Levels are elevated in folate deficiency due to impaired conversion into methionine.

Educational objective:
Folate deficiency inhibits the synthesis of nucleic acids, particularly the formation of thymidine. This leads to defective DNA synthesis and increased apoptosis affecting hemopoietic cells (megaloblastic anemia). Thymidine supplementation bypasses the enzyme thymidylate synthase and can reduce erythroid cell apoptosis.

Biochemistry Gastrointestinal & Nutrition Folic acid deficiency

https://t.me/USMLEWorldStep1

dUMP

5,10-methylene THF

(RNA & DNA synthesis)

Exhibit Display

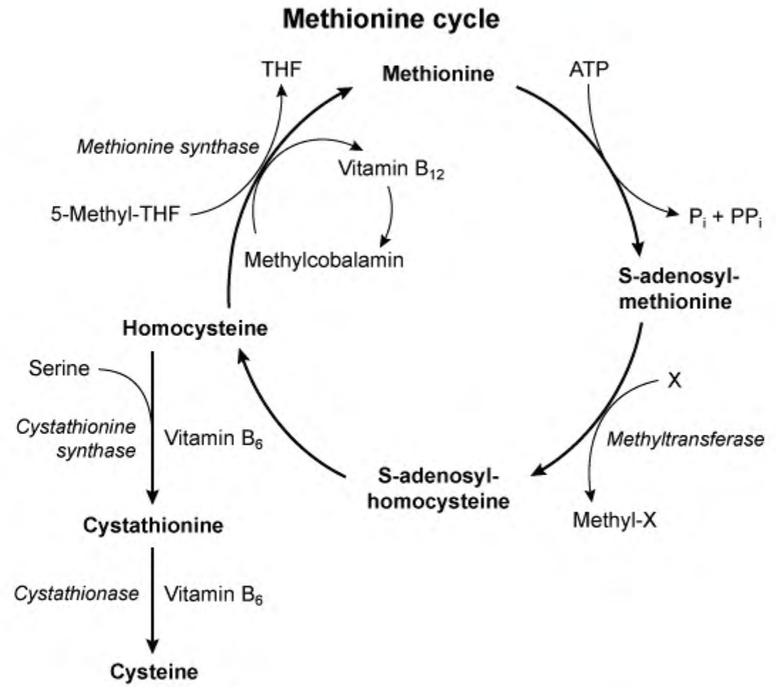

Zoom In | Zoom Out | Reset | New | Existing | My Notebook

Folate
methic
bioche
dihydr

The er
deoxy
folate
methy
folate-

In this
causin
repair
the me

(Choi
from 5
deficie
deficie

(Choi
sufficie

(Choi
glutamine supplementation would not ameliorate the cellular apoptosis induced by folate deficiency.

https://t.me/USMLEWorldStep1

A 23-year-old woman comes to the emergency department due to right wrist pain after a fall. The patient fell on her outstretched hand while walking across the floor at a gym where she exercises regularly. She has no significant medical history and takes no medications. The patient says she avoids eating high-fat or high-carbohydrate foods because she wants to avoid "getting bloated" and "gaining fat." Her last menstrual period was 7 months ago. She does not use tobacco, alcohol, or recreational drugs. Temperature is 35.9 C (96.6 F), blood pressure is 90/58 mm Hg, and pulse is 48/min. BMI is 18 kg/m^2. Tenderness and swelling are present over the right distal radius. The parotid glands are enlarged and there are fine, soft hairs on her extremities. Urine pregnancy test is negative. X-ray reveals a nondisplaced fracture of the right distal radius and generalized radiolucency of the bone. Which of the following is the most likely underlying diagnosis?

- A. Anorexia nervosa
- B. Avoidant/restrictive food intake disorder
- C. Bulimia nervosa
- D. Celiac disease
- E. Hyperthyroidism

Submit

https://t.me/USMLEWorldStep1

A 23-year-old woman comes to the emergency department due to right wrist pain after a fall. The patient fell on her outstretched hand while walking across the floor at a gym where she exercises regularly. She has no significant medical history and takes no medications. The patient says she avoids eating high-fat or high-carbohydrate foods because she wants to avoid "getting bloated" and "gaining fat." Her last menstrual period was 7 months ago. She does not use tobacco, alcohol, or recreational drugs. Temperature is 35.9 C (96.6 F), blood pressure is 90/58 mm Hg, and pulse is 48/min. BMI is 18 kg/m^2. Tenderness and swelling are present over the right distal radius. The parotid glands are enlarged and there are fine, soft hairs on her extremities. Urine pregnancy test is negative. X-ray reveals a nondisplaced fracture of the right distal radius and generalized radiolucency of the bone. Which of the following is the most likely underlying diagnosis?

- ✓ A. Anorexia nervosa (65%)
- ✗ B. Avoidant/restrictive food intake disorder (13%)
- C. Bulimia nervosa (16%)
- D. Celiac disease (3%)
- E. Hyperthyroidism (2%)

Incorrect
Correct answer
A

65%
Answered correctly

03 secs
Time Spent

2023
Version

Explanation

Anorexia nervosa	
Epidemiology	• Increased risk in white individuals, industrialized countries, athletes, models • Median onset at age 18 • 10:1 female/male ratio

https://t.me/USMLEWorldStep1

Anorexia nervosa	
Epidemiology	• Increased risk in white individuals, industrialized countries, athletes, models • Median onset at age 18 • 10:1 female/male ratio
DSM-5 diagnostic criteria	• Restricted energy intake with significantly **low body weight** (BMI generally <18.5 kg/m^2) • Intense **fear of becoming fat** or persistent avoidance of weight gain • **Distorted body image**, excessive influence of weight on self-worth, or persistent denial of complications related to low body weight
Medical complications	• Osteoporosis • Amenorrhea • Lanugo or hair loss • Parotid hypertrophy (if binge/purge behavior) • Hypotension, hypothermia, bradycardia • Cardiac atrophy, arrhythmias

This patient has a restricted diet, thin body habitus, and amenorrhea (last menstrual cycle 7 months ago); these features suggest **functional hypothalamic amenorrhea** (FHA), characterized by a low-estrogen state due to suppression of GnRH by chronic energy deficits. Hypoestrogenism in FHA increases the risk for **osteoporosis**, suggested by this patient's low-trauma fragility fracture (eg, fall from standing height).

FHA is a potential manifestation of **anorexia nervosa** (AN), an eating disorder that should be suspected in patients with the following:

- **Low BMI** (<18.5 kg/m^2)
- **Restrictive eating** patterns or **purging** behaviors (eg, self-induced vomiting leading to parotid hypertrophy)
- Physiologic changes arising from chronic caloric deficits and associated **clinical starvation** (eg, bradycardia, osteoporosis, lanugo [ie, fine, downy body hair])

https://t.me/USMLEWorldStep1

This patient has a restricted diet, thin body habitus, and amenorrhea (last menstrual cycle 7 months ago); these features suggest **functional hypothalamic amenorrhea** (FHA), characterized by a low-estrogen state due to suppression of GnRH by chronic energy deficits. Hypoestrogenism in FHA increases the risk for **osteoporosis**, suggested by this patient's low-trauma fragility fracture (eg, fall from standing height).

FHA is a potential manifestation of **anorexia nervosa** (AN), an eating disorder that should be suspected in patients with the following:

- **Low BMI** (<18.5 kg/m^2)
- **Restrictive eating** patterns or **purging** behaviors (eg, self-induced vomiting leading to parotid hypertrophy)
- Physiologic changes arising from chronic caloric deficits and associated **clinical starvation** (eg, bradycardia, osteoporosis, lanugo [ie, fine, downy body hair])
- **Distorted body image** and abnormal fear of gaining weight

Like AN, bulimia nervosa is characterized by abnormal fear of gaining weight; however, the predominant behavior pattern includes cycles of binge eating with purging (eg, vomiting, laxative abuse), and BMI is generally normal or near-normal. Electrolyte disorders are common, but manifestations of clinical starvation, seen in this patient (eg, FHA, lanugo, osteoporosis), are inconsistent with bulimia nervosa **(Choice C)**.

(Choice B) Avoidant/restrictive food intake disorder is characterized by inadequate food intake due to lack of interest in eating (eg, dislike of sensory experience of eating). Patients may have low BMI and signs of nutritional deficiency, but fear of gaining fat and distorted body image are not seen.

(Choices D and E) Celiac disease and hyperthyroidism can cause weight loss and osteoporosis. However, the patient's fear of gaining fat suggests an alternate diagnosis; moreover, parotid gland swelling, bradycardia, and hypothermia are not expected in either of these conditions.

Educational objective:
Anorexia nervosa is characterized by low body weight (BMI<18.5 kg/m^2), fear of becoming fat, and distorted body image. Unlike other patterns of restrictive eating (eg, bulimia nervosa), patients with anorexia nervosa experience complications of progressive clinical starvation, such as bradycardia, osteoporosis, and amenorrhea.

https://t.me/USMLEWorldStep1

suggested by this patient's low-trauma fragility fracture (eg, fall from standing height).

FHA is a potential manifestation of **anorexia nervosa** (AN), an eating disorder that should be suspected in patients with the following:

- **Low BMI** (<18.5 kg/m^2)
- **Restrictive eating** patterns or **purging** behaviors (eg, self-induced vomiting leading to parotid hypertrophy)
- Physiologic changes arising from chronic caloric deficits and associated **clinical starvation** (eg, bradycardia, osteoporosis, lanugo [ie, fine, downy body hair])
- **Distorted body image** and abnormal fear of gaining weight

Like AN, bulimia nervosa is characterized by abnormal fear of gaining weight; however, the predominant behavior pattern includes cycles of binge eating with purging (eg, vomiting, laxative abuse), and BMI is generally normal or near-normal. Electrolyte disorders are common, but manifestations of clinical starvation, seen in this patient (eg, FHA, lanugo, osteoporosis), are inconsistent with bulimia nervosa **(Choice C)**.

(Choice B) Avoidant/restrictive food intake disorder is characterized by inadequate food intake due to lack of interest in eating (eg, dislike of sensory experience of eating). Patients may have low BMI and signs of nutritional deficiency, but fear of gaining fat and distorted body image are not seen.

(Choices D and E) Celiac disease and hyperthyroidism can cause weight loss and osteoporosis. However, the patient's fear of gaining fat suggests an alternate diagnosis; moreover, parotid gland swelling, bradycardia, and hypothermia are not expected in either of these conditions.

Educational objective:
Anorexia nervosa is characterized by low body weight (BMI<18.5 kg/m^2), fear of becoming fat, and distorted body image. Unlike other patterns of restrictive eating (eg, bulimia nervosa), patients with anorexia nervosa experience complications of progressive clinical starvation, such as bradycardia, osteoporosis, and amenorrhea.

References

- Bone health in anorexia nervosa.

https://t.me/USMLEWorldStep1

This patient has a restricted diet, thin body habitus, and amenorrhea (last menstrual cycle 7 months ago); these
featur
suppr
sugge

FHA is
with th

- **L**
- **R**
- P
  o
- **D**

Like A
patter
near-n
FHA, l

(Choi
interes
deficie

(Choi
patien
hypoth

Educa
Anore
image. Unlike other patterns of restrictive eating (eg, bulimia nervosa), patients with anorexia nervosa experience
complications of progressive clinical starvation, such as bradycardia, osteoporosis, and amenorrhea

Exhibit Display

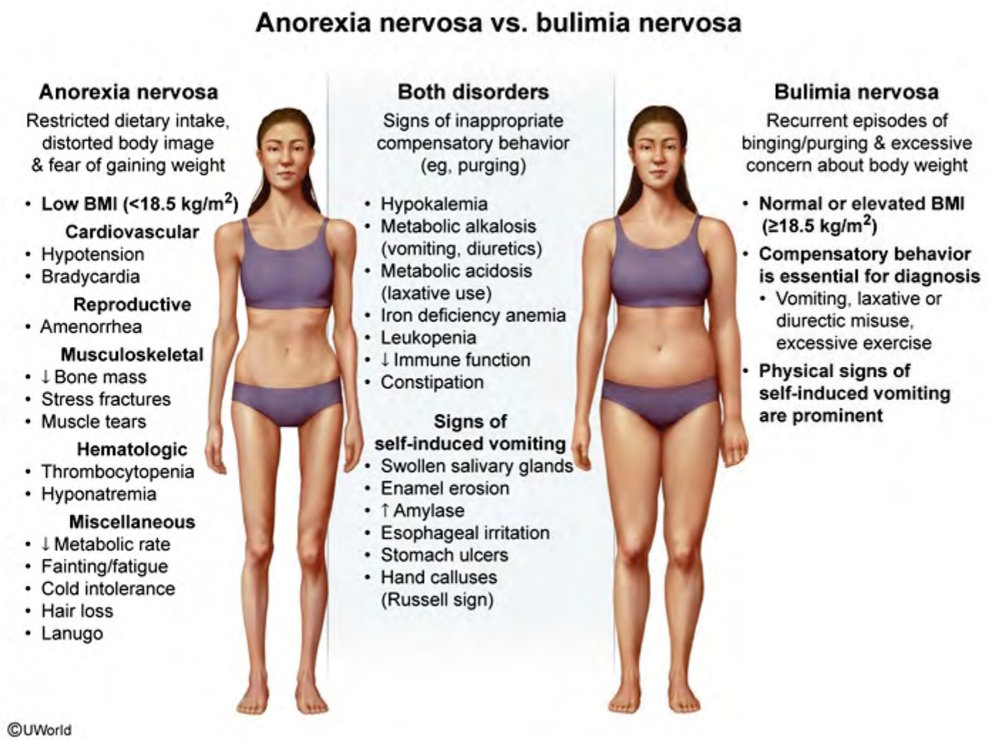

Zoom In | Zoom Out | Reset | New | Existing | My Notebook

https://t.me/USMLEWorldStep1

A 62-year-old man comes to the physician due to intermittent groin pain. The pain is most severe when the patient lifts heavy loads and after a long day at his job as a construction worker. Physical examination shows a right-sided groin bulge directly above the inguinal ligament. The bulge increases in size when he bears down. An ultrasound reveals that the mass originates medial to the inferior epigastric vessels. This patient's condition is most likely caused by which of the following?

- A. Failure of the internal inguinal ring to close
- B. Patent processus vaginalis
- C. Separation of the abdominal muscles
- D. Weakness of the transversalis fascia
- E. Widening of the femoral ring

Submit

https://t.me/USMLEWorldStep1

A 62-year-old man comes to the physician due to intermittent groin pain. The pain is most severe when the patient lifts heavy loads and after a long day at his job as a construction worker. Physical examination shows a right-sided groin bulge directly above the inguinal ligament. The bulge increases in size when he bears down. An ultrasound reveals that the mass originates medial to the inferior epigastric vessels. This patient's condition is most likely caused by which of the following?

- ✗ A. Failure of the internal inguinal ring to close (3%)
- B. Patent processus vaginalis (5%)
- C. Separation of the abdominal muscles (5%)
- ✓ D. Weakness of the transversalis fascia (83%)
- E. Widening of the femoral ring (1%)

Incorrect
Correct answer
D

83%
Answered correctly

04 secs
Time Spent

2023
Version

Explanation

Groin hernias			
Type	**Classic presentation**	**Pathophysiology**	**Anatomy**
Indirect inguinal	Male infants	Patent processus vaginalis	• Originates lateral to inferior epigastric vessels • Protrudes through the deep inguinal ring into inguinal canal • May extend into the scrotum (following

https://t.me/USMLEWorldStep1

Explanation

Groin hernias			
Type	**Classic presentation**	**Pathophysiology**	**Anatomy**
Indirect inguinal	Male infants	Patent processus vaginalis	• Originates lateral to inferior epigastric vessels • Protrudes through the deep inguinal ring into inguinal canal • May extend into the scrotum (following spermatic cord)
Direct inguinal	Older men	Weakness of transversalis fascia	• Protrudes medial to the inferior epigastric vessels into Hesselbach's triangle • May pass through superficial inguinal ring • No direct route into the scrotum
Femoral	Women	Widening of the femoral ring	• Emerges inferior to inguinal ligament • Protrudes through the femoral ring into the femoral canal

Direct and indirect inguinal hernias are both located **above the inguinal ligament**. They can be differentiated by their side of origination in relation to the inferior epigastric vessels. Direct inguinal hernias originate medial to the inferior epigastric vessels, while indirect inguinal hernias originate lateral to the inferior epigastric vessels.

This patient's groin mass originating **medial** to the inferior epigastric vessels is characteristic of a **direct inguinal hernia** in the Hesselbach triangle. The transversalis fascia makes up the floor of the triangle, and **defects or weakness** involving the **transversalis fascia** can lead to protrusion of abdominal contents. Failure of this fascial layer is most often due to acquired connective tissue abnormalities or chronic abdominal wall injury (most

https://t.me/USMLEWorldStep1

Direct and indirect inguinal hernias are both located **above the inguinal ligament**. They can be differentiated by their side of origination in relation to the inferior epigastric vessels. Direct inguinal hernias originate medial to the inferior epigastric vessels, while indirect inguinal hernias originate lateral to the inferior epigastric vessels.

This patient's groin mass originating **medial** to the inferior epigastric vessels is characteristic of a **direct inguinal hernia** in the Hesselbach triangle. The transversalis fascia makes up the floor of the triangle, and **defects or weakness** involving the **transversalis fascia** can lead to protrusion of abdominal contents. Failure of this fascial layer is most often due to acquired connective tissue abnormalities or chronic abdominal wall injury (most commonly in older men).

Unlike indirect inguinal hernias, direct inguinal hernias do not pass through the internal (deep) inguinal ring but only through the external (superficial) inguinal ring. As a result, they do not have a direct route to the scrotum.

(Choices A and B) Indirect inguinal hernias are the most common type of groin hernia in both sexes. The underlying etiology is usually congenital; due to failure of the processus vaginalis to obliterate (in males) or of the deep inguinal ring to close (in females). Indirect inguinal hernias protrude through the internal inguinal ring, lateral to the inferior epigastric vessels, allowing them to follow the same path as the spermatic cord though the inguinal canal and into the scrotum.

(Choice C) Diastasis rectus abdominus is characterized by an abnormally large separation between the rectus abdominus muscles due to stretching and laxity of the linea alba. This usually occurs in states with increased intraabdominal pressure (eg, pregnancy, obesity) and characteristically presents with a bulge in the midline around the umbilicus (rather than in the groin directly above the inguinal ligament).

(Choice E) Femoral hernias occur mainly in older women due to laxity and widening of the femoral ring, which allows abdominal contents to protrude below the inguinal ligament into the femoral canal.

Educational objective:
Direct inguinal hernias occur most commonly in older men due to weakness of the transversalis fascia. They protrude medial to the inferior epigastric vessels into the Hesselbach triangle and pass only through the superficial inguinal ring with no direct route to the scrotum.

https://t.me/USMLEWorldStep1

Direct and indirect inguinal hernias are both located **above the inguinal ligament**. They can be differentiated by their s
inferio

This p
hernia
weakn
layer i
comm

Unlike
throug

(Choi
underl
deep i
to the
canal

(Choi
abdom
intraab
the um

(Choi
allows

Educa
Direct
protru
inguinal ring with no direct route to the scrotum.

Exhibit Display

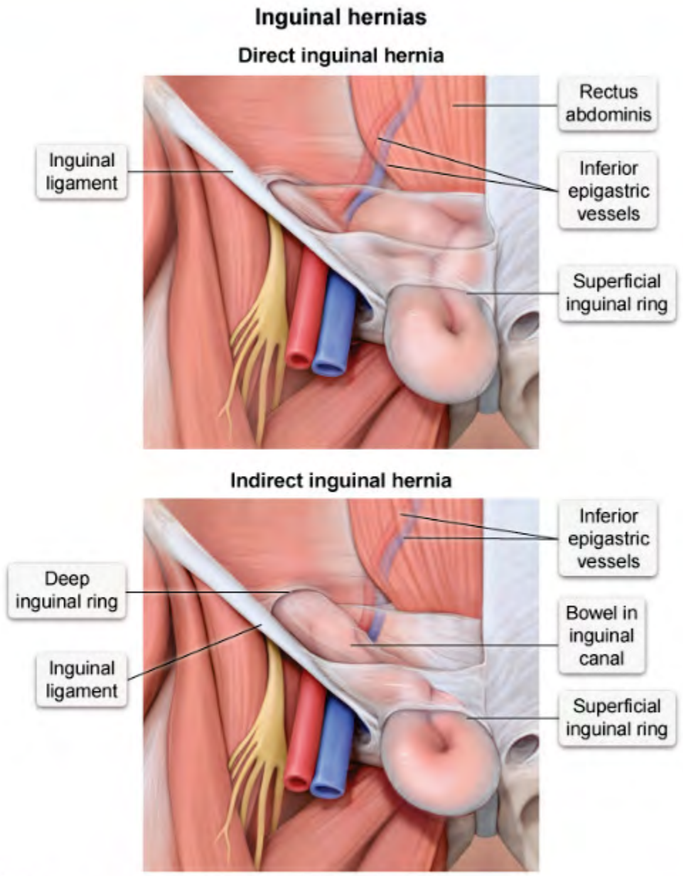

Zoom In Zoom Out Reset New | Existing My Notebook

https://t.me/USMLEWorldStep1

Direct and indirect inguinal hernias are both located **above the inguinal ligament**. They can be differentiated by their s
inferio

This p
hernia
weakn
layer i
comm

Unlike
throug

(Choi
underl
deep i
to the
canal

(Choi
abdom
intraab
the um

(Choi
allows

Educa
Direct
protru
inguinal ring with no direct route to the scrotum.

Exhibit Display

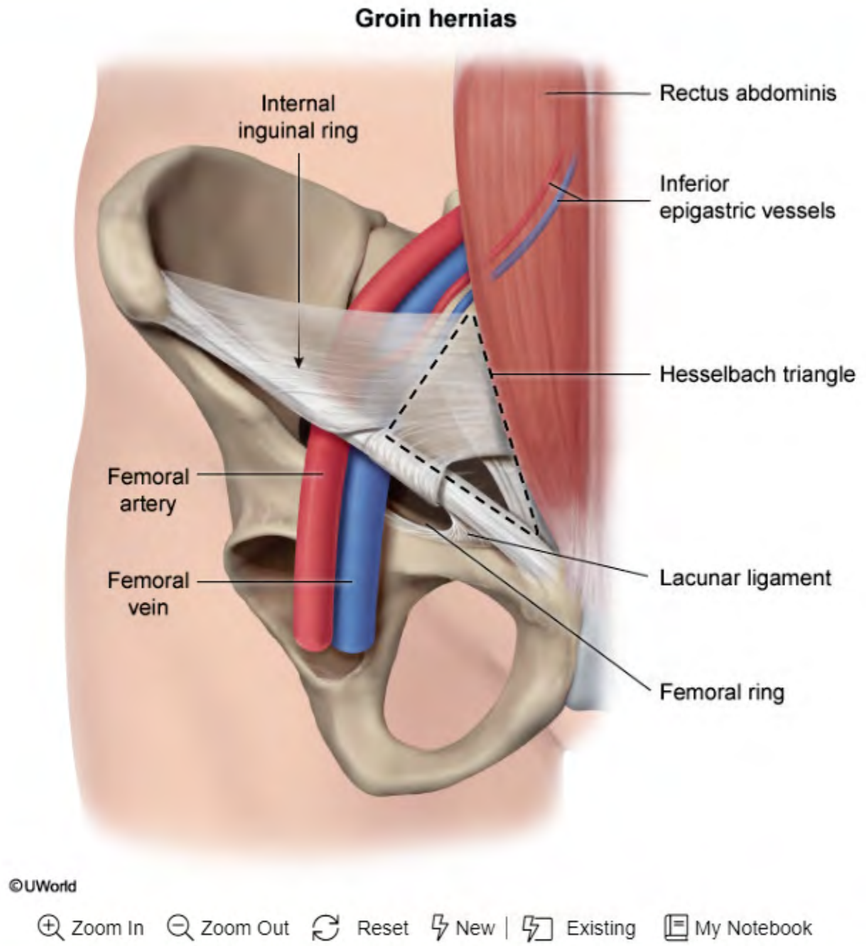

Zoom In | Zoom Out | Reset | New | Existing | My Notebook

https://t.me/USMLEWorldStep1

Direct and indirect inguinal hernias are both located **above the inguinal ligament**. They can be differentiated by their s
inferio

This p
hernia
weakn
layer i
comm

Unlike
throug

(Choi
underl
deep i
to the
canal

(Choi
abdom
intraab
the um

(Choi
allows

Educa
Direct
protru
inguinal ring with no direct route to the scrotum.

Exhibit Display

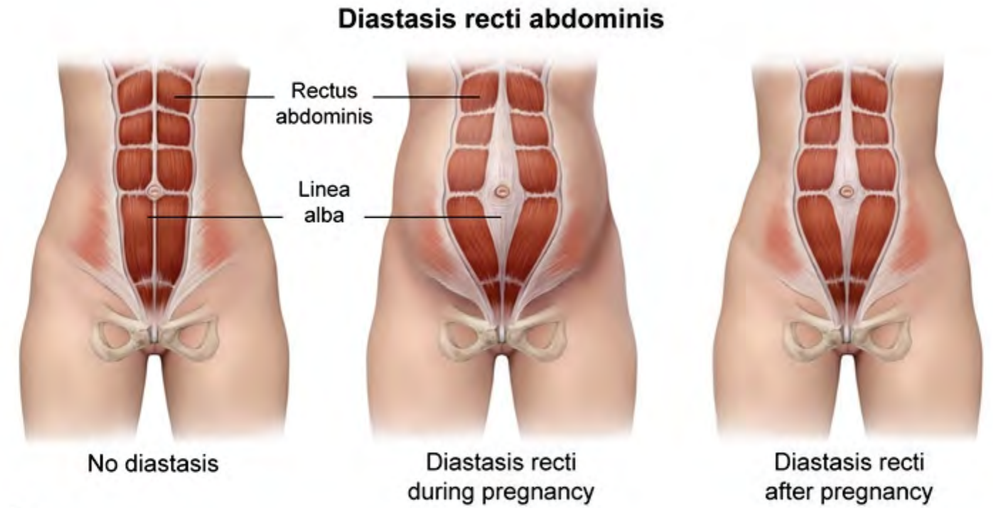

Zoom In Zoom Out Reset New | Existing My Notebook

https://t.me/USMLEWorldStep1

Direct and indirect inguinal hernias are both located **above the inguinal ligament**. They can be differentiated by their s
inferio

This p
hernia
weakn
layer i
comm

Unlike
throug

(Choi
underl
deep i
to the
canal

(Choi
abdom
intraab
the um

(Choi
allows

Educa
Direct
protru
inguinal ring with no direct route to the scrotum.

Exhibit Display

Femoral hernia

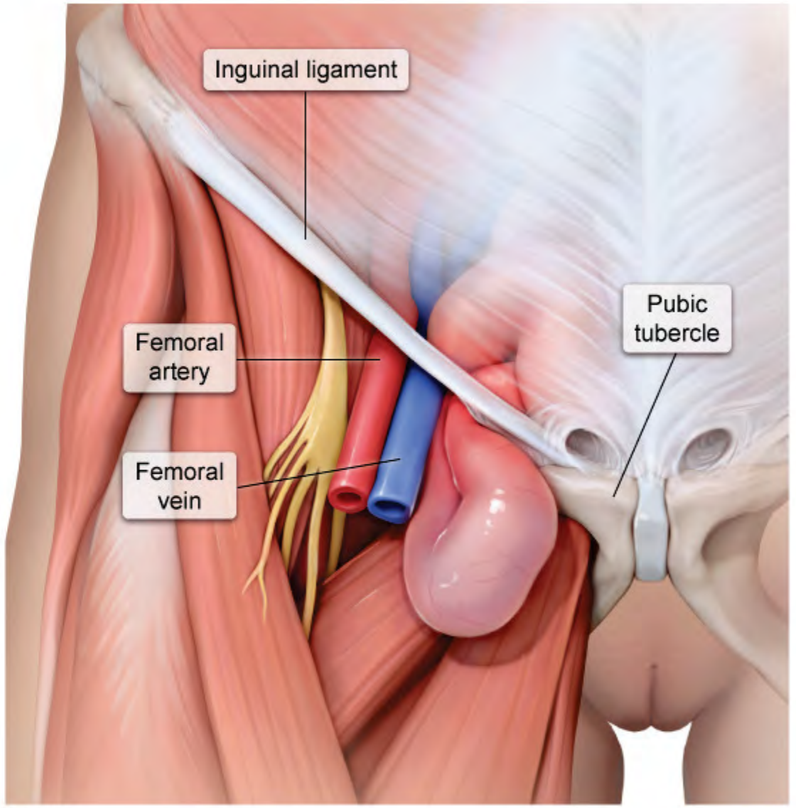

©UWorld

Zoom In | Zoom Out | Reset | New | Existing | My Notebook

https://t.me/USMLEWorldStep1

A 39-year-old woman is brought to the emergency department after an end-to-end motor vehicle collision. She was a restrained passenger and did not hit her head or lose consciousness. She has had abdominal pain and nausea since the collision. Blood pressure is 115/55 mm Hg and pulse is 96/min and regular. On examination, she has ecchymosis over the area of the seat belt and abdominal tenderness. CT scan of the abdomen reveals a retroperitoneal hematoma. Which of the following injuries is most likely to be responsible for this patient's internal bleeding?

- A. Contusion of the body of the pancreas
- B. Laceration of the inferior border of the spleen
- C. Laceration of the right hepatic lobe
- D. Tear at the lesser curvature of the stomach
- E. Tear at the proximal transverse colon

Submit

https://t.me/USMLEWorldStep1

A 39-year-old woman is brought to the emergency department after an end-to-end motor vehicle collision. She was a restrained passenger and did not hit her head or lose consciousness. She has had abdominal pain and nausea since the collision. Blood pressure is 115/55 mm Hg and pulse is 96/min and regular. On examination, she has ecchymosis over the area of the seat belt and abdominal tenderness. CT scan of the abdomen reveals a retroperitoneal hematoma. Which of the following injuries is most likely to be responsible for this patient's internal bleeding?

- ✓ A. Contusion of the body of the pancreas (46%)
- ✗ B. Laceration of the inferior border of the spleen (41%)
- C. Laceration of the right hepatic lobe (3%)
- D. Tear at the lesser curvature of the stomach (2%)
- E. Tear at the proximal transverse colon (5%)

Incorrect
Correct answer
A

46%
Answered correctly

03 secs
Time Spent

2023
Version

Explanation

https://t.me/USMLEWorldStep1

A 39-year-old woman is brought to the emergency department after an end-to-end motor vehicle collision. She was a
nause
has ec
retrope
bleedi

Inco
Corre
A

Expl

Exhibit Display

Retroperitoneal abdominal organs

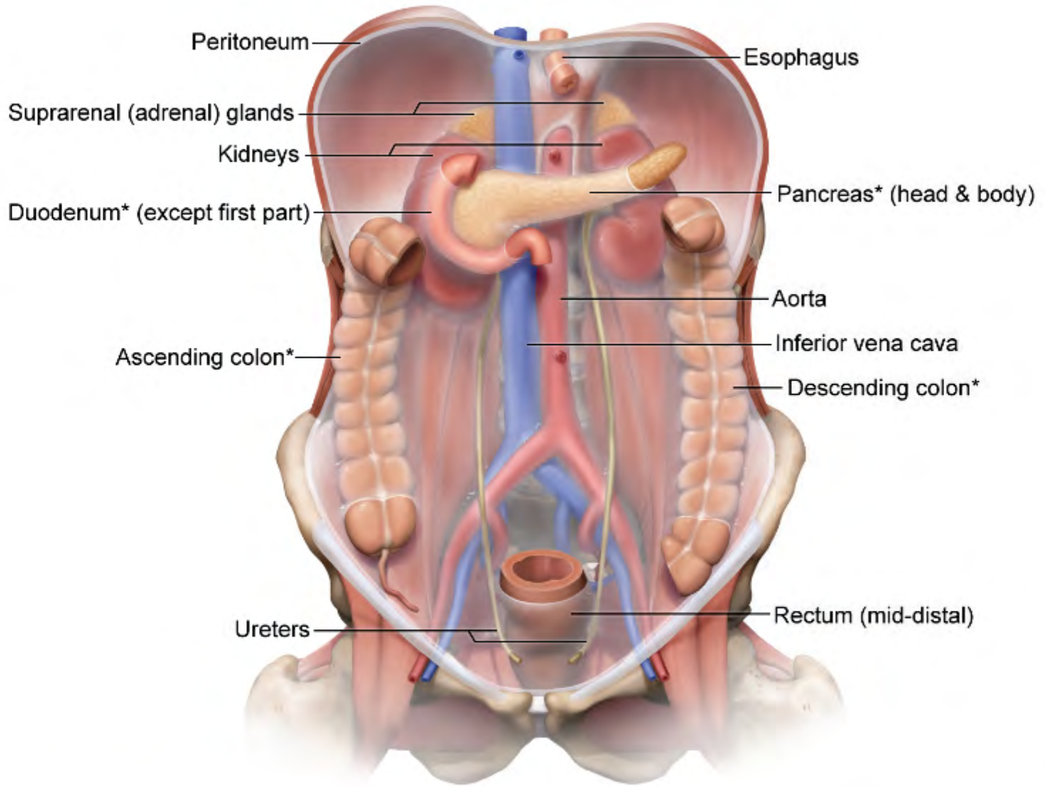

*Secondarily retroperitoneal (developed intraperitoneal & migrated retroperitoneal).

©UWorld

Zoom In | Zoom Out | Reset | New | Existing | My Notebook

Aorta

https://t.me/USMLEWorldStep1

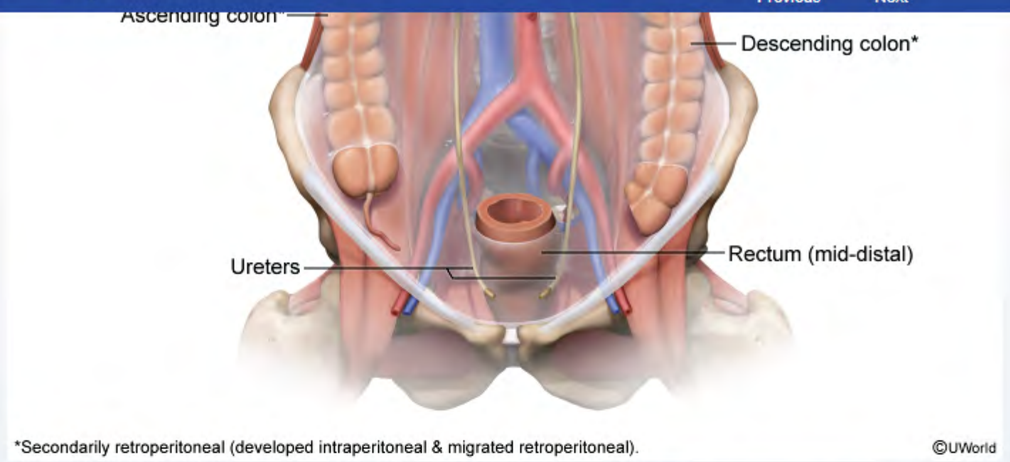

*Secondarily retroperitoneal (developed intraperitoneal & migrated retroperitoneal). ©UWorld

Retroperitoneal hematomas are commonly associated with **blunt abdominal trauma** and typically reflect injury to one of the retroperitoneal organs. **Pancreatic injury** is a frequent cause, and may result from blunt abdominal trauma that rapidly compresses the pancreas against the vertebral column, as may occur from a high-riding seat belt or a steering wheel during a motor vehicle collision.

Pancreatic injury with retroperitoneal hematoma may initially cause only mild symptoms or be asymptomatic, but it can lead to life-threatening blood loss. Therefore, an abdominal CT scan is usually performed in patients with blunt abdominal trauma to rule out retroperitoneal hematoma as well as other intraabdominal injuries.

(Choices B, C, D, and E) The spleen, liver, stomach, and transverse colon are intraperitoneal organs. Lacerations or rupture of these organs can occur in blunt abdominal trauma, but these injuries would lead to hemoperitoneum (free blood in the peritoneal space), not retroperitoneal hematoma.

Educational objective:
Retroperitoneal hematoma is a common complication of blunt abdominal trauma. The pancreas is a retroperitoneal organ, and pancreatic injury is frequently a source of retroperitoneal bleeding.

Anatomy	Gastrointestinal & Nutrition	Retroperitoneal hematoma
Subject	System	Topic

Copyright © UWorld. All rights reserved.

https://t.me/USMLEWorldStep1

Exhibit Display

Retroperitoneal abdominal organs
• **S**uprarenal (adrenal) glands • **A**orta & inferior vena cava • **D**uodenum* (except 1st part) • **P**ancreas* (head & body) • **U**reters • **C**olon* (ascending & descending) • **K**idneys • **E**sophagus • **R**ectum (mid-distal) Mnemonic: **SAD PUCKER**
*Secondarily retroperitoneal (developed intraperitoneal & migrated retroperitoneal).

New | Existing | My Notebook

Retrop
to one
trauma
belt or

Pancre
can le
abdom

(Choi
Lacera
hemop

Educa
Retrop
retrope

Anatom
Subject

Copyright © UWorld. All rights reserved.

https://t.me/USMLEWorldStep1

A 39-year-old man comes to the clinic with a month-long history of fever, fatigue, joint pain, and an urticarial skin rash. He did not seek attention immediately as he hoped his symptoms would resolve. The patient is generally improving but is still very easily fatigued. Past medical history is unremarkable and the patient takes no regular medications, although he has not seen a physician since early childhood. He is not married and has a history of multiple heterosexual partners. The patient recently stopped smoking, drinks alcohol socially and does not use illicit drugs. Physical examination is notable for a moderately enlarged and tender liver. No jaundice is seen. Laboratory studies show significant elevations in serum alanine aminotransferase (ALT) and aspartate aminotransferase (AST). Which of the following is the most likely diagnosis in this patient?

- A. Acute hepatitis B
- B. Acute hepatitis C
- C. Gilbert syndrome
- D. Hemochromatosis
- E. Hepatic steatosis
- F. Wilson disease

Submit

https://t.me/USMLEWorldStep1

A 39-year-old man comes to the clinic with a month-long history of fever, fatigue, joint pain, and an urticarial skin rash. He did not seek attention immediately as he hoped his symptoms would resolve. The patient is generally improving but is still very easily fatigued. Past medical history is unremarkable and the patient takes no regular medications, although he has not seen a physician since early childhood. He is not married and has a history of multiple heterosexual partners. The patient recently stopped smoking, drinks alcohol socially and does not use illicit drugs. Physical examination is notable for a moderately enlarged and tender liver. No jaundice is seen. Laboratory studies show significant elevations in serum alanine aminotransferase (ALT) and aspartate aminotransferase (AST). Which of the following is the most likely diagnosis in this patient?

- ✓ A. Acute hepatitis B (70%)
- B. Acute hepatitis C (13%)
- C. Gilbert syndrome (2%)
- D. Hemochromatosis (7%)
- E. Hepatic steatosis (4%)
- F. Wilson disease (2%)

Correct

70%
Answered correctly

03 secs
Time Spent

2023
Version

Explanation

This patient has features of **acute hepatitis B** (HBV), including systemic, skin, and joint symptoms; hepatomegaly; and elevated transaminase levels. Hepatitis B is a DNA virus with an incubation period of 30-180 days. Transmission can occur sexually, parenterally, or vertically. Onset is dominated by nonspecific symptoms, although patients may develop a **serum sickness-like** syndrome with joint pain, lymphadenopathy, and a pruritic urticarial vasculitis rash. Right upper quadrant pain can also be present.

https://t.me/USMLEWorldStep1

This patient has features of **acute hepatitis B** (HBV), including systemic, skin, and joint symptoms; hepatomegaly; and elevated transaminase levels. Hepatitis B is a DNA virus with an incubation period of 30-180 days. Transmission can occur sexually, parenterally, or vertically. Onset is dominated by nonspecific symptoms, although patients may develop a **serum sickness-like** syndrome with joint pain, lymphadenopathy, and a pruritic urticarial vasculitis rash. Right upper quadrant pain can also be present.

Acute HBV is characterized by significant elevations in **aspartate aminotransferase and alanine aminotransferase**, often >10 times the upper limit of normal. Most patients will have nonicteric hepatitis, but icteric hepatitis with jaundice and elevated bilirubin is also common. Impaired hepatic synthetic function, as indicated by a prolonged prothrombin time, confers a poor prognosis. The most important early marker of acute infection is **hepatitis B surface antigen** (HBsAg), which may be detectable prior to symptoms or changes in transaminase levels. IgM anti-hepatitis B core (anti-HBc) may also be positive. **Hepatitis B e antigen** (HBeAg) and HBV DNA counts correlate with **infectivity**.

(Choice B) Acute hepatitis C is typically asymptomatic; dermatologic manifestations (eg, cryoglobulinemia) are seen in chronic infection. This patient is unlikely to have hepatitis C as he does not use intravenous drugs and sexual transmission is rare.

(Choice C) Gilbert syndrome is a common disorder characterized by mild unconjugated hyperbilirubinemia. Patients are almost always asymptomatic.

(Choice D) Hemochromatosis is due to abnormal iron absorption resulting in iron overload. Chronic manifestations include cirrhosis, hyperpigmentation, and diabetes mellitus ("bronze diabetes").

(Choice E) Hepatic steatosis is characterized by excessive deposition of lipids in the liver and is usually caused by chronic alcohol abuse or obesity (and insulin resistance). Steatosis may lead to cirrhosis, but it does not cause acute symptoms.

(Choice F) Wilson disease presents with acute or chronic hepatitis in patients age <30. Neurologic manifestations (eg, cognitive or motor deficits) are frequent. Kayser-Fleischer rings (green or golden corneal deposits) are a common incidental finding.

Educational objective:

https://t.me/USMLEWorldStep1

aminotransferase, often >10 times the upper limit of normal. Most patients will have nonicteric hepatitis, but icteric hepatitis with jaundice and elevated bilirubin is also common. Impaired hepatic synthetic function, as indicated by a prolonged prothrombin time, confers a poor prognosis. The most important early marker of acute infection is **hepatitis B surface antigen** (HBsAg), which may be detectable prior to symptoms or changes in transaminase levels. IgM anti-hepatitis B core (anti-HBc) may also be positive. **Hepatitis B e antigen** (HBeAg) and HBV DNA counts correlate with **infectivity**.

(Choice B) Acute hepatitis C is typically asymptomatic; dermatologic manifestations (eg, cryoglobulinemia) are seen in chronic infection. This patient is unlikely to have hepatitis C as he does not use intravenous drugs and sexual transmission is rare.

(Choice C) Gilbert syndrome is a common disorder characterized by mild unconjugated hyperbilirubinemia. Patients are almost always asymptomatic.

(Choice D) Hemochromatosis is due to abnormal iron absorption resulting in iron overload. Chronic manifestations include cirrhosis, hyperpigmentation, and diabetes mellitus ("bronze diabetes").

(Choice E) Hepatic steatosis is characterized by excessive deposition of lipids in the liver and is usually caused by chronic alcohol abuse or obesity (and insulin resistance). Steatosis may lead to cirrhosis, but it does not cause acute symptoms.

(Choice F) Wilson disease presents with acute or chronic hepatitis in patients age <30. Neurologic manifestations (eg, cognitive or motor deficits) are frequent. Kayser-Fleischer rings (green or golden corneal deposits) are a common incidental finding.

Educational objective:
Acute hepatitis B infection can cause a serum sickness-like syndrome with joint pain, lymphadenopathy, and a pruritic urticarial rash. Other features may include right upper quadrant pain, hepatomegaly, and elevated hepatic transaminase levels.

References

- Cutaneous manifestations of viral hepatitis.

Pathophysiology Gastrointestinal & Nutrition Hepatitis b

https://t.me/USMLEWorldStep1

Expl

Exhibit Display

Zoom In Zoom Out Reset New | Existing My Notebook

This p
and el
Transr
patien
vascul

Acute
aminc
icteric
indicat
infecti
transa
and HI

(Choi
seen i
sexual

(Choi
Patien

(Choi
manife

(Choi
by chr
acute

(Choice F) Wilson disease presents with acute or chronic hepatitis in patients age <30. Neurologic manifestations

https://t.me/USMLEWorldStep1

This patient has features of **acute hepatitis B** (HBV), including systemic, skin, and joint symptoms; hepatomegaly;
and el
Transr
patien
vascul

Acute
aminc
icteric
indicat
infecti
transa
and HI

(Choi
seen i
sexual

(Choi
Patien

(Choi
manife

(Choi
by chr
acute

(Choi
(eg, c
comm

Educational objective:

Exhibit Display

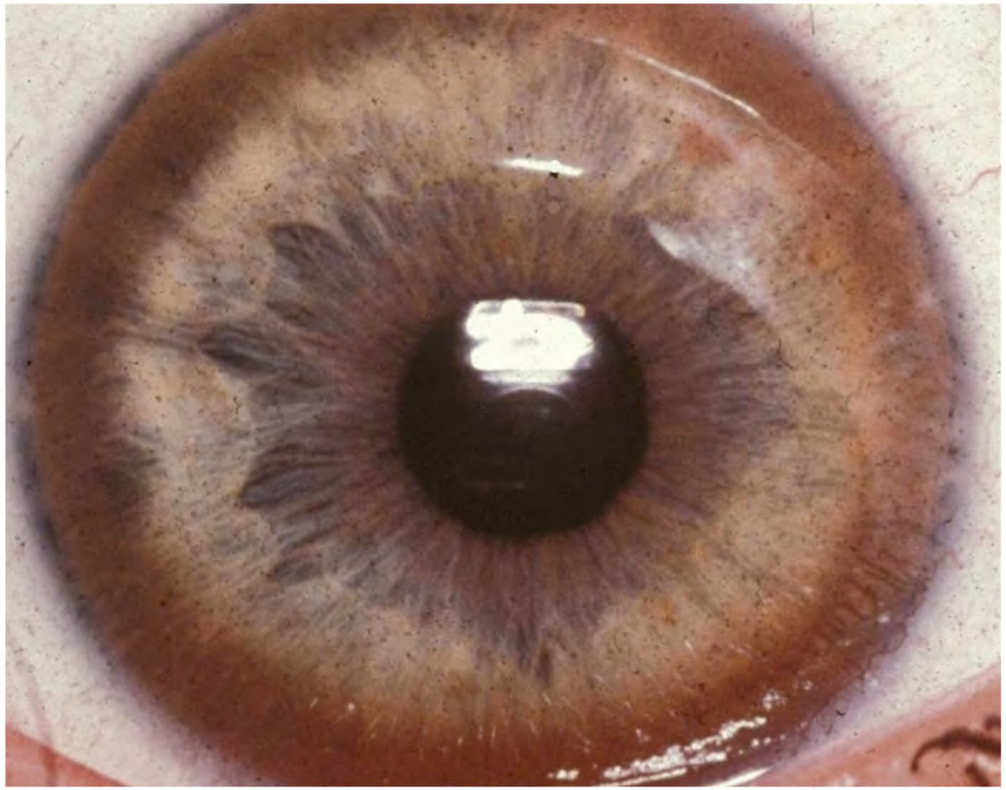

Zoom In | Zoom Out | Reset | New | Existing | My Notebook

https://t.me/USMLEWorldStep1

A 55-year-old man is evaluated for progressive fatigue, weakness, and unintentional weight loss. He has no other medical issues and takes no medications. Physical examination shows mucosal pallor. Stool testing for occult blood is positive, and a subsequent colonoscopy reveals a solitary mass in the ascending colon. Biopsy is consistent with colon adenocarcinoma, and surgical resection is planned. Which of the following features would carry the worst prognosis in this patient?

- A. High degree of tumor cell aneuploidy
- B. High number of mitotic figures
- C. Poor differentiation of tumor cells
- D. Presence of clinical symptoms
- E. Tumor penetration into the muscularis propria

Submit

https://t.me/USMLEWorldStep1

A 55-year-old man is evaluated for progressive fatigue, weakness, and unintentional weight loss. He has no other medical issues and takes no medications. Physical examination shows mucosal pallor. Stool testing for occult blood is positive, and a subsequent colonoscopy reveals a solitary mass in the ascending colon. Biopsy is consistent with colon adenocarcinoma, and surgical resection is planned. Which of the following features would carry the worst prognosis in this patient?

- A. High degree of tumor cell aneuploidy
- ✗ B. High number of mitotic figures
- C. Poor differentiation of tumor cells
- D. Presence of clinical symptoms
- ✓ E. Tumor penetration into the muscularis propria

Incorrect
Correct answer
E

Collecting Statistics

03 secs
Time Spent

2023
Version

Explanation

Comparison of tumor grading & staging

	Grading	Staging
Describes	• How closely neoplastic cells resemble normal, mature cells (ie, degree of differentiation)	• How far the tumor has spread
Assessed by	Histopathology	• Clinical examination (eg, lymphadenopathy) • Pathologic examination (eg, gross

https://t.me/USMLEWorldStep1

Explanation

Comparison of tumor grading & staging		
	Grading	**Staging**
Describes	• How closely neoplastic cells resemble normal, mature cells (ie, degree of differentiation)	• How far the tumor has spread
Assessed by	• Histopathology	• Clinical examination (eg, lymphadenopathy) • Pathologic examination (eg, gross inspection) • Radiologic & nuclear medicine studies (eg, PET/CT)
Criteria*	• Cellular differentiation • Architectural features • Mitotic count	• Tumor size • Noninvasive vs invasive • Spread to regional lymph nodes • Distant metastases
*The specific criteria used vary by tumor type.		

Tumor **stage** reflects the extent of tumor expansion and spread to other tissues. It is the **greatest prognostic predictor** of long-term survival in patients with **colorectal cancer** and is determined by the following features:

- **Depth of invasion** into the intestinal wall: Tumors that have not penetrated the muscularis mucosae have a very good long-term outcome and a very low risk of spread because the colorectal mucosa contains sparse lymphatics. In contrast, the risk of death rises significantly when the tumor invades the **muscularis propria**.
- **Lymph node involvement**: The prognosis worsens when tumor is identified within regional lymph nodes.

https://t.me/USMLEWorldStep1

		• Distant metastases
*The specific criteria used vary by tumor type.		

Tumor **stage** reflects the extent of tumor expansion and spread to other tissues. It is the **greatest prognostic predictor** of long-term survival in patients with **colorectal cancer** and is determined by the following features:

- **Depth of invasion** into the intestinal wall: Tumors that have not penetrated the muscularis mucosae have a very good long-term outcome and a very low risk of spread because the colorectal mucosa contains sparse lymphatics. In contrast, the risk of death rises significantly when the tumor invades the **muscularis propria**.
- **Lymph node involvement**: The prognosis worsens when tumor is identified within regional lymph nodes.
- **Distant metastases**: The presence of distant metastases (eg, liver) is generally associated with a very poor prognosis.

Tumor **grade** (ie, degree of differentiation of tumor cells) also affects prognosis but is a less important prognostic indicator than the stage of colorectal cancer. Low-grade tumors have well-differentiated cells that form glands. High-grade (ie, poorly differentiated) tumors form fewer well-defined glands and instead show sheets or cords of tumor cells, often with a high degree of aneuploidy, mitotic figures, and pleomorphism **(Choices A, B, and C)**.

(Choice D) Ascending (right-sided) tumors often cause unexplained iron deficiency anemia from tumor bleeding; descending (left-sided) tumors often grow in an annular fashion and result in bowel dysfunction (eg, constipation, diarrhea, obstruction). Although bowel perforation or obstruction may be associated with a slightly worse prognosis, the presence of clinical symptoms does not seem to be of major prognostic importance.

Educational objective:
The most important prognostic factor for patients with colorectal cancer is the tumor stage (ie, extent of tumor expansion and spread). Prognosis deteriorates when tumors penetrate the muscularis propria, spread to lymph nodes, and metastasize to distant sites.

Pathology	Gastrointestinal & Nutrition	Colorectal polyps and cancer
Subject	System	Topic

Copyright © UWorld. All rights reserved.

https://t.me/USMLEWorldStep1

A 45-year-old woman comes to the office due to colicky abdominal pain, diarrhea, and nausea 15-20 minutes after meals. These episodes are accompanied by light-headedness and diaphoresis. She feels normal between the episodes and at night. The patient underwent Roux-en-Y gastric bypass surgery 4 weeks ago for obesity. She is otherwise healthy, and her only medication is a daily multivitamin. On physical examination, the patient has a well-healed midline abdominal scar. Mild epigastric tenderness to palpation is present. The remainder of the examination is normal. Which of the following is the most likely cause of this patient's symptoms?

- A. Bacterial overgrowth in a surgically created blind loop
- B. Increased gastric fundal contractility from vagal nerve injury
- C. Postsurgical scarring and stenosis of the gastrojejunostomy site
- D. Rapid transition of hyperosmolar food into the small bowel
- E. Spasm of the pyloric sphincter

Submit

https://t.me/USMLEWorldStep1

A 45-year-old woman comes to the office due to colicky abdominal pain, diarrhea, and nausea 15-20 minutes after meals. These episodes are accompanied by light-headedness and diaphoresis. She feels normal between the episodes and at night. The patient underwent Roux-en-Y gastric bypass surgery 4 weeks ago for obesity. She is otherwise healthy, and her only medication is a daily multivitamin. On physical examination, the patient has a well-healed midline abdominal scar. Mild epigastric tenderness to palpation is present. The remainder of the examination is normal. Which of the following is the most likely cause of this patient's symptoms?

- ✗ A. Bacterial overgrowth in a surgically created blind loop (6%)
- B. Increased gastric fundal contractility from vagal nerve injury (14%)
- C. Postsurgical scarring and stenosis of the gastrojejunostomy site (8%)
- ✓ D. Rapid transition of hyperosmolar food into the small bowel (66%)
- E. Spasm of the pyloric sphincter (3%)

Incorrect
Correct answer
D

66%
Answered correctly

03 secs
Time Spent

2023
Version

Explanation

This patient's symptoms are consistent with **dumping syndrome**, a common complication of gastric surgery.

Normally, food moves through the stomach slowly, ensuring proper digestion. First, the fundus relaxes (ie, accommodation), which allows the stomach to function as a reservoir and facilitates digestion by acid and proteases. As food moves to the antrum, it is broken down by high-amplitude muscular contractions. The **pyloric sphincter** serves as a barrier and allows only tiny, properly digested food particles to move to the small intestine.

When the pyloric sphincter is surgically removed or circumvented, as in Roux-en-Y gastric bypass, **incompletely digested food particles** enter the small intestine rapidly. The undigested material is often **hyperosmolar** and causes fluid movement from the intravascular space to the intestinal lumen. Activation of autonomic (sympathetic)

https://t.me/USMLEWorldStep1

This patient's symptoms are consistent with **dumping syndrome**, a common complication of gastric surgery.

Normally, food moves through the stomach slowly, ensuring proper digestion. First, the fundus relaxes (ie, accommodation), which allows the stomach to function as a reservoir and facilitates digestion by acid and proteases. As food moves to the antrum, it is broken down by high-amplitude muscular contractions. The **pyloric sphincter** serves as a barrier and allows only tiny, properly digested food particles to move to the small intestine.

When the pyloric sphincter is surgically removed or circumvented, as in Roux-en-Y gastric bypass, **incompletely digested food particles** enter the small intestine rapidly. The undigested material is often **hyperosmolar** and causes fluid movement from the intravascular space to the intestinal lumen. Activation of autonomic (sympathetic) reflexes and the release of vasoactive hormones (eg, serotonin, vasoactive intestinal peptide) may also occur. The resulting dumping syndrome is characterized by symptoms related to the following, which typically occur within **10-30 minutes** after eating:

- Excessive intestinal fluid: Abdominal **cramps, diarrhea**, nausea
- Vasomotor hyperactivity: **Diaphoresis**, palpitations, flushing
- Intravascular volume depletion: Hypotension, tachycardia

(Choice A) Small intestinal bacterial overgrowth can occur after surgical creation of a blind intestinal loop that promotes bacterial colonization. It manifests with diarrhea, bloating, nausea, and abdominal cramps. Autonomic symptoms (eg, diaphoresis) are not typical, and this patient's symptom onset shortly after meals is more consistent with dumping syndrome.

(Choices B and E) Vagal nerve injury, which impairs gastric muscular contractions and accommodation, and pyloric sphincter spasm would both delay the passage of food through the stomach. This can manifest as early satiety, nausea, and postprandial vomiting. Diarrhea and diaphoresis are not consistent with these disorders.

(Choice C) Stenosis of the gastrojejunostomy would prevent food from entering the small intestine, leading to postprandial vomiting and abdominal pain. It would not cause diarrhea or diaphoresis.

Educational objective:
The pyloric sphincter prevents incompletely digested hyperosmolar food particles from entering the intestines too rapidly; when the sphincter is bypassed or surgically removed, dumping syndrome may occur. Symptoms are

https://t.me/USMLEWorldStep1

proteases. As food moves to the antrum, it is broken down by high-amplitude muscular contractions. The **pyloric sphincter** serves as a barrier and allows only tiny, properly digested food particles to move to the small intestine.

When the pyloric sphincter is surgically removed or circumvented, as in Roux-en-Y gastric bypass, **incompletely digested food particles** enter the small intestine rapidly. The undigested material is often **hyperosmolar** and causes fluid movement from the intravascular space to the intestinal lumen. Activation of autonomic (sympathetic) reflexes and the release of vasoactive hormones (eg, serotonin, vasoactive intestinal peptide) may also occur. The resulting dumping syndrome is characterized by symptoms related to the following, which typically occur within **10-30 minutes** after eating:

- Excessive intestinal fluid: Abdominal **cramps, diarrhea**, nausea
- Vasomotor hyperactivity: **Diaphoresis**, palpitations, flushing
- Intravascular volume depletion: Hypotension, tachycardia

(Choice A) Small intestinal bacterial overgrowth can occur after surgical creation of a blind intestinal loop that promotes bacterial colonization. It manifests with diarrhea, bloating, nausea, and abdominal cramps. Autonomic symptoms (eg, diaphoresis) are not typical, and this patient's symptom onset shortly after meals is more consistent with dumping syndrome.

(Choices B and E) Vagal nerve injury, which impairs gastric muscular contractions and accommodation, and pyloric sphincter spasm would both delay the passage of food through the stomach. This can manifest as early satiety, nausea, and postprandial vomiting. Diarrhea and diaphoresis are not consistent with these disorders.

(Choice C) Stenosis of the gastrojejunostomy would prevent food from entering the small intestine, leading to postprandial vomiting and abdominal pain. It would not cause diarrhea or diaphoresis.

Educational objective:
The pyloric sphincter prevents incompletely digested hyperosmolar food particles from entering the intestines too rapidly; when the sphincter is bypassed or surgically removed, dumping syndrome may occur. Symptoms are related to excessive intestinal fluid (eg, abdominal cramps, diarrhea, nausea), vasomotor hyperactivity (eg, diaphoresis, palpitations, flushing), and intravascular volume depletion (eg, hypotension, tachycardia).

Pathophysiology Gastrointestinal & Nutrition Bariatric surgery

https://t.me/USMLEWorldStep1

proteases. As food moves to the antrum, it is broken down by high-amplitude muscular contractions. The **pyloric**

sphinc

When

digest

cause

reflexe

resulti

30 mi

- E
- V
- In

(Choi

promo

sympt

with d

(Choi

pyloric

satiety

(Choi

postpr

Educa

The py

rapidly

related

diapho

Exhibit Display

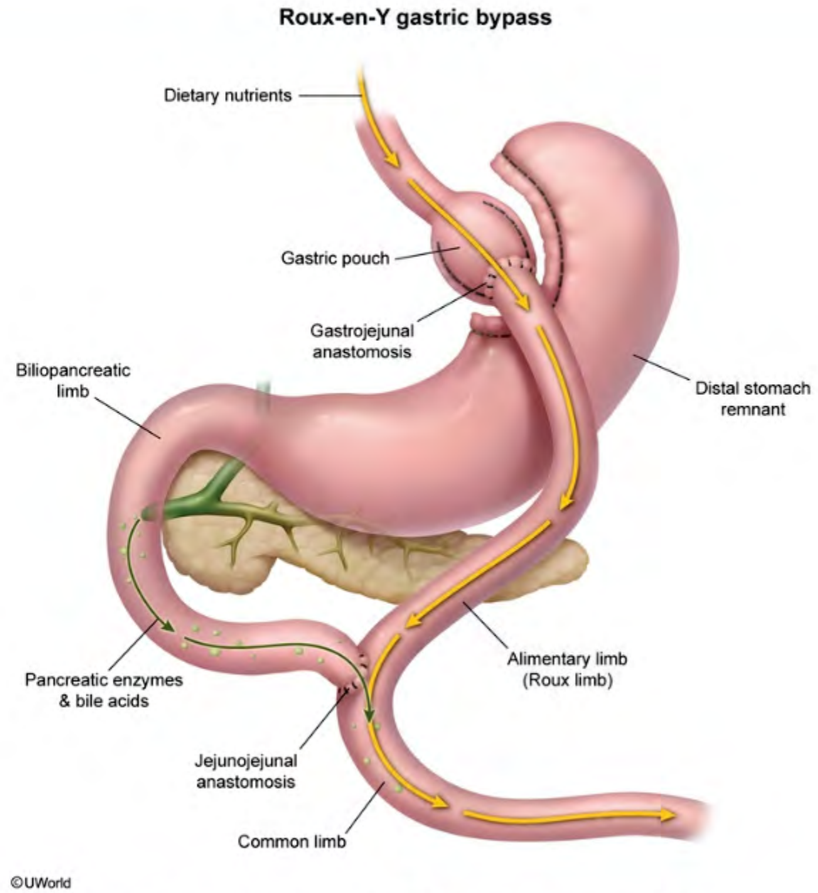

Zoom In | Zoom Out | Reset | New | Existing | My Notebook

Pathophysiology | Gastrointestinal & Nutrition | Bariatric surgery

https://t.me/USMLEWorldStep1

A 62-year-old man comes to the office due to gnawing epigastric pain radiating to the back, which started 3 months ago and has become increasingly intense. He has also experienced a 10-kg (22-lb) weight loss and yellowing of the eyes. The patient has smoked 4 or 5 cigarettes a day for most of his life. Vital signs are within normal limits. The patient appears cachectic. Examination shows scleral icterus. The abdomen is tender to deep palpation. Abdominal CT scan is shown in the image below:

This patient's abdominal lesion most likely originated from which of the following?

- A. Bile duct epithelium
- B. Hepatocyte
- C. Pancreatic acinar cell
- D. Pancreatic duct epithelium
- E. Vascular endothelium

Submit

https://t.me/USMLEWorldStep1

A 62-year-old man comes to the office due to gnawing epigastric pain radiating to the back, which started 3 months ago ar
the ey
The pa
Abdon

Exhibit Display

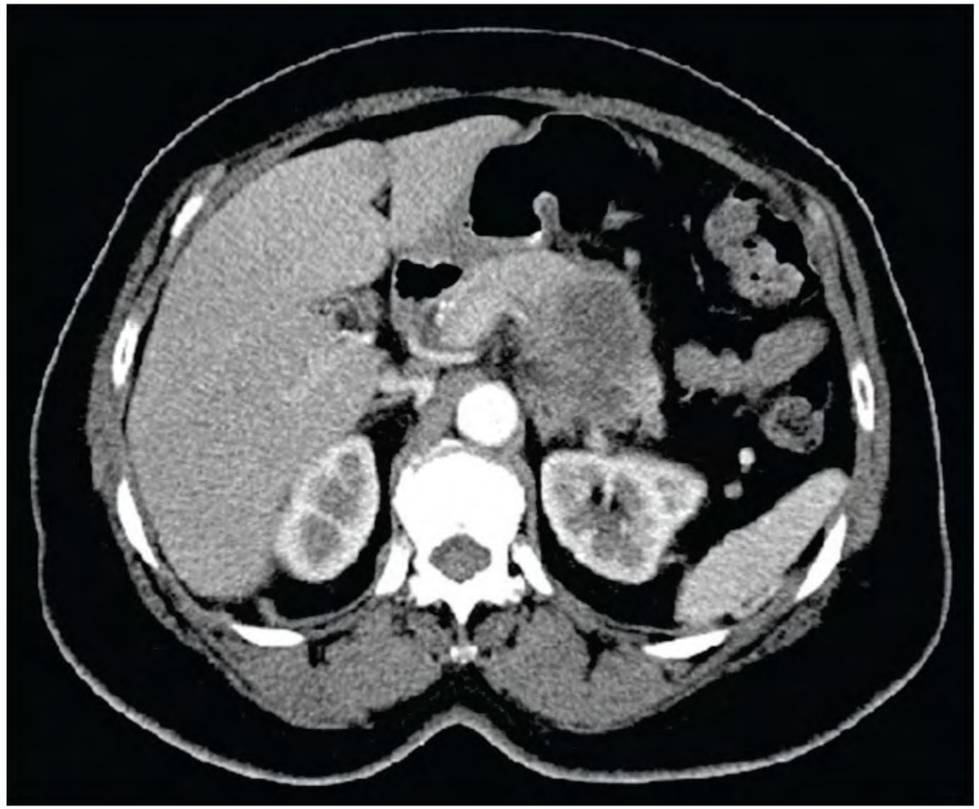

Zoom In | Zoom Out | Reset | New | Existing | My Notebook

This p

A. Bile duct epithelium

https://t.me/USMLEWorldStep1

This patient's abdominal lesion most likely originated from which of the following?

- A. Bile duct epithelium
- B. Hepatocyte
- C. Pancreatic acinar cell
- D. Pancreatic duct epithelium
- E. Vascular endothelium

Submit

https://t.me/USMLEWorldStep1

This patient's abdominal lesion most likely originated from which of the following?

- A. Bile duct epithelium (5%)
- ✗ B. Hepatocyte (3%)
- C. Pancreatic acinar cell (33%)
- ✓ D. Pancreatic duct epithelium (56%)
- E. Vascular endothelium (1%)

Incorrect
Correct answer
D

56%
Answered correctly

10 secs
Time Spent

2023
Version

https://t.me/USMLEWorldStep1

Explanation

Exhibit Display

Pancreatic neoplasm

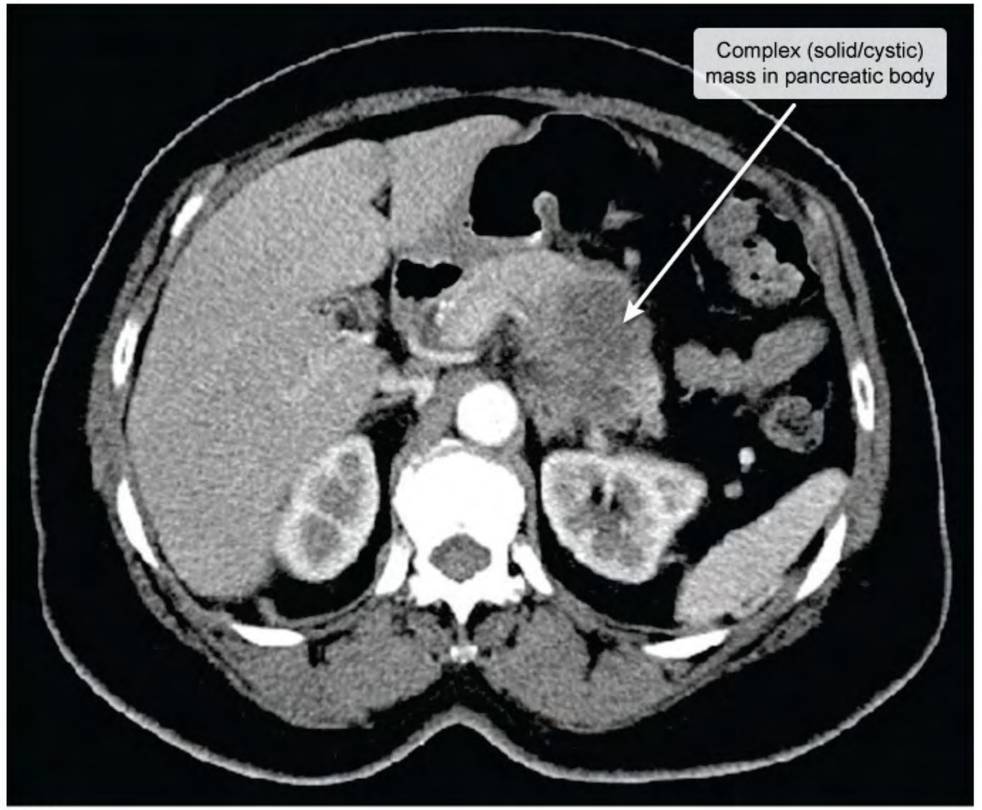

©UWorld

Zoom In | Zoom Out | Reset | New | Existing | My Notebook

This p
setting
of the
pancreatic body or tail. Other manifestations include **back pain** (especially if body/tail tumor), steatorrhea (due to exocrine pancreatic insufficiency), and new-onset diabetes mellitus (due to destruction of islet cells).

https://t.me/USMLEWorldStep1

This patient's CT scan shows a **mass** in the body of the **pancreas**, which is concerning for malignancy in the setting of gnawing **epigastric pain**, jaundice, and **unexpected weight loss**. Jaundice is more common in cancers of the pancreatic head due to obstruction of extrahepatic bile ducts but can also occur in large tumors of the pancreatic body or tail. Other manifestations include **back pain** (especially if body/tail tumor), steatorrhea (due to exocrine pancreatic insufficiency), and new-onset diabetes mellitus (due to destruction of islet cells).

The majority of pancreatic cancers are derived from the pancreatic ductal system (ie, **pancreatic ductal adenocarcinoma** [PDAC]). On gross examination, they appear as firm, whitish-yellow masses, often with cystic features. On CT scan, they often appear as **ill-defined hypoattenuating lesions** within the pancreatic parenchyma. PDAC is microscopically characterized by haphazardly arranged pleomorphic glandular cells surrounded by dense stromal fibrosis (eg, desmoplasia).

(Choice A) Cholangiocarcinoma is a cancer derived from bile duct epithelial cells. Although abdominal pain, jaundice, and weight loss are common in cholangiocarcinoma, this patient's CT scan clearly shows a mass in the pancreas, not the biliary tree.

(Choice B) Hepatocellular carcinoma originates from hepatocytes and most commonly occurs in patients with chronic liver disease (eg, viral hepatitis, cirrhosis). A pancreatic mass without liver involvement is not consistent with this diagnosis.

(Choice C) Cancers derived from pancreatic acinar cells (eg, acinar cell carcinoma) can cause symptoms similar to those of PDAC and may have similar CT findings; however, acinar cell carcinoma is extremely rare compared to PDAC and is therefore less likely in this patient.

(Choice E) Hemangiomas are benign hepatic tumors that arise from vascular endothelium; they do not typically develop within the pancreas.

Educational objective:
Pancreatic ductal adenocarcinoma is the most common pancreatic malignancy and typically presents with epigastric pain, weight loss, jaundice (more common if in the pancreatic head), or back pain (more common if in the pancreatic body/tail). It appears radiographically as an ill-defined hypoattenuating lesion within the pancreatic parenchyma. It is characterized microscopically by haphazardly arranged pleomorphic glandular cells surrounded by dense stromal fibrosis (eg, desmoplasia).

https://t.me/USMLEWorldStep1

pancreatic body or tail. Other manifestations include **back pain** (especially if body/tail tumor), steatorrhea (due to exocrine pancreatic insufficiency), and new-onset diabetes mellitus (due to destruction of islet cells).

The majority of pancreatic cancers are derived from the pancreatic ductal system (ie, **pancreatic ductal adenocarcinoma** [PDAC]). On gross examination, they appear as firm, whitish-yellow masses, often with cystic features. On CT scan, they often appear as **ill-defined hypoattenuating lesions** within the pancreatic parenchyma. PDAC is microscopically characterized by haphazardly arranged pleomorphic glandular cells surrounded by dense stromal fibrosis (eg, desmoplasia).

(Choice A) Cholangiocarcinoma is a cancer derived from bile duct epithelial cells. Although abdominal pain, jaundice, and weight loss are common in cholangiocarcinoma, this patient's CT scan clearly shows a mass in the pancreas, not the biliary tree.

(Choice B) Hepatocellular carcinoma originates from hepatocytes and most commonly occurs in patients with chronic liver disease (eg, viral hepatitis, cirrhosis). A pancreatic mass without liver involvement is not consistent with this diagnosis.

(Choice C) Cancers derived from pancreatic acinar cells (eg, acinar cell carcinoma) can cause symptoms similar to those of PDAC and may have similar CT findings; however, acinar cell carcinoma is extremely rare compared to PDAC and is therefore less likely in this patient.

(Choice E) Hemangiomas are benign hepatic tumors that arise from vascular endothelium; they do not typically develop within the pancreas.

Educational objective:
Pancreatic ductal adenocarcinoma is the most common pancreatic malignancy and typically presents with epigastric pain, weight loss, jaundice (more common if in the pancreatic head), or back pain (more common if in the pancreatic body/tail). It appears radiographically as an ill-defined hypoattenuating lesion within the pancreatic parenchyma. It is characterized microscopically by haphazardly arranged pleomorphic glandular cells surrounded by dense stromal fibrosis (eg, desmoplasia).

Pathology	Gastrointestinal & Nutrition	Pancreatic cancer
Subject	System	Topic

https://t.me/USMLEWorldStep1

This patient's CT scan shows a **mass** in the body of the **pancreas**, which is concerning for malignancy in the setting
of the
pancre
exocri

The m
adeno
feature
parenc
surrou

(Choi
jaundi
pancre

(Choi
chroni
with th

(Choi
to thos
PDAC

(Choi
develc

Educa
Pancre
epigas
the pa
parenchyma. It is characterized microscopically by haphazardly arranged pleomorphic glandular cells surrounded

Exhibit Display

Pancreatic ductal adenocarcinoma

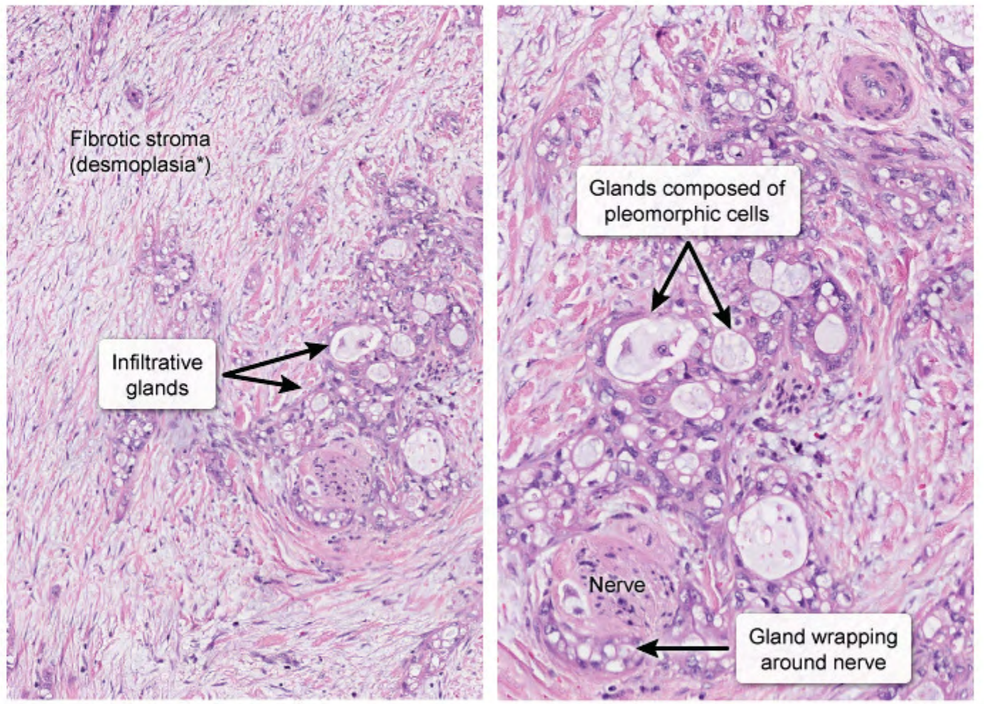

*Tumor cells elicit stromal collagen synthesis.

©UWorld

Zoom In | Zoom Out | Reset | New | Existing | My Notebook

https://t.me/USMLEWorldStep1

A 5-week-old boy born to a 23-year-old primigravida is brought to the emergency department due to increasingly frequent, forceful vomiting after every feed over the last 4 days. The emesis appears to be undigested formula. The patient seems hungry again after vomiting. On examination, the anterior fontanelle is slightly sunken, and mucous membranes are dry. Abdominal examination shows prominent peristalsis in the epigastric region. Laboratory evaluation indicates metabolic alkalosis and mild unconjugated hyperbilirubinemia. Which of the following developmental defects most likely underlies this patient's condition?

- A. Abnormal growth of smooth muscle
- B. Abnormal rotation of the midgut
- C. Cystic dilation of the biliary tree
- D. Disruption of the mesenteric blood vessels
- E. Fibrous obliteration of the extrahepatic bile ducts

Submit

https://t.me/USMLEWorldStep1

A 5-week-old boy born to a 23-year-old primigravida is brought to the emergency department due to increasingly frequent, forceful vomiting after every feed over the last 4 days. The emesis appears to be undigested formula. The patient seems hungry again after vomiting. On examination, the anterior fontanelle is slightly sunken, and mucous membranes are dry. Abdominal examination shows prominent peristalsis in the epigastric region. Laboratory evaluation indicates metabolic alkalosis and mild unconjugated hyperbilirubinemia. Which of the following developmental defects most likely underlies this patient's condition?

- ✓ A. Abnormal growth of smooth muscle (58%)
- B. Abnormal rotation of the midgut (23%)
- C. Cystic dilation of the biliary tree (5%)
- D. Disruption of the mesenteric blood vessels (4%)
- E. Fibrous obliteration of the extrahepatic bile ducts (8%)

Correct

58% Answered correctly

04 secs Time Spent

2023 Version

Explanation

Infantile hypertrophic pyloric stenosis	
Pathogenesis	• Thickening of pylorus → gastric outlet obstruction
Risk factors	• First-born male • Positive family history • Macrolide antibiotic exposure
Clinical findings	• Age 3-6 weeks • Projectile, post-prandial nonbilious emesis

https://t.me/USMLEWorldStep1

Infantile hypertrophic pyloric stenosis	
Pathogenesis	• Thickening of pylorus → gastric outlet obstruction
Risk factors	• First-born male • Positive family history • Macrolide antibiotic exposure
Clinical findings	• Age 3-6 weeks • Projectile, post-prandial nonbilious emesis • ± Signs of dehydration (eg, sunken fontanelle) • Palpable, olive-shaped epigastric mass
Laboratory/imaging	• Hypochloremic hypokalemic metabolic alkalosis • ± Indirect hyperbilirubinemia • Ultrasound: thickened, elongated pylorus

Nonbilious emesis and signs of dehydration (eg, sunken fontanelle, dry mucous membranes) in an infant **age 3-6 weeks** raise concern for infantile **hypertrophic pyloric stenosis**. Hypertrophy of the circular layer of smooth muscle that surrounds the pylorus obstructs the gastric outlet and impedes the passage of gastric contents, resulting in nonbilious, projectile emesis. Vomiting usually occurs immediately after oral intake, and infants classically show signs of hunger soon after emesis. The etiology of this abnormal postnatal **growth of smooth muscle** is likely multifactorial, involving the interplay of genetic factors (eg, positive family history) with environmental exposures (eg, macrolide antibiotics).

If the diagnosis is delayed, protracted vomiting can result in hypochloremic **metabolic alkalosis** because of the loss of hydrochloric acid in the emesis. In addition, hypovolemia activates the renin-angiotensin-aldosterone system, and aldosterone stimulates potassium excretion by the kidneys, resulting in hypokalemia. **Unconjugated hyperbilirubinemia** is also commonly seen due to dehydration, which increases enterohepatic circulation of bilirubin.

Examination of patients with infantile hypertrophic pyloric stenosis often reveals palpation of the hypertrophied

https://t.me/USMLEWorldStep1

	• Ultrasound: thickened, elongated pylorus

Nonbilious emesis and signs of dehydration (eg, sunken fontanelle, dry mucous membranes) in an infant **age 3-6 weeks** raise concern for infantile **hypertrophic pyloric stenosis**. Hypertrophy of the circular layer of smooth muscle that surrounds the pylorus obstructs the gastric outlet and impedes the passage of gastric contents, resulting in nonbilious, projectile emesis. Vomiting usually occurs immediately after oral intake, and infants classically show signs of hunger soon after emesis. The etiology of this abnormal postnatal **growth of smooth muscle** is likely multifactorial, involving the interplay of genetic factors (eg, positive family history) with environmental exposures (eg, macrolide antibiotics).

If the diagnosis is delayed, protracted vomiting can result in hypochloremic **metabolic alkalosis** because of the loss of hydrochloric acid in the emesis. In addition, hypovolemia activates the renin-angiotensin-aldosterone system, and aldosterone stimulates potassium excretion by the kidneys, resulting in hypokalemia. **Unconjugated hyperbilirubinemia** is also commonly seen due to dehydration, which increases enterohepatic circulation of bilirubin.

Examination of patients with infantile hypertrophic pyloric stenosis often reveals palpation of the hypertrophied muscle as an **olive-shaped abdominal mass** in the epigastrium, although its absence does not exclude the diagnosis. Visually **prominent peristaltic waves** may be seen and represent exaggerated gastric contractions attempting to move food beyond the obstruction. A thick, elongated pylorus visualized with abdominal ultrasonography is diagnostic, and pyloromyotomy is the definitive treatment.

(Choice B) Midgut malrotation is a defect in the normal rotation of the midgut around the superior mesenteric artery in early gestation and can lead to volvulus of the small intestine. Although vomiting commonly occurs, the emesis is typically bilious, and infants are usually ill-appearing and hemodynamically unstable.

(Choices C and E) Biliary cysts and biliary atresia (fibrous obliteration of the extrahepatic bile ducts) cause jaundice due to direct (conjugated) hyperbilirubinemia, which is not present in this patient. Moreover, these conditions do not typically cause vomiting.

(Choice D) Intestinal atresia is caused by disruption of mesenteric blood vessels during embryologic development, leading to ischemic necrosis and resorption of the fetal bowel. Vomiting is a common presenting symptom, but it occurs within 48 hours of birth and the emesis is bilious.

https://t.me/USMLEWorldStep1

muscle is likely multifactorial, involving the interplay of genetic factors (eg, positive family history) with environmental exposures (eg, macrolide antibiotics).

If the diagnosis is delayed, protracted vomiting can result in hypochloremic **metabolic alkalosis** because of the loss of hydrochloric acid in the emesis. In addition, hypovolemia activates the renin-angiotensin-aldosterone system, and aldosterone stimulates potassium excretion by the kidneys, resulting in hypokalemia. **Unconjugated hyperbilirubinemia** is also commonly seen due to dehydration, which increases enterohepatic circulation of bilirubin.

Examination of patients with infantile hypertrophic pyloric stenosis often reveals palpation of the hypertrophied muscle as an **olive-shaped abdominal mass** in the epigastrium, although its absence does not exclude the diagnosis. Visually **prominent peristaltic waves** may be seen and represent exaggerated gastric contractions attempting to move food beyond the obstruction. A thick, elongated pylorus visualized with abdominal ultrasonography is diagnostic, and pyloromyotomy is the definitive treatment.

(Choice B) Midgut malrotation is a defect in the normal rotation of the midgut around the superior mesenteric artery in early gestation and can lead to volvulus of the small intestine. Although vomiting commonly occurs, the emesis is typically bilious, and infants are usually ill-appearing and hemodynamically unstable.

(Choices C and E) Biliary cysts and biliary atresia (fibrous obliteration of the extrahepatic bile ducts) cause jaundice due to direct (conjugated) hyperbilirubinemia, which is not present in this patient. Moreover, these conditions do not typically cause vomiting.

(Choice D) Intestinal atresia is caused by disruption of mesenteric blood vessels during embryologic development, leading to ischemic necrosis and resorption of the fetal bowel. Vomiting is a common presenting symptom, but it occurs within 48 hours of birth and the emesis is bilious.

Educational objective:
Infantile hypertrophic pyloric stenosis is characterized by smooth muscle overgrowth of the pylorus. Gastric outlet obstruction leads to the classic presentation of nonbilious, projectile emesis and dehydration in an infant age 3-6 weeks.

Pathology	Gastrointestinal & Nutrition	Hypertrophic pyloric stenosis
Subject	System	Topic

https://t.me/USMLEWorldStep1

- Ultrasound: thickened, elongated pylorus

Exhibit Display

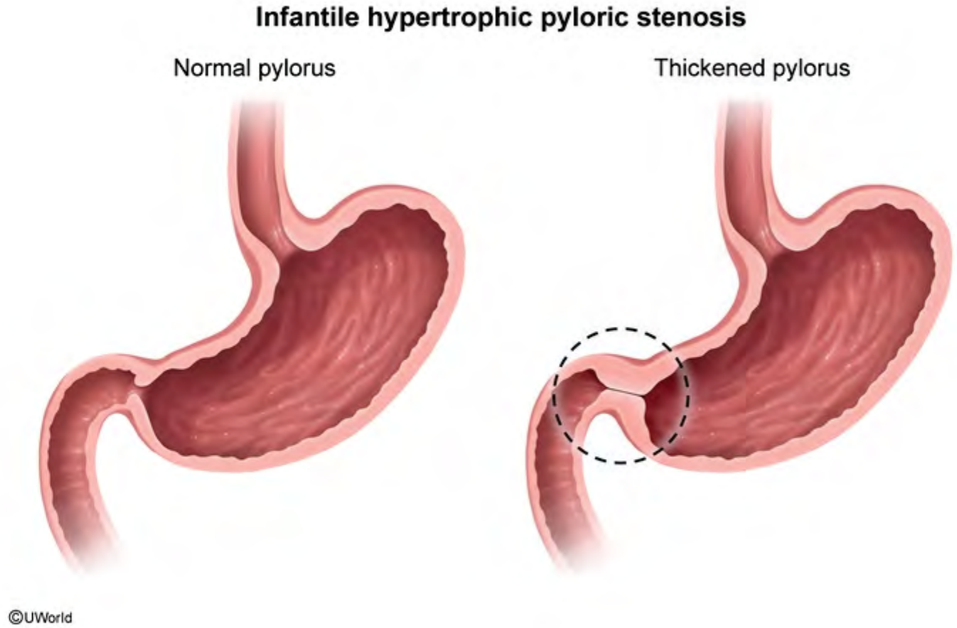

Zoom In | Zoom Out | Reset | New | Existing | My Notebook

Nonbi
weeks
muscl
resulti
classic
muscl
enviro

If the c
loss of
systen
hyper
bilirubi

Exami
muscl
diagno
attemp
ultrasc

(Choic
artery
emesis

(Choic
jaundi
conditi

(Choic
development, leading to ischemic necrosis and resorption of the fetal bowel. Vomiting is a common presenting symptom, but it occurs within 48 hours of birth and the emesis is bilious.

https://t.me/USMLEWorldStep1

A 1-month-old boy is brought to the office for follow-up of blood-streaked stools and diarrhea. The patient was born preterm at 35 weeks gestation and had no complications in the newborn nursery. He had been taking a standard cow's milk–based formula until 2 weeks ago when he developed loose stools streaked with blood and mucus. Symptoms resolved after changing the formula. If histopathologic examination had been performed when the patient was symptomatic, which of the following would most likely be seen?

- A. Eosinophilic infiltration in the distal colon
- B. Hemorrhagic necrosis of the bowel wall
- C. Heterotopic gastric mucosa in the distal ileum
- D. Neutrophilic crypt abscess formation in the colon

Submit

https://t.me/USMLEWorldStep1

A 1-month-old boy is brought to the office for follow-up of blood-streaked stools and diarrhea. The patient was born preterm at 35 weeks gestation and had no complications in the newborn nursery. He had been taking a standard cow's milk–based formula until 2 weeks ago when he developed loose stools streaked with blood and mucus. Symptoms resolved after changing the formula. If histopathologic examination had been performed when the patient was symptomatic, which of the following would most likely be seen?

- ✓ A. Eosinophilic infiltration in the distal colon (43%)
- B. Hemorrhagic necrosis of the bowel wall (27%)
- C. Heterotopic gastric mucosa in the distal ileum (14%)
- D. Neutrophilic crypt abscess formation in the colon (15%)

Correct

43% Answered correctly

03 secs Time Spent

2023 Version

Explanation

Food protein–induced allergic proctocolitis	
Pathophysiology	• Non–IgE-mediated reaction • Eosinophilic inflammation of rectosigmoid colon • Common triggers: cow's milk & soy protein
Clinical features	• Age 1-4 weeks (up to 6 months) • Well appearing • Blood- &/or mucus-streaked stools (positive Hemoccult)
Treatment & prognosis	• Protein elimination (eg, hydrolyzed formula) • Tolerance of offending protein by age 1

https://t.me/USMLEWorldStep1

Food protein–induced allergic proctocolitis	
Pathophysiology	• Non–IgE-mediated reaction • Eosinophilic inflammation of rectosigmoid colon • Common triggers: cow's milk & soy protein
Clinical features	• Age 1-4 weeks (up to 6 months) • Well appearing • Blood- &/or mucus-streaked stools (positive Hemoccult)
Treatment & prognosis	• Protein elimination (eg, hydrolyzed formula) • Tolerance of offending protein by age 1

This patient most likely has **food protein–induced allergic proctocolitis**, a benign condition of early infancy (age <6 months). Affected infants have a **non–IgE-mediated reaction** to proteins found in breast milk or formula (most common trigger is cow's milk). **Painless, blood-streaked stools** (which may also be loose and contain mucus) typically develop weeks to months after initial exposure to the food allergen.

Diagnosis is clinical. Although endoscopy is not performed unless symptoms are atypical (eg, severe bleeding, constipation, vomiting), characteristic findings include **inflammation** (ie, erythema, edema) confined to the **distal colon** and rectum. Histopathology findings include infiltration of **eosinophils** within the lamina propria and muscularis mucosa.

Management includes dietary avoidance of the trigger protein (eg, switching to a hydrolyzed formula, maternal elimination of dairy for breastfed infants). Symptoms typically resolve within weeks, and most infants can tolerate the offending protein by age 1.

(Choice B) Hemorrhagic necrosis of the bowel wall describes necrotizing enterocolitis, a gastrointestinal emergency that can result in gut ischemia and death if untreated (eg, bowel rest, antibiotics). In addition to rectal bleeding, patients often have abdominal distension, poor feeding, and hemodynamic instability, none of which is present in this patient.

https://t.me/USMLEWorldStep1

<6 months). Affected infants have a **non–IgE-mediated reaction** to proteins found in breast milk or formula (most common trigger is cow's milk). **Painless, blood-streaked stools** (which may also be loose and contain mucus) typically develop weeks to months after initial exposure to the food allergen.

Diagnosis is clinical. Although endoscopy is not performed unless symptoms are atypical (eg, severe bleeding, constipation, vomiting), characteristic findings include **inflammation** (ie, erythema, edema) confined to the **distal colon** and rectum. Histopathology findings include infiltration of **eosinophils** within the lamina propria and muscularis mucosa.

Management includes dietary avoidance of the trigger protein (eg, switching to a hydrolyzed formula, maternal elimination of dairy for breastfed infants). Symptoms typically resolve within weeks, and most infants can tolerate the offending protein by age 1.

(Choice B) Hemorrhagic necrosis of the bowel wall describes necrotizing enterocolitis, a gastrointestinal emergency that can result in gut ischemia and death if untreated (eg, bowel rest, antibiotics). In addition to rectal bleeding, patients often have abdominal distension, poor feeding, and hemodynamic instability, none of which is present in this patient.

(Choices C and D) A Meckel diverticulum can contain heterotopic gastric mucosa in the distal ileum, and neutrophilic crypt abscesses can be seen with ulcerative colitis. Although these conditions, which are both exceedingly rare in the neonatal period, can cause blood in the stool, neither would resolve with a change in formula.

Educational objective:
Food protein–induced allergic proctocolitis is a non–IgE-mediated reaction that causes inflammation and eosinophilic infiltration of the distal colon. Classic presentation is in early infancy with painless, blood-streaked stools that resolve with dietary avoidance of the offending food protein (eg, cow's milk).

References

- Food protein–induced enterocolitis syndrome and allergic proctocolitis.

Pathology	Gastrointestinal & Nutrition	Food protein-induced allergic proctocolitis
Subject	System	Topic

https://t.me/USMLEWorldStep1

<6 months). Affected infants have a **non–IgE-mediated reaction** to proteins found in breast milk or formula (most common trigger is cow's milk). **Painless, blood-streaked stools** (which may also be loose and contain mucus) typical

Diagn
consti
colon
muscu

Manag
elimin
the off

(Choi
emerg
bleedi
preser

(Choi
neutro
excee
formul

Educa
Food p
eosinc
stools

Refere
- Foo

Exhibit Display

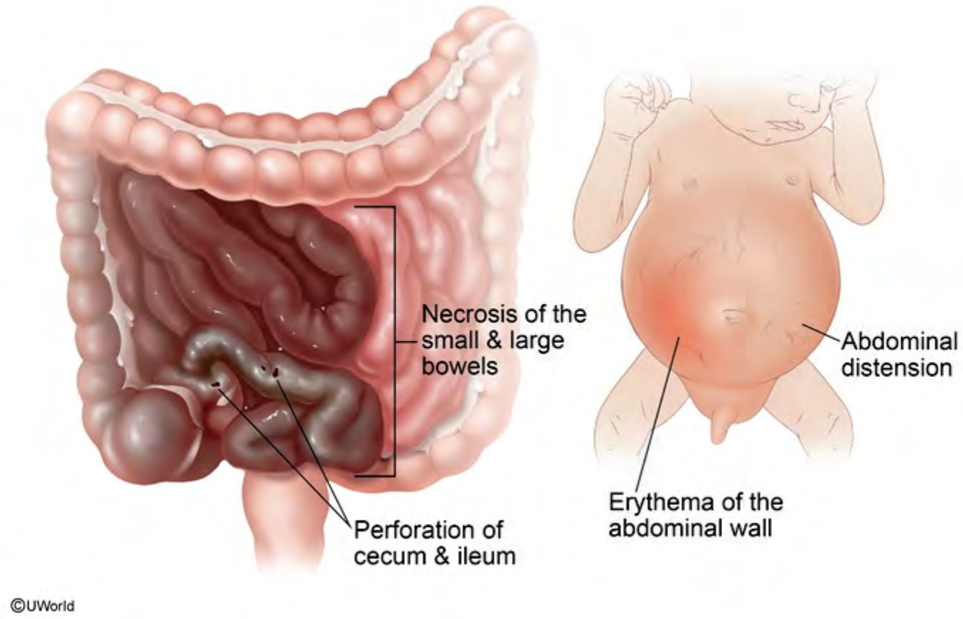

Zoom In | Zoom Out | Reset | New | Existing | My Notebook

Pathology (Subject) | Gastrointestinal & Nutrition (System) | Food protein-induced allergic proctocolitis (Topic)

https://t.me/USMLEWorldStep1

<6 months). Affected infants have a **non–IgE-mediated reaction** to proteins found in breast milk or formula (most common trigger is cow's milk). **Painless, blood-streaked stools** (which may also be loose and contain mucus) typical

Diagn
consti
colon
muscu

Manag
elimin
the off

(Choi
emerg
bleedi
preser

(Choi
neutro
excee
formul

Educa
Food p
eosinc
stools

Refere
- Foo

Exhibit Display

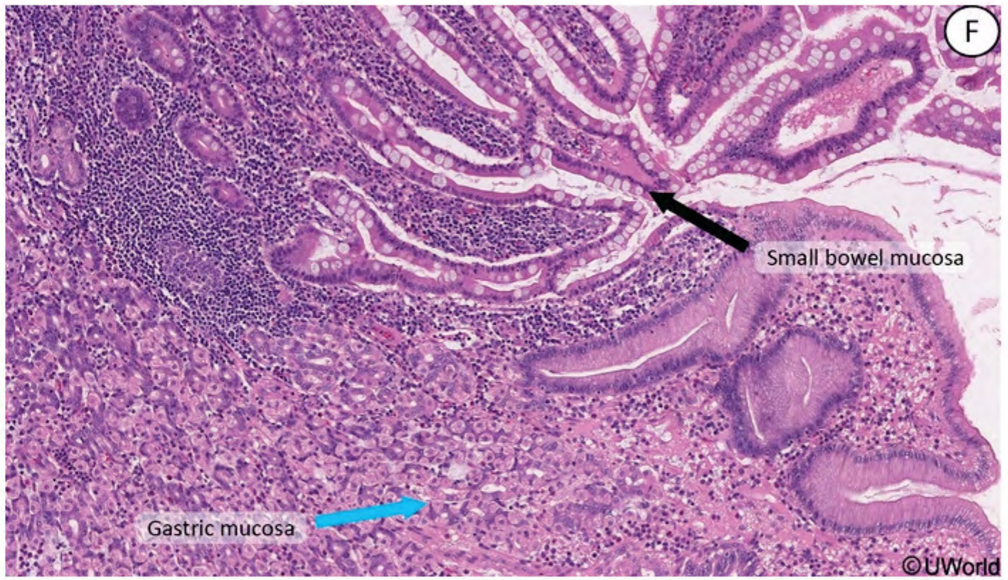

Zoom In Zoom Out Reset New | Existing My Notebook

Pathology (Subject) | Gastrointestinal & Nutrition (System) | Food protein-induced allergic proctocolitis (Topic)

https://t.me/USMLEWorldStep1

<6 months). Affected infants have a **non–IgE-mediated reaction** to proteins found in breast milk or formula (most common trigger is cow's milk). **Painless, blood-streaked stools** (which may also be loose and contain mucus)

typical

Diagn
consti
colon
muscu

Manag
elimin
the off

(Choi
emerg
bleedi
preser

(Choi
neutro
excee
formul

Educa
Food p
eosinc
stools

Refere
- Foo

Exhibit Display

Ulcerative colitis

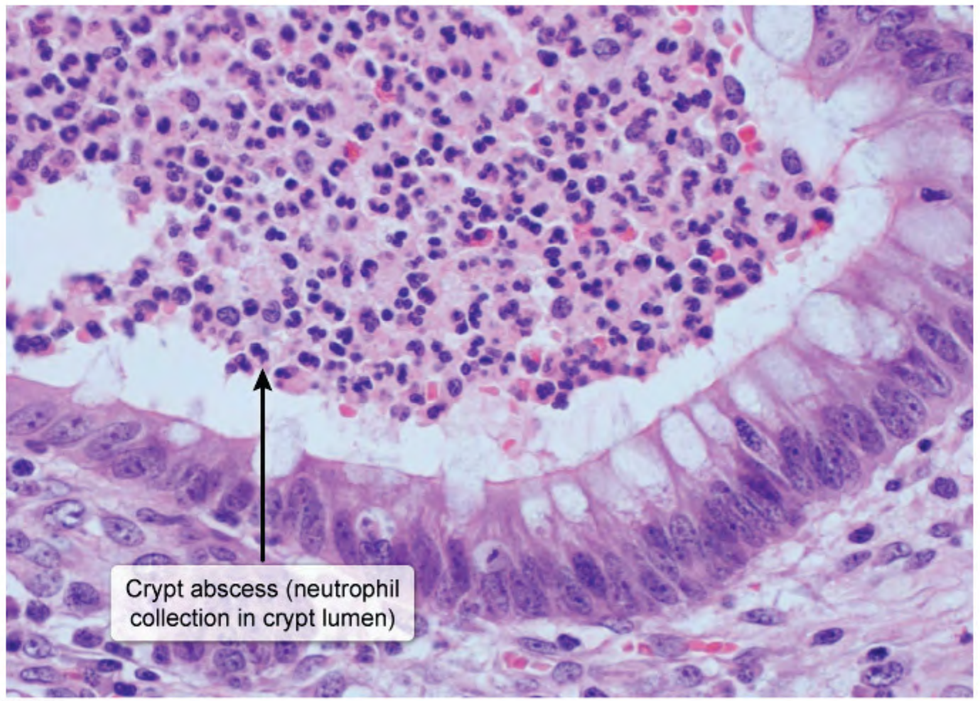

©UWorld

Zoom In | Zoom Out | Reset | New | Existing | My Notebook

Pathology	Gastrointestinal & Nutrition	Food protein-induced allergic proctocolitis
Subject	System	Topic

https://t.me/USMLEWorldStep1

A 45-year-old man with diabetes mellitus is admitted to the intensive care unit due to community-acquired pneumonia, septic shock, and respiratory failure. Two days ago, he developed fever, productive cough, and shortness of breath that has progressively worsened. The patient is intubated and placed on mechanical ventilation. He is also started on intravenous fluids, broad-spectrum antibiotics, and a norepinephrine infusion. On the third day of hospitalization, hemoglobin level drops from 14 g/dL to 12 g/dL. Nasogastric suctioning reveals bright red blood. This patient's bleeding is most likely a result of which of the following processes?

- A. Autoimmune parietal cell destruction
- B. Gastrin-secreting tumor
- C. Granuloma formation
- D. *Helicobacter pylori* infection
- E. Malignant transformation
- F. Stress-related mucosal injury

Submit

https://t.me/USMLEWorldStep1

A 45-year-old man with diabetes mellitus is admitted to the intensive care unit due to community-acquired pneumonia, septic shock, and respiratory failure. Two days ago, he developed fever, productive cough, and shortness of breath that has progressively worsened. The patient is intubated and placed on mechanical ventilation. He is also started on intravenous fluids, broad-spectrum antibiotics, and a norepinephrine infusion. On the third day of hospitalization, hemoglobin level drops from 14 g/dL to 12 g/dL. Nasogastric suctioning reveals bright red blood. This patient's bleeding is most likely a result of which of the following processes?

- A. Autoimmune parietal cell destruction (2%)
- B. Gastrin-secreting tumor (1%)
- ✗ C. Granuloma formation (2%)
- D. *Helicobacter pylori* infection (6%)
- E. Malignant transformation (1%)
- ✓ F. Stress-related mucosal injury (85%)

Incorrect
Correct answer
F

85%
Answered correctly

03 secs
Time Spent

2023
Version

Explanation



https://t.me/USMLEWorldStep1

A 45-year-old man with diabetes mellitus is admitted to the intensive care unit due to community-acquired pneum
shortn
ventila
the thi
bright

Exhibit Display

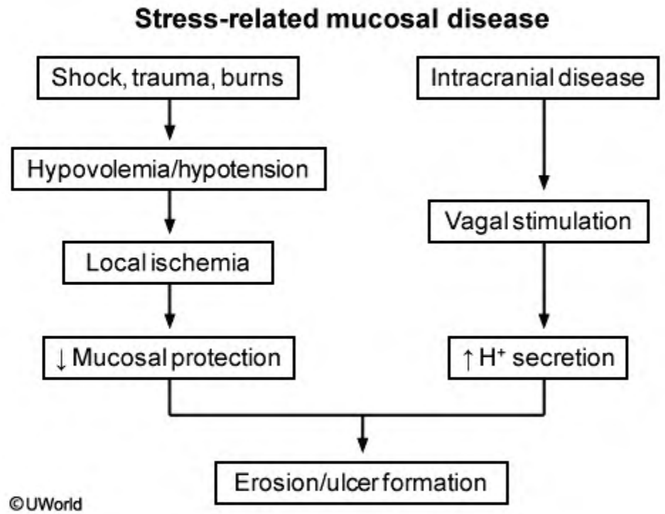

Zoom In Zoom Out Reset New | Existing My Notebook

Local ischemia

https://t.me/USMLEWorldStep1

©UWorld

Stress-related mucosal disease is characterized by acute gastric mucosal defects that develop in response to severe **physiologic stress** (eg, shock, extensive burns, sepsis, severe trauma, intracranial injury). Patients often have multiple, small (<1 cm), circular lesions in the stomach, ranging from superficial erosions to full-thickness ulcers. Ulcers may perforate or **bleed**, as in this patient.

The pathogenesis of these ulcers most often involves impaired mucosal protection due to **local ischemia** caused by systemic hypotension and splanchnic vasoconstriction. Ulcers arising in the proximal duodenum in association with severe trauma/burns are called **Curling ulcers**. Ulcers arising in the esophagus, stomach, or duodenum in patients with intracranial injury are particularly prone to perforation and are called **Cushing ulcers**. Cushing ulcers are a consequence of **direct vagus nerve stimulation** caused by elevated intracranial pressure, resulting in acetylcholine release and hypersecretion of gastric acid.

(Choice A) Chronic gastritis with antral sparing is characteristic of autoimmune gastritis. CD4+ T cell-mediated parietal cell destruction causes impaired gastric acid and intrinsic factor secretion, resulting in achlorhydria and pernicious anemia, respectively.

(Choice B) Zollinger-Ellison syndrome is caused by a gastrin-secreting tumor (gastrinoma) that is usually located in the small intestine or pancreas. Patients classically have multiple peptic ulcers that may involve the distal duodenum and are more likely to respond poorly to therapy.

(Choice C) Granulomatous gastritis is most often idiopathic but may be associated with Crohn disease, sarcoidosis, or mycobacterial infection. It is characterized by intramucosal epithelioid granulomas that cause narrowing of the antrum secondary to transmural inflammation, which can result in gastric outlet obstruction.

(Choice D) Peptic ulcers in the stomach or duodenum are most commonly due to *Helicobacter pylori* infection or nonsteroidal anti-inflammatory drug use. *H pylori* infection is also associated with chronic antral-predominant gastritis.

(Choice E) Gastric adenocarcinoma can occur as the intestinal subtype (ie, bulky mass composed of glandular structures) or diffuse subtype (ie, gross stomach wall thickening with signet-ring cells on microscopy). Risk factors for gastric adenocarcinoma include chronic gastritis, cigarette smoking, *H pylori* infection, and a diet high in salt/nitrosamines.

https://t.me/USMLEWorldStep1

with severe trauma/burns are called **Curling ulcers**. Ulcers arising in the esophagus, stomach, or duodenum in patients with intracranial injury are particularly prone to perforation and are called **Cushing ulcers**. Cushing ulcers are a consequence of **direct vagus nerve stimulation** caused by elevated intracranial pressure, resulting in acetylcholine release and hypersecretion of gastric acid.

(Choice A) Chronic gastritis with antral sparing is characteristic of autoimmune gastritis. CD4+ T cell-mediated parietal cell destruction causes impaired gastric acid and intrinsic factor secretion, resulting in achlorhydria and pernicious anemia, respectively.

(Choice B) Zollinger-Ellison syndrome is caused by a gastrin-secreting tumor (gastrinoma) that is usually located in the small intestine or pancreas. Patients classically have multiple peptic ulcers that may involve the distal duodenum and are more likely to respond poorly to therapy.

(Choice C) Granulomatous gastritis is most often idiopathic but may be associated with Crohn disease, sarcoidosis, or mycobacterial infection. It is characterized by intramucosal epithelioid granulomas that cause narrowing of the antrum secondary to transmural inflammation, which can result in gastric outlet obstruction.

(Choice D) Peptic ulcers in the stomach or duodenum are most commonly due to *Helicobacter pylori* infection or nonsteroidal anti-inflammatory drug use. *H pylori* infection is also associated with chronic antral-predominant gastritis.

(Choice E) Gastric adenocarcinoma can occur as the intestinal subtype (ie, bulky mass composed of glandular structures) or diffuse subtype (ie, gross stomach wall thickening with signet-ring cells on microscopy). Risk factors for gastric adenocarcinoma include chronic gastritis, cigarette smoking, *H pylori* infection, and a diet high in salt/nitrosamines.

Educational objective:
Stress-related mucosal disease is usually caused by local ischemia in the setting of severe physiologic stress (eg, shock, extensive burns, sepsis, severe trauma). Ulcers arising in the setting of severe trauma/burns are called Curling ulcers. Ulcers arising from intracranial injury are caused by direct vagal stimulation and are called Cushing ulcers.

References

https://t.me/USMLEWorldStep1

A 5-year-old boy is brought to the emergency department due to diarrhea and a low-grade fever. He attends a day care center where other children have developed similar symptoms. The patient has no known medical conditions. He is up to date with age-appropriate vaccinations. The patient has not traveled abroad. Physical examination shows abdominal tenderness on deep palpation but no rigidity. Stool cultures are diagnostic for *Shigella sonnei* infection. The outbreak is reported to public health authorities and is traced to consumption of potato salad handled by a food worker who recently had a mild diarrheal illness. The organism responsible for this patient's infection initially invades the intestinal epithelium through which of the following cells?

- A. Endothelial cells
- B. Enteroendocrine cells
- C. Goblet cells
- D. Microfold (M) cells
- E. Paneth cells

Submit

https://t.me/USMLEWorldStep1

A 5-year-old boy is brought to the emergency department due to diarrhea and a low-grade fever. He attends a day care center where other children have developed similar symptoms. The patient has no known medical conditions. He is up to date with age-appropriate vaccinations. The patient has not traveled abroad. Physical examination shows abdominal tenderness on deep palpation but no rigidity. Stool cultures are diagnostic for *Shigella sonnei* infection. The outbreak is reported to public health authorities and is traced to consumption of potato salad handled by a food worker who recently had a mild diarrheal illness. The organism responsible for this patient's infection initially invades the intestinal epithelium through which of the following cells?

- ✗ A. Endothelial cells (10%)
- B. Enteroendocrine cells (4%)
- C. Goblet cells (3%)
- ✓ D. Microfold (M) cells (73%)
- E. Paneth cells (7%)

Incorrect
Correct answer
D

73%
Answered correctly

03 secs
Time Spent

2023
Version

Explanation

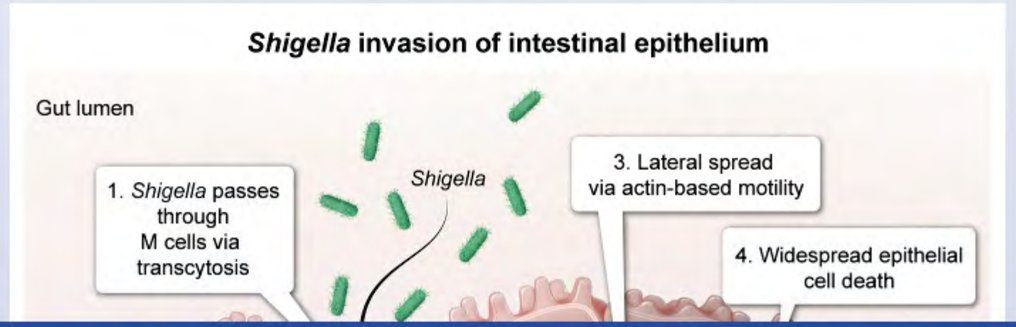

https://t.me/USMLEWorldStep1

A 5-year-old boy is brought to the emergency department due to diarrhea and a low-grade fever. He attends a day care c
conditi
exami
for *Sh*
potato
patien

Exhibit Display

***Shigella* invasion of intestinal epithelium**

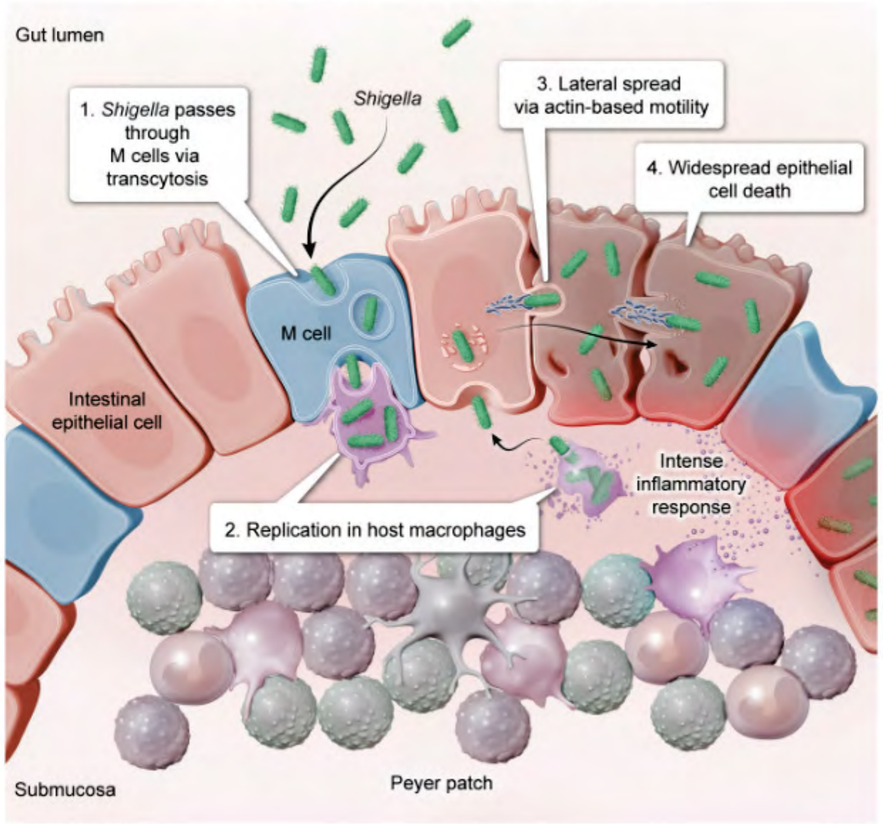

M cell = Microfold cell.

©UWorld

Zoom In | Zoom Out | Reset | New | Existing | My Notebook

https://t.me/USMLEWorldStep1

M cell = Microfold cell.

©UWorld

Shigellosis is an infectious form of hemorrhagic diarrhea that can be caused by a variety of *Shigella* species (eg, *S dysenteriae, flexneri, sonnei*). *Shigella* invades cells within the intestinal epithelial barrier, including enterocytes and **microfold (M) cells**. M cells are found at the base of mucosal villi that overlie **Peyer patches** in the ileum, and normally transfer antigens from the gut lumen to the basal membrane via transcytosis. Macrophages and lymphocytes aggregate near a special pocket (microfold) at the base of M cells, where they can sample antigens and mount an immune response.

Shigella most easily penetrates the epithelial barrier by passing through M cells. Once at the basolateral surface, *Shigella* can more efficiently enter enterocytes and then spread laterally into other epithelial cells without reentering the gut lumen (ie, actin-based motility). The bacterium also induces macrophage apoptosis, resulting in a massive inflammatory response that causes denuding and ulceration of the mucosa with subsequent **bloody and mucoid** stools.

(Choice A) Endothelial cells form the innermost lining of blood vessels. Shiga toxin produced by *Escherichia coli* O157:H7 and *S dysenteriae*, not *S sonnei*, can cause toxicity to renal endothelial cells, leading to hemolytic uremic syndrome. However, all *Shigella* species are transmitted via the fecal-oral route and initiate infection by disrupting the intestinal epithelial barrier.

(Choice B) Enteroendocrine cells in the gastrointestinal tract secrete hormones such as somatostatin and cholecystokinin. They are not involved in the pathogenesis of *Shigella* infection.

(Choice C) Goblet cells secrete mucus into the gut lumen, and mucous release is increased in inflammatory states, including *Shigella* diarrhea. However, goblet cells do not uptake bacteria.

(Choice E) Paneth cells, which occur in small groups at the base of intestinal crypts, are both phagocytic and secretory, thereby providing first-line immune defense against microorganisms. They secrete lysozyme (an enzyme that dissolves the cell walls of many bacteria) and defensins (polypeptides with antimicrobial properties) but do not uptake *Shigella*.

Educational objective:

Shigella initially invades the intestinal epithelial barrier by passing through microfold (M) cells overlying ileal Peyer

https://t.me/USMLEWorldStep1

S dysenteriae, flexneri, sonnei). *Shigella* invades cells within the intestinal epithelial barrier, including enterocytes and **microfold (M) cells**. M cells are found at the base of mucosal villi that overlie **Peyer patches** in the ileum, and normally transfer antigens from the gut lumen to the basal membrane via transcytosis. Macrophages and lymphocytes aggregate near a special pocket (microfold) at the base of M cells, where they can sample antigens and mount an immune response.

Shigella most easily penetrates the epithelial barrier by passing through M cells. Once at the basolateral surface, *Shigella* can more efficiently enter enterocytes and then spread laterally into other epithelial cells without reentering the gut lumen (ie, actin-based motility). The bacterium also induces macrophage apoptosis, resulting in a massive inflammatory response that causes denuding and ulceration of the mucosa with subsequent **bloody and mucoid** stools.

(Choice A) Endothelial cells form the innermost lining of blood vessels. Shiga toxin produced by *Escherichia coli* O157:H7 and *S dysenteriae*, not *S sonnei*, can cause toxicity to renal endothelial cells, leading to hemolytic uremic syndrome. However, all *Shigella* species are transmitted via the fecal-oral route and initiate infection by disrupting the intestinal epithelial barrier.

(Choice B) Enteroendocrine cells in the gastrointestinal tract secrete hormones such as somatostatin and cholecystokinin. They are not involved in the pathogenesis of *Shigella* infection.

(Choice C) Goblet cells secrete mucus into the gut lumen, and mucous release is increased in inflammatory states, including *Shigella* diarrhea. However, goblet cells do not uptake bacteria.

(Choice E) Paneth cells, which occur in small groups at the base of intestinal crypts, are both phagocytic and secretory, thereby providing first-line immune defense against microorganisms. They secrete lysozyme (an enzyme that dissolves the cell walls of many bacteria) and defensins (polypeptides with antimicrobial properties) but do not uptake *Shigella*.

Educational objective:
Shigella initially invades the intestinal epithelial barrier by passing through microfold (M) cells overlying ileal Peyer patches. Once at the basolateral mucosal surface, *Shigella* can more efficiently enter enterocytes and then spread laterally into other epithelial cells, causing cell death and ulceration with bloody/mucoid diarrhea.

https://t.me/USMLEWorldStep1

A 42-year-old man is brought to the emergency department after a suspected suicide attempt. The patient's wife filed for divorce a few days ago, and 3 hours ago, he began drinking alcohol and took multiple acetaminophen tablets. He has had several episodes of vomiting. The patient has no significant history of alcohol use, and he last drank alcohol 6 months ago. Vital signs are stable. Laboratory results are pending. The patient's family is concerned about significant liver injury given his concurrent alcohol and acetaminophen intake. A physician explains to the family that acute ethanol ingestion may reduce the risk of acetaminophen-induced liver toxicity. Which of the following actions of ethanol best explains this phenomenon?

- A. Competitive inhibition of hepatic cytochrome P450
- B. Depletion of hepatic glutathione synthesis
- C. Impaired hepatic glucuronidation of acetaminophen
- D. Impaired intestinal absorption of acetaminophen
- E. Induction of hepatic cytochrome P450

Submit

https://t.me/USMLEWorldStep1

A 42-year-old man is brought to the emergency department after a suspected suicide attempt. The patient's wife filed for divorce a few days ago, and 3 hours ago, he began drinking alcohol and took multiple acetaminophen tablets. He has had several episodes of vomiting. The patient has no significant history of alcohol use, and he last drank alcohol 6 months ago. Vital signs are stable. Laboratory results are pending. The patient's family is concerned about significant liver injury given his concurrent alcohol and acetaminophen intake. A physician explains to the family that acute ethanol ingestion may reduce the risk of acetaminophen-induced liver toxicity. Which of the following actions of ethanol best explains this phenomenon?

- ✓ A. Competitive inhibition of hepatic cytochrome P450 (44%)
- B. Depletion of hepatic glutathione synthesis (8%)
- C. Impaired hepatic glucuronidation of acetaminophen (21%)
- D. Impaired intestinal absorption of acetaminophen (3%)
- E. Induction of hepatic cytochrome P450 (21%)

Correct

44%
Answered correctly

04 secs
Time Spent

2023
Version

Explanation

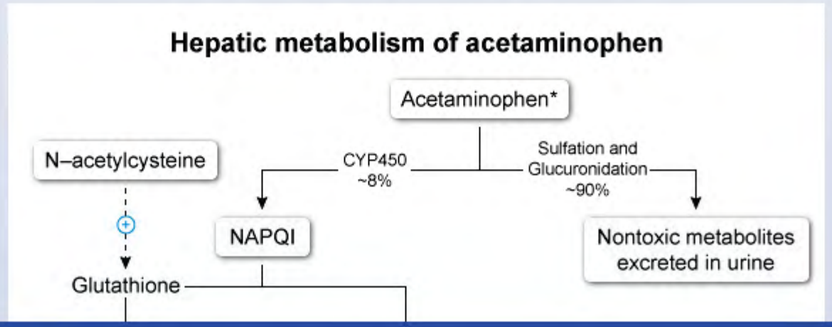

https://t.me/USMLEWorldStep1

A 42-year-old man is brought to the emergency department after a suspected suicide attempt. The patient's wife filed fo
tablets
drank
concer
explai
Which

Exhibit Display

Hepatic metabolism of acetaminophen

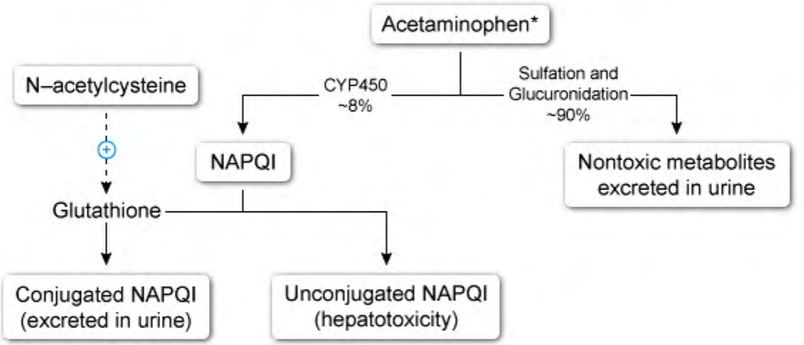

*2% of Acetaminophen is excreted unchanged in the urine.
CYP450 = Cytochrome p450.
NAPQI = N-acetyl-p-benzoquinoneimine.

©UWorld

Zoom In | Zoom Out | Reset | New | Existing | My Notebook

https://t.me/USMLEWorldStep1

Acetaminophen is a commonly used antipyretic and analgesic drug that is metabolized by the liver. Although it is mostly converted to nontoxic metabolites by sulfation and glucuronidation, a small amount of the drug is **metabolized by cytochrome P450** enzymes (including subtype 2E1) **into the toxic metabolite** N-acetyl-p-benzoquinone imine (NAPQI). When acetaminophen dosage is appropriate, NAPQI is conjugated by glutathione into a nontoxic compound and eliminated in the urine. However, an acetaminophen overdose **depletes intrahepatic glutathione**, causing the NAPQI level to rise and cause **hepatotoxicity**.

Concomitant **acute ethanol ingestion** can potentially reduce acetaminophen-induced hepatotoxicity. Although ethanol is primarily metabolized by alcohol dehydrogenase, it can also be converted to acetaldehyde by cytochrome P450 2E1. Through **competitive inhibition** of cytochrome P450 2E1, ethanol can decrease metabolism of acetaminophen to NAPQI and therefore **decrease NAPQI concentrations**.

Notably, although some of these patients may experience less hepatotoxicity from acetaminophen overdose than expected, the amount of ethanol that confers this protective effect is unknown and ethanol should therefore not be considered an antidote for acetaminophen toxicity. Moreover, ethanol itself can cause hepatotoxicity when consumed excessively.

(Choices B and E) In contrast to acute ethanol ingestion, chronic consumption can lead to nutritional deficiencies and chronic oxidative damage that decrease intrahepatic glutathione synthesis. In addition, cytochrome P450 2E1 activity is upregulated by chronic ethanol use. As a result chronic alcohol consumption increases NAPQI concentrations and the risk of hepatotoxicity during an acetaminophen overdose.

(Choice C) Impairment of glucuronidation would decrease conversion of acetaminophen to nontoxic metabolites and increase the amount of acetaminophen converted to NAPQI, worsening hepatotoxicity.

(Choice D) Activated charcoal is a highly absorbent powder that binds to drugs and toxins, including acetaminophen, and is sometimes used to limit intestinal absorption after an overdose. However, ethanol does not affect intestinal absorption of acetaminophen.

Educational objective:
Acetaminophen and ethanol are metabolized by the same cytochrome P450 enzyme. Through competitive inhibition, acute (not chronic) ingestion of ethanol can lead to decreased conversion of acetaminophen to N-acetyl-p-benzoquinone imine (a toxic metabolite), potentially reducing acetaminophen-induced hepatotoxicity. However,

https://t.me/USMLEWorldStep1

benzoquinone imine (NAPQI). When acetaminophen dosage is appropriate, NAPQI is conjugated by glutathione into a nontoxic compound and eliminated in the urine. However, an acetaminophen overdose **depletes intrahepatic glutathione**, causing the NAPQI level to rise and cause **hepatotoxicity**.

Concomitant **acute ethanol ingestion** can potentially reduce acetaminophen-induced hepatotoxicity. Although ethanol is primarily metabolized by alcohol dehydrogenase, it can also be converted to acetaldehyde by cytochrome P450 2E1. Through **competitive inhibition** of cytochrome P450 2E1, ethanol can decrease metabolism of acetaminophen to NAPQI and therefore **decrease NAPQI concentrations**.

Notably, although some of these patients may experience less hepatotoxicity from acetaminophen overdose than expected, the amount of ethanol that confers this protective effect is unknown and ethanol should therefore not be considered an antidote for acetaminophen toxicity. Moreover, ethanol itself can cause hepatotoxicity when consumed excessively.

(Choices B and E) In contrast to acute ethanol ingestion, chronic consumption can lead to nutritional deficiencies and chronic oxidative damage that decrease intrahepatic glutathione synthesis. In addition, cytochrome P450 2E1 activity is upregulated by chronic ethanol use. As a result chronic alcohol consumption increases NAPQI concentrations and the risk of hepatotoxicity during an acetaminophen overdose.

(Choice C) Impairment of glucuronidation would decrease conversion of acetaminophen to nontoxic metabolites and increase the amount of acetaminophen converted to NAPQI, worsening hepatotoxicity.

(Choice D) Activated charcoal is a highly absorbent powder that binds to drugs and toxins, including acetaminophen, and is sometimes used to limit intestinal absorption after an overdose. However, ethanol does not affect intestinal absorption of acetaminophen.

Educational objective:
Acetaminophen and ethanol are metabolized by the same cytochrome P450 enzyme. Through competitive inhibition, acute (not chronic) ingestion of ethanol can lead to decreased conversion of acetaminophen to N-acetyl-p-benzoquinone imine (a toxic metabolite), potentially reducing acetaminophen-induced hepatotoxicity. However, cytochrome P450 2E1 activity is upregulated by chronic ethanol use. As a result chronic alcohol consumption increases NAPQI concentrations and the risk of hepatotoxicity during an acetaminophen overdose.

References

https://t.me/USMLEWorldStep1

Acetaminophen is a commonly used antipyretic and analgesic drug that is metabolized by the liver. Although it is mostly converted to nontoxic metabolites by sulfation and glucuronidation, a small amount of the drug is **metab** benzo into a **intrah**

Conco ethano cytoch metab

Notabl expect consid consu

(Choi and ch activity concer

(Choi and in

(Choi acetar affect

Educa Acetar inhibition, acute (not chronic) ingestion of ethanol can lead to decreased conversion of acetaminophen to N-acetyl-p-benzoquinone imine (a toxic metabolite), potentially reducing acetaminophen-induced hepatotoxicity. However,

Exhibit Display

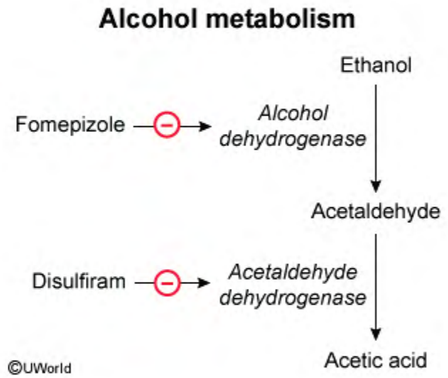

Zoom In Zoom Out Reset New | Existing My Notebook

https://t.me/USMLEWorldStep1

A 67-year-old man comes to the emergency department due to progressive fever and lethargy. The patient has also had severe right shoulder and abdominal pain, nausea, and vomiting for the past 2 days. He had an appendectomy during childhood and a pacemaker placed 10 years ago for symptomatic sinus bradycardia. He has no other medical problems and takes no medications. The patient does not use tobacco but drinks an occasional beer. Temperature is 38.4 C (101.1 F), blood pressure is 80/50 mm Hg, and pulse is 120/min and regular. Abdominal examination shows generalized tenderness with rebound tenderness. Right shoulder examination is normal. Upright chest x-ray is shown below.

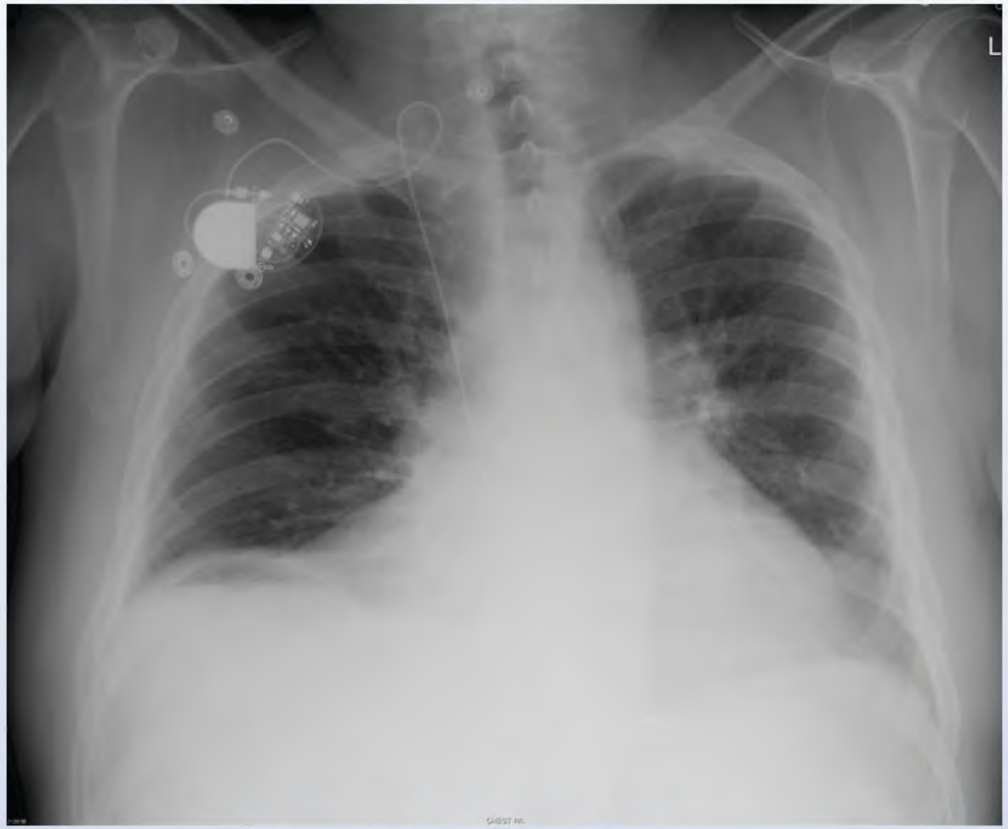

Which of the following is the most likely cause of this patient's condition?

https://t.me/USMLEWorldStep1

A 67-year-old man comes to the emergency department due to progressive fever and lethargy. The patient has also h
appen
has no
occasi
regula
exami

Exhibit Display

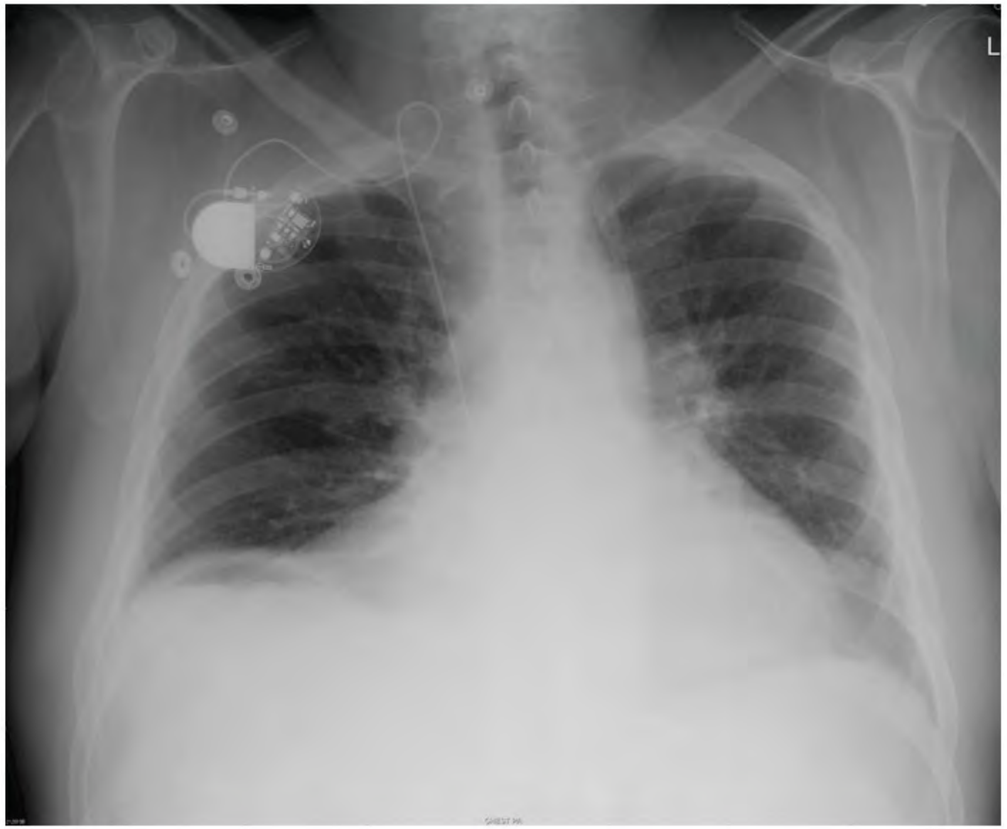

Zoom In | Zoom Out | Reset | New | Existing | My Notebook

Which of the following is the most likely cause of this patient's condition?

https://t.me/USMLEWorldStep1

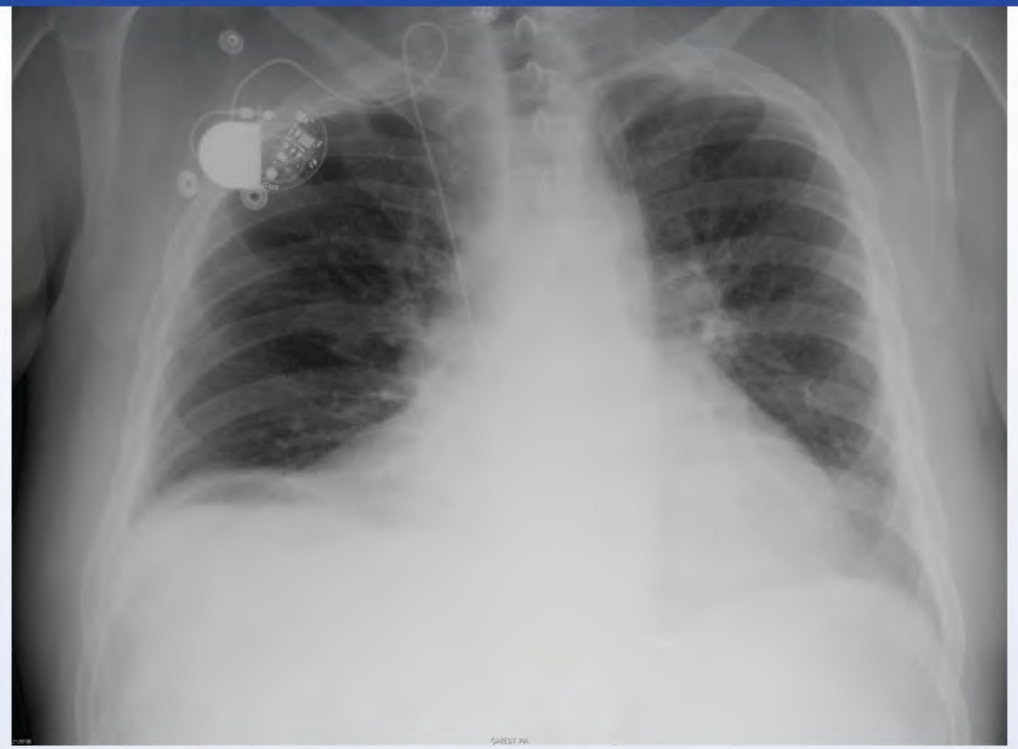

Which of the following is the most likely cause of this patient's condition?

- A. Acute cholecystitis
- B. Acute pancreatitis
- C. Nephrolithiasis
- D. Perforated viscus
- E. Small bowel obstruction

Submit

https://t.me/USMLEWorldStep1

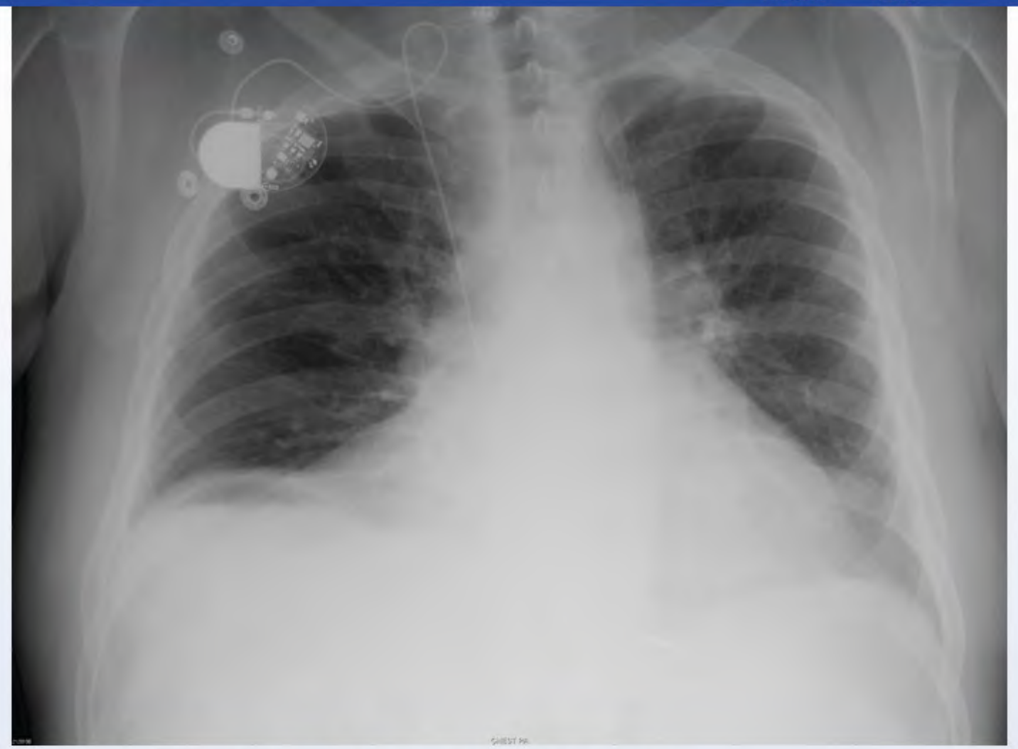

Which of the following is the most likely cause of this patient's condition?

- A. Acute cholecystitis (24%)
- ✗ B. Acute pancreatitis (13%)
- C. Nephrolithiasis (0%)
- ✓ D. Perforated viscus (57%)
- E. Small bowel obstruction (4%)

Incorrect
Correct answer
D

57%
Answered correctly

01 min, 07 secs
Time Spent

2023
Version

https://t.me/USMLEWorldStep1

Explanation

Exhibit Display

Pneumoperitoneum on upright chest x-ray

©UWorld

Zoom In | Zoom Out | Reset | New | Existing | My Notebook

This p
perfor
duode
ulcers.

Contai
bacter
peritor
freque
multipl
the bra

(Choi
should
associated with intraabdominal free air.

(Choice B) Acute pancreatitis causes epigastric abdominal pain that may be referred to the back. X-ray findings

https://t.me/USMLEWorldStep1

©UWorld

This patient's upright chest x-ray demonstrates **free air** under the diaphragm (**pneumoperitoneum**), likely due to **perforation** of a hollow abdominal viscus. The most common cause of pneumoperitoneum is a perforated duodenal ulcer, but perforation can occur anywhere along the gastrointestinal (or female reproductive) tract due to ulcers, tumors, trauma, or iatrogenic causes (eg, endoscopy, surgery).

Contamination of the sterile peritoneal cavity with bowel contents leads to chemical (acid or chyme-related) or bacterial **peritonitis**, which, if left untreated, can progress to sepsis and death. Diffuse irritation of the parietal peritoneum results in severe abdominal pain with **rigidity** and **rebound tenderness**. **Shoulder pain** is another frequent finding and reflects referred pain from diaphragmatic irritation. Referred pain is due to convergence of multiple nociceptors (visceral and somatic) onto a single secondary neuron within the spinal cord, which causes the brain to misinterpret visceral pain as arising from a body surface.

(Choice A) Other common causes of abdominal pain with associated diaphragmatic irritation and referred shoulder pain include acute cholecystitis/biliary colic and splenic lacerations. However, these would not be associated with intraabdominal free air.

(Choice B) Acute pancreatitis causes epigastric abdominal pain that may be referred to the back. X-ray findings are often normal, although a localized ileus near the inflammed pancreas (sentinel loop sign) may be seen.

(Choice C) Nephrolithiasis typically presents with colicky flank pain that is referred to the groin. Radiopaque stones (calcium, struvite, and cystine) may be visualized on plain radiography.

(Choice E) Small bowel obstruction causes poorly localized, constant abdominal pain, which can be referred to the epigastrium. Plain radiography demonstrates dilation of the small bowel with air fluid levels; free air is not seen in the absence of perforation.

Educational objective:
Pneumoperitoneum is air or gas in the peritoneal cavity; it can be seen as free air under the diaphragm in an upright chest x-ray. The most common cause is a perforated duodenal ulcer, but perforation can occur anywhere along the gastrointestinal (or female reproductive) tract. Subsequent peritonitis can lead to diffuse abdominal pain with rebound and guarding, sometimes with referred shoulder pain due to diaphragmatic irritation.

https://t.me/USMLEWorldStep1

duodenal ulcer, but perforation can occur anywhere along the gastrointestinal (or female reproductive) tract due to ulcers, tumors, trauma, or iatrogenic causes (eg, endoscopy, surgery).

Contai
bacter
peritor
freque
multipl
the bra

(Choi
should
associ

(Choi
are oft

(Choi
stones

(Choi
the ep
in the

Educa
Pneun
upright
along
with re

Anatom
Subject

Exhibit Display

Nephrolithiasis

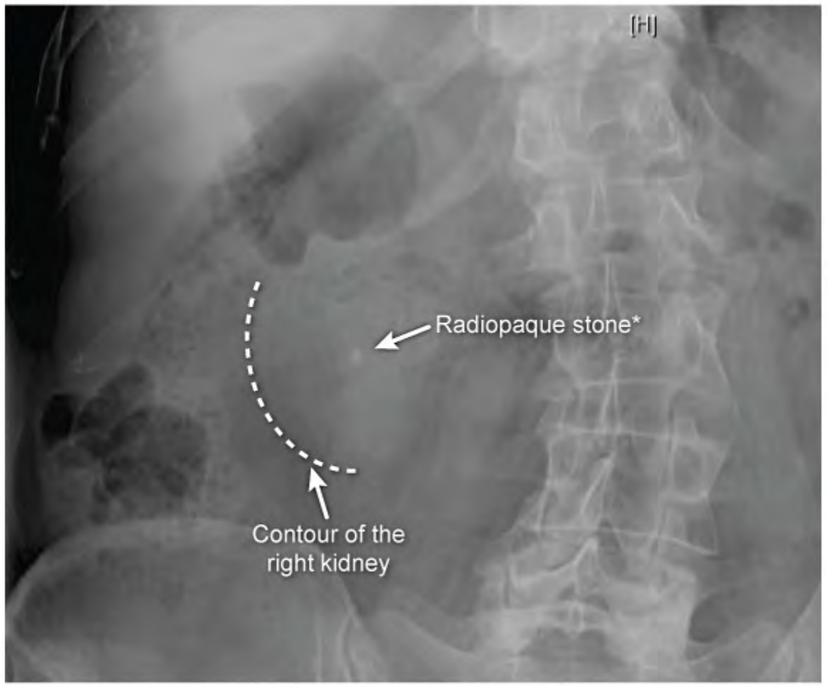

*Calcium containing stones: calcium oxalate and phosphate, struvite (usually mixed with calcium phosphate)

©UWorld

Zoom In | Zoom Out | Reset | New | Existing | My Notebook

Copyright © UWorld. All rights reserved.

https://t.me/USMLEWorldStep1

duodenal ulcer, but perforation can occur anywhere along the gastrointestinal (or female reproductive) tract due to ulcers, tumors, trauma, or iatrogenic causes (eg, endoscopy, surgery).

Contai
bacter
peritor
freque
multipl
the bra

(Choi
should
associ

(Choi
are oft

(Choi
stones

(Choi
the ep
in the

Educa
Pneun
upright
along
with re

Anatom
Subject

Exhibit Display

Zoom In | Zoom Out | Reset | New | Existing | My Notebook

Copyright © UWorld. All rights reserved.

https://t.me/USMLEWorldStep1

Biochemistry researchers are investigating the speed at which various carbohydrates are metabolized within the liver. They hypothesize that different monosaccharides delivered to the liver have different rates of intracellular metabolism. Which of the following substances is most likely to have the fastest rate of metabolism in the glycolytic pathway?

- A. Fructose-1-phosphate
- B. Galactose-1-phosphate
- C. Glucose-1-phosphate
- D. Glucose-6-phosphate
- E. Mannose-6-phosphate

Submit

https://t.me/USMLEWorldStep1

Biochemistry researchers are investigating the speed at which various carbohydrates are metabolized within the liver. They hypothesize that different monosaccharides delivered to the liver have different rates of intracellular metabolism. Which of the following substances is most likely to have the fastest rate of metabolism in the glycolytic pathway?

- ✓ A. Fructose-1-phosphate (39%)
- B. Galactose-1-phosphate (1%)
- C. Glucose-1-phosphate (11%)
- D. Glucose-6-phosphate (45%)
- E. Mannose-6-phosphate (1%)

Correct

39% Answered correctly

03 secs Time Spent

2023 Version

Explanation

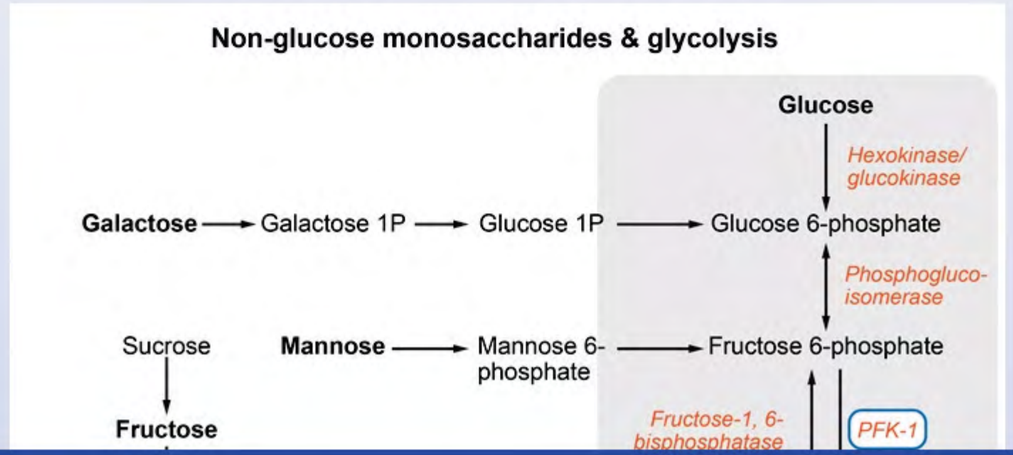

https://t.me/USMLEWorldStep1

Biochemistry researchers are investigating the speed at which various carbohydrates are metabolized within the liver. T
metab
glycoly

Cor

Expl

Exhibit Display

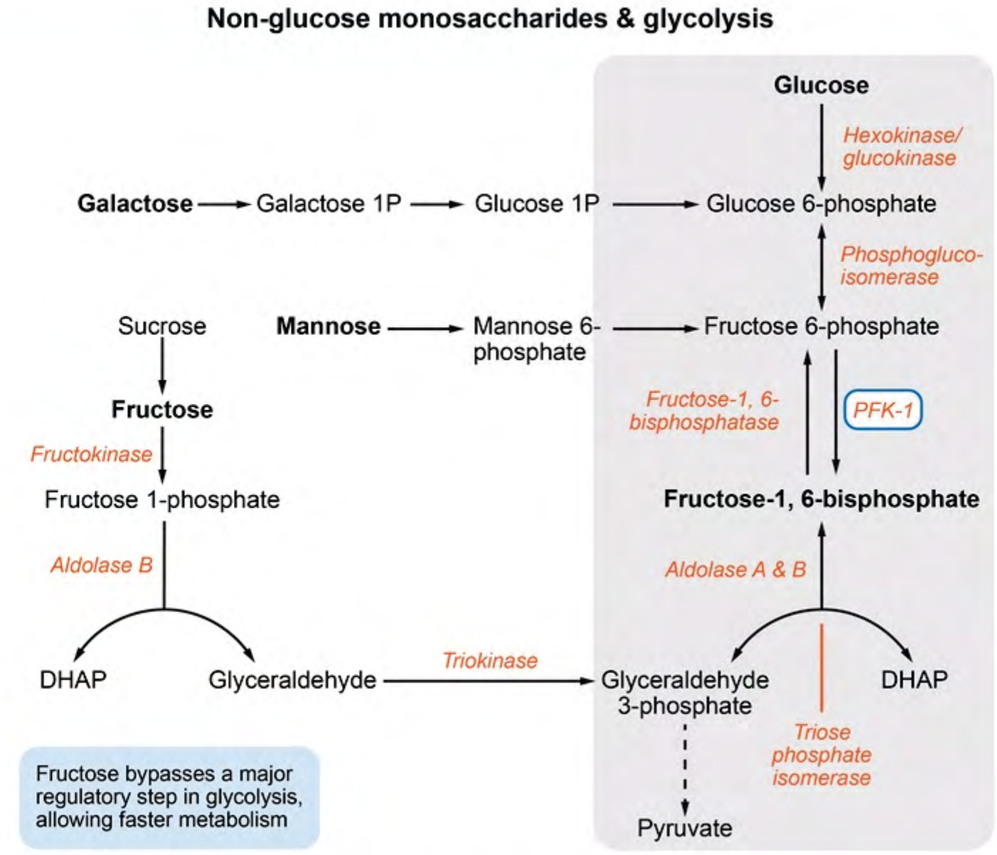

Zoom In | Zoom Out | Reset | New | Existing | My Notebook

Fructose
Fructose-1, 6-bisphosphatase
PFK-1

https://t.me/USMLEWorldStep1

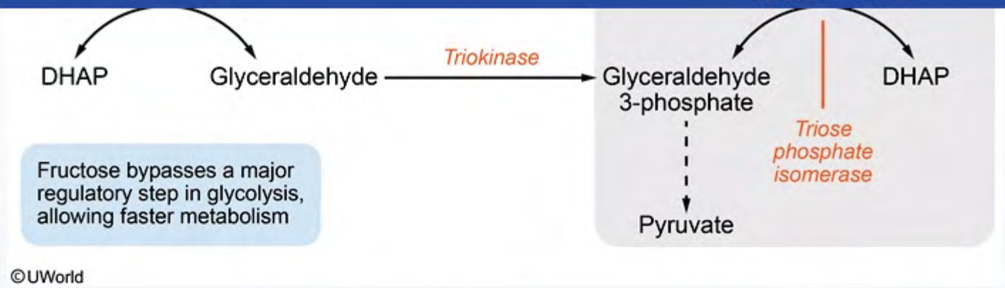

©UWorld

Non-glucose monosaccharides (eg, galactose, mannose, fructose) enter the glycolytic pathway at different points as **intermediates of glycolysis**. Of these, **fructose** is the only one whose metabolites **bypass phosphofructokinase**, one of the key enzymes involved in regulating the rate of glycolysis. As a result, fructose is metabolized by the liver faster than the other monosaccharides and is rapidly cleared from the bloodstream following dietary absorption.

Metabolism of fructose in the liver begins with phosphorylation by fructokinase to **fructose-1-phosphate (F1P)**. Aldolase B can use both fructose-1,6-bisphosphate and F1P as substrates; it converts F1P into **dihydroxy acetone phosphate (DHAP)** and **glyceraldehyde**. Glyceraldehyde can be either phosphorylated to glyceraldehyde-3-phosphate by triokinase or converted to DHAP. DHAP is converted by triose phosphate isomerase to glyceraldehyde-3-phosphate, which continues down the glycolytic pathway.

(Choices B, C, D, and E) Galactose-1-phosphate, glucose-1-phosphate, glucose-6-phosphate, and mannose-6-phosphate enter glycolysis upstream of phosphofructokinase, a major rate-limiting enzyme of glycolysis. This slows down the rate of their metabolism relative to fructose and its metabolites (eg, F1P).

Educational objective:
Dietary fructose is phosphorylated in the liver to F1P and is rapidly metabolized because it bypasses PFK-1, the major rate-limiting enzyme of glycolysis. Other sugars (eg, glucose, galactose, mannose) enter glycolysis prior to PFK-1 and as a result are metabolized more slowly.

Biochemistry	Gastrointestinal & Nutrition	Glycolysis
Subject	System	Topic

Copyright © UWorld. All rights reserved.

https://t.me/USMLEWorldStep1

A newborn boy is examined in the nursery shortly after birth. He was born at term by vaginal delivery to a 40-year-old woman who did not receive prenatal care. Temperature is 36.7 C (98 F), pulse is 132/min, and respirations are 38/min. Examination shows slanted palpebral fissures, epicanthal folds, thick nuchal folds, and a single palmar crease. The patient has a large, reducible midline abdominal protrusion covered by skin that is more pronounced when he cries. The umbilical stump is at the center of the protrusion. Which of the following is the most likely cause of this patient's abdominal finding?

- A. Failure of the extraembryonic gut to return to the abdominal cavity
- B. Incomplete closure of the umbilical ring
- C. Incomplete recanalization of the fetal intestinal tract
- D. Incomplete rotation of the midgut in utero
- E. Persistent processus vaginalis

Submit

https://t.me/USMLEWorldStep1

A newborn boy is examined in the nursery shortly after birth. He was born at term by vaginal delivery to a 40-year-old woman who did not receive prenatal care. Temperature is 36.7 C (98 F), pulse is 132/min, and respirations are 38/min. Examination shows slanted palpebral fissures, epicanthal folds, thick nuchal folds, and a single palmar crease. The patient has a large, reducible midline abdominal protrusion covered by skin that is more pronounced when he cries. The umbilical stump is at the center of the protrusion. Which of the following is the most likely cause of this patient's abdominal finding?

- A. Failure of the extraembryonic gut to return to the abdominal cavity (37%)
- ✓ B. Incomplete closure of the umbilical ring (46%)
- C. Incomplete recanalization of the fetal intestinal tract (7%)
- D. Incomplete rotation of the midgut in utero (4%)
- E. Persistent processus vaginalis (3%)

Correct

46% Answered correctly

03 secs Time Spent

2023 Version

Explanation

Pediatric abdominal wall defects		
Diagnosis	**Pathophysiology**	**Clinical features**
Congenital umbilical hernia	• Incomplete closure of umbilical ring (fascial opening)	• Benign, reducible protrusion • Defect covered by skin • Midline (umbilical cord at apex)
		• Sac containing bowel ± other abdominal organs

https://t.me/USMLEWorldStep1

Pediatric abdominal wall defects		
Diagnosis	**Pathophysiology**	**Clinical features**
Congenital umbilical hernia	• Incomplete closure of umbilical ring (fascial opening)	• Benign, reducible protrusion • Defect covered by skin • Midline (umbilical cord at apex)
Omphalocele	• Abnormal gut rotation without physiologic reduction back into abdominal cavity	• Sac containing bowel ± other abdominal organs • Defect covered by peritoneum (no skin, fascia, muscle) • Midline (umbilical cord at apex)
Gastroschisis	• Full-thickness abdominal wall defect	• Eviscerated bowel • Not covered by membrane • Located to the right of midline/umbilicus

This patient's abdominal examination is consistent with a congenital umbilical hernia. Normally, the umbilical ring (ie, the congenital fascial opening for the umbilical cord) closes and forms the linea alba, a midline band of fibrous tissue. **Umbilical hernias** are caused by an **incomplete closure of the umbilical ring**, thereby allowing protrusion of bowel through the abdominal musculature. This generally benign condition is often an isolated defect, but patients with certain genetic conditions are more likely to develop an umbilical hernia, as in this newborn with features consistent with Down syndrome (eg, palpebral fissures, epicanthal folds, single palmar crease).

Almost all congenital umbilical hernias are **reducible** and **asymptomatic**. They often appear larger and more prominent with increased abdominal pressure (eg, crying). Incarceration and strangulation are very rare.

Most umbilical hernias **resolve spontaneously** in the first few years of life as the fascial layers fuse.

(Choice A) During midgut development in the first trimester, the abdominal contents undergo physiologic herniation, followed by a rotation of the midgut and physiologic reduction. Failure of this reduction may contribute

https://t.me/USMLEWorldStep1

This patient's abdominal examination is consistent with a congenital umbilical hernia. Normally, the umbilical ring (ie, the congenital fascial opening for the umbilical cord) closes and forms the linea alba, a midline band of fibrous tissue. **Umbilical hernias** are caused by an **incomplete closure of the umbilical ring**, thereby allowing protrusion of bowel through the abdominal musculature. This generally benign condition is often an isolated defect, but patients with certain genetic conditions are more likely to develop an umbilical hernia, as in this newborn with features consistent with Down syndrome (eg, palpebral fissures, epicanthal folds, single palmar crease).

Almost all congenital umbilical hernias are **reducible** and **asymptomatic**. They often appear larger and more prominent with increased abdominal pressure (eg, crying). Incarceration and strangulation are very rare.

Most umbilical hernias **resolve spontaneously** in the first few years of life as the fascial layers fuse.

(Choice A) During midgut development in the first trimester, the abdominal contents undergo physiologic herniation, followed by a rotation of the midgut and physiologic reduction. Failure of this reduction may contribute to omphalocele, which presents as a midline herniation of abdominal contents contained within a thin, membranous sac. It is not covered by skin, in contrast to this patient.

(Choice C) Midgut development in the first trimester involves a physiologic occlusion of the intestinal lumen followed by recanalization. Failure of recanalization results in duodenal atresia, which is associated with Down syndrome. However, symptoms include vomiting, often bilious, in the first 24 hours of life.

(Choice D) Malrotation results from an incomplete rotation of the midgut prior to physiologic reduction into the abdominal cavity; malrotation alone is asymptomatic. Its main complication is volvulus (intestinal torsion), which results in bowel ischemia and necrosis from constriction of the blood supply. In contrast to this patient, volvulus typically presents with bilious emesis in the first month of life.

(Choice E) Congenital inguinal hernias develop when the processus vaginalis, an outpouching of the peritoneum, fails to obliterate, allowing bowel contents into the inguinal canal. Inguinal hernias are more prominent with increased abdominal pressure, but they present as a mass in the groin, not the umbilicus.

Educational objective:
Umbilical hernias are caused by a defect in the linea alba and present as protrusions at the umbilicus that are soft, reducible, and benign. They can occur in isolation or in association with other conditions (eg, Down syndrome).

https://t.me/USMLEWorldStep1

skin, fascia, muscle)

- Midline (umbilical cord at apex)

Exhibit Display

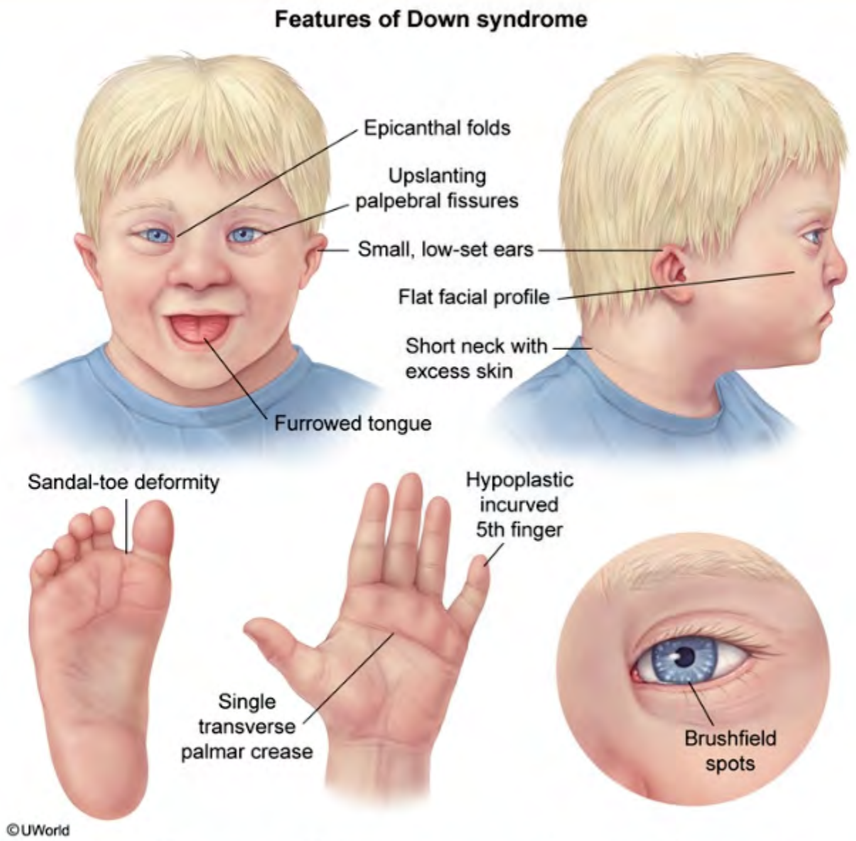

Zoom In | Zoom Out | Reset | New | Existing | My Notebook

This p
(ie, the
tissue.
protrus
but pa
feature

Almos
promi

Most u

(Choi
hernia
to omp
memb

(Choi
followe
syndro

(Choi
abdominal cavity; malrotation alone is asymptomatic. Its main complication is volvulus (intestinal torsion), which results in bowel ischemia and necrosis from constriction of the blood supply. In contrast to this patient, volvulus

https://t.me/USMLEWorldStep1

skin, fascia, muscle)
- Midline (umbilical cord at apex)

This p
(ie, the
tissue.
protrus
but pa
feature

Almos
promir

Most u

(Choi
hernia
to omp
memb

(Choi
followe
syndro

(Choi
abdom
result

Exhibit Display

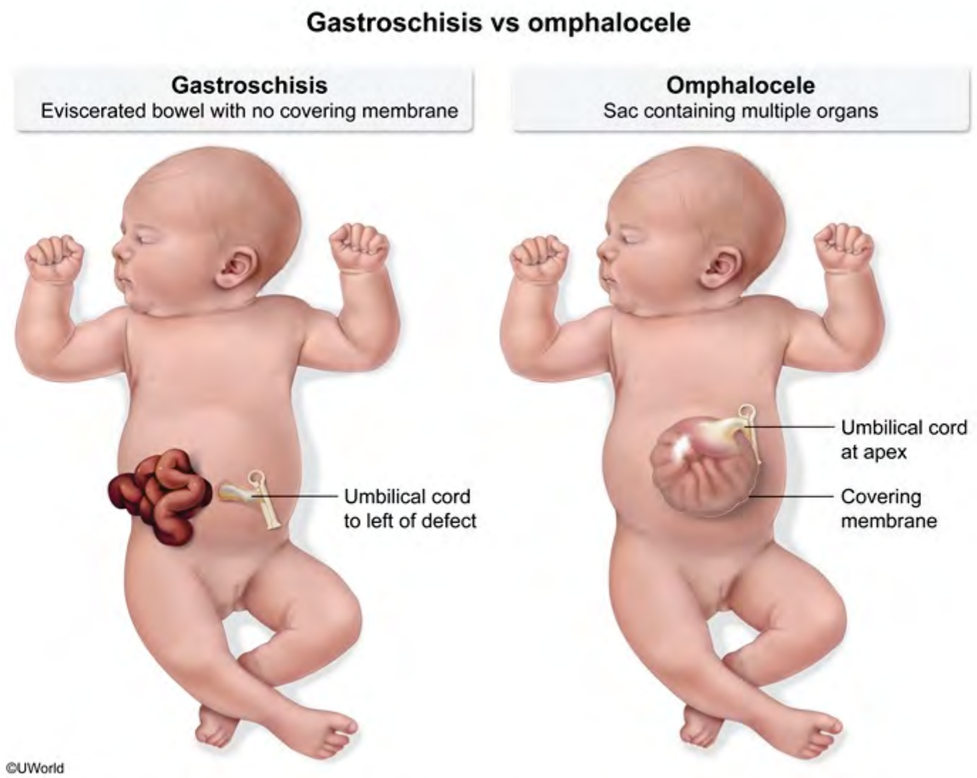

Zoom In Zoom Out Reset New | Existing My Notebook

https://t.me/USMLEWorldStep1

Show all

A 25-year-old woman comes to the office due to progressive fatigue and dizziness for several months. She also has intermittent loose stools and abdominal cramps but no hematochezia, melena, vomiting, or abnormal menses. Vital signs are within normal limits. Conjunctival pallor is present. The abdomen is mildly distended but nontender. Laboratory evaluation reveals anemia and a low ferritin level. Fecal occult blood testing is negative. An upper endoscopy is performed and reveals no visible abnormalities of the stomach or duodenum, although biopsies of the duodenum are significant for intraepithelial lymphocytosis. Which of the following is the most likely cause of this patient's condition?

- A. Brush border enzyme deficiency
- B. *Helicobacter pylori* infection
- C. HLA-associated autoimmune disorder
- D. Irritable bowel syndrome
- E. Nonsteroidal anti-inflammatory drugs

Submit

https://t.me/USMLEWorldStep1
Show all

A 25-year-old woman comes to the office due to progressive fatigue and dizziness for several months. She also has intermittent loose stools and abdominal cramps but no hematochezia, melena, vomiting, or abnormal menses. Vital signs are within normal limits. Conjunctival pallor is present. The abdomen is mildly distended but nontender. Laboratory evaluation reveals anemia and a low ferritin level. Fecal occult blood testing is negative. An upper endoscopy is performed and reveals no visible abnormalities of the stomach or duodenum, although biopsies of the duodenum are significant for intraepithelial lymphocytosis. Which of the following is the most likely cause of this patient's condition?

- ✗ A. Brush border enzyme deficiency (11%)
- B. *Helicobacter pylori* infection (8%)
- ✓ C. HLA-associated autoimmune disorder (68%)
- D. Irritable bowel syndrome (9%)
- E. Nonsteroidal anti-inflammatory drugs (1%)

Incorrect
Correct answer
C

68%
Answered correctly

04 secs
Time Spent

2023
Version

Explanation

Celiac disease	
Pathogenesis	• Gluten (gliadin) consumption → immune-mediated small intestine inflammation → chronic malabsorption
	• Abdominal pain

https://t.me/USMLEWorldStep1
Show all

Celiac disease	
Pathogenesis	• Gluten (gliadin) consumption → immune-mediated small intestine inflammation → chronic malabsorption
Symptoms	• Abdominal pain • Diarrhea, flatulence & bloating • Failure to thrive (children) or weight loss • Iron deficiency anemia • Dermatitis herpetiformis
Diagnosis	• Serology: tissue transglutaminase IgA, antiendomysial antibodies • Duodenal biopsy: intraepithelial lymphocytes, villous atrophy, crypt hyperplasia
Associated conditions	• Autoimmune disorders (eg, type 1 diabetes) • Cancer risk: T-cell lymphoma

This patient with loose stools and crampy abdominal pain has **celiac disease**, an **autoimmune disorder** of the small intestine triggered by dietary gluten. Besides intestinal symptoms, celiac disease commonly causes nutrient malabsorption that leads to weight loss, steatorrhea (ie, greasy, malodorous stools), and **deficiency of iron** (eg, anemia, low serum ferritin) and vitamin D (eg, loss of bone density).

Initial testing for celiac disease typically includes an **anti-tissue transglutaminase IgA** assay. The diagnosis is confirmed with duodenal biopsy. The earliest histologic finding is intraepithelial lymphocytosis; crypt hyperplasia and villous blunting develop later as the disorder progresses.

Celiac disease occurs almost exclusively (>99%) in individuals with an **HLA-DQ2 or -DQ8** serotype. These variants must be present on antigen-presenting cells for recognition of deamidated gliadin (a breakdown product of gluten) and induction of the T-cell–mediated response.

https://t.me/USMLEWorldStep1
Show all

small intestine triggered by dietary gluten. Besides intestinal symptoms, celiac disease commonly causes nutrient malabsorption that leads to weight loss, steatorrhea (ie, greasy, malodorous stools), and **deficiency of iron** (eg, anemia, low serum ferritin) and vitamin D (eg, loss of bone density).

Initial testing for celiac disease typically includes an **anti-tissue transglutaminase IgA** assay. The diagnosis is confirmed with duodenal biopsy. The earliest histologic finding is intraepithelial lymphocytosis; crypt hyperplasia and villous blunting develop later as the disorder progresses.

Celiac disease occurs almost exclusively (>99%) in individuals with an **HLA-DQ2 or -DQ8** serotype. These variants must be present on antigen-presenting cells for recognition of deamidated gliadin (a breakdown product of gluten) and induction of the T-cell–mediated response.

(Choice A) Lactose intolerance is caused by a deficiency in lactase, an enzyme located on the small intestine brush border. Although diarrhea is common, lactose intolerance does not cause iron deficiency anemia or intraepithelial lymphocytosis.

(Choices B and E) Both *Helicobacter pylori* and nonsteroidal anti-inflammatory drugs can cause iron deficiency due to chronic upper gastrointestinal blood loss. However, they typically cause gastritis, duodenitis, or peptic ulcer disease, none of which was identified during this patient's endoscopy. Diarrhea, duodenal lymphocytosis, and a negative fecal occult blood test make celiac disease more likely.

(Choice D) Irritable bowel syndrome is a disorder of bowel motility that causes abdominal pain associated with defecation, as well as diarrhea and/or constipation. It does not cause iron deficiency anemia or duodenal intraepithelial lymphocytosis.

Educational objective:
Celiac disease is an autoimmune disorder triggered by dietary gluten that develops almost exclusively in patients with HLA-DQ2 or -DQ8 serotypes. It often causes diarrhea and malabsorption (eg, iron deficiency anemia). The earliest histologic finding is duodenal intraepithelial lymphocytosis; crypt hyperplasia and villous blunting develop later.

References

https://t.me/USMLEWorldStep1
Show all

Associated conditions

- Autoimmune disorders (eg, type 1 diabetes)
- Cancer risk: T-cell lymphoma

Exhibit Display

Celiac sprue

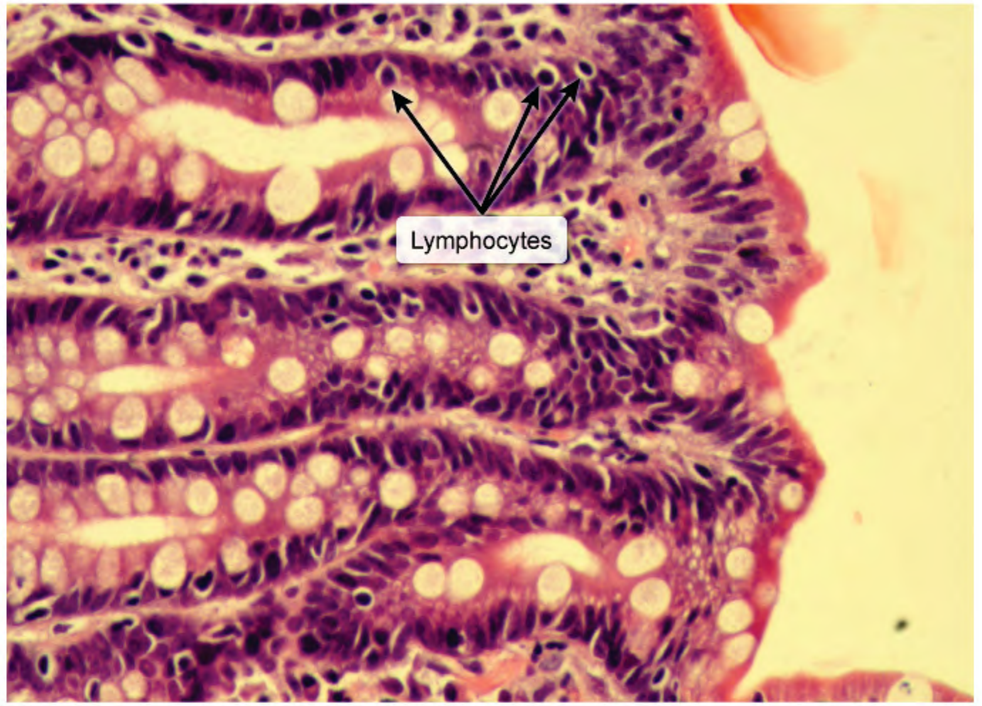

©UWorld

Zoom In | Zoom Out | Reset | New | Existing | My Notebook

This p
small i
malab
anemi

Initial t
confirm
and vi

Celiac
varian
gluten

(Choi
brush
intraep

(Choi
due to
diseas
negati

(Choi
defeca
intraep

Educa

Celiac disease is an autoimmune disorder triggered by dietary gluten that develops almost exclusively in patients with HLA-DQ2 or -DQ8 serotypes. It often causes diarrhea and malabsorption (eg, iron deficiency anemia). The

https://t.me/USMLEWorldStep1

Associated conditions	• Autoimmune disorders (eg, type 1 diabetes) • Cancer risk: T-cell lymphoma

This p
small i
malab
anemi

Initial t
confirm
and vi

Celiac
varian
gluten

(Choi
brush
intraep

(Choi
due to
diseas
negati

(Choi
defeca
intraep

Educa
Celiac
with H

Exhibit Display

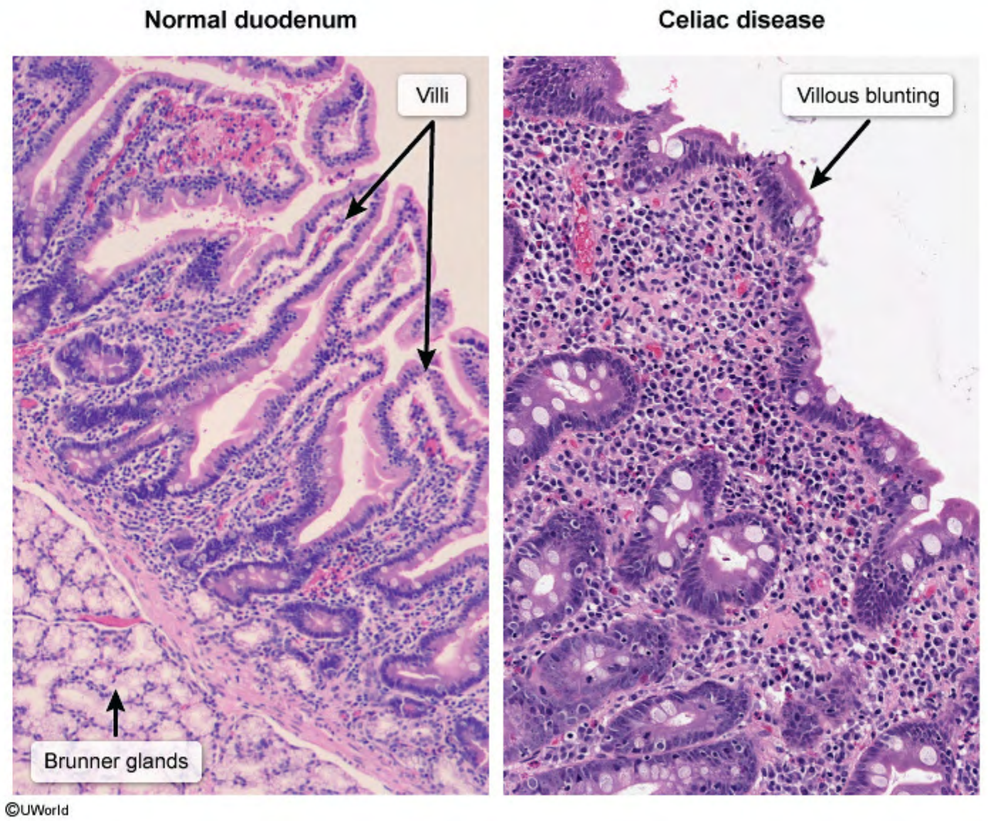

Zoom In | Zoom Out | Reset | New | Existing | My Notebook

https://t.me/USMLEWorldStep1

Associated conditions

- Autoimmune disorders (eg, type 1 diabetes)
- Cancer risk: T-cell lymphoma

Exhibit Display

Chronic gastritis

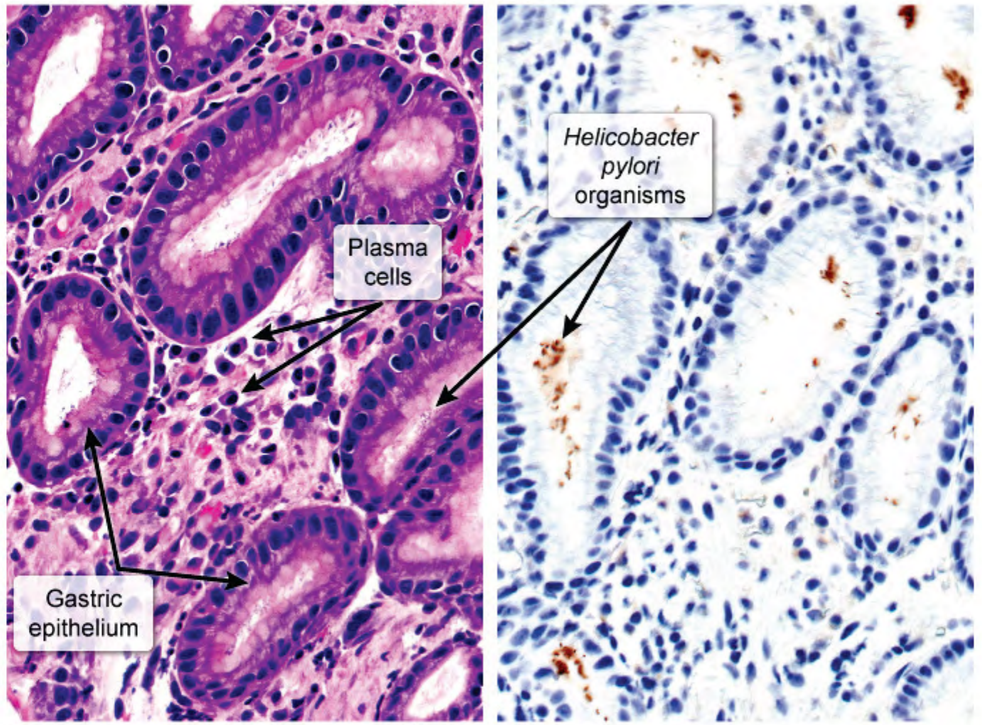

Zoom In | Zoom Out | Reset | New | Existing | My Notebook

This p
small i
malab
anemi

Initial t
confirm
and vi

Celiac
varian
gluten

(Choi
brush
intraep

(Choi
due to
diseas
negati

(Choi
defeca
intraep

Educa
Celiac disease is an autoimmune disorder triggered by dietary gluten that develops almost exclusively in patients with HLA-DQ2 or -DQ8 serotypes. It often causes diarrhea and malabsorption (eg, iron deficiency anemia). The

https://t.me/USMLEWorldStep1

A 32-year-old woman comes to the office due to bloating, intermittent diarrhea, and abdominal cramps. Symptoms have been ongoing for many years and are usually triggered by meals. Past medical history and family history are otherwise unremarkable. Vital signs are within normal limits. BMI is 27 kg/m^2. The patient is well-appearing, and the abdomen is soft and nontender. Laboratory analysis is unremarkable. The patient is diagnosed with irritable bowel syndrome, and it is recommended that she take loperamide and consume an adequate amount of dietary fiber. After reading about her disorder on the internet, the patient decides to manage her symptoms with a strict vegan diet that includes a vitamin B_{12} supplement. This patient is at highest risk for dietary deficiency of which of the following nutrients?

- A. Calcium
- B. Folic acid
- C. Magnesium
- D. Niacin
- E. Thiamine

Submit

https://t.me/USMLEWorldStep1

A 32-year-old woman comes to the office due to bloating, intermittent diarrhea, and abdominal cramps. Symptoms have been ongoing for many years and are usually triggered by meals. Past medical history and family history are otherwise unremarkable. Vital signs are within normal limits. BMI is 27 kg/m^2. The patient is well-appearing, and the abdomen is soft and nontender. Laboratory analysis is unremarkable. The patient is diagnosed with irritable bowel syndrome, and it is recommended that she take loperamide and consume an adequate amount of dietary fiber. After reading about her disorder on the internet, the patient decides to manage her symptoms with a strict vegan diet that includes a vitamin B_{12} supplement. This patient is at highest risk for dietary deficiency of which of the following nutrients?

- ✓ A. Calcium (42%)
- B. Folic acid (24%)
- C. Magnesium (6%)
- D. Niacin (12%)
- E. Thiamine (13%)

Correct

42% Answered correctly

03 secs Time Spent

2023 Version

Explanation

Vegan diet	
Composition	• Plant-based foods: fruits, vegetables, legumes, grains • No animal-derived foods (eg, meat, dairy, egg)

https://t.me/USMLEWorldStep1
Show all

Explanation

Vegan diet	
Composition	• Plant-based foods: fruits, vegetables, legumes, grains • No animal-derived foods (eg, meat, dairy, egg)
Potential benefits	• Lower blood glucose & cholesterol levels • Reduced risk for cardiovascular disease (eg, heart disease, stroke)
Potential nutritional deficiencies	• Common: vitamin B_{12}, vitamin D, calcium • Possible*: iron, zinc
*Increased risk: children (rapid growth requires higher zinc/iron) & young women (menstrual blood loss requires higher iron).	

Individuals who adhere to a **vegan diet** consume only plant-based foods and avoid all meat and other animal-derived products (eg, milk). Adherence to a vegan diet is associated with a decreased risk for type 2 diabetes mellitus, hypercholesterolemia, coronary artery disease, and stroke.

However, most people obtain a significant portion of daily calcium and vitamin D requirements from dairy products; individuals on a vegan diet often consume **less calcium and vitamin D** than nonvegans. Although some vegan products are fortified with calcium and vitamin D, individuals who do not consume these products may require additional supplementation to avoid long-term consequences (eg, **osteoporosis**, bone fractures). **Cobalamin (vitamin B_{12}) deficiency** can also be seen in vegans, leading to megaloblastic anemia and subacute combined degeneration of the dorsal columns of the spinal cord.

(Choice B) Folic acid is found in many plant-based products, including leafy vegetables and legumes. Supplementation is recommended during pregnancy to prevent fetal neural tube defects but is not needed in a vegan diet.

https://t.me/USMLEWorldStep1
Show all

Individuals who adhere to a **vegan diet** consume only plant-based foods and avoid all meat and other animal-derived products (eg, milk). Adherence to a vegan diet is associated with a decreased risk for type 2 diabetes mellitus, hypercholesterolemia, coronary artery disease, and stroke.

However, most people obtain a significant portion of daily calcium and vitamin D requirements from dairy products; individuals on a vegan diet often consume **less calcium and vitamin D** than nonvegans. Although some vegan products are fortified with calcium and vitamin D, individuals who do not consume these products may require additional supplementation to avoid long-term consequences (eg, **osteoporosis**, bone fractures). **Cobalamin (vitamin B_{12}) deficiency** can also be seen in vegans, leading to megaloblastic anemia and subacute combined degeneration of the dorsal columns of the spinal cord.

(Choice B) Folic acid is found in many plant-based products, including leafy vegetables and legumes. Supplementation is recommended during pregnancy to prevent fetal neural tube defects but is not needed in a vegan diet.

(Choice C) Magnesium is found in almost all foods. Hypomagnesemia can cause neuromuscular excitability (eg, tetany) and arrythmias but is usually related to fluid losses (eg, diarrhea, diuretic use) or heavy alcohol use rather than dietary inadequacy.

(Choice D) Niacin deficiency can lead to pellagra, which is characterized by diarrhea, dermatitis, and possible dementia. Deficiency usually occurs in severely malnourished individuals (eg, alcohol use disorder, anorexia nervosa); however, niacin is plentiful in many vegetables and deficiency is uncommon in a vegan diet.

(Choice E) Thiamine is found in many vegan products, including legumes, brown rice, and whole-grain cereals. Thiamine deficiency is most common in those with alcohol use disorder and leads to Wernicke-Korsakoff syndrome (oculomotor dysfunction, ataxia, memory loss).

Educational objective:
Individuals on a vegan diet are at increased risk for deficiencies in calcium and vitamin D, which may increase the risk for osteoporosis and bone fractures. Cobalamin (vitamin B_{12}) deficiency can also occur.

https://t.me/USMLEWorldStep1
Show all

A 72-year-old man comes to the office due to watery diarrhea and abdominal cramps. The symptoms began several days after he started chemotherapy for metastatic colon cancer. He denies hematochezia, melena, or bulky, foul-smelling stools. Vital signs are within normal limits, and physical examination is unremarkable. Laboratory testing reveals no electrolyte abnormalities and no leukocytosis. Stool testing is negative for infection and fecal occult blood. The patient is advised to take a medication after each loose stool. The medication works by inhibiting the release of acetylcholine in the intestinal wall but does not cross the blood-brain barrier. Which of the following is the most likely medication prescribed for this patient?

- A. Aprepitant
- B. Bismuth subsalicylate
- C. Fentanyl
- D. Loperamide
- E. Neostigmine
- F. Octreotide

Submit

https://t.me/USMLEWorldStep1

A 72-year-old man comes to the office due to watery diarrhea and abdominal cramps. The symptoms began several days after he started chemotherapy for metastatic colon cancer. He denies hematochezia, melena, or bulky, foul-smelling stools. Vital signs are within normal limits, and physical examination is unremarkable. Laboratory testing reveals no electrolyte abnormalities and no leukocytosis. Stool testing is negative for infection and fecal occult blood. The patient is advised to take a medication after each loose stool. The medication works by inhibiting the release of acetylcholine in the intestinal wall but does not cross the blood-brain barrier. Which of the following is the most likely medication prescribed for this patient?

- ✗ A. Aprepitant (8%)
- B. Bismuth subsalicylate (5%)
- C. Fentanyl (1%)
- ✓ D. Loperamide (51%)
- E. Neostigmine (18%)
- F. Octreotide (14%)

Incorrect
Correct answer
D

51%
Answered correctly

03 secs
Time Spent

2023
Version

Explanation

Antidiarrheal agents	
Opioid agonists (eg, loperamide,	• Binds to mu opiate receptors in the colonic myenteric plexus, slowing

https://t.me/USMLEWorldStep1

Explanation

Antidiarrheal agents	
Opioid agonists (eg, loperamide, diphenoxylate with atropine, tincture of opium)	• Binds to mu opiate receptors in the colonic myenteric plexus, slowing peristalsis
Bulk forming agents (eg, psyllium, pectin)	• Absorbs water and intraluminal contents to form stool
Bismuth subsalicylate	• Stimulates intestinal fluid absorption and inhibits prostaglandin synthesis (antispasmotic effect)
Octreotide	• Somatostatin analog that reduces secretion of pancreatic and GI hormones
Bile acid sequestrants (eg, cholestyramine)	• Binds bile acid in intestines (used for bile-acid diarrhea)
GI = gastrointestinal.	

This patient with uncomplicated, chemotherapy-induced diarrhea was prescribed **loperamide**. Loperamide is an **opioid agonist** that exerts its antidiarrheal effects by binding to **mu opiate receptors** in the colonic myenteric plexus. This **inhibits acetylcholine release** from myenteric plexus neurons, decreasing activity of the intestinal smooth muscles and **slowing peristalsis**. Transit time within the intestine is prolonged, allowing for increased

https://t.me/USMLEWorldStep1

(eg, cholestyramine)	for bile-acid diarrhea)
GI = gastrointestinal.	

This patient with uncomplicated, chemotherapy-induced diarrhea was prescribed **loperamide**. Loperamide is an **opioid agonist** that exerts its antidiarrheal effects by binding to **mu opiate receptors** in the colonic myenteric plexus. This **inhibits acetylcholine release** from myenteric plexus neurons, decreasing activity of the intestinal smooth muscles and **slowing peristalsis**. Transit time within the intestine is prolonged, allowing for increased water absorption. In addition, the anticholinergic effects also result in decreased secretion from the intestinal epithelia, further reducing stool volume and increasing fecal consistency.

Unlike other opiates (eg, hydrocodone, fentanyl), loperamide undergoes **high first-pass metabolism** and **does not cross the blood-brain barrier**, allowing it to be used without opiate-related adverse events (eg, respiratory depression, sedation) or threat of abuse. The only side effect is constipation, which can be avoided with careful dose titration. Diphenoxylate, another opiate used for diarrhea, is less extensively metabolized and crosses the blood-brain barrier. To discourage abuse, diphenoxylate is typically combined with a small amount of atropine, an anticholinergic medication that results in dry mouth, flushing, pupil dilation, and urinary retention when used in large amounts.

(Choice A) Aprepitant is a neurokinin-1 receptor antagonist used for chemotherapy-related nausea and vomiting, not diarrhea.

(Choice B) Bismuth subsalicylate is frequently used for diarrhea and dyspepsia. Although its mechanism of action is not clearly understood, it stimulates the intestinal absorption of fluid (reducing diarrhea) and inhibits prostaglandin synthesis (reducing hypermotility). It does not inhibit acetylcholine release.

(Choice C) Fentanyl is an opiate commonly used as an analgesic and sedative. Although it causes constipation, it crosses the blood-brain barrier and therefore is not used for diarrhea due to the risk of systemic opiate-related adverse events (eg, respiratory depression, abuse).

(Choice E) Neostigmine is an acetylcholinesterase inhibitor that increases acetylcholine within the synapse. Its cholinergic effects would worsen this patient's diarrhea.

https://t.me/USMLEWorldStep1
Show all

not cross the blood-brain barrier, allowing it to be used without opiate-related adverse events (eg, respiratory depression, sedation) or threat of abuse. The only side effect is constipation, which can be avoided with careful dose titration. Diphenoxylate, another opiate used for diarrhea, is less extensively metabolized and crosses the blood-brain barrier. To discourage abuse, diphenoxylate is typically combined with a small amount of atropine, an anticholinergic medication that results in dry mouth, flushing, pupil dilation, and urinary retention when used in large amounts.

(Choice A) Aprepitant is a neurokinin-1 receptor antagonist used for chemotherapy-related nausea and vomiting, not diarrhea.

(Choice B) Bismuth subsalicylate is frequently used for diarrhea and dyspepsia. Although its mechanism of action is not clearly understood, it stimulates the intestinal absorption of fluid (reducing diarrhea) and inhibits prostaglandin synthesis (reducing hypermotility). It does not inhibit acetylcholine release.

(Choice C) Fentanyl is an opiate commonly used as an analgesic and sedative. Although it causes constipation, it crosses the blood-brain barrier and therefore is not used for diarrhea due to the risk of systemic opiate-related adverse events (eg, respiratory depression, abuse).

(Choice E) Neostigmine is an acetylcholinesterase inhibitor that increases acetylcholine within the synapse. Its cholinergic effects would worsen this patient's diarrhea.

(Choice F) Octreotide is a somatostatin analogue that is sometimes used for refractory chemotherapy-induced diarrhea; however, it exerts its antidiarrheal effect by reducing secretion of pancreatic and gastrointestinal hormones (eg, secretin, gastrin, vasoactive intestinal peptide).

Educational objective:
Loperamide is an opioid agonist that exerts its antidiarrheal effects by binding to mu opiate receptors in the colonic myenteric plexus, which inhibits acetylcholine release, decreases intestinal smooth muscle activity, and slows peristalsis. It undergoes high first-pass metabolism and does not cross the blood-brain barrier, thus avoiding systemic opiate-related adverse events (eg, sedation, respiratory depression).

References

https://t.me/USMLEWorldStep1
Show all

A 32-year-old man with abdominal pain and periodic diarrhea is found to have heme-positive stools. Stool cultures show no growth of pathogenic organisms. Colonoscopy with biopsy of the colonic mucosa is performed. Light microscopy of the tissue sample is shown in the image below.

This patient most likely suffers from which of the following disorders?

- A. Acute appendicitis
- B. Collagenous colitis
- C. Crohn disease
- D. Ischemic colitis
- E. Pseudomembranous colitis
- F. Ulcerative colitis

Submit

https://t.me/USMLEWorldStep1
Show all

A 32-year-old man with abdominal pain and periodic diarrhea is found to have heme-positive stools. Stool cultures show
micros

Exhibit Display

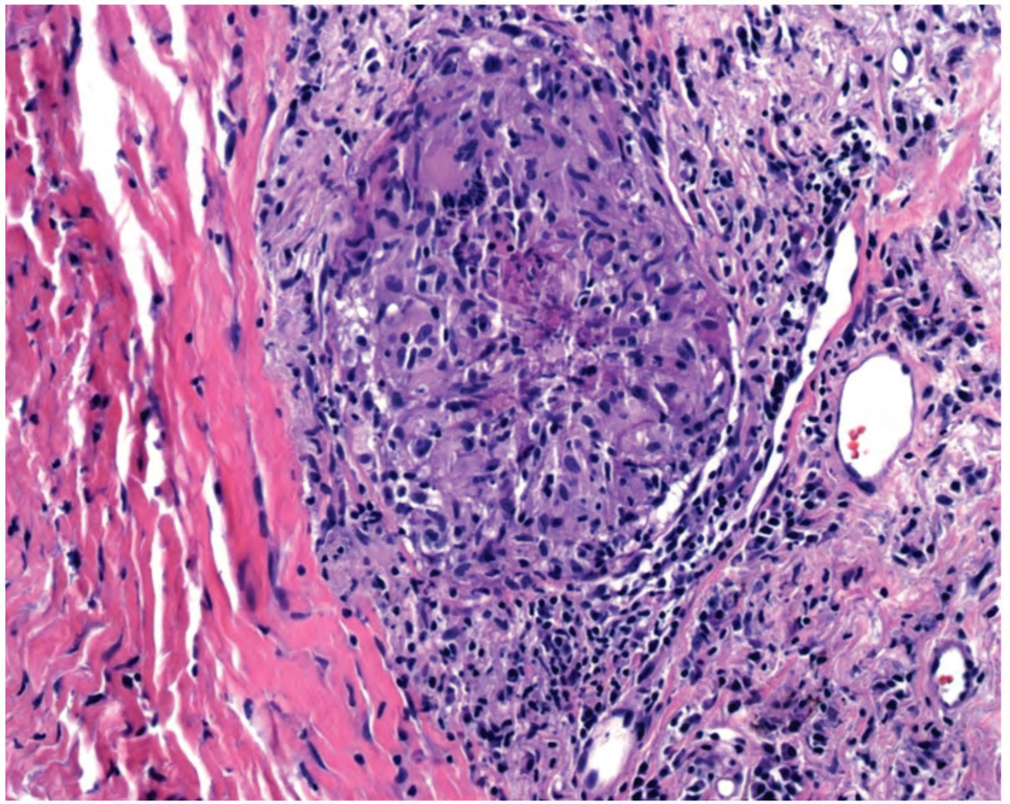

Zoom In Zoom Out Reset New | Existing My Notebook

This p

B. Collagenous colitis

https://t.me/USMLEWorldStep1

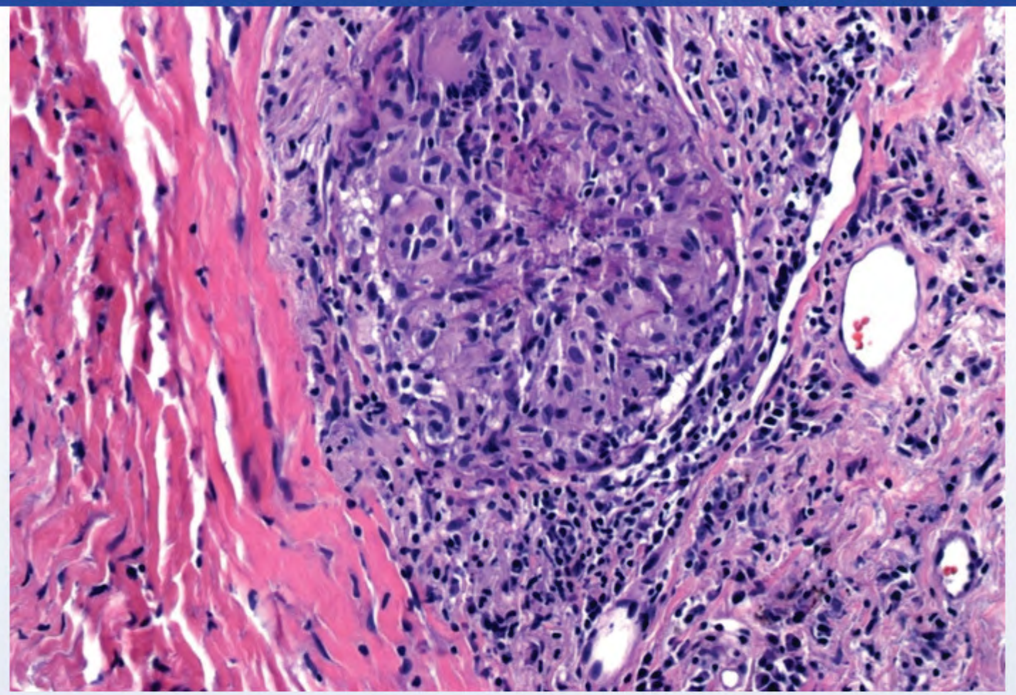

This patient most likely suffers from which of the following disorders?

- A. Acute appendicitis
- B. Collagenous colitis
- C. Crohn disease
- D. Ischemic colitis
- E. Pseudomembranous colitis
- F. Ulcerative colitis

https://t.me/USMLEWorldStep1
Show all

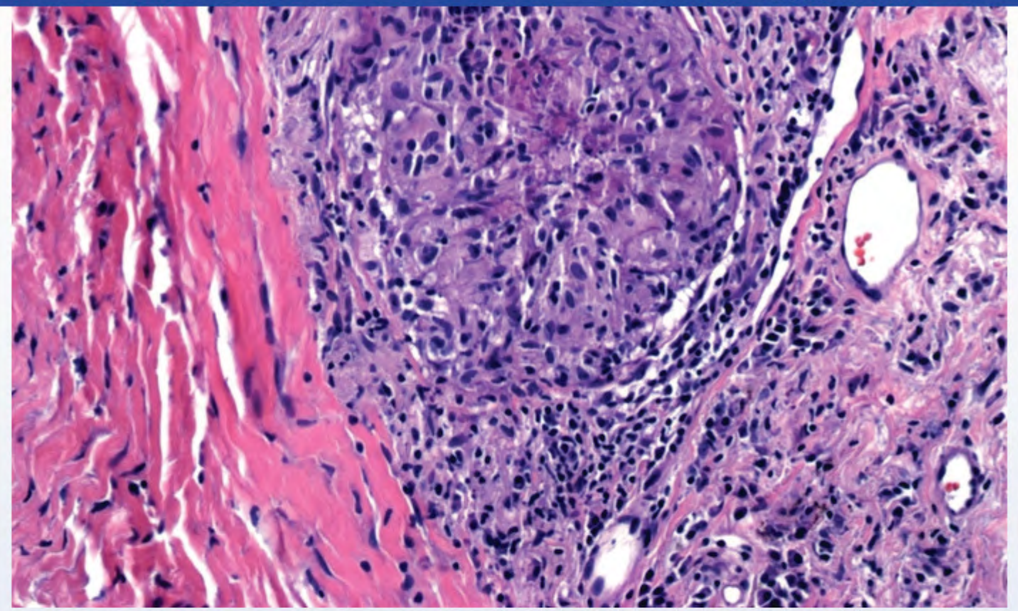

This patient most likely suffers from which of the following disorders?

- A. Acute appendicitis (0%)
- B. Collagenous colitis (3%)
- ✓ C. Crohn disease (75%)
- D. Ischemic colitis (1%)
- E. Pseudomembranous colitis (1%)
- F. Ulcerative colitis (18%)

Correct

75%
Answered correctly

26 secs
Time Spent

2023
Version

https://t.me/USMLEWorldStep1
Show all

Exhibit Display

Noncaseating granuloma

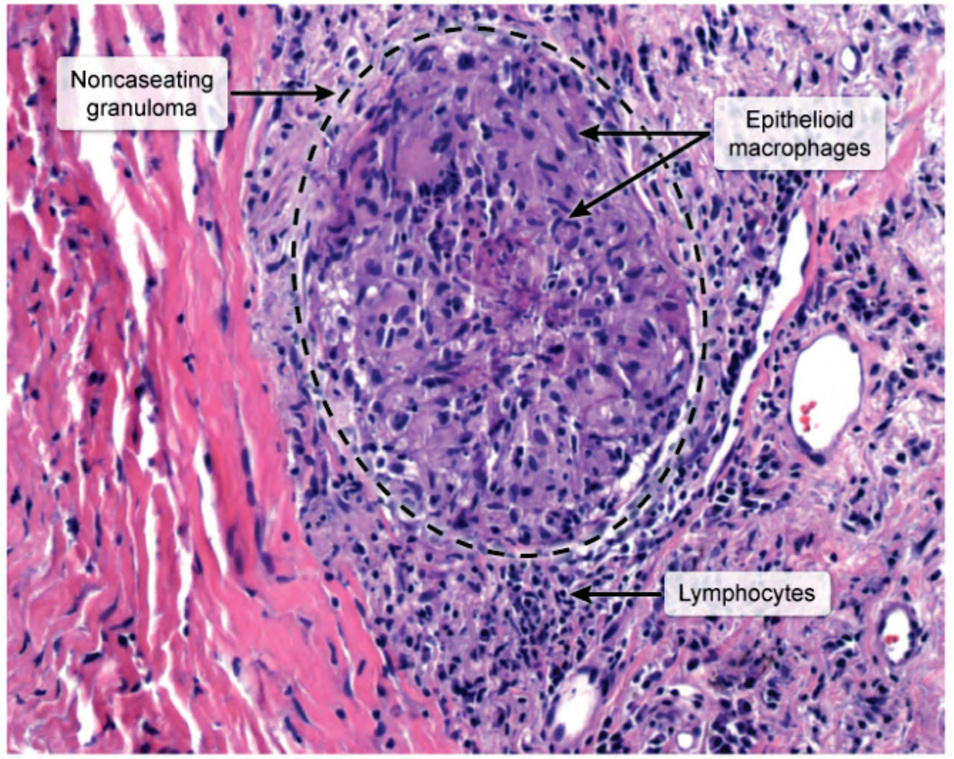

©UWorld

Zoom In | Zoom Out | Reset | New | Existing | My Notebook

https://t.me/USMLEWorldStep1

Show all

©UWorld

This younger patient with abdominal pain, heme-positive stool, and **noncaseating granulomas** (NCGs, pictured above) on microscopy has **Crohn disease** (CD). CD is an inflammatory bowel disease that can cause patchy inflammation throughout the gastrointestinal tract, interspersed with areas of normal bowel (**skip lesions**).

NCGs are often seen in CD and are considered a hallmark of the disease. NCGs are characterized by an accumulation of epithelioid macrophages that frequently form multinucleated giant cells without central necrosis (noncaseating), surrounded by a cuff of lymphocytes. Granulomas are formed in an attempt to wall off an offending agent; in the case of CD this is likely due to an unregulated immune response to gut flora or self-antigens. They can be found in any layer of the intestinal wall, and may also be present in other tissues such as the lymph nodes and skin. Other characteristic histopathologic findings in CD include inflammation involving the entire thickness of the intestinal wall (**transmural inflammation**), distortion of normal mucosal architecture, and Paneth cell metaplasia.

(Choice A) Acute appendicitis presents with periumbilical or right lower quadrant pain and fever. Microscopy shows a dense neutrophilic infiltrate and necrosis of the appendix.

(Choice B) Collagenous (microscopic) colitis typically presents with frequent diarrhea in older women and histology demonstrates thickening of the subepithelial collagen band.

(Choice D) Ischemic colitis is most common in older patients and presents with abdominal pain and bleeding; microscopy shows necrosis, thrombus formation, and hemorrhage.

(Choice E) Pseudomembranous colitis is due to *Clostridioides difficile* infection and presents with watery diarrhea, abdominal pain, and fever. Microscopy shows mucopurulent exudates composed of fibrin, bacteria, and neutrophils.

(Choice F) Ulcerative colitis is another cause of inflammatory bowel disease; histology demonstrates a continuous superficial inflammation affecting the mucosa and submucosa with crypt abscesses (neutrophil collections within glandular lumen) and crypt atrophy. Granulomas do not occur.

https://t.me/USMLEWorldStep1
Show all

(noncaseating), surrounded by a cuff of lymphocytes. Granulomas are formed in an attempt to wall off an offending agent; in the case of CD this is likely due to an unregulated immune response to gut flora or self-antigens. They can be found in any layer of the intestinal wall, and may also be present in other tissues such as the lymph nodes and skin. Other characteristic histopathologic findings in CD include inflammation involving the entire thickness of the intestinal wall (**transmural inflammation**), distortion of normal mucosal architecture, and Paneth cell metaplasia.

(Choice A) Acute appendicitis presents with periumbilical or right lower quadrant pain and fever. Microscopy shows a dense neutrophilic infiltrate and necrosis of the appendix.

(Choice B) Collagenous (microscopic) colitis typically presents with frequent diarrhea in older women and histology demonstrates thickening of the subepithelial collagen band.

(Choice D) Ischemic colitis is most common in older patients and presents with abdominal pain and bleeding; microscopy shows necrosis, thrombus formation, and hemorrhage.

(Choice E) Pseudomembranous colitis is due to *Clostridioides difficile* infection and presents with watery diarrhea, abdominal pain, and fever. Microscopy shows mucopurulent exudates composed of fibrin, bacteria, and neutrophils.

(Choice F) Ulcerative colitis is another cause of inflammatory bowel disease; histology demonstrates a continuous superficial inflammation affecting the mucosa and submucosa with crypt abscesses (neutrophil collections within glandular lumen) and crypt atrophy. Granulomas do not occur.

Educational objective:
Noncaseating granulomas are a hallmark of Crohn disease and can help distinguish it from ulcerative colitis, which does not form granulomas. Histopathology in Crohn disease also demonstrates transmural inflammation, distortion of the normal architecture, and Paneth cell metaplasia.

Pathology	Gastrointestinal & Nutrition	Inflammatory bowel disease
Subject	System	Topic

https://t.me/USMLEWorldStep1
Show all

(noncaseating), surrounded by a cuff of lymphocytes. Granulomas are formed in an attempt to wall off an offending agent; in the case of CD this is likely due to an unregulated immune response to gut flora or self antige
the lyn
entire
Paneth

(Choi
shows

(Choi
histolo

(Choi
micros

(Choi
abdom
neutro

(Choi
superf
glandu

Educa
Nonca
does r
of the

Patholog
Subject System Topic

Exhibit Display

Acute appendicitis

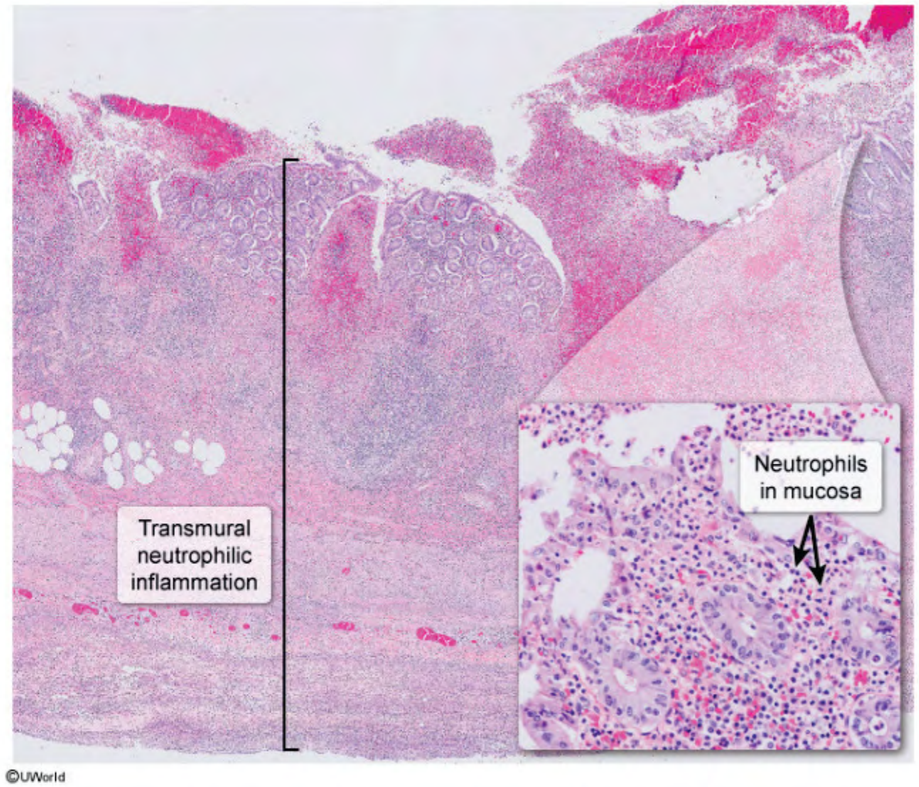

Zoom In Zoom Out Reset New | Existing My Notebook

https://t.me/USMLEWorldStep1

(noncaseating), surrounded by a cuff of lymphocytes. Granulomas are formed in an attempt to wall off an offending agent; in the case of CD this is likely due to an unregulated immune response to gut flora or self antige
the lyn
entire
Paneth

(Choi
shows

(Choi
histolo

(Choi
micros

(Choi
abdom
neutro

(Choi
superf
glandu

Educa
Nonca
does r
of the

Pathol
Subject System Topic

Exhibit Display

Collagenous colitis

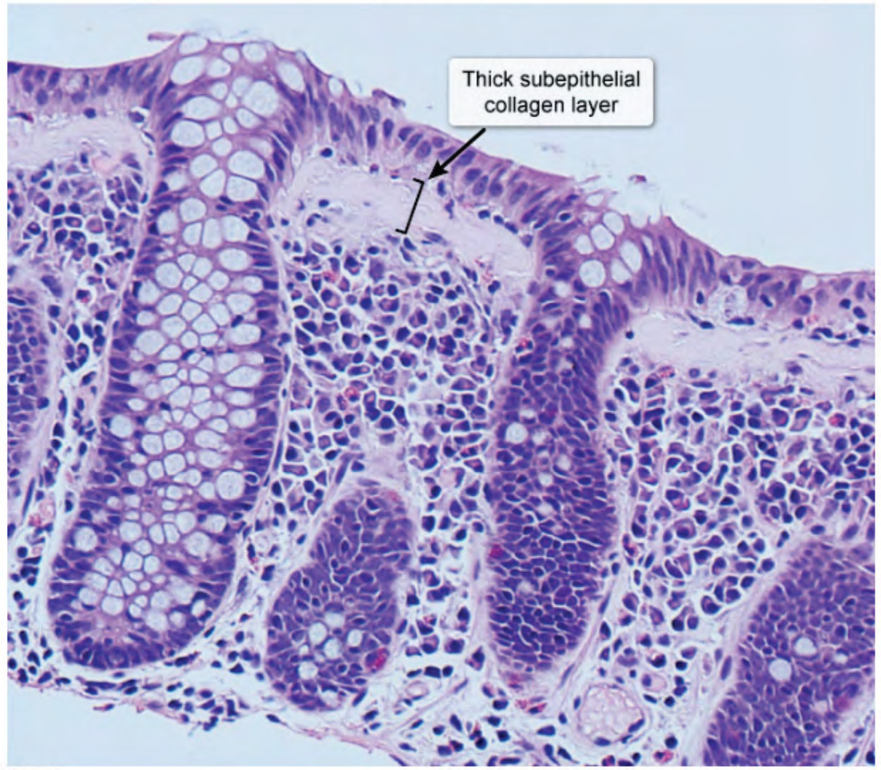

Zoom In Zoom Out Reset New | Existing My Notebook

https://t.me/USMLEWorldStep1

(noncaseating), surrounded by a cuff of lymphocytes. Granulomas are formed in an attempt to wall off an offending agent; in the case of CD this is likely due to an unregulated immune response to gut flora or self antige
the lyn
entire
Paneth

(Choi
shows

(Choi
histolo

(Choi
micros

(Choi
abdom
neutro

(Choi
superf
glandu

Educa
Nonca
does n
of the

Patholog
Subject System Topic

Exhibit Display

Ischemic colitis

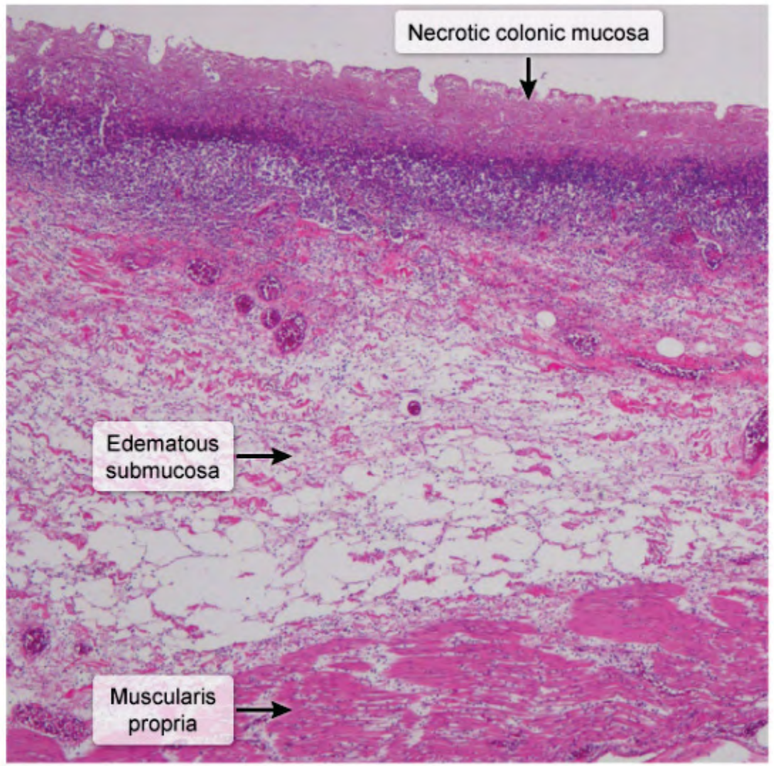

Zoom In Zoom Out Reset New | Existing My Notebook

https://t.me/USMLEWorldStep1
Show all

(noncaseating), surrounded by a cuff of lymphocytes. Granulomas are formed in an attempt to wall off an offending agent; in the case of CD this is likely due to an unregulated immune response to gut flora or self antige
the lyn
entire
Paneth

(Choi
shows

(Choi
histolo

(Choi
micros

(Choi
abdom
neutro

(Choi
superf
glandu

Educa
Nonca
does r
of the

Patholog
Subject System Topic

Exhibit Display

Pseudomembranous colitis

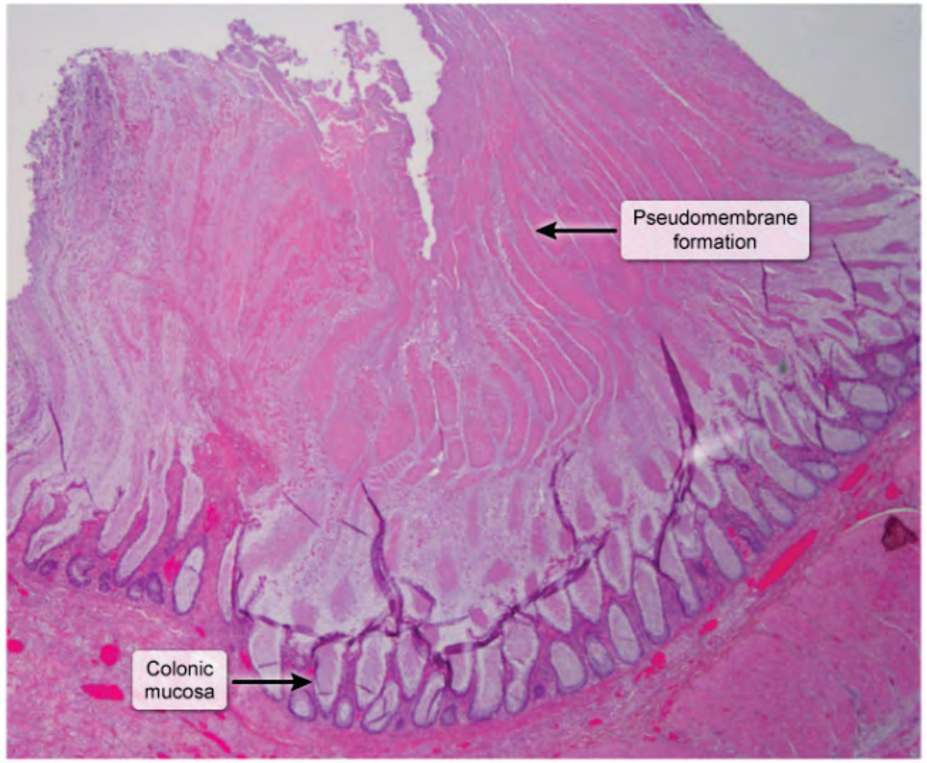

©UWorld

Zoom In Zoom Out Reset New | Existing My Notebook

https://t.me/USMLEWorldStep1

(noncaseating), surrounded by a cuff of lymphocytes. Granulomas are formed in an attempt to wall off an offending agent; in the case of CD this is likely due to an unregulated immune response to gut flora or self-

antige

the lyr

entire

Paneth

(Choi

shows

(Choi

histolo

(Choi

micros

(Choi

abdom

neutro

(Choi

superf

glandu

Educa

Nonca

does r

of the

Pathol

Subject

Exhibit Display

Ulcerative colitis

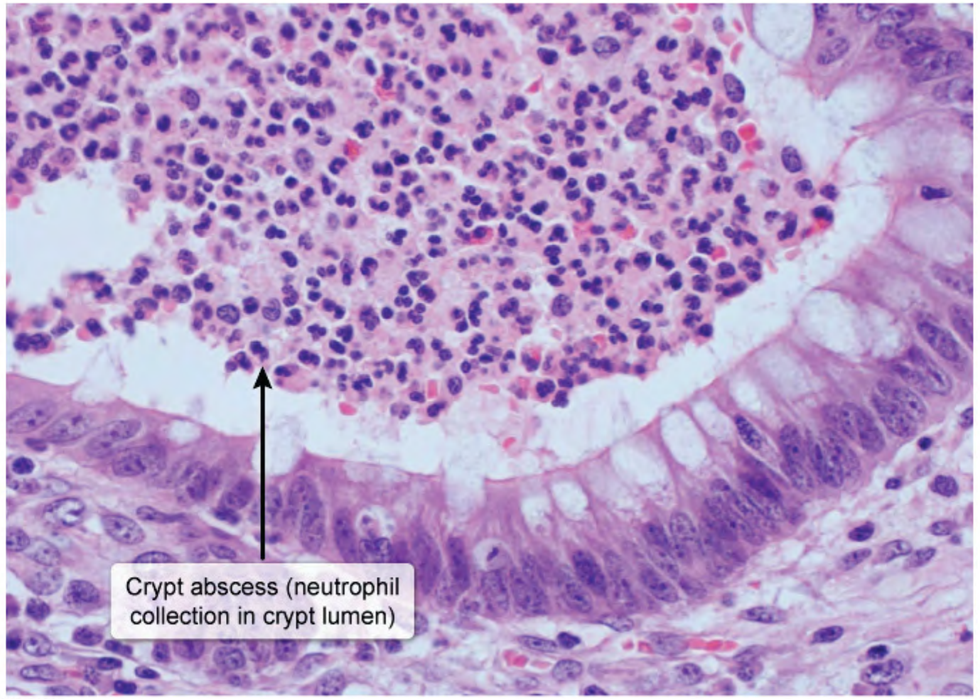

©UWorld

Zoom In | Zoom Out | Reset | New | Existing | My Notebook

https://t.me/USMLEWorldStep1

A 43-year-old man is evaluated for retrosternal discomfort and dysphagia for the past several months. He smokes a pack of cigarettes daily and drinks alcohol on weekends. His BMI is 32.8 kg/m^2. Physical examination is unremarkable. Esophageal manometry is performed; after a single swallow of 5 mL of water, the tracings appear as shown in the image below.

Which of the following is the most likely diagnosis in this patient?

- A. Achalasia
- B. Cricopharyngeal dysfunction
- C. Diffuse esophageal spasm
- D. Esophageal stricture
- E. Systemic sclerosis

Submit

https://t.me/USMLEWorldStep1

A 43-year-old man is evaluated for retrosternal discomfort and dysphagia for the past several months. He smokes a pack
unrem
as sho

Exhibit Display

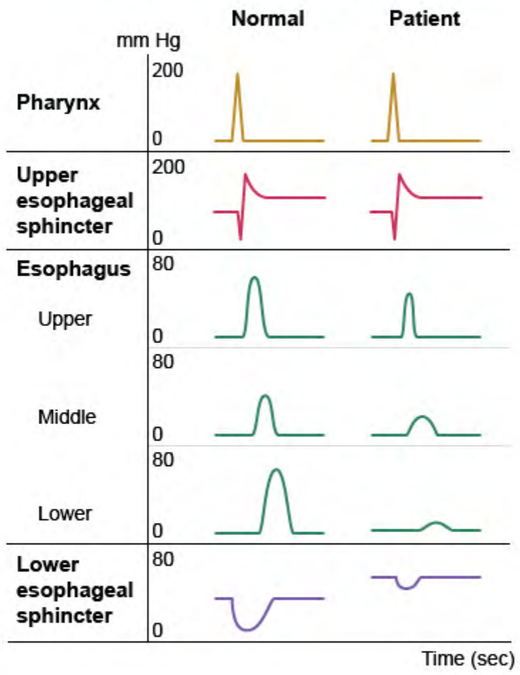

Zoom In | Zoom Out | Reset | New | Existing | My Notebook

Which

C. Diffuse esophageal spasm

https://t.me/USMLEWorldStep1

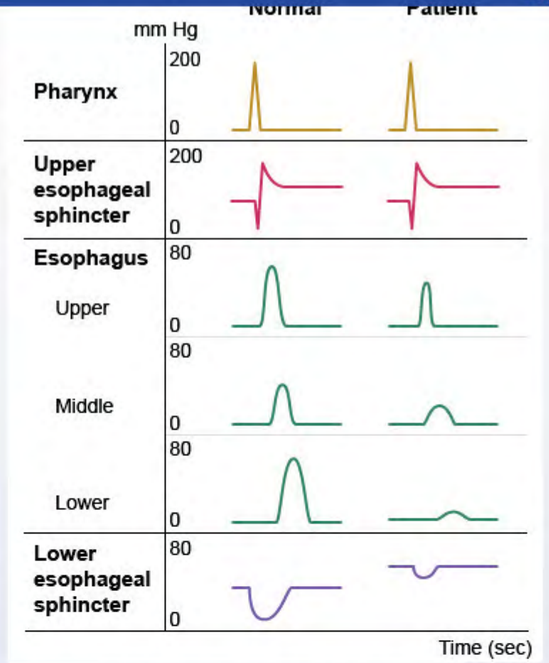

Which of the following is the most likely diagnosis in this patient?

- A. Achalasia
- B. Cricopharyngeal dysfunction
- C. Diffuse esophageal spasm
- D. Esophageal stricture
- E. Systemic sclerosis

Submit

https://t.me/USMLEWorldStep1
Show all

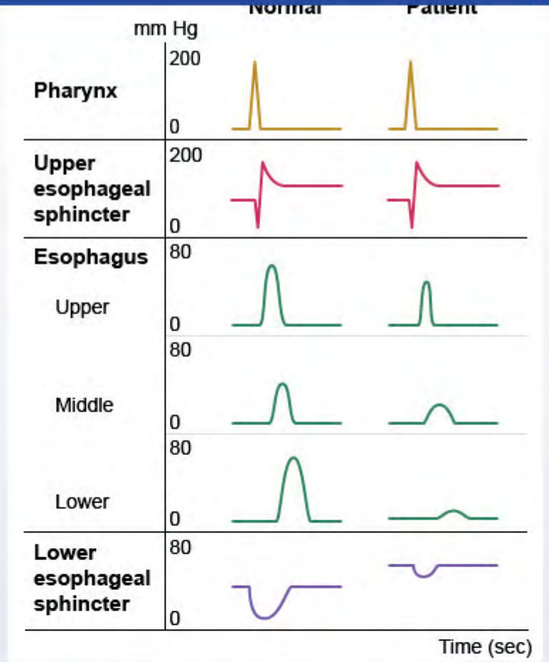

Which of the following is the most likely diagnosis in this patient?

- ✓ A. Achalasia (74%)
- B. Cricopharyngeal dysfunction (1%)
- C. Diffuse esophageal spasm (4%)
- D. Esophageal stricture (9%)
- E. Systemic sclerosis (9%)

Correct

74% Answered correctly

11 secs Time Spent

2023 Version

https://t.me/USMLEWorldStep1

Exhibit Display

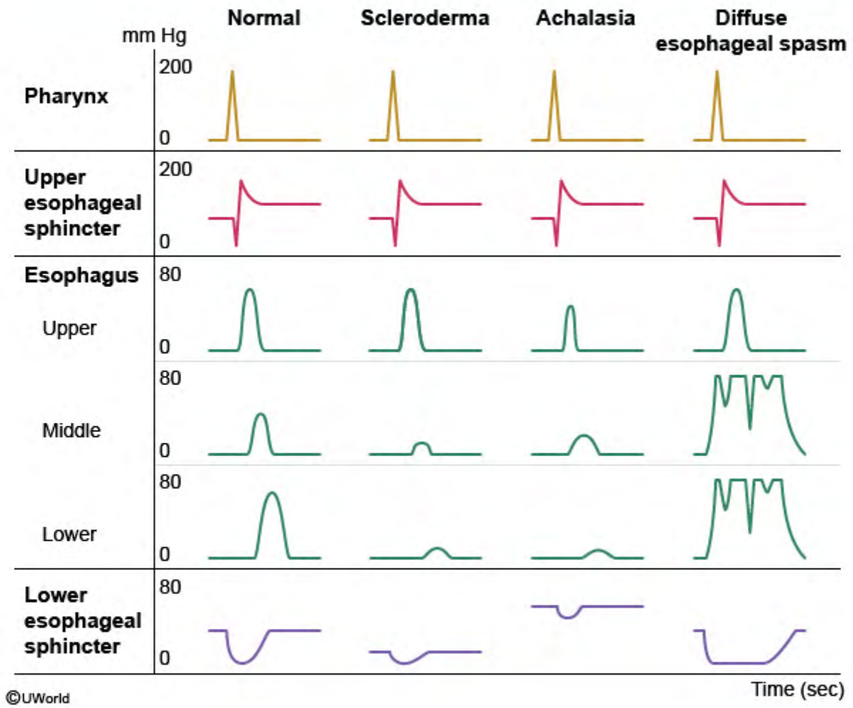

Zoom In | Zoom Out | Reset | New | Existing | My Notebook

To initi
where
muscl
bolus
the sto

Achalasia is a motility disorder caused by reduced numbers of **inhibitory ganglion cells** in the esophageal wall.

https://t.me/USMLEWorldStep1

To initiate swallowing, the contents of the oral cavity are collected on the tongue and propelled into the pharynx, where contraction of the pharyngeal muscles pushes the material into the esophagus. The cricopharyngeus muscle contracts behind the food bolus, initiating a peristaltic wave to propel the bolus downward. When the food bolus reaches the lower esophagus, the lower esophageal sphincter (LES) relaxes to allow the material to enter the stomach.

Achalasia is a motility disorder caused by reduced numbers of **inhibitory ganglion cells** in the esophageal wall, which creates an imbalance favoring excitatory ganglion cells. This patient's esophageal manometry shows typical findings in achalasia, including normal contraction of the upper esophageal sphincter, **decreased amplitude of peristalsis** in the mid esophagus, and increased tone and **incomplete relaxation** at the LES. Patients experience dysphagia, regurgitation, and retrosternal chest pain. Barium esophagram typically shows dilation of the esophagus with distal narrowing.

(Choice B) Cricopharyngeal dysfunction results from failure of the cricopharyngeus to relax during swallowing and causes a choking or "food-sticking" sensation on swallowing. Manometry findings are variable and can show decreased pharyngeal tone or incomplete relaxation at the upper esophageal sphincter.

(Choice C) Diffuse esophageal spasm presents with severe, retrosternal chest pain. It is characterized by uncoordinated contractions of the esophageal body. Esophageal manometry shows intermittent peristalsis and multiple simultaneous contractions on tracings from the mid and lower esophagus.

(Choice D) Esophageal stricture presents with progressive solid food dysphagia. It is diagnosed with contrast imaging (eg, barium swallow) rather than manometry. However, most patients will have a long history of gastroesophageal reflux with decreased tone at the LES.

(Choice E) Systemic sclerosis (scleroderma) can affect the esophagus, leading to impaired motility, incompetence of the LES, and gastroesophageal reflux. Manometry will show decreased peristalsis with decreased tone at the LES.

Educational objective:

https://t.me/USMLEWorldStep1
Show all

bolus reaches the lower esophagus, the lower esophageal sphincter (LES) relaxes to allow the material to enter the stomach.

Achalasia is a motility disorder caused by reduced numbers of **inhibitory ganglion cells** in the esophageal wall, which creates an imbalance favoring excitatory ganglion cells. This patient's esophageal manometry shows typical findings in achalasia, including normal contraction of the upper esophageal sphincter, **decreased amplitude of peristalsis** in the mid esophagus, and increased tone and **incomplete relaxation** at the LES. Patients experience dysphagia, regurgitation, and retrosternal chest pain. Barium esophagram typically shows dilation of the esophagus with distal narrowing.

(Choice B) Cricopharyngeal dysfunction results from failure of the cricopharyngeus to relax during swallowing and causes a choking or "food-sticking" sensation on swallowing. Manometry findings are variable and can show decreased pharyngeal tone or incomplete relaxation at the upper esophageal sphincter.

(Choice C) Diffuse esophageal spasm presents with severe, retrosternal chest pain. It is characterized by uncoordinated contractions of the esophageal body. Esophageal manometry shows intermittent peristalsis and multiple simultaneous contractions on tracings from the mid and lower esophagus.

(Choice D) Esophageal stricture presents with progressive solid food dysphagia. It is diagnosed with contrast imaging (eg, barium swallow) rather than manometry. However, most patients will have a long history of gastroesophageal reflux with decreased tone at the LES.

(Choice E) Systemic sclerosis (scleroderma) can affect the esophagus, leading to impaired motility, incompetence of the LES, and gastroesophageal reflux. Manometry will show decreased peristalsis with decreased tone at the LES.

Educational objective:
Achalasia is caused by reduced numbers of inhibitory ganglion cells in the esophageal wall. Esophageal manometry in achalasia shows decreased amplitude of peristalsis in the mid esophagus, with increased tone and incomplete relaxation at the lower esophageal sphincter.

https://t.me/USMLEWorldStep1
Show all

bolus reaches the lower esophagus, the lower esophageal sphincter (LES) relaxes to allow the material to enter the sto

Achal
which
findin
perist
dyspha
esoph

(Choi
cause
decrea

(Choi
uncoo
multip

(Choi
imagi
gastro

(Choi
of the
LES.

Educa
Achala
manor
incomplete relaxation at the lower esophageal sphincter.

Exhibit Display

Achalasia

Zoom In | Zoom Out | Reset | New | Existing | My Notebook

https://t.me/USMLEWorldStep1
Show all

A 75-year-old man is brought to the emergency department due to acute-onset profuse vomiting of large amounts of bright red blood. He has had intermittent, dull epigastric pain for the last 3 months. Medical history is significant for chronic obstructive pulmonary disease with multiple exacerbations and lumbar spinal stenosis. The patient has smoked 1 pack of cigarettes daily for 40 years. Blood pressure is 70/40 mm Hg and pulse is 120/min. Examination shows epigastric tenderness. The patient dies an hour after admission despite resuscitation efforts. Autopsy shows a deep peptic ulcer localized proximally on the lesser curvature of the stomach. The ulcer most likely penetrated which of the following arteries?

- A. Common hepatic
- B. Gastroduodenal
- C. Inferior pancreaticoduodenal
- D. Left gastric
- E. Right gastroepiploic
- F. Splenic
- G. Superior mesenteric

Submit

https://t.me/USMLEWorldStep1
Show all

A 75-year-old man is brought to the emergency department due to acute-onset profuse vomiting of large amounts of bright red blood. He has had intermittent, dull epigastric pain for the last 3 months. Medical history is significant for chronic obstructive pulmonary disease with multiple exacerbations and lumbar spinal stenosis. The patient has smoked 1 pack of cigarettes daily for 40 years. Blood pressure is 70/40 mm Hg and pulse is 120/min. Examination shows epigastric tenderness. The patient dies an hour after admission despite resuscitation efforts. Autopsy shows a deep peptic ulcer localized proximally on the lesser curvature of the stomach. The ulcer most likely penetrated which of the following arteries?

- ✗ A. Common hepatic (1%)
- B. Gastroduodenal (9%)
- C. Inferior pancreaticoduodenal (0%)
- ✓ D. Left gastric (75%)
- E. Right gastroepiploic (6%)
- F. Splenic (5%)
- G. Superior mesenteric (0%)

Incorrect
Correct answer
D

75%
Answered correctly

03 secs
Time Spent

2023
Version

Explanation

https://t.me/USMLEWorldStep1
Show all

A 75-year-old man is brought to the emergency department due to acute-onset profuse vomiting of large amounts of brig
for chr
smoke
Exami
Autops
likely p

Inco
Corre
D

Expl

Exhibit Display

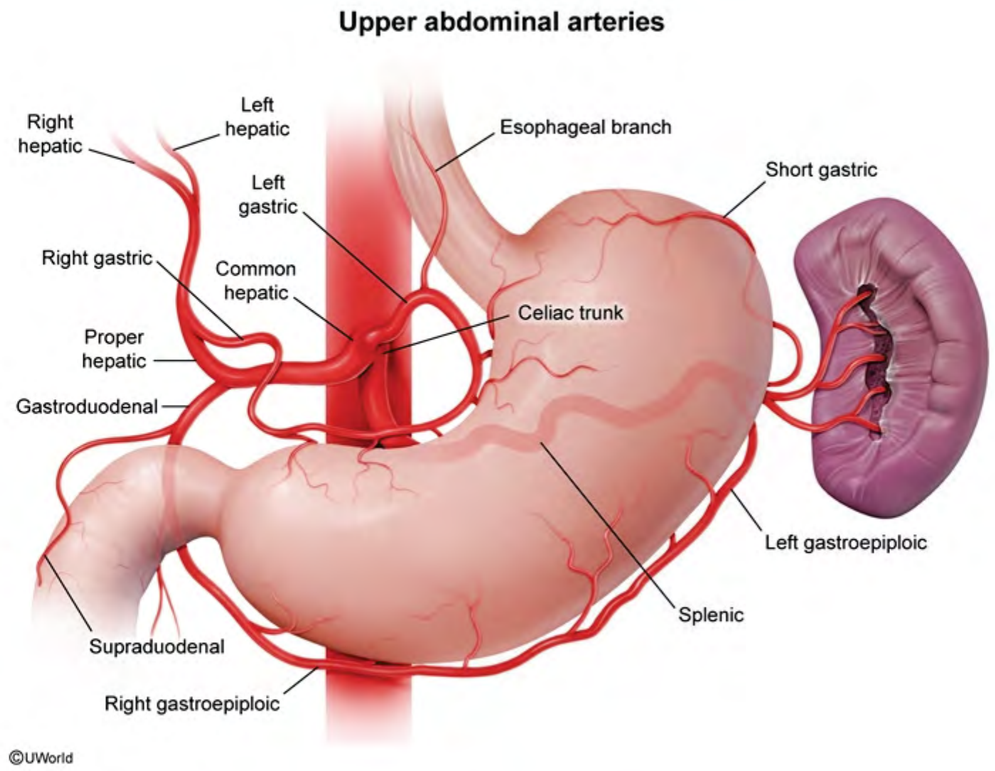

Zoom In | Zoom Out | Reset | New | Existing | My Notebook

https://t.me/USMLEWorldStep1

©UWorld

Massive hemorrhage with hypovolemic shock is a potential life-threatening complication of peptic ulcer disease (PUD). Most cases of PUD are due to *Helicobacter pylori* infection or nonsteroidal anti-inflammatory drug use. Other risk factors include smoking, glucocorticoid use, and older age.

Most **gastric ulcers** arise along the **lesser curvature** of the stomach, usually at the transitional zone between the gastric corpus (body) and antrum. Glands in the corpus contain parietal cells that produce hydrochloric acid and intrinsic factor; mucosal glands in the antrum contain G cells that secrete gastrin. This **transitional zone** provides the optimal microenvironment (eg, pH, host immune factors) for *H pylori* proliferation. The resultant inflammation leads to mucosal atrophy and ulcer formation.

The left and right **gastric arteries** run along and perfuse the lesser curvature of the stomach, and are a common source of hemorrhage from penetrating gastric ulcers. Other potential complications of PUD include penetration into other adjacent structures (eg, biliary tract, colon), gastric outlet obstruction, and free wall perforation with peritonitis.

(Choices A and B) The common hepatic artery perfuses the liver, gallbladder, pylorus, duodenum, and pancreas. It arises from the celiac trunk and ends when it bifurcates into the proper hepatic and gastroduodenal arteries. The gastroduodenal artery supplies blood to the pylorus and proximal duodenum. Ulcers in the posterior duodenal bulb can erode into the gastroduodenal artery, but a gastric ulcer at the lesser curvature would not involve these arteries.

(Choices C and G) The superior mesenteric and inferior pancreaticoduodenal arteries do not perfuse the stomach.

(Choice E) The right gastroepiploic artery arises from the gastroduodenal artery and perfuses the distal greater curvature of the stomach. Gastric ulcers do not commonly occur in the greater curvature.

(Choice F) The splenic artery arises from the celiac trunk and supplies blood to the spleen. It is separated from

https://t.me/USMLEWorldStep1
Show all

gastric corpus (body) and antrum. Glands in the corpus contain parietal cells that produce hydrochloric acid and intrinsic factor; mucosal glands in the antrum contain G cells that secrete gastrin. This **transitional zone** provides the optimal microenvironment (eg, pH, host immune factors) for *H pylori* proliferation. The resultant inflammation leads to mucosal atrophy and ulcer formation.

The left and right **gastric arteries** run along and perfuse the lesser curvature of the stomach, and are a common source of hemorrhage from penetrating gastric ulcers. Other potential complications of PUD include penetration into other adjacent structures (eg, biliary tract, colon), gastric outlet obstruction, and free wall perforation with peritonitis.

(Choices A and B) The common hepatic artery perfuses the liver, gallbladder, pylorus, duodenum, and pancreas. It arises from the celiac trunk and ends when it bifurcates into the proper hepatic and gastroduodenal arteries. The gastroduodenal artery supplies blood to the pylorus and proximal duodenum. Ulcers in the posterior duodenal bulb can erode into the gastroduodenal artery, but a gastric ulcer at the lesser curvature would not involve these arteries.

(Choices C and G) The superior mesenteric and inferior pancreaticoduodenal arteries do not perfuse the stomach.

(Choice E) The right gastroepiploic artery arises from the gastroduodenal artery and perfuses the distal greater curvature of the stomach. Gastric ulcers do not commonly occur in the greater curvature.

(Choice F) The splenic artery arises from the celiac trunk and supplies blood to the spleen. It is separated from the posterior wall of the stomach by the pancreas and is only rarely penetrated by gastric ulcers.

Educational objective:
Most gastric ulcers arise along the lesser curvature of the stomach, usually at the transitional zone between the gastric corpus (body) and antrum. The left and right gastric arteries run along the lesser curvature and are likely to be penetrated by ulcers, causing gastric bleeding.

Anatomy Gastrointestinal & Nutrition Peptic ulcer disease

https://t.me/USMLEWorldStep1
Show all

A 4-day-old boy is brought to the office due to a 2-day history of progressive jaundice. The patient was born at term following an uncomplicated pregnancy. He is formula fed. The patient and his mother are both blood group A, Rh-positive. Vital signs are normal. Examination shows scleral icterus and jaundice over the face and chest. Laboratory results are as follows:

Hemoglobin	17.5 g/dL
Total bilirubin	8 mg/dL
Indirect bilirubin	7.2 mg/dL

The patient is followed closely, and the jaundice resolves without intervention in 3 days. This patient's jaundice was most likely the result of which of the following changes in bilirubin metabolism compared to an adult?

	Bilirubin production	Bilirubin conjugation	Enterohepatic bilirubin circulation
A.	Decreased	Increased	Decreased
B.	Increased	Decreased	Decreased
C.	Increased	Decreased	Increased
D.	Increased	Increased	Increased
E.	Unchanged	Increased	Decreased

Submit

https://t.me/USMLEWorldStep1
Show all

A 4-day-old boy is brought to the office due to a 2-day history of progressive jaundice. The patient was born at term following an uncomplicated pregnancy. He is formula fed. The patient and his mother are both blood group A, Rh-positive. Vital signs are normal. Examination shows scleral icterus and jaundice over the face and chest. Laboratory results are as follows:

Hemoglobin	17.5 g/dL
Total bilirubin	8 mg/dL
Indirect bilirubin	7.2 mg/dL

The patient is followed closely, and the jaundice resolves without intervention in 3 days. This patient's jaundice was most likely the result of which of the following changes in bilirubin metabolism compared to an adult?

	Bilirubin production	Bilirubin conjugation	Enterohepatic bilirubin circulation	
✗ A.	Decreased	Increased	Decreased	(0%)
B.	Increased	Decreased	Decreased	(47%)
✓ C.	Increased	Decreased	Increased	(43%)
D.	Increased	Increased	Increased	(3%)
E.	Unchanged	Increased	Decreased	(4%)

Incorrect
Correct answer
C

43%
Answered correctly

03 secs
Time Spent

2023
Version

https://t.me/USMLEWorldStep1
Show all

Incorrect
Correct answer
C

43%
Answered correctly

03 secs
Time Spent

2023
Version

Exhibit Display

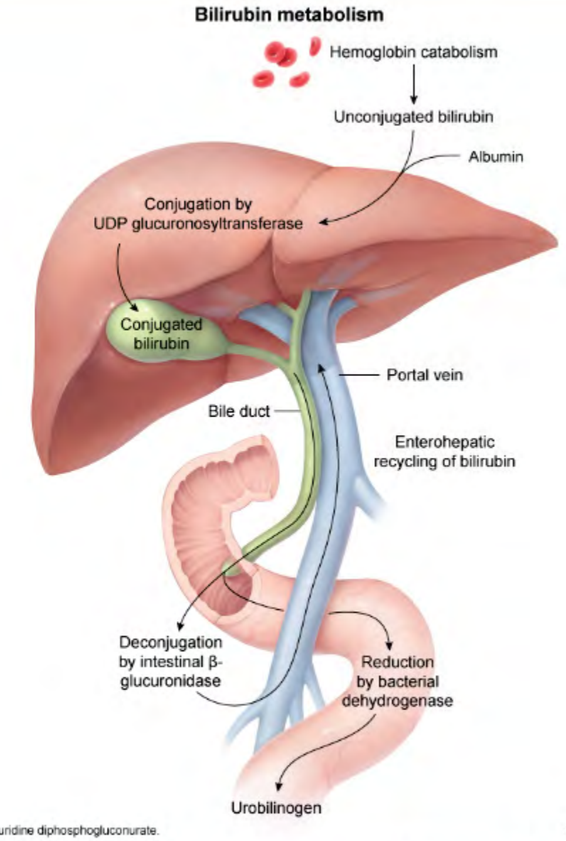

Zoom In | Zoom Out | Reset | New | Existing | My Notebook

https://t.me/USMLEWorldStep1

Show all

This newborn had **elevated indirect bilirubin** levels with jaundice that **self-resolved** in the first week of life, findings consistent with **benign neonatal hyperbilirubinemia**.

Normally, unconjugated bilirubin is released into the bloodstream upon breakdown of red blood cells (RBCs) and taken up by the liver. Hepatic UDP glucuronosyltransferase then conjugates bilirubin, which is secreted into bile and excreted into the intestines. Bacterial enzymes in the intestines then reduce bilirubin to urobilinogen, allowing for excretion through the urine and stool.

Benign neonatal hyperbilirubinemia is caused by several **physiologic differences** in bilirubin metabolism **in newborns** as compared to those in older children and adults.

- First, **bilirubin production is increased** due to increased breakdown of fetal RBCs, which are high in number (hematocrit up to 60%) and have a shorter life span (90 days as compared to 120 days in adults).
- Second, **bilirubin conjugation is decreased** due to physiologically lower levels of UDP glucuronosyltransferase in the immature neonatal liver.
- Finally, relative gut sterility in newborns results in decreased reduction of bilirubin to urobilinogen; instead, intestinal β-glucuronidase (which is synthesized both endogenously and by gut bacteria) deconjugates the bilirubin which allows it to be reabsorbed, therefore **increasing enterohepatic circulation**.

Educational objective:
Pathophysiology of benign neonatal hyperbilirubinemia involves increased bilirubin production and decreased bilirubin conjugation as well as increased enterohepatic circulation. Indirect hyperbilirubinemia and jaundice typically peak in the first few days of life and usually resolve without intervention.

References

- Neonatal jaundice.
- Neonatal jaundice.

Biochemistry Gastrointestinal & Nutrition Neonatal jaundice

https://t.me/USMLEWorldStep1
Show all

A 65-year-old man comes to the emergency department due to abdominal pain and diarrhea. Three weeks ago, he drove from Texas to Mexico for a family vacation. Temperature is 38.3 C (101 F), blood pressure is 115/70 mm Hg, and pulse is 98/min. Abdominal examination shows mild, generalized tenderness with no rebound tenderness or guarding. Leukocyte count is 14,000/mm^3. Sigmoidoscopy demonstrates white-yellow plaques on the colonic mucosa, and biopsy shows that the plaques are composed of fibrin and inflammatory cells. Further questioning regarding this patient's trip to Mexico is most likely to reveal which of the following events?

- A. He consumed shellfish from the hotel buffet
- B. He drank unpurified tap water on several occasions
- C. He had undercooked pork at a resort barbecue
- D. He required hospitalization and antibiotics for pneumonia
- E. He took home-canned foods to consume during the trip

Submit

https://t.me/USMLEWorldStep1
Show all

A 65-year-old man comes to the emergency department due to abdominal pain and diarrhea. Three weeks ago, he drove from Texas to Mexico for a family vacation. Temperature is 38.3 C (101 F), blood pressure is 115/70 mm Hg, and pulse is 98/min. Abdominal examination shows mild, generalized tenderness with no rebound tenderness or guarding. Leukocyte count is 14,000/mm^3. Sigmoidoscopy demonstrates white-yellow plaques on the colonic mucosa, and biopsy shows that the plaques are composed of fibrin and inflammatory cells. Further questioning regarding this patient's trip to Mexico is most likely to reveal which of the following events?

- ✗ A. He consumed shellfish from the hotel buffet (7%)
- B. He drank unpurified tap water on several occasions (22%)
- C. He had undercooked pork at a resort barbecue (8%)
- ✓ D. He required hospitalization and antibiotics for pneumonia (59%)
- E. He took home-canned foods to consume during the trip (1%)

Incorrect
Correct answer
D

59%
Answered correctly

03 secs
Time Spent

2023
Version

Explanation

***Clostridioides difficile* colitis**	
Risk factors	• Recent antibiotic use • Hospitalization • Gastric acid suppression (eg, PPI)
	• Disruption of intestinal flora → *C difficile* overgrowth

https://t.me/USMLEWorldStep1
Show all

***Clostridioides difficile* colitis**	
Risk factors	• Recent antibiotic use • Hospitalization • Gastric acid suppression (eg, PPI)
Pathogenesis	• Disruption of intestinal flora → *C difficile* overgrowth • Toxins A & B disrupt cytoskeleton integrity & stimulate inflammation • Pseudomembrane formation
Clinical presentation	• Profuse watery diarrhea (most common) • Leukocytosis (~15,000/mm^3) • Fulminant colitis/toxic megacolon
Diagnosis	• Stool PCR for *C difficile* genes* • Stool EIA for *C difficile* toxin & glutamate dehydrogenase antigen
Treatment	• Oral fidaxomicin or oral vancomycin • IV metronidazole added for fulminant disease
*Genes specific to toxigenic strains are assessed. **EIA** = enzyme immunoassay; **IV** = intravenous; **PCR** = polymerase chain reaction; **PPI** = proton pump inhibitor.	

This patient has abdominal pain, diarrhea, and leukocytosis. The formation of pseudomembranes (white-yellow plaques composed of fibrin, inflammatory cells, and cellular debris) on the colonic mucosa is highly consistent with pseudomembranous colitis due to ***Clostridioides difficile***, a spore-forming bacillus that colonizes up to 50% of hospitalized adults. **Antibiotic therapy** (eg, fluoroquinolones for bacterial pneumonia) **increases the risk** of *C difficile* infection because it kills intestinal microbes that normally keep potential pathogens in check. *C difficile* can proliferate in the altered microbiome, leading to overgrowth and clinical disease.

C difficile produces 2 toxins—toxin A (enterotoxin) and toxin B (cytotoxin)—which penetrate colonic epithelial cells

https://t.me/USMLEWorldStep1
Show all

*Genes specific to toxigenic strains are assessed.

EIA = enzyme immunoassay; **IV** = intravenous; **PCR** = polymerase chain reaction; **PPI** = proton pump inhibitor.

This patient has abdominal pain, diarrhea, and leukocytosis. The formation of pseudomembranes (white-yellow plaques composed of fibrin, inflammatory cells, and cellular debris) on the colonic mucosa is highly consistent with pseudomembranous colitis due to ***Clostridioides difficile***, a spore-forming bacillus that colonizes up to 50% of hospitalized adults. **Antibiotic therapy** (eg, fluoroquinolones for bacterial pneumonia) **increases the risk** of *C difficile* infection because it kills intestinal microbes that normally keep potential pathogens in check. *C difficile* can proliferate in the altered microbiome, leading to overgrowth and clinical disease.

C difficile produces 2 toxins—toxin A (enterotoxin) and toxin B (cytotoxin)—which penetrate colonic epithelial cells and damage cellular cytoskeletons and intercellular tight junctions. This results in widespread inflammation, edema, necrosis, and fibrin deposition. Clinical manifestations range from watery diarrhea and mild abdominal cramping to fulminant colitis with nonobstructive colonic enlargement (megacolon) and intestinal perforation.

(Choices A and B) Ingestion of undercooked shellfish is associated with *Vibrio*, Norwalk virus, and hepatitis A infections. Traveler's diarrhea, caused by bacteria (eg, enterotoxigenic *Escherichia coli*, *Campylobacter*, *Salmonella*, *Shigella*) or parasites (eg, *Giardia*), is often due to contaminated water consumption. These conditions can manifest as diarrhea and abdominal pain; however, pseudomembranes are virtually pathognomonic for *C difficile* colitis.

(Choice C) Consumption of undercooked pork is a risk factor for intestinal tapeworm (taeniasis), which occurs after ingestion of *Taenia solium*. Patients are often asymptomatic but may have nausea or abdominal pain.

(Choice E) Adult botulism occurs after ingestion of preformed toxin in home-canned food. This neurotoxin inhibits acetylcholine release from the nerve terminals at neuromuscular junctions and causes a descending flaccid paralysis.

Educational objective:

Antibiotics disrupt the normal intestinal flora and can allow for overgrowth of *Clostridioides difficile*, an anaerobic, gram-positive, spore-forming bacillus. *C difficile* produces 2 toxins that penetrate colonic epithelial cells leading to

https://t.me/USMLEWorldStep1
Show all

plaques composed of fibrin, inflammatory cells, and cellular debris) on the colonic mucosa is highly consistent with pseudomembranous colitis due to ***Clostridioides difficile***, a spore-forming bacillus that colonizes up to 50% of hospitalized adults. **Antibiotic therapy** (eg, fluoroquinolones for bacterial pneumonia) **increases the risk** of *C difficile* infection because it kills intestinal microbes that normally keep potential pathogens in check. *C difficile* can proliferate in the altered microbiome, leading to overgrowth and clinical disease.

C difficile produces 2 toxins—toxin A (enterotoxin) and toxin B (cytotoxin)—which penetrate colonic epithelial cells and damage cellular cytoskeletons and intercellular tight junctions. This results in widespread inflammation, edema, necrosis, and fibrin deposition. Clinical manifestations range from watery diarrhea and mild abdominal cramping to fulminant colitis with nonobstructive colonic enlargement (megacolon) and intestinal perforation.

(Choices A and B) Ingestion of undercooked shellfish is associated with *Vibrio*, Norwalk virus, and hepatitis A infections. Traveler's diarrhea, caused by bacteria (eg, enterotoxigenic *Escherichia coli*, *Campylobacter*, *Salmonella*, *Shigella*) or parasites (eg, *Giardia*), is often due to contaminated water consumption. These conditions can manifest as diarrhea and abdominal pain; however, pseudomembranes are virtually pathognomonic for *C difficile* colitis.

(Choice C) Consumption of undercooked pork is a risk factor for intestinal tapeworm (taeniasis), which occurs after ingestion of *Taenia solium*. Patients are often asymptomatic but may have nausea or abdominal pain.

(Choice E) Adult botulism occurs after ingestion of preformed toxin in home-canned food. This neurotoxin inhibits acetylcholine release from the nerve terminals at neuromuscular junctions and causes a descending flaccid paralysis.

Educational objective:
Antibiotics disrupt the normal intestinal flora and can allow for overgrowth of *Clostridioides difficile*, an anaerobic, gram-positive, spore-forming bacillus. *C difficile* produces 2 toxins that penetrate colonic epithelial cells leading to watery diarrhea, abdominal cramping, and colitis. The presence of a pseudomembrane (exudate on colonic mucosa consisting of fibrin and inflammatory cells) is highly suggestive of *C difficile* infection.

References

https://t.me/USMLEWorldStep1
Show all

- Stool EIA for *C difficile* toxin & glutamate dehydrogenase antigen

Exhibit Display

Pseudomembranous colitis

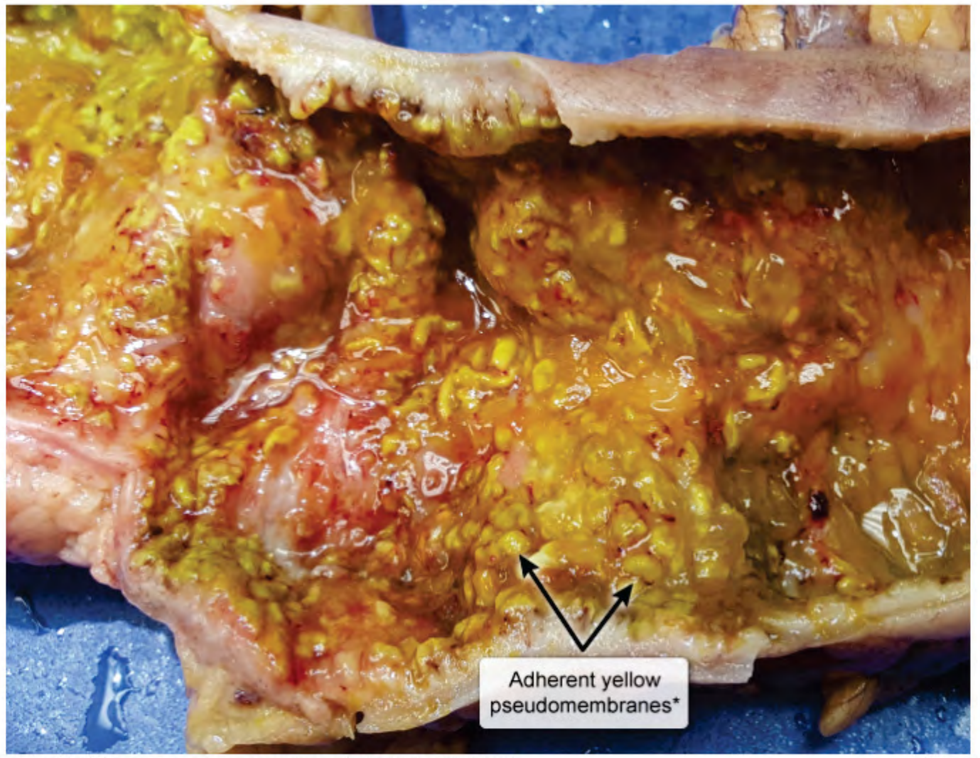

*Fibrin and inflammatory debris associated with *Clostridioides difficile*.

©UWorld

Zoom In | Zoom Out | Reset | New | Existing | My Notebook

This p
plaque
pseud
hospit
difficile
prolife

C diffi
and da
edema
cramp

(Choi
infecti
Salmo
can m
difficile

(Choi
after ir

(Choi
acetylcholine release from the nerve terminals at neuromuscular junctions and causes a descending flaccid

https://t.me/USMLEWorldStep1

An 8-month-old girl is brought to the emergency department due to fussiness. Symptoms began about 4 hours ago, and the patient has vomited several times. The parents state that the vomitus is dark green but nonbloody. The patient was born at term via spontaneous vaginal delivery after an uncomplicated pregnancy. She has no known medical conditions and normally consumes breast milk and pureed foods. Examination demonstrates abdominal distension. Abdominal imaging is shown in the exhibit. Surgical intervention is needed in this patient to prevent ischemia to structures supplied by which of the following?

- A. Common hepatic artery
- B. Inferior mesenteric artery
- C. Left gastric artery
- D. Splenic artery
- E. Superior mesenteric artery

Submit

https://t.me/USMLEWorldStep1
Show all

An 8-month-old girl is brought to the emergency department due to fussiness. Symptoms began about 4 hours ago, a
The pa
known
abdom
prever

Sub

Exhibit Display

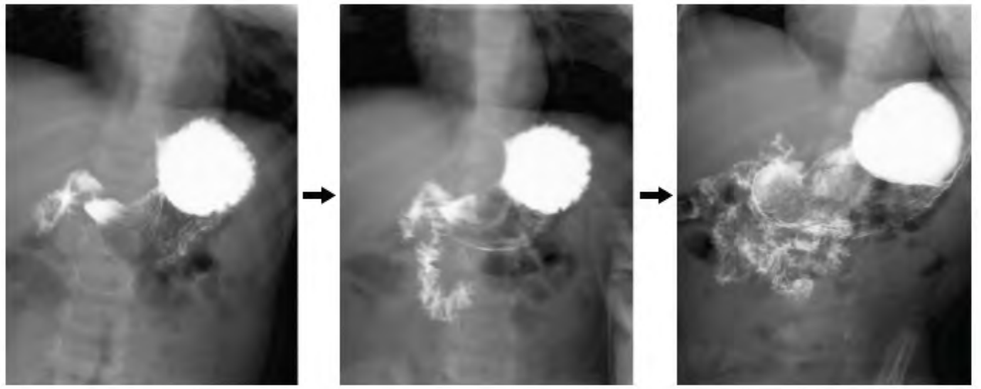

Zoom In Zoom Out Reset New | Existing My Notebook

https://t.me/USMLEWorldStep1

An 8-month-old girl is brought to the emergency department due to fussiness. Symptoms began about 4 hours ago, and the patient has vomited several times. The parents state that the vomitus is dark green but nonbloody. The patient was born at term via spontaneous vaginal delivery after an uncomplicated pregnancy. She has no known medical conditions and normally consumes breast milk and pureed foods. Examination demonstrates abdominal distension. Abdominal imaging is shown in the exhibit. Surgical intervention is needed in this patient to prevent ischemia to structures supplied by which of the following?

- A. Common hepatic artery (9%)
- ✗ B. Inferior mesenteric artery (7%)
- C. Left gastric artery (24%)
- D. Splenic artery (14%)
- ✓ E. Superior mesenteric artery (44%)

Incorrect
Correct answer
E

44%
Answered correctly

01 min, 18 secs
Time Spent

2023
Version

Explanation

Malrotation

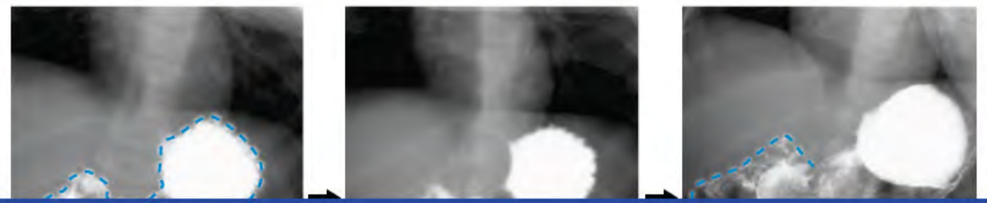

https://t.me/USMLEWorldStep1
Show all

C. Left gastric artery (24%)

Exhibit Display

Malrotation

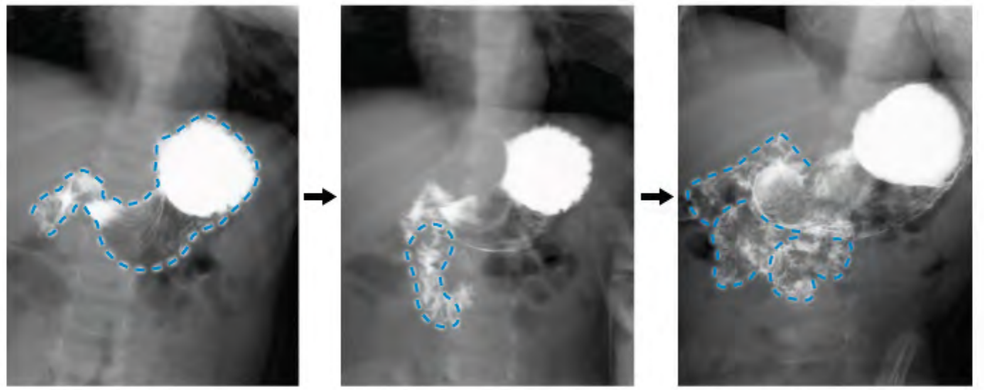

Contrast in stomach* & first part of duodenum

Contrast in second part of duodenum

Contrast in **proximal jejunum on right side of abdomen (malrotation)**

*Contrast pooled in fundus due to supine positioning during upper GI series.

©UWorld

Zoom In | Zoom Out | Reset | New | Existing | My Notebook

This p
series (sequential x-rays obtained after ingestion of radiopaque contrast) revealing proximal small bowel loops on the right side of the abdomen

https://t.me/USMLEWorldStep1

An 8-month-old girl is brought to the emergency department due to fussiness. Symptoms began about 4 hours ago, and the patient has vomited several times. The parents state that the vomitus is dark green but nonbloody. The patient was born at term via spontaneous vaginal delivery after an uncomplicated pregnancy. She has no known medical conditions and normally consumes breast milk and pureed foods. Examination demonstrates abdominal distension. Abdominal imaging is shown in the exhibit. Surgical intervention is needed in this patient to prevent ischemia to structures supplied by which of the following?

- A. Common hepatic artery (9%)
- ✗ B. Inferior mesenteric artery (7%)
- C. Left gastric artery (24%)
- D. Splenic artery (14%)
- ✓ E. Superior mesenteric artery (44%)

Incorrect
Correct answer
E

44%
Answered correctly

01 min, 18 secs
Time Spent

2023
Version

Explanation

Malrotation

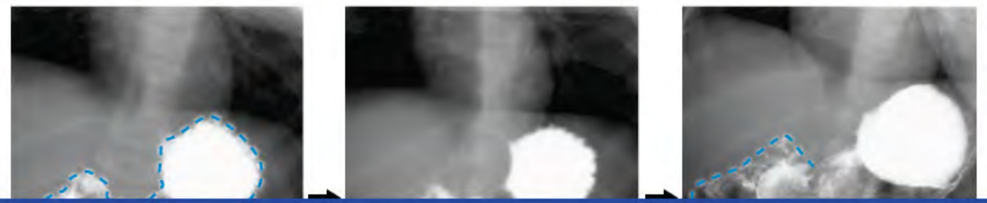

https://t.me/USMLEWorldStep1
Show all

*Contrast pooled in fundus due to supine positioning during upper GI series.

©UWorld

This patient with bilious (dark green) emesis has **midgut malrotation**, as evidenced by the upper gastrointestinal series (sequential x-rays obtained after ingestion of radiopaque contrast) revealing proximal small bowel loops on the right side of the abdomen.

Normally, at 4-8 weeks gestation, the rapidly growing midgut physiologically herniates through the umbilical ring and rotates 90 degrees counterclockwise; the midgut then returns to the abdominal cavity and rotates an additional 180 degrees counterclockwise. This rotation allows for appropriate positioning of the bowel loops within the abdomen to create a wide mesenteric base that extends from the duodenojejunal flexure in the left upper quadrant to the cecum in the right lower quadrant.

Incomplete rotation causes midgut malrotation. Pathologic anatomic findings include the following:

- The **duodenojejunal flexure** and **jejunal loops** lie on the **right** (instead of the left) side of the abdomen
- The partially rotated cecum still lies within the right side of the abdomen but in the mid to upper quadrants and is held in place by fibrous bands (Ladd bands) crossing the duodenum. This results in a narrow mesenteric base that is abnormally mobile.

This mobility permits **twisting** around the **superior mesenteric artery** (SMA), or **midgut volvulus**, that can lead to life-threatening bowel ischemia and necrosis involving the intestinal segments that the SMA perfuses (ie, distal duodenum to proximal transverse colon). The most common presenting symptom is bilious emesis and management is prompt surgical correction.

(Choices A, C, and D) The common hepatic, left gastric, and splenic arteries do not supply the intestines and are not involved in midgut volvulus.

(Choice B) The inferior mesenteric artery supplies the hindgut (distal transverse colon to rectum).

Educational objective:
Intestinal malrotation occurs when the midgut undergoes incomplete physiologic rotation in utero. A life-threatening complication of malrotation is midgut volvulus, in which the small intestines twist around the superior

https://t.me/USMLEWorldStep1
Show all

the right side of the abdomen.

Normally, at 4-8 weeks gestation, the rapidly growing midgut physiologically herniates through the umbilical ring and rotates 90 degrees counterclockwise; the midgut then returns to the abdominal cavity and rotates an additional 180 degrees counterclockwise. This rotation allows for appropriate positioning of the bowel loops within the abdomen to create a wide mesenteric base that extends from the duodenojejunal flexure in the left upper quadrant to the cecum in the right lower quadrant.

Incomplete rotation causes midgut malrotation. Pathologic anatomic findings include the following:

- The **duodenojejunal flexure** and **jejunal loops** lie on the **right** (instead of the left) side of the abdomen
- The partially rotated cecum still lies within the right side of the abdomen but in the mid to upper quadrants and is held in place by fibrous bands (Ladd bands) crossing the duodenum. This results in a narrow mesenteric base that is abnormally mobile.

This mobility permits **twisting** around the **superior mesenteric artery** (SMA), or **midgut volvulus**, that can lead to life-threatening bowel ischemia and necrosis involving the intestinal segments that the SMA perfuses (ie, distal duodenum to proximal transverse colon). The most common presenting symptom is bilious emesis and management is prompt surgical correction.

(Choices A, C, and D) The common hepatic, left gastric, and splenic arteries do not supply the intestines and are not involved in midgut volvulus.

(Choice B) The inferior mesenteric artery supplies the hindgut (distal transverse colon to rectum).

Educational objective:
Intestinal malrotation occurs when the midgut undergoes incomplete physiologic rotation in utero. A life-threatening complication of malrotation is midgut volvulus, in which the small intestines twist around the superior mesenteric artery due to the abnormally mobile mesenteric base. Patients have bilious emesis, and an upper gastrointestinal series typically shows proximal small intestinal loops on the right side of the abdomen.

References

https://t.me/USMLEWorldStep1
Show all

Exhibit Display

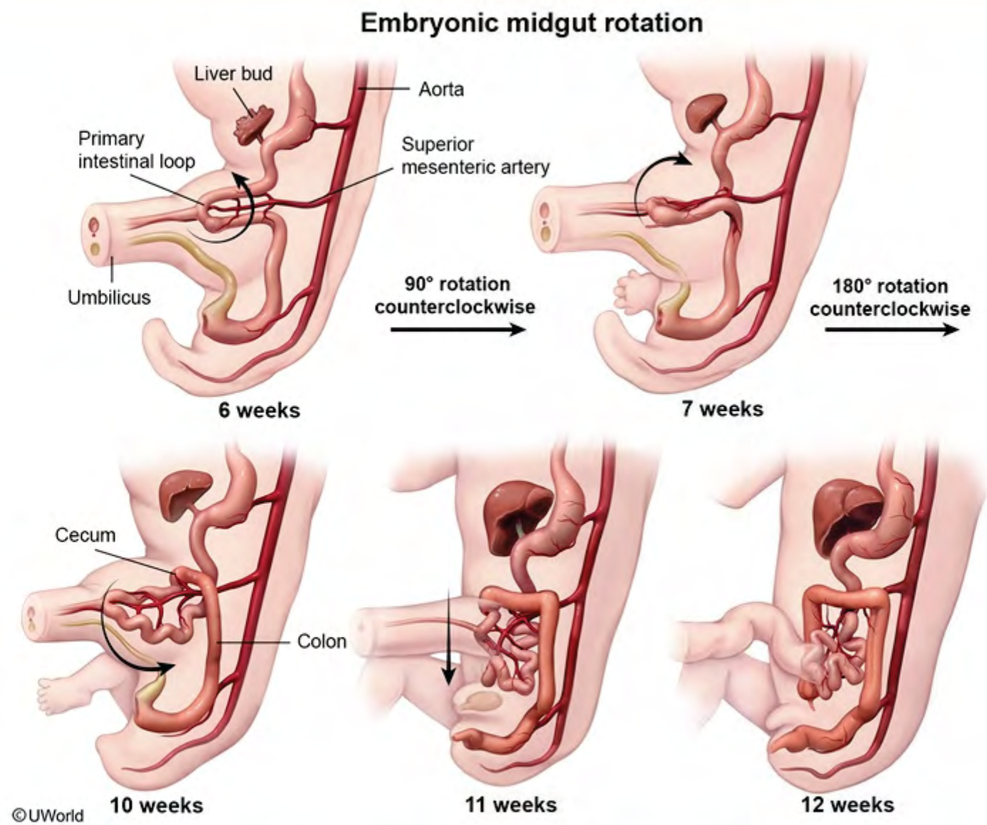

This p
series
the rig

Norma
and ro
180 de
abdom
to the

Incom

- T
- T
  is
  b

This m
to life-
duode
manag

(Choi
not inv

(Choice B) The inferior mesenteric artery supplies the hindgut (distal transverse colon to rectum).

https://t.me/USMLEWorldStep1

Exhibit Display

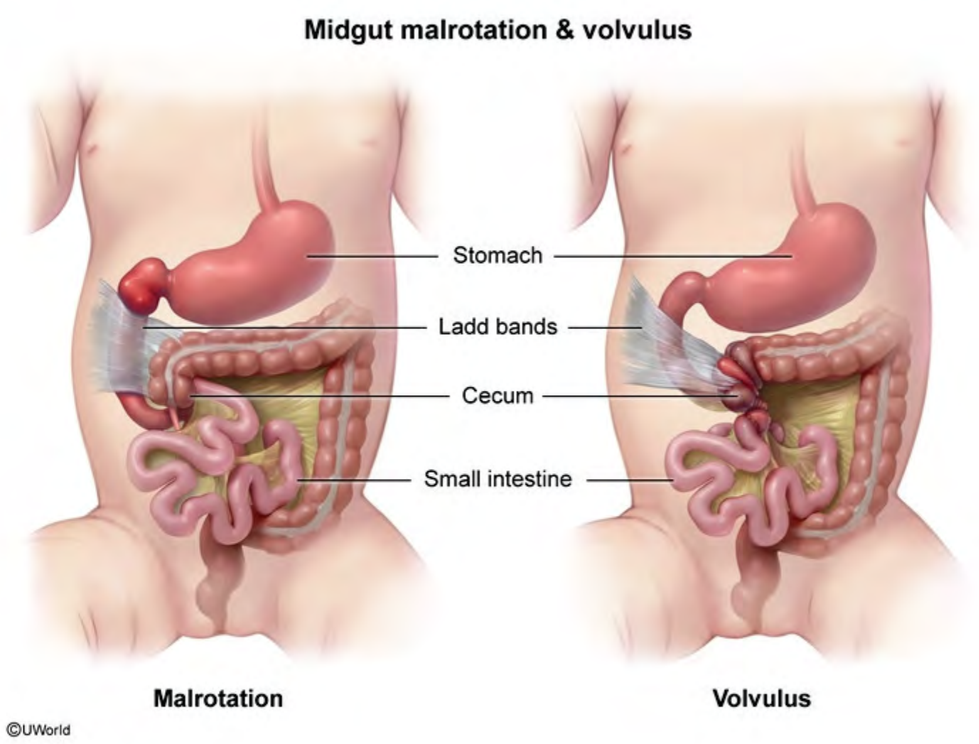

Zoom In | Zoom Out | Reset | New | Existing | My Notebook

This p
series
the rig

Norma
and ro
180 de
abdom
to the

Incom

- T
- T
  is
  b

This m
to life-
duode
manag

(Choi
not inv

(Choice B) The inferior mesenteric artery supplies the hindgut (distal transverse colon to rectum).

https://t.me/USMLEWorldStep1

Exhibit Display

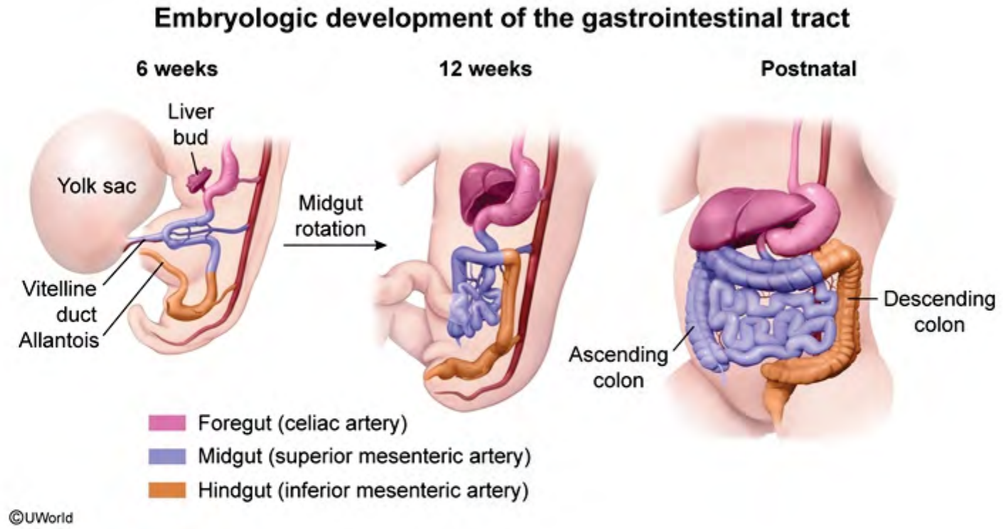

Zoom In | Zoom Out | Reset | New | Existing | My Notebook

This p
series
the rig

Norma
and ro
180 de
abdom
to the

Incom

- T
- T
  is
  b

This m
to life-
duode
manag

(Choi
not inv

(Choice B) The inferior mesenteric artery supplies the hindgut (distal transverse colon to rectum).

https://t.me/USMLEWorldStep1

the right side of the abdomen.

Normally, at 4-8 weeks gestation, the rapidly growing midgut physiologically herniates through the umbilical ring
and ro
180 de
abdom
to the

Incom

- T
- T
  is
  b

This m
to life-
duode
manag

(Choi
not inv

(Choi

Educa
Intesti
threate
meser
gastro

Refere

Exhibit Display

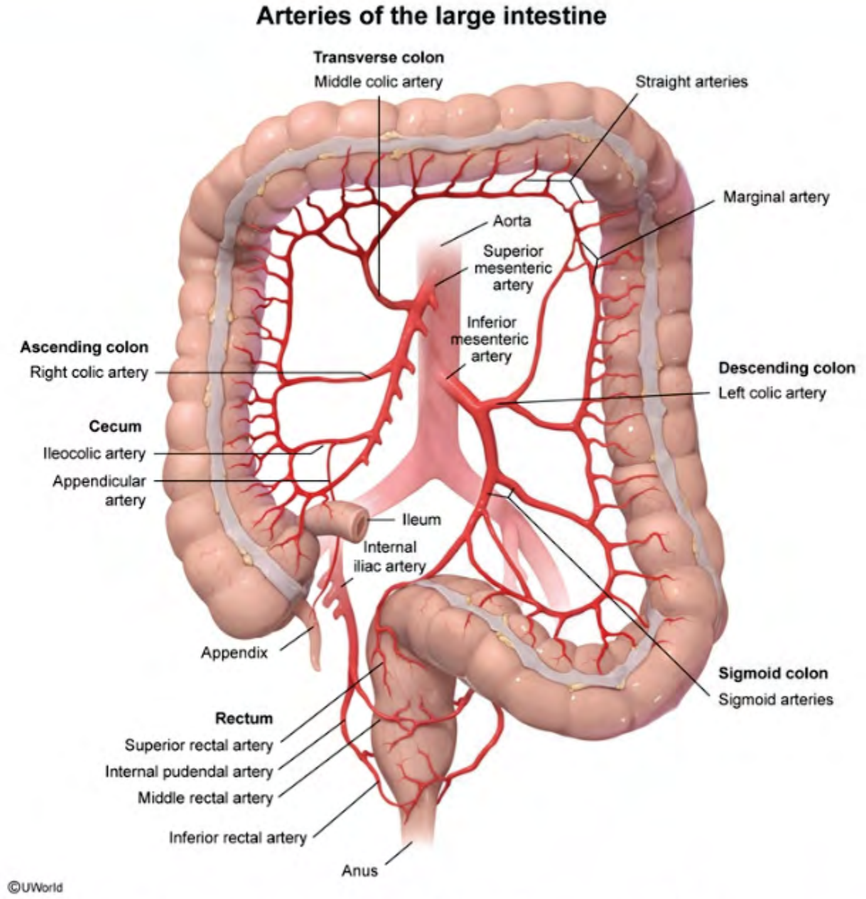

Zoom In | Zoom Out | Reset | New | Existing | My Notebook

https://t.me/USMLEWorldStep1

A 43-year-old woman comes to the emergency department with severe epigastric pain that started after she ate a heavy meal. She has had several milder episodes, noting that they occur after she eats fried food. The patient has not experienced bloating or changes in stool frequency. She recently sprained her ankle, for which she takes ibuprofen daily. BMI is 31 kg/m^2. Physical examination is limited by pain. Which of the following substances most likely initiates the recurrent episodes of epigastric pain seen in this patient?

- A. Cholecystokinin
- B. Lactose
- C. Prostaglandin E_2
- D. Secretin
- E. Serotonin
- F. Somatostatin

Submit

https://t.me/USMLEWorldStep1
Show all

A 43-year-old woman comes to the emergency department with severe epigastric pain that started after she ate a heavy meal. She has had several milder episodes, noting that they occur after she eats fried food. The patient has not experienced bloating or changes in stool frequency. She recently sprained her ankle, for which she takes ibuprofen daily. BMI is 31 kg/m^2. Physical examination is limited by pain. Which of the following substances most likely initiates the recurrent episodes of epigastric pain seen in this patient?

- ✓ A. Cholecystokinin (66%)
- ✗ B. Lactose (0%)
- C. Prostaglandin E_2 (16%)
- D. Secretin (11%)
- E. Serotonin (2%)
- F. Somatostatin (2%)

Incorrect
Correct answer
A

66%
Answered correctly

04 secs
Time Spent

2023
Version

Explanation

https://t.me/USMLEWorldStep1
Show all

A 43-year-old woman comes to the emergency department with severe epigastric pain that started after she ate a heavy
has no
ibupro
likely i

Exhibit Display

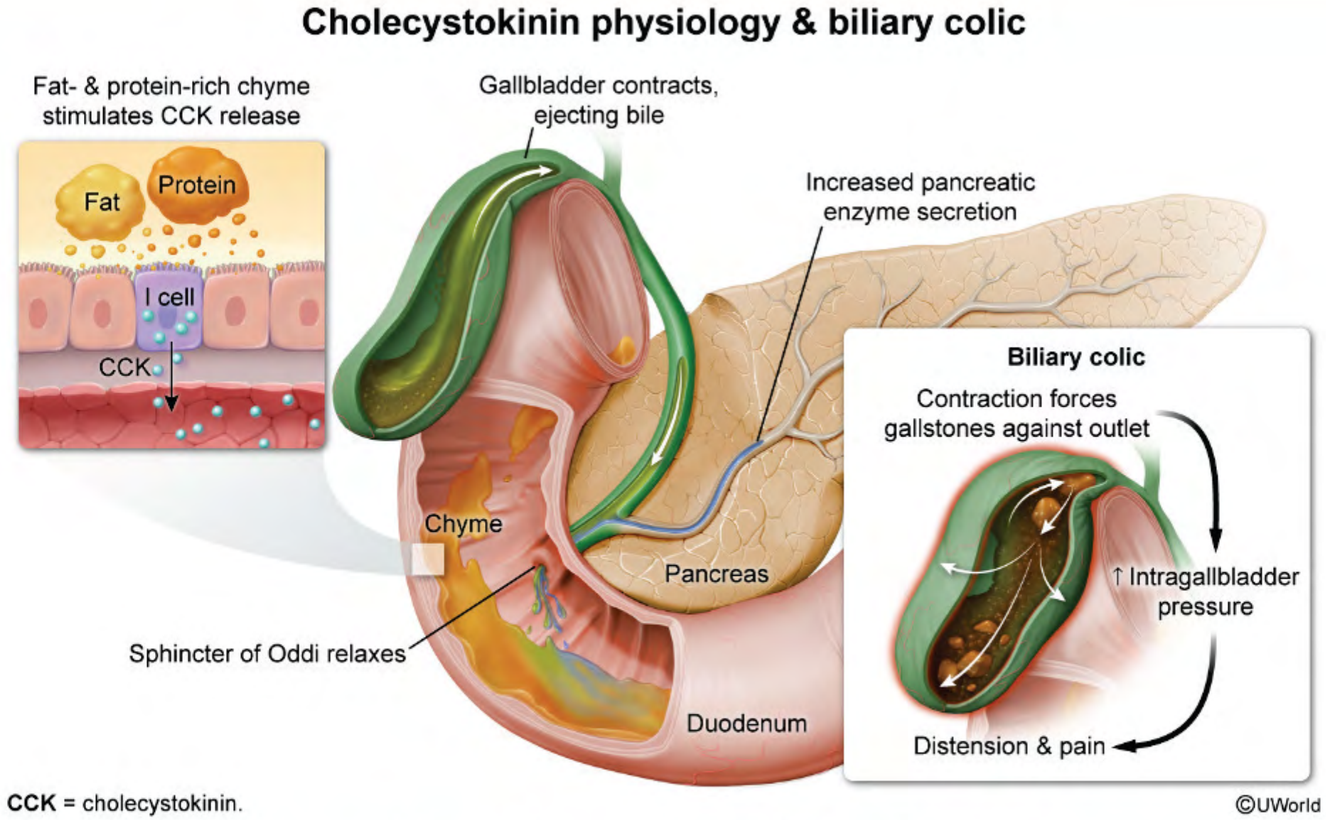

Zoom In | Zoom Out | Reset | New | Existing | My Notebook

https://t.me/USMLEWorldStep1

Show all

CCK = cholecystokinin.

©UWorld

This patient's recurrent epigastric pain after eating fat- and protein-rich meals strongly suggests **biliary colic** from underlying gallstones and/or biliary sludge. Most commonly, gallstones are cholesterol based, often developing in persons older than age 40. Elevated estrogen exposure (eg, female sex, obesity, pregnancy) significantly increases the risk because it stimulates cholesterol-rich bile secretion.

When bile becomes supersaturated with cholesterol, microscopic crystal formation creates a thick slurry (biliary sludge), with further aggregation producing gallstones. On detecting fat- and protein-rich chyme, I cells lining the duodenum and jejunum release the hormone **cholecystokinin** (CCK), causing the **gallbladder to contract**. This contraction may force gallstones and sludge against the gallbladder outlet; the resulting occlusion increases intragallbladder pressure, leading to pain that is typically felt in the **right subcostal or epigastric** region. As CCK levels wane, the gallstones and sludge fall back, relieving pressure (ie, a postprandial waxing-waning pain pattern).

In addition to stimulating gallbladder contraction, CCK also increases pancreatic enzyme secretion and relaxes the sphincter of Oddi, thereby orchestrating fatty and amino acid absorption.

(Choice B) Patients with lactose intolerance often have postprandial abdominal pain after ingesting dairy products. However, the pain usually occurs with bloating and diarrhea, symptoms not present in this patient.

(Choice C) Prostaglandins (eg, PGE2, PGI2) help protect the gastric mucosa from damage by acid; in contrast, excess consumption of nonsteroidal anti-inflammatory drugs can inhibit production of gastroprotective prostaglandins, increasing the risk for gastric ulcers that may cause postprandial epigastric pain.

(Choice D) Secretin is a hormone that stimulates the pancreas to secrete bicarbonate, helping to regulate pH in the duodenum. Although it also increases bicarbonate secretion by the biliary tract, it does not induce gallbladder contraction.

(Choice E) Carcinoid tumors can secrete high amounts of serotonin, causing flushing, diarrhea, and bronchospasm. They most commonly present with periodic abdominal pain, which arises from mesenteric fibrosis

https://t.me/USMLEWorldStep1
Show all

contraction may force gallstones and sludge against the gallbladder outlet; the resulting occlusion increases intragallbladder pressure, leading to pain that is typically felt in the **right subcostal or epigastric** region. As CCK levels wane, the gallstones and sludge fall back, relieving pressure (ie, a postprandial waxing-waning pain pattern).

In addition to stimulating gallbladder contraction, CCK also increases pancreatic enzyme secretion and relaxes the sphincter of Oddi, thereby orchestrating fatty and amino acid absorption.

(Choice B) Patients with lactose intolerance often have postprandial abdominal pain after ingesting dairy products. However, the pain usually occurs with bloating and diarrhea, symptoms not present in this patient.

(Choice C) Prostaglandins (eg, PGE2, PGI2) help protect the gastric mucosa from damage by acid; in contrast, excess consumption of nonsteroidal anti-inflammatory drugs can inhibit production of gastroprotective prostaglandins, increasing the risk for gastric ulcers that may cause postprandial epigastric pain.

(Choice D) Secretin is a hormone that stimulates the pancreas to secrete bicarbonate, helping to regulate pH in the duodenum. Although it also increases bicarbonate secretion by the biliary tract, it does not induce gallbladder contraction.

(Choice E) Carcinoid tumors can secrete high amounts of serotonin, causing flushing, diarrhea, and bronchospasm. They most commonly present with periodic abdominal pain, which arises from mesenteric fibrosis or bowel kinking/obstruction rather than increased serotonin.

(Choice F) Somatostatin suppresses gastrointestinal hormone release (eg, insulin, CCK, vasoactive intestinal peptide), reduces intestinal motility, and decreases splanchnic blood flow.

Educational objective:
The release of cholecystokinin (CCK) from the duodenum and jejunum after exposure to fat- and protein-rich meals stimulates gallbladder contraction. In patients with gallstones or biliary sludge, contraction can force the stones/sludge against the gallbladder outlet, causing temporary occlusion of outflow and increased intragallbladder pressure. This manifests as postprandial upper abdominal pain that waxes and wanes with CCK levels (biliary colic).

https://t.me/USMLEWorldStep1
Show all

A 45-year-old woman comes to the office for evaluation of dysphagia. The patient's symptoms first began 2 years ago with regurgitation and bloating after meals but have recently progressed to difficulty swallowing both solid foods and liquids. She has been using antacids without relief. The patient has no other medical history. She drinks 1 or 2 beers on weekends but does not smoke or use illicit drugs. Family history is unremarkable. Vital signs are within normal limits. BMI is 21 kg/m^2. The abdomen is nontender and soft with normal active bowel sounds. The patient undergoes upper endoscopy that shows a dilated esophagus and retained food. Esophageal manometry reveals increased lower esophageal sphincter (LES) tone and incomplete relaxation. Peristalsis is absent in the distal esophagus. Injection of which of the following into the patient's LES would most likely help relieve her symptoms?

- A. Botulinum toxin
- B. Corticosteroids
- C. Neostigmine
- D. Phenylephrine
- E. Pilocarpine

Submit

https://t.me/USMLEWorldStep1
Show all

A 45-year-old woman comes to the office for evaluation of dysphagia. The patient's symptoms first began 2 years ago with regurgitation and bloating after meals but have recently progressed to difficulty swallowing both solid foods and liquids. She has been using antacids without relief. The patient has no other medical history. She drinks 1 or 2 beers on weekends but does not smoke or use illicit drugs. Family history is unremarkable. Vital signs are within normal limits. BMI is 21 kg/m^2. The abdomen is nontender and soft with normal active bowel sounds. The patient undergoes upper endoscopy that shows a dilated esophagus and retained food. Esophageal manometry reveals increased lower esophageal sphincter (LES) tone and incomplete relaxation. Peristalsis is absent in the distal esophagus. Injection of which of the following into the patient's LES would most likely help relieve her symptoms?

- ✓ A. Botulinum toxin (78%)
- B. Corticosteroids (1%)
- C. Neostigmine (9%)
- D. Phenylephrine (2%)
- E. Pilocarpine (7%)

Correct | 78% Answered correctly | 03 secs Time Spent | 2023 Version

Explanation

Achalasia is an esophageal motility disorder characterized by the absence of esophageal peristalsis in the distal esophagus and incomplete relaxation of a **hypertonic lower esophageal sphincter** (LES). Achalasia is caused by the immune-mediated **destruction of inhibitory ganglion cells** in the esophageal wall. Nitric oxide–producing neurons in the myenteric plexus that are responsible for esophageal smooth muscle relaxation are preferentially

https://t.me/USMLEWorldStep1
Show all

Achalasia is an esophageal motility disorder characterized by the absence of esophageal peristalsis in the distal esophagus and incomplete relaxation of a **hypertonic lower esophageal sphincter** (LES). Achalasia is caused by the immune-mediated **destruction of inhibitory ganglion cells** in the esophageal wall. Nitric oxide–producing neurons in the myenteric plexus that are responsible for esophageal smooth muscle relaxation are preferentially destroyed, whereas excitatory cholinergic neurons responsible for smooth muscle contraction are relatively spared. This imbalance results in increased lower esophageal tone and impaired sphincter relaxation.

Botulinum toxin, a neurotoxin formed by *Clostridium botulinum*, prevents the fusion of acetylcholine-containing synaptic vesicles with the plasma membrane. This effectively prevents acetylcholine release into the neuromuscular synapse, resulting in muscle weakness and paralysis. In a patient with achalasia, injection of **botulinum toxin** into the LES causes **cholinergic blockade**, leading to sphincter relaxation and symptomatic improvement.

(Choices B and D) In addition to the cholinergic neurons, there are multiple other hormones and neurotransmitters that modulate esophageal tone. Prostaglandins promote LES relaxation, whereas alpha-adrenergic agonists, such as phenylephrine, increase LES tone. Because corticosteroids inhibit prostaglandin synthesis, both corticosteroids and phenylephrine would worsen the patient's symptoms.

(Choices C and E) Neostigmine is a cholinesterase inhibitor and pilocarpine is a cholinergic agonist. Both of these medications increase cholinergic stimuli at the LES and would worsen the patient's symptoms.

Educational objective:
Achalasia is caused by loss of inhibitory ganglion cells in the distal esophageal wall and is characterized by the absence of esophageal peristalsis and incomplete relaxation of a hypertonic lower esophageal sphincter. Botulinum toxin prevents acetylcholine release into the neuromuscular synapse, resulting in inhibition of cholinergic neurons and lower esophageal sphincter relaxation.

Pharmacology	Gastrointestinal & Nutrition	Achalasia
Subject	System	Topic

Copyright © UWorld. All rights reserved.

https://t.me/USMLEWorldStep1
Show all

Achalasia is an esophageal motility disorder characterized by the absence of esophageal peristalsis in the distal esophagus and incomplete relaxation of a **hypertonic lower esophageal sphincter** (LES). Achalasia is caused by the
neuron
destro
spared

Botulin
synapt
neuron
botuli
improv

(Choi
neurot
adrene
synthe

(Choi
these

Educa
Achala
absen
Botulin
neuron

Pharma
Subject

Exhibit Display

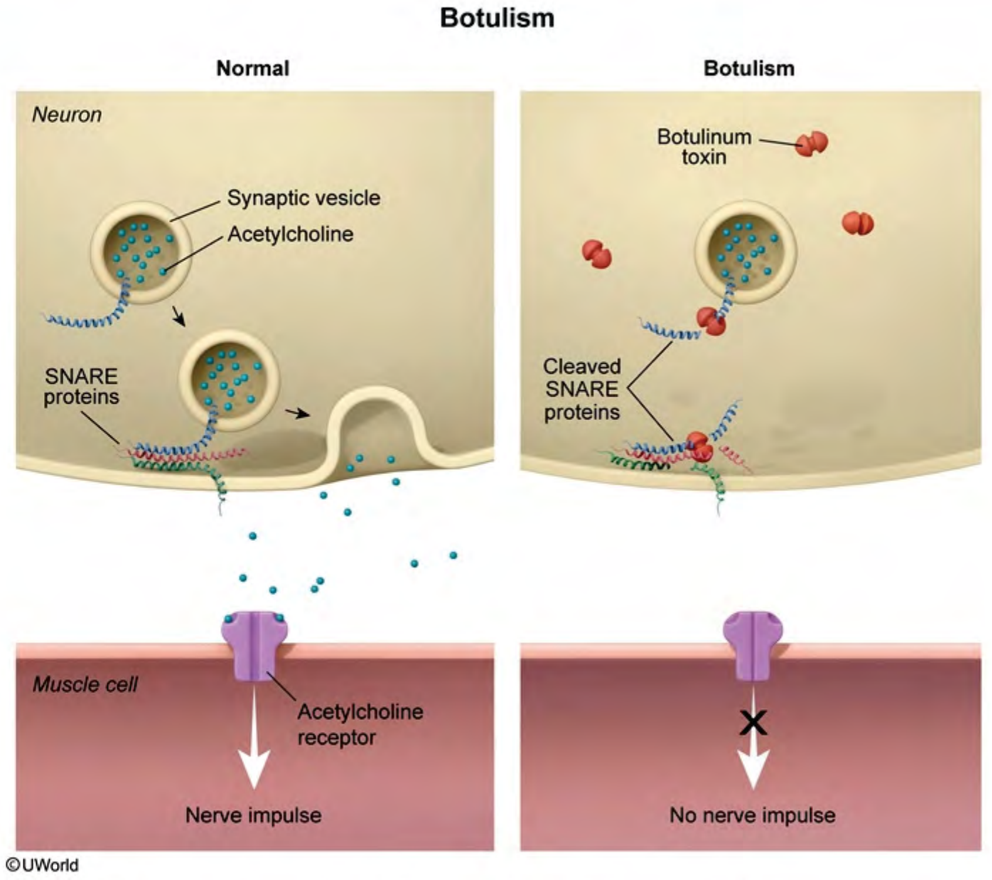

Zoom In Zoom Out Reset New | Existing My Notebook

https://t.me/USMLEWorldStep1

A 52-year-old man is brought to the emergency department for hematemesis that began an hour earlier. He has regularly consumed large amounts of alcohol for the last 20 years and has been hospitalized numerous times due to ethanol intoxication. Temperature is 36.7 C (98 F), blood pressure is 90/60 mm Hg, pulse is 106/min, and respirations are 22/min. Physical examination shows jaundice and scleral icterus. Examination of the abdomen reveals a palpable spleen and moderate ascites. Endoscopy reveals bleeding esophageal varices. This patient's current condition most likely resulted from chronic shunting of blood through which of the following veins?

- A. Left gastric
- B. Middle colic
- C. Paraumbilical
- D. Right gastroepiploic
- E. Splenic
- F. Superficial epigastric

Submit

https://t.me/USMLEWorldStep1
Show all

A 52-year-old man is brought to the emergency department for hematemesis that began an hour earlier. He has regularly consumed large amounts of alcohol for the last 20 years and has been hospitalized numerous times due to ethanol intoxication. Temperature is 36.7 C (98 F), blood pressure is 90/60 mm Hg, pulse is 106/min, and respirations are 22/min. Physical examination shows jaundice and scleral icterus. Examination of the abdomen reveals a palpable spleen and moderate ascites. Endoscopy reveals bleeding esophageal varices. This patient's current condition most likely resulted from chronic shunting of blood through which of the following veins?

- ✓ A. Left gastric (71%)
- B. Middle colic (0%)
- C. Paraumbilical (5%)
- D. Right gastroepiploic (5%)
- E. Splenic (10%)
- F. Superficial epigastric (6%)

Correct

71%
Answered correctly

03 secs
Time Spent

2023
Version

Explanation

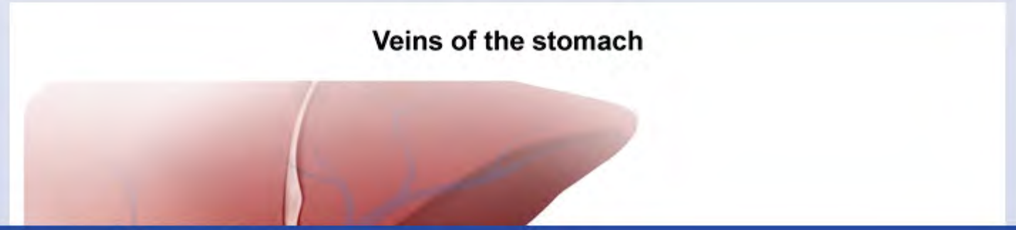

https://t.me/USMLEWorldStep1
Show all

A 52-year-old man is brought to the emergency department for hematemesis that began an hour earlier. He has
regula
to etha
respira
reveal
curren

Exhibit Display

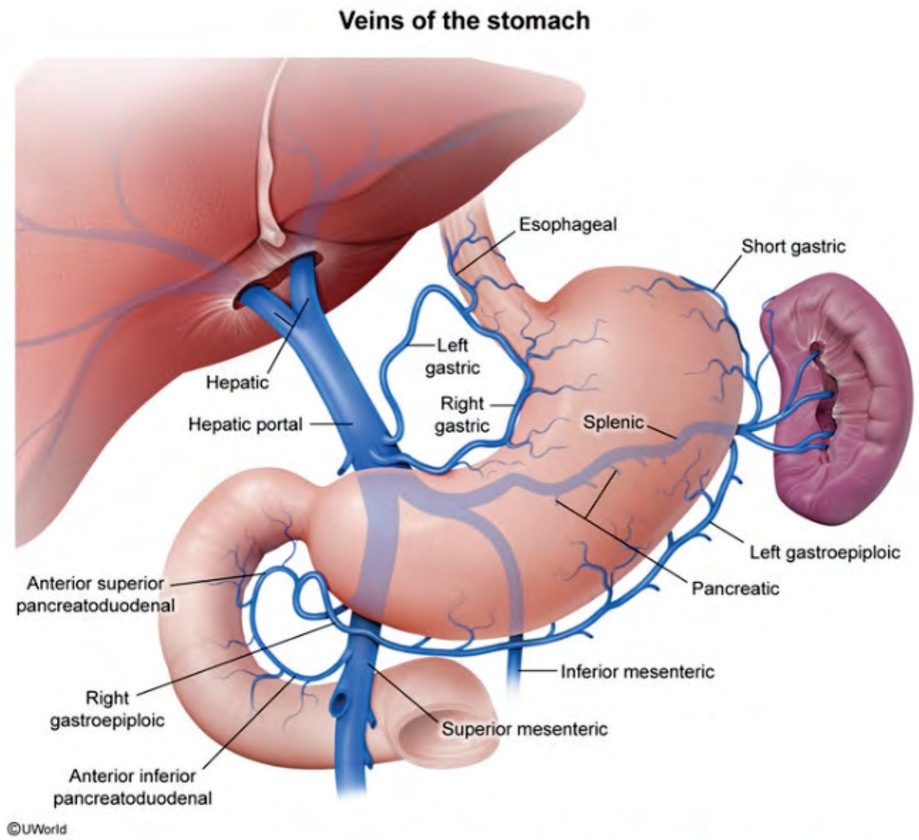

Zoom In Zoom Out Reset New | Existing My Notebook

https://t.me/USMLEWorldStep1

This patient has numerous cirrhotic stigmata including ascites, jaundice, and splenomegaly. An important cause of cirrhosis-related morbidity and mortality is the development of **variceal hemorrhaging** as a direct consequence of portal hypertension.

Cirrhosis (of any type) represents the end stage of progressive hepatic fibrosis. It is characterized by distortion of the hepatic architecture and formation of regenerative nodules. Cirrhosis is the most common cause of **portal hypertension**, which arises from increased resistance to portal flow at the hepatic sinusoids. Chronic portal hypertension leads to dilation of small, pre-existing vascular channels between the portal and systemic circulations. These dilated collateral vessels (portosystemic anastomoses) commonly form in the anterior abdomen (caput medusae), lower rectum (anorectal varices), and **inferior end of the esophagus** (esophageal varices).

Treatment sometimes includes inserting a transjugular intrahepatic portosystemic shunt (TIPS) between the portal vein and hepatic vein percutaneously, relieving portal hypertension by shunting blood to the systemic circulation.

(Choice B) The middle colic vein drains the transverse colon.

(Choices C and F) In cirrhosis, the paraumbilical veins can shunt blood from the portal system to superficial epigastric veins in the abdominal wall, causing caput medusae.

(Choice D) The right gastroepiploic vein drains venous blood from the inferior portions of the stomach. It runs along the greater curvature of the stomach.

(Choice E) The splenic vein drains blood from the spleen. It joins with the superior mesenteric vein to form the hepatic portal vein. Patients with portal hypertension can develop splenomegaly due to congestion of the splenic red pulp.

Educational objective:
In cirrhosis, portal hypertension arises from increased resistance to portal flow at the hepatic sinusoids. This causes increased pressure in the portosystemic collateral veins within the lower end of the esophagus, anterior abdomen, and lower rectum. Dilation of these collateral vessels is responsible for the esophageal varices, caput medusae, and anorectal varices commonly seen in patients with cirrhosis.

https://t.me/USMLEWorldStep1
Show all

Cirrhosis (of any type) represents the end stage of progressive hepatic fibrosis. It is characterized by distortion of the hepatic architecture and formation of regenerative nodules. Cirrhosis is the most common cause of **portal hypertension**, which arises from increased resistance to portal flow at the hepatic sinusoids. Chronic portal hypertension leads to dilation of small, pre-existing vascular channels between the portal and systemic circulations. These dilated collateral vessels (portosystemic anastomoses) commonly form in the anterior abdomen (caput medusae), lower rectum (anorectal varices), and **inferior end of the esophagus** (esophageal varices).

Treatment sometimes includes inserting a transjugular intrahepatic portosystemic shunt (TIPS) between the portal vein and hepatic vein percutaneously, relieving portal hypertension by shunting blood to the systemic circulation.

(Choice B) The middle colic vein drains the transverse colon.

(Choices C and F) In cirrhosis, the paraumbilical veins can shunt blood from the portal system to superficial epigastric veins in the abdominal wall, causing caput medusae.

(Choice D) The right gastroepiploic vein drains venous blood from the inferior portions of the stomach. It runs along the greater curvature of the stomach.

(Choice E) The splenic vein drains blood from the spleen. It joins with the superior mesenteric vein to form the hepatic portal vein. Patients with portal hypertension can develop splenomegaly due to congestion of the splenic red pulp.

Educational objective:
In cirrhosis, portal hypertension arises from increased resistance to portal flow at the hepatic sinusoids. This causes increased pressure in the portosystemic collateral veins within the lower end of the esophagus, anterior abdomen, and lower rectum. Dilation of these collateral vessels is responsible for the esophageal varices, caput medusae, and anorectal varices commonly seen in patients with cirrhosis.

Anatomy	Gastrointestinal & Nutrition	Cirrhosis
Subject	System	Topic

https://t.me/USMLEWorldStep1
Show all

Exhibit Display

Portacaval anastomoses		
Clinical manifestation	**Portal circulation**	**Systemic circulation**
Esophageal varices	Left gastric vein	Esophageal vein
Anorectal varices	Superior rectal vein	Middle & inferior rectal veins
Caput medusae	Paraumbilical veins	Superficial & inferior epigastric veins

New | Existing | My Notebook

This p
cirrhos
portal

Cirrho
the he
hyper
hypert
circula
abdom
varices

Treatm
vein a

(Choi

(Choi
epigas

(Choi
along

(Choi
hepati
red pu

Educational objective:

https://t.me/USMLEWorldStep1

Exhibit Display

Caput medusae

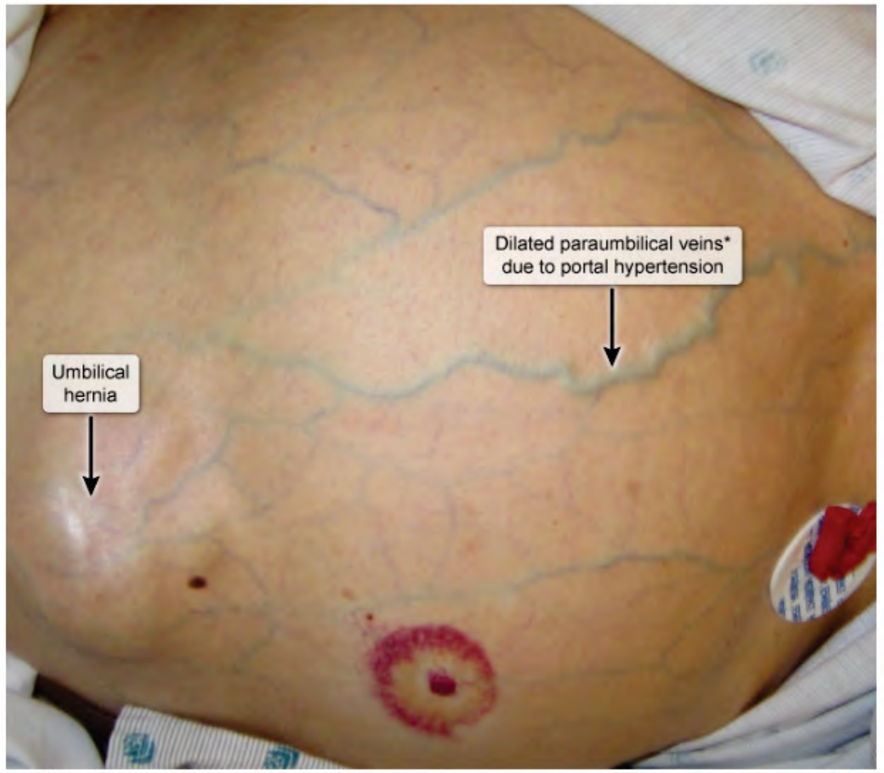

*Shunt blood from portal system to abdominal wall veins.

©UWorld

Zoom In | Zoom Out | Reset | New | Existing | My Notebook

This p
cirrhos
portal

Cirrho
the he
hyper
hypert
circula
abdom
varices

Treatm
vein a

(Choi

(Choi
epigas

(Choi
along

(Choi
hepati
red pu

Educational objective:

https://t.me/USMLEWorldStep1

A 42-year-old woman comes to the office due to frequent episodes of burning in her chest and small amounts of regurgitation after meals and at nighttime. Medical history includes hypertension. Vital signs are within normal limits. BMI is 30 kg/m^2. There is no abdominal tenderness and the remainder of the physical examination is normal. The patient shows the clinician an over-the-counter antacid that she has been taking to relieve her symptoms. The preparation contains a combination of magnesium and aluminum hydroxide. Which of the following is the most likely rationale for combining both mineral salts in this antacid preparation?

- A. Improve systemic absorption
- B. Minimize drug interactions
- C. Prevent rebound acid secretion
- D. Reduce adverse effects
- E. Reduce the risk of alkalosis and renal failure

Submit

https://t.me/USMLEWorldStep1
Show all

A 42-year-old woman comes to the office due to frequent episodes of burning in her chest and small amounts of regurgitation after meals and at nighttime. Medical history includes hypertension. Vital signs are within normal limits. BMI is 30 kg/m^2. There is no abdominal tenderness and the remainder of the physical examination is normal. The patient shows the clinician an over-the-counter antacid that she has been taking to relieve her symptoms. The preparation contains a combination of magnesium and aluminum hydroxide. Which of the following is the most likely rationale for combining both mineral salts in this antacid preparation?

- A. Improve systemic absorption (9%)
- ✗ B. Minimize drug interactions (3%)
- C. Prevent rebound acid secretion (19%)
- ✓ D. Reduce adverse effects (55%)
- E. Reduce the risk of alkalosis and renal failure (12%)

Incorrect
Correct answer
D

55%
Answered correctly

03 secs
Time Spent

2023
Version

Explanation

Magnesium salts (eg, magnesium trisilicate, magnesium hydroxide) and aluminum hydroxide are **weak alkali mineral salts**. They temporarily **increase the gastric pH** by neutralizing hydrochloric acid, helping to **relieve gastroesophageal reflux** symptoms.

Aluminum hydroxide has a tendency to cause **constipation** due to interactions with intestinal secretions that form insoluble salts. In contrast, **magnesium** salts cause osmotic **diarrhea**. Therefore, the two medications are combined to offset the adverse effects of the individual medications. Patients with reflux symptoms and chronic

https://t.me/USMLEWorldStep1
Show all

Magnesium salts (eg, magnesium trisilicate, magnesium hydroxide) and aluminum hydroxide are **weak alkali mineral salts**. They temporarily **increase the gastric pH** by neutralizing hydrochloric acid, helping to **relieve gastroesophageal reflux** symptoms.

Aluminum hydroxide has a tendency to cause **constipation** due to interactions with intestinal secretions that form insoluble salts. In contrast, **magnesium** salts cause osmotic **diarrhea**. Therefore, the two medications are combined to offset the adverse effects of the individual medications. Patients with reflux symptoms and chronic constipation may benefit from magnesium salt monotherapy, whereas aluminum hydroxide monotherapy may be of value in patients with chronic diarrhea.

(Choice A) Aluminum, when absorbed in large doses, causes osteomalacia, bone pain, hypercalcemia, and dementia. Aluminum absorption in the gastrointestinal tract is minimal from the salt form, and toxicity tends to occur in patients with chronic kidney disease that limits renal excretion. Combination therapy does not alter systemic absorption.

(Choice B) Drug interactions are common with antacid medications, largely due to pH-related changes in protein binding, absorption, or elimination of the drugs. Combining multiple alkalinizing agents would not minimize their effects on other drugs.

(Choice C) Rebound acid hypersecretion can occur with calcium carbonate, magnesium hydroxide, aluminum hydroxide, and proton pump inhibitors. This is likely due to increased gastrin release as a result of gastric alkalinization or (in the case of calcium salts) direct ionic stimulation.

(Choice E) Milk-alkali syndrome is caused by excessive use of calcium carbonate antacids and is characterized by hypercalcemia, alkalosis, and renal dysfunction. Kidney injury occurs due to both hypercalcemia-induced renal vasoconstriction and calcium-induced diuresis. The resultant volume depletion, decreased glomerular filtration rate, and alkali intake lead to a metabolic alkalosis. However, severe alkalosis can occur with all antacids, and the combination of magnesium and aluminum would not decrease this risk.

Educational objective:
Magnesium salts and aluminum hydroxide are basic mineral salts used to neutralize gastric acid and relieve

https://t.me/USMLEWorldStep1
Show all

Aluminum hydroxide has a tendency to cause **constipation** due to interactions with intestinal secretions that form insoluble salts. In contrast, **magnesium** salts cause osmotic **diarrhea**. Therefore, the two medications are combined to offset the adverse effects of the individual medications. Patients with reflux symptoms and chronic constipation may benefit from magnesium salt monotherapy, whereas aluminum hydroxide monotherapy may be of value in patients with chronic diarrhea.

(Choice A) Aluminum, when absorbed in large doses, causes osteomalacia, bone pain, hypercalcemia, and dementia. Aluminum absorption in the gastrointestinal tract is minimal from the salt form, and toxicity tends to occur in patients with chronic kidney disease that limits renal excretion. Combination therapy does not alter systemic absorption.

(Choice B) Drug interactions are common with antacid medications, largely due to pH-related changes in protein binding, absorption, or elimination of the drugs. Combining multiple alkalinizing agents would not minimize their effects on other drugs.

(Choice C) Rebound acid hypersecretion can occur with calcium carbonate, magnesium hydroxide, aluminum hydroxide, and proton pump inhibitors. This is likely due to increased gastrin release as a result of gastric alkalinization or (in the case of calcium salts) direct ionic stimulation.

(Choice E) Milk-alkali syndrome is caused by excessive use of calcium carbonate antacids and is characterized by hypercalcemia, alkalosis, and renal dysfunction. Kidney injury occurs due to both hypercalcemia-induced renal vasoconstriction and calcium-induced diuresis. The resultant volume depletion, decreased glomerular filtration rate, and alkali intake lead to a metabolic alkalosis. However, severe alkalosis can occur with all antacids, and the combination of magnesium and aluminum would not decrease this risk.

Educational objective:
Magnesium salts and aluminum hydroxide are basic mineral salts used to neutralize gastric acid and relieve gastroesophageal reflux symptoms. Side effects include diarrhea and constipation, respectively. Therefore, these medications are often combined to offset the adverse effects of the individual medications.

https://t.me/USMLEWorldStep1
Show all

A pharmaceutical researcher is trying to develop a vaccine against the hepatitis C virus. She infects a chimpanzee with hepatitis C virus of known genotype and subtype. Several weeks later, a liver sample is obtained, and viral RNAs are extracted from the hepatocytes. A genetic study of the viral genomes reveals that the extracted RNA sequences vary significantly from that of the original infecting virus. This genetic instability is most likely due to the lack of which of the following features during the viral replication process?

- A. 3' → 5' exonuclease activity
- B. 5' → 3' exonuclease activity
- C. Glycosylase activity
- D. Ligase activity
- E. Nucleotide specificity
- F. Primase activity

Submit

https://t.me/USMLEWorldStep1
Show all

A pharmaceutical researcher is trying to develop a vaccine against the hepatitis C virus. She infects a chimpanzee with hepatitis C virus of known genotype and subtype. Several weeks later, a liver sample is obtained, and viral RNAs are extracted from the hepatocytes. A genetic study of the viral genomes reveals that the extracted RNA sequences vary significantly from that of the original infecting virus. This genetic instability is most likely due to the lack of which of the following features during the viral replication process?

- ✓ A. 3' → 5' exonuclease activity (67%)
- ✗ B. 5' → 3' exonuclease activity (20%)
- C. Glycosylase activity (2%)
- D. Ligase activity (2%)
- E. Nucleotide specificity (5%)
- F. Primase activity (2%)

Incorrect
Correct answer
A

67%
Answered correctly

03 secs
Time Spent

2023
Version

Explanation

Hepatitis C virus (HCV) has ≥6 genotypes and multiple subgenotypes. These variant strains differ primarily at **hypervariable** genomic regions, such as those found in the sequences encoding its 2 **envelope glycoproteins**. Moreover, there is **no proofreading 3' → 5'** exonuclease activity built into the virion-encoded RNA polymerase. As a result, the RNA polymerase makes many errors during replication, and several dozen subspecies of HCV are typically present in the blood of an infected individual at any one time.

(Choice B) 5' → 3' exonuclease activity allows DNA polymerase I to engage in nick translation, which is important

https://t.me/USMLEWorldStep1
Show all

Hepatitis C virus (HCV) has ≥6 genotypes and multiple subgenotypes. These variant strains differ primarily at **hypervariable** genomic regions, such as those found in the sequences encoding its 2 **envelope glycoproteins**. Moreover, there is **no proofreading 3' → 5'** exonuclease activity built into the virion-encoded RNA polymerase. As a result, the RNA polymerase makes many errors during replication, and several dozen subspecies of HCV are typically present in the blood of an infected individual at any one time.

(Choice B) 5' → 3' exonuclease activity allows DNA polymerase I to engage in nick translation, which is important for both DNA repair and removal of RNA primers during replication. This feature is not the cause of instability in HCV.

(Choice C) DNA glycosylase is important in base excision repair as it removes the nitrogen base from the sugar-phosphate backbone. An endonuclease then completes the remainder of the repair. This enzyme is not the cause of instability in HCV.

(Choice D) DNA ligase is used to join 2 fragments of DNA and is therefore necessary for both DNA repair and replication. The HCV genome is a single-stranded, positive-sense RNA molecule that does not require ligase activity during replication.

(Choice E) Nucleotide specificity refers to the importance of inserting the correct nucleotide (eg, adenine, guanine, cytosine, thymine, uracil) into a strand of DNA or RNA. It is not the cause of instability in HCV.

(Choice F) DNA primase is a form of RNA polymerase. In bacteria, it binds with DNA helicase and synthesizes a short RNA primer to which nucleotides can be added by DNA polymerase. This enzyme is not the cause of instability in HCV.

Educational objective:
The hepatitis C virus is genetically unstable because it lacks proofreading 3' → 5' exonuclease activity in its RNA polymerase. Its envelope glycoprotein sequences also contain a hypervariable region prone to frequent genetic mutation.

Microbiology Gastrointestinal & Nutrition Hepatitis c

https://t.me/USMLEWorldStep1
Show all

A 34-year-old woman comes to the office with recent onset of malaise. The patient reports feeling "run down and under the weather" but otherwise has no symptoms. She is an avid cyclist and is concerned about her ability to participate in a charity race in 3 days. The patient works as a nurse at a local hospital and lives at home with her husband and 2-year-old son. She occasionally smokes when she goes out, but since she began feeling ill, she no longer has the desire to smoke. Physical examination is notable for hepatomegaly. Laboratory results are as follows:

Anti-HAV IgM	positive
Anti-HAV IgG	negative
HBsAg	negative
HBeAg	negative
Anti-HBs	positive
Anti-HBc	negative
Anti-HBe	negative
Anti-HCV	negative

Which of the following is most likely to be elicited on further history taking?

- A. Had a tattoo recently at a local tattoo parlor
- B. Had an accidental needlestick exposure at work
- C. Had boiled eggs from the hospital cafeteria
- D. Had steamed oysters at a neighborhood restaurant
- E. Had unprotected sexual intercourse with a new partner

https://t.me/USMLEWorldStep1
Show all

participate in a charity race in 3 days. The patient works as a nurse at a local hospital and lives at home with her husband and 2-year-old son. She occasionally smokes when she goes out, but since she began feeling ill, she no longer has the desire to smoke. Physical examination is notable for hepatomegaly. Laboratory results are as follows:

Anti-HAV IgM	positive
Anti-HAV IgG	negative
HBsAg	negative
HBeAg	negative
Anti-HBs	positive
Anti-HBc	negative
Anti-HBe	negative
Anti-HCV	negative

Which of the following is most likely to be elicited on further history taking?

- A. Had a tattoo recently at a local tattoo parlor (1%)
- B. Had an accidental needlestick exposure at work (10%)
- C. Had boiled eggs from the hospital cafeteria (8%)
- ✓ D. Had steamed oysters at a neighborhood restaurant (75%)
- E. Had unprotected sexual intercourse with a new partner (3%)

Correct

75% Answered correctly

05 secs Time Spent

2023 Version

https://t.me/USMLEWorldStep1
Show all

Hepatitis A infection is caused by an RNA picornavirus with an average incubation period of 30 days. Transmission occurs through the **fecal-oral** route and is common in areas with overcrowding and poor sanitation. Outbreaks frequently result from **contaminated water or food**, with raw or steamed **shellfish** being the typical (and classically tested) culprit in the United States. Onset is acute, and symptoms can include malaise, fatigue, anorexia, nausea, vomiting, mild abdominal pain, and an aversion to smoking (for unclear reasons). Hepatomegaly is commonly seen. Serum aminotransferases spike early in the illness, followed by increases in bilirubin and alkaline phosphatase. Anti-HAV IgM is positive and is a marker of active disease. Hepatitis A infection is a self-limiting disease and does not progress to chronic hepatitis, cirrhosis, or hepatocellular carcinoma.

Treatment is largely supportive, with complete recovery expected in 3-6 weeks. People considered at high risk (eg, those living in or traveling to endemic areas, those with chronic liver disease or clotting factor disorders, men who have sex with men) should be given the hepatitis A vaccine as prophylaxis. Unvaccinated close contacts of individuals with hepatitis A should receive the vaccine or immune globulin.

(Choices A, B, and E) Unsanitary tattooing (eg, with contaminated needles), accidental needlesticks, and unprotected sexual intercourse are important risk factors for hepatitis B and C. This patient is positive for HBsAb, which confirms that she has antibodies to hepatitis B surface antigen and, given the negative anti-HBc, suggests that she has been vaccinated and is now immune.

(Choice C) The consumption of boiled eggs is not commonly associated with hepatitis A infection. If the boiled eggs were insufficiently cooked, *Salmonella* infection would be a risk.

Educational objective:
Transmission of the hepatitis A virus occurs through the fecal-oral route and is common in areas with overcrowding and poor sanitation. Outbreaks frequently result from contaminated water or food, and raw or steamed shellfish is a common culprit in the United States.

References

- Risk assessment in shellfish-borne outbreaks of hepatitis A.

https://t.me/USMLEWorldStep1
Show all

A group of researchers investigates why individuals who have undergone gastrectomy lose more weight than can be explained by dietary changes alone. They recruit several subjects who have had distal gastrectomy for benign gastric-outlet obstruction for a clinical study. Control subjects with matching baseline weight are also enrolled and are instructed to follow a diet similar to that of the postgastrectomy subjects during the study period. Plasma levels of several hormones are serially measured over 24 hours in both groups. Levels of one of the hormones are shown in the graph below:

This profile most likely represents which of the following hormones?

- A. Cholecystokinin
- B. Gastrin
- C. Ghrelin
- D. Insulin
- E. Leptin
- F. Motilin

Submit

https://t.me/USMLEWorldStep1
Show all

A group of researchers investigates why individuals who have undergone gastrectomy lose more weight than can be exp
gastric
are ins
of sev
shown

Exhibit Display

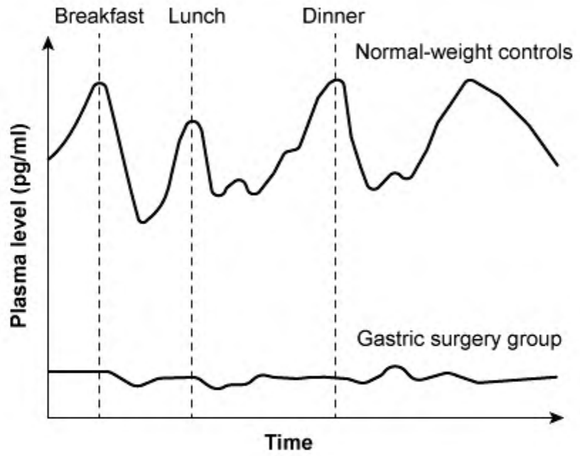

Zoom In Zoom Out Reset New | Existing My Notebook

This p

E. Leptin

https://t.me/USMLEWorldStep1
Show all

are instructed to follow a diet similar to that of the postgastrectomy subjects during the study period. Plasma levels of several hormones are serially measured over 24 hours in both groups. Levels of one of the hormones are shown in the graph below:

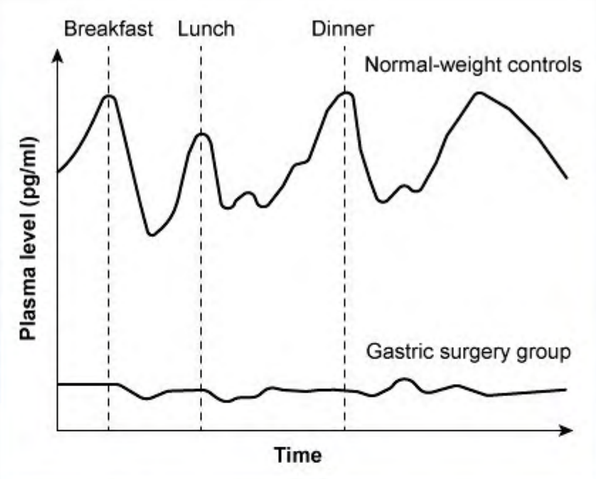

This profile most likely represents which of the following hormones?

- A. Cholecystokinin
- B. Gastrin
- C. Ghrelin
- D. Insulin
- E. Leptin
- F. Motilin

Submit

https://t.me/USMLEWorldStep1
Show all

are instructed to follow a diet similar to that of the postgastrectomy subjects during the study period. Plasma levels of several hormones are serially measured over 24 hours in both groups. Levels of one of the hormones are shown in the graph below:

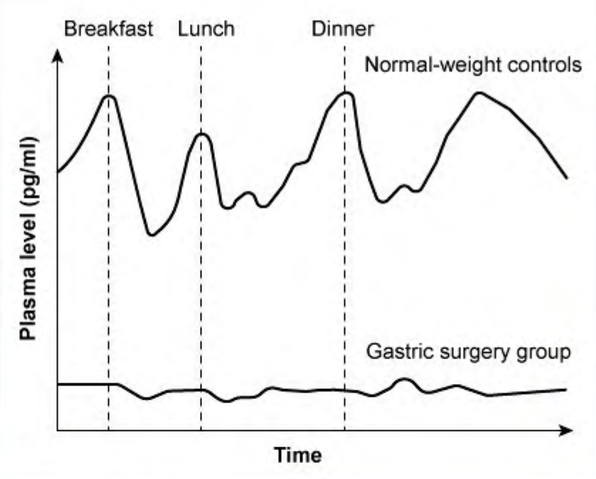

This profile most likely represents which of the following hormones?

- A. Cholecystokinin (3%)
- B. Gastrin (21%)
- ✓ C. Ghrelin (63%)
- D. Insulin (4%)
- ✗ E. Leptin (4%)
- F. Motilin (1%)

Incorrect

63% 11 secs 2023

https://t.me/USMLEWorldStep1
Show all

F. Motilin (1%)

Exhibit Display

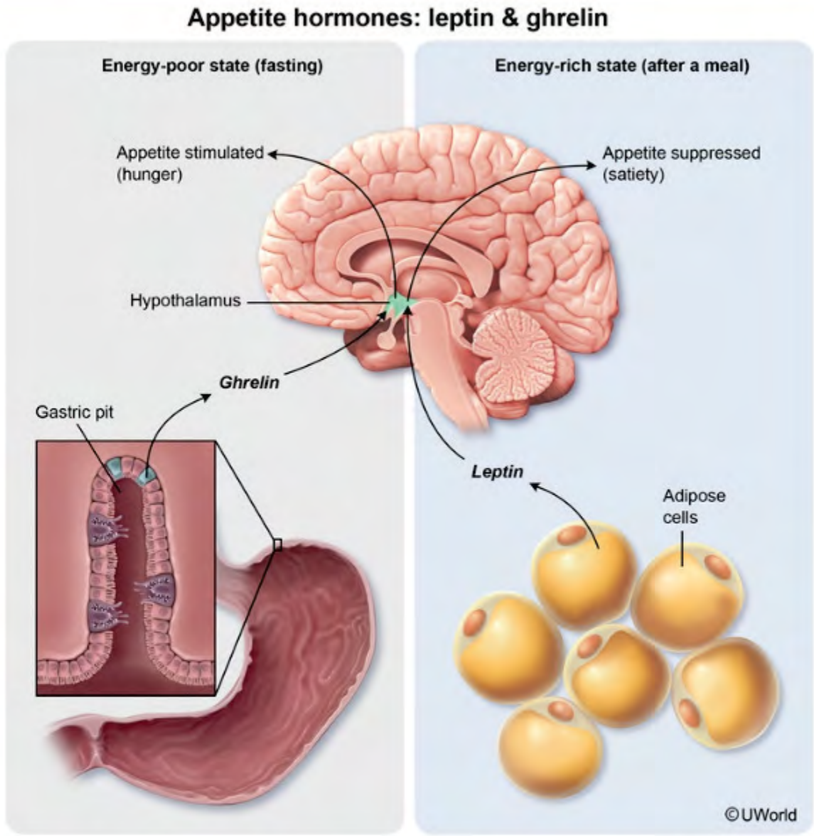

Zoom In | Zoom Out | Reset | New | Existing | My Notebook

https://t.me/USMLEWorldStep1

Show all

©UWorld

The 24-hour hormone levels in the control subjects show increasing secretion leading up to meals, followed by a sharp postprandial drop. However, the subjects who have undergone gastrectomy show lower baseline levels with attenuation of meal-related fluctuations. This pattern suggests that the hormone is likely secreted in the stomach and suppressed by food intake, which is consistent with the secretory pattern of **ghrelin**.

Ghrelin is **produced primarily in the stomach** in response to **fasting**; levels surge leading up to meals and fall after eating. Ghrelin **stimulates appetite** and promotes **weight gain**. Caloric restriction and falling fat stores lead to increased ghrelin levels (along with decreased leptin and insulin levels), which limits weight loss from dietary modification alone. However, patients who have undergone bariatric procedures that remove a portion of the stomach (eg, roux-en-Y gastric bypass, sleeve **gastrectomy**) can lose a significant number of ghrelin-secreting cells. This leads to **lower ghrelin levels** and less stimulation of appetite in response to fasting, promoting weight loss.

(Choice A) Cholecystokinin stimulates gallbladder contraction and pancreatic enzyme and bicarbonate secretion. It is secreted in the duodenum and jejunum in response to fat and protein in the intestinal lumen, and levels rise following meals.

(Choice B) Gastrin stimulates parietal cell acid production. It is secreted primarily by G cells of the gastric antrum in response to vagal activity, gastric distension, and the presence of amino acids in the gastric lumen. Although gastrin production would be lower in the postgastrectomy subjects, gastrin levels normally rise (not fall) in response to meals.

(Choice D) Insulin levels rise rapidly in response to increased blood glucose following meals then gradually fall back to baseline. Insulin is secreted by pancreatic beta cells and would not be drastically reduced following gastrectomy.

(Choice E) Leptin is produced primarily by fat cells in response to short-term food intake and long-term adequacy of fat stores. It acts on the hypothalamus to decrease appetite (obesity blunts this action). During fasting states,

https://t.me/USMLEWorldStep1
Show all

stomach (eg, roux-en-Y gastric bypass, sleeve **gastrectomy**) can lose a significant number of ghrelin-secreting cells. This leads to **lower ghrelin levels** and less stimulation of appetite in response to fasting, promoting weight loss.

(Choice A) Cholecystokinin stimulates gallbladder contraction and pancreatic enzyme and bicarbonate secretion. It is secreted in the duodenum and jejunum in response to fat and protein in the intestinal lumen, and levels rise following meals.

(Choice B) Gastrin stimulates parietal cell acid production. It is secreted primarily by G cells of the gastric antrum in response to vagal activity, gastric distension, and the presence of amino acids in the gastric lumen. Although gastrin production would be lower in the postgastrectomy subjects, gastrin levels normally rise (not fall) in response to meals.

(Choice D) Insulin levels rise rapidly in response to increased blood glucose following meals then gradually fall back to baseline. Insulin is secreted by pancreatic beta cells and would not be drastically reduced following gastrectomy.

(Choice E) Leptin is produced primarily by fat cells in response to short-term food intake and long-term adequacy of fat stores. It acts on the hypothalamus to decrease appetite (obesity blunts this action). During fasting states, leptin levels fall.

(Choice F) Motilin stimulates smooth muscle contraction in the upper gastrointestinal tract and generally increases gastric motility. Although secretion appears to increase during fasting and decrease following meals, it is produced primarily in the duodenal mucosa rather than the stomach.

Educational objective:
Ghrelin is produced in the stomach in response to fasting; levels surge leading up to meals and fall after eating. Ghrelin stimulates appetite and promotes weight gain. Patients who have undergone gastrectomy have reduced ghrelin levels, leading to weight loss.

References

https://t.me/USMLEWorldStep1
Show all

Exhibit Display

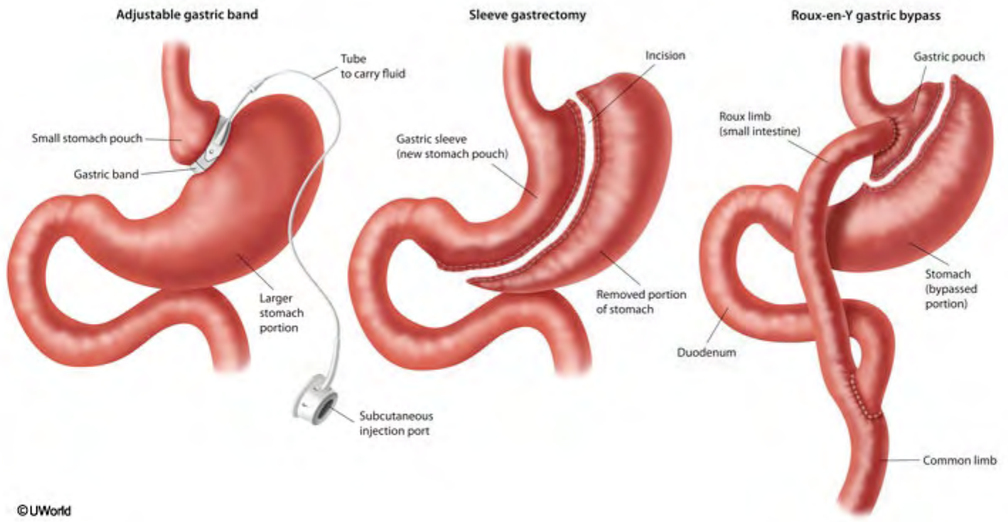

Zoom In | Zoom Out | Reset | New | Existing | My Notebook

The 24
sharp
attenu
and su

Ghreli
after e
to incr
modifi
stoma
cells.
loss.

(Choi
It is se
followi

(Choi
in resp
gastrin production would be lower in the postgastrectomy subjects, gastrin levels normally rise (not fall) in response

https://t.me/USMLEWorldStep1

A 70-year old man comes to the office due to persistent aspiration. Two weeks ago, he had a stroke that impacted his speech, voice, and swallowing. Modified barium swallow study reveals aspiration of liquids without nasal regurgitation. Aspiration is ameliorated when the patient flexes his neck to put his chin to his chest during swallowing. This maneuver is most likely augmenting which of the following airway-protective mechanisms?

- A. Improvement of mastication
- B. Elevation of the soft palate
- C. Contraction of the base of tongue
- D. Superior displacement of the larynx
- E. Adduction of the vocal folds

Submit

https://t.me/USMLEWorldStep1

A 70-year old man comes to the office due to persistent aspiration. Two weeks ago, he had a stroke that impacted his speech, voice, and swallowing. Modified barium swallow study reveals aspiration of liquids without nasal regurgitation. Aspiration is ameliorated when the patient flexes his neck to put his chin to his chest during swallowing. This maneuver is most likely augmenting which of the following airway-protective mechanisms?

- A. Improvement of mastication (0%)
- ✗ B. Elevation of the soft palate (27%)
- C. Contraction of the base of tongue (12%)
- ✓ D. Superior displacement of the larynx (49%)
- E. Adduction of the vocal folds (9%)

Incorrect
Correct answer
D

49%
Answered correctly

03 secs
Time Spent

2023
Version

Explanation

Normal **swallowing** involves a complex sequence of voluntary and reflexive processes that move food from the mouth to the esophagus while preventing it from entering the airway (ie, aspiration). Three main **airway-protective movements** occur during normal swallowing:

- **Displacement of the larynx superiorly** and anteriorly under the base of tongue, which allows food to be directed into the more posteriorly located esophagus
- **Tilting of the epiglottis** to block the airway
- Closing of the glottis by **adduction of the vocal folds**

https://t.me/USMLEWorldStep1
Show all

Normal **swallowing** involves a complex sequence of voluntary and reflexive processes that move food from the mouth to the esophagus while preventing it from entering the airway (ie, aspiration). Three main **airway-protective movements** occur during normal swallowing:

- **Displacement of the larynx superiorly** and anteriorly under the base of tongue, which allows food to be directed into the more posteriorly located esophagus
- **Tilting of the epiglottis** to block the airway
- Closing of the glottis by **adduction of the vocal folds**

Because of the complexity of swallowing, patients who sustain **strokes** often have persistent **dysphagia and/or aspiration**. If a neurologic deficit cannot be corrected, behavioral modifications can sometimes improve the safety of swallowing. A **chin-tuck maneuver** (ie, flexion of the head and neck during swallowing) sometimes helps. The maneuver seems to decrease the distance from the hyoid bone to the larynx (**simulating elevation of the larynx**), as well as to narrow the distance of the laryngeal entrance, leading to decreased aspiration.

(Choice A) The first phase of swallowing is the oral preparatory phase, in which food is chewed and mixed with saliva to form a controlled bolus. Although impaired mastication can lead to poor bolus formation, flexion of the head and neck does not generally change the mechanics of mastication.

(Choice B) Elevation of the soft palate primarily prevents food from entering the nasopharynx rather than the larynx.

(Choice C) Contraction of the base of tongue occurs during the pharyngeal phase of swallowing and pushes the bolus posteriorly into the pharynx. Head and neck flexion could potentially worsen this function by increasing the distance that the base of tongue has to contract and by increasing the anterior force on the tongue due to gravity.

(Choice E) Although adduction of the vocal folds is an important airway-protective mechanism, head and neck flexion would not alter vocal fold movement.

https://t.me/USMLEWorldStep1
Show all

- **Tilting of the epiglottis** to block the airway
- Closing of the glottis by **adduction of the vocal folds**

Because of the complexity of swallowing, patients who sustain **strokes** often have persistent **dysphagia and/or aspiration**. If a neurologic deficit cannot be corrected, behavioral modifications can sometimes improve the safety of swallowing. A **chin-tuck maneuver** (ie, flexion of the head and neck during swallowing) sometimes helps. The maneuver seems to decrease the distance from the hyoid bone to the larynx (**simulating elevation of the larynx**), as well as to narrow the distance of the laryngeal entrance, leading to decreased aspiration.

(Choice A) The first phase of swallowing is the oral preparatory phase, in which food is chewed and mixed with saliva to form a controlled bolus. Although impaired mastication can lead to poor bolus formation, flexion of the head and neck does not generally change the mechanics of mastication.

(Choice B) Elevation of the soft palate primarily prevents food from entering the nasopharynx rather than the larynx.

(Choice C) Contraction of the base of tongue occurs during the pharyngeal phase of swallowing and pushes the bolus posteriorly into the pharynx. Head and neck flexion could potentially worsen this function by increasing the distance that the base of tongue has to contract and by increasing the anterior force on the tongue due to gravity.

(Choice E) Although adduction of the vocal folds is an important airway-protective mechanism, head and neck flexion would not alter vocal fold movement.

Educational objective:
The most important airway-protective movements during swallowing are the anterior/superior displacement of the larynx, the tilting of the epiglottis to block the airway, and vocal fold adduction. A chin-tuck maneuver can be helpful in some patients with aspiration by simulating the airway-protective movement of the larynx.

Physiology	Gastrointestinal & Nutrition	Dysphagia
Subject	System	Topic

https://t.me/USMLEWorldStep1
Show all

A 6-week-old boy is brought to the clinic due to frequent emesis. For the last month, after most feedings, the patient spits up a moderate amount of partially digested breast milk that often also dribbles out his nares. He appears unbothered by the emesis. The patient has been exclusively breastfed since birth and continues to feed well. Weight and height have been tracking at the 70th percentile and head circumference along the 80th percentile. Physical examination shows a well-hydrated infant with no abnormalities. Which of the following is the most likely explanation for this patient's emesis?

- A. Abnormal communication between the trachea and the esophagus
- B. Increased pressure on the area postrema of the medulla
- C. Non–IgE-mediated allergy to proteins in breast milk
- D. Physiologic low tone of the lower esophageal sphincter
- E. Smooth muscle hypertrophy of the gastric outlet

Submit

21877.mp4
https://t.me/USMLEWorldStep1
Show all

A 6-week-old boy is brought to the clinic due to frequent emesis. For the last month, after most feedings, the patient spits up a moderate amount of partially digested breast milk that often also dribbles out his nares. He appears unbothered by the emesis. The patient has been exclusively breastfed since birth and continues to feed well. Weight and height have been tracking at the 70th percentile and head circumference along the 80th percentile. Physical examination shows a well-hydrated infant with no abnormalities. Which of the following is the most likely explanation for this patient's emesis?

- A. Abnormal communication between the trachea and the esophagus (21%)
- ✕ B. Increased pressure on the area postrema of the medulla (5%)
- C. Non–IgE-mediated allergy to proteins in breast milk (3%)
- ✓ D. Physiologic low tone of the lower esophageal sphincter (47%)
- E. Smooth muscle hypertrophy of the gastric outlet (21%)

Incorrect
Correct answer
D

47%
Answered correctly

04 secs
Time Spent

2023
Version

Explanation

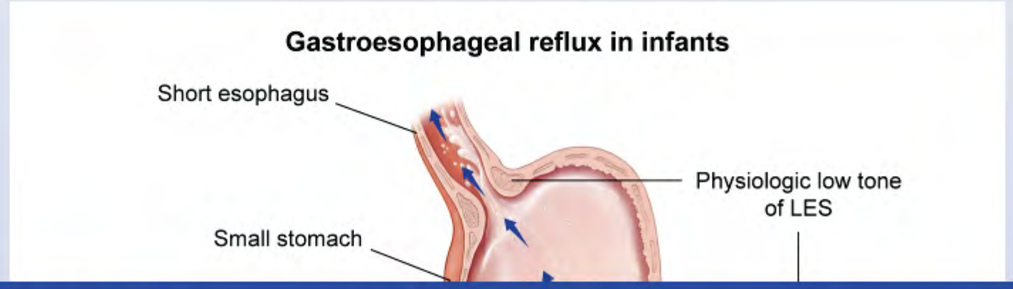

21877.mp4
https://t.me/USMLEWorldStep1
Show all

A 6-week-old boy is brought to the clinic due to frequent emesis. For the last month, after most feedings, the patien
appea
well. V
percer
most li

Exhibit Display

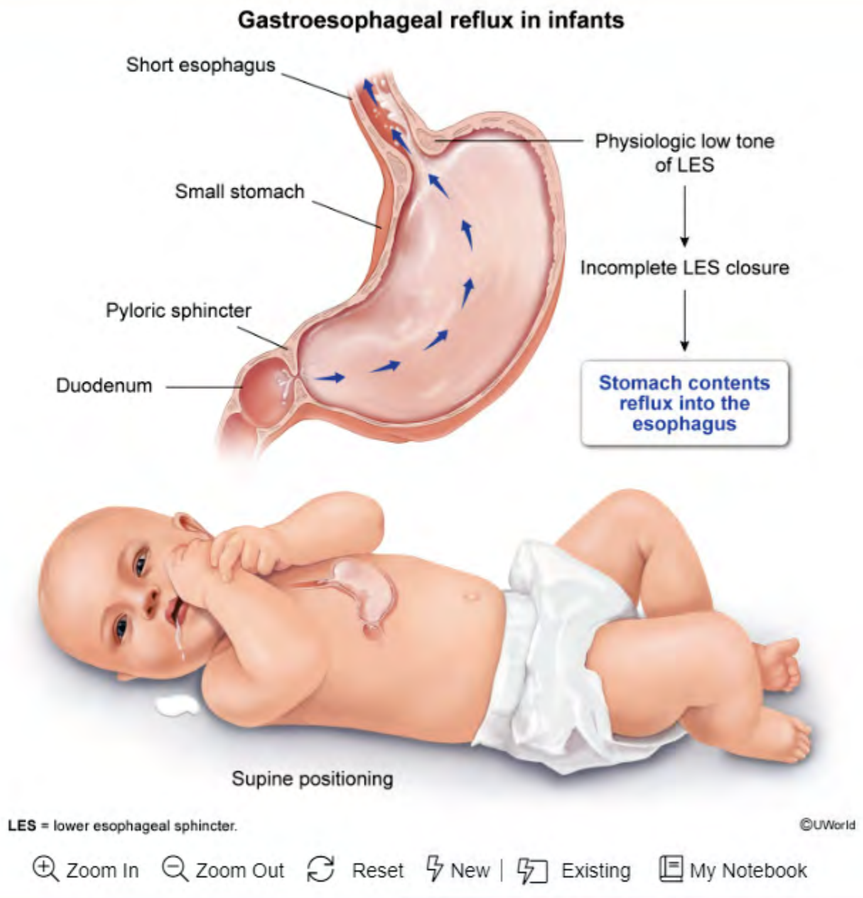

Zoom In | Zoom Out | Reset | New | Existing | My Notebook

Inco
Corre
D

Expl

Small stomach

21877.mp4
https://t.me/USMLEWorldStep1
Show all

This **infant** with frequent nonbilious emesis has normal growth and painless feeding, findings consistent with **gastroesophageal reflux** (GER). In infants, GER is a common and normal condition caused by **low physiologic tone** of the lower esophageal sphincter (LES).

In contrast to older children and adults, who normally only have brief LES relaxation in response to swallowing, infants have an **immature LES** that relaxes for a longer period and in response to gastric distension. Therefore, breast milk and formula are easily regurgitated into the esophagus and out of the mouth and nose.

(Choice A) Tracheoesophageal fistula is caused by a failed separation of the foregut into the trachea and esophagus. Infants have coughing, choking, or respiratory distress associated with feeding, none of which are seen in this patient.

(Choice B) Increased intracranial pressure (ICP) can cause vomiting due to pressure on the area postrema (vomiting center) of the medulla. Unlike this patient, infants with increased ICP have a bulging fontanelle, an increasing head circumference percentile, and a downward gaze preference.

(Choice C) Food protein–induced allergic proctocolitis, most commonly due to a non–IgE-mediated reaction to cow's milk protein in formula or breast milk, usually presents with grossly bloody stools with or without mucus. Vomiting alone makes this diagnosis unlikely.

(Choice E) Pyloric stenosis is characterized by smooth muscle hypertrophy of the pylorus, leading to gastric outlet obstruction. Patients age 3-6 weeks typically have new-onset, forceful/projectile, postprandial vomiting and often dehydration/weight loss. This patient's duration of symptoms, nonforceful regurgitation, and normal growth are inconsistent with pyloric stenosis.

Educational objective:
Gastroesophageal reflux is a common physiologic phenomenon in infants and is due to low tone of an immature lower esophageal sphincter. It is characterized by frequent spit-up in an otherwise asymptomatic patient with appropriate weight gain.

Pathophysiology Gastrointestinal & Nutrition Gastroesophageal reflux disease

21877.mp4
https://t.me/USMLEWorldStep1
Show all

This **infant** with frequent nonbilious emesis has normal growth and painless feeding, findings consistent with

gastro
tone c

In con
infants
breast

(Choi
esoph
seen i

(Choi
(vomit
increa

(Choi
cow's
Vomiti

(Choi
obstru
dehyd
incons

Educa
Gastro
lower
approp

Exhibit Display

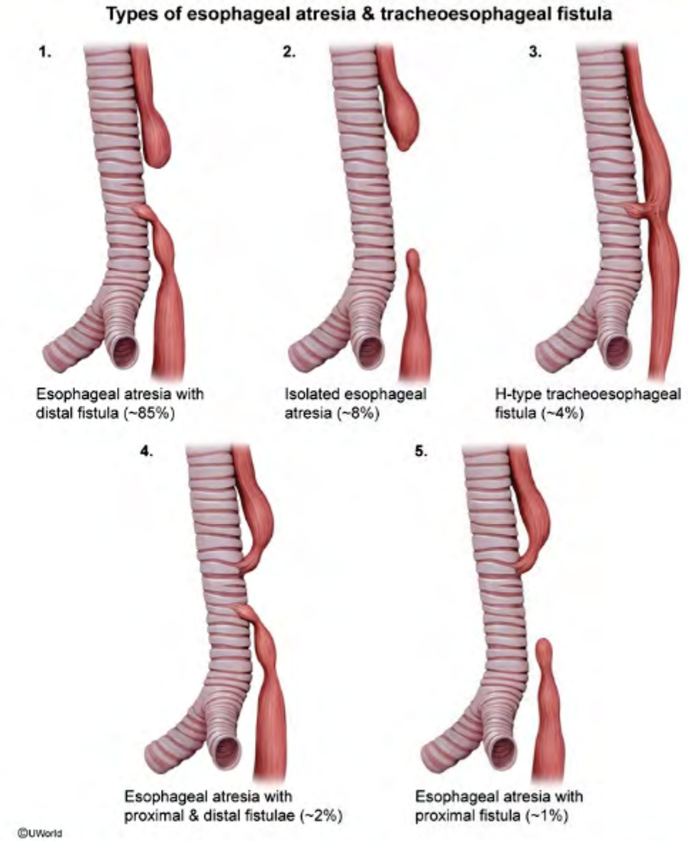

Zoom In | Zoom Out | Reset | New | Existing | My Notebook

Pathophysiology | Gastrointestinal & Nutrition | Gastroesophageal reflux disease

21877.mp4
https://t.me/USMLEWorldStep1
Show all

A 31-year-old woman comes to the emergency department due to worsening right upper quadrant pain, fever, nausea, and vomiting for a day. The pain increases with deep inspiration. Other medical conditions include uterine fibroids and sickle cell anemia. The patient does not use tobacco, alcohol, or illicit drugs. Temperature is 38.6 C (101.5 F), blood pressure is 120/70 mm Hg, and pulse is 102/min. BMI is 24 kg/m^2. On examination, the patient appears uncomfortable because of the pain; there is no jaundice. Tenderness and guarding are present over the right upper quadrant. Bowel sounds are decreased. Hemoglobin is 10.1 g/dL and white blood cell count is 18,000/mm^3 with 7% band forms. Abdominal ultrasound shows evidence of cholelithiasis and gallbladder wall thickening. Gross inspection of the specimen obtained during laparoscopic cholecystectomy is shown in the image below:

Which of the following is most likely responsible for this patient's symptoms?

- A. Altered enterohepatic circulation of bilirubin
- B. Biliary stasis due to lack of enteral stimulation
- C. Decreased gallbladder motility due to denervation
- D. Impaired bile acid synthesis
- E. Increased cholesterol synthesis
- F. Increased efflux of bilirubin into bile

Submit

21877.mp4
https://t.me/USMLEWorldStep1
Show all

A 31-year-old woman comes to the emergency department due to worsening right upper quadrant pain, fever, nause
fibroid
(101.5
appea
right u
18,000
thicker
below:

Exhibit Display

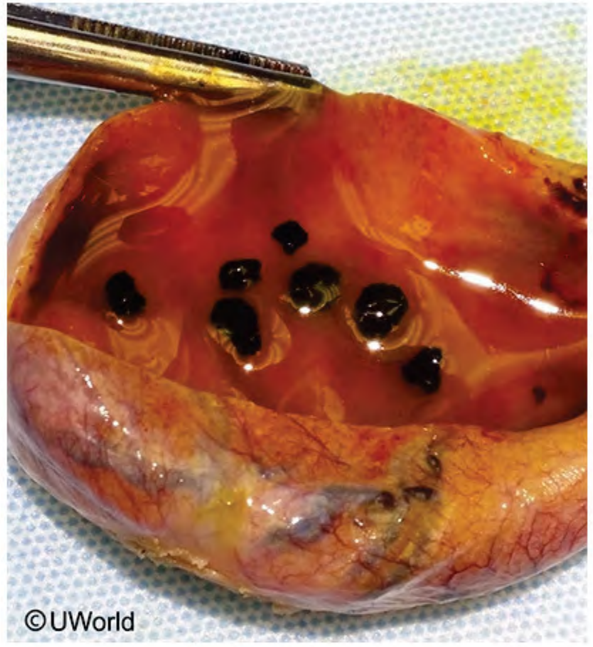

Zoom In | Zoom Out | Reset | New | Existing | My Notebook

Which of the following is most likely responsible for this patient's symptoms?

21877.mp4
https://t.me/USMLEWorldStep1
Show all

Which of the following is most likely responsible for this patient's symptoms?

- A. Altered enterohepatic circulation of bilirubin (14%)
- ✗ B. Biliary stasis due to lack of enteral stimulation (5%)
- C. Decreased gallbladder motility due to denervation (2%)
- D. Impaired bile acid synthesis (5%)
- E. Increased cholesterol synthesis (3%)
- ✓ F. Increased efflux of bilirubin into bile (68%)

Incorrect
Correct answer
F

68%
Answered correctly

09 secs
Time Spent

2023
Version

21877.mp4
https://t.me/USMLEWorldStep1
Show all

Expl

Exhibit Display

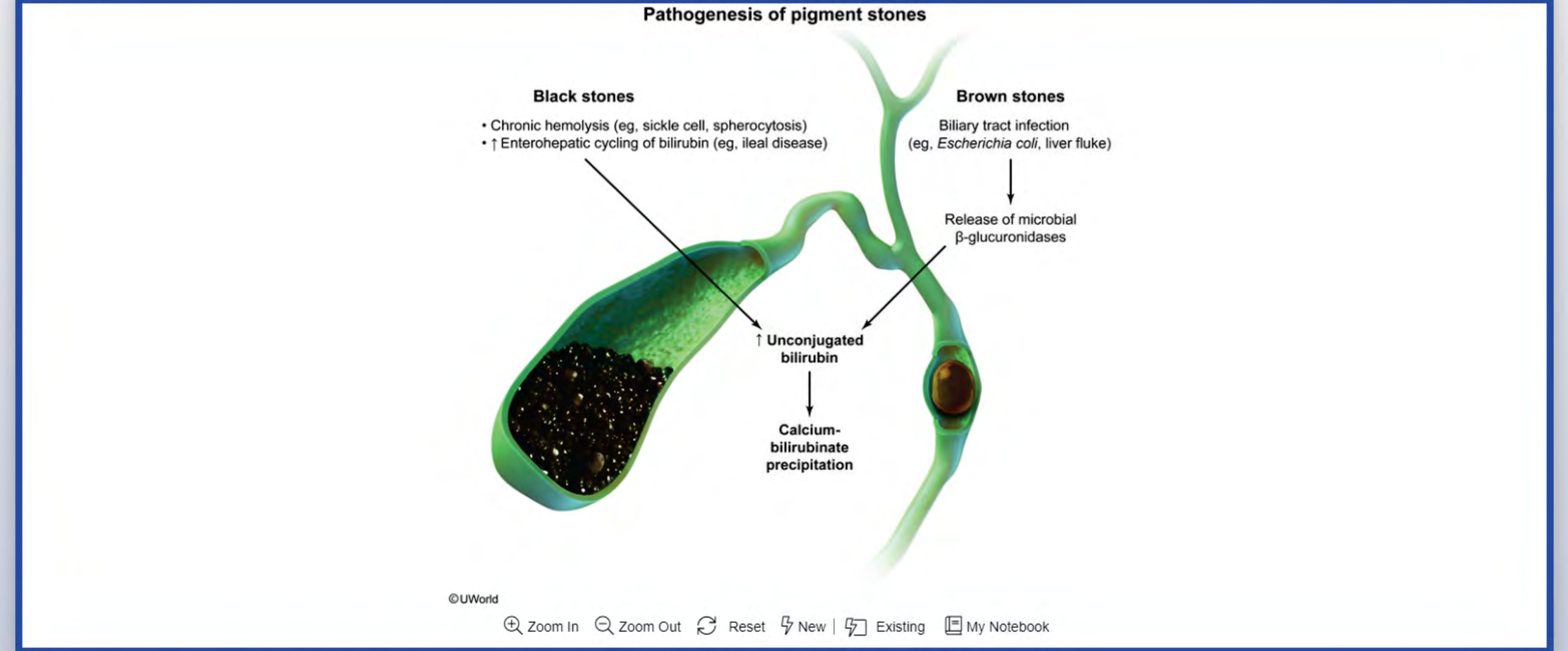

This p

inflammation of the gallbladder that usually occurs when gallstones obstruct the cystic duct. Gallstones form due

21877.mp4
https://t.me/USMLEWorldStep1
Show all

©UWorld

This patient with fever, right upper quadrant pain, and leukocytosis has **acute cholecystitis**. Cholecystitis is inflammation of the gallbladder that usually occurs when gallstones obstruct the cystic duct. Gallstones form due to supersaturation of bile constituents (eg, cholesterol, bilirubin), which then crystalize out of solution with other bile components (eg, mucin, calcium, proteins) to produce stones.

Black gallstones, as seen in this patient, form due to the **supersaturation of bilirubin**, which precipitates with calcium to form multiple small calcium bilirubinate stones. Bilirubin supersaturation occurs through the following mechanisms:

- **Increased bilirubin production:** Chronic hemolysis, as seen in **sickle cell anemia**, hereditary spherocytosis, and thalassemia, increases circulating levels of free bilirubin, which is taken up by the liver and **excreted into bile**.
- **Altered enterohepatic circulation** of bilirubin: Ileal disease (eg, Crohn disease) or resection allows bile acids, which are normally reabsorbed in the ileum, to spill into the colon. There, bile acids solubilize unconjugated bilirubin, allowing its reabsorption and concentration within the bile **(Choice A)**.

This patient with sickle cell anemia most likely has chronic hemolysis, which has increased bilirubin efflux into the bile, promoting formation of black stones.

(Choices B and C) Biliary stasis promotes gallstone formation by providing a favorable environment for crystal nucleation and aggregation. Stasis can occur due to gallbladder denervation (eg, transection of the nerves that control gallbladder contraction) or decreased stimulation by enterocytes during prolonged fasting (cholecystokinin is released in response to food). However, stasis usually promotes the formation of yellow cholesterol stones, and this patient did not have prolonged fasting or surgery prior to developing her symptoms.

(Choice D) Cirrhosis can also occasionally promote the formation of black stones due to impaired bile acid synthesis and hyperbilirubinemia (due to cholestasis). However, this patient does not have a history of cirrhosis or stigmata of chronic liver disease (eg, jaundice).

21877.mp4
https://t.me/USMLEWorldStep1
Show all

spherocytosis, and thalassemia, increases circulating levels of free bilirubin, which is taken up by the liver and **excreted into bile**.

- **Altered enterohepatic circulation** of bilirubin: Ileal disease (eg, Crohn disease) or resection allows bile acids, which are normally reabsorbed in the ileum, to spill into the colon. There, bile acids solubilize unconjugated bilirubin, allowing its reabsorption and concentration within the bile **(Choice A)**.

This patient with sickle cell anemia most likely has chronic hemolysis, which has increased bilirubin efflux into the bile, promoting formation of black stones.

(Choices B and C) Biliary stasis promotes gallstone formation by providing a favorable environment for crystal nucleation and aggregation. Stasis can occur due to gallbladder denervation (eg, transection of the nerves that control gallbladder contraction) or decreased stimulation by enterocytes during prolonged fasting (cholecystokinin is released in response to food). However, stasis usually promotes the formation of yellow cholesterol stones, and this patient did not have prolonged fasting or surgery prior to developing her symptoms.

(Choice D) Cirrhosis can also occasionally promote the formation of black stones due to impaired bile acid synthesis and hyperbilirubinemia (due to cholestasis). However, this patient does not have a history of cirrhosis or stigmata of chronic liver disease (eg, jaundice).

(Choice E) Increased cholesterol synthesis results in the formation of yellow cholesterol gallstones. This typically occurs in the setting of obesity, diabetes mellitus, or certain medications (eg, estrogen-containing oral contraceptives).

Educational objective:
Black gallstones form due to supersaturation of the bile with bilirubin, which precipitates with calcium to form calcium bilirubinate stones. This typically occurs in the setting of chronic hemolysis (eg, sickle cell disease) or altered enterohepatic circulation of bilirubin (eg, Crohn disease, ileal resection).

References

- Gallstones.

21877.mp4
https://t.me/USMLEWorldStep1
Show all

A 30-year-old woman comes to the office due to a 6-month history of increasingly severe fatigue and malaise. For the past 5 years, she has lived on a small farm and eats only vegetables, fruits, and grains she grows herself. Medical history is unremarkable. The patient takes no medications or nutritional supplements. She does not use tobacco or alcohol. This patient is at increased risk for deficiency involving which of the following nutrients?

	Folic acid	Iron	Thiamine	Vitamin B_{12}
○ A.	No	No	No	Yes
○ B.	No	No	Yes	Yes
○ C.	No	Yes	No	Yes
○ D.	Yes	No	Yes	Yes
○ E.	Yes	Yes	No	No
○ F.	Yes	Yes	Yes	Yes

Submit

21877.mp4
https://t.me/USMLEWorldStep1
Show all

A 30-year-old woman comes to the office due to a 6-month history of increasingly severe fatigue and malaise. For the past 5 years, she has lived on a small farm and eats only vegetables, fruits, and grains she grows herself. Medical history is unremarkable. The patient takes no medications or nutritional supplements. She does not use tobacco or alcohol. This patient is at increased risk for deficiency involving which of the following nutrients?

		Folic acid	Iron	Thiamine	Vitamin B_{12}	
	A.	No	No	No	Yes	(19%)
✗	B.	No	No	Yes	Yes	(6%)
✓	C.	No	Yes	No	Yes	(51%)
	D.	Yes	No	Yes	Yes	(5%)
	E.	Yes	Yes	No	No	(5%)
	F.	Yes	Yes	Yes	Yes	(11%)

Incorrect
Correct answer
C

51%
Answered correctly

04 secs
Time Spent

2023
Version

Explanation

Vegan diet	
Composition	• Plant-based foods: fruits, vegetables, legumes, grains • No animal-derived foods (eg, meat, dairy, egg)
Potential benefits	• Lower blood glucose & cholesterol levels

21877.mp4
https://t.me/USMLEWorldStep1
Show all

Vegan diet	
Composition	• Plant-based foods: fruits, vegetables, legumes, grains • No animal-derived foods (eg, meat, dairy, egg)
Potential benefits	• Lower blood glucose & cholesterol levels • Reduced risk for cardiovascular disease (eg, heart disease, stroke)
Potential nutritional deficiencies	• Common: vitamin B_{12}, vitamin D, calcium • Possible*: iron, zinc
*Increased risk: children (rapid growth requires higher zinc/iron) & young women (menstrual blood loss requires higher iron).	

A **vegan diet** is characterized by abstinence from **all animal-sourced products**. It differs from a vegetarian diet in that vegetarians consume some nonmeat animal products (eg, milk, eggs). A vegan diet is plentiful in most vitamins (eg, A, B complex [except B_{12}], C), minerals (eg, potassium, magnesium), and soluble fiber. In addition, although most single plant–based protein sources (except soy) are deficient in certain essential amino acids, dietary requirements can be met with a mixed vegan diet (eg, legumes plus grains).

However, a vegan diet without supplementation or food fortification (as in this case) increases the risk for the following:

- **Vitamin B_{12} (cobalamin) deficiency:** Vitamin B_{12} is naturally present in only animal-based foods. Deficiency usually takes years to develop after initiating a strict vegan diet due to large hepatic stores of vitamin B_{12}.
- **Calcium and vitamin D deficiency:** Most dietary calcium and vitamin D intake is from animal-sourced products (eg, dairy). Individuals who follow a vegan diet often require supplementation to prevent osteoporosis, especially those without significant sunlight exposure (sunlight accounts for ~200-400 IU/day of the required 600 IU/day).

21877.mp4
https://t.me/USMLEWorldStep1
Show all

*Increased risk: children (rapid growth requires higher zinc/iron) & young women (menstrual blood loss requires higher iron).

A **vegan diet** is characterized by abstinence from **all animal-sourced products**. It differs from a vegetarian diet in that vegetarians consume some nonmeat animal products (eg, milk, eggs). A vegan diet is plentiful in most vitamins (eg, A, B complex [except B_{12}], C), minerals (eg, potassium, magnesium), and soluble fiber. In addition, although most single plant–based protein sources (except soy) are deficient in certain essential amino acids, dietary requirements can be met with a mixed vegan diet (eg, legumes plus grains).

However, a vegan diet without supplementation or food fortification (as in this case) increases the risk for the following:

- **Vitamin B_{12} (cobalamin) deficiency:** Vitamin B_{12} is naturally present in only animal-based foods. Deficiency usually takes years to develop after initiating a strict vegan diet due to large hepatic stores of vitamin B_{12}.
- **Calcium and vitamin D deficiency:** Most dietary calcium and vitamin D intake is from animal-sourced products (eg, dairy). Individuals who follow a vegan diet often require supplementation to prevent osteoporosis, especially those without significant sunlight exposure (sunlight accounts for ~200-400 IU/day of the required 600 IU/day).
- **Iron deficiency:** Many plant products (eg, leafy green vegetables) contain iron. However, the iron derived from plants (nonheme iron) is less well absorbed compared with iron derived from animals (heme iron). In addition, the quantity is often inadequate for those with increased dietary iron requirements, such as children during periods of rapid growth and women who are menstruating (like this young woman) **(Choice A)**.

This patient developed fatigue and malaise after 5 years of following a strict vegan diet. Although many commercially prepared vegan products are fortified with additional vitamins and minerals, this patient is consuming unprocessed whole foods only. She likely has anemia due to iron and/or vitamin B_{12} deficiency.

(Choices B, D, E, and F) Folic acid and thiamine (vitamin B_1) are abundant in plant-based foods. Deficiency may occur in individuals with poor absorption (eg, alcohol use disorder) or malnutrition but is uncommon in those

21877.mp4
https://t.me/USMLEWorldStep1
Show all

dietary requirements can be met with a mixed vegan diet (eg, legumes plus grains).

However, a vegan diet without supplementation or food fortification (as in this case) increases the risk for the following:

- **Vitamin B_{12} (cobalamin) deficiency:** Vitamin B_{12} is naturally present in only animal-based foods. Deficiency usually takes years to develop after initiating a strict vegan diet due to large hepatic stores of vitamin B_{12}.
- **Calcium and vitamin D deficiency:** Most dietary calcium and vitamin D intake is from animal-sourced products (eg, dairy). Individuals who follow a vegan diet often require supplementation to prevent osteoporosis, especially those without significant sunlight exposure (sunlight accounts for ~200-400 IU/day of the required 600 IU/day).
- **Iron deficiency:** Many plant products (eg, leafy green vegetables) contain iron. However, the iron derived from plants (nonheme iron) is less well absorbed compared with iron derived from animals (heme iron). In addition, the quantity is often inadequate for those with increased dietary iron requirements, such as children during periods of rapid growth and women who are menstruating (like this young woman) **(Choice A)**.

This patient developed fatigue and malaise after 5 years of following a strict vegan diet. Although many commercially prepared vegan products are fortified with additional vitamins and minerals, this patient is consuming unprocessed whole foods only. She likely has anemia due to iron and/or vitamin B_{12} deficiency.

(Choices B, D, E, and F) Folic acid and thiamine (vitamin B_1) are abundant in plant-based foods. Deficiency may occur in individuals with poor absorption (eg, alcohol use disorder) or malnutrition but is uncommon in those consuming a variety of fruits, vegetables, and grains.

Educational objective:
A vegan diet is characterized by abstinence from all animal-sourced products. Individuals who consume a vegan diet are often deficient in vitamin B_{12}, calcium, and vitamin D. Those with increased dietary iron requirements (eg, menstruating women, children) may also develop iron deficiency. Supplementation is routinely recommended.

21877.mp4
https://t.me/USMLEWorldStep1
Show all

A 54-year-old man dies from profuse upper gastrointestinal hemorrhage. An autopsy is performed; gross examination of his liver is shown in the image below.

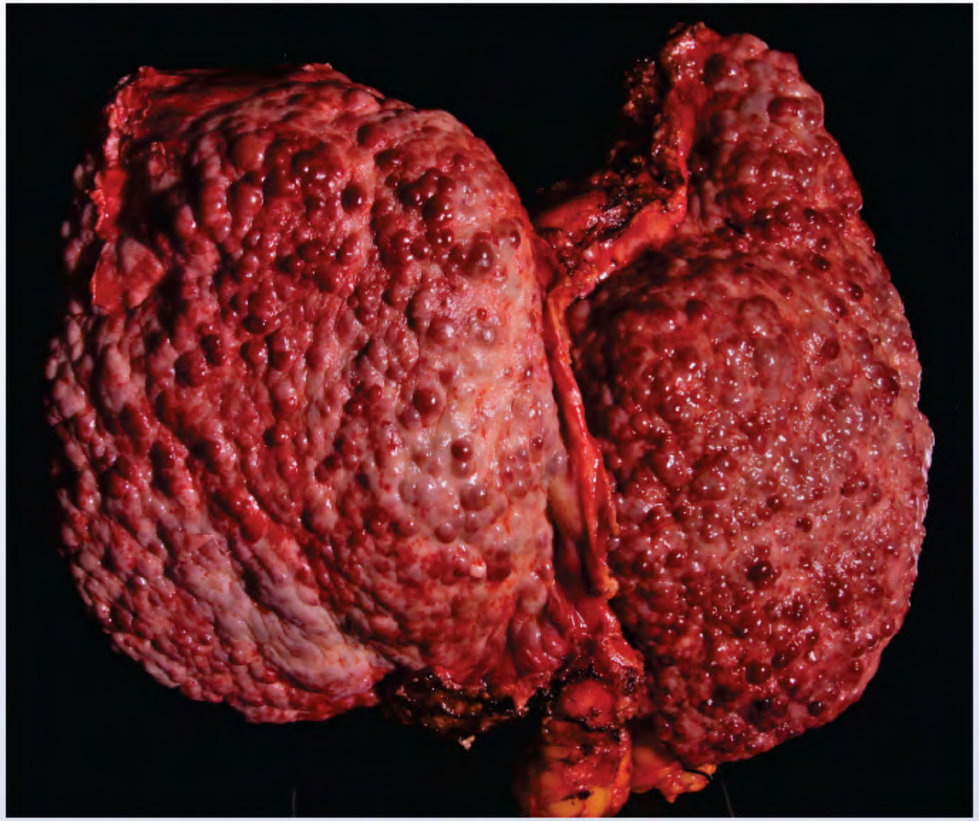

This patient's liver findings most likely resulted from which of the following processes?

- A. Dilation of sinusoids and perivenular hemorrhage
- B. Fibrosis and nodular parenchymal regeneration

21877.mp4
https://t.me/USMLEWorldStep1
Show all

A 54-year-old man dies from profuse upper gastrointestinal hemorrhage. An autopsy is performed; gross
exami

Exhibit Display

Zoom In | Zoom Out | Reset | New | Existing | My Notebook

This p

B. Fibrosis and nodular parenchymal regeneration

21877.mp4
https://t.me/USMLEWorldStep1
Show all

This patient's liver findings most likely resulted from which of the following processes?

- A. Dilation of sinusoids and perivenular hemorrhage
- B. Fibrosis and nodular parenchymal regeneration
- C. Granulomatous destruction of bile ducts
- D. Intrahepatic hydatid cysts with surrounding fibrous reaction
- E. Pigment accumulation within hepatocytes

Submit

21877.mp4
https://t.me/USMLEWorldStep1
Show all

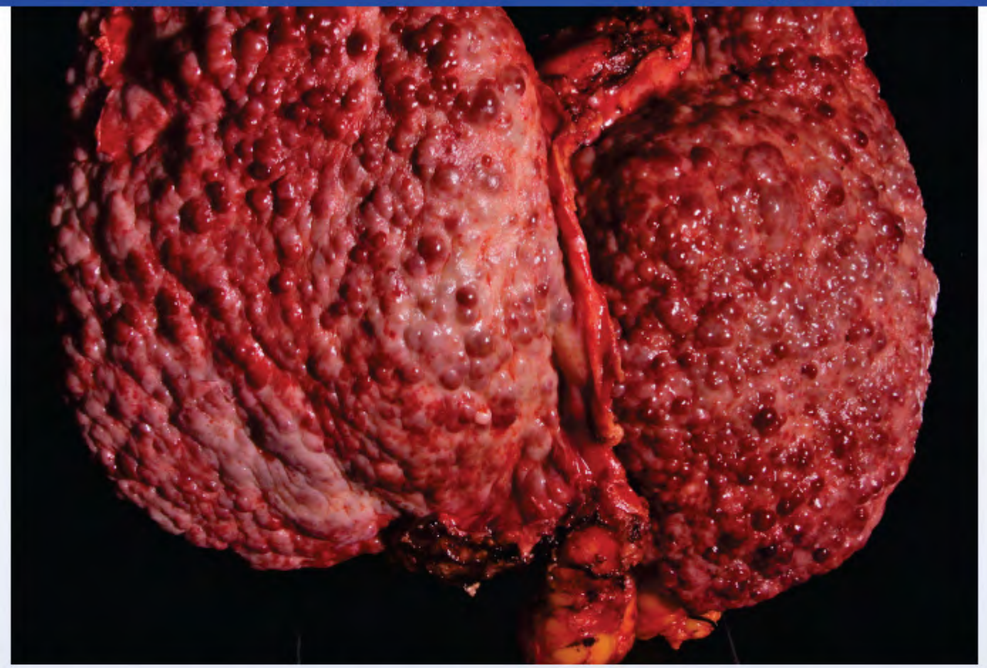

This patient's liver findings most likely resulted from which of the following processes?

- A. Dilation of sinusoids and perivenular hemorrhage (13%)
- ✓ B. Fibrosis and nodular parenchymal regeneration (76%)
- ✗ C. Granulomatous destruction of bile ducts (0%)
- D. Intrahepatic hydatid cysts with surrounding fibrous reaction (7%)
- E. Pigment accumulation within hepatocytes (1%)

Incorrect
Correct answer
B

76%
Answered correctly

49 secs
Time Spent

2023
Version

21877.mp4
https://t.me/USMLEWorldStep1
Show all

Cirrhosis, the end stage of many chronic liver diseases, is characterized by **diffuse hepatic fibrosis** with replacement of the normal lobular architecture by fibrous-lined regenerative parenchymal nodules. This gives the liver a nodular appearance on gross examination. The most common causes of cirrhosis include **chronic viral hepatitis** (eg, hepatitis B and C), **alcohol**, hemochromatosis, and nonalcoholic fatty liver disease. **Portal hypertension**, from increased resistance to hepatic blood flow, typically develops in advanced cirrhosis and can lead to development of **gastroesophageal varices**. Untreated, these varices are prone to rupture and can result in a massive gastrointestinal hemorrhage and possibly death.

(Choice A) Dilation of sinusoids and perivenular hemorrhage are associated with acute venous outflow obstruction affecting the liver (eg, Budd-Chiari syndrome). Chronic hepatic vein obstruction is a rare cause of cirrhosis and portal hypertension.

(Choice C) Granulomatous destruction of bile ducts is seen in patients with primary biliary cholangitis (PBC). Although PBC can cause cirrhosis, it is a far less common cause than alcohol or chronic hepatitis. Moreover, PBC primarily occurs in women.

(Choice D) Intrahepatic hydatid cysts with surrounding fibrous reaction can be seen in patients with an *Echinococcus* infection, but it is a very rare disease in the United States.

(Choice E) Pigment accumulation within hepatocytes occurs in conditions such as Dubin-Johnson syndrome, an autosomal recessive disorder causing conjugated hyperbilirubinemia. In this condition, hepatocellular accumulation of coarse pigmented granules causes the liver to appear grossly black.

Educational objective:
Cirrhosis is characterized by diffuse hepatic fibrosis with replacement of the normal lobular architecture by fibrous-lined parenchymal nodules. Chronic viral hepatitis (eg, hepatitis B and C), alcohol, hemochromatosis, and nonalcoholic fatty liver disease are the most common causes of cirrhosis in the United States.

Pathology	Gastrointestinal & Nutrition	Cirrhosis
Subject	System	Topic

21877.mp4
https://t.me/USMLEWorldStep1
Show all

Cirrhosis, the end stage of many chronic liver diseases, is characterized by **diffuse hepatic fibrosis** with

replac
liver a
hepati
hyper
lead to
in a m

(Choi
obstru
cirrhos

(Choi
Althou
primar

(Choi
Echino

(Choi
autosc
accum

Educa
Cirrho
lined p
nonalc

Patholog
Subject System Topic

Exhibit Display

Cirrhosis

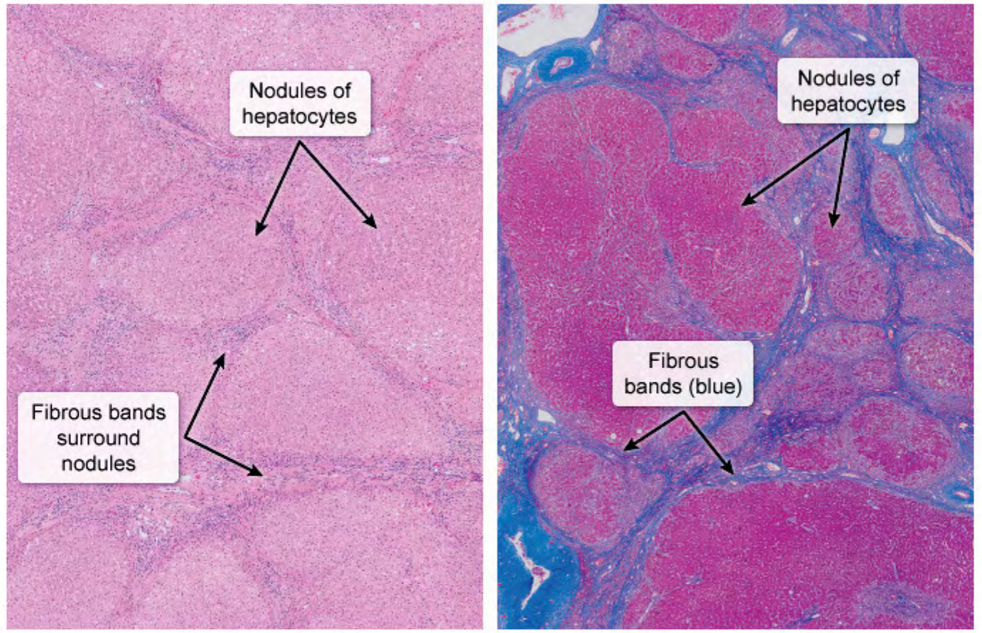

©UWorld

Hematoxylin & eosin stain

Trichrome stain

Zoom In Zoom Out Reset New | Existing My Notebook

21877.mp4
https://t.me/USMLEWorldStep1
Show all

Cirrhosis, the end stage of many chronic liver diseases, is characterized by **diffuse hepatic fibrosis** with

replac
liver a
hepati
hyper
lead to
in a m

(Choi
obstru
cirrhos

(Choi
Althou
primar

(Choi
Echino

(Choi
autosc
accum

Educa
Cirrho
lined p
nonalc

Patholog
Subject System Topic

Exhibit Display

Cirrhotic liver

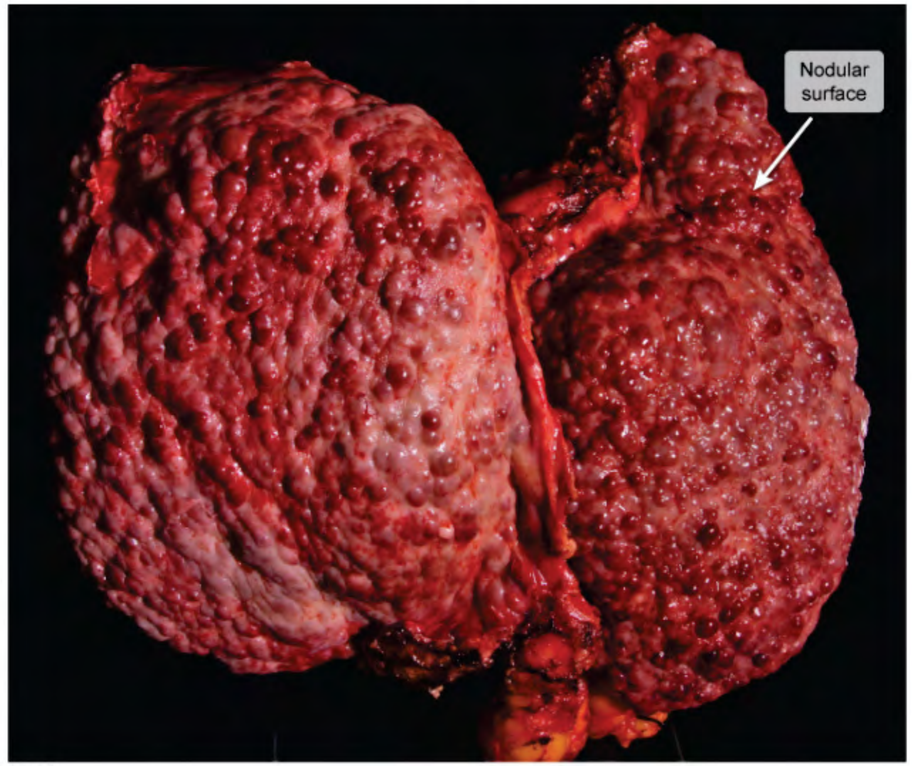

©UWorld

Zoom In Zoom Out Reset New | Existing My Notebook

21877.mp4
https://t.me/USMLEWorldStep1
Show all

A 48-year-old man is evaluated for abdominal pain and diarrhea. The patient characterizes his stool as voluminous and foul smelling. He has no significant past medical history. The patient drinks 6 cans of beer daily. On examination, he has normal bowel sounds and mild epigastric tenderness. A 72-hour stool collection shows excessive excretion of fecal fat. A CT scan of the abdomen is shown in the image below. Involvement of which of the following structures is most likely causing this patient's symptoms?

- A. A
- B. B
- C. C
- D. D
- E. E

Submit

21877.mp4
https://t.me/USMLEWorldStep1
Show all

A 48-year-old man is evaluated for abdominal pain and diarrhea. The patient characterizes his stool as voluminous
and fo
exami
excess
the fol

Exhibit Display

Zoom In Zoom Out Reset New | Existing My Notebook

B. B

21877.mp4
https://t.me/USMLEWorldStep1
Show all

- A. A
- B. B
- C. C
- D. D
- E. E

Submit

21877.mp4
https://t.me/USMLEWorldStep1
Show all

- A. A (1%)
- ✓ B. B (91%)
- C. C (0%)
- D. D (0%)
- E. E (5%)

Correct

91%
Answered correctly

12 secs
Time Spent

2023
Version

21877.mp4
https://t.me/USMLEWorldStep1
Show all

C. C (0%)

Exhibit Display

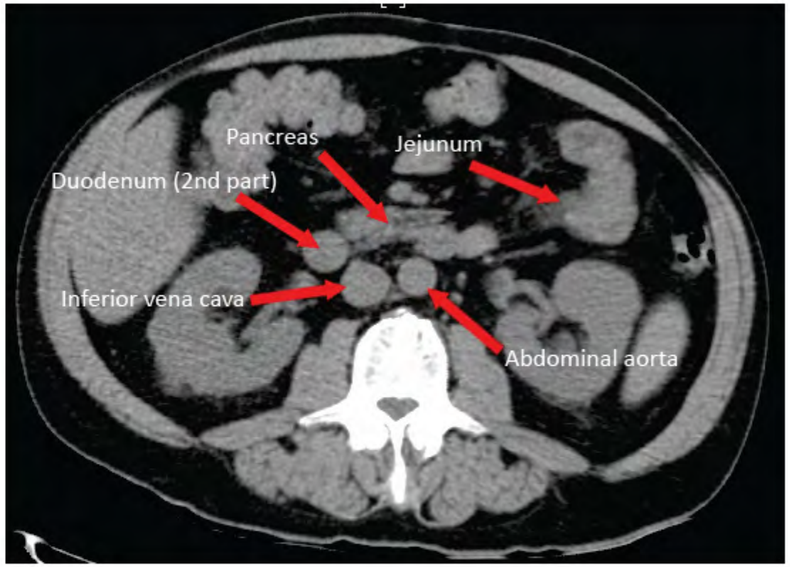

Zoom In | Zoom Out | Reset | New | Existing | My Notebook

This p
exocri
of digestive enzymes (eg, lipase). Consequently, patients may develop **fat malabsorption** with greasy,

21877.mp4
https://t.me/USMLEWorldStep1
Show all

This patient with excessive alcohol use, **epigastric pain**, and **steatorrhea** likely has **chronic pancreatitis** with exocrine insufficiency. Atrophy and fibrosis of pancreatic acinar cells result in failed secretion of adequate amounts of digestive enzymes (eg, lipase). Consequently, patients may develop **fat malabsorption** with greasy, malodorous stools that are difficult to flush. A 72-hour stool collection can confirm excessive excretion of fecal fat.

The head, neck, and body of the pancreas are retroperitoneal, whereas the tail is peritoneal. The head of the pancreas lies in the curve of the duodenum and overlies the L2 vertebra, with a portion extending behind the superior mesenteric vessels (uncinate process). The neck connects the head to the body and lies anterior to the portal vein and superior mesenteric vessels. The pancreas body overlies the L1 and L2 vertebrae and makes contact posteriorly with the aorta, left adrenal gland, left kidney, and renal vessels. The tail of the pancreas courses within the splenorenal ligament alongside the splenic vessels.

(Choice A) This structure is the second (descending) part of the duodenum.

(Choice C) This structure is the inferior vena cava, which lies on the right side of the vertebrae in a retroperitoneal position.

(Choice D) This structure is the abdominal aorta, which lies on the left side of the vertebrae in a retroperitoneal position.

(Choice E) At this level in the abdominal cavity, these loops of small bowel represent jejunum. If this CT slice were lower in the abdomen, these loops would more likely represent ileum.

Educational objective:
Chronic pancreatitis often presents with epigastric pain and pancreatic exocrine insufficiency resulting in fat malabsorption/steatorrhea. On abdominal CT scan, the pancreas can be identified by its head in close association with the second part of the duodenum; its body overlying the aorta, left kidney, and renal vessels; and its tail lying within the splenorenal ligament.

References

- Chronic pancreatitis.

21877.mp4
https://t.me/USMLEWorldStep1
Show all

This patient with excessive alcohol use, **epigastric pain**, and **steatorrhea** likely has **chronic pancreatitis** with exocri
of dige
malod

The he
pancre
superi
portal
contac
course

(Choi

(Choi
positic

(Choi
positic

(Choi
were l

Educa
Chron
malab
with th
within

Refere

- Chronic pancreatitis.

Exhibit Display

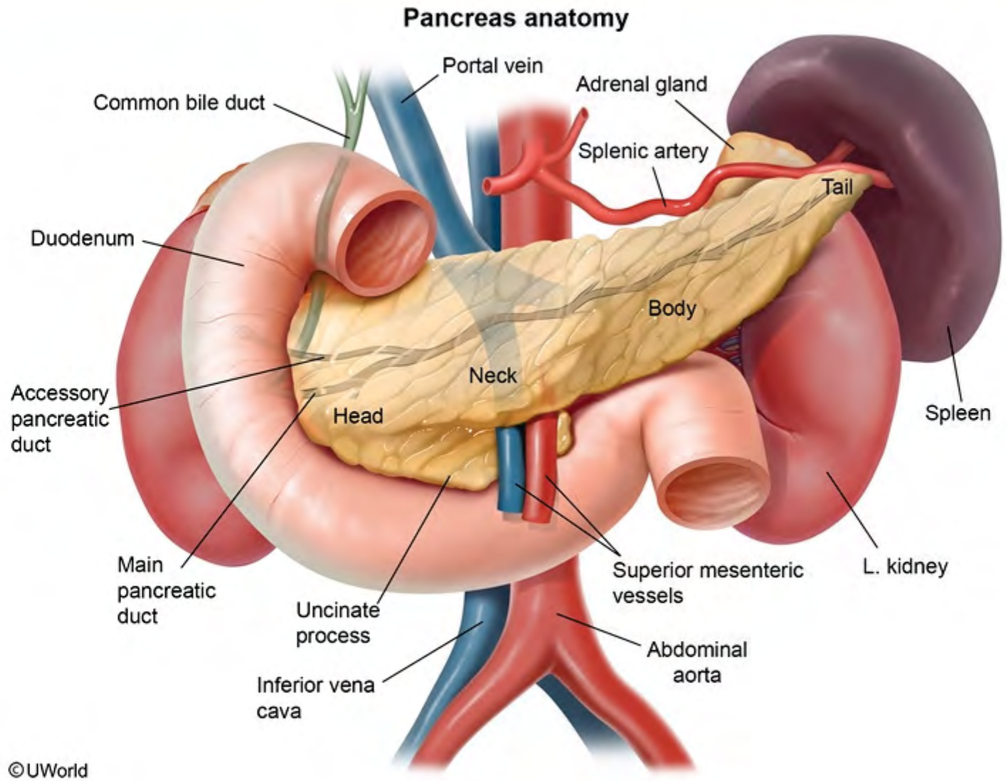

Zoom In | Zoom Out | Reset | New | Existing | My Notebook

21877.mp4
https://t.me/USMLEWorldStep1
Show all

A 64-year-old man comes to the emergency department after an episode of hematemesis. He also reports dark stools and abdominal pain for the past several days. The patient has a history of chronic pancreatitis. Abdominal examination shows epigastric tenderness to palpation. Rectal examination is notable for black, guaiac-positive feces. Upper gastrointestinal endoscopy reveals a bleeding spot within a cluster of enlarged tortuous veins in the gastric fundus. The rest of the stomach and esophagus appears normal. Increased pressure in which of the following vascular structures is the most likely cause of this patient's condition?

- A. Azygos vein
- B. Left gastric vein
- C. Pancreaticoduodenal vein
- D. Splenic vein
- E. Superior mesenteric vein

Submit

21877.mp4
https://t.me/USMLEWorldStep1
Show all

A 64-year-old man comes to the emergency department after an episode of hematemesis. He also reports dark stools and abdominal pain for the past several days. The patient has a history of chronic pancreatitis. Abdominal examination shows epigastric tenderness to palpation. Rectal examination is notable for black, guaiac-positive feces. Upper gastrointestinal endoscopy reveals a bleeding spot within a cluster of enlarged tortuous veins in the gastric fundus. The rest of the stomach and esophagus appears normal. Increased pressure in which of the following vascular structures is the most likely cause of this patient's condition?

- ✗ A. Azygos vein (6%)
- B. Left gastric vein (51%)
- C. Pancreaticoduodenal vein (7%)
- ✓ D. Splenic vein (30%)
- E. Superior mesenteric vein (3%)

Incorrect
Correct answer
D

30%
Answered correctly

03 secs
Time Spent

2023
Version

Explanation

Splenic vein thrombosis

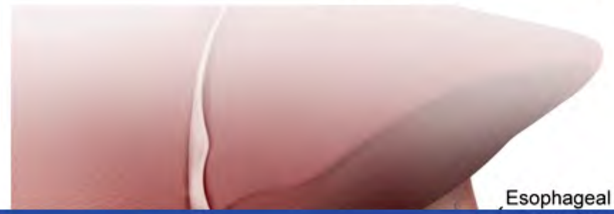

21877.mp4
https://t.me/USMLEWorldStep1
Show all

A. Azygos vein (6%)

Incc
Corre
D

Expl

Exhibit Display

Splenic vein thrombosis

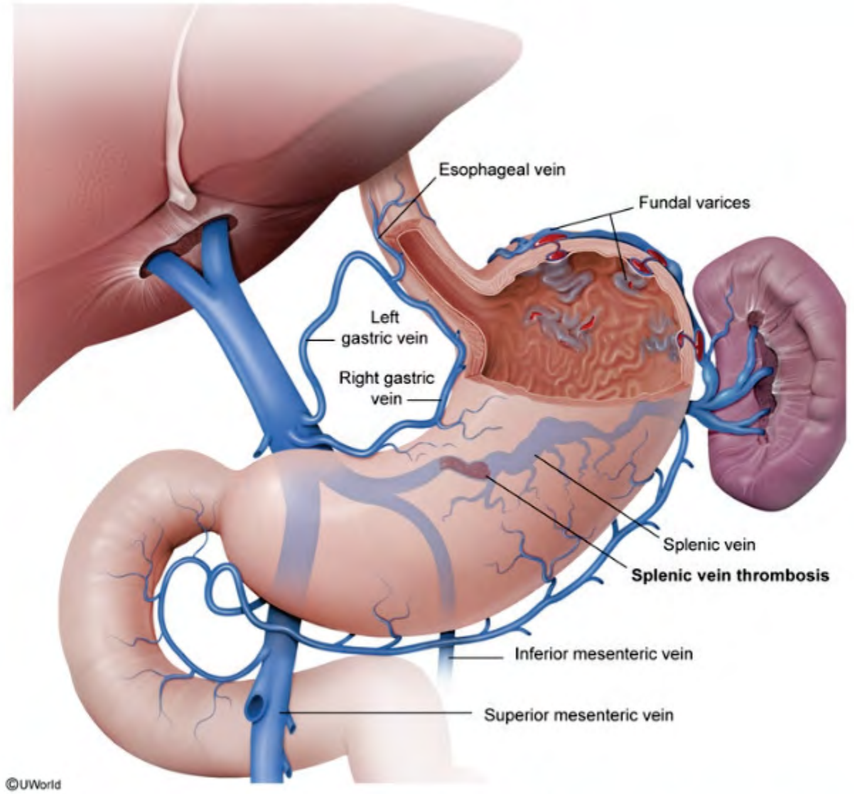

Zoom In | Zoom Out | Reset | New | Existing | My Notebook

21877.mp4
https://t.me/USMLEWorldStep1
Show all

Gastric varices are dilated submucosal veins that can cause life-threatening bleeding in the upper gastrointestinal tract. The varices are commonly due to portal hypertension, which can be a complication of cirrhosis. Gastric varices can also be seen with **splenic vein thrombosis** due to chronic pancreatitis, pancreatic cancer, and abdominal tumors. The splenic vein runs along the posterior surface of the pancreas and can develop a blood clot from pancreatic inflammation. The **short gastric veins** drain the fundus of the stomach into the splenic vein. Splenic vein thrombosis can increase pressure in the short gastric veins and cause **gastric varices** only in the **fundus**. The rest of the stomach and esophagus are usually not affected.

(Choice A) The azygos vein drains blood from the esophageal veins into the superior vena cava. The formation of esophageal varices in the setting of portal hypertension provides collateral drainage from the portal venous system to the azygos system. The azygos vein also provides collateral circulation between the superior and inferior vena cava and can become enlarged with caval obstruction.

(Choice B) The left gastric vein drains blood from the upper stomach and lower esophagus into the portal vein. Portal hypertension can increase pressure in the left gastric veins and usually causes both gastric and esophageal varices.

(Choices C and E) The pancreaticoduodenal vein drains the pancreas and duodenum into the superior mesenteric vein (SMV). The SMV also drains blood from the lower stomach (via the right gastroepiploic vein) and small intestine. Blockage of the SMV could lead to variceal formation in the lower stomach, but not the upper regions.

Educational objective:
The short gastric veins drain blood from the gastric fundus into the splenic vein. Pancreatic inflammation (eg, pancreatitis, pancreatic cancer) can cause a blood clot within the splenic vein, which can increase pressure in the short gastric veins and lead to gastric varices only in the fundus.

References

- Repeated pancreatitis-induced splenic vein thrombosis leads to intractable gastric variceal bleeding: A case report and review

21877.mp4
https://t.me/USMLEWorldStep1
Show all

A 38-year-old man comes to the emergency department with severe abdominal pain and vomiting. The pain radiates to his back and improves by bending forward. Physical examination shows tenderness over the epigastrium and decreased bowel sounds. The patient is admitted to the hospital and treated with intravenous fluids and pain medication, but his condition fails to improve. An abdominal CT scan reveals diffuse pancreatic enlargement with areas of necrosis. The inappropriate activation of which of the following most likely initiated this patient's condition?

- A. Amylase
- B. Chymotrypsinogen
- C. Lipase
- D. Proelastase
- E. Prophospholipase
- F. Trypsinogen

Submit

21877.mp4
https://t.me/USMLEWorldStep1
Show all

A 38-year-old man comes to the emergency department with severe abdominal pain and vomiting. The pain radiates to his back and improves by bending forward. Physical examination shows tenderness over the epigastrium and decreased bowel sounds. The patient is admitted to the hospital and treated with intravenous fluids and pain medication, but his condition fails to improve. An abdominal CT scan reveals diffuse pancreatic enlargement with areas of necrosis. The inappropriate activation of which of the following most likely initiated this patient's condition?

- (●) A. Amylase
- ( ) B. Chymotrypsinogen
- ( ) C. Lipase
- ( ) D. Proelastase
- ( ) E. Prophospholipase
- ( ) F. Trypsinogen

Submit

21877.mp4
https://t.me/USMLEWorldStep1
Show all

A 38-year-old man comes to the emergency department with severe abdominal pain and vomiting. The pain radiates to his back and improves by bending forward. Physical examination shows tenderness over the epigastrium and decreased bowel sounds. The patient is admitted to the hospital and treated with intravenous fluids and pain medication, but his condition fails to improve. An abdominal CT scan reveals diffuse pancreatic enlargement with areas of necrosis. The inappropriate activation of which of the following most likely initiated this patient's condition?

- ✗ A. Amylase (3%)
- B. Chymotrypsinogen (3%)
- C. Lipase (12%)
- D. Proelastase (1%)
- E. Prophospholipase (0%)
- ✓ F. Trypsinogen (78%)

Incorrect
Correct answer
F

78%
Answered correctly

07 secs
Time Spent

2023
Version

Explanation

Pathogenesis of acute pancreatitis

Ductal obstruction
- Ampullary obstruction (eg, gallstones, tumors)
- Ductal concretions due

Direct parenchymal injury
- Alcohol
- Iatrogenic (eg, drugs & post-ERCP)
- Hypertriglyceridemia

21877.mp4
https://t.me/USMLEWorldStep1
Show all

A. Amylase (3%)

Exhibit Display

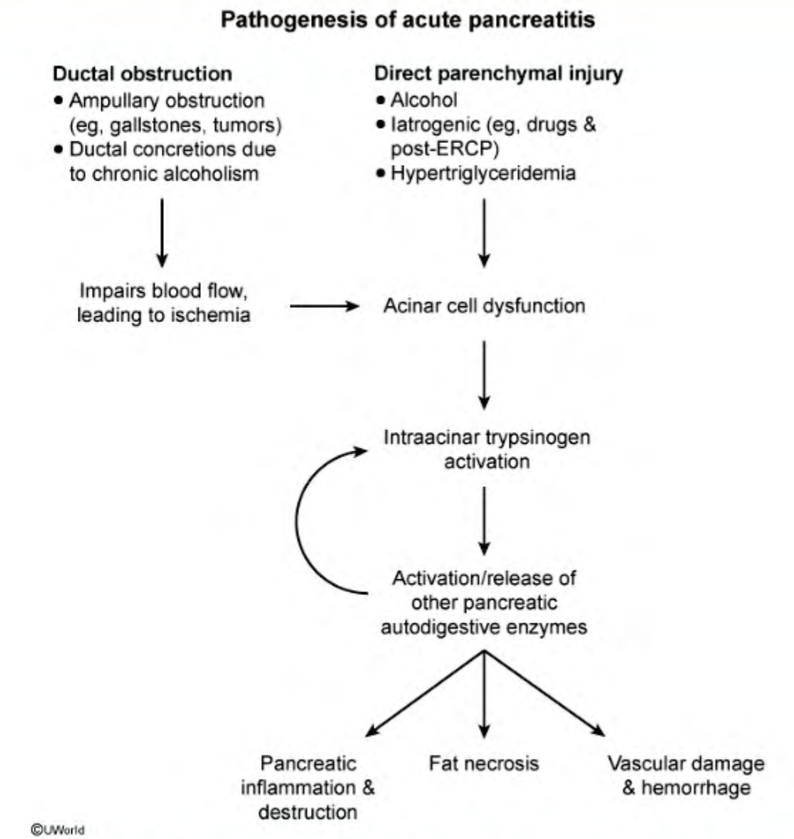

Zoom In | Zoom Out | Reset | New | Existing | My Notebook

21877.mp4
https://t.me/USMLEWorldStep1
Show all

©UWorld

Most pancreatic enzymes are synthesized by pancreatic acinar cells as inactive enzyme precursors called zymogens. Zymogen granules are secreted from the apical surface of acinar cells into the lumen. After traversing the pancreatic duct system, they drain through the ampulla of Vater into the descending part of the duodenum. The enzyme enterokinase (secreted from intestinal mucosa) cleaves trypsinogen into trypsin, its active form. Once a small quantity of trypsin is produced, it activates other zymogens, including chymotrypsin, elastase, and carboxypeptidase, through proteolytic cleavage. Trypsin can also cleave trypsinogen to produce more trypsin, accelerating pancreatic enzyme activation in the duodenum.

The pathogenesis of **acute pancreatitis** begins with either a toxic or an ischemic injury to the acinar cells that leads to **premature activation of trypsin** inside the pancreatic acini. Trypsin then activates the other proteolytic enzymes and starts a self-sustaining cycle of pancreatic inflammation and autodigestion with further release of digestive enzymes. In severe cases, this process can result in **necrotizing pancreatitis**, which is characterized by gross areas of parenchymal necrosis with a high propensity for secondary bacterial infection.

(Choice A) Amylase hydrolyzes starch to produce maltose (a glucose-glucose disaccharide) and trisaccharide maltotriose and limit dextrins. It does not require activation by trypsin.

(Choices B, D, and E) Chymotrypsin, phospholipase A2 (which can damage cell membranes), and elastase are secreted by the pancreas as inactive precursors (chymotrypsinogen, prophospholipase A2, and proelastase) that are subsequently activated by trypsin.

(Choice C) Lipase hydrolyzes triglycerides into fatty acids and glycerol. It does not require activation by trypsin (although its activity is increased by colipase, which is activated by trypsin). Release of lipase during acute pancreatitis causes the formation of characteristic calcium soap deposits (fat necrosis).

Educational objective:
Pancreatic zymogens are normally converted into their active form by trypsin in the duodenal lumen. Premature cleavage of trypsinogen to trypsin within the pancreas leads to uncontrolled activation of these zymogens, causing

21877.mp4
https://t.me/USMLEWorldStep1
Show all

zymogens. Zymogen granules are secreted from the apical surface of acinar cells into the lumen. After traversing the pancreatic duct system, they drain through the ampulla of Vater into the descending part of the duodenum. The enzyme enterokinase (secreted from intestinal mucosa) cleaves trypsinogen into trypsin, its active form. Once a small quantity of trypsin is produced, it activates other zymogens, including chymotrypsin, elastase, and carboxypeptidase, through proteolytic cleavage. Trypsin can also cleave trypsinogen to produce more trypsin, accelerating pancreatic enzyme activation in the duodenum.

The pathogenesis of **acute pancreatitis** begins with either a toxic or an ischemic injury to the acinar cells that leads to **premature activation of trypsin** inside the pancreatic acini. Trypsin then activates the other proteolytic enzymes and starts a self-sustaining cycle of pancreatic inflammation and autodigestion with further release of digestive enzymes. In severe cases, this process can result in **necrotizing pancreatitis**, which is characterized by gross areas of parenchymal necrosis with a high propensity for secondary bacterial infection.

(Choice A) Amylase hydrolyzes starch to produce maltose (a glucose-glucose disaccharide) and trisaccharide maltotriose and limit dextrins. It does not require activation by trypsin.

(Choices B, D, and E) Chymotrypsin, phospholipase A2 (which can damage cell membranes), and elastase are secreted by the pancreas as inactive precursors (chymotrypsinogen, prophospholipase A2, and proelastase) that are subsequently activated by trypsin.

(Choice C) Lipase hydrolyzes triglycerides into fatty acids and glycerol. It does not require activation by trypsin (although its activity is increased by colipase, which is activated by trypsin). Release of lipase during acute pancreatitis causes the formation of characteristic calcium soap deposits (fat necrosis).

Educational objective:
Pancreatic zymogens are normally converted into their active form by trypsin in the duodenal lumen. Premature cleavage of trypsinogen to trypsin within the pancreas leads to uncontrolled activation of these zymogens, causing pancreatic autodigestion and acute pancreatitis.

Pathophysiology	Gastrointestinal & Nutrition	Acute pancreatitis
Subject	System	Topic

21877.mp4
https://t.me/USMLEWorldStep1
Show all

inflammation & destruction

& hemorrhage

Exhibit Display

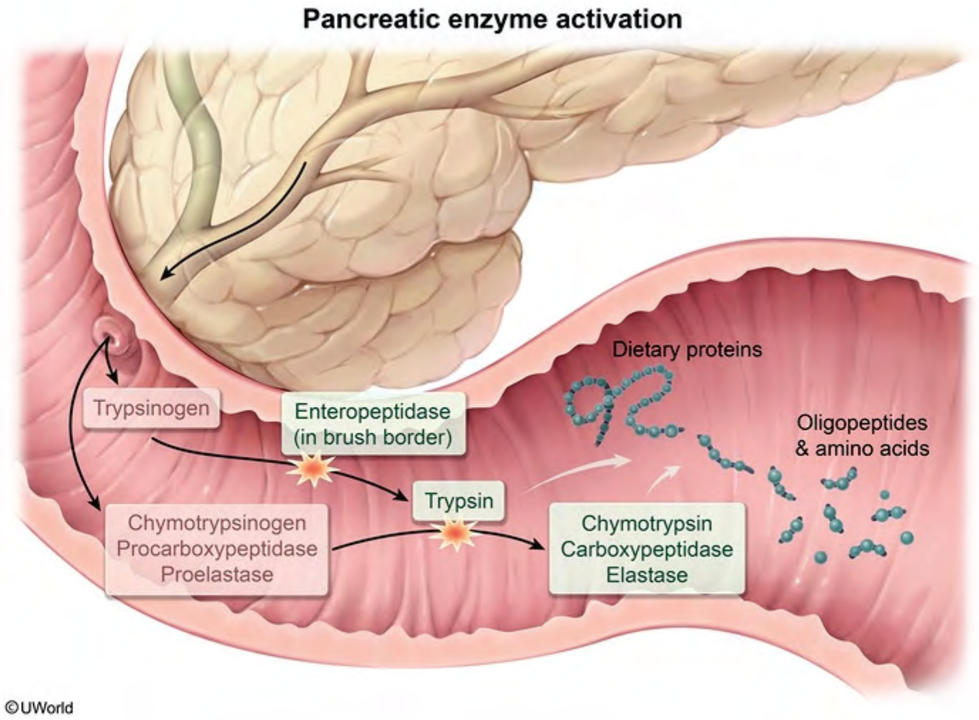

Zoom In | Zoom Out | Reset | New | Existing | My Notebook

Most p
zymog
the pa
The en
a sma
carbox
accele

The pa
leads t
enzym
digesti
gross

(Choi
maltot

(Choi
secret
are su

(Choi
(althou
pancre

Educa

Pancreatic zymogens are normally converted into their active form by trypsin in the duodenal lumen. Premature cleavage of trypsinogen to trypsin within the pancreas leads to uncontrolled activation of these zymogens, causing

21877.mp4
https://t.me/USMLEWorldStep1
Show all

A 26-year-old woman is evaluated for intermittent abdominal pain occurring over the last several years. The pain is crampy without radiation and graded 6/10 in intensity. She also has fluctuating diarrhea but has not seen blood in the stool. The patient has no nausea, vomiting, constipation, urinary frequency, dysuria, or vaginal symptoms. Her last menstrual period was 2 weeks ago. She does not use tobacco or alcohol. Temperature is 37.2 C (99 F), blood pressure is 115/70 mm Hg, and pulse is 90/min. On examination, the abdomen is tender without guarding or rebound. There is a draining fistula near her coccyx. Which of the following is the most likely diagnosis?

- A. Crohn disease
- B. Diverticulitis
- C. Intergluteal pilonidal disease
- D. Irritable bowel syndrome
- E. Ulcerative colitis

Submit

21877.mp4
https://t.me/USMLEWorldStep1
Show all

A 26-year-old woman is evaluated for intermittent abdominal pain occurring over the last several years. The pain is crampy without radiation and graded 6/10 in intensity. She also has fluctuating diarrhea but has not seen blood in the stool. The patient has no nausea, vomiting, constipation, urinary frequency, dysuria, or vaginal symptoms. Her last menstrual period was 2 weeks ago. She does not use tobacco or alcohol. Temperature is 37.2 C (99 F), blood pressure is 115/70 mm Hg, and pulse is 90/min. On examination, the abdomen is tender without guarding or rebound. There is a draining fistula near her coccyx. Which of the following is the most likely diagnosis?

- ✓ A. Crohn disease
- B. Diverticulitis
- C. Intergluteal pilonidal disease
- D. Irritable bowel syndrome
- E. Ulcerative colitis

Correct | Collecting Statistics | 03 secs Time Spent | 2023 Version

Explanation

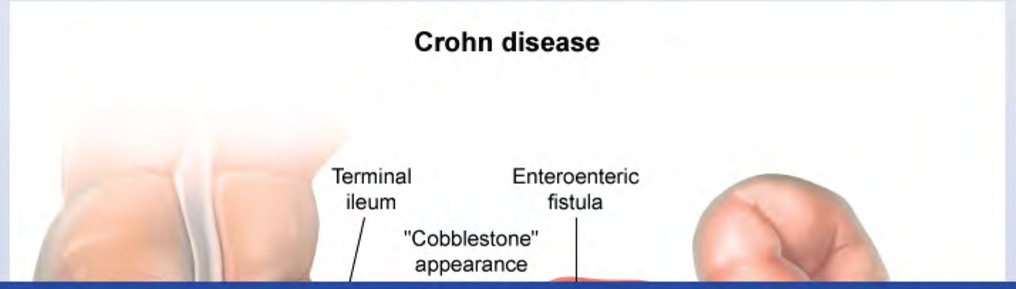

21877.mp4
https://t.me/USMLEWorldStep1
Show all

C. Intergluteal pilonidal disease

Exhibit Display

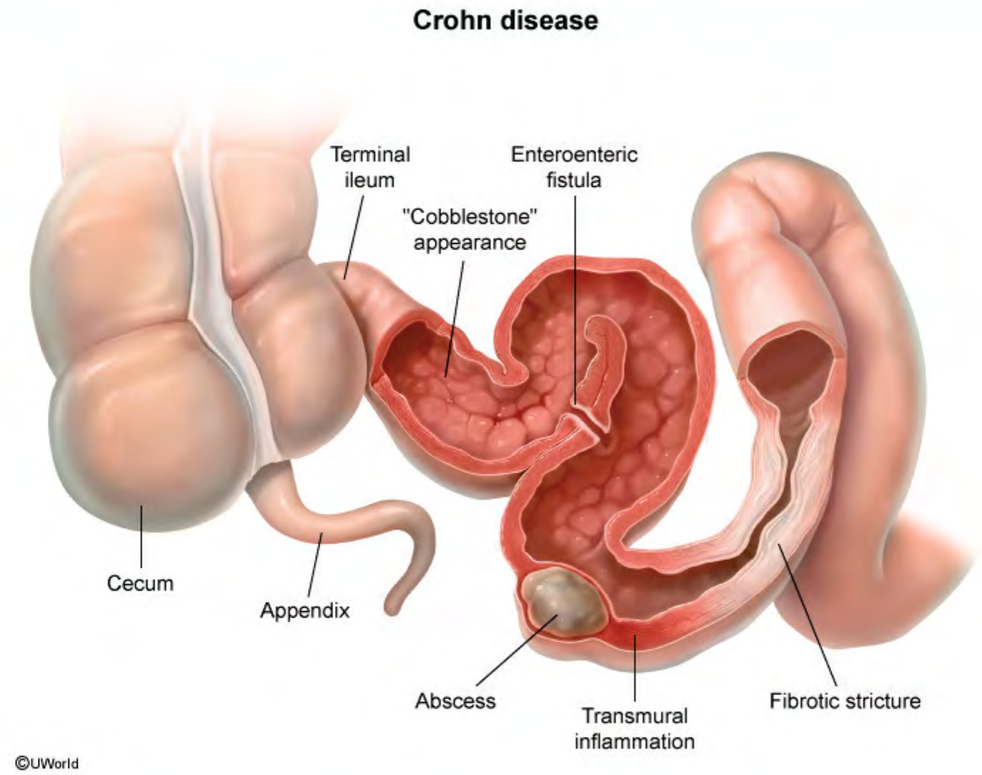

Zoom In | Zoom Out | Reset | New | Existing | My Notebook

21877.mp4
https://t.me/USMLEWorldStep1
Show all

This patient likely has **Crohn disease (CD)** complicated by a perianal fistula. CD can involve the gastrointestinal tract anywhere from the mouth to the anus but often spares the rectum. Patients typically present insidiously (over the course of years) with bouts of crampy **abdominal pain**, **diarrhea**, and constitutional symptoms (eg, fatigue, weight loss, fever). Fecal occult blood testing is often positive; however, grossly bloody stool is less commonly seen unless the colon is involved.

Patients are prone to developing fistulas and abscesses due to the **transmural inflammation** that occurs in CD. **Fistulas** are abnormal connections between 2 epithelial-lined organs. They are usually formed between the bowel and nearby structures that include the skin (enterocutaneous), urinary bladder (enterovesical), vagina (enterovaginal), or bowel (enteroenteric). **Perianal disease** other than fistulas is also common and may include skin tags and fissures.

(Choice B) Diverticulitis is characterized by inflammation of saclike protrusions (diverticula) that typically form in the sigmoid colon of older patients. It can present with left lower quadrant abdominal pain, diarrhea or constipation, low-grade fever, and fistulas; however, this patient's young age makes the diagnosis less likely.

(Choice C) Intergluteal pilonidal disease is a common skin condition involving the upper natal cleft of the buttocks. Although patients may present with draining sinus tracts in the intergluteal region, abdominal pain/tenderness and diarrhea are not characteristic.

(Choice D) Irritable bowel syndrome (IBS) is characterized by chronic abdominal pain associated with altered bowel habits (eg, diarrhea and/or constipation). Pain is often relieved with bowel movements. IBS is not an inflammatory condition and does not cause fistulas.

(Choice E) Ulcerative colitis is an inflammatory disease of the colonic mucosa that almost always affects the rectum and often presents with grossly bloody stool. Fistulas are not commonly seen as inflammation does not involve the full thickness of the bowel wall.

21877.mp4
https://t.me/USMLEWorldStep1
Show all

seen unless the colon is involved.

Patients are prone to developing fistulas and abscesses due to the **transmural inflammation** that occurs in CD. **Fistulas** are abnormal connections between 2 epithelial-lined organs. They are usually formed between the bowel and nearby structures that include the skin (enterocutaneous), urinary bladder (enterovesical), vagina (enterovaginal), or bowel (enteroenteric). **Perianal disease** other than fistulas is also common and may include skin tags and fissures.

(Choice B) Diverticulitis is characterized by inflammation of saclike protrusions (diverticula) that typically form in the sigmoid colon of older patients. It can present with left lower quadrant abdominal pain, diarrhea or constipation, low-grade fever, and fistulas; however, this patient's young age makes the diagnosis less likely.

(Choice C) Intergluteal pilonidal disease is a common skin condition involving the upper natal cleft of the buttocks. Although patients may present with draining sinus tracts in the intergluteal region, abdominal pain/tenderness and diarrhea are not characteristic.

(Choice D) Irritable bowel syndrome (IBS) is characterized by chronic abdominal pain associated with altered bowel habits (eg, diarrhea and/or constipation). Pain is often relieved with bowel movements. IBS is not an inflammatory condition and does not cause fistulas.

(Choice E) Ulcerative colitis is an inflammatory disease of the colonic mucosa that almost always affects the rectum and often presents with grossly bloody stool. Fistulas are not commonly seen as inflammation does not involve the full thickness of the bowel wall.

Educational objective:
Crohn disease typically presents with the insidious onset of abdominal pain, diarrhea, and constitutional symptoms (eg, weight loss, fever). Patients are prone to developing fistulas/abscesses as the lesions affect the entire thickness of the bowel wall. Perianal disease (eg, skin tags, fissures) is also common.

References

- Diagnosis and management of Crohn's disease.
- Natural history and long-term clinical course of Crohn's disease

21877.mp4
https://t.me/USMLEWorldStep1
Show all

Cecum

Exhibit Display

Crohn disease

©UWorld

Zoom In | Zoom Out | Reset | New | Existing | My Notebook

This p
tract a
the co
weight
seen u

Patien
Fistul
and ne
(enter
skin ta

(Choi
the sig
consti

(Choi
buttoc
pain/te

(Choi
bowel
inflammatory condition and does not cause fistulas.

21877.mp4
https://t.me/USMLEWorldStep1
Show all

Cecum

Exhibit Display

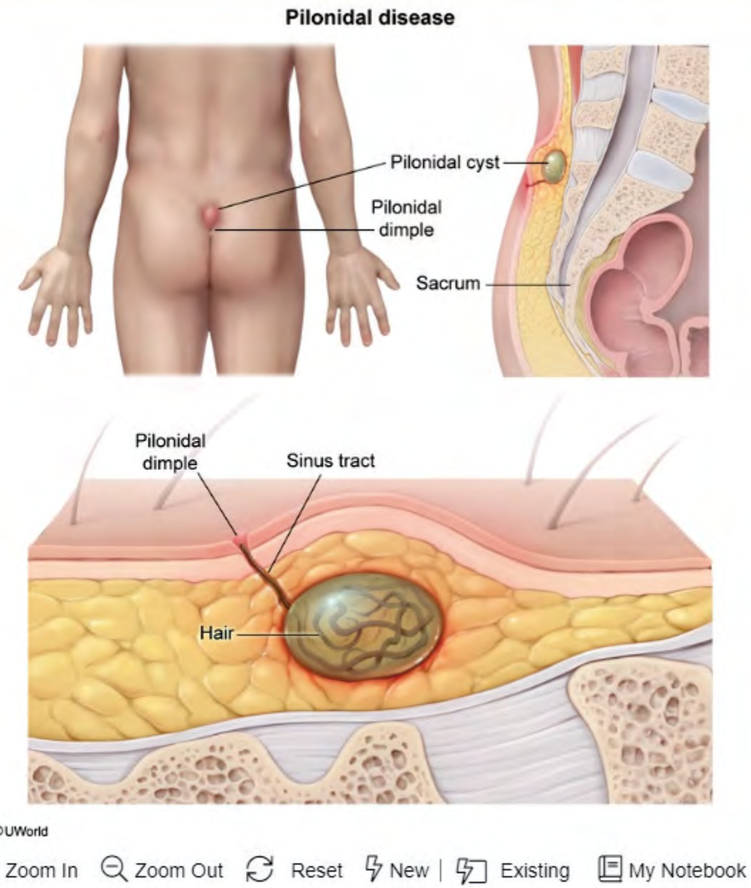

Zoom In | Zoom Out | Reset | New | Existing | My Notebook

This p
tract a
the co
weight
seen u

Patien
Fistul
and ne
(enter
skin ta

(Choi
the sig
consti

(Choi
buttoc
pain/te

(Choi
bowel
inflammatory condition and does not cause fistulas.

21877.mp4
https://t.me/USMLEWorldStep1
Show all

A 55-year-old man comes to the office due to intermittent abdominal pain. He has no difficulty or pain with swallowing. The patient occasionally uses over-the-counter pain medicine for osteoarthritis of the right knee. He does not use alcohol or tobacco and has no history of cancer in the family. He works as an air traffic controller at a busy airport. Upper gastrointestinal endoscopy shows an ulcer in the distal duodenum. Fasting serum gastrin concentration is at the upper limit of normal and rises in response to intravenous secretin. This patient's condition is most likely caused by which of the following processes?

- A. Autoimmune destruction
- B. *Helicobacter pylori* infection
- C. Mucosal immune dysregulation
- D. Neoplasm
- E. Nonsteroidal anti-inflammatory drug use
- F. Stress

Submit

21877.mp4
https://t.me/USMLEWorldStep1
Show all

A 55-year-old man comes to the office due to intermittent abdominal pain. He has no difficulty or pain with swallowing. The patient occasionally uses over-the-counter pain medicine for osteoarthritis of the right knee. He does not use alcohol or tobacco and has no history of cancer in the family. He works as an air traffic controller at a busy airport. Upper gastrointestinal endoscopy shows an ulcer in the distal duodenum. Fasting serum gastrin concentration is at the upper limit of normal and rises in response to intravenous secretin. This patient's condition is most likely caused by which of the following processes?

- A. Autoimmune destruction (2%)
- ✗ B. *Helicobacter pylori* infection (29%)
- C. Mucosal immune dysregulation (2%)
- ✓ D. Neoplasm (36%)
- E. Nonsteroidal anti-inflammatory drug use (22%)
- F. Stress (7%)

Incorrect
Correct answer
D

36%
Answered correctly

04 secs
Time Spent

2023
Version

Explanation

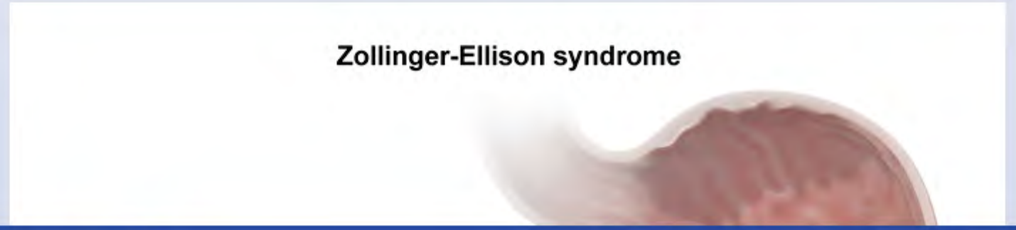

21877.mp4
https://t.me/USMLEWorldStep1
Show all

A 55-year-old man comes to the office due to intermittent abdominal pain. He has no difficulty or pain with swallo
does r
busy a
concer
is mos

Exhibit Display

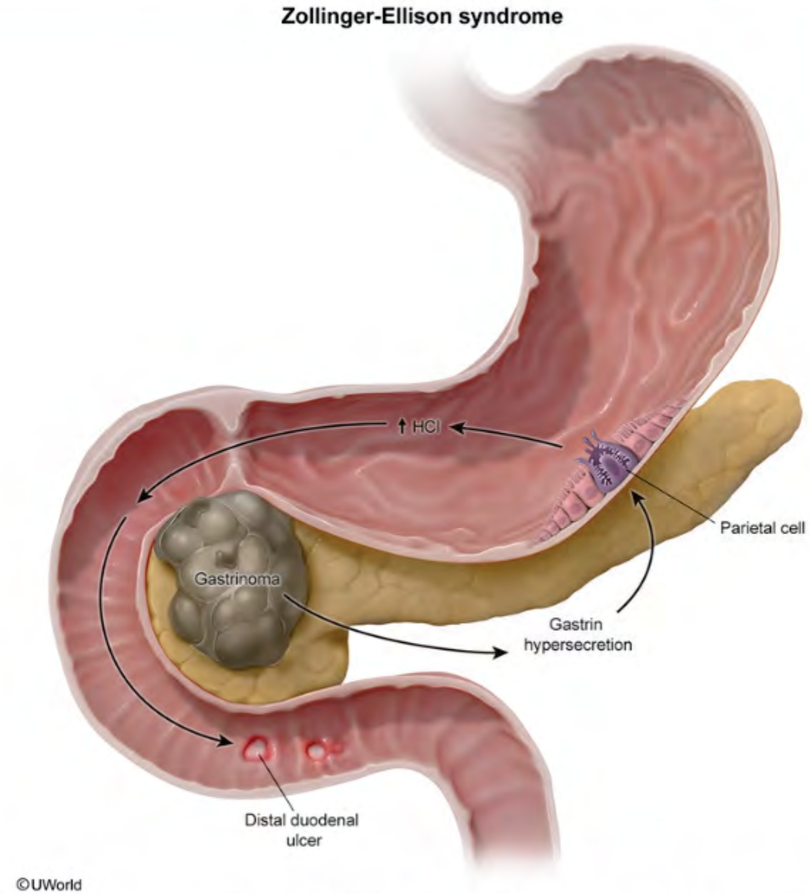

Zoom In Zoom Out Reset New | Existing My Notebook

Inco
Corre
D

Expl

21877.mp4
https://t.me/USMLEWorldStep1
Show all

©UWorld

This patient's distal duodenal ulcer and high-normal gastrin levels that rise in response to secretin administration are suggestive of **Zollinger-Ellison syndrome** (ZES). This condition is caused by **gastrin-secreting tumors** (gastrinomas) that are often malignant and usually located in the small intestine or pancreas. Gastrin causes parietal cell hyperplasia and stimulates gastric acid secretion, resulting in the development of **peptic ulcers**, heartburn, and **diarrhea** (excess gastric acid impairs intestinal epithelial cells and digestive enzymes). Although most proximal duodenal ulcers are caused by *Helicobacter pylori* infection or nonsteroidal anti-inflammatory drug (NSAID) use **(Choice E)**, ulcers found **beyond the duodenal bulb** suggest ZES.

Secretin is a hormone released from the duodenum in response to acid and fat in the small intestine. The hormone increases pancreatic bicarbonate secretion and inhibits the release of gastrin from normal gastric G cells. However, secretin paradoxically **stimulates gastrin release from gastrinomas** due to abnormal adenylate cyclase activation. As such, secretin administration can be used to differentiate ZES from other causes of hypergastrinemia (eg, atrophic gastritis).

(Choice A) Autoimmune gastritis (chronic atrophic gastritis) involves the body/fundus of the stomach with antral sparing. $CD4^+$ T cell-mediated parietal cell destruction causes impaired gastric acid and intrinsic factor secretion, resulting in achlorhydria and pernicious anemia, respectively. Low acid levels stimulate gastrin release from G cells (hypergastrinemia), but secretin administration causes a reduction in gastrin levels.

(Choice B) *H pylori* infection is associated with chronic antral-predominant gastritis, which may lead to a reduction in somatostatin-producing cells (delta cells). Lack of inhibition by somatostatin allows for excessive gastrin release, which promotes gastric acid hypersecretion and proximal duodenal ulcer formation. Secretin administration typically causes a reduction in gastrin levels in these patients.

(Choice C) Crohn disease is associated with dysregulation of the mucosal immune response, intestinal epithelial dysfunction, and altered composition of gut flora. Patients characteristically have linear ulcerations with adjacent normal-appearing mucosa (cobblestone appearance) in the small intestine.

(Choice E) Stress-related mucosal disease can occur with severe physiologic stress (eg, shock, head trauma

21877.mp4
https://t.me/USMLEWorldStep1
Show all

hormone increases pancreatic bicarbonate secretion and inhibits the release of gastrin from normal gastric G cells. However, secretin paradoxically **stimulates gastrin release from gastrinomas** due to abnormal adenylate cyclase activation. As such, secretin administration can be used to differentiate ZES from other causes of hypergastrinemia (eg, atrophic gastritis).

(Choice A) Autoimmune gastritis (chronic atrophic gastritis) involves the body/fundus of the stomach with antral sparing. $CD4^+$ T cell-mediated parietal cell destruction causes impaired gastric acid and intrinsic factor secretion, resulting in achlorhydria and pernicious anemia, respectively. Low acid levels stimulate gastrin release from G cells (hypergastrinemia), but secretin administration causes a reduction in gastrin levels.

(Choice B) *H pylori* infection is associated with chronic antral-predominant gastritis, which may lead to a reduction in somatostatin-producing cells (delta cells). Lack of inhibition by somatostatin allows for excessive gastrin release, which promotes gastric acid hypersecretion and proximal duodenal ulcer formation. Secretin administration typically causes a reduction in gastrin levels in these patients.

(Choice C) Crohn disease is associated with dysregulation of the mucosal immune response, intestinal epithelial dysfunction, and altered composition of gut flora. Patients characteristically have linear ulcerations with adjacent normal-appearing mucosa (cobblestone appearance) in the small intestine.

(Choice F) Stress-related mucosal disease can occur with severe physiologic stress (eg, shock, head trauma, burns), but the association between psychological stress (eg, working as an air traffic controller) and peptic ulcer formation is controversial. Nonetheless, neither form of stress would cause distal duodenal ulcers and hypergastrinemia.

Educational objective:
Zollinger-Ellison syndrome is caused by gastrinomas located in the small intestine/pancreas and presents with peptic ulcers (especially distal duodenal ulcers), heartburn, and diarrhea. Patients typically have elevated gastrin levels that rise in response to exogenous secretin administration. In contrast, secretin inhibits release of gastrin from normal gastric G cells.

References

21877.mp4
https://t.me/USMLEWorldStep1
Show all

A 32-year-old man is evaluated due to several weeks of watery diarrhea. He has also had intermittent, crampy abdominal pain and has lost 7.0 kg (15.4 lb) during this period. The patient has a history of HIV and was hospitalized 6 months ago for *Pneumocystis* pneumonia. On physical examination, the patient is afebrile and the abdomen is soft and nontender with no organomegaly. Stool tests for leukocytes and occult blood are negative. Endoscopy is performed and mucosal biopsy shows an inflammatory infiltrate in the lamina propria and pathogens lining the epithelium, as shown in the exhibit. Which of the following is the most likely cause of this patient's condition?

- A. *Cryptosporidium parvum*
- B. Cytomegalovirus
- C. *Entamoeba histolytica*
- D. *Giardia lamblia*
- E. *Mycobacterium avium* complex

Submit

21877.mp4
https://t.me/USMLEWorldStep1
Show all

A 32-year-old man is evaluated due to several weeks of watery diarrhea. He has also had intermittent, crampy abdominal pain and has lost 7.0 kg (15.4 lb) during this period. The patient has a history of HIV and was hospitalized 6 months ago for *Pneumocystis* pneumonia. On physical examination, the patient is afebrile and the abdomen is soft and nontender with no organomegaly. Stool tests for leukocytes and occult blood are negative. Endoscopy is performed and mucosal biopsy shows an inflammatory infiltrate in the lamina propria and pathogens lining the epithelium, as shown in the exhibit. Which of the following is the most likely cause of this patient's condition?

- ✓ A. *Cryptosporidium parvum* (62%)
- ✗ B. Cytomegalovirus (11%)
- C. *Entamoeba histolytica* (7%)
- D. *Giardia lamblia* (13%)
- E. *Mycobacterium avium* complex (4%)

Incorrect
Correct answer
A

62%
Answered correctly

03 secs
Time Spent

2023
Version

Explanation

Cryptosporidiosis	
Pathogenesis	• Fecal-oral transmission (eg, contaminated water, animal contact) • Oocyte ingestion → sporozoite attachment to intestinal epithelium → intraluminal meront formation → fecal oocyte shedding

21877.mp4
https://t.me/USMLEWorldStep1
Show all

A 32-year-old man is evaluated due to several weeks of watery diarrhea. He has also had intermittent, crampy abdom
hospit
abdom
Endos
lining t
conditi

Incc
Corre
A

Expl

meront formation → fecal oocyte shedding

Exhibit Display

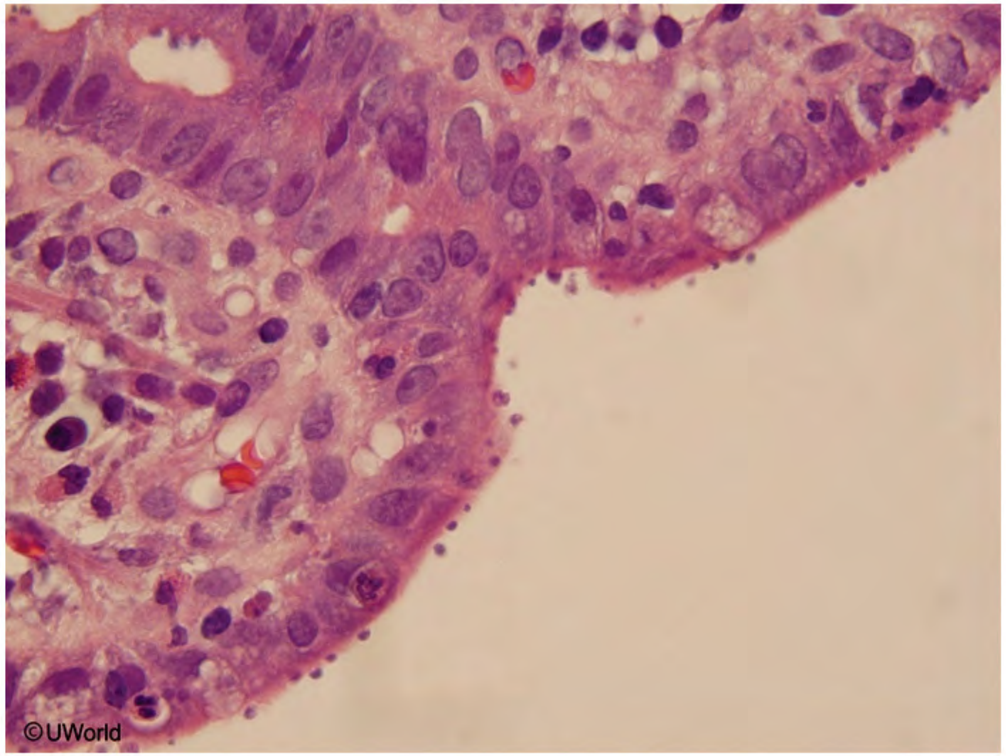

Zoom In Zoom Out Reset New | Existing My Notebook

21877.mp4
https://t.me/USMLEWorldStep1
Show all

Cryptosporidiosis	
Pathogenesis	• Fecal-oral transmission (eg, contaminated water, animal contact) • Oocyte ingestion → sporozoite attachment to intestinal epithelium → intraluminal meront formation → fecal oocyte shedding
Clinical manifestations	• Immunocompetent: self-resolving, watery (noninflammatory) diarrhea <2 weeks • Immunosuppressed (eg, AIDS, transplant recipient): prolonged, severe diarrhea with weight loss/malabsorption
Diagnosis	• Stool PCR testing • Stool microscopy: acid-fast staining oocysts or immunofluorescent assay • Histology: basophilic *Cryptosporidium* organisms on intestinal brush border, small intestine villous blunting, lamina propria inflammation

Cryptosporidium is a protozoan that causes infectious diarrhea. Oocysts are ingested in contaminated water (less commonly in food), travel to the small intestine, and shed sporozoites that attach to **epithelial cells**. They then mature intraluminally into meronts capable of invading new host intestinal cells (eg, auto-infection) as well as producing oocytes that are then shed in feces.

Patients who are otherwise healthy develop self-limited, **watery diarrhea** that typically lasts <2 weeks. However, those with impaired cell-mediated immunity—particularly individuals with **AIDS** (as is likely in this patient with HIV who recently had *Pneumocystis* pneumonia)—are at risk for life-threatening diarrhea with fluid loss sometimes exceeding >20 L per day.

The diagnosis can be made by stool PCR testing or modified **acid-fast stain**, which usually reveals *Cryptosporidium* **oocysts**. Standard ova and parasite stool tests cannot detect the organism, and fecal leukocytes/occult blood tests are often negative (ie, noninflammatory). Histopathologic findings include small intestinal villous blunting, inflammatory infiltration within the lamina propria, and **basophilic *Cryptosporidium***

21877.mp4
https://t.me/USMLEWorldStep1
Show all

Clinical manifestations	• Immunocompetent: self-resolving, watery (noninflammatory) diarrhea <2 weeks • Immunosuppressed (eg, AIDS, transplant recipient): prolonged, severe diarrhea with weight loss/malabsorption
Diagnosis	• Stool PCR testing • Stool microscopy: acid-fast staining oocysts or immunofluorescent assay • Histology: basophilic *Cryptosporidium* organisms on intestinal brush border, small intestine villous blunting, lamina propria inflammation

Cryptosporidium is a protozoan that causes infectious diarrhea. Oocysts are ingested in contaminated water (less commonly in food), travel to the small intestine, and shed sporozoites that attach to **epithelial cells**. They then mature intraluminally into meronts capable of invading new host intestinal cells (eg, auto-infection) as well as producing oocytes that are then shed in feces.

Patients who are otherwise healthy develop self-limited, **watery diarrhea** that typically lasts <2 weeks. However, those with impaired cell-mediated immunity—particularly individuals with **AIDS** (as is likely in this patient with HIV who recently had *Pneumocystis* pneumonia)—are at risk for life-threatening diarrhea with fluid loss sometimes exceeding >20 L per day.

The diagnosis can be made by stool PCR testing or modified **acid-fast stain**, which usually reveals *Cryptosporidium* **oocysts**. Standard ova and parasite stool tests cannot detect the organism, and fecal leukocytes/occult blood tests are often negative (ie, noninflammatory). Histopathologic findings include small intestinal villous blunting, inflammatory infiltration within the lamina propria, and **basophilic *Cryptosporidium* organisms** on the mucosal brush border.

(Choice B) Cytomegalovirus (CMV) enterocolitis in immunosuppressed patients may cause profuse diarrhea, but biopsies of CMV-infected tissues reveal large cells with intranuclear and intracytoplasmic inclusions (eg, owl's eye appearance); organisms lining the epithelium would not be seen. In addition, most patients have abdominal pain and fever.

(Choice C) *Entamoeba histolytica* is a protozoan that usually causes dysentery (bloody diarrhea); this patient's

21877.mp4
https://t.me/USMLEWorldStep1
Show all

The diagnosis can be made by stool PCR testing or modified **acid-fast stain**, which usually reveals *Cryptosporidium* **oocysts**. Standard ova and parasite stool tests cannot detect the organism, and fecal leukocytes/occult blood tests are often negative (ie, noninflammatory). Histopathologic findings include small intestinal villous blunting, inflammatory infiltration within the lamina propria, and **basophilic *Cryptosporidium* organisms** on the mucosal brush border.

(Choice B) Cytomegalovirus (CMV) enterocolitis in immunosuppressed patients may cause profuse diarrhea, but biopsies of CMV-infected tissues reveal large cells with intranuclear and intracytoplasmic inclusions (eg, owl's eye appearance); organisms lining the epithelium would not be seen. In addition, most patients have abdominal pain and fever.

(Choice C) *Entamoeba histolytica* is a protozoan that usually causes dysentery (bloody diarrhea); this patient's negative fecal leukocytes and blood make this diagnosis less likely. Moreover, histopathology generally reveals flask-shaped colonic ulcers with "foamy" trophozoites that resemble macrophages.

(Choice D) *Giardia lamblia* is a protozoan that causes foul-smelling, oily diarrhea (steatorrhea) from fat malabsorption, which can lead to weight loss. Unlike this case, stool microscopy shows oval-shaped cysts and flagellated pear-shaped trophozoites with two large central nuclei.

(Choice E) *Mycobacterium avium* complex is an opportunistic infection in patients with advanced HIV (CD4 count <50/mm^3) and often causes watery diarrhea and weight loss. However, the organism rapidly penetrates the mucosa and disseminates throughout the reticuloendothelial system (eg, lymphadenopathy, hepatosplenomegaly); it does not remain attached to the intestinal mucosa.

Educational objective:
Cryptosporidium may lead to severe and protracted diarrhea in immunocompromised patients (eg, advanced HIV). Diagnosis is usually made by visualizing acid-fast staining oocysts in the stool. The presence of basophilic organisms lining the brush border on intestinal histopathology is also diagnostic.

References

- Cryptosporidium infection: epidemiology, pathogenesis, and differential diagnosis.

21877.mp4
https://t.me/USMLEWorldStep1
Show all

The diagnosis can be made by stool PCR testing or modified **acid-fast stain**, which usually reveals *Cryptosporidium* **oocysts**. Standard ova and parasite stool tests cannot detect the organism, and fecal leukoc
intesti
organ

(Choi
biopsie
appea
and fe

(Choi
negati
flask-s

(Choi
malab
flagell

(Choi
<50/m
mucos
it does

Educa
Crypto
Diagn
organi

Refere
- Cryptosporidium infection: epidemiology, pathogenesis, and differential diagnosis.

Exhibit Display

Cryptosporidiosis

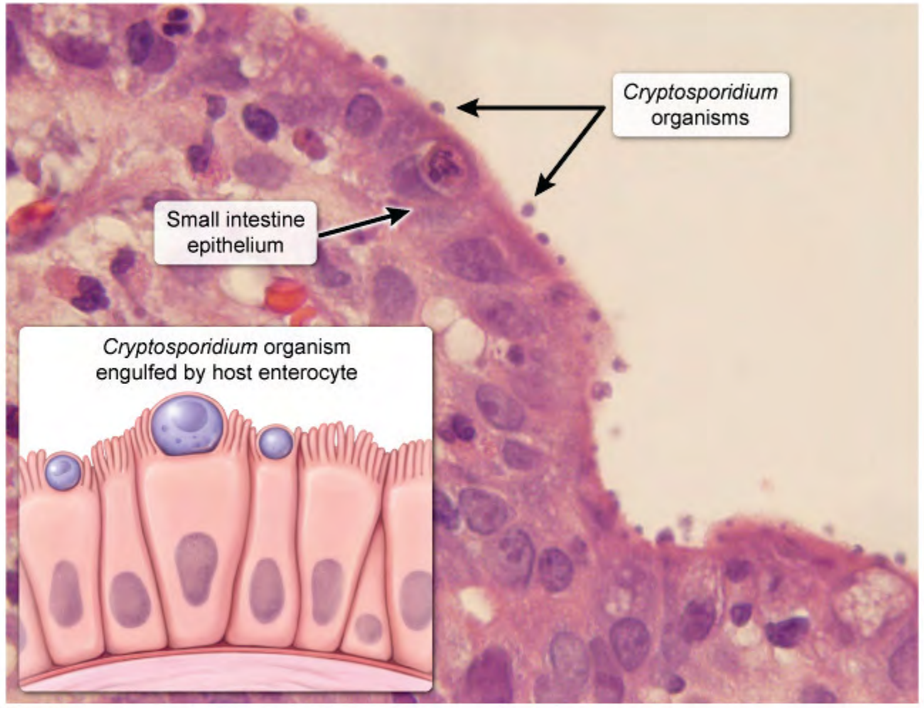

©UWorld

Zoom In | Zoom Out | Reset | New | Existing | My Notebook

21877.mp4
https://t.me/USMLEWorldStep1
Show all

The diagnosis can be made by stool PCR testing or modified **acid-fast stain**, which usually reveals *Cryptosporidium* **oocysts**. Standard ova and parasite stool tests cannot detect the organism, and fecal leukoc
intesti
organ

(Choi
biopsi
appea
and fe

(Choi
negati
flask-s

(Choi
malab
flagell

(Choi
<50/m
mucos
it does

Educa
Crypto
Diagn
organi

Refere

- Cryptosporidium infection: epidemiology, pathogenesis, and differential diagnosis.

Exhibit Display

Cytomegalovirus

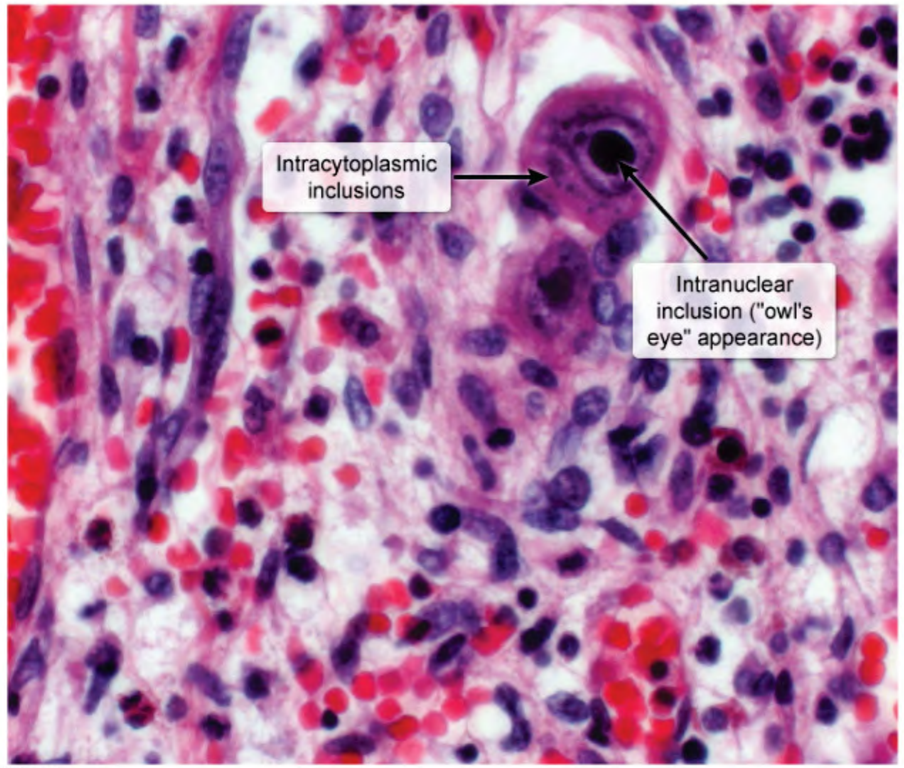

©UWorld

Zoom In Zoom Out Reset New | Existing My Notebook

21877.mp4
https://t.me/USMLEWorldStep1
Show all

The diagnosis can be made by stool PCR testing or modified **acid-fast stain**, which usually reveals *Cryptosporidium* **oocysts**. Standard ova and parasite stool tests cannot detect the organism, and fecal leukoc
intesti
organ

(Choi
biopsie
appea
and fe

(Choi
negati
flask-s

(Choi
malab
flagell

(Choi
<50/m
mucos
it does

Educa
Crypto
Diagn
organi

Refere
- Cryptosporidium infection: epidemiology, pathogenesis, and differential diagnosis.

Exhibit Display

Amebiasis

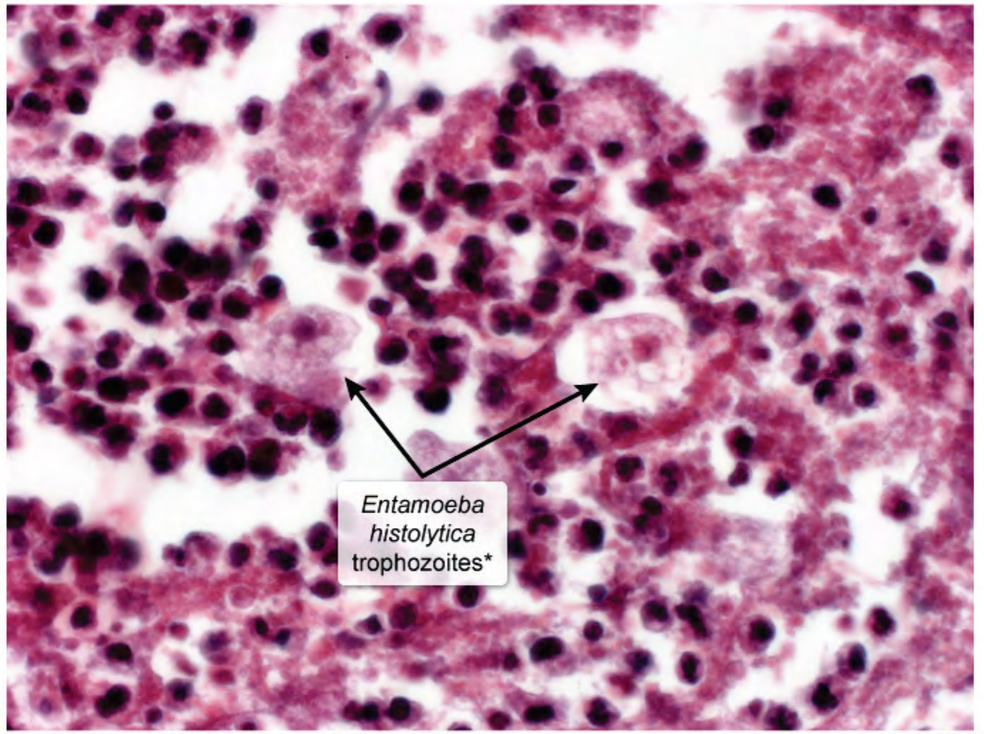

*Vacuolated cytoplasm with ingested erythrocytes.

©UWorld

Zoom In | Zoom Out | Reset | New | Existing | My Notebook

21877.mp4
https://t.me/USMLEWorldStep1
Show all

The diagnosis can be made by stool PCR testing or modified **acid-fast stain**, which usually reveals *Cryptosporidium* **oocysts**. Standard ova and parasite stool tests cannot detect the organism, and fecal leukoc
intesti
organ

(Choi
biopsie
appea
and fe

(Choi
negati
flask-s

(Choi
malab
flagell

(Choi
<50/m
mucos
it does

Educa
Crypto
Diagn
organi

Refere
- Cryptosporidium infection: epidemiology, pathogenesis, and differential diagnosis.

Exhibit Display

Giardia

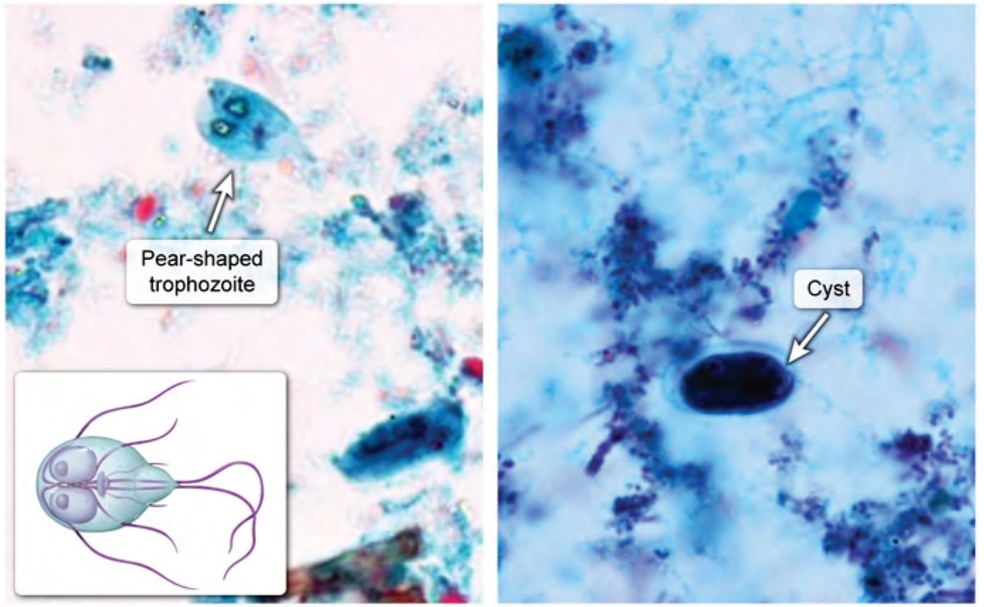

©UWorld

Zoom In | Zoom Out | Reset | New | Existing | My Notebook

21877.mp4
https://t.me/USMLEWorldStep1
Show all

The diagnosis can be made by stool PCR testing or modified **acid-fast stain**, which usually reveals *Cryptosporidium* **oocysts**. Standard ova and parasite stool tests cannot detect the organism, and fecal leukoc
intesti
organ

(Choi
biopsie
appea
and fe

(Choi
negati
flask-s

(Choi
malab
flagell

(Choi
<50/m
mucos
it does

Educa
Crypto
Diagn
organi

Refere
- Cryptosporidium infection: epidemiology, pathogenesis, and differential diagnosis.

Exhibit Display

***Mycobacterium avium* complex (MAC)**

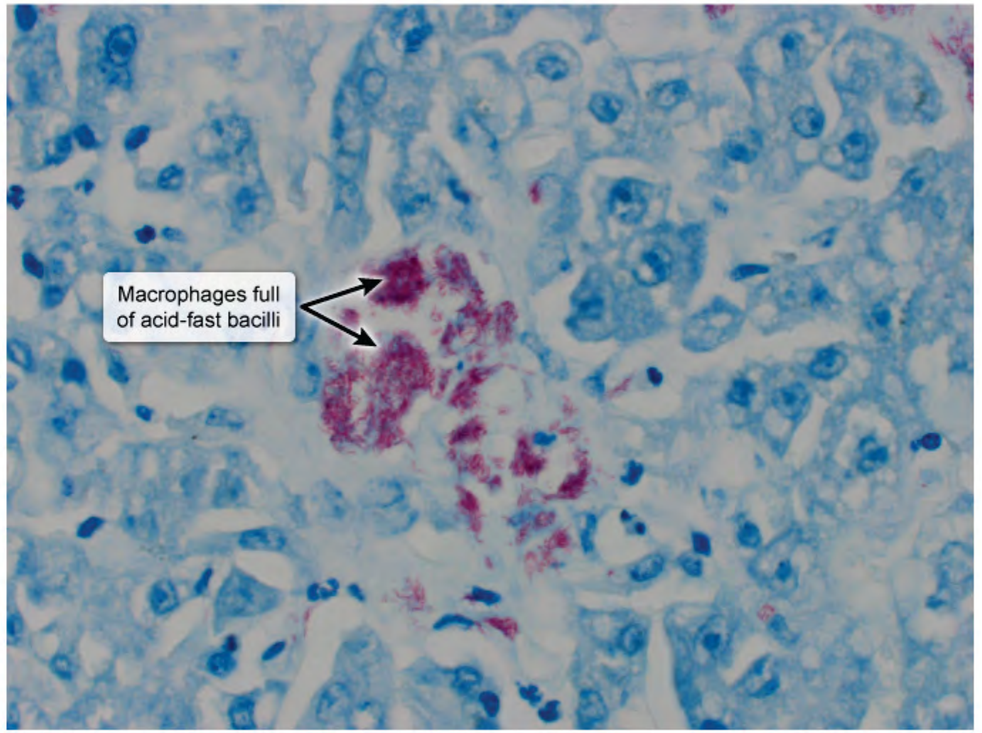

Acid-fast stain

©UWorld

Zoom In | Zoom Out | Reset | New | Existing | My Notebook

21877.mp4
https://t.me/USMLEWorldStep1
Show all

A 15-year-old girl is hospitalized due to confusion and hematemesis for 2 days. Medical history is notable for depression over the past year. Temperature is 37.2 C (99 F), blood pressure is 86/56 mm Hg, pulse is 112/min, and respirations are 20/min; BMI is 23 kg/m^2. She is oriented to person but disoriented to time and place. The patient quickly deteriorates and dies during hospitalization. Autopsy examination reveals a nodular liver, esophageal varices, splenomegaly, and atrophy of the basal ganglia with increased copper content. The most likely cause of this patient's condition is an abnormality in which of the following physiologic processes?

- A. Biliary excretion
- B. Immunoglobulin production
- C. Intestinal absorption
- D. Lipid metabolism
- E. Renal tubular reabsorption

Submit

21877.mp4
https://t.me/USMLEWorldStep1
Show all

A 15-year-old girl is hospitalized due to confusion and hematemesis for 2 days. Medical history is notable for depression over the past year. Temperature is 37.2 C (99 F), blood pressure is 86/56 mm Hg, pulse is 112/min, and respirations are 20/min; BMI is 23 kg/m^2. She is oriented to person but disoriented to time and place. The patient quickly deteriorates and dies during hospitalization. Autopsy examination reveals a nodular liver, esophageal varices, splenomegaly, and atrophy of the basal ganglia with increased copper content. The most likely cause of this patient's condition is an abnormality in which of the following physiologic processes?

- ✓ A. Biliary excretion (56%)
- B. Immunoglobulin production (1%)
- C. Intestinal absorption (34%)
- D. Lipid metabolism (3%)
- E. Renal tubular reabsorption (3%)

Correct

56%
Answered correctly

03 secs
Time Spent

2023
Version

Explanation

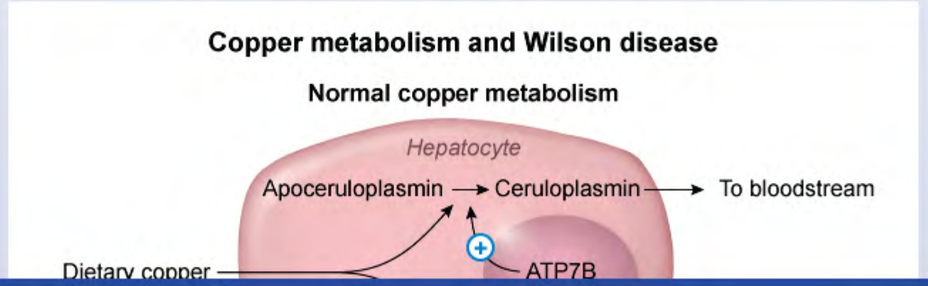

21877.mp4
https://t.me/USMLEWorldStep1
Show all

A 15-year-old girl is hospitalized due to confusion and hematemesis for 2 days. Medical history is notable for depres
and re
patien
esoph
likely c

Exhibit Display

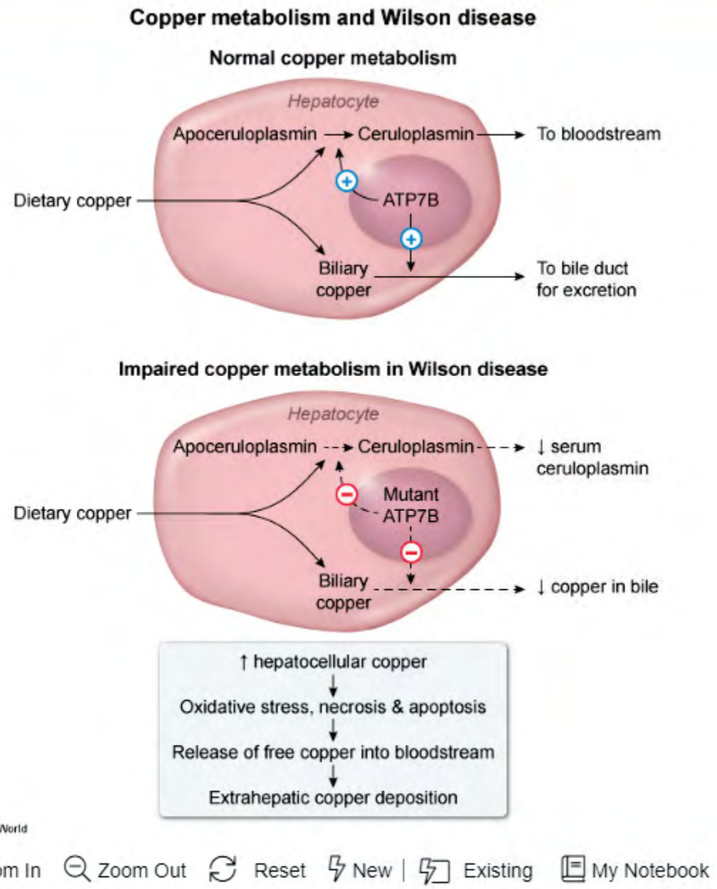

Zoom In | Zoom Out | Reset | New | Existing | My Notebook

21877.mp4
https://t.me/USMLEWorldStep1
Show all

©UWorld

This patient has evidence of **cirrhosis** (eg, nodular liver, splenomegaly, esophageal varices) with **acute liver failure** (ie, encephalopathy) in addition to copper deposition in the basal ganglia. These findings are consistent with **Wilson disease**, an autosomal recessive disorder characterized by accumulation of copper due to a **defective copper transport protein**, ATP7B.

In general, dietary copper is absorbed in the stomach and duodenum and bound to circulating albumin. It is then transported to the liver and taken up by hepatocytes. Excessive intracellular copper levels normally cause ATP7B to transfer the excess copper into the bile canaliculi. This process is essential for biliary excretion of copper, which accounts for the majority of total body copper excretion.

In Wilson disease, defective ATP7B results in **impaired biliary excretion** of copper. The **accumulation** of **hepatocellular copper** results in oxidative stress and apoptosis. Upon cell death, free copper is released into the bloodstream and **deposited into extrahepatic tissues** (eg, basal ganglia, cornea), causing the classic triad of hepatic, neurologic, and psychiatric (eg, depression) symptoms.

ATP7B is also required for the hepatic production of ceruloplasmin, which is apoceruloplasmin bound to copper. The inability to create and secrete ceruloplasmin in Wilson disease results in low serum ceruloplasmin. This abnormality does not account for the clinical manifestations of Wilson disease but is an important diagnostic finding.

(Choice B) Autoimmune hepatitis due to production of autoantibodies can cause cirrhosis and acute liver failure but not copper accumulation.

(Choice C) Hereditary hemochromatosis is an autosomal recessive disorder that can cause cirrhosis due to increased intestinal absorption of iron, not copper.

(Choice D) Niemann-Pick disease and Gaucher disease are lipid storage disorders that cause hepatosplenomegaly. Symptoms usually present in early childhood, and copper deposition is not seen in either condition.

21877.mp4
https://t.me/USMLEWorldStep1
Show all

accounts for the majority of total body copper excretion.

In Wilson disease, defective ATP7B results in **impaired biliary excretion** of copper. The **accumulation** of **hepatocellular copper** results in oxidative stress and apoptosis. Upon cell death, free copper is released into the bloodstream and **deposited into extrahepatic tissues** (eg, basal ganglia, cornea), causing the classic triad of hepatic, neurologic, and psychiatric (eg, depression) symptoms.

ATP7B is also required for the hepatic production of ceruloplasmin, which is apoceruloplasmin bound to copper. The inability to create and secrete ceruloplasmin in Wilson disease results in low serum ceruloplasmin. This abnormality does not account for the clinical manifestations of Wilson disease but is an important diagnostic finding.

(Choice B) Autoimmune hepatitis due to production of autoantibodies can cause cirrhosis and acute liver failure but not copper accumulation.

(Choice C) Hereditary hemochromatosis is an autosomal recessive disorder that can cause cirrhosis due to increased intestinal absorption of iron, not copper.

(Choice D) Niemann-Pick disease and Gaucher disease are lipid storage disorders that cause hepatosplenomegaly. Symptoms usually present in early childhood, and copper deposition is not seen in either condition.

(Choice E) Renal copper deposition in Wilson disease can cause Fanconi syndrome (eg, proximal tubular dysfunction). However, this occurs as a result of impaired biliary excretion of copper; it is not the cause of copper accumulation in Wilson disease.

Educational objective:
Wilson disease is caused by defective copper transport within hepatocytes, which leads to impaired biliary excretion of copper. Hepatic copper accumulation eventually results in the release of free copper into the bloodstream and copper deposition into extrahepatic tissues (eg, basal ganglia, cornea).

References

21877.mp4
https://t.me/USMLEWorldStep1
Show all

A 1-day-old girl is evaluated in the nursery due to persistent vomiting and refusal to feed since early in the morning. The vomitus appears green-yellow. It does not contain blood. The infant appears dehydrated. Examination shows a distended abdomen. The remainder of the physical examination is unremarkable. After initial evaluation, the infant undergoes laparotomy. The full length of the duodenum is present. The proximal jejunum ends in a blind pouch. The distal jejunum and proximal ileum are absent. The distal ileum is present and winds around a thin vascular stalk. Which of the following embryologic processes is most likely responsible for this patient's condition?

- A. Amniotic band constriction
- B. Cell migration failure
- C. Partitioning failure
- D. Recanalization failure
- E. Vascular occlusion

Submit

21877.mp4
https://t.me/USMLEWorldStep1
Show all

A 1-day-old girl is evaluated in the nursery due to persistent vomiting and refusal to feed since early in the morning. The vomitus appears green-yellow. It does not contain blood. The infant appears dehydrated. Examination shows a distended abdomen. The remainder of the physical examination is unremarkable. After initial evaluation, the infant undergoes laparotomy. The full length of the duodenum is present. The proximal jejunum ends in a blind pouch. The distal jejunum and proximal ileum are absent. The distal ileum is present and winds around a thin vascular stalk. Which of the following embryologic processes is most likely responsible for this patient's condition?

- A. Amniotic band constriction (11%)
- ✗ B. Cell migration failure (14%)
- C. Partitioning failure (9%)
- D. Recanalization failure (42%)
- ✓ E. Vascular occlusion (21%)

Incorrect
Correct answer
E

21%
Answered correctly

03 secs
Time Spent

2023
Version

Explanation

Small intestine atresia		
	Duodenal	**Jejunal/ileal**
Pathophysiology	• Recanalization failure	• Vascular occlusion
	• Abdominal distension (mild,	• Abdominal distension (marked)

21877.mp4
https://t.me/USMLEWorldStep1
Show all

Small intestine atresia		
	Duodenal	**Jejunal/ileal**
Pathophysiology	• Recanalization failure	• Vascular occlusion
Initial evaluation	• Abdominal distension (mild, epigastric) • Emesis (± bilious) • X-ray: gastric & proximal duodenal dilation (double bubble sign); absent distal gas	• Abdominal distension (marked) • Emesis (bilious) • X-ray: dilated loops of small bowel with air-fluid levels; absent distal gas
Associations	• Chromosomal abnormality (eg, trisomy 21)	• Other intestinal pathology (eg, gastroschisis, volvulus)

This infant has **bilious emesis**, a sign of intestinal **obstruction distal** to the second part of the duodenum (where the common bile duct enters the intestine). In a neonate, causes include malrotation/volvulus, small intestine atresia, and colon disorders (eg, Hirschsprung disease); less commonly, extrinsic compression of the bowel (eg, annular pancreas) can occur. In this case, the patient has a blind-ending jejunum and parts of the distal small intestine are absent, confirming **intestinal atresia**.

The pathophysiology of intestinal atresia varies based on the segment of bowel involved. In duodenal atresia, the mechanism involves failure of the lumen to recanalize after epithelial proliferation in the first trimester **(Choice D)**. In contrast, intestinal atresia of the **midgut** (eg, jejunum, ileum, proximal colon) is the result of **vascular occlusion** in utero. Risk factors include underlying intestinal abnormality (eg, gastroschisis) or maternal use of vasoconstrictive drugs or substances (eg, nicotine).

Compromised perfusion leads to ischemia of a bowel segment, with subsequent narrowing (stenosis) or obliteration (atresia) of the lumen. This patient most likely developed occlusion of the **superior mesenteric artery**

21877.mp4
https://t.me/USMLEWorldStep1
Show all

	trisomy 21)	gastroschisis, volvulus)

This infant has **bilious emesis**, a sign of intestinal **obstruction distal** to the second part of the duodenum (where the common bile duct enters the intestine). In a neonate, causes include malrotation/volvulus, small intestine atresia, and colon disorders (eg, Hirschsprung disease); less commonly, extrinsic compression of the bowel (eg, annular pancreas) can occur. In this case, the patient has a blind-ending jejunum and parts of the distal small intestine are absent, confirming **intestinal atresia**.

The pathophysiology of intestinal atresia varies based on the segment of bowel involved. In duodenal atresia, the mechanism involves failure of the lumen to recanalize after epithelial proliferation in the first trimester **(Choice D)**. In contrast, intestinal atresia of the **midgut** (eg, jejunum, ileum, proximal colon) is the result of **vascular occlusion** in utero. Risk factors include underlying intestinal abnormality (eg, gastroschisis) or maternal use of vasoconstrictive drugs or substances (eg, nicotine).

Compromised perfusion leads to ischemia of a bowel segment, with subsequent narrowing (stenosis) or obliteration (atresia) of the lumen. This patient most likely developed occlusion of the **superior mesenteric artery**, resulting in ischemia, necrosis, and resorption of the distal small bowel associated with the dorsal mesentery. The jejunum proximal to the ischemic segment ends in a blind pouch, and the ileum distal to the segment spirals around the ileocolic vessel that perfuses it (apple peel atresia).

(Choice A) Amniotic band constriction occurs when fibrous bands in the amniotic sac constrict otherwise normally growing structures (eg, limbs), causing constriction rings or amputation. Internal structures such as the developing intestine are not affected.

(Choice B) Hirschsprung disease results from failure of neural crest cell migration to the distal colon. The absence of submucosal and myenteric plexi leads to an aganglionic colon segment and symptoms of functional obstruction (eg, bilious emesis, abdominal distension) with delayed passage of meconium. However, unlike this case, the small intestine is unaffected.

(Choice C) Failure of the tracheoesophageal septum to partition the foregut into the esophagus and the trachea in early gestation leads to tracheoesophageal fistula. Poor feeding, excessive secretions, and choking are typical;

21877.mp4
https://t.me/USMLEWorldStep1
Show all

The pathophysiology of intestinal atresia varies based on the segment of bowel involved. In duodenal atresia, the mechanism involves failure of the lumen to recanalize after epithelial proliferation in the first trimester **(Choice D)**. In contrast, intestinal atresia of the **midgut** (eg, jejunum, ileum, proximal colon) is the result of **vascular occlusion** in utero. Risk factors include underlying intestinal abnormality (eg, gastroschisis) or maternal use of vasoconstrictive drugs or substances (eg, nicotine).

Compromised perfusion leads to ischemia of a bowel segment, with subsequent narrowing (stenosis) or obliteration (atresia) of the lumen. This patient most likely developed occlusion of the **superior mesenteric artery**, resulting in ischemia, necrosis, and resorption of the distal small bowel associated with the dorsal mesentery. The jejunum proximal to the ischemic segment ends in a blind pouch, and the ileum distal to the segment spirals around the ileocolic vessel that perfuses it (apple peel atresia).

(Choice A) Amniotic band constriction occurs when fibrous bands in the amniotic sac constrict otherwise normally growing structures (eg, limbs), causing constriction rings or amputation. Internal structures such as the developing intestine are not affected.

(Choice B) Hirschsprung disease results from failure of neural crest cell migration to the distal colon. The absence of submucosal and myenteric plexi leads to an aganglionic colon segment and symptoms of functional obstruction (eg, bilious emesis, abdominal distension) with delayed passage of meconium. However, unlike this case, the small intestine is unaffected.

(Choice C) Failure of the tracheoesophageal septum to partition the foregut into the esophagus and the trachea in early gestation leads to tracheoesophageal fistula. Poor feeding, excessive secretions, and choking are typical; the remainder of the gastrointestinal tract is typically normal.

Educational objective:
Intestinal atresia involving bowel distal to the duodenum occurs due to vascular occlusion in utero. Superior mesenteric artery occlusion results in ischemia of the jejunum and ileum, resulting in a blind-ending proximal jejunum and a distal ileum that spirals around the ileocolic vessel that perfuses it (apple peel atresia).

21877.mp4
https://t.me/USMLEWorldStep1
Show all

Associations	• Chromosomal abnormality (eg, trisomy 21)	• Other intestinal pathology (eg, gastroschisis, volvulus)

Exhibit Display

This in
the co
atresia
annula
intesti

The pa
mecha
In cont
in uter
vasocc

Compr
obliter
resulti
jejunu
around

(Choic
growin
intesti

(Choic
absen
obstru
case,

Duodenal atresia

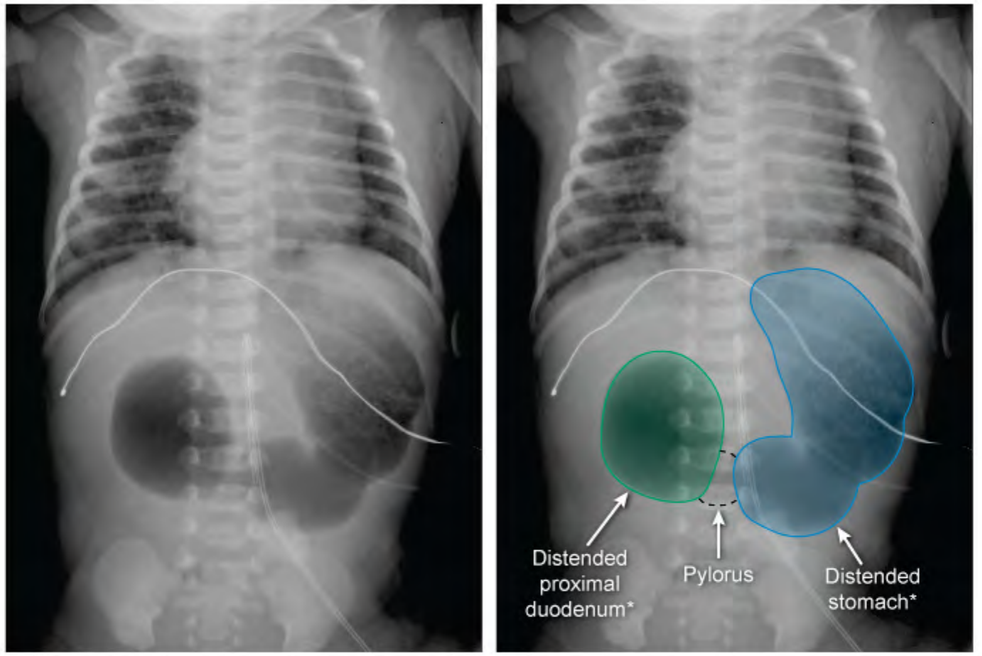

*Double bubble sign; failure to recanalize the duodenum in early gestation.

©UWorld

Zoom In | Zoom Out | Reset | New | Existing | My Notebook

(Choice C) Failure of the tracheoesophageal septum to partition the foregut into the esophagus and the trachea in

21877.mp4
https://t.me/USMLEWorldStep1
Show all

Associations	• Chromosomal abnormality (eg, trisomy 21)	• Other intestinal pathology (eg, gastroschisis, volvulus)

Exhibit Display

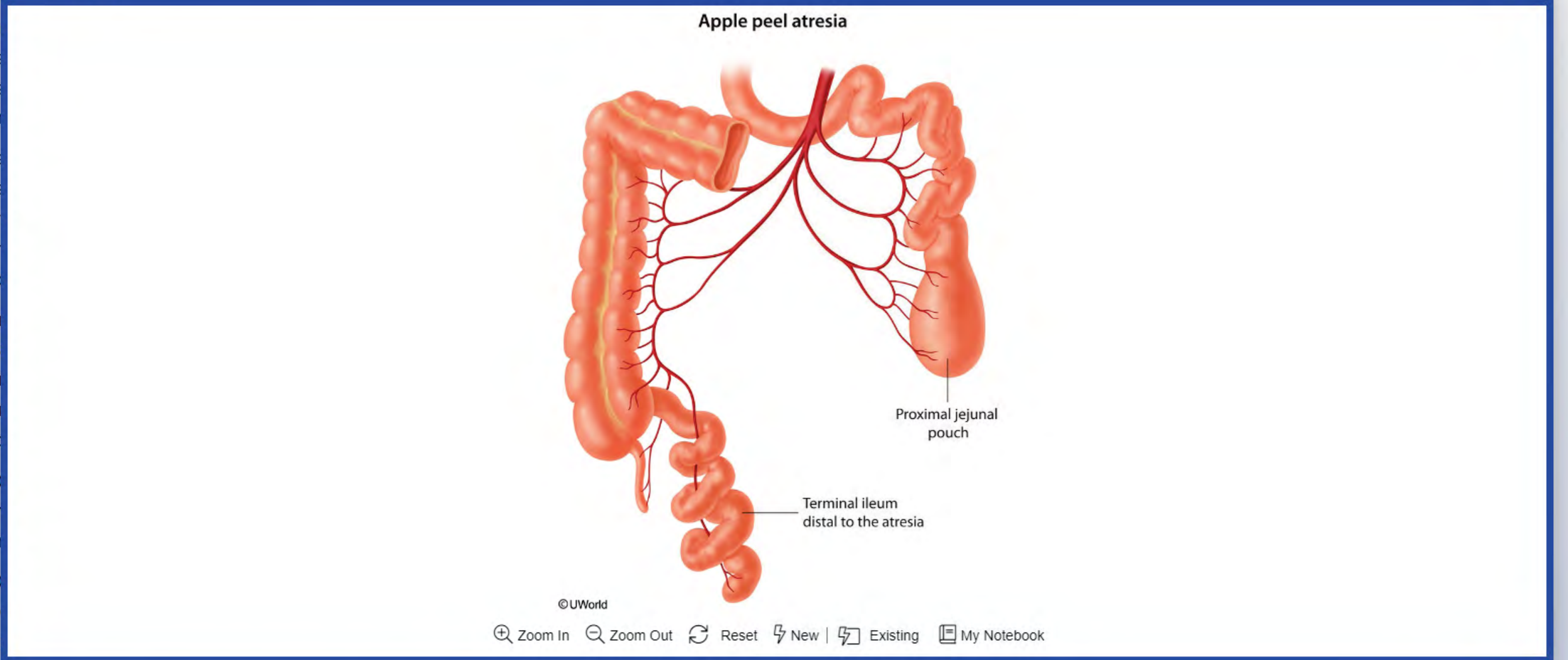

This in
the co
atresia
annula
intesti

The pa
mecha
In con
in uter
vasoc

Compr
obliter
resulti
jejunu
around

(Choic
growin
intesti

(Choic
absen
obstru
case,

(Choice C) Failure of the tracheoesophageal septum to partition the foregut into the esophagus and the trachea in

21877.mp4
https://t.me/USMLEWorldStep1
Show all

Associations	• Chromosomal abnormality (eg, trisomy 21)	• Other intestinal pathology (eg, gastroschisis, volvulus)

Exhibit Display

Amniotic band syndrome

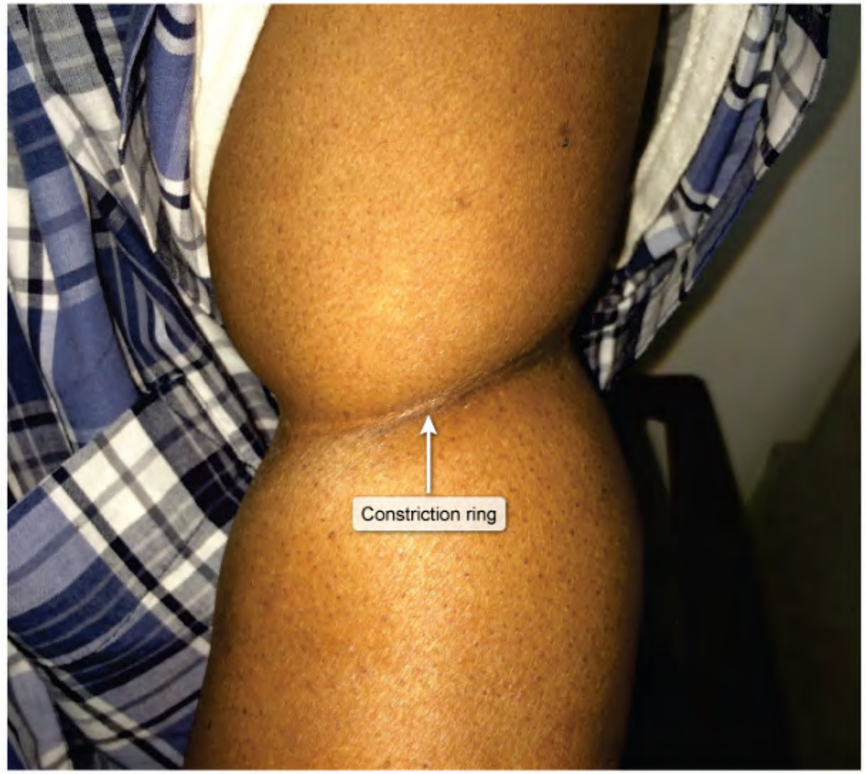

©UWorld

Zoom In | Zoom Out | Reset | New | Existing | My Notebook

This in
the co
atresia
annula
intesti

The pa
mecha
In cont
in uter
vasocc

Compr
obliter
resulti
jejunu
around

(Choic
growin
intesti

(Choic
absen
obstru
case,

(Choice C) Failure of the tracheoesophageal septum to partition the foregut into the esophagus and the trachea in

21877.mp4
https://t.me/USMLEWorldStep1
Show all

Associations	• Chromosomal abnormality (eg, trisomy 21)	• Other intestinal pathology (eg, gastroschisis, volvulus)

Exhibit Display

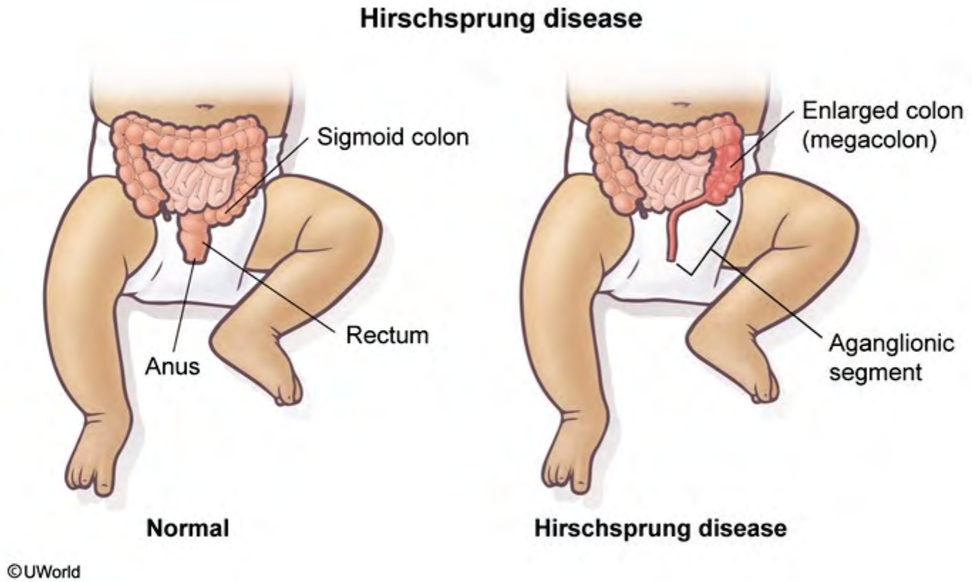

Zoom In | Zoom Out | Reset | New | Existing | My Notebook

This in
the co
atresia
annula
intesti

The pa
mecha
In cont
in uter
vasocc

Compr
obliter
resulti
jejunu
around

(Choic
growin
intesti

(Choic
absen
obstru
case,

(Choice C) Failure of the tracheoesophageal septum to partition the foregut into the esophagus and the trachea in

21877.mp4
https://t.me/USMLEWorldStep1
Show all

in utero. Risk factors include underlying intestinal abnormality (eg, gastroschisis) or maternal use of

vasoc

Compr
obliter
resulti
jejunu
aroun

(Choi
growir
intesti

(Choi
absen
obstru
case,

(Choi
early g
the rer

Educa
Intesti
meser
jejunu

Embryo
Subject

Exhibit Display

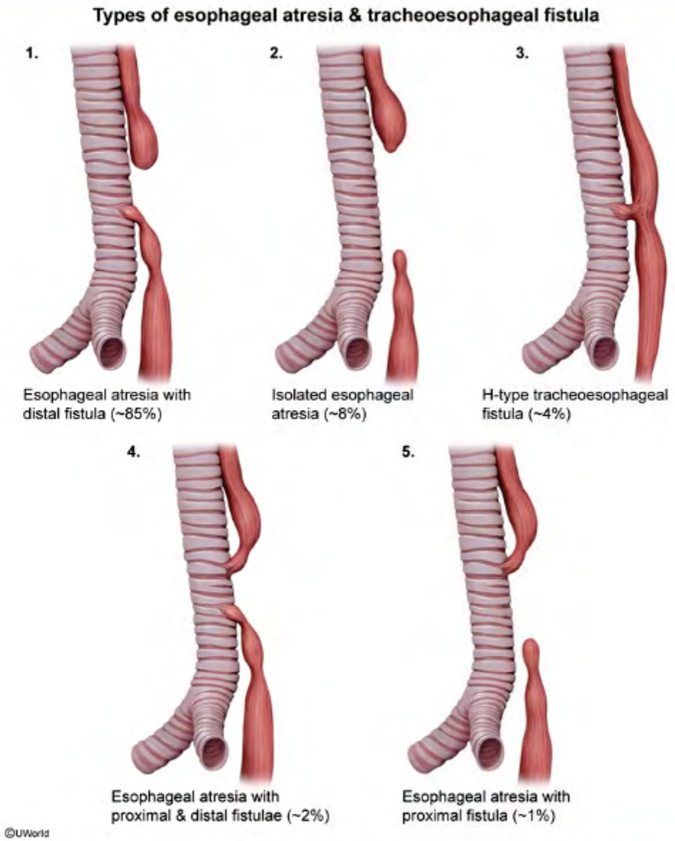

Zoom In | Zoom Out | Reset | New | Existing | My Notebook

Copyright © UWorld. All rights reserved.

21877.mp4
https://t.me/USMLEWorldStep1
Show all

A 52-year-old man comes to the office due to diarrhea. For the past 3 months, he has had loose, brown, watery stools 4 or 5 times a day; it is associated with postprandial bloating. The patient has no vomiting, melena, hematochezia, or unexpected weight changes. He was diagnosed 10 years ago with systemic sclerosis, which presented with sclerodactyly and Raynaud phenomenon. The patient does not use tobacco, alcohol, or illicit drugs. The abdomen is visibly distended but nontender and without rebound or guarding. His symptoms dramatically improve after treatment with oral antibiotics. Which of the following is most likely responsible for this patient's diarrhea?

- A. Defective structure of apoproteins
- B. Impaired pancreatic enzyme release
- C. Maldigestion in the intestinal lumen
- D. Pancreatic enzyme inactivation

Submit

21877.mp4
https://t.me/USMLEWorldStep1
Show all

A 52-year-old man comes to the office due to diarrhea. For the past 3 months, he has had loose, brown, watery stools 4 or 5 times a day; it is associated with postprandial bloating. The patient has no vomiting, melena, hematochezia, or unexpected weight changes. He was diagnosed 10 years ago with systemic sclerosis, which presented with sclerodactyly and Raynaud phenomenon. The patient does not use tobacco, alcohol, or illicit drugs. The abdomen is visibly distended but nontender and without rebound or guarding. His symptoms dramatically improve after treatment with oral antibiotics. Which of the following is most likely responsible for this patient's diarrhea?

- A. Defective structure of apoproteins (4%)
- ✗ B. Impaired pancreatic enzyme release (16%)
- ✓ C. Maldigestion in the intestinal lumen (69%)
- D. Pancreatic enzyme inactivation (8%)

Incorrect
Correct answer
C

69%
Answered correctly

04 secs
Time Spent

2023
Version

Explanation

Small intestinal bacterial overgrowth	
Risk factors	• Anatomic abnormalities (eg, strictures, surgery) • Motility disorders (eg, diabetes mellitus, scleroderma, opioid use) • Immunodeficiency (IgA deficiency) • Gastric hypochlorhydria (proton pump inhibitor use)
	• Proliferation of colonic bacteria in the small intestine

21877.mp4
https://t.me/USMLEWorldStep1
Show all

Small intestinal bacterial overgrowth	
Risk factors	• Anatomic abnormalities (eg, strictures, surgery) • Motility disorders (eg, diabetes mellitus, scleroderma, opioid use) • Immunodeficiency (IgA deficiency) • Gastric hypochlorhydria (proton pump inhibitor use)
Pathogenesis	• Proliferation of colonic bacteria in the small intestine • Maldigestion and possible malabsorption of nutrients • Fermentation of carbohydrates
Clinical manifestations	• Bloating, flatulence • Chronic watery diarrhea • Severe: steatorrhea, vitamin deficiencies
Treatment	• Dietary changes (eg, high fat, low carbohydrate) • Oral antibiotics (eg, rifaximin, ciprofloxacin)

This patient has **small intestinal bacterial overgrowth** (SIBO) presenting with bloating and diarrhea. SIBO is caused by bacterial proliferation (eg, *Escherichia coli*, *Bacteroides*, *Aeromonas*) in the small bowel. It is a common complication of **scleroderma**, which can alter intestinal motility due to smooth muscle atrophy and fibrosis. As in this patient, symptoms often improve with **antibiotics**.

SIBO is characterized by mucosal enterocyte injury due to bacterial adherence, invasion, and toxin injury. The activity of brush border enzymes is often impaired. These changes lead to **maldigestion** and often malabsorption in more severe cases. Specific macronutrient effects include the following:

- Carbohydrates: decreased digestion and absorption of carbohydrates facilitate **bacterial fermentation**, producing carbon dioxide, hydrogen, and methane gases (eg, bloating).
- Fatty acids: conjugated bile acids normally emulsify dietary fats in the proximal small bowel and are reabsorbed in the terminal ileum. However, SIBO causes deconjugation of bile acids, leading to early bile acid

21877.mp4
https://t.me/USMLEWorldStep1
Show all

Clinical manifestations	• Bloating, flatulence • Chronic watery diarrhea • Severe: steatorrhea, vitamin deficiencies
Treatment	• Dietary changes (eg, high fat, low carbohydrate) • Oral antibiotics (eg, rifaximin, ciprofloxacin)

This patient has **small intestinal bacterial overgrowth** (SIBO) presenting with bloating and diarrhea. SIBO is caused by bacterial proliferation (eg, *Escherichia coli*, *Bacteroides*, *Aeromonas*) in the small bowel. It is a common complication of **scleroderma**, which can alter intestinal motility due to smooth muscle atrophy and fibrosis. As in this patient, symptoms often improve with **antibiotics**.

SIBO is characterized by mucosal enterocyte injury due to bacterial adherence, invasion, and toxin injury. The activity of brush border enzymes is often impaired. These changes lead to **maldigestion** and often malabsorption in more severe cases. Specific macronutrient effects include the following:

- Carbohydrates: decreased digestion and absorption of carbohydrates facilitate **bacterial fermentation**, producing carbon dioxide, hydrogen, and methane gases (eg, bloating).
- Fatty acids: conjugated bile acids normally emulsify dietary fats in the proximal small bowel and are reabsorbed in the terminal ileum. However, SIBO causes deconjugation of bile acids, leading to early bile acid resorption in the jejunum, reduced lipid emulsification, and **fat malabsorption**.
- Amino acids: SIBO causes maldigestion of proteins and malabsorption of amino acids, occasionally leading to protein-losing enteropathy in severe cases.

(Choice A) Defective apoprotein structure occurs in abetalipoproteinemia, an autosomal recessive disorder that presents in infancy with fat malabsorption and growth abnormalities; symptoms would not improve with antibiotics.

(Choice B) Impaired release of pancreatic lipase occurs with chronic pancreatitis. Patients typically have severe postprandial abdominal pain and steatorrhea (bulky, fat-laden stools); therapy involves pancreatic enzyme replacement, not antibiotics.

21877.mp4
https://t.me/USMLEWorldStep1
Show all

SIBO is characterized by mucosal enterocyte injury due to bacterial adherence, invasion, and toxin injury. The activity of brush border enzymes is often impaired. These changes lead to **maldigestion** and often malabsorption in more severe cases. Specific macronutrient effects include the following:

- Carbohydrates: decreased digestion and absorption of carbohydrates facilitate **bacterial fermentation**, producing carbon dioxide, hydrogen, and methane gases (eg, bloating).
- Fatty acids: conjugated bile acids normally emulsify dietary fats in the proximal small bowel and are reabsorbed in the terminal ileum. However, SIBO causes deconjugation of bile acids, leading to early bile acid resorption in the jejunum, reduced lipid emulsification, and **fat malabsorption**.
- Amino acids: SIBO causes maldigestion of proteins and malabsorption of amino acids, occasionally leading to protein-losing enteropathy in severe cases.

(Choice A) Defective apoprotein structure occurs in abetalipoproteinemia, an autosomal recessive disorder that presents in infancy with fat malabsorption and growth abnormalities; symptoms would not improve with antibiotics.

(Choice B) Impaired release of pancreatic lipase occurs with chronic pancreatitis. Patients typically have severe postprandial abdominal pain and steatorrhea (bulky, fat-laden stools); therapy involves pancreatic enzyme replacement, not antibiotics.

(Choice D) Gastrin-secreting tumors (ie, Zollinger-Ellison syndrome) cause gastric acid hypersecretion, which lowers duodenal pH and inactivates pancreatic lipase. Although it can cause diarrhea and fat malabsorption, hypersecretion typically presents with abdominal pain and multiple gastrointestinal ulcers; antibiotics are ineffective.

Educational objective:
Small intestinal bacterial overgrowth is characterized by bacterial proliferation in the small bowel, leading to mucosal inflammation with subsequent fermentation of carbohydrates and fat malabsorption; it manifests with diarrhea, abdominal distension, and flatulence. Patients with impaired intestinal peristalsis (eg, systemic sclerosis) are at increased risk. Treatment includes oral antibiotics.

21877.mp4
https://t.me/USMLEWorldStep1
Show all

A 65-year-old man comes to the office with dysphagia. For the last 3 months, he has relied on protein shakes and juices for nourishment as he has had difficulty swallowing solid foods. He has also had a diminished appetite and an estimated weight loss of 9.1 kg (20 lb). Medical history includes hyperlipidemia, emphysema, and previous episodes of pancreatitis. Family history includes lung cancer in his mother. The patient smoked a pack of cigarettes daily for 50 years but quit 2 years ago. He has been drinking a fifth (750 mL) of vodka weekly for the last decade. Vital signs are normal. BMI is 19.2 kg/m^2. Temporal wasting is present but physical examination is otherwise unremarkable. Upper endoscopy reveals a 4-cm mass in the middle third of the esophagus, and several biopsies are taken. Thoracic imaging reveals mediastinal lymphadenopathy. Histologic evaluation of the biopsy specimens will most likely show which of the following in this patient?

- A. Intestinal cells without dysplasia
- B. Irregular glandular cells with tissue invasion
- C. Keratin pearls and intercellular bridges
- D. Myocytes with prominent atypia
- E. Spindle cells expressing CD117

Submit

21877.mp4
https://t.me/USMLEWorldStep1
Show all

A 65-year-old man comes to the office with dysphagia. For the last 3 months, he has relied on protein shakes and juices for nourishment as he has had difficulty swallowing solid foods. He has also had a diminished appetite and an estimated weight loss of 9.1 kg (20 lb). Medical history includes hyperlipidemia, emphysema, and previous episodes of pancreatitis. Family history includes lung cancer in his mother. The patient smoked a pack of cigarettes daily for 50 years but quit 2 years ago. He has been drinking a fifth (750 mL) of vodka weekly for the last decade. Vital signs are normal. BMI is 19.2 kg/m^2. Temporal wasting is present but physical examination is otherwise unremarkable. Upper endoscopy reveals a 4-cm mass in the middle third of the esophagus, and several biopsies are taken. Thoracic imaging reveals mediastinal lymphadenopathy. Histologic evaluation of the biopsy specimens will most likely show which of the following in this patient?

- A. Intestinal cells without dysplasia (0%)
- ✗ B. Irregular glandular cells with tissue invasion (13%)
- ✓ C. Keratin pearls and intercellular bridges (83%)
- D. Myocytes with prominent atypia (1%)
- E. Spindle cells expressing CD117 (1%)

Incorrect
Correct answer
C

83%
Answered correctly

05 secs
Time Spent

2023
Version

Explanation

Squamous cell carcinoma of the esophagus	
Risk factors	• Alcohol, smoking, foods containing N-nitroso • Age >50

21877.mp4
https://t.me/USMLEWorldStep1
Show all

Squamous cell carcinoma of the esophagus	
Risk factors	• Alcohol, smoking, foods containing N-nitroso • Age >50
Location	• Proximal two-thirds of esophagus (most common in the middle third) • Associated mediastinal lymphadenopathy
Histopathology	• Sheets of eosinophilic squamous cells • Keratin pearls, intercellular bridges

This patient with a mid-esophageal mass and mediastinal lymphadenopathy likely has **squamous cell carcinoma** (SCC) of the esophagus. SCC is characterized by sheets or nests of atypical squamous cells with abundant eosinophilic cytoplasm and may show large, bizarre nuclei with atypical mitoses; **keratin formation** (keratin pearls) and intercellular bridges are common. Malignant cells are often seen invading the submucosa and surrounding structures.

The esophagus can be subdivided (based on anatomy and embryonic formation) into thirds; malignancies occur at different frequencies within each segment.

- Proximal and middle third: SCC is more common, and occurs at the highest frequency in the **middle third**. Lymphatics drain to mediastinal nodes; metastatic disease may present with **mediastinal lymphadenopathy**.
- Distal third: Adenocarcinoma is more common. Lymphatics drain caudally to the gastric and celiac nodes; metastatic disease may present with abdominal lymphadenopathy.

Adenocarcinoma is characterized by invasive patches of dysplastic, mucin-producing cells that form glands. It typically occurs as a consequence of chronic gastroesophageal reflux disease and is preceded by Barrett esophagus (replacement of the normal esophagus with nondysplastic columnar intestinal cells) **(Choices A and B)**.

(Choices D and E) Leiomyosarcoma demonstrates myocyte atypia on histology. Gastrointestinal stromal tumors

21877.mp4
https://t.me/USMLEWorldStep1
Show all

(SCC) of the esophagus. SCC is characterized by sheets or nests of atypical squamous cells with abundant eosinophilic cytoplasm and may show large, bizarre nuclei with atypical mitoses; **keratin formation** (keratin pearls) and intercellular bridges are common. Malignant cells are often seen invading the submucosa and surrounding structures.

The esophagus can be subdivided (based on anatomy and embryonic formation) into thirds; malignancies occur at different frequencies within each segment.

- Proximal and middle third: SCC is more common, and occurs at the highest frequency in the **middle third**. Lymphatics drain to mediastinal nodes; metastatic disease may present with **mediastinal lymphadenopathy**.
- Distal third: Adenocarcinoma is more common. Lymphatics drain caudally to the gastric and celiac nodes; metastatic disease may present with abdominal lymphadenopathy.

Adenocarcinoma is characterized by invasive patches of dysplastic, mucin-producing cells that form glands. It typically occurs as a consequence of chronic gastroesophageal reflux disease and is preceded by Barrett esophagus (replacement of the normal esophagus with nondysplastic columnar intestinal cells) **(Choices A and B)**.

(Choices D and E) Leiomyosarcoma demonstrates myocyte atypia on histology. Gastrointestinal stromal tumors are often composed of uniform spindle cells that overexpress CD117. These malignancies occur more commonly in the stomach and small intestine and are rare in the esophagus.

Educational objective:
Esophageal squamous cell carcinoma presents mostly in the proximal two-thirds of the esophagus and frequently metastasizes to the mediastinal lymph nodes. Histology characteristically shows sheets of atypical squamous cells with keratin pearls and intercellular bridges.

Pathology	Gastrointestinal & Nutrition	Esophageal cancer
Subject	System	Topic

Copyright © UWorld. All rights reserved.

21877.mp4
https://t.me/USMLEWorldStep1
Show all

Exhibit Display

Squamous cell carcinoma

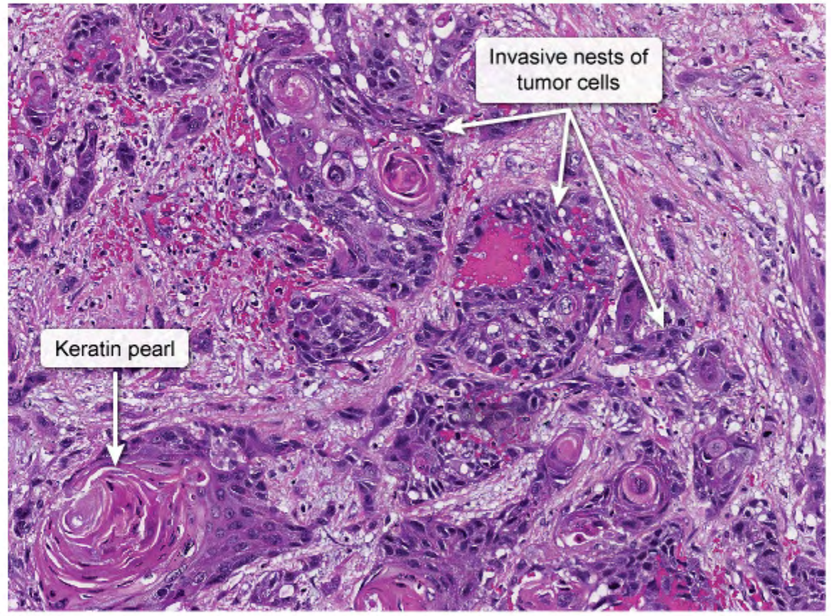

©UWorld

Zoom In | Zoom Out | Reset | New | Existing | My Notebook

This p
(SCC)
eosinc
and in
structu

The es
differe

- P
  L
- D
  m

Adenc
typical
esoph
B).

(Choi
are oft
in the

Educational objective:

21877.mp4
https://t.me/USMLEWorldStep1
Show all

Exhibit Display

Squamous cell carcinoma

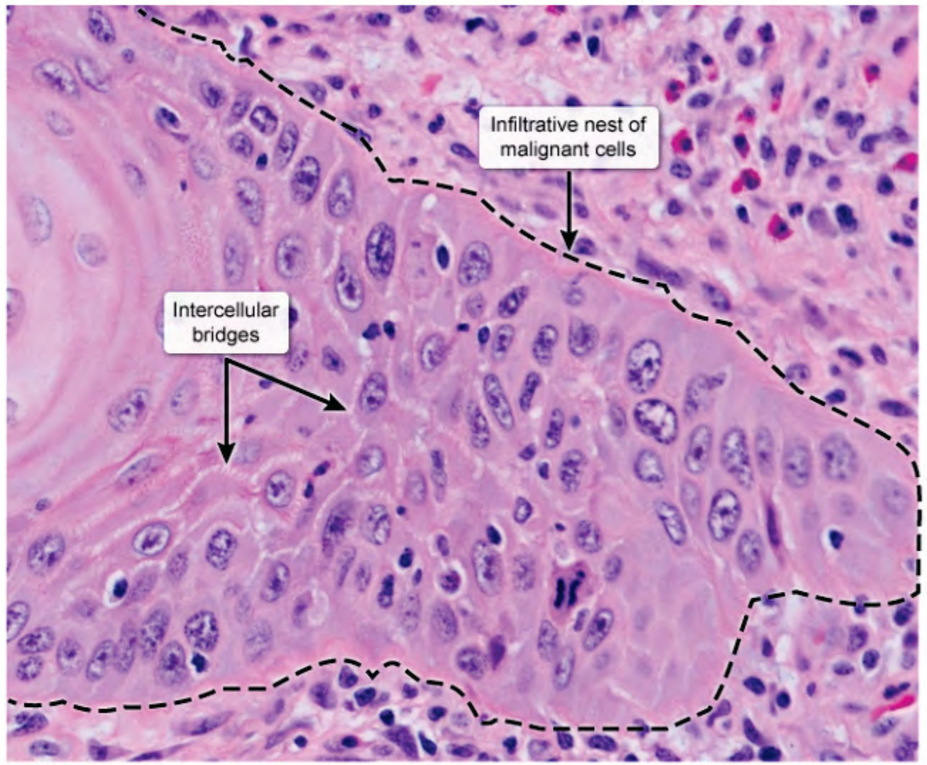

Zoom In | Zoom Out | Reset | New | Existing | My Notebook

This p
(SCC)
eosinc
and in
structu

The es
differe

- P
  L
- D
  m

Adenc
typical
esoph
B).

(Choi
are oft
in the

Educational objective:

21877.mp4
https://t.me/USMLEWorldStep1
Show all

	• Proximal two-thirds of esophagus (most common in the middle third)

Exhibit Display

Esophageal adenocarcinoma

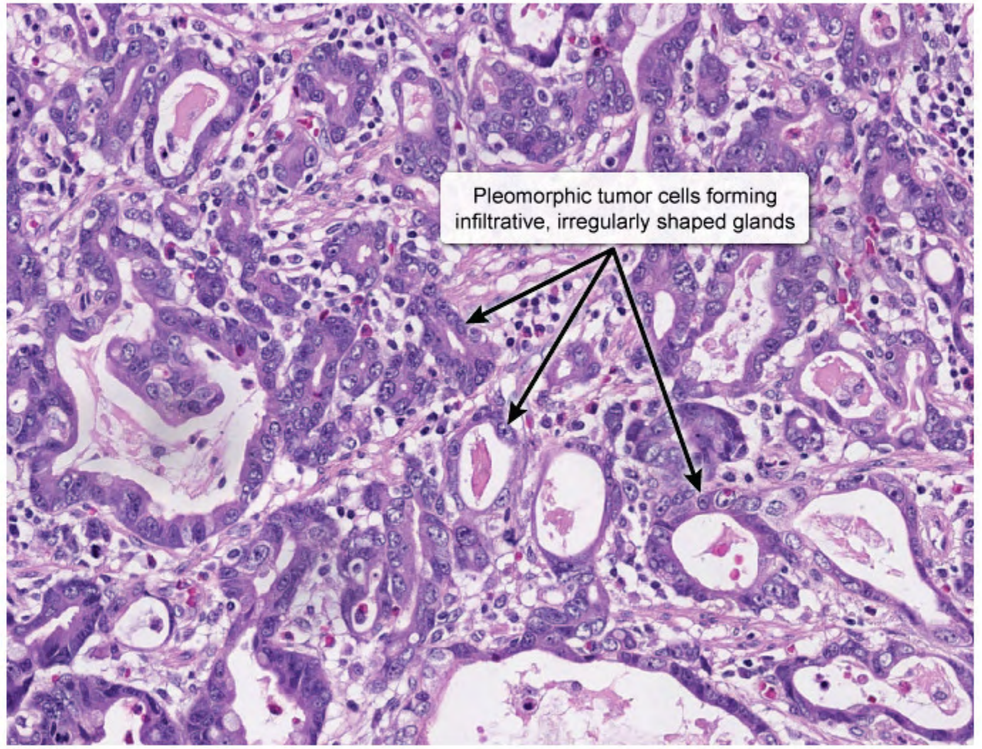

©UWorld

Zoom In | Zoom Out | Reset | New | Existing | My Notebook

This p
(SCC)
eosinc
and in
structu

The es
differe

- P
  L
- D
  m

Adenoc
typical
esoph
B).

(Choi
are oft
in the

Educational objective:

21877.mp4
https://t.me/USMLEWorldStep1
Show all

Histopathology	• Sheets of eosinophilic squamous cells • Keratin pearls, intercellular bridges

Exhibit Display

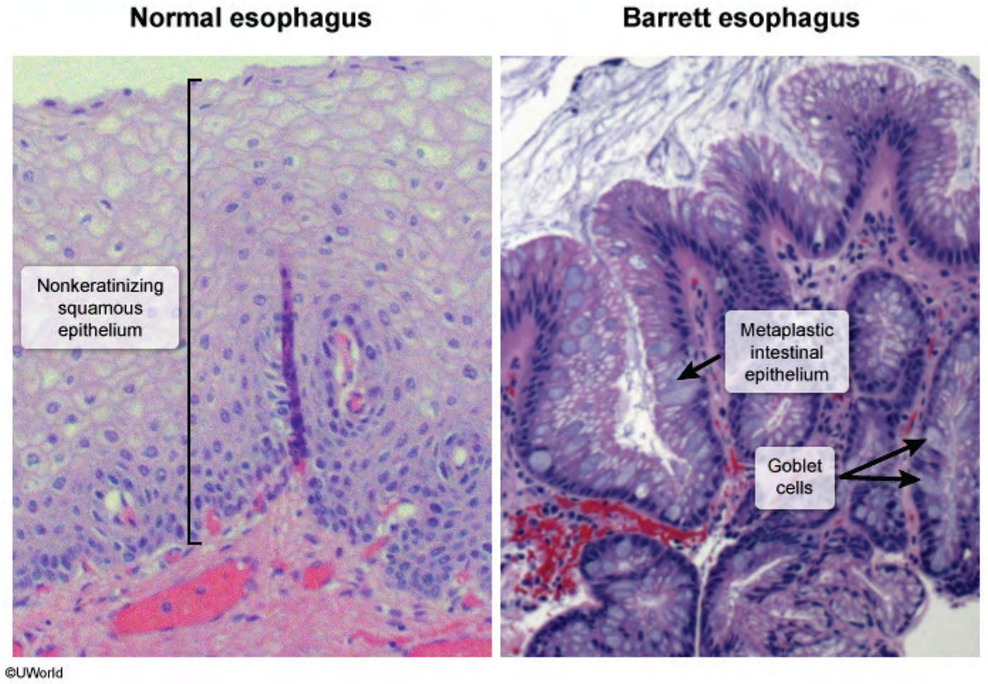

Zoom In | Zoom Out | Reset | New | Existing | My Notebook

This p
(SCC)
eosinc
and in
structu

The es
differe

- P
  L
- D
  m

Adenc
typical
esoph
B).

(Choi
are oft
in the

Educa
Esoph
metas
with keratin pearls and intercellular bridges.

21877.mp4
https://t.me/USMLEWorldStep1
Show all

(SCC) of the esophagus. SCC is characterized by sheets or nests of atypical squamous cells with abundant
eosinc
and in
structu

The es
differe

- P
  L
- D
  m

Adenc
typical
esoph
B).

(Choi
are oft
in the

Educa
Esoph
metas
with k

Pathol
Subject

Exhibit Display

Leiomyosarcoma

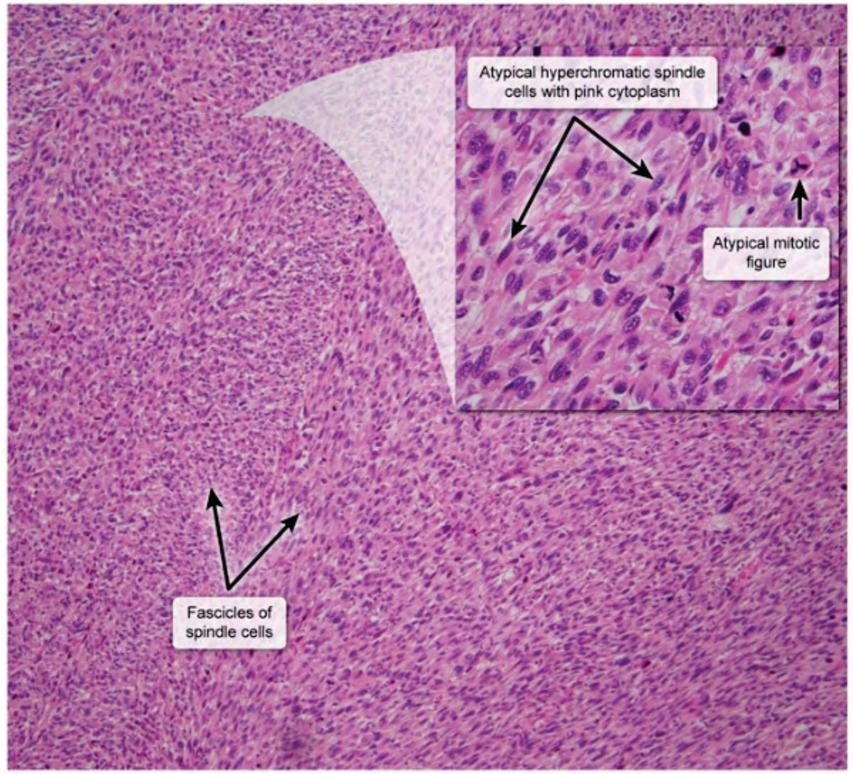

©UWorld

Zoom In | Zoom Out | Reset | New | Existing | My Notebook

Copyright © UWorld. All rights reserved.

21877.mp4
https://t.me/USMLEWorldStep1
Show all

(SCC) of the esophagus. SCC is characterized by sheets or nests of atypical squamous cells with abundant
eosinc
and in
structu

The es
differe

- P
  L
- D
  m

Adenc
typical
esoph
B).

(Choi
are oft
in the

Educa
Esoph
metas
with k

Pathol
Subject

Exhibit Display

Gastrointestinal stromal tumor

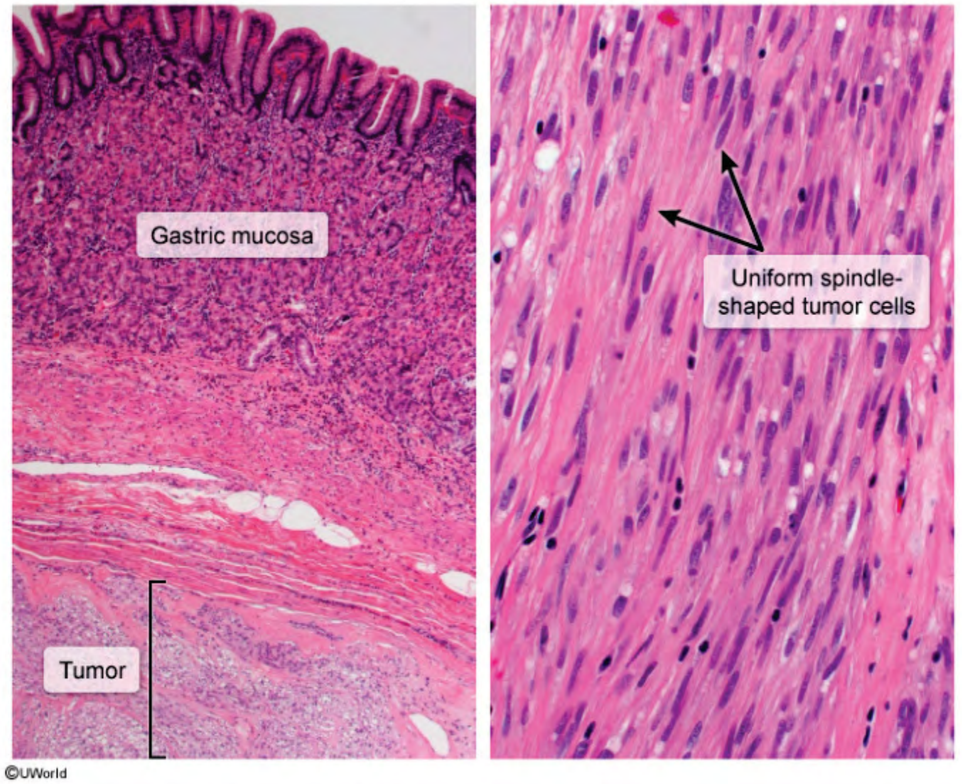

Zoom In | Zoom Out | Reset | New | Existing | My Notebook

Copyright © UWorld. All rights reserved.

21877.mp4
https://t.me/USMLEWorldStep1
Show all

A 59-year-old man is evaluated in the clinic for recent unintentional weight loss. He says, "My pants are fitting a lot looser than usual." The patient also has epigastric discomfort after meals with occasional nausea. He reports that food is not as appetizing as it used to be. He has no known medical conditions and takes no medications. The patient's father has a history of peptic ulcer disease. Upper endoscopy shows a lesion in the stomach that is biopsied; a histologic section is shown below:

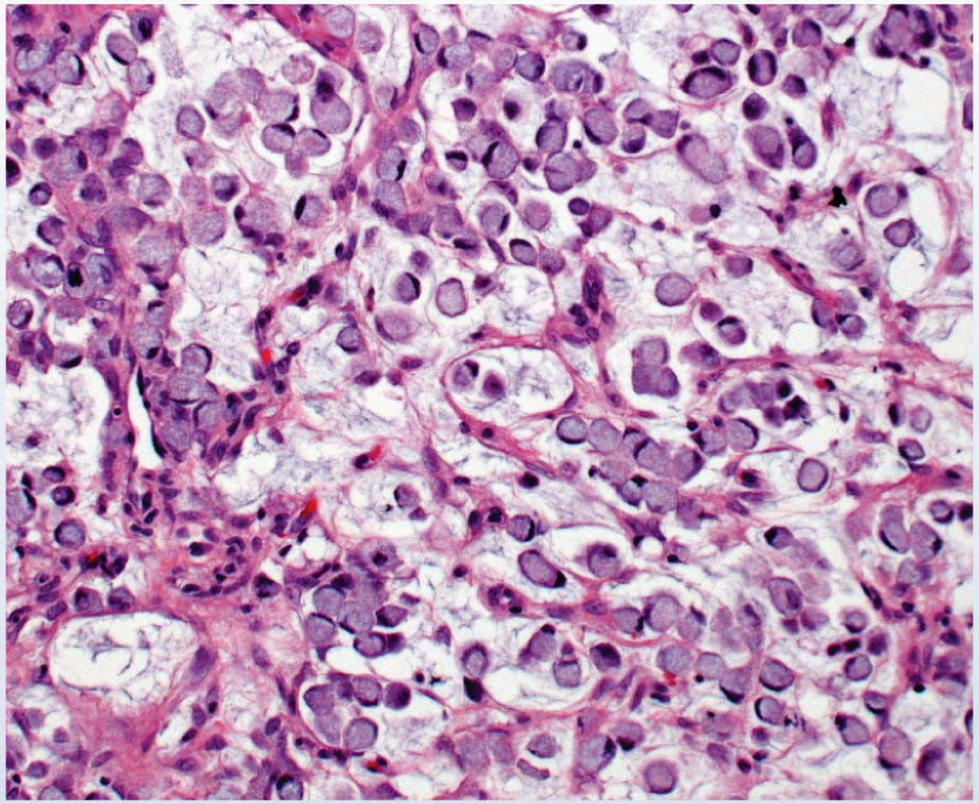

This patient's lesion is most likely to demonstrate which of the following gross findings?

- A. Deep ulceration and vessel erosion
- B. Infiltrative growth within the stomach wall

https://t.me/USMLEWorldStep1

A 59-year-old man is evaluated in the clinic for recent unintentional weight loss. He says, "My pants are fitting a lot looser
food is
patien
biopsi

Exhibit Display

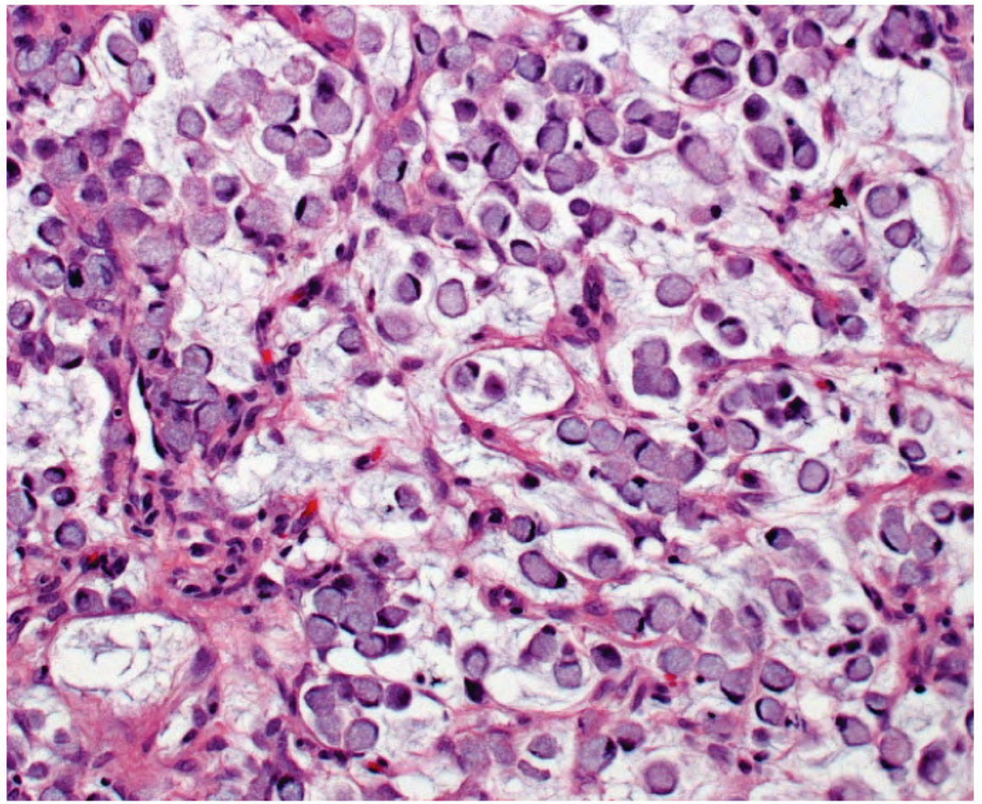

Zoom In | Zoom Out | Reset | New | Existing | My Notebook

This p

A. Deep ulceration and vessel erosion

B. Infiltrative growth within the stomach wall

https://t.me/USMLEWorldStep1

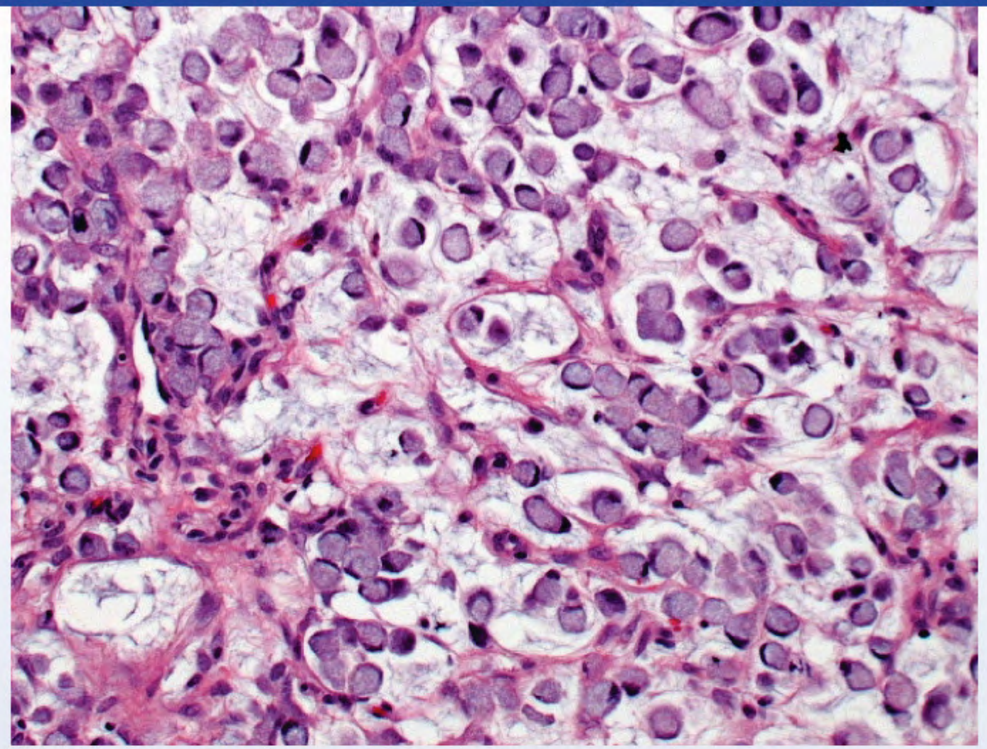

This patient's lesion is most likely to demonstrate which of the following gross findings?

- A. Deep ulceration and vessel erosion
- B. Infiltrative growth within the stomach wall
- C. Progressive mucosal atrophy
- D. Rapid intraluminal expansion
- E. Rugal thickening with acid hypersecretion

Submit

https://t.me/USMLEWorldStep1

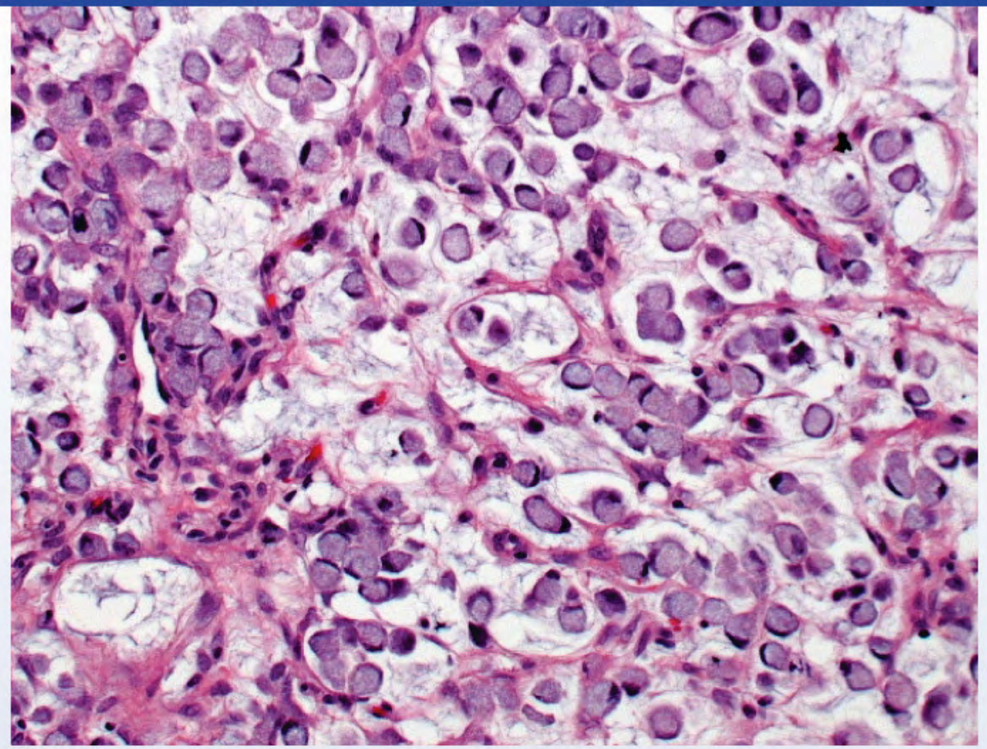

This patient's lesion is most likely to demonstrate which of the following gross findings?

- A. Deep ulceration and vessel erosion (9%)
- ✓ B. Infiltrative growth within the stomach wall (53%)
- C. Progressive mucosal atrophy (9%)
- D. Rapid intraluminal expansion (4%)
- ✗ E. Rugal thickening with acid hypersecretion (22%)

Incorrect
Correct answer
B

53%
Answered correctly

48 secs
Time Spent

2023
Version

https://t.me/USMLEWorldStep1

D. Rapid intraluminal expansion (4%)

Exhibit Display

Diffuse-type gastric adenocarcinoma

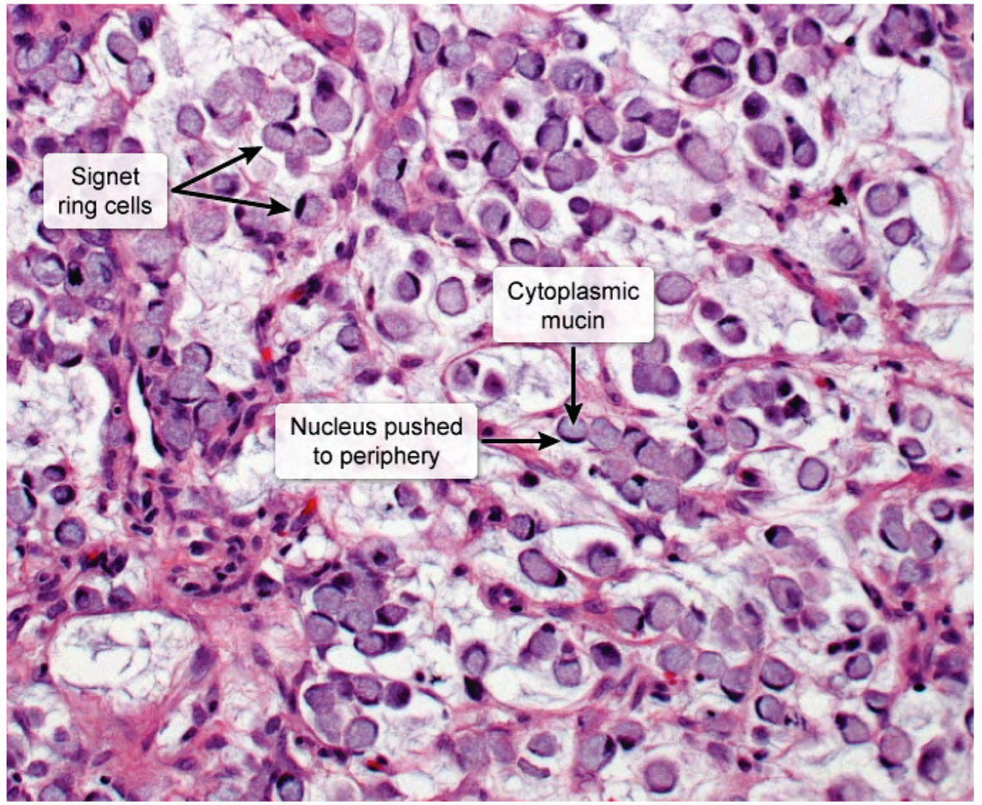

©UWorld

Zoom In | Zoom Out | Reset | New | Existing | My Notebook

https://t.me/USMLEWorldStep1

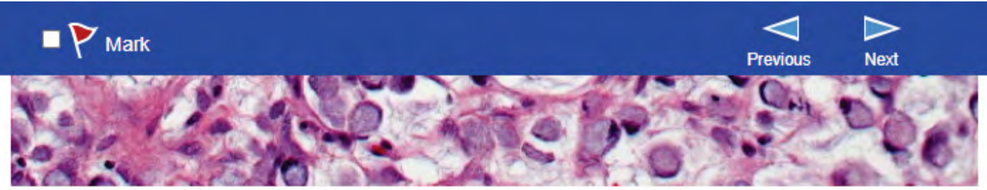

©UWorld

This image shows typical features of **diffuse-type** adenocarcinoma, 1 of 2 major types of **gastric adenocarcinoma**. Diffuse-type adenocarcinomas often consist of **signet ring cells** that do not form glands. Signet ring cells contain abundant mucin droplets that push the nucleus to one side and lead to the characteristic appearance of a signet ring. On gross examination, diffuse-type adenocarcinomas are characterized by diffuse involvement of the stomach wall (due to loss of the cell adhesion protein E-cadherin). They have a plaque-like appearance, are ill defined, and often **infiltrate** large areas of the **stomach wall**, causing a "leather-bottle" stomach (**linitis plastica**).

In contrast, intestinal-type adenocarcinomas of the stomach resemble colon cancers, showing well-formed glands that consist of columnar or cuboidal cells. They tend to grow as nodular, polypoid, and well-demarcated masses that rapidly expand within the gastric lumen **(Choice D)**. These lesions often ulcerate/bleed and must be differentiated from peptic gastric ulcers by biopsy **(Choice A)**.

(Choice C) Chronic gastritis is most commonly associated with *Helicobacter pylori* infection. Long-standing inflammation of the gastric mucosa can lead to diffuse gland atrophy and intestinal metaplasia. Chronic gastric inflammation increases the risk of gastric carcinomas.

(Choice E) Rugal thickening with acid hypersecretion is a characteristic finding in the stomach of a patient with Zollinger-Ellison syndrome.

Educational objective:
There are 2 morphological variants of gastric adenocarcinoma. The intestinal type forms a solid mass that projects into the stomach lumen and is composed of gland-forming cuboidal or columnar cells. In contrast, diffuse-type adenocarcinoma infiltrates the stomach wall (linitis plastica) and displays signet ring cells on light microscopy.

References

- Gastric cancer: classification, histology and application of molecular pathology.

https://t.me/USMLEWorldStep1

Exhibit Display

Intestinal-type gastric adenocarcinoma

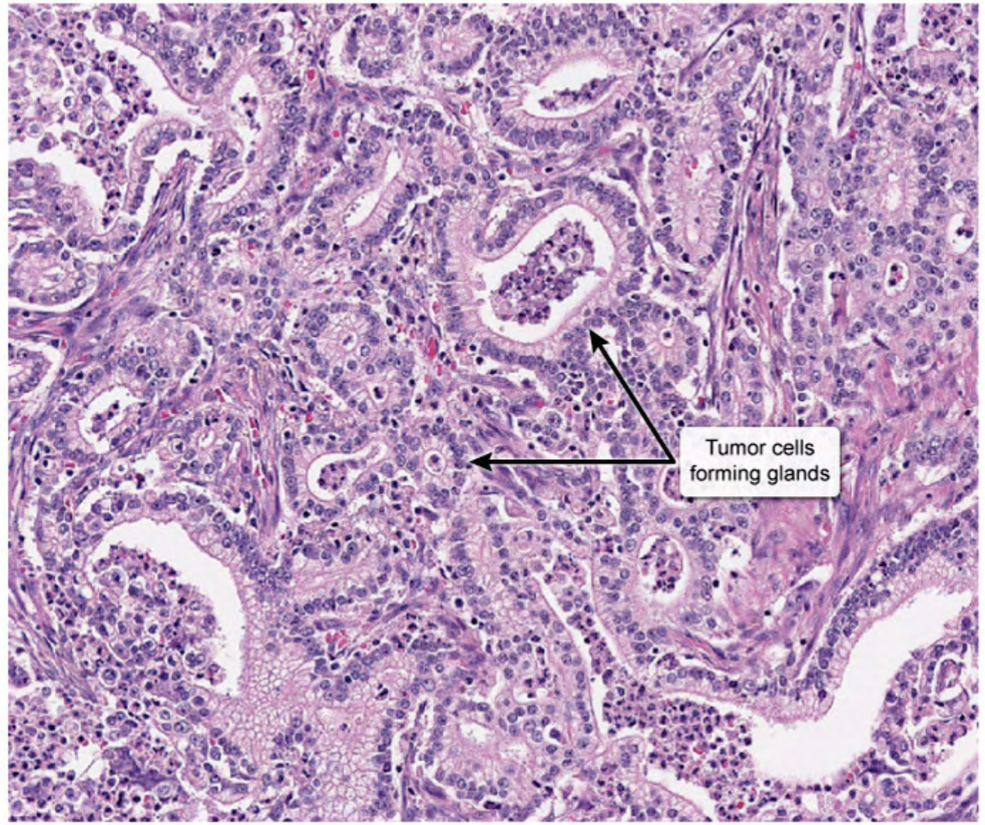

©UWorld

Zoom In | Zoom Out | Reset | New | Existing | My Notebook

This in
adeno
Signet
appea
involve
appea
stoma

In con
that co
that ra
differe

(Choi
inflam
inflam

(Choi
Zolling

Educa
There
into th
adeno

Refere
- Ga

https://t.me/USMLEWorldStep1

Exhibit Display

Chronic gastritis

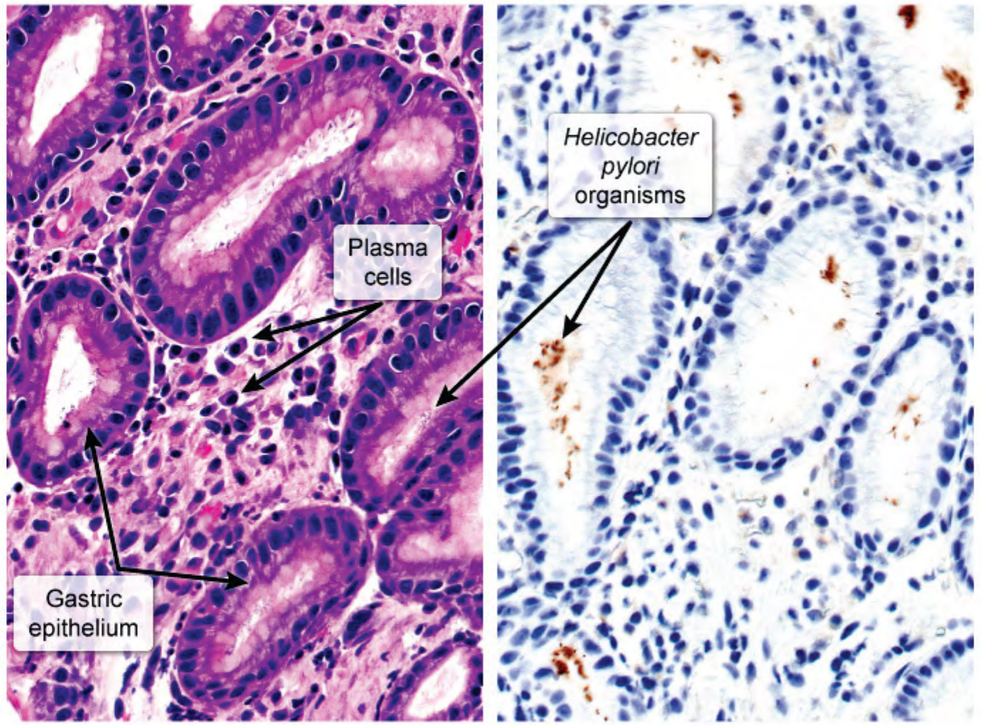

©UWorld

Zoom In | Zoom Out | Reset | New | Existing | My Notebook

This in
adeno
Signet
appea
involve
appea
stoma

In con
that co
that ra
differe

(Choi
inflam
inflam

(Choi
Zolling

Educa
There
into th
adeno

References

- Gastric cancer: classification, histology and application of molecular pathology.

https://t.me/USMLEWorldStep1

A 57-year-old man comes to the office due to anorexia, a 4.5 kg (9.9 lb) weight loss, and generalized weakness. Other medical conditions include psoriasis and cervical spondylosis. Two years ago, the patient emigrated from Taiwan, where he worked for many years on a maize (corn) farm. He does not use tobacco, alcohol, or recreational drugs. Vital signs are within normal limits. BMI is 23 kg/m^2. The patient appears cachectic. Examination shows a mass in the liver. There is no splenomegaly or ascites. Laboratory results are as follows:

Total bilirubin	1.8 mg/dL
Alanine aminotransferase (SGPT)	70 U/L
Aspartate aminotransferase (SGOT)	105 U/L
Alkaline phosphatase	280 U/L
Anti–hepatitis C virus antibodies	negative
Hepatitis B surface antigen	negative
Antibody to hepatitis B core antigen	negative
Antibody to hepatitis B surface antigen	positive

Abdominal ultrasound shows a 6-cm mass in the right lobe of the liver; the remainder of the liver appears normal. Biopsy of the mass shows plates of abnormal cells that are smaller than normal hepatocytes with a high nuclear/cytoplasmic ratio and nuclear pleomorphism. Which of the following is most likely responsible for this patient's current condition?

- A. Chronic hepatitis B infection
- B. Exposure to vinyl chloride
- C. Ingestion of aflatoxin
- D. Liver fluke infection
- E. Nonalcoholic fatty liver disease

https://t.me/USMLEWorldStep1

recreational drugs. Vital signs are within normal limits. BMI is 23 kg/m². The patient appears cachectic. Examination shows a mass in the liver. There is no splenomegaly or ascites. Laboratory results are as follows:

Total bilirubin	1.8 mg/dL
Alanine aminotransferase (SGPT)	70 U/L
Aspartate aminotransferase (SGOT)	105 U/L
Alkaline phosphatase	280 U/L
Anti–hepatitis C virus antibodies	negative
Hepatitis B surface antigen	negative
Antibody to hepatitis B core antigen	negative
Antibody to hepatitis B surface antigen	positive

Abdominal ultrasound shows a 6-cm mass in the right lobe of the liver; the remainder of the liver appears normal. Biopsy of the mass shows plates of abnormal cells that are smaller than normal hepatocytes with a high nuclear/cytoplasmic ratio and nuclear pleomorphism. Which of the following is most likely responsible for this patient's current condition?

- A. Chronic hepatitis B infection
- B. Exposure to vinyl chloride
- C. Ingestion of aflatoxin
- D. Liver fluke infection
- E. Nonalcoholic fatty liver disease
- F. Psoriasis

Submit

https://t.me/USMLEWorldStep1

recreational drugs. Vital signs are within normal limits. BMI is 23 kg/m². The patient appears cachectic. Examination shows a mass in the liver. There is no splenomegaly or ascites. Laboratory results are as follows:

Total bilirubin	1.8 mg/dL
Alanine aminotransferase (SGPT)	70 U/L
Aspartate aminotransferase (SGOT)	105 U/L
Alkaline phosphatase	280 U/L
Anti–hepatitis C virus antibodies	negative
Hepatitis B surface antigen	negative
Antibody to hepatitis B core antigen	negative
Antibody to hepatitis B surface antigen	positive

Abdominal ultrasound shows a 6-cm mass in the right lobe of the liver; the remainder of the liver appears normal. Biopsy of the mass shows plates of abnormal cells that are smaller than normal hepatocytes with a high nuclear/cytoplasmic ratio and nuclear pleomorphism. Which of the following is most likely responsible for this patient's current condition?

- A. Chronic hepatitis B infection (11%)
- ✗ B. Exposure to vinyl chloride (9%)
- ✓ C. Ingestion of aflatoxin (64%)
- D. Liver fluke infection (11%)
- E. Nonalcoholic fatty liver disease (2%)
- F. Psoriasis (0%)

Incorrect
Correct answer

64%
Answered correctly

08 secs
Time Spent

2023
Version

https://t.me/USMLEWorldStep1

Explanation

This patient with weight loss, weakness, and abnormal laboratory studies (eg, hyperbilirubinemia, elevated liver enzymes) has a liver mass with histopathologic features of **hepatocellular carcinoma** (HCC). Common risk factors include viral hepatitis, alcohol use, congenital metabolic disorders, and environmental toxins. Given this patient's former job on a corn farm, **aflatoxin B1** exposure likely contributed to tumor development.

Aflatoxin B1 is a carcinogenic metabolite produced as a by-product by certain strains of ***Aspergillus*** that contaminate grains and nuts (eg, **corn**, peanuts), particularly in hot, humid environments (eg, Southeast Asia, sub-Saharan Africa). Ingestion contributes to pathogenesis by inducing specific mutations in ***p53*** that impair the protein's tumor-suppressor function, leading to unregulated hepatocyte proliferation and accumulation of further genetic abnormalities. In addition, chronic exposure can act with other risk factors (eg, hepatitis B virus [HBV] infection) to significantly increase the risk for HCC.

Patients with HCC are often asymptomatic or have mild abdominal pain with nonspecific symptoms (eg, weight loss, malaise). Those with underlying chronic liver disease may show signs of worsening cirrhosis (eg, ascites, variceal bleeding). Microscopically, HCC typically shows thickened plates of **malignant hepatocytes** that resemble normal hepatocytes but are often smaller and have variable **cytologic atypia** (eg, pleomorphism, high nuclear/cytoplasmic ratio).

(Choice A) Chronic HBV infection is a common risk factor for HCC, but this patient's serology studies are consistent with prior vaccination, not chronic infection.

(Choice B) Vinyl chloride exposure is a risk factor for hepatic angiosarcoma, a malignant vascular tumor. Weight loss and weakness may occur, but histopathology typically shows infiltrative vascular structures lined by atypical (eg, pleomorphic, hyperchromatic) endothelial cells.

(Choice D) *Clonorchis sinensis* (liver fluke) infection is a risk factor for cholangiocarcinoma, a malignant tumor derived from bile duct epithelium. Although *C sinensis* is endemic in east Asia, histopathology of cholangiocarcinoma typically shows infiltrative glands lined by atypical epithelial cells.

(Choice E) Nonalcoholic fatty liver disease is a risk factor for HCC but is usually associated with metabolic

https://t.me/USMLEWorldStep1

protein's tumor-suppressor function, leading to unregulated hepatocyte proliferation and accumulation of further genetic abnormalities. In addition, chronic exposure can act with other risk factors (eg, hepatitis B virus [HBV] infection) to significantly increase the risk for HCC.

Patients with HCC are often asymptomatic or have mild abdominal pain with nonspecific symptoms (eg, weight loss, malaise). Those with underlying chronic liver disease may show signs of worsening cirrhosis (eg, ascites, variceal bleeding). Microscopically, HCC typically shows thickened plates of **malignant hepatocytes** that resemble normal hepatocytes but are often smaller and have variable **cytologic atypia** (eg, pleomorphism, high nuclear/cytoplasmic ratio).

(Choice A) Chronic HBV infection is a common risk factor for HCC, but this patient's serology studies are consistent with prior vaccination, not chronic infection.

(Choice B) Vinyl chloride exposure is a risk factor for hepatic angiosarcoma, a malignant vascular tumor. Weight loss and weakness may occur, but histopathology typically shows infiltrative vascular structures lined by atypical (eg, pleomorphic, hyperchromatic) endothelial cells.

(Choice D) *Clonorchis sinensis* (liver fluke) infection is a risk factor for cholangiocarcinoma, a malignant tumor derived from bile duct epithelium. Although *C sinensis* is endemic in east Asia, histopathology of cholangiocarcinoma typically shows infiltrative glands lined by atypical epithelial cells.

(Choice E) Nonalcoholic fatty liver disease is a risk factor for HCC but is usually associated with metabolic syndrome (eg, obesity, hypertension); liver ultrasonography typically reveals evidence of fatty infiltration.

(Choice F) This patient has psoriasis, a chronic inflammatory skin disorder that causes well-circumscribed, erythematous plaques with silver-white scales. Psoriasis is not thought to have a direct role in HCC pathogenesis.

Educational objective:
Aflatoxin B1 is a carcinogen produced by *Aspergillus* that contaminates food (eg, corn) in hot, humid environments (eg, Southeast Asia). Chronic aflatoxin B1 ingestion is associated with inactivating *p53* mutations that increases the risk for hepatocellular carcinoma.

Pathology	Gastrointestinal & Nutrition	Hepatocellular cancer
Subject	System	Topic

https://t.me/USMLEWorldStep1

enzymes) has a liver mass with histopathologic features of **hepatocellular carcinoma** (HCC). Common risk

factors

patien

Aflatox

contar

Sahar

protei

geneti

infecti

Patien

loss, n

varice

resem

nuclea

(Choi

consis

(Choi

loss a

(eg, pl

(Choi

derive

cholar

(Choi

syndr

(Choi

erythematous plaques with silver-white scales. Psoriasis is not thought to have a direct role in HCC pathogenesis.

Exhibit Display

Hepatocellular carcinoma

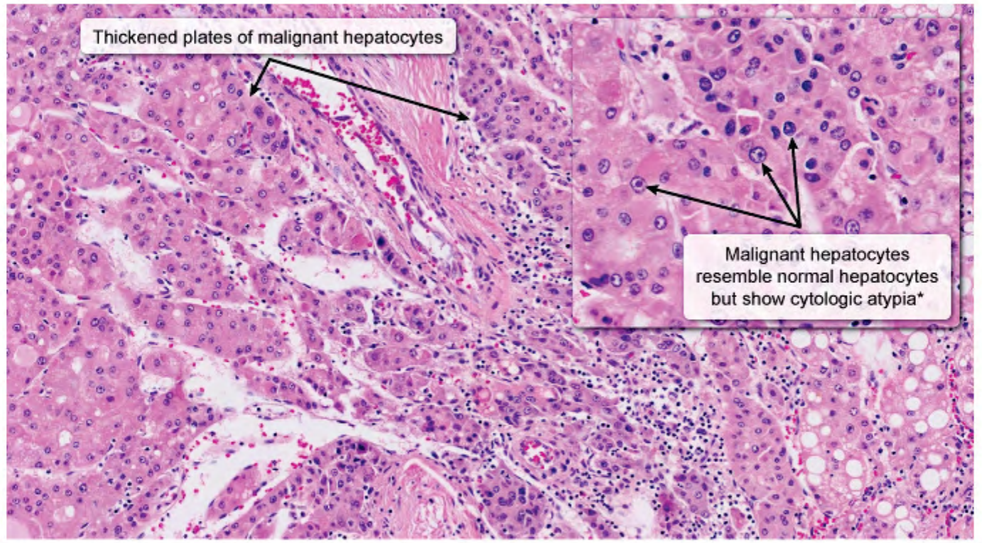

*Eg, large, irregular, hyperchromatic nuclei; prominent nucleoli.

©UWorld

Zoom In | Zoom Out | Reset | New | Existing | My Notebook

https://t.me/USMLEWorldStep1

enzymes) has a liver mass with histopathologic features of **hepatocellular carcinoma** (HCC). Common risk factors

patien

Aflatox
contar
Sahar
protei
geneti
infecti

Patien
loss, n
varice
resem
nuclea

(Choi
consis

(Choi
loss a
(eg, pl

(Choi
derive
cholar

(Choi
syndro

(Choi
erythematous plaques with silver-white scales. Psoriasis is not thought to have a direct role in HCC pathogenesis.

Exhibit Display

	HBsAg	HBeAg	IgM anti-HBc	IgG anti-HBc	Anti-HBs	Anti-HBe	HBV DNA
Acute HBV							
Early phase	+	+	+				+++
Window phase			+				+
Recovery phase				+	+	+	Likely +
Chronic HBV carrier	+			+			
Acute flare of chronic HBV	+	Likely +	+	+			+
Vaccinated for HBV					+		
Immune due to natural HBV infection				+	+		

anti-HBc = hepatitis B core antibody; **anti-HBe** = hepatitis B e antibody; **anti-HBs** = hepatitis B surface antibody; **HBeAg** = hepatitis B e antigen; **HBsAg** = hepatitis B surface antigen; **HBV** = hepatitis B virus.

New | Existing | My Notebook

https://t.me/USMLEWorldStep1

enzymes) has a liver mass with histopathologic features of **hepatocellular carcinoma** (HCC). Common risk

factors

patien

Aflatox

contar

Sahar

protei

geneti

infecti

Patien

loss, n

varice

resem

nuclea

(Choi

consis

(Choi

loss a

(eg, pl

(Choi

derive

cholan

(Choi

syndr

(Choi

erythematous plaques with silver-white scales. Psoriasis is not thought to have a direct role in HCC pathogenesis.

Exhibit Display

Hepatic angiosarcoma

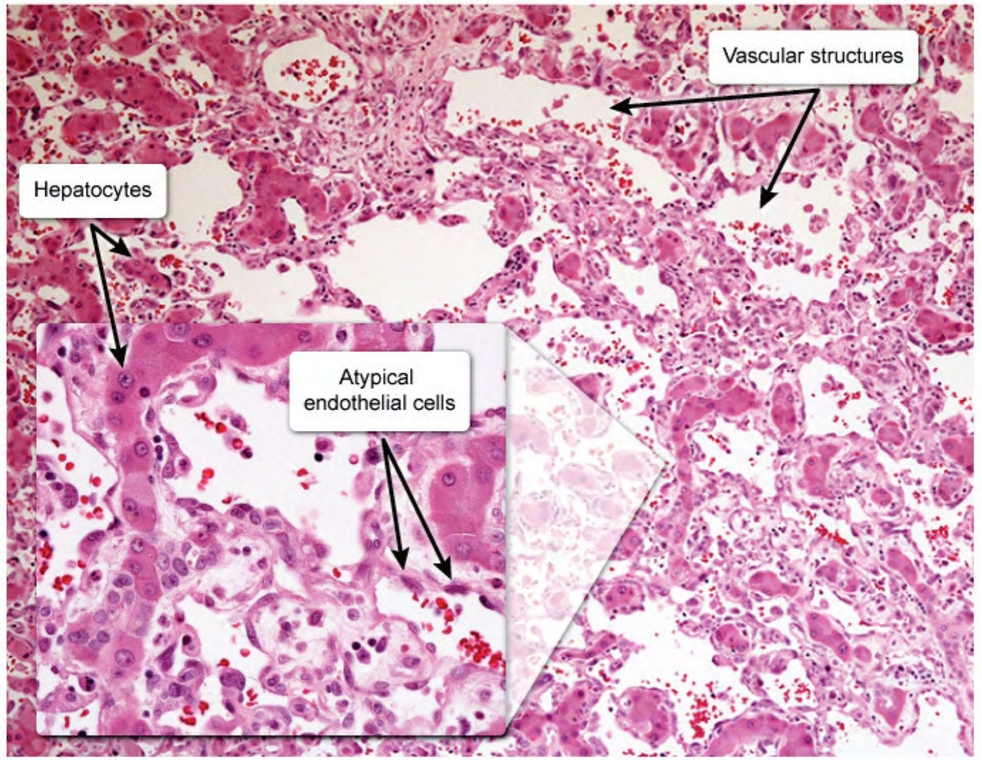

©UWorld

Zoom In Zoom Out Reset New | Existing My Notebook

https://t.me/USMLEWorldStep1

enzymes) has a liver mass with histopathologic features of **hepatocellular carcinoma** (HCC). Common risk

factors

patien

Aflatox

contar

Sahar

protei

geneti

infecti

Patien

loss, n

varice

resem

nuclea

(Choi

consis

(Choi

loss a

(eg, pl

(Choi

derive

cholan

(Choi

syndr

(Choi

erythematous plaques with silver-white scales. Psoriasis is not thought to have a direct role in HCC pathogenesis.

Exhibit Display

Intrahepatic cholangiocarcinoma

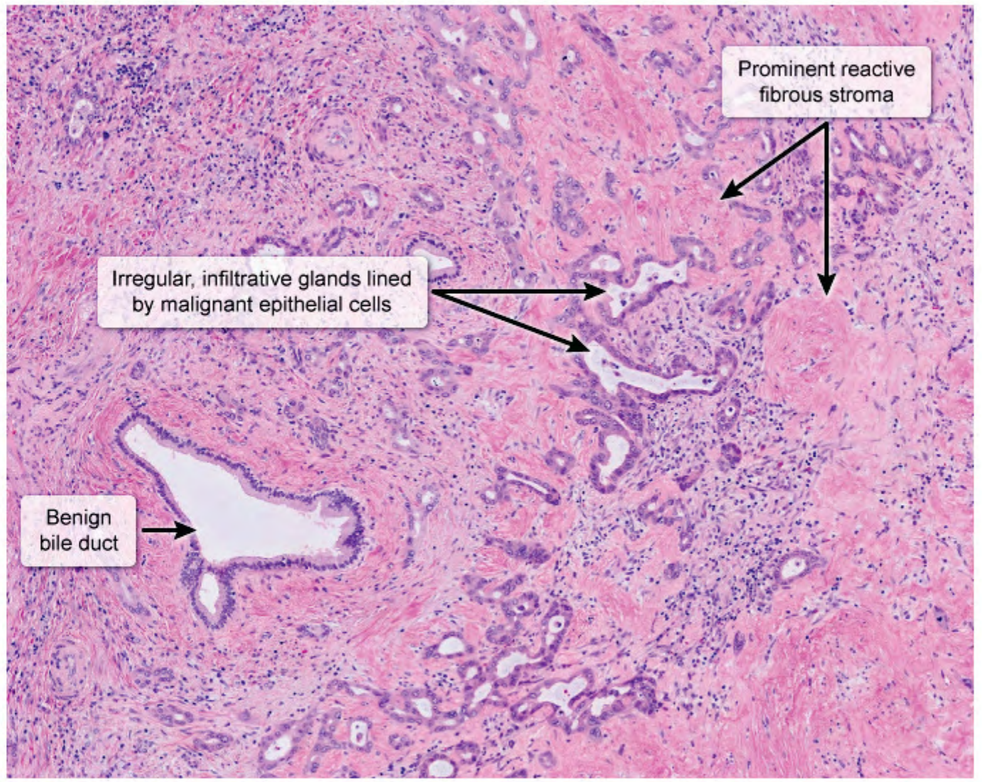

©UWorld

Zoom In Zoom Out Reset New | Existing My Notebook

https://t.me/USMLEWorldStep1

A 65-year-old man is referred to a gastroenterology clinic by his primary care provider after he develops symptoms suspicious for colorectal cancer. The patient has a history of obesity, diabetes mellitus, and chronic obstructive pulmonary disease. He often eats steaks and hamburgers but avoids vegetables as "they have no flavor." The patient has smoked a pack of cigarettes daily for the past 40 years and occasionally consumes alcohol. He undergoes a colonoscopy and is found to have a mass lesion in the ascending colon. The mass is biopsied, and the histopathologic findings are consistent with colon adenocarcinoma. This patient most likely initially presented with which of the following clinical symptoms?

- A. Abdominal pain, distension, and nausea
- B. Constipation alternating with diarrhea
- C. Recurrent grossly bloody stool and low-grade fever
- D. Tenesmus and small-caliber stool
- E. Weight loss and progressive fatigue

Submit

https://t.me/USMLEWorldStep1

A 65-year-old man is referred to a gastroenterology clinic by his primary care provider after he develops symptoms suspicious for colorectal cancer. The patient has a history of obesity, diabetes mellitus, and chronic obstructive pulmonary disease. He often eats steaks and hamburgers but avoids vegetables as "they have no flavor." The patient has smoked a pack of cigarettes daily for the past 40 years and occasionally consumes alcohol. He undergoes a colonoscopy and is found to have a mass lesion in the ascending colon. The mass is biopsied, and the histopathologic findings are consistent with colon adenocarcinoma. This patient most likely initially presented with which of the following clinical symptoms?

- ✗ A. Abdominal pain, distension, and nausea (6%)
- B. Constipation alternating with diarrhea (8%)
- C. Recurrent grossly bloody stool and low-grade fever (19%)
- D. Tenesmus and small-caliber stool (7%)
- ✓ E. Weight loss and progressive fatigue (58%)

Incorrect
Correct answer
E

58%
Answered correctly

04 secs
Time Spent

2023
Version

Explanation

The location of colon adenocarcinoma can influence its clinical manifestations. **Right-sided colon cancers** usually grow as exophytic masses. Patients generally do not develop intestinal obstruction because the ascending colon has a larger caliber lumen than the descending colon and stool in the proximal colon is more liquid. Right-sided colon cancers typically present with features of **iron deficiency anemia** (eg, fatigue, pallor) due to occult blood loss. Nonspecific symptoms such as anorexia, malaise, and unintentional weight loss may also occur.

Environmental and lifestyle factors that may have increased this patient's risk of colon cancer include obesity, cigarette smoking, consumption of red/processed meat, and low dietary intake of vegetables.

https://t.me/USMLEWorldStep1

The location of colon adenocarcinoma can influence its clinical manifestations. **Right-sided colon cancers** usually grow as exophytic masses. Patients generally do not develop intestinal obstruction because the ascending colon has a larger caliber lumen than the descending colon and stool in the proximal colon is more liquid. Right-sided colon cancers typically present with features of **iron deficiency anemia** (eg, fatigue, pallor) due to occult blood loss. Nonspecific symptoms such as anorexia, malaise, and unintentional weight loss may also occur.

Environmental and lifestyle factors that may have increased this patient's risk of colon cancer include obesity, cigarette smoking, consumption of red/processed meat, and low dietary intake of vegetables.

(Choice A) Left-sided colon cancers tend to infiltrate the intestinal wall and encircle the lumen, causing a change in bowel habits (eg, constipation) and symptoms of intestinal obstruction (eg, abdominal pain, distension, nausea/vomiting).

(Choice B) Constipation that alternates with diarrhea is characteristic of irritable bowel syndrome.

(Choice C) Recurrent grossly bloody stool associated with abdominal discomfort and low-grade fever is characteristic of ulcerative colitis, which is a risk factor for colon cancer. Rectosigmoid cancer often causes hematochezia, but fever is uncommon.

(Choice D) Tenesmus (ineffectual/painful straining on defecation) and small-caliber stool are characteristic of rectal adenocarcinoma.

Educational objective:
Right-sided colon cancers usually grow as exophytic masses and present with occult bleeding and symptoms of iron deficiency anemia. Left-sided colon cancers tend to infiltrate the intestinal wall and encircle the lumen, causing constipation and symptoms of intestinal obstruction. Rectosigmoid involvement often causes hematochezia.

References

- Left and right sided large bowel cancer.
- Correlation of clinical data, anatomical site and disease stage in colorectal cancer.
- How does colorectal cancer present? Symptoms, duration, and clues to location.

https://t.me/USMLEWorldStep1

A 35-year-old man with a history of alcohol use disorder is brought to the emergency department with hematemesis. Prior to this, he has had three episodes of vomiting. His BP is 110/80 mmHg and pulse is 98/min. He has no jaundice. Lungs are clear to auscultation. Abdomen is soft, non-tender, and non-distended. There is no hepatomegaly. Endoscopy shows longitudinal mucosal tears at the gastroesophageal junction. Which of the following factors is most directly related to the pathogenesis of this patient's current condition?

- A. Intraabdominal pressure
- B. Venous pressure
- C. Local inflammation
- D. Acid reflux
- E. Mucosal ischemia

Submit

https://t.me/USMLEWorldStep1

A 35-year-old man with a history of alcohol use disorder is brought to the emergency department with hematemesis. Prior to this, he has had three episodes of vomiting. His BP is 110/80 mmHg and pulse is 98/min. He has no jaundice. Lungs are clear to auscultation. Abdomen is soft, non-tender, and non-distended. There is no hepatomegaly. Endoscopy shows longitudinal mucosal tears at the gastroesophageal junction. Which of the following factors is most directly related to the pathogenesis of this patient's current condition?

- ✓ A. Intraabdominal pressure (60%)
- B. Venous pressure (11%)
- C. Local inflammation (4%)
- D. Acid reflux (19%)
- E. Mucosal ischemia (3%)

Correct | 60% Answered correctly | 04 secs Time Spent | 2023 Version

Explanation

Longitudinal mucosal tears at the esophagogastric-squamocolumnar junction describe **Mallory-Weiss syndrome**. Most commonly, these tears occur secondary to rapid **increase of intraabdominal and intraluminal gastric pressure**, as happens during **retching and vomiting**. Other precipitating factors include coughing, hiccupping, other repeated abdominal straining, and abdominal trauma. Additionally, hiatal hernias are found in about half of patients with Mallory-Weiss syndrome and are considered a strong predisposing factor. Mallory-Weiss syndrome is very commonly associated with chronic alcohol use.

Mallory-Weiss tears can be asymptomatic or can lead to gastrointestinal hemorrhage that manifests as **hematemesis**. About 10% of all upper gastrointestinal bleeds are from Mallory-Weiss syndrome. The intensity of hemorrhage and amount of blood loss varies widely according to the length and depth of the tears, but is almost

https://t.me/USMLEWorldStep1

Explanation

Longitudinal mucosal tears at the esophagogastric-squamocolumnar junction describe **Mallory-Weiss syndrome**. Most commonly, these tears occur secondary to rapid **increase of intraabdominal and intraluminal gastric pressure**, as happens during **retching and vomiting**. Other precipitating factors include coughing, hiccupping, other repeated abdominal straining, and abdominal trauma. Additionally, hiatal hernias are found in about half of patients with Mallory-Weiss syndrome and are considered a strong predisposing factor. Mallory-Weiss syndrome is very commonly associated with chronic alcohol use.

Mallory-Weiss tears can be asymptomatic or can lead to gastrointestinal hemorrhage that manifests as **hematemesis**. About 10% of all upper gastrointestinal bleeds are from Mallory-Weiss syndrome. The intensity of hemorrhage and amount of blood loss varies widely according to the length and depth of the tears, but is almost never life-threatening.

(Choice B) Increased venous pressure is associated with potentially life-threatening hemorrhage from esophageal varices. Esophageal varices occur in patients with cirrhosis who often have other signs of chronic liver disease–such as jaundice, spider nevi, palmar erythema, gynecomastia, and a history of chronic alcohol use. Endoscopy is diagnostic.

(Choices C and D) Local inflammation plays a role in the development of chronic gastritis and esophagitis. Acid reflux is characteristic of gastroesophageal reflux disease (GERD). Neither condition is known for significant upper GI bleeding.

(Choice E) Diminished blood perfusion to the small bowel and colon may result from arterial occlusion by embolus, thrombosis of the venous system, or low cardiac output. Ischemic bowel is the result, and it is a very dangerous condition. Ischemic bowel occurs most often in older patients.

Educational objective:
Mallory-Weiss tears account for about 10% of cases of upper GI hemorrhage. They occur due to increased intraluminal gastric pressure due to retching, vomiting, or other abdominal straining.

Pathology Gastrointestinal & Nutrition Mallory-weiss syndrome

https://t.me/USMLEWorldStep1

A 65-year-old woman comes to the emergency department with progressive fatigue and lower-extremity paresthesias. Medical history is otherwise insignificant and the patient takes no medications. Laboratory studies show a mean corpuscular volume of 112 fL. Upper gastrointestinal endoscopy shows atrophic mucosa in the gastric body and fundus and a normal-appearing antrum. Destruction of which of the following gastric layers is most likely responsible for this patient's symptoms?

- A. A
- B. B
- C. C
- D. D

Submit

https://t.me/USMLEWorldStep1

A 65-year-old woman comes to the emergency department with progressive fatigue and lower-extremity
parest
show
gastric
most li

Exhibit Display

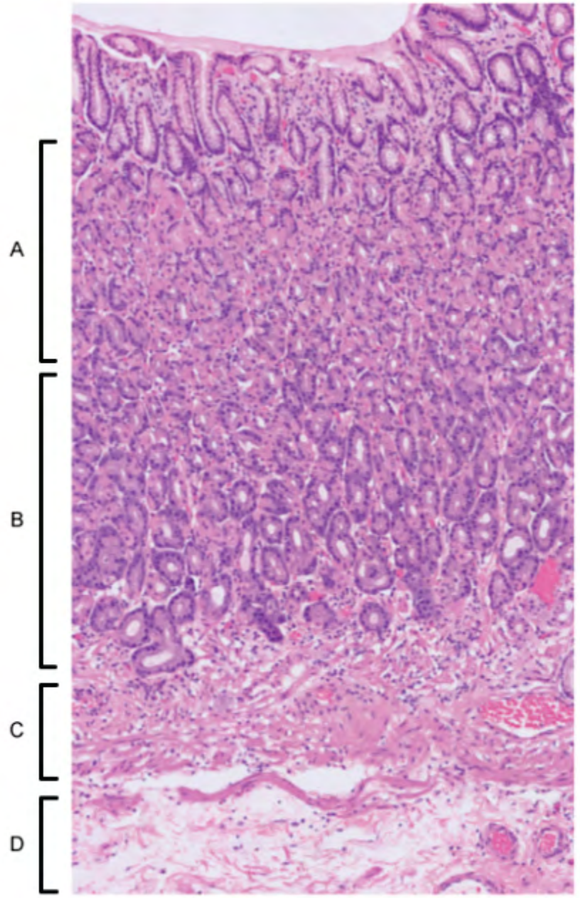

Zoom In | Zoom Out | Reset | New | Existing | My Notebook

https://t.me/USMLEWorldStep1

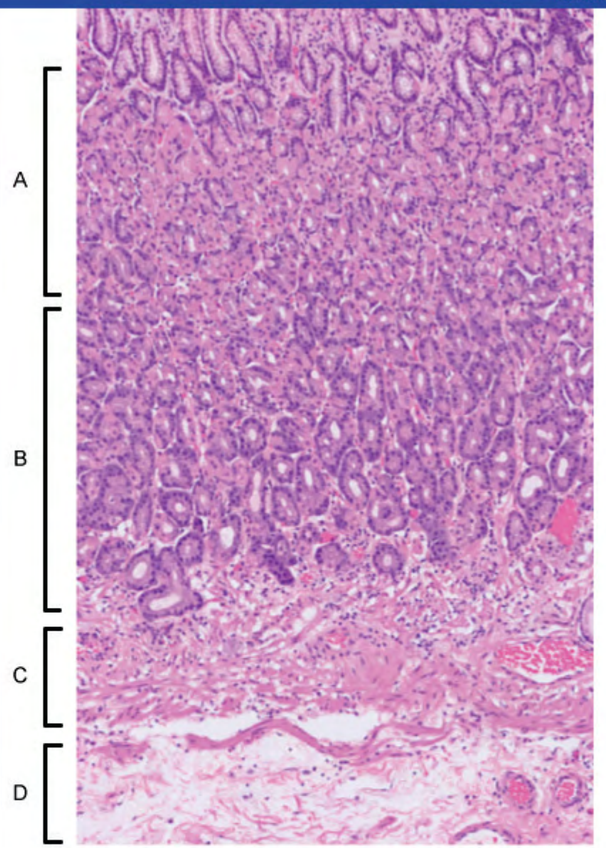

- A. A
- B. B
- C. C
- D. D

Submit

https://t.me/USMLEWorldStep1

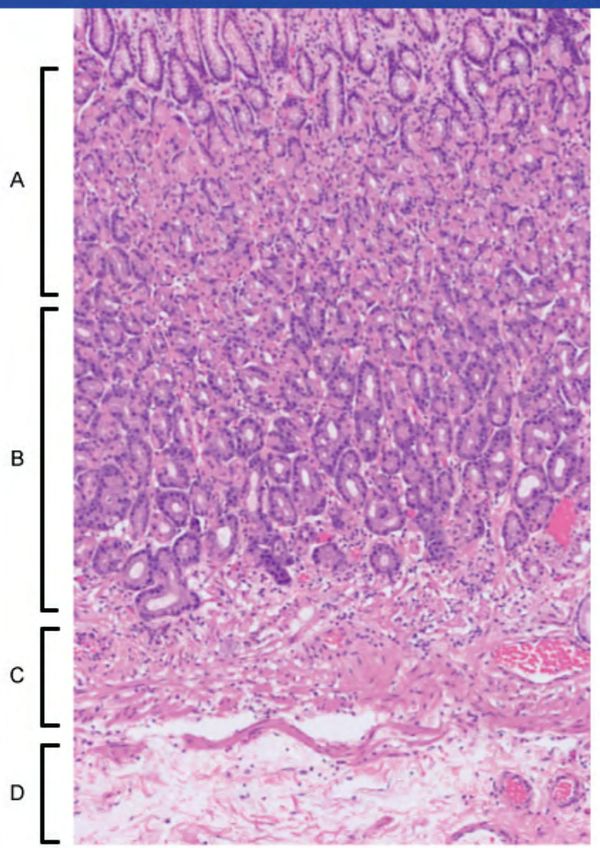

- ✓ A. A (49%)
- ✗ B. B (42%)
- C. C (5%)
- D. D (1%)

Incorrect
Correct answer
A

49%
Answered correctly

12 secs
Time Spent

2023
Version

https://t.me/USMLEWorldStep1

Incorrect
Correct answer
A

49%
Answered correctly

12 secs
Time Spent

2023
Version

Exhibit Display

Normal gastric histology

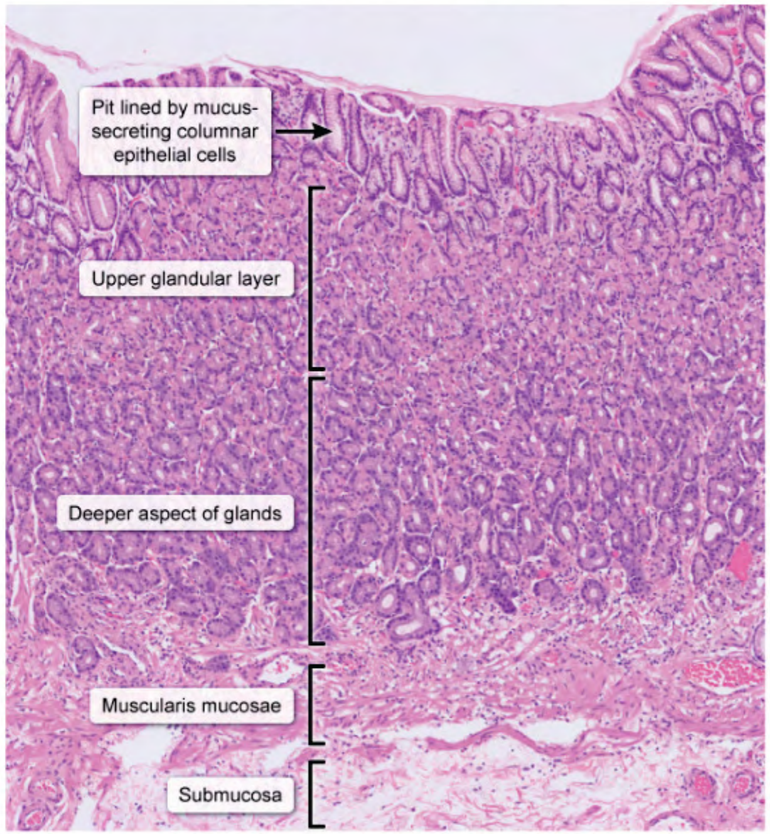

Zoom In | Zoom Out | Reset | New | Existing | My Notebook

https://t.me/USMLEWorldStep1

©UWorld

The combination of lower-extremity paresthesias, macrocytic red blood cells (RBCs), and gastric body and fundal atrophy is highly suggestive of **pernicious anemia** (PA). PA is an autoimmune disorder caused by the cell-mediated **destruction of parietal cells**, pink cells found predominantly in the **upper glandular layer** of the gastric body and fundus. Over time, progressive parietal cell destruction leads to chronic atrophic gastritis (ie, autoimmune gastritis), characterized histologically by a CD4-predominate inflammatory infiltrate, oxyntic gland atrophy, and intestinal metaplasia (ie, normal stomach epithelia replaced by intestinal epithelium with goblet cells).

Parietal cells are responsible for the secretion of hydrochloric acid and intrinsic factor, a glycoprotein that is involved in the absorption of B_{12} (cobalamin, an essential nutrient). After a critical number of parietal cells are destroyed and hepatic stores of cobalamin are depleted, patients **develop B_{12} deficiency**. This results in a **megaloblastic anemia**, characterized by macro-ovalocytes (elevated mean corpuscular volume, oval-shaped RBCs) and hypersegmented neutrophils. Patients also develop neurologic dysfunction due to demyelination of the dorsal and lateral spinal tracts, resulting in **paresthesias and ataxia**.

(Choice B) In contrast to the parietal cell-rich superficial gastric glands, the deeper region of the gastric oxyntic glands has a preponderance of small, basophilic, granular chief cells that synthesize and secrete pepsinogen.

(Choice C) This region contains the muscularis mucosae, which separates the lamina propria from the submucosa.

(Choice D) This region contains the submucosa, which consists of well-vascularized connective tissue.

Educational objective:
Pernicious anemia is an autoimmune disorder caused by the cell-mediated destruction of parietal cells in the superficial upper glandular layer of the gastric body and fundus. Parietal cells are responsible for the secretion of hydrochloric acid and intrinsic factor, a glycoprotein involved in the absorption of B_{12}. Deficiency leads to megaloblastic anemia and neurologic dysfunction.

Histology	Gastrointestinal & Nutrition	Vitamin b12 deficiency
Subject	System	Topic

Copyright © UWorld. All rights reserved.

https://t.me/USMLEWorldStep1

©UWorld

The co
atroph
media
body a
autoim
atroph

Parieta
involve
destro
megal
RBCs)
dorsal

(Choi
glands

(Choi
submu

(Choi

Educa
Pernic
superf
hydroc
megal

Histolog
Subject

Exhibit Display

Normal gastric mucosa

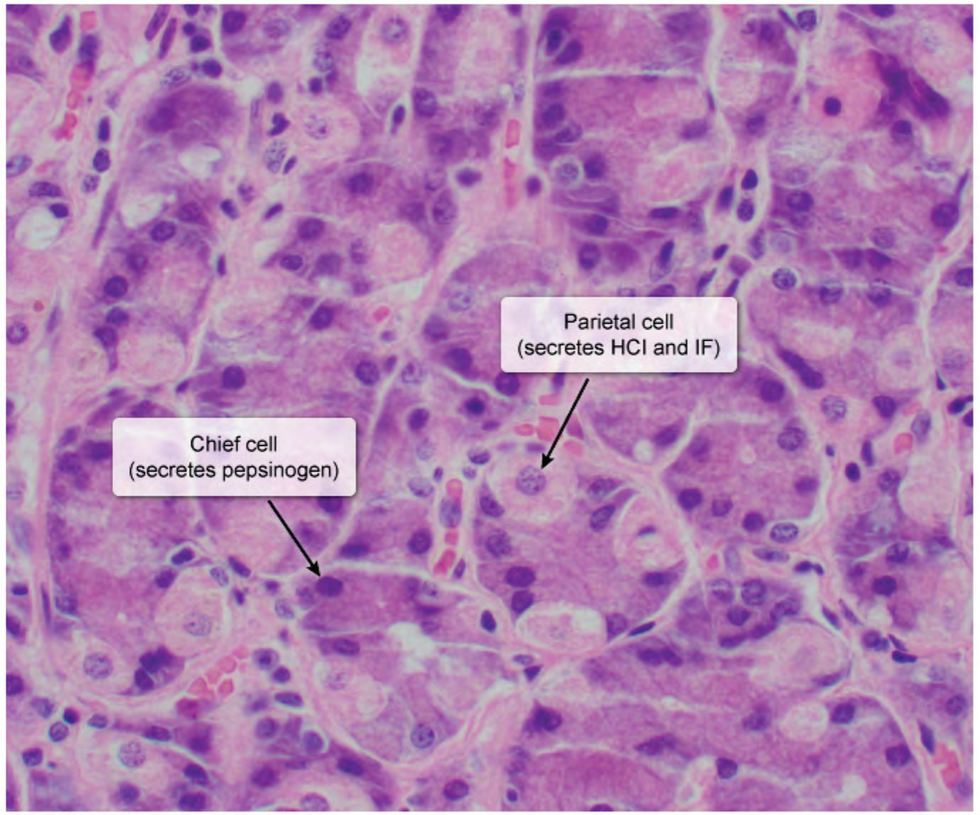

HCl = hydrochloric acid; **IF** = intrinsic factor.

©UWorld

Zoom In | Zoom Out | Reset | New | Existing | My Notebook

Copyright © UWorld. All rights reserved.

https://t.me/USMLEWorldStep1

©UWorld

The co
atroph
media
body a
autoim
atroph

Parieta
involve
destro
megal
RBCs)
dorsal

(Choi
glands

(Choi
submu

(Choi

Educa
Pernic
superf
hydroc
megal

Histolog
Subject

Exhibit Display

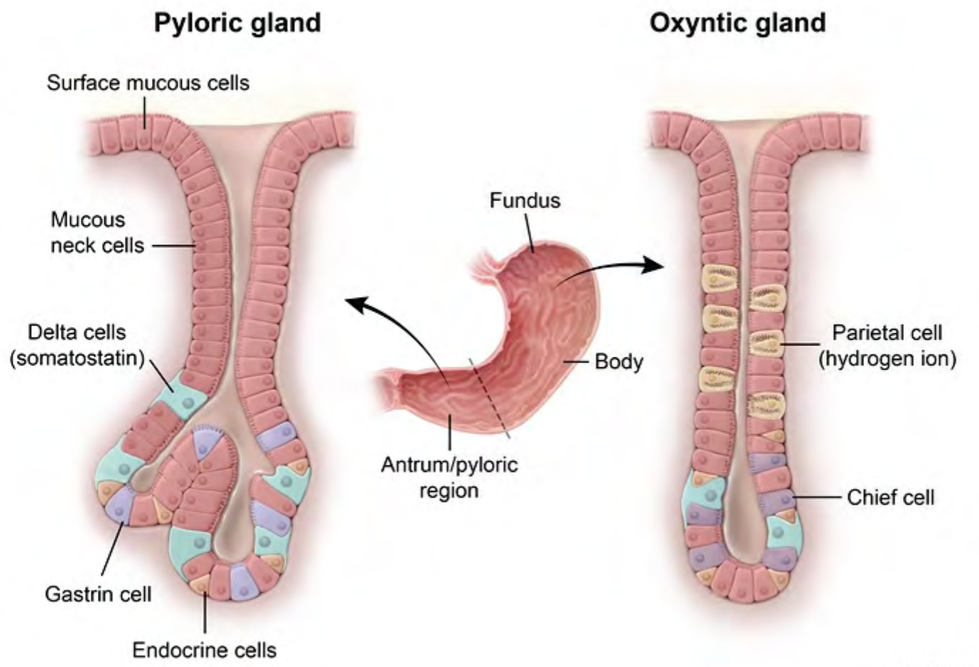

Zoom In | Zoom Out | Reset | New | Existing | My Notebook

Copyright © UWorld. All rights reserved.

https://t.me/USMLEWorldStep1

A 35-year-old woman comes to the clinic due to severe heartburn that is resistant to over-the-counter antacids. The patient has no known medical problems and takes no other medications. She occasionally has a glass of wine with dinner but does not use tobacco or illicit drugs. Physical examination shows scattered telangiectasias on the face, several ulcers at the tips of the fingers, and small calcium deposits in the soft tissues of the hands and elbows. Which of the following processes is the most likely cause of this patient's heartburn?

- A. Abnormal location of the gastroesophageal junction
- B. Fibrous replacement of the muscularis in the lower esophagus
- C. Increased gastric acid production
- D. Increase in resting lower esophageal sphincter tone
- E. Uncoordinated, simultaneous muscle contractions in the lower esophagus

Submit

https://t.me/USMLEWorldStep1

A 35-year-old woman comes to the clinic due to severe heartburn that is resistant to over-the-counter antacids. The patient has no known medical problems and takes no other medications. She occasionally has a glass of wine with dinner but does not use tobacco or illicit drugs. Physical examination shows scattered telangiectasias on the face, several ulcers at the tips of the fingers, and small calcium deposits in the soft tissues of the hands and elbows. Which of the following processes is the most likely cause of this patient's heartburn?

- A. Abnormal location of the gastroesophageal junction (3%)
- ✓ B. Fibrous replacement of the muscularis in the lower esophagus (59%)
- C. Increased gastric acid production (13%)
- D. Increase in resting lower esophageal sphincter tone (7%)
- E. Uncoordinated, simultaneous muscle contractions in the lower esophagus (15%)

Correct | 59% Answered correctly | 04 secs Time Spent | 2023 Version

Explanation

This patient has features consistent with **CREST syndrome** (ie, Calcinosis, Raynaud phenomenon, Esophageal dysmotility, Sclerodactyly, Telangiectasia), a limited variant of systemic sclerosis with skin disease that primarily affects the face, forearms, and fingers. The pathogenesis of systemic sclerosis involves chronic autoimmune inflammation, vascular endothelial injury resulting in chronic ischemic tissue damage (eg, fingertip ulcers), and excessive activation of fibroblasts leading to progressive tissue fibrosis.

Esophageal dysmotility is a result of **atrophy** and **fibrous replacement** of the muscularis in the lower esophagus. The esophageal body and the lower esophageal sphincter become atonic and dilated, resulting in symptoms of **gastroesophageal reflux** (eg, heartburn, regurgitation, dysphagia). This increases the risk of Barrett esophagus and fibrous stricture formation.

https://t.me/USMLEWorldStep1

Explanation

This patient has features consistent with **CREST syndrome** (ie, Calcinosis, Raynaud phenomenon, Esophageal dysmotility, Sclerodactyly, Telangiectasia), a limited variant of systemic sclerosis with skin disease that primarily affects the face, forearms, and fingers. The pathogenesis of systemic sclerosis involves chronic autoimmune inflammation, vascular endothelial injury resulting in chronic ischemic tissue damage (eg, fingertip ulcers), and excessive activation of fibroblasts leading to progressive tissue fibrosis.

Esophageal dysmotility is a result of **atrophy** and **fibrous replacement** of the muscularis in the lower esophagus. The esophageal body and the lower esophageal sphincter become atonic and dilated, resulting in symptoms of **gastroesophageal reflux** (eg, heartburn, regurgitation, dysphagia). This increases the risk of Barrett esophagus and fibrous stricture formation.

(Choice A) A sliding hiatal hernia is characterized by herniation of the gastroesophageal junction and a portion of the stomach through the esophageal hiatus, which predisposes patients to gastroesophageal reflux.

(Choice C) Increased gastric acid production occurs with gastrinomas, gastrin-secreting neuroendocrine tumors of the small intestine/pancreas that often present with multiple or medically refractory peptic ulcers.

(Choice D) Achalasia is an esophageal motility disorder characterized by failed relaxation of the lower esophageal sphincter resulting in food retention, dilation of the esophageal body, and symptoms of solid/liquid dysphagia.

(Choice E) Diffuse esophageal spasm is characterized by periodic, uncoordinated, simultaneous contractions of the lower esophagus due to impaired inhibitory innervation within the esophageal myenteric plexus. Patients typically have liquid/solid dysphagia and chest pain due to inefficient propagation of food into the stomach.

Educational objective:
Systemic sclerosis may result in esophageal dysmotility and incompetence of the lower esophageal sphincter due to atrophy and fibrous replacement of the esophageal muscularis. This can cause gastroesophageal reflux with an increased risk of Barrett esophagus and stricture formation.

References

- Diagnosis and treatment of scleroderma.

https://t.me/USMLEWorldStep1

Explanation

This p
dysmo
affects
inflam
excess

Esoph
The es
gastro
and fib

(Choi
the sto

(Choi
the sm

(Choi
sphinc

(Choi
the lov
typical

Educa
Syster
to atro
increa

References

- Diagnosis and treatment of scleroderma.

Exhibit Display

Calcinosis

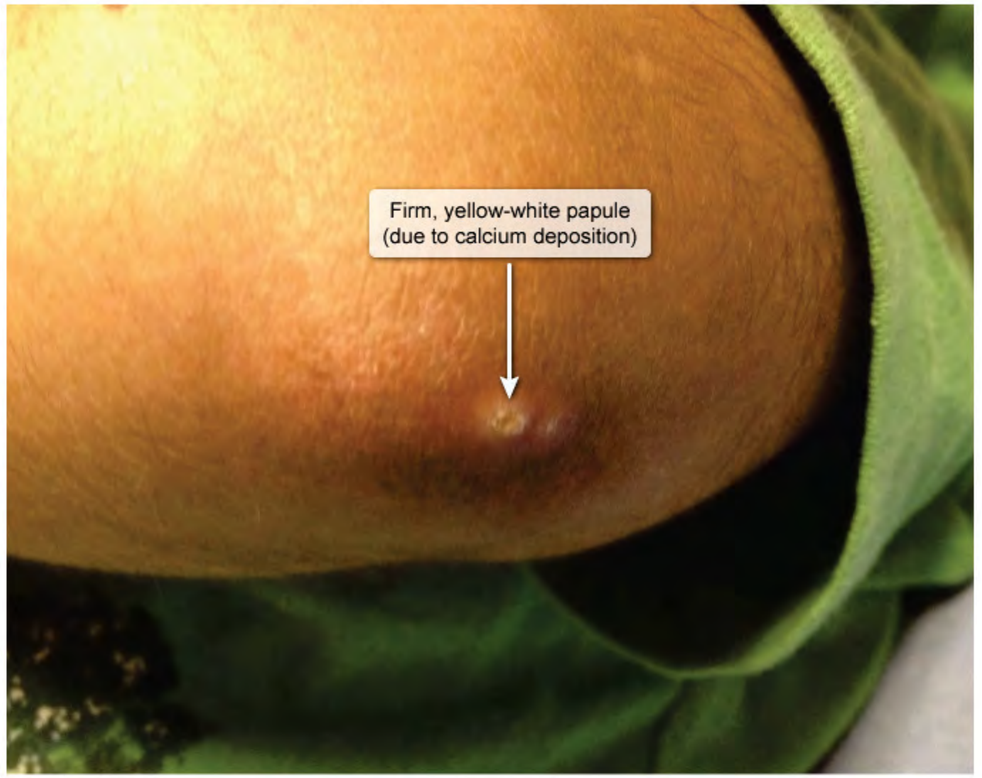

©UWorld

Zoom In | Zoom Out | Reset | New | Existing | My Notebook

https://t.me/USMLEWorldStep1

Explanation

Exhibit Display

This p
dysmo
affects
inflam
excess

Esoph
The es
gastro
and fib

(Choi
the sto

(Choi
the sm

(Choi
sphinc

(Choi
the lov
typical

Educa
Syster
to atro
increa

References

- Diagnosis and treatment of scleroderma.

Sclerodactyly

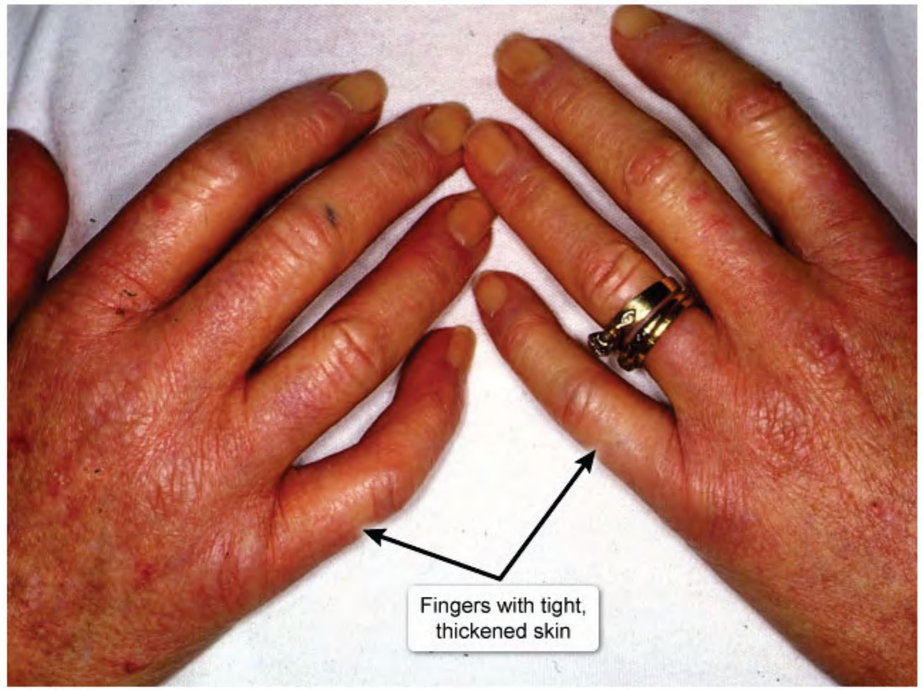

©UWorld

Zoom In | Zoom Out | Reset | New | Existing | My Notebook

https://t.me/USMLEWorldStep1

Explanation

Exhibit Display

This p
dysmo
affects
inflam
excess

Esoph
The es
gastro
and fib

(Choi
the sto

(Choi
the sm

(Choi
sphinc

(Choi
the lov
typical

Educa
Syster
to atro
increa

References

- Diagnosis and treatment of scleroderma.

Telangiectasia

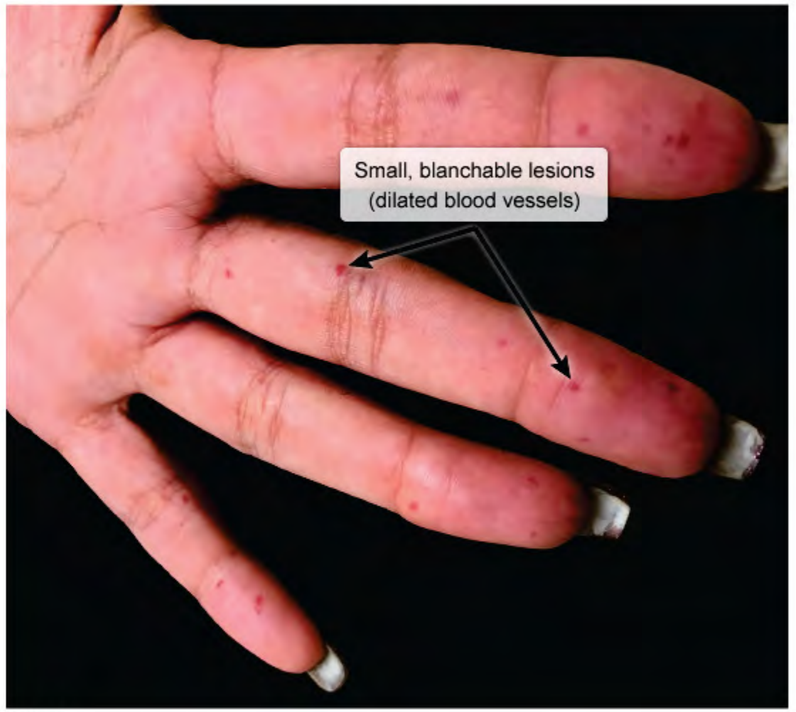

©UWorld

Zoom In | Zoom Out | Reset | New | Existing | My Notebook

https://t.me/USMLEWorldStep1

Explanation

Exhibit Display

This p
dysmo
affects
inflam
excess

Esoph
The es
gastro
and fib

(Choi
the sto

(Choi
the sm

(Choi
sphinc

(Choi
the lov
typical

Educa
Syster
to atro
increa

References

- Diagnosis and treatment of scleroderma.

Systemic sclerosis

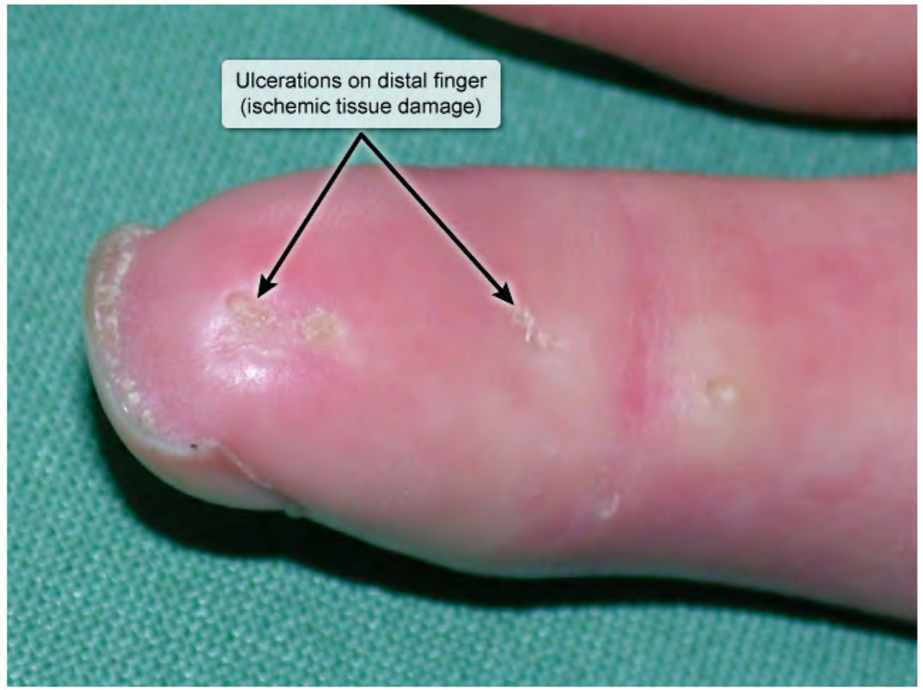

©UWorld

Zoom In | Zoom Out | Reset | New | Existing | My Notebook

https://t.me/USMLEWorldStep1

A 54-year-old man is evaluated in the clinic due to generalized weakness and lethargy for the past 5 years. He has no history of hypothyroidism or depression. The patient uses acetaminophen intermittently for joint pains that he attributes to "old age." He drinks alcohol occasionally but does not use tobacco or illicit drugs. His older brother died of liver cirrhosis. Laboratory tests show a serum ferritin level of 1800 µg/L. If this patient's disorder is hereditary, the genetic defect responsible for his condition most likely affects which of the following processes?

- A. Blood iron transport
- B. Hemoglobin synthesis
- C. Hepatic iron excretion
- D. Intestinal iron absorption
- E. Renal iron excretion

Submit

https://t.me/USMLEWorldStep1

A 54-year-old man is evaluated in the clinic due to generalized weakness and lethargy for the past 5 years. He has no history of hypothyroidism or depression. The patient uses acetaminophen intermittently for joint pains that he attributes to "old age." He drinks alcohol occasionally but does not use tobacco or illicit drugs. His older brother died of liver cirrhosis. Laboratory tests show a serum ferritin level of 1800 µg/L. If this patient's disorder is hereditary, the genetic defect responsible for his condition most likely affects which of the following processes?

- A. Blood iron transport (9%)
- B. Hemoglobin synthesis (3%)
- ✗ C. Hepatic iron excretion (24%)
- ✓ D. Intestinal iron absorption (60%)
- E. Renal iron excretion (1%)

Incorrect
Correct answer
D

60%
Answered correctly

19 secs
Time Spent

2023
Version

Explanation

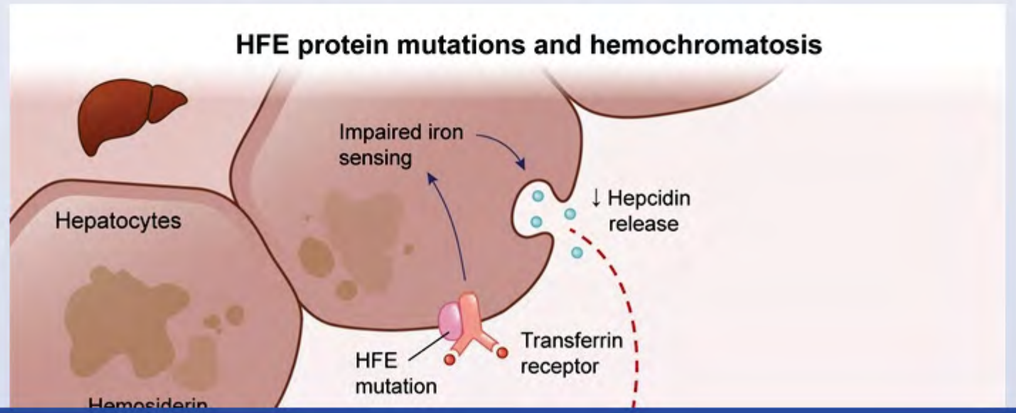

https://t.me/USMLEWorldStep1

A 54-year-old man is evaluated in the clinic due to generalized weakness and lethargy for the past 5 years. He has no hist
attribu
died o
heredi

Exhibit Display

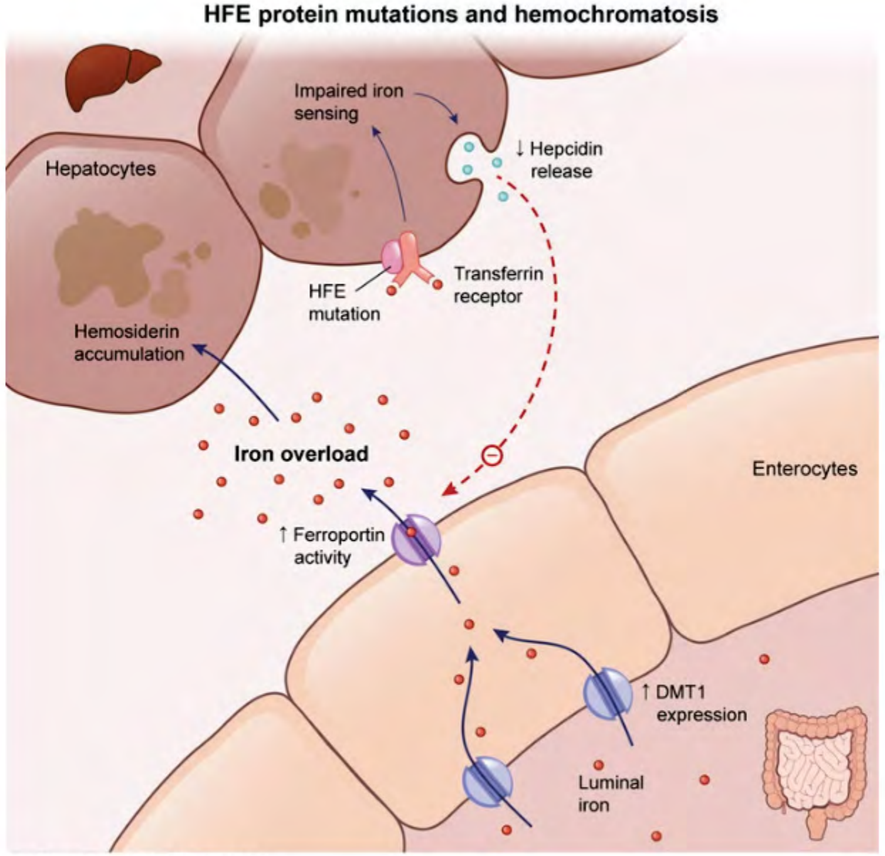

DMT1 = divalent metal transporter 1.
©UWorld

Zoom In | Zoom Out | Reset | New | Existing | My Notebook

©UWorld

This patient likely has **hereditary hemochromatosis**, an autosomal recessive disorder characterized by excessive intestinal iron absorption and accumulation within parenchymal tissues that result in end-organ damage (eg, cirrhosis, diabetes mellitus, cardiomyopathy, arthropathy). The condition is frequently caused by a missense mutation in the ***HFE* gene** (eg, C282Y).

The HFE protein interacts with the transferrin receptor on the cell surface to facilitate endocytosis of the iron-transferrin complex. Once inside the cell, transferrin is degraded and the released iron is added to the labile iron pool. Mutation of the HFE protein leads to reduced iron uptake and causes enterocytes and hepatocytes to sense falsely low iron levels. This enhances iron accumulation in the body via 2 mechanisms:

1. Enterocytes increase apical expression of divalent metal transporter 1 (DMT1), **increasing intestinal iron absorption** from the lumen.
2. Hepatocytes **decrease hepcidin** synthesis, which increases ferroportin expression on the basolateral surface of enterocytes and promotes iron secretion into the circulation.

Excessive iron accumulation results in elevated levels of serum ferritin (cellular iron storage protein) and increased saturation of transferrin (major iron transporter in the plasma).

(Choice A) Iron transport in the blood is not impaired in hereditary hemochromatosis as transferrin function is normal.

(Choice B) Patients with severe forms of thalassemia (eg, beta thalassemia major) often have chronic hemolytic anemia and develop iron overload due to repeated blood transfusions (secondary hemochromatosis). However, hemoglobin production is normal in patients with hereditary hemochromatosis as iron transport to the bone marrow is unaffected.

(Choices C and E) Total body iron levels are regulated by varying the rate of intestinal iron absorption. Although iron loss occurs through sloughing of the intestinal lining and during menstruation in women, there are no regulated mechanisms to excrete iron from the body.

Educational objective:
Hereditary hemochromatosis is most commonly caused by a missense mutation in the *HFE* gene, resulting in excessive intestinal iron absorption and organ damage (eg, cirrhosis, diabetes mellitus, cardiomyopathy

https://t.me/USMLEWorldStep1

mutation in the ***HFE* gene** (eg, C282Y).

The HFE protein interacts with the transferrin receptor on the cell surface to facilitate endocytosis of the iron-transferrin complex. Once inside the cell, transferrin is degraded and the released iron is added to the labile iron pool. Mutation of the HFE protein leads to reduced iron uptake and causes enterocytes and hepatocytes to sense falsely low iron levels. This enhances iron accumulation in the body via 2 mechanisms:

1. Enterocytes increase apical expression of divalent metal transporter 1 (DMT1), **increasing intestinal iron absorption** from the lumen.
2. Hepatocytes **decrease hepcidin** synthesis, which increases ferroportin expression on the basolateral surface of enterocytes and promotes iron secretion into the circulation.

Excessive iron accumulation results in elevated levels of serum ferritin (cellular iron storage protein) and increased saturation of transferrin (major iron transporter in the plasma).

(Choice A) Iron transport in the blood is not impaired in hereditary hemochromatosis as transferrin function is normal.

(Choice B) Patients with severe forms of thalassemia (eg, beta thalassemia major) often have chronic hemolytic anemia and develop iron overload due to repeated blood transfusions (secondary hemochromatosis). However, hemoglobin production is normal in patients with hereditary hemochromatosis as iron transport to the bone marrow is unaffected.

(Choices C and E) Total body iron levels are regulated by varying the rate of intestinal iron absorption. Although iron loss occurs through sloughing of the intestinal lining and during menstruation in women, there are no regulated mechanisms to excrete iron from the body.

Educational objective:
Hereditary hemochromatosis is most commonly caused by a missense mutation in the *HFE* gene, resulting in excessive intestinal iron absorption and organ damage (eg, cirrhosis, diabetes mellitus, cardiomyopathy, arthropathy) due to iron accumulation within parenchymal tissues.

References

https://t.me/USMLEWorldStep1

A 31-year-old previously healthy man comes to the office due to myalgias, anorexia, and skin rash. He does not use tobacco, alcohol, or illicit drugs. The patient works as a personal trainer and is a bodybuilding enthusiast. He denies using anabolic steroids but has been consuming large amounts of raw egg whites for the past several months. Physical examination shows macular dermatitis of the extremities. A water-soluble vitamin deficiency is suspected as the cause of his condition. Which of the following biochemical conversions most likely uses the deficient vitamin as a cofactor?

- A. Glucose to ribose-5-phosphate
- B. Pyruvate to acetyl-CoA
- C. Pyruvate to alanine
- D. Pyruvate to oxaloacetate
- E. Succinate to oxaloacetate

Submit

https://t.me/USMLEWorldStep1

A 31-year-old previously healthy man comes to the office due to myalgias, anorexia, and skin rash. He does not use tobacco, alcohol, or illicit drugs. The patient works as a personal trainer and is a bodybuilding enthusiast. He denies using anabolic steroids but has been consuming large amounts of raw egg whites for the past several months. Physical examination shows macular dermatitis of the extremities. A water-soluble vitamin deficiency is suspected as the cause of his condition. Which of the following biochemical conversions most likely uses the deficient vitamin as a cofactor?

- A. Glucose to ribose-5-phosphate (6%)
- ✕ B. Pyruvate to acetyl-CoA (24%)
- C. Pyruvate to alanine (8%)
- ✓ D. Pyruvate to oxaloacetate (50%)
- E. Succinate to oxaloacetate (9%)

Incorrect
Correct answer
D

50%
Answered correctly

28 secs
Time Spent

2023
Version

Explanation

Biotin (vitamin B_7) as a cofactor	
Enzyme	**Reaction**
Pyruvate carboxylase	Pyruvate to oxaloacetate (gluconeogenesis)
Acetyl-CoA carboxylase	Acetyl-CoA to malonyl-CoA (fatty acid synthesis)
	Propionyl-CoA to methylmalonyl-CoA

https://t.me/USMLEWorldStep1

Biotin (vitamin B_7) as a cofactor	
Enzyme	**Reaction**
Pyruvate carboxylase	Pyruvate to oxaloacetate (gluconeogenesis)
Acetyl-CoA carboxylase	Acetyl-CoA to malonyl-CoA (fatty acid synthesis)
Propionyl-CoA carboxylase	Propionyl-CoA to methylmalonyl-CoA (fatty acid oxidation)

Biotin (vitamin B_7) is an important cofactor for several **carboxylase** enzymes. It functions as a CO_2 carrier and plays an essential role in carbohydrate, lipid, and amino acid metabolism. In the liver, the conversion of **pyruvate to oxaloacetate** for gluconeogenesis requires pyruvate carboxylase and biotin.

Biotin deficiency is rare but can occur secondary to poor diet, excessive raw egg white consumption (due to high levels of **biotin-binding avidin** in egg whites), and congenital disorders of biotin metabolism. Patients with biotin deficiency present with nonspecific symptoms, including changes in mental status, myalgias, anorexia, and chronic **dermatologic changes** such as macular dermatitis. Biotin-deficient individuals can also develop **metabolic acidosis** as a result of increased conversion of pyruvate to lactic acid.

(Choice A) Niacin (vitamin B_3), in the form of $NADP^+$, is used to oxidize glucose-6-phosphate in the pentose phosphate pathway, generating ribose-5-phosphate and NADPH in the process.

(Choice B) Thiamine (vitamin B_1), riboflavin (vitamin B_2), niacin (vitamin B_3), pantothenic acid (vitamin B_5), and lipoic acid are the 5 cofactors required by the mitochondrial enzyme complex pyruvate dehydrogenase. In their absence, the metabolism of pyruvate to acetyl-CoA is not possible.

(Choice C) Pyridoxal phosphate (vitamin B_6) acts as a cofactor for alanine transaminase, which catalyzes the reversible reaction between pyruvate and glutamate to alanine and alpha-ketoglutarate in the liver and muscle tissue.

https://t.me/USMLEWorldStep1

Biotin (vitamin B_7) is an important cofactor for several **carboxylase** enzymes. It functions as a CO_2 carrier and plays an essential role in carbohydrate, lipid, and amino acid metabolism. In the liver, the conversion of **pyruvate to oxaloacetate** for gluconeogenesis requires pyruvate carboxylase and biotin.

Biotin deficiency is rare but can occur secondary to poor diet, excessive raw egg white consumption (due to high levels of **biotin-binding avidin** in egg whites), and congenital disorders of biotin metabolism. Patients with biotin deficiency present with nonspecific symptoms, including changes in mental status, myalgias, anorexia, and chronic **dermatologic changes** such as macular dermatitis. Biotin-deficient individuals can also develop **metabolic acidosis** as a result of increased conversion of pyruvate to lactic acid.

(Choice A) Niacin (vitamin B_3), in the form of $NADP^+$, is used to oxidize glucose-6-phosphate in the pentose phosphate pathway, generating ribose-5-phosphate and NADPH in the process.

(Choice B) Thiamine (vitamin B_1), riboflavin (vitamin B_2), niacin (vitamin B_3), pantothenic acid (vitamin B_5), and lipoic acid are the 5 cofactors required by the mitochondrial enzyme complex pyruvate dehydrogenase. In their absence, the metabolism of pyruvate to acetyl-CoA is not possible.

(Choice C) Pyridoxal phosphate (vitamin B_6) acts as a cofactor for alanine transaminase, which catalyzes the reversible reaction between pyruvate and glutamate to alanine and alpha-ketoglutarate in the liver and muscle tissue.

(Choice E) Production of oxaloacetate from succinate in the TCA cycle requires 2 enzymes (succinate dehydrogenase and malate dehydrogenase), along with riboflavin (vitamin B_2) and niacin (vitamin B_3) in the forms of cofactors FAD^+ and NAD^+, respectively.

Educational objective:
Biotin acts as a CO_2 carrier on the surface of carboxylase enzymes and is an essential cofactor for numerous reactions, including the conversion of pyruvate to oxaloacetate and fatty acid metabolism. Excess ingestion of avidin, found in egg whites, has been associated with biotin deficiency. This condition presents with mental status changes, myalgias, anorexia, macular dermatitis, and lactic acidosis.

Biochemistry Gastrointestinal & Nutrition Tca cycle

https://t.me/USMLEWorldStep1

plays an essential role in carbohydrate, lipid, and amino acid metabolism. In the liver, the conversion of **pyruvate to oxaloacetate** for gluconeogenesis requires pyruvate carboxylase and biotin.

Biotin
levels
deficie
derma
acidos

(Choi
phosp

(Choi
lipoic a
absen

(Choi
revers
tissue.

(Choi
dehyd
of cofa

Educa
Biotin
reactio
avidin,
chang

Biochen
Subject

Copyright © UWorld. All rights reserved.

Exhibit Display

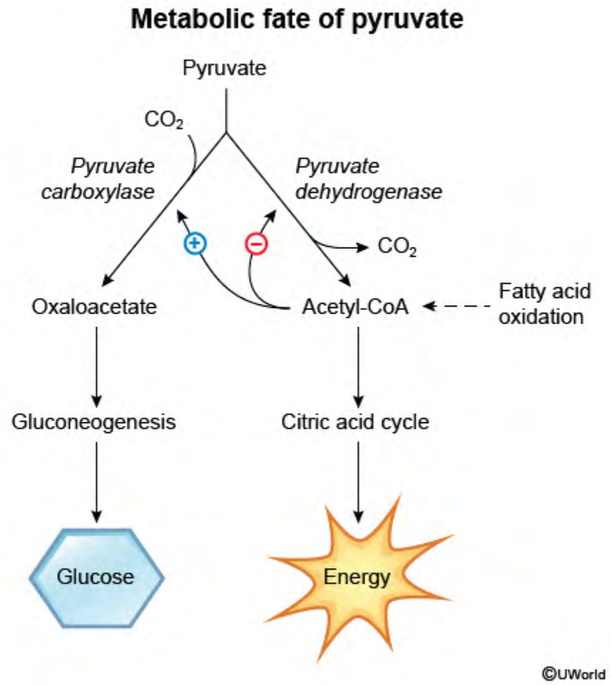

Zoom In | Zoom Out | Reset | New | Existing | My Notebook

https://t.me/USMLEWorldStep1

plays an essential role in carbohydrate, lipid, and amino acid metabolism. In the liver, the conversion of **pyruvate to oxaloacetate** for gluconeogenesis requires pyruvate carboxylase and biotin.

Biotin
levels
deficie
derma
acidos

(Choi
phosp

(Choi
lipoic a
absen

(Choi
revers
tissue.

(Choi
dehyd
of cofa

Educa
Biotin
reactio
avidin,
chang

Biochen
Subject

Exhibit Display

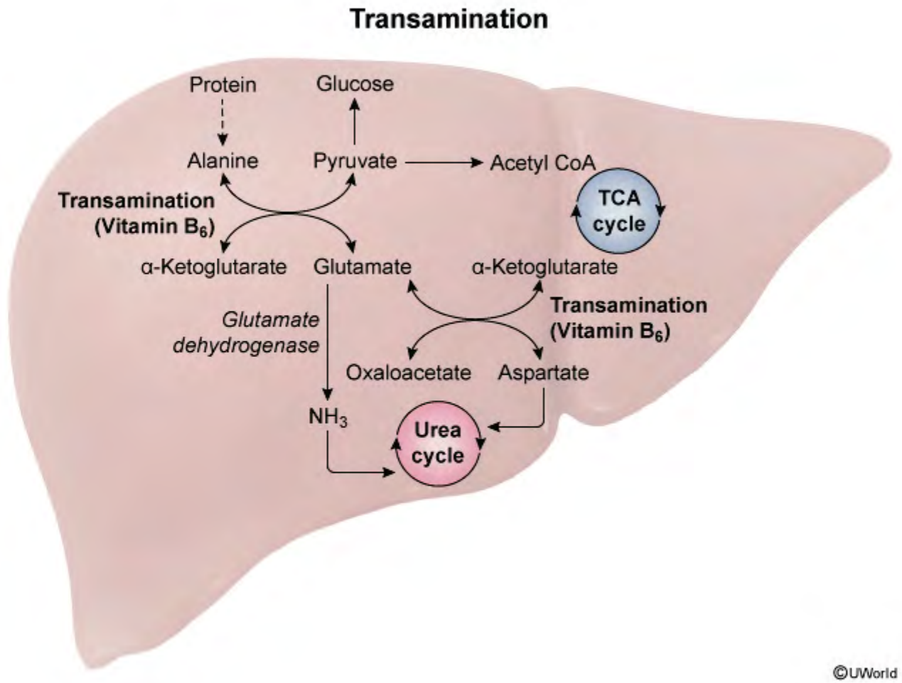

Zoom In | Zoom Out | Reset | New | Existing | My Notebook

Copyright © UWorld. All rights reserved.

https://t.me/USMLEWorldStep1

A 65-year-old man comes to the office due to progressive weight loss, jaundice, and anorexia over the last 3 months. His urine has been dark and his stools have been pale. The patient has no prior medical conditions and takes no medications. He has smoked a pack of cigarettes a day for 40 years. He drinks 2 cups of coffee every day and 1 or 2 glasses of wine on most nights. He used illicit drugs for 2 years when he was in his teens but has used none since. The patient has a sedentary lifestyle and frequently consumes red and processed meats. Vital signs are within normal limits. BMI is 28 kg/m^2. Physical examination shows scleral icterus. The chest is clear to auscultation and percussion. Abdominal examination shows an enlarged but nontender gallbladder. There is no ascites. Which of the following is the strongest factor predisposing to this patient's current condition?

- A. Alcohol use
- B. Cigarette smoking
- C. Coffee consumption
- D. Low-fiber diet
- E. Processed meat consumption
- F. Viral hepatitis

Submit

https://t.me/USMLEWorldStep1

A 65-year-old man comes to the office due to progressive weight loss, jaundice, and anorexia over the last 3 months. His urine has been dark and his stools have been pale. The patient has no prior medical conditions and takes no medications. He has smoked a pack of cigarettes a day for 40 years. He drinks 2 cups of coffee every day and 1 or 2 glasses of wine on most nights. He used illicit drugs for 2 years when he was in his teens but has used none since. The patient has a sedentary lifestyle and frequently consumes red and processed meats. Vital signs are within normal limits. BMI is 28 kg/m^2. Physical examination shows scleral icterus. The chest is clear to auscultation and percussion. Abdominal examination shows an enlarged but nontender gallbladder. There is no ascites. Which of the following is the strongest factor predisposing to this patient's current condition?

- ✗ A. Alcohol use (18%)
- ✓ B. Cigarette smoking (44%)
- C. Coffee consumption (0%)
- D. Low-fiber diet (3%)
- E. Processed meat consumption (9%)
- F. Viral hepatitis (23%)

Incorrect
Correct answer
B

44%
Answered correctly

12 mins, 10 secs
Time Spent

2023
Version

Explanation

Pancreatic adenocarcinoma	
	• Age≥65 • Smoking • Chronic pancreatitis

https://t.me/USMLEWorldStep1

Pancreatic adenocarcinoma	

Risk factors	• Age≥65
	• Smoking
	• Chronic pancreatitis
	• Genetic predisposition
	  ◦ Hereditary pancreatitis
	  ◦ Peutz-Jeghers syndrome
	  ◦ MEN syndromes
	  ◦ Hereditary nonpolyposis colon cancer

Clinical presentation	• Weight loss, anorexia • Abdominal/back pain or painless obstructive jaundice • Migratory thrombophlebitis • Hepatomegaly & ascites (with metastasis)

Pancreatic adenocarcinoma should be considered in any patient with painless **obstructive jaundice** (elevated bilirubin, dark urine, pale stools) and **weight loss**. Courvoisier sign (painless palpable gallbladder in a jaundiced patient) can also raise suspicion, although this can be seen in a number of conditions (eg, cholangiocarcinoma, hepatic duct obstruction). Symptoms of pancreatic malignancy vary with location; tumors at the pancreatic head typically produce obstructive symptoms due to compression of the common bile duct (CBD), whereas those in the body and tail do not obstruct the CBD and often produce midepigastric pain due to invasion of the splanchnic plexus.

Smoking is the most important environmental risk factor for pancreatic cancer and doubles the risk.

(Choice A) Alcohol consumption increases the risk of malignant tumors involving the head, neck, esophagus, and liver. Chronic alcohol consumption can cause chronic pancreatitis, but moderate alcohol use in the absence of chronic pancreatitis does not appear to confer any additional risk for pancreatic cancer.

(Choice C) Chronic, heavy intake of hot beverages is associated with increased risk for esophageal cancer, but

https://t.me/USMLEWorldStep1

presentation	• Migratory thrombophlebitis • Hepatomegaly & ascites (with metastasis)

Pancreatic adenocarcinoma should be considered in any patient with painless **obstructive jaundice** (elevated bilirubin, dark urine, pale stools) and **weight loss**. Courvoisier sign (painless palpable gallbladder in a jaundiced patient) can also raise suspicion, although this can be seen in a number of conditions (eg, cholangiocarcinoma, hepatic duct obstruction). Symptoms of pancreatic malignancy vary with location; tumors at the pancreatic head typically produce obstructive symptoms due to compression of the common bile duct (CBD), whereas those in the body and tail do not obstruct the CBD and often produce midepigastric pain due to invasion of the splanchnic plexus.

Smoking is the most important environmental risk factor for pancreatic cancer and doubles the risk.

(Choice A) Alcohol consumption increases the risk of malignant tumors involving the head, neck, esophagus, and liver. Chronic alcohol consumption can cause chronic pancreatitis, but moderate alcohol use in the absence of chronic pancreatitis does not appear to confer any additional risk for pancreatic cancer.

(Choice C) Chronic, heavy intake of hot beverages is associated with increased risk for esophageal cancer, but coffee intake does not increase the risk of pancreatic cancer.

(Choices D and E) A low-fiber diet and diets high in processed meats are associated with an increased risk of colon adenocarcinoma.

(Choice F) Chronic viral hepatitis B and C greatly increase the risk of hepatocellular carcinoma. They may increase the risk of pancreatic cancer, but only slightly.

Educational objective:
Smoking is the most important environmental risk factor for pancreatic cancer. Other risk factors include advanced age, chronic pancreatitis, and genetic predisposition (eg, Peutz-Jeghers syndrome).

References

- Alcohol intake and pancreatic cancer: A pooled analysis from the pancreatic cancer cohort consortium (PanScan).

https://t.me/USMLEWorldStep1

A 35-year-old woman comes to the office due to malaise and generalized weakness. The patient has type 1 diabetes mellitus and hypothyroidism for which she takes insulin and levothyroxine. She eats a balanced diabetic diet and exercises 5 times per week. Physical examination shows mild conjunctival pallor. Laboratory results are as follows:

Hemoglobin	10 g/dL
Mean corpuscular volume	118 μm^3
Folate, serum	9 ng/mL (normal: 2.5-20)
Vitamin B_{12}, serum	60 pg/mL (normal: 200-800)

Which of the following changes are most likely to be present in this patient?

	Serum gastrin	Gastric pH	Gastric parietal cell mass
A.	↑	↑	↑
B.	↑	↑	↓
C.	↑	↓	↑
D.	↓	↑	↑
E.	↓	↓	↓

Submit

https://t.me/USMLEWorldStep1

A 35-year-old woman comes to the office due to malaise and generalized weakness. The patient has type 1 diabetes mellitus and hypothyroidism for which she takes insulin and levothyroxine. She eats a balanced diabetic diet and exercises 5 times per week. Physical examination shows mild conjunctival pallor. Laboratory results are as follows:

Hemoglobin	10 g/dL
Mean corpuscular volume	118 μm^3
Folate, serum	9 ng/mL (normal: 2.5-20)
Vitamin B_{12}, serum	60 pg/mL (normal: 200-800)

Which of the following changes are most likely to be present in this patient?

	Serum gastrin	Gastric pH	Gastric parietal cell mass	
✗ A.	↑	↑	↑	(6%)
✓ B.	↑	↑	↓	(50%)
C.	↑	↓	↑	(19%)
D.	↓	↑	↑	(10%)
E.	↓	↓	↓	(13%)

Incorrect
Correct answer
B

50%
Answered correctly

03 secs
Time Spent

2023
Version

Explanation

https://t.me/USMLEWorldStep1

D. (10%)

E (13%)

Incc
Corre
B

Expl

Exhibit Display



Zoom In Zoom Out Reset New | Existing My Notebook

This p

deficiency. With a history of **autoimmune disease** (eg, type 1 diabetes mellitus, Hashimoto thyroiditis) and a balanced diet, the most likely cause is **pernicious anemia**. This autoimmune condition occurs as a result of a

https://t.me/USMLEWorldStep1

- Subacute combined degeneration

©UWorld

This patient with malaise, weakness, and conjunctival pallor has anemia due to **vitamin B_{12} (cobalamin) deficiency**. With a history of **autoimmune disease** (eg, type 1 diabetes mellitus, Hashimoto thyroiditis) and a balanced diet, the most likely cause is **pernicious anemia**. This autoimmune condition occurs as a result of a **$CD4^+$ cell–mediated immune response** against parietal cells in the body and fundus of the stomach; autoantibodies against parietal cell components are also produced in many patients but are less significant in the pathogenesis of disease.

Parietal cells normally produce hydrochloric acid and intrinsic factor. In pernicious anemia, progressive destruction of oxyntic (acid-producing) mucosa leads to **loss of gastric parietal cell mass**, resulting in:

- Decreased hydrochloric acid secretion (achlorhydria), which **increases gastric pH**. Increased gastric alkalinity provides positive feedback for the production of gastrin (which normally stimulates parietal cell acid release). As a result, patients with pernicious anemia have **elevated gastrin** levels **(Choices D and E)**.
- Decreased intrinsic factor secretion, which impairs absorption of dietary vitamin B_{12} in the terminal ileum. Vitamin B_{12} deficiency leads to **megaloblastic anemia**, as in this patient with an increased mean corpuscular volume, and subacute combined degeneration of the spinal cord.

(Choice A) Proton pump inhibitors increase gastric pH, which upregulates gastrin secretion. Prolonged use may result in secondary hypertrophy and hyperplasia of gastric parietal cells, a finding not seen in pernicious anemia.

(Choice C) Gastrinomas are gastrin-secreting tumors that typically develop in the pancreas and duodenum. Because parietal cells respond appropriately in this condition, the excess gastrin production results in parietal cell hypertrophy and increased hydrochloric acid secretion (ie, decreased gastric pH).

Educational objective:
Pernicious anemia is an autoimmune disease characterized by $CD4^+$ cell–mediated destruction of parietal cells. Because these cells normally produce hydrochloric acid, patients with pernicious anemia have elevated gastric pH, which upregulates gastrin secretion. Decreased parietal cell secretion of intrinsic factor also results in vitamin B_{12} deficiency (eg, megaloblastic anemia).

https://t.me/USMLEWorldStep1

deficiency. With a history of **autoimmune disease** (eg, type 1 diabetes mellitus, Hashimoto thyroiditis) and a balanced diet, the most likely cause is **pernicious anemia**. This autoimmune condition occurs as a result of a **$CD4^+$ cell–mediated immune response** against parietal cells in the body and fundus of the stomach; autoantibodies against parietal cell components are also produced in many patients but are less significant in the pathogenesis of disease.

Parietal cells normally produce hydrochloric acid and intrinsic factor. In pernicious anemia, progressive destruction of oxyntic (acid-producing) mucosa leads to **loss of gastric parietal cell mass**, resulting in:

- Decreased hydrochloric acid secretion (achlorhydria), which **increases gastric pH**. Increased gastric alkalinity provides positive feedback for the production of gastrin (which normally stimulates parietal cell acid release). As a result, patients with pernicious anemia have **elevated gastrin** levels **(Choices D and E)**.
- Decreased intrinsic factor secretion, which impairs absorption of dietary vitamin B_{12} in the terminal ileum. Vitamin B_{12} deficiency leads to **megaloblastic anemia**, as in this patient with an increased mean corpuscular volume, and subacute combined degeneration of the spinal cord.

(Choice A) Proton pump inhibitors increase gastric pH, which upregulates gastrin secretion. Prolonged use may result in secondary hypertrophy and hyperplasia of gastric parietal cells, a finding not seen in pernicious anemia.

(Choice C) Gastrinomas are gastrin-secreting tumors that typically develop in the pancreas and duodenum. Because parietal cells respond appropriately in this condition, the excess gastrin production results in parietal cell hypertrophy and increased hydrochloric acid secretion (ie, decreased gastric pH).

Educational objective:
Pernicious anemia is an autoimmune disease characterized by $CD4^+$ cell–mediated destruction of parietal cells. Because these cells normally produce hydrochloric acid, patients with pernicious anemia have elevated gastric pH, which upregulates gastrin secretion. Decreased parietal cell secretion of intrinsic factor also results in vitamin B_{12} deficiency (eg, megaloblastic anemia).

Pathophysiology	Gastrointestinal & Nutrition	Vitamin b12 deficiency
Subject	System	Topic

https://t.me/USMLEWorldStep1

- Subacute combined degeneration

Exhibit Display

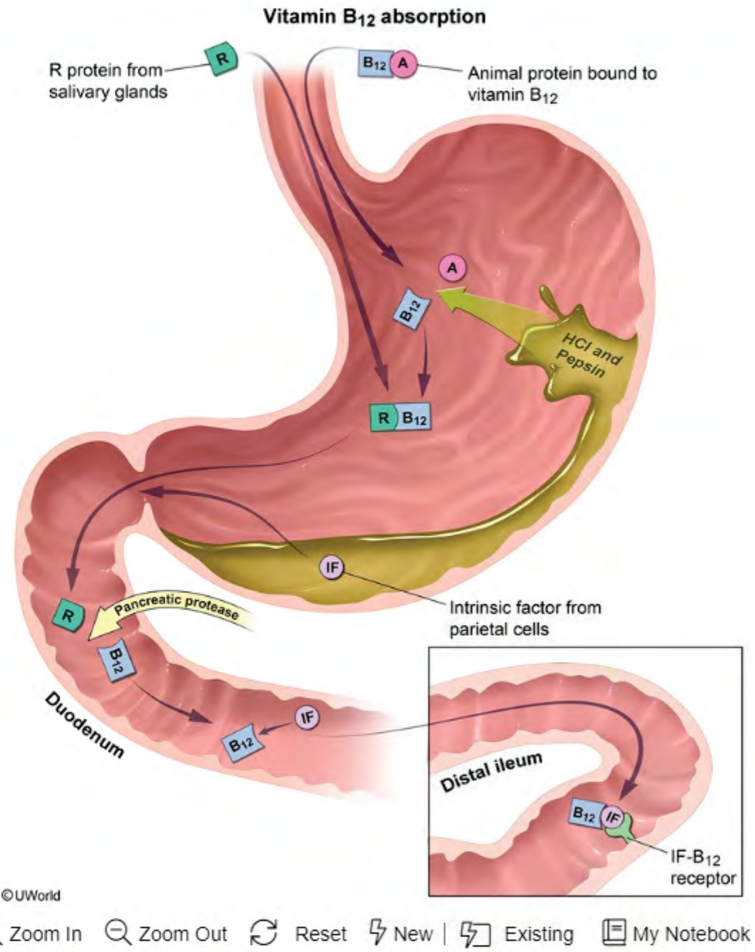

Zoom In | Zoom Out | Reset | New | Existing | My Notebook

This p
deficie
balanc
CD4⁺
autoar
pathog

Parieta
of oxy

- D
  a
  re
- D
  V
  v

(Choi
result

(Choi
Becau
hypert

Educa
Pernic
Becau
which upregulates gastrin secretion. Decreased parietal cell secretion of intrinsic factor also results in vitamin B_{12} deficiency (eg, megaloblastic anemia).

https://t.me/USMLEWorldStep1

A 23-year-old man comes to the physician due to a 2-month history of fatigue, malaise, and abdominal discomfort. He is found to have tender hepatomegaly with elevated liver function tests. The patient has never been vaccinated against hepatitis. He has had no raw or uncooked foods recently and recalls no ill contacts. There is no history of blood transfusion. The patient is a graduate student who immigrated to the United States 2 years ago and has not traveled outside the country since. He smokes 2 packs of cigarettes a day and consumes 1 or 2 bottles of beer on weekends. The patient does not use illicit drugs. He has had several episodes of unprotected sex with different female partners within the past year. Which of the following is most likely to be present in this patient?

- A. HAV in the stool
- B. Serum anti-HAV IgM
- C. Serum anti-HBsAg IgG
- D. Serum HBsAg
- E. Hepatitis C virus RNA viral load in blood
- F. Serum anti-hepatitis D virus IgG

Submit

https://t.me/USMLEWorldStep1

A 23-year-old man comes to the physician due to a 2-month history of fatigue, malaise, and abdominal discomfort. He is found to have tender hepatomegaly with elevated liver function tests. The patient has never been vaccinated against hepatitis. He has had no raw or uncooked foods recently and recalls no ill contacts. There is no history of blood transfusion. The patient is a graduate student who immigrated to the United States 2 years ago and has not traveled outside the country since. He smokes 2 packs of cigarettes a day and consumes 1 or 2 bottles of beer on weekends. The patient does not use illicit drugs. He has had several episodes of unprotected sex with different female partners within the past year. Which of the following is most likely to be present in this patient?

- A. HAV in the stool (0%)
- ✗ B. Serum anti-HAV IgM (1%)
- C. Serum anti-HBsAg IgG (7%)
- ✓ D. Serum HBsAg (79%)
- E. Hepatitis C virus RNA viral load in blood (10%)
- F. Serum anti-hepatitis D virus IgG (0%)

Incorrect
Correct answer
D

79%
Answered correctly

04 secs
Time Spent

2023
Version

Explanation

The main modes of transmission of **hepatitis B virus (HBV)** are sexual (transmission among heterosexual partners and among men who have sex with men) and percutaneous (eg, intravenous drug use, needlestick accidents, blood transfusions). Vertical (mother-to-child) transmission is common in high-prevalence areas. This **unvaccinated** patient with tender hepatomegaly and liver function abnormalities most likely has acute HBV infection contracted during an episode of **unprotected sex** (most common mode of transmission in developed countries, >70% of cases). Serum hepatitis B surface antigen (HBsAg) would be present.

https://t.me/USMLEWorldStep1

Explanation

The main modes of transmission of **hepatitis B virus (HBV)** are sexual (transmission among heterosexual partners and among men who have sex with men) and percutaneous (eg, intravenous drug use, needlestick accidents, blood transfusions). Vertical (mother-to-child) transmission is common in high-prevalence areas. This **unvaccinated** patient with tender hepatomegaly and liver function abnormalities most likely has acute HBV infection contracted during an episode of **unprotected sex** (most common mode of transmission in developed countries, >70% of cases). Serum hepatitis B surface antigen (HBsAg) would be present.

Anti-HBsAg immunoglobulin G (IgG) appears after either successful HBV vaccination or HBsAg clearance and remains detectable for life (indicator of non-infectivity and immunity). Because this patient is symptomatic, he obviously has not cleared the virus and would likely not yet have anti-HBsAg IgG **(Choice C)**.

(Choices A and B) Hepatitis A virus (HAV) in the stool or serum anti-HAV IgM would be expected with acute HAV following recent travel to an endemic area or consumption of tainted, insufficiently heated food (eg, oysters). HAV (fecal-oral transmission) is not usually symptomatic for 2 months and is not associated with a chronic carrier state.

(Choice E) Hepatitis C virus (HCV) infection is most often asymptomatic. Also, most HCV transmission occurs in the setting of intravenous drug use. Sexual transmission of HCV can occur but is inefficient; the risk is actually low (eg, incidence of 0.07% per year in a study of 500 heterosexual couples) and would be lower than that of HBV transmission.

(Choice F) Hepatitis D virus (HDV) transmission occurs primarily through inoculations and blood transfusions, with sexual transmission far less common. Co-infection with HBV or superinfection of chronic HBV is necessary. Globally, only about 5% of HBV carriers also have HDV (rates vary based on geography).

Educational objective:
The main modes of transmission of hepatitis B virus include sexual (among both heterosexual partners and men who have sex with men) and percutaneous (eg, intravenous drug use, needlestick accidents, blood transfusions). The risk of sexual transmission of hepatitis C virus is low.

Microbiology Gastrointestinal & Nutrition Hepatitis b

https://t.me/USMLEWorldStep1

A 57-year-old man with a history of alcohol-induced cirrhosis is brought to the emergency department due to altered mental status. Over the weekend, he ate a lot of smoked meats at a local barbecue competition. Since then, he has been sleeping most of the day and is confused and disoriented when awake. On examination, he has abdominal distension with shifting dullness. The patient answers correctly when asked for his name but does not know that he is in the hospital and says the year is "1997." When asked to extend his hands as if stopping traffic, the patient makes rhythmic flapping movements. He is started on rifaximin. Which of the following is the most likely mechanism of action of this drug when used to treat this patient's current condition?

- A. Binding of dietary phosphate
- B. Decreased intraluminal ammonia production
- C. Exchange of intraluminal sodium ions for potassium ions
- D. Formation of a nonabsorbable complex with bile acids
- E. Increased conversion of ammonia to ammonium ion

Submit

https://t.me/USMLEWorldStep1

A 57-year-old man with a history of alcohol-induced cirrhosis is brought to the emergency department due to altered mental status. Over the weekend, he ate a lot of smoked meats at a local barbecue competition. Since then, he has been sleeping most of the day and is confused and disoriented when awake. On examination, he has abdominal distension with shifting dullness. The patient answers correctly when asked for his name but does not know that he is in the hospital and says the year is "1997." When asked to extend his hands as if stopping traffic, the patient makes rhythmic flapping movements. He is started on rifaximin. Which of the following is the most likely mechanism of action of this drug when used to treat this patient's current condition?

- ✗ A. Binding of dietary phosphate (1%)
- ✓ B. Decreased intraluminal ammonia production (47%)
- C. Exchange of intraluminal sodium ions for potassium ions (1%)
- D. Formation of a nonabsorbable complex with bile acids (3%)
- E. Increased conversion of ammonia to ammonium ion (45%)

Incorrect
Correct answer
B

47%
Answered correctly

03 secs
Time Spent

2023
Version

Explanation

This patient likely has **hepatic encephalopathy** (HE), a neurologic complication of **cirrhosis** due in part to the liver's inability to convert **ammonia** (a neurotoxin) to urea. Excess ammonia is shunted past the liver and crosses the blood-brain barrier, leading to **altered mental status** (thought due to impaired neurotransmitter release, astrocyte dysfunction, neuroinflammation, and/or edema). Asterixis, the rhythmic flapping of dorsiflexed hands, is another common manifestation of HE.

A primary source of ammonia is degradation of nitrogen products by intestinal bacteria. Therefore, **gastrointestinal (GI) bleeding** can precipitate HE as hemoglobin breakdown leads to increased nitrogen products

https://t.me/USMLEWorldStep1

This patient likely has **hepatic encephalopathy** (HE), a neurologic complication of **cirrhosis** due in part to the liver's inability to convert **ammonia** (a neurotoxin) to urea. Excess ammonia is shunted past the liver and crosses the blood-brain barrier, leading to **altered mental status** (thought due to impaired neurotransmitter release, astrocyte dysfunction, neuroinflammation, and/or edema). Asterixis, the rhythmic flapping of dorsiflexed hands, is another common manifestation of HE.

A primary source of ammonia is degradation of nitrogen products by intestinal bacteria. Therefore, **gastrointestinal (GI) bleeding** can precipitate HE as hemoglobin breakdown leads to increased nitrogen products in the gut. **Excess dietary protein intake** (eg, large steak meal) is another common trigger. Others include infection, sedatives, and metabolic derangements (eg, hypokalemia).

Rifaximin is a nonabsorbable antibiotic that alters GI flora to decrease intestinal production and absorption of ammonia. In patients with HE, rifaximin is generally used in addition to **lactulose**, which is catabolized by intestinal bacterial flora to short chain fatty acids, lowering the colonic pH and increasing conversion of ammonia to ammonium **(Choice E)**. Rifaximin is also sometimes used for traveler's diarrhea, as it inhibits bacterial RNA synthesis through binding with DNA-dependent RNA polymerase.

(Choices A and C) Phosphate binders (eg, calcium acetate) lower serum phosphate in patients with end-stage renal disease. Sodium polystyrene resin (eg, sodium polystyrene sulfonate) exchanges intraluminal sodium for potassium ions and can lower serum potassium in patients with hyperkalemia. However, neither effectively treats HE.

(Choice D) Bile acid sequestrants (cholestyramine, colestipol) bind intestinal bile acids to lower serum cholesterol, but they are not used for treating HE.

Educational objective:
Treatments for hepatic encephalopathy include lactulose (increases conversion of ammonia to ammonium) and rifaximin (decreases intraluminal ammonia production).

References

- Treatment options for hepatic encephalopathy.

https://t.me/USMLEWorldStep1

A 74-year-old man comes to the office due to several months of choking spells, dysphagia, and cough. He has also had recurrent episodes of pneumonia. His other medical problems include hypertension and osteoarthritis. Blood pressure is 130/70 mm Hg. The patient has foul-smelling breath, but his oropharyngeal and neck examinations are normal. Cardiopulmonary examination is also normal. A barium swallow study is performed and reveals an abnormality in the upper esophagus, as shown in the image below.

Which of the following mechanisms is the most likely cause of his symptoms?

- A. Cricopharyngeal motor dysfunction
- B. Degenerative changes of the myenteric plexus
- C. Increased intraluminal pressure in the stomach
- D. Retention cyst due to duct obstruction
- E. Scarring and traction of the esophagus

Submit

https://t.me/USMLEWorldStep1

A 74-year-old man comes to the office due to several months of choking spells, dysphagia, and cough. He has also h
Blood
exami
reveal

Exhibit Display

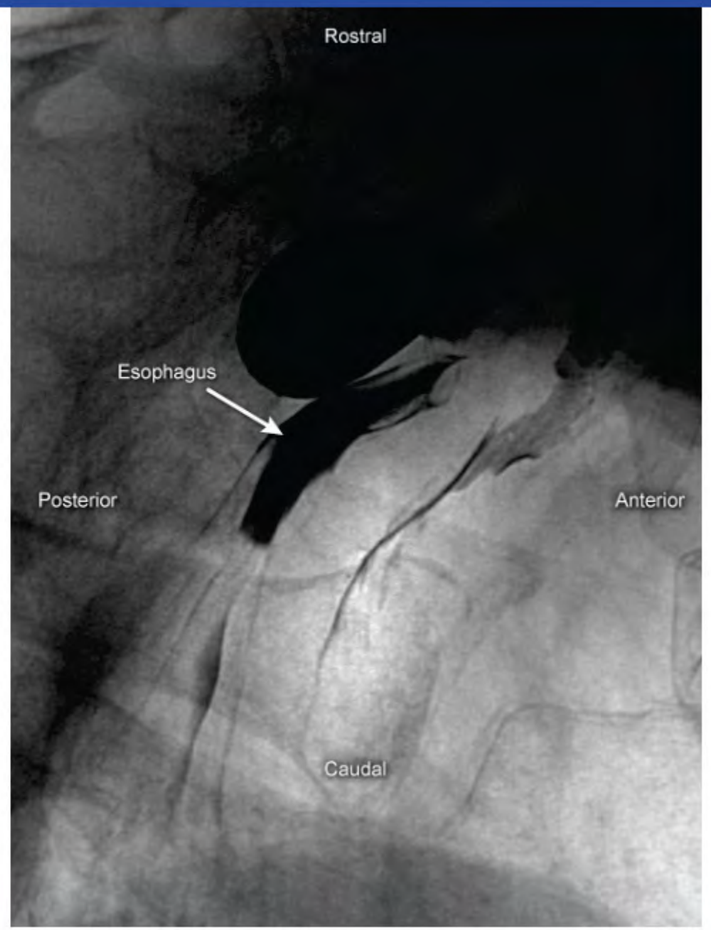

Zoom In Zoom Out Reset New | Existing My Notebook

https://t.me/USMLEWorldStep1

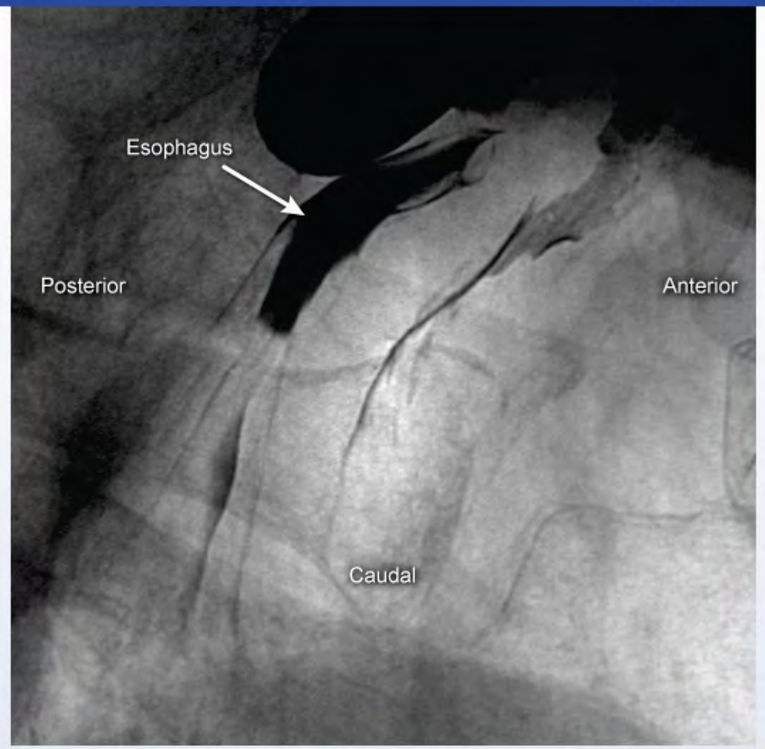

Which of the following mechanisms is the most likely cause of his symptoms?

- A. Cricopharyngeal motor dysfunction
- B. Degenerative changes of the myenteric plexus
- C. Increased intraluminal pressure in the stomach
- D. Retention cyst due to duct obstruction
- E. Scarring and traction of the esophagus

Submit

https://t.me/USMLEWorldStep1

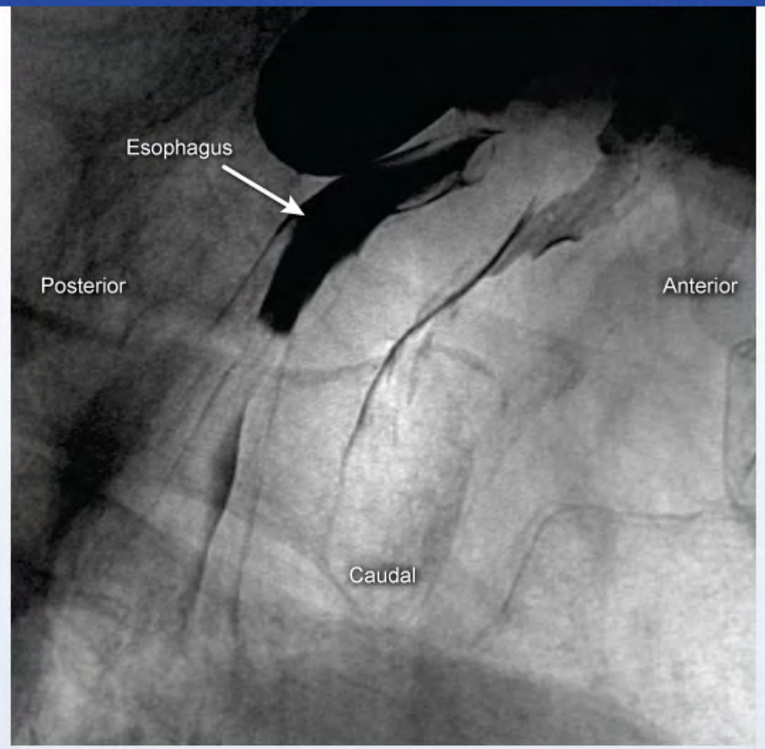

Which of the following mechanisms is the most likely cause of his symptoms?

- ✓ A. Cricopharyngeal motor dysfunction (44%)
- ✗ B. Degenerative changes of the myenteric plexus (16%)
- C. Increased intraluminal pressure in the stomach (5%)
- D. Retention cyst due to duct obstruction (15%)
- E. Scarring and traction of the esophagus (17%)

Incorrect
Correct answer
A

44%
Answered correctly

40 secs
Time Spent

2023
Version

https://t.me/USMLEWorldStep1

D. Retention cyst due to duct obstruction (15%)

Exhibit Display

Zenker diverticulum

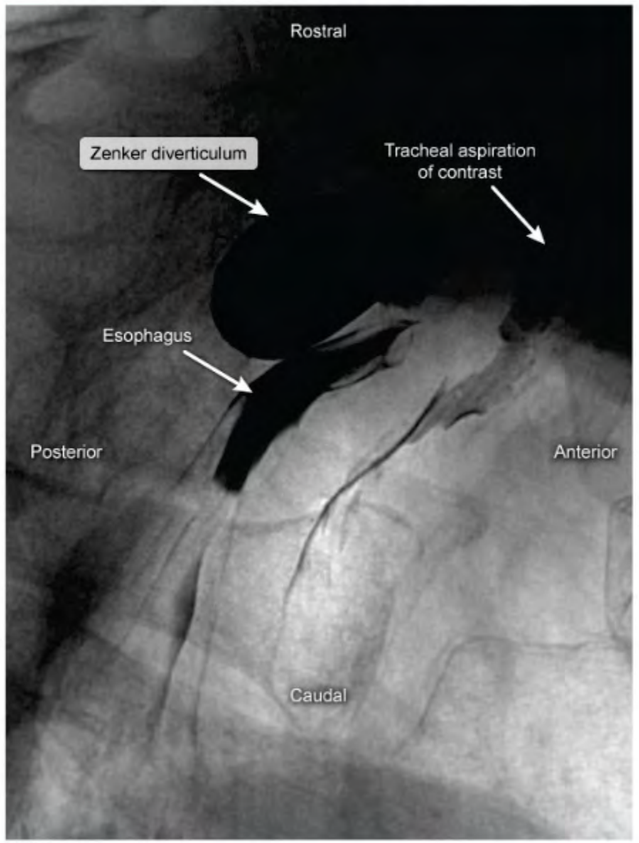

©UWorld

Zoom In | Zoom Out | Reset | New | Existing | My Notebook

https://t.me/USMLEWorldStep1

©UWorld

Deglutition (swallowing) is a complex process that involves 3 phases:

1. In the voluntary oral phase, the food bolus is collected in the back of the mouth and lifted upward to the posterior wall of the pharynx.
2. This initiates the pharyngeal phase, which consists of involuntary pharyngeal muscle contractions that propel the food bolus to the esophagus.
3. During the esophageal phase, food stretches the walls of the esophagus, stimulating peristalsis just above the site of distension and moving the food downward. Relaxation of the lower esophageal sphincter (LES) follows, allowing the food bolus to enter the stomach.

Abnormal spasm or diminished relaxation of the cricopharyngeal muscles during swallowing (**cricopharyngeal motor dysfunction**) is thought to be the underlying mechanism of Zenker diverticulum formation. This process results in early **oropharyngeal dysphagia** with a feeling of food obstruction at the level of the neck and coughing/choking. Increased oropharyngeal intraluminal pressure eventually results in herniation of the pharyngeal mucosa through a zone of muscle weakness (false diverticulum) in the posterior hypopharynx (Killian triangle). Patients consequently develop food retention with **halitosis/regurgitation**. **Pulmonary aspiration** of diverticular contents may also lead to recurrent pneumonia. As the diverticulum enlarges, it may become palpable as a lateral neck mass, and dysphagia can worsen due to luminal narrowing caused by extrinsic esophageal compression.

(Choice B) Degenerative changes of the myenteric plexus with impaired LES relaxation result in achalasia. Barium swallow typically shows esophageal dilation with esophagogastric junction narrowing ("bird's beak").

(Choice C) Mucosal tears around the gastroesophageal junction can be caused by increased intraluminal pressure in the stomach during prolonged or recurrent retching/vomiting (Mallory-Weiss syndrome).

(Choice D) Retention cysts form due to accumulation of trapped secretions following obstruction of a gland's duct. Chronic rhinosinusitis frequently causes mucus retention cysts in the maxillary sinus.

(Choice E) Mediastinal lymphadenitis (eg, due to tuberculosis, fungal infections) can cause scarring/traction of the mid-portion of the esophagus, resulting in the formation of true diverticula (containing all gut wall layers).

https://t.me/USMLEWorldStep1

3. During the esophageal phase, food stretches the walls of the esophagus, stimulating peristalsis just above the site of distension and moving the food downward. Relaxation of the lower esophageal sphincter (LES) follows, allowing the food bolus to enter the stomach.

Abnormal spasm or diminished relaxation of the cricopharyngeal muscles during swallowing (**cricopharyngeal motor dysfunction**) is thought to be the underlying mechanism of Zenker diverticulum formation. This process results in early **oropharyngeal dysphagia** with a feeling of food obstruction at the level of the neck and coughing/choking. Increased oropharyngeal intraluminal pressure eventually results in herniation of the pharyngeal mucosa through a zone of muscle weakness (false diverticulum) in the posterior hypopharynx (Killian triangle). Patients consequently develop food retention with **halitosis/regurgitation**. **Pulmonary aspiration** of diverticular contents may also lead to recurrent pneumonia. As the diverticulum enlarges, it may become palpable as a lateral neck mass, and dysphagia can worsen due to luminal narrowing caused by extrinsic esophageal compression.

(Choice B) Degenerative changes of the myenteric plexus with impaired LES relaxation result in achalasia. Barium swallow typically shows esophageal dilation with esophagogastric junction narrowing ("bird's beak").

(Choice C) Mucosal tears around the gastroesophageal junction can be caused by increased intraluminal pressure in the stomach during prolonged or recurrent retching/vomiting (Mallory-Weiss syndrome).

(Choice D) Retention cysts form due to accumulation of trapped secretions following obstruction of a gland's duct. Chronic rhinosinusitis frequently causes mucus retention cysts in the maxillary sinus.

(Choice E) Mediastinal lymphadenitis (eg, due to tuberculosis, fungal infections) can cause scarring/traction of the mid-portion of the esophagus, resulting in the formation of true diverticula (containing all gut wall layers).

Educational objective:
Diminished relaxation of cricopharyngeal muscles during swallowing results in increased intraluminal pressure in the oropharynx. This may eventually cause the mucosa to herniate through a zone of muscle weakness in the posterior hypopharynx, forming a Zenker (false) diverticulum, which presents in elderly patients with oropharyngeal dysphagia, halitosis, regurgitation, and recurrent aspiration.

References

https://t.me/USMLEWorldStep1

3. During the esophageal phase, food stretches the walls of the esophagus, stimulating peristalsis just above the
si
fo

Abnor
motor
results
cough
pharyn
triangl
diverti
as a la
compr

(Choi
Bariun

(Choi
pressu

(Choi
duct.

(Choi
mid-po

Educa
Dimini
the orc
poster
dysphagia, halitosis, regurgitation, and recurrent aspiration.

References

Exhibit Display

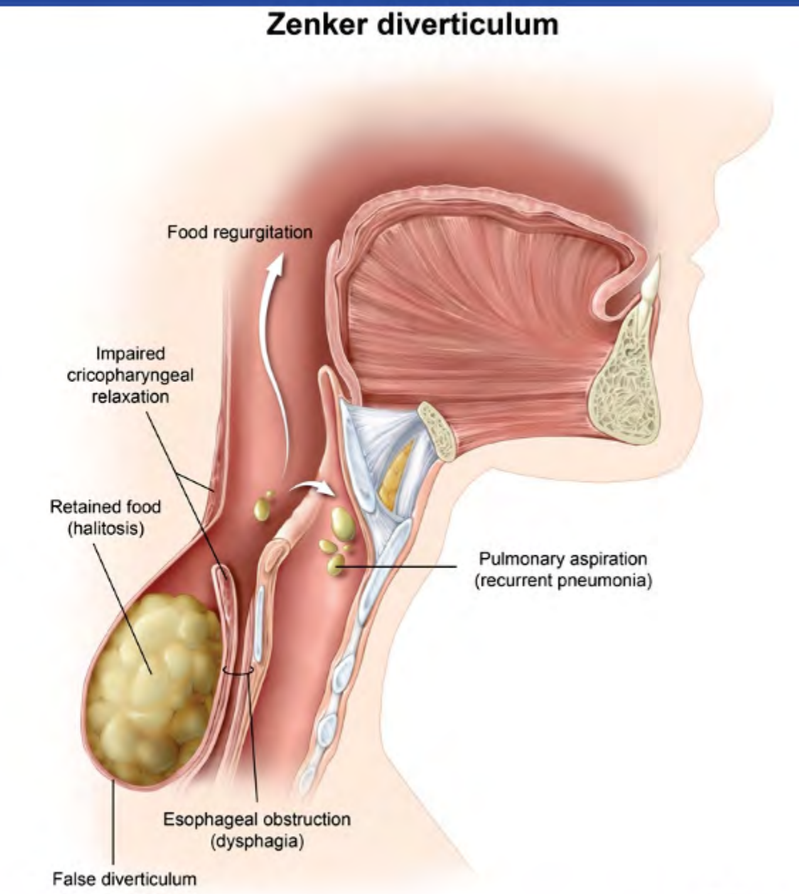

Zoom In | Zoom Out | Reset | New | Existing | My Notebook

https://t.me/USMLEWorldStep1

3. During the esophageal phase, food stretches the walls of the esophagus, stimulating peristalsis just above the
si
fo

Abnor
motor
results
cough
pharyn
triangl
diverti
as a la
compr

(Choi
Bariun

(Choi
pressu

(Choi
duct.

(Choi
mid-po

Educa
Dimini
the orc
poster
dysphagia, halitosis, regurgitation, and recurrent aspiration.

References

Exhibit Display

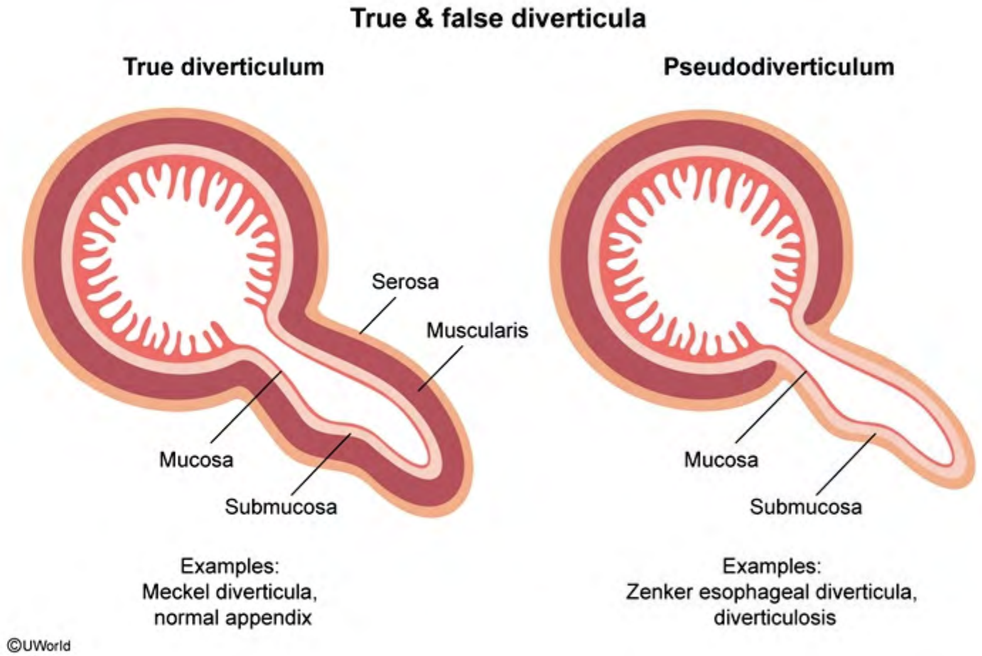

Zoom In | Zoom Out | Reset | New | Existing | My Notebook

https://t.me/USMLEWorldStep1

3. During the esophageal phase, food stretches the walls of the esophagus, stimulating peristalsis just above the
si
fo

Abnor
motor
result
cough
pharyn
triangl
diverti
as a la
compr

(Choi
Bariun

(Choi
pressu

(Choi
duct.

(Choi
mid-po

Educa
Dimini
the orc
poster
dysphagia, halitosis, regurgitation, and recurrent aspiration.

References

Exhibit Display

Achalasia

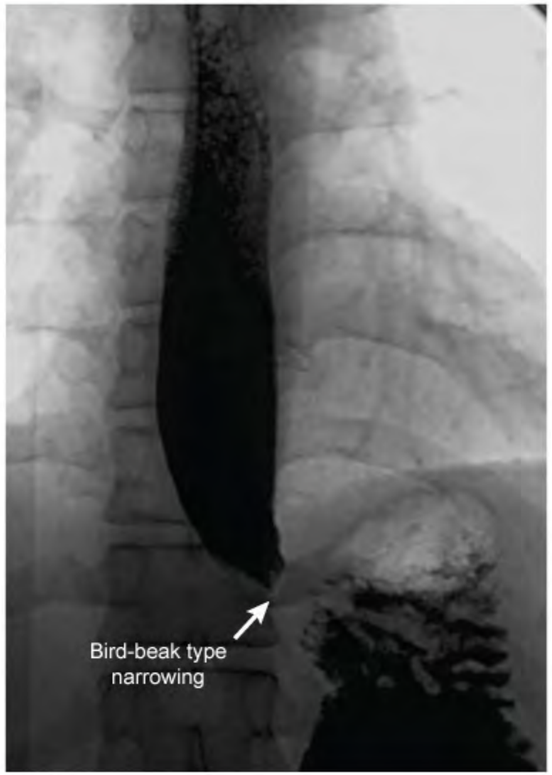

©UWorld

Zoom In | Zoom Out | Reset | New | Existing | My Notebook

https://t.me/USMLEWorldStep1

A 38-year-old man comes to the office with abdominal discomfort and loose stools over the past year. He has also lost 10 kg (22 lb) despite having a normal appetite. The patient eats a balanced diet that includes a variety of fruits and vegetables, meats, whole grains, and dairy products. He has had no international travel, works indoors as an office manager, and has no sick contacts. Medical history is insignificant and the patient takes no medications. The patient drinks alcohol socially and does not use tobacco. Vital signs and physical examination are normal. Serum chemistry panel, complete blood count, and thyroid function tests are normal. Which of the following is the best next step for assessing for impaired nutrient absorption in this patient?

- A. Abdominal ultrasound
- B. Colonoscopy
- C. Jejunal biopsy
- D. Stool evaluation for ova and parasites
- E. Stool microscopy with Sudan III stain
- F. Vitamin B_{12} level

Submit

https://t.me/USMLEWorldStep1

A 38-year-old man comes to the office with abdominal discomfort and loose stools over the past year. He has also lost 10 kg (22 lb) despite having a normal appetite. The patient eats a balanced diet that includes a variety of fruits and vegetables, meats, whole grains, and dairy products. He has had no international travel, works indoors as an office manager, and has no sick contacts. Medical history is insignificant and the patient takes no medications. The patient drinks alcohol socially and does not use tobacco. Vital signs and physical examination are normal. Serum chemistry panel, complete blood count, and thyroid function tests are normal. Which of the following is the best next step for assessing for impaired nutrient absorption in this patient?

- A. Abdominal ultrasound (4%)
- ✗ B. Colonoscopy (19%)
- C. Jejunal biopsy (29%)
- D. Stool evaluation for ova and parasites (9%)
- ✓ E. Stool microscopy with Sudan III stain (27%)
- F. Vitamin B_{12} level (9%)

Incorrect
Correct answer
E

27%
Answered correctly

04 secs
Time Spent

2023
Version

Explanation

Impaired intestinal absorption of nutrients is called **malabsorption**. Significant malabsorption may present with diarrhea and **steatorrhea** (bulky, foul-smelling stools; visible oil droplets; greasy toilet ring), but more often patients have nonspecific symptoms such as weight loss, fatigue, or vague abdominal discomfort. Patients may also have characteristic findings due to specific nutrient deficiencies. Generalized malabsorption is commonly due to defects in pancreatic secretion (eg, chronic pancreatitis, cystic fibrosis), mucosal disorders (eg, celiac disease, inflammatory bowel disease), bacterial overgrowth (eg, gastrointestinal surgery, abnormal motility), or parasitic

https://t.me/USMLEWorldStep1

Explanation

Impaired intestinal absorption of nutrients is called **malabsorption**. Significant malabsorption may present with diarrhea and **steatorrhea** (bulky, foul-smelling stools; visible oil droplets; greasy toilet ring), but more often patients have nonspecific symptoms such as weight loss, fatigue, or vague abdominal discomfort. Patients may also have characteristic findings due to specific nutrient deficiencies. Generalized malabsorption is commonly due to defects in pancreatic secretion (eg, chronic pancreatitis, cystic fibrosis), mucosal disorders (eg, celiac disease, inflammatory bowel disease), bacterial overgrowth (eg, gastrointestinal surgery, abnormal motility), or parasitic diseases (eg, *Giardia*).

Dietary lipids are the macronutrient with the most complex digestive pathway. Fats are typically the earliest and most severely affected nutrient in generalized malabsorption, and **testing for fat** malabsorption is therefore the **most sensitive** strategy for screening for malabsorptive disorders. A qualitative assay of stool with **Sudan III stain** can quickly and easily identify unabsorbed fat and confirm malabsorption. (Stool should normally contain no measurable fat.)

(Choices A, B, C, and D) Abdominal imaging can be used to identify thickening of the bowel wall due to inflammation or structural disorders of the pancreas (eg, chronic pancreatitis). Endoscopy with jejunal biopsy can diagnose celiac disease, and colonoscopy can identify inflammatory bowel disease. Stool inspection for ova and parasites can identify infectious causes of malabsorption such as *Giardia* and *Cryptosporidium*. Although these tests are useful for determining **specific causes** of generalized malabsorption, fecal fat testing is a less invasive and more sensitive test for confirming malabsorption of any etiology.

(Choice F) Iron and vitamin B_{12} deficiency occur commonly in patients with malabsorption. However, vitamin B_{12} levels have a low sensitivity for malabsorption; deficiency develops only after years and is more common with specific etiologies (eg, pernicious anemia). In addition, this patient's normal complete blood count makes vitamin B_{12} deficiency less likely.

Educational objective:
Malabsorption is a syndrome of impaired intestinal digestion and absorption. Fats are typically the most severely affected macronutrient in generalized malabsorption, and testing the stool for fat (eg, with Sudan III stain) is the

https://t.me/USMLEWorldStep1

diarrhea and **steatorrhea** (bulky, foul-smelling stools; visible oil droplets; greasy toilet ring), but more often patients have nonspecific symptoms such as weight loss, fatigue, or vague abdominal discomfort. Patients may also have characteristic findings due to specific nutrient deficiencies. Generalized malabsorption is commonly due to defects in pancreatic secretion (eg, chronic pancreatitis, cystic fibrosis), mucosal disorders (eg, celiac disease, inflammatory bowel disease), bacterial overgrowth (eg, gastrointestinal surgery, abnormal motility), or parasitic diseases (eg, *Giardia*).

Dietary lipids are the macronutrient with the most complex digestive pathway. Fats are typically the earliest and most severely affected nutrient in generalized malabsorption, and **testing for fat** malabsorption is therefore the **most sensitive** strategy for screening for malabsorptive disorders. A qualitative assay of stool with **Sudan III stain** can quickly and easily identify unabsorbed fat and confirm malabsorption. (Stool should normally contain no measurable fat.)

(Choices A, B, C, and D) Abdominal imaging can be used to identify thickening of the bowel wall due to inflammation or structural disorders of the pancreas (eg, chronic pancreatitis). Endoscopy with jejunal biopsy can diagnose celiac disease, and colonoscopy can identify inflammatory bowel disease. Stool inspection for ova and parasites can identify infectious causes of malabsorption such as *Giardia* and *Cryptosporidium*. Although these tests are useful for determining **specific causes** of generalized malabsorption, fecal fat testing is a less invasive and more sensitive test for confirming malabsorption of any etiology.

(Choice F) Iron and vitamin B_{12} deficiency occur commonly in patients with malabsorption. However, vitamin B_{12} levels have a low sensitivity for malabsorption; deficiency develops only after years and is more common with specific etiologies (eg, pernicious anemia). In addition, this patient's normal complete blood count makes vitamin B_{12} deficiency less likely.

Educational objective:
Malabsorption is a syndrome of impaired intestinal digestion and absorption. Fats are typically the most severely affected macronutrient in generalized malabsorption, and testing the stool for fat (eg, with Sudan III stain) is the most sensitive strategy for screening for malabsorptive disorders.

Pathophysiology | Gastrointestinal & Nutrition | Malabsorption

https://t.me/USMLEWorldStep1

diarrhea and **steatorrhea** (bulky, foul-smelling stools; visible oil droplets; greasy toilet ring), but more often patients have r
charac
in pan
inflam
diseas

Dietar
most s
most
can qu
measu

(Choi
inflam
diagno
parasi
tests a
and m

(Choi
levels
specifi
B_{12} det

Educa
Malab
affecte
most s

Exhibit Display

Nutrient deficiencies associated with malabsorption	
Nutrient	**Clinical presentation**
Protein	Muscle wasting, edema
Fat	Weight loss
Iron **Folate** **Vitamin B_{12}**	Anemia
Calcium **Vitamin D**	Bone pain, muscle weakness, tetany
Vitamin A	Hyperkeratosis, night blindness
Vitamin K	Petechiae, easy bruising

New | Existing | My Notebook

Pathophysiology | Gastrointestinal & Nutrition | Malabsorption

https://t.me/USMLEWorldStep1

A 40-year-old woman comes to the office due to recurrent episodes of postprandial abdominal pain. The pain is in the right upper quadrant and is associated with nausea. The patient has no fever, jaundice, or loss of appetite. Other medical conditions include obstructive sleep apnea and obesity. The patient takes no medications. She has never had any surgeries. She does not use tobacco, alcohol, or illicit drugs. The patient is afebrile. Blood pressure is 140/90 mm Hg. BMI is 38 kg/m^2. Examination shows tenderness in the right upper quadrant. Abdominal ultrasound demonstrates multiple gallstones. A gross specimen obtained from laparoscopic cholecystectomy is shown in the image below:

Which of the following is the most likely mechanism responsible for gallstone formation in this patient?

- A. Altered enterohepatic cycling of bilirubin
- B. Decreased bile acid synthesis
- C. Delayed gallbladder emptying
- D. Increased cholesterol synthesis
- E. Increased efflux of bilirubin into bile

Submit

https://t.me/USMLEWorldStep1

A 40-year-old woman comes to the office due to recurrent episodes of postprandial abdominal pain. The pain is in the rig
Other
never
pressu
Abdon
cholec

Exhibit Display

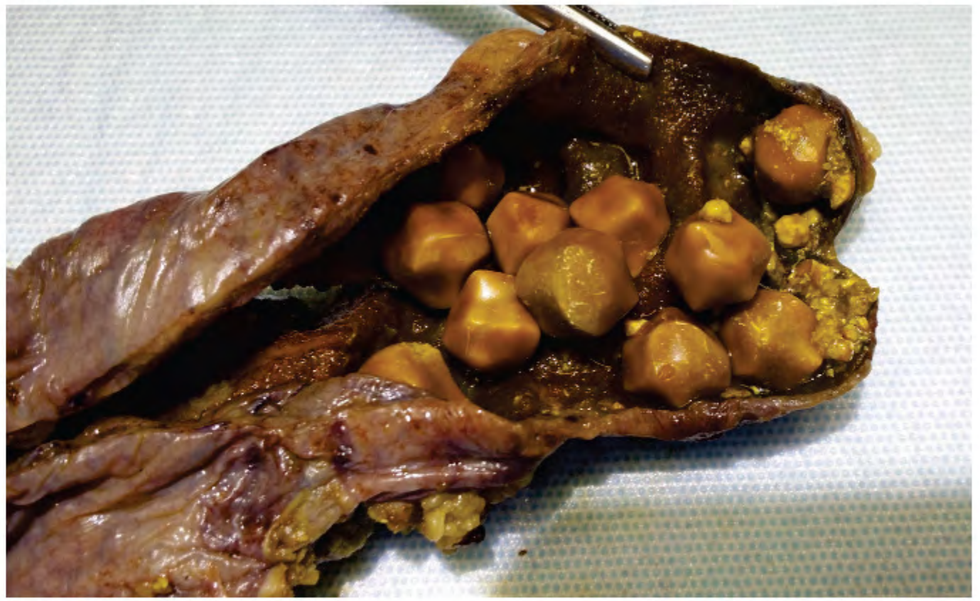

Zoom In Zoom Out Reset New | Existing My Notebook

Which

C. Delayed gallbladder emptying
D. Increased cholesterol synthesis

https://t.me/USMLEWorldStep1

pressure is 140/90 mm Hg. BMI is 38 kg/m². Examination shows tenderness in the right upper quadrant. Abdominal ultrasound demonstrates multiple gallstones. A gross specimen obtained from laparoscopic cholecystectomy is shown in the image below:

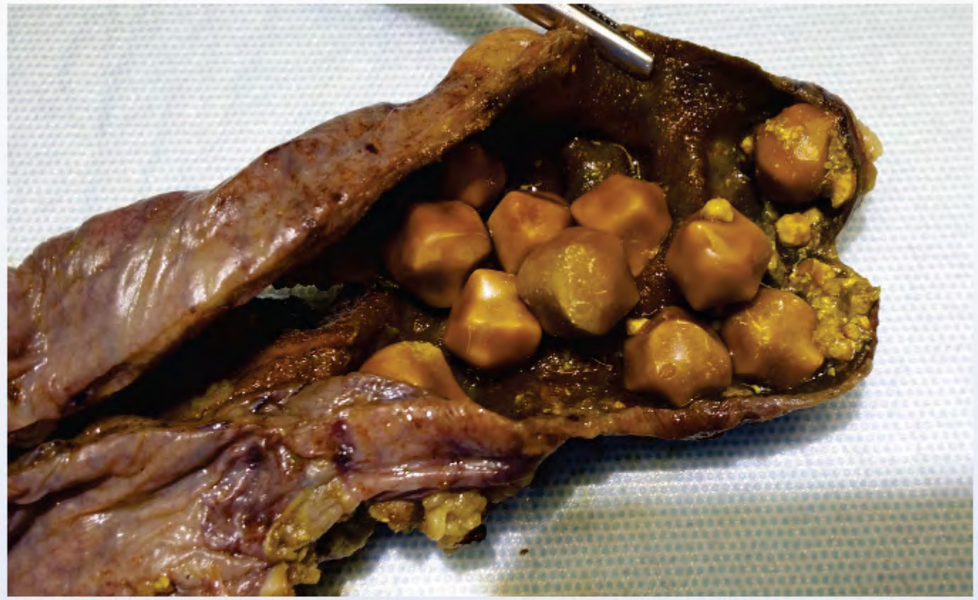

Which of the following is the most likely mechanism responsible for gallstone formation in this patient?

- A. Altered enterohepatic cycling of bilirubin
- B. Decreased bile acid synthesis
- C. Delayed gallbladder emptying
- D. Increased cholesterol synthesis
- E. Increased efflux of bilirubin into bile

Submit

https://t.me/USMLEWorldStep1

pressure is 140/90 mm Hg. BMI is 38 kg/m². Examination shows tenderness in the right upper quadrant. Abdominal ultrasound demonstrates multiple gallstones. A gross specimen obtained from laparoscopic cholecystectomy is shown in the image below:

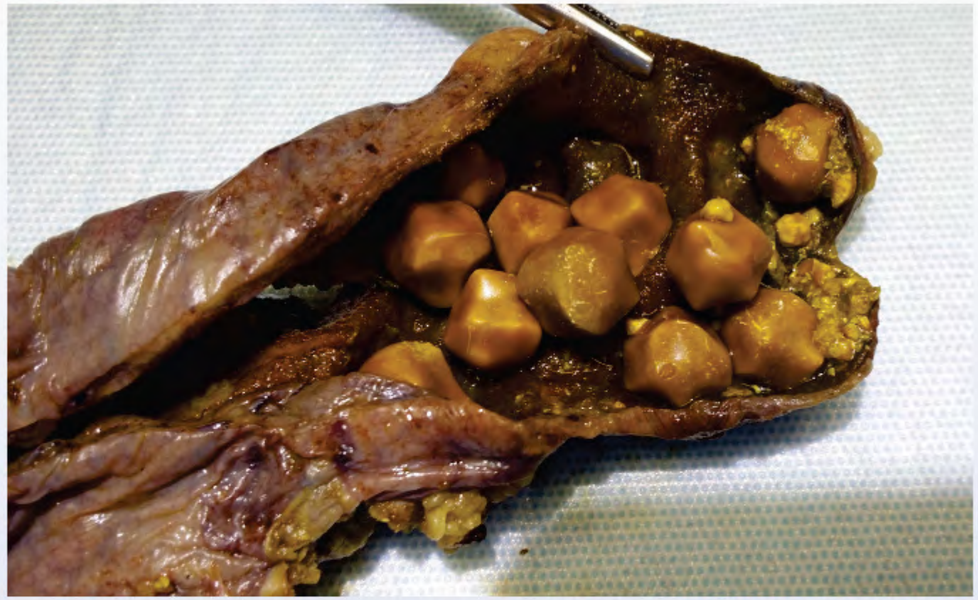

Which of the following is the most likely mechanism responsible for gallstone formation in this patient?

- A. Altered enterohepatic cycling of bilirubin (2%)
- ✗ B. Decreased bile acid synthesis (9%)
- C. Delayed gallbladder emptying (13%)
- ✓ D. Increased cholesterol synthesis (73%)
- E. Increased efflux of bilirubin into bile (1%)

Incorrect
Correct answer
D

73%
Answered correctly

12 secs
Time Spent

2023
Version

https://t.me/USMLEWorldStep1

Explanation

Bile is stored and concentrated within the gallbladder and is involved in digestion and absorption of dietary fats and removal of waste products (eg, bilirubin, cholesterol) for excretion in feces. Gallstones usually occur when one such waste product supersaturates the bile, resulting in precipitation and eventual stone formation.

In the United States, most gallstones are due to the **supersaturation of cholesterol**, which usually precipitates out of bile with calcium salts and mucin, forming **white or yellow cholesterol stones**, as seen in this patient. Cholesterol stone formation occurs due to the following:

- **Increased cholesterol synthesis:** Hypercholesterolemia, caused by diet, genetics, diabetes mellitus, medications (eg, oral contraceptives), or **obesity** (increased HMG-CoA reductase activity), results in hypersecretion of cholesterol into the bile.
- **Gallbladder hypomotility:** Pregnancy, medications (eg, somatostatin), prolonged fasting, parenteral nutrition, and spinal cord injury lead to gallbladder stasis, which promotes excessive water resorption from bile and concentration of cholesterol.
- **Decreased bile acid synthesis** (or recirculation): Fibrates (eg, fenofibrate) inhibit bile acid synthesis, increasing cholesterol concentration within the bile. Decreased bile acid resorption at the ileum (eg, due to Crohn disease) also promotes cholesterol concentration.
- Increased calcium or mucin concentration**:** Rapid weight loss (eg, gastric bypass) promotes increased calcium and mucin concentrations in the bile, which trap cholesterol crystals and promote stone formation.

(Choices A and E) Increased enterohepatic cycling of bilirubin occurs with ileal disease (eg, Crohn disease), as the loss of bile acids promotes reabsorption of unconjugated bilirubin. Increased efflux of bilirubin into bile also occurs with hyperbilirubinemia from chronic hemolysis (eg, sickle cell disease). Because of high bilirubin concentrations, these mechanisms promote the formation of black pigment stones, not cholesterol stones.

(Choices B and C) Although both decreased bile acid synthesis (eg, due to fibrate medications) and gallbladder hypomotility (eg, due to pregnancy, prolonged fasting, or spinal cord injury) promote the formation of cholesterol gallstones, this patient does not have risk factors for either etiology.

https://t.me/USMLEWorldStep1

out of bile with calcium salts and mucin, forming **white or yellow cholesterol stones**, as seen in this patient.

Cholesterol stone formation occurs due to the following:

- **Increased cholesterol synthesis:** Hypercholesterolemia, caused by diet, genetics, diabetes mellitus, medications (eg, oral contraceptives), or **obesity** (increased HMG-CoA reductase activity), results in hypersecretion of cholesterol into the bile.
- **Gallbladder hypomotility:** Pregnancy, medications (eg, somatostatin), prolonged fasting, parenteral nutrition, and spinal cord injury lead to gallbladder stasis, which promotes excessive water resorption from bile and concentration of cholesterol.
- **Decreased bile acid synthesis** (or recirculation): Fibrates (eg, fenofibrate) inhibit bile acid synthesis, increasing cholesterol concentration within the bile. Decreased bile acid resorption at the ileum (eg, due to Crohn disease) also promotes cholesterol concentration.
- Increased calcium or mucin concentration**:** Rapid weight loss (eg, gastric bypass) promotes increased calcium and mucin concentrations in the bile, which trap cholesterol crystals and promote stone formation.

(Choices A and E) Increased enterohepatic cycling of bilirubin occurs with ileal disease (eg, Crohn disease), as the loss of bile acids promotes reabsorption of unconjugated bilirubin. Increased efflux of bilirubin into bile also occurs with hyperbilirubinemia from chronic hemolysis (eg, sickle cell disease). Because of high bilirubin concentrations, these mechanisms promote the formation of black pigment stones, not cholesterol stones.

(Choices B and C) Although both decreased bile acid synthesis (eg, due to fibrate medications) and gallbladder hypomotility (eg, due to pregnancy, prolonged fasting, or spinal cord injury) promote the formation of cholesterol gallstones, this patient does not have risk factors for either etiology.

Educational objective:
Most gallstones occur due to the supersaturation of cholesterol, which precipitates out of bile with mucin and calcium salts to form white or yellow cholesterol stones. Factors that promote the formation of cholesterol stones include increased cholesterol synthesis, gallbladder hypomotility, increased calcium or mucin concentration, and decreased bile acid synthesis or recirculation.

Pathology Gastrointestinal & Nutrition Gallstone disease

https://t.me/USMLEWorldStep1

Incorrect
Correct answer
D

73%
Answered correctly

12 secs
Time Spent

2023
Version

Expl

Bile is
remov
such v

In the
out of
Choles

- In
m
h
- G
n
a
- D
in
C
- In
ca

(Choi
the los
occurs with hyperbilirubinemia from chronic hemolysis (eg, sickle cell disease). Because of high bilirubin concentrations, these mechanisms promote the formation of black pigment stones, not cholesterol stones.

Exhibit Display

Cholelithiasis

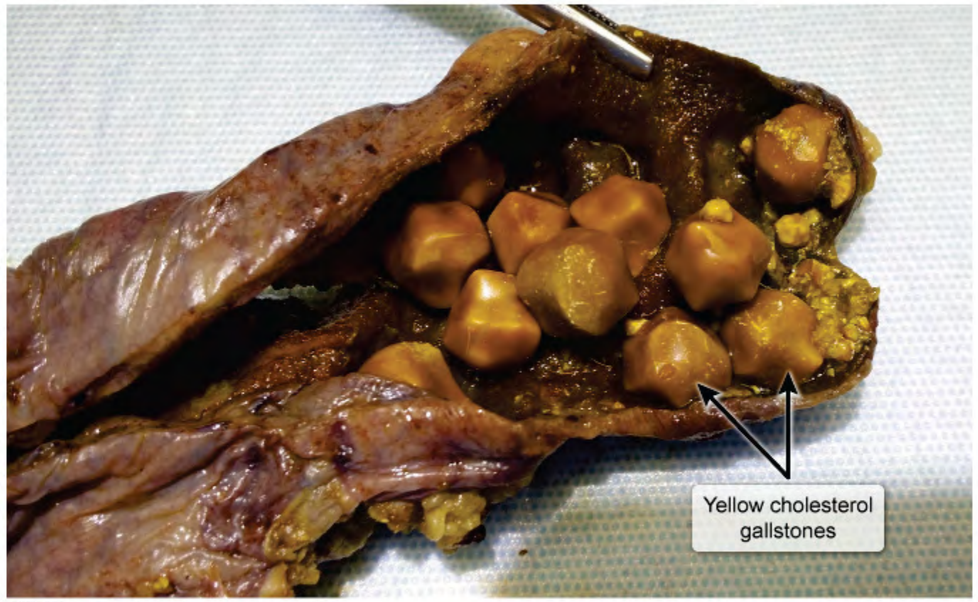

©UWorld

Zoom In | Zoom Out | Reset | New | Existing | My Notebook

https://t.me/USMLEWorldStep1

Incorrect
Correct answer
D

73%
Answered correctly

12 secs
Time Spent

2023
Version

Exhibit Display

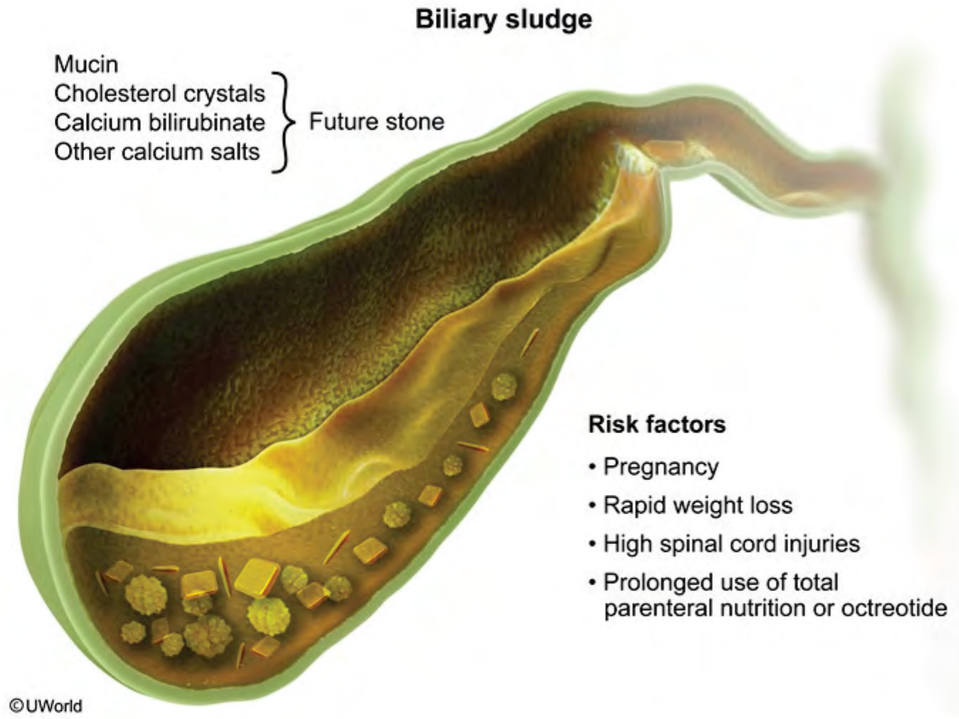

Zoom In | Zoom Out | Reset | New | Existing | My Notebook

Expl

Bile is
remov
such v

In the
out of
Choles

- In
- G
- D
- In

(Choi
the los
occurs with hyperbilirubinemia from chronic hemolysis (eg, sickle cell disease). Because of high bilirubin
concentrations, these mechanisms promote the formation of black pigment stones, not cholesterol stones.

https://t.me/USMLEWorldStep1

removal of waste products (eg, bilirubin, cholesterol) for excretion in feces. Gallstones usually occur when one such waste product supersaturates the bile, resulting in precipitation and eventual stone formation.

In the

out of

Choles

- **In**
- **G**
- **D**
- In

(Choi

the los

occurs

concer

(Choi

hypom

gallsto

Exhibit Display

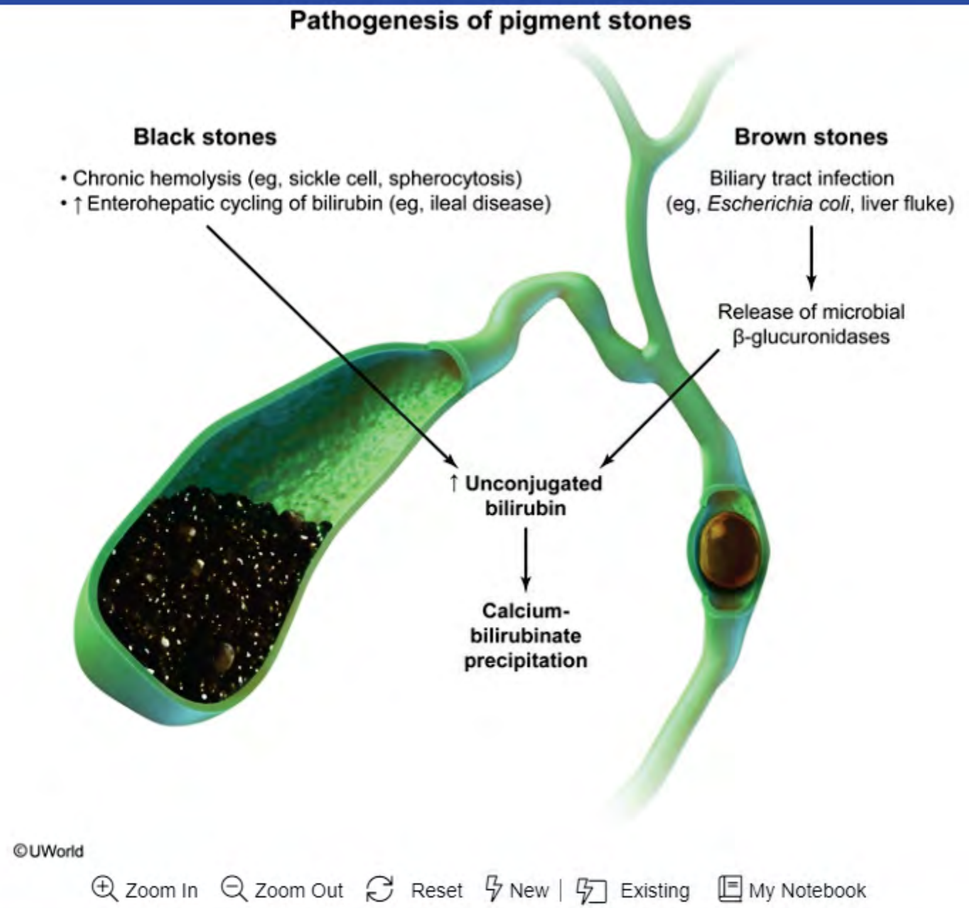

Zoom In | Zoom Out | Reset | New | Existing | My Notebook

Educational objective:

Most gallstones occur due to the supersaturation of cholesterol, which precipitates out of bile with mucin and calcium salts to form white or yellow cholesterol stones. Factors that promote the formation of cholesterol stones

https://t.me/USMLEWorldStep1

A 28-year-old man with vague abdominal pain, low-grade fever, and diarrhea is treated with antibiotics without significant improvement in his symptoms. Several weeks after symptom onset, the patient develops a skin lesion over the abdomen. His temperature is 37.8 C (100 F), blood pressure is 120/70 mm Hg, and pulse is 88/min. On physical examination, the abdomen is mildly distended and tender to palpation. Bowel contents appear to be draining to the surface of the skin in the right lower abdominal quadrant. This patient most likely suffers from which of the following conditions?

- A. Acute appendicitis
- B. Crohn disease
- C. Mesenteric adenitis
- D. Pseudomembranous colitis
- E. Ulcerative colitis

Submit

https://t.me/USMLEWorldStep1

A 28-year-old man with vague abdominal pain, low-grade fever, and diarrhea is treated with antibiotics without significant improvement in his symptoms. Several weeks after symptom onset, the patient develops a skin lesion over the abdomen. His temperature is 37.8 C (100 F), blood pressure is 120/70 mm Hg, and pulse is 88/min. On physical examination, the abdomen is mildly distended and tender to palpation. Bowel contents appear to be draining to the surface of the skin in the right lower abdominal quadrant. This patient most likely suffers from which of the following conditions?

- A. Acute appendicitis (7%)
- ✓ B. Crohn disease (68%)
- C. Mesenteric adenitis (11%)
- D. Pseudomembranous colitis (7%)
- E. Ulcerative colitis (5%)

Correct | 68% Answered correctly | 03 secs Time Spent | 2023 Version

Explanation

Inflammatory bowel disease subtype characteristics

	Crohn disease	Ulcerative colitis
Involvement	• Anywhere mouth to anus (mostly ileum & colon) • Perianal disease with rectal sparing • Skip lesions	• Rectum (always) & colon • Continuous lesions
Microscopy	• Noncaseating granulomas	• No granulomas

https://t.me/USMLEWorldStep1

Inflammatory bowel disease subtype characteristics		
	Crohn disease	**Ulcerative colitis**
Involvement	• Anywhere mouth to anus (mostly ileum & colon) • Perianal disease with rectal sparing • Skip lesions	• Rectum (always) & colon • Continuous lesions
Microscopy	• Noncaseating granulomas	• No granulomas
Gross findings	• Transmural inflammation • Linear mucosal ulcerations • Cobblestoning, creeping fat	• Mucosal & submucosal inflammation • Pseudopolyps
Clinical manifestations	• Abdominal pain (often RLQ) • Watery diarrhea (bloody if colitis)	• Abdominal pain (varying locations) • Bloody diarrhea
Intestinal complications	• Fistulae, abscesses • Strictures (bowel obstruction)	• Toxic megacolon
RLQ = right lower quadrant.		

Crohn disease and ulcerative colitis are collectively referred to as inflammatory bowel disease. They may have similar clinical manifestations, but they also have key distinguishing features (Table).

Crohn disease typically presents with **prolonged diarrhea** and **abdominal pain**. Diarrhea can be bloody if the colon is involved. Constitutional symptoms (eg, low-grade fever, fatigue), malabsorption, and weight loss are also common. **Transmural inflammation** of the bowel wall may result in the formation of fistulas and fibrotic strictures, causing bowel obstruction. Fistulas can form between 2 adjacent loops of bowel (enteroenteric fistula), between the bowel and another organ (eg, bladder, vagina), or between the bowel and skin of the abdominal wall (**enterocutaneous fistula**). Perianal fistulas and abscesses are also often seen.

Ulcerative colitis typically presents with bloody diarrhea associated with abdominal pain and tenesmus. Fistula

https://t.me/USMLEWorldStep1

RLQ = right lower quadrant.

Crohn disease and ulcerative colitis are collectively referred to as inflammatory bowel disease. They may have similar clinical manifestations, but they also have key distinguishing features (Table).

Crohn disease typically presents with **prolonged diarrhea** and **abdominal pain**. Diarrhea can be bloody if the colon is involved. Constitutional symptoms (eg, low-grade fever, fatigue), malabsorption, and weight loss are also common. **Transmural inflammation** of the bowel wall may result in the formation of fistulas and fibrotic strictures, causing bowel obstruction. Fistulas can form between 2 adjacent loops of bowel (enteroenteric fistula), between the bowel and another organ (eg, bladder, vagina), or between the bowel and skin of the abdominal wall (**enterocutaneous fistula**). Perianal fistulas and abscesses are also often seen.

Ulcerative colitis typically presents with bloody diarrhea associated with abdominal pain and tenesmus. Fistula formation does not usually occur as inflammation is confined to the mucosa and submucosa **(Choice E)**.

(Choice A) Right lower quadrant abdominal pain, fever, nausea, and vomiting are classic symptoms of acute appendicitis. If untreated, appendicitis may progress to peritonitis or abscess formation, but fistula formation is not common.

(Choice C) Mesenteric adenitis most often occurs in children age 5-14. Many cases are thought to be associated with *Yersinia enterocolitica* infection. Clinical manifestations may include fever, right lower quadrant abdominal pain, and nausea/vomiting, but fistulas are not characteristic.

(Choice D) Pseudomembranous colitis is typically caused by *Clostridium difficile* infection and presents with diarrhea, abdominal pain, and fever in a patient who has recently been hospitalized or treated with antibiotics. Fistulas are not typically seen.

Educational objective:
Crohn disease typically presents with prolonged diarrhea and abdominal pain. Constitutional symptoms (eg, low-grade fever, fatigue), malabsorption, and weight loss are also common. Transmural inflammation of the bowel wall may result in the formation of fistulas (eg, enteroenteric, enterocutaneous), abscesses, and fibrotic strictures.

References

https://t.me/USMLEWorldStep1

RLQ = right lower quadrant.

Exhibit Display

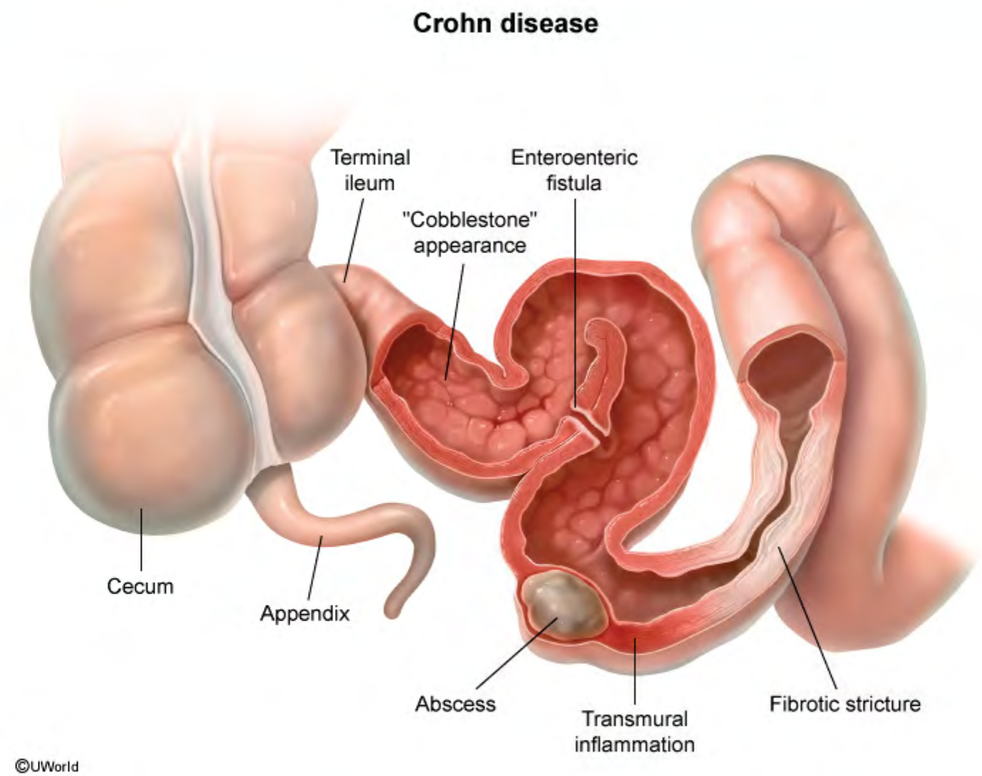

Zoom In | Zoom Out | Reset | New | Existing | My Notebook

Crohn
similar

Crohn
colon i
comm
causin
the bo
(enter

Ulcera
format

(Choi
appen
comm

(Choi
with Y
pain, a

(Choi
diarrhe
Fistula

Educa
Crohn
grade fever, fatigue), malabsorption, and weight loss are also common. Transmural inflammation of the bowel wall may result in the formation of fistulas (eg, enteroenteric, enterocutaneous), abscesses, and fibrotic strictures.

References

https://t.me/USMLEWorldStep1

A 68-year-old woman comes to the emergency department due to a 2-day history of crampy abdominal pain and vomiting. The patient has had no hematemesis, melena, or hematochezia. She has a history of hypertension, type 2 diabetes mellitus, and coronary artery disease. Several months ago, the patient had an episode of acute calculous cholecystitis that was managed non-operatively. Physical examination shows a distended, tympanic abdomen with high-pitched bowel sounds. Abdominal x-ray reveals air in the gallbladder and biliary tree. This patient's gallstone has most likely lodged in which of the following sites?

- A. Common bile duct
- B. Cystic duct
- C. Duodenum
- D. Ileum
- E. Jejunum

Submit

https://t.me/USMLEWorldStep1

A 68-year-old woman comes to the emergency department due to a 2-day history of crampy abdominal pain and vomiting. The patient has had no hematemesis, melena, or hematochezia. She has a history of hypertension, type 2 diabetes mellitus, and coronary artery disease. Several months ago, the patient had an episode of acute calculous cholecystitis that was managed non-operatively. Physical examination shows a distended, tympanic abdomen with high-pitched bowel sounds. Abdominal x-ray reveals air in the gallbladder and biliary tree. This patient's gallstone has most likely lodged in which of the following sites?

- A. Common bile duct (24%)
- ✕ B. Cystic duct (11%)
- C. Duodenum (17%)
- ✓ D. Ileum (44%)
- E. Jejunum (1%)

Incorrect
Correct answer
D

44%
Answered correctly

03 secs
Time Spent

2023
Version

Explanation

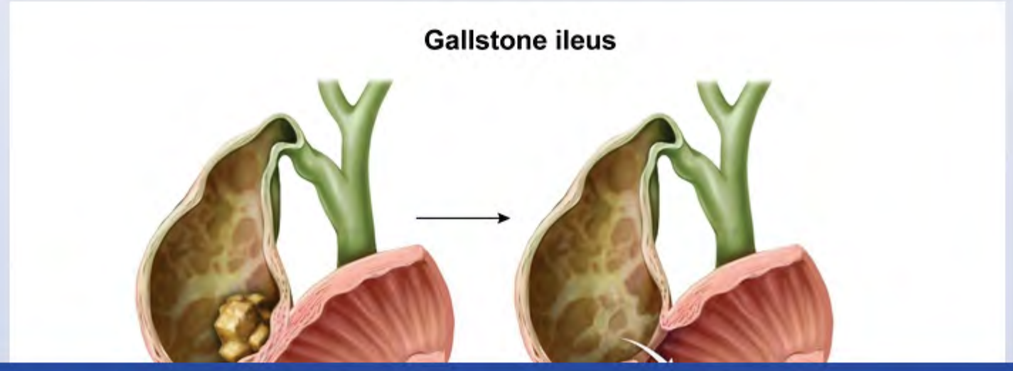

https://t.me/USMLEWorldStep1

A 68-year-old woman comes to the emergency department due to a 2-day history of crampy abdominal pain and vomiti
2 diab
calculo
abdom
patien

Exhibit Display

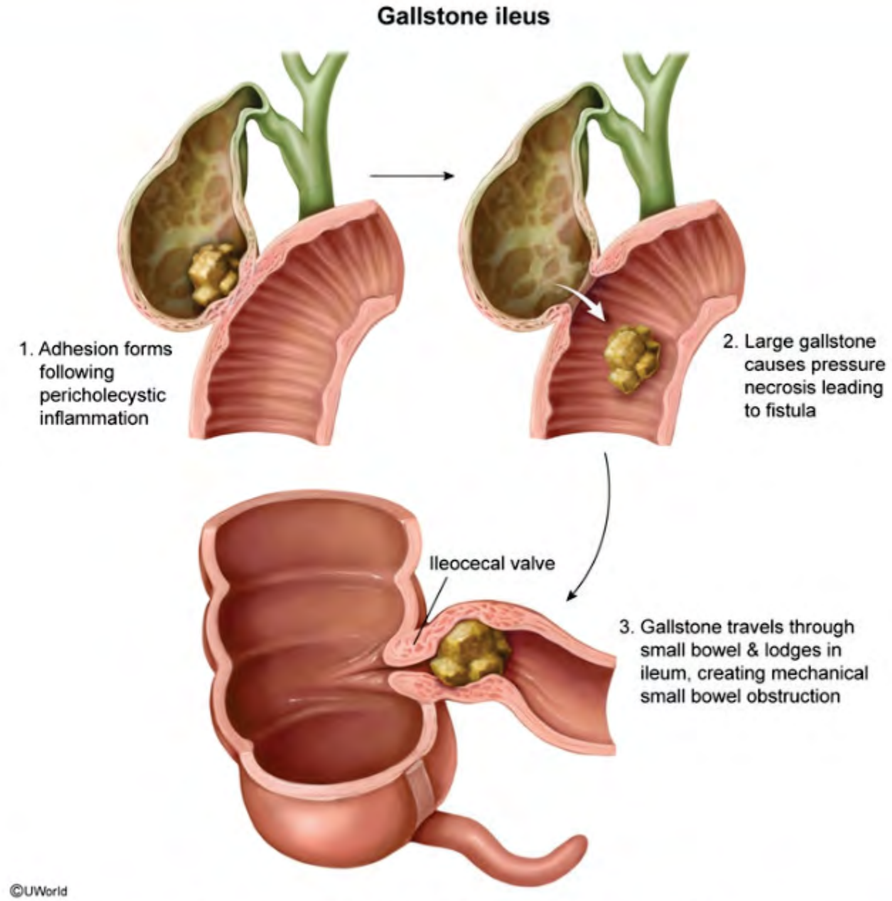

Zoom In | Zoom Out | Reset | New | Existing | My Notebook

Inco
Corre
D

Expl

https://t.me/USMLEWorldStep1

©UWorld

This patient likely has **gallstone ileus**, an uncommon complication of longstanding cholelithiasis that usually occurs in elderly women. A large (typically ≥2.5 cm) gallstone causes formation of a **cholecystoenteric fistula** between the gallbladder and adjoining gut (most often the duodenum) due to pressure necrosis and erosion of these tissues.

Fistula formation allows passage of the gallstone into the small bowel, where it travels freely until it becomes trapped in the **ileum**, the narrowest portion of the intestine. Patients consequently develop symptoms/signs of **small bowel obstruction**, including abdominal pain/distension, nausea/vomiting, high-pitched (tinkling) bowel sounds, and tenderness to palpation. Abdominal x-ray may reveal dilated loops of bowel with air-fluid levels due to intestinal obstruction. Communication between the intestine and gallbladder may also allow gas to enter the biliary tree (**pneumobilia**).

(Choice A) Obstruction of the common bile duct by a gallstone (choledocholithiasis) can lead to pancreatitis and/or cholangitis. Cholangitis typically presents with fever, right upper quadrant abdominal pain, and jaundice (Charcot triad). Pneumobilia and features of small bowel obstruction are not characteristic.

(Choice B) Obstruction of the cystic duct by a gallstone may result in biliary colic or acute cholecystitis. Acute cholecystitis usually presents with fever, abdominal pain, leukocytosis, and an inspiratory pause during right upper quadrant palpation (Murphy sign). Pneumobilia and features of small bowel obstruction are not characteristic.

(Choices C and E) The caliber of the duodenum and jejunum is typically sufficient to allow passage of larger gallstones that cause gallstone ileus.

Educational objective:
Gallstone ileus results from passage of a large gallstone through a cholecystenteric fistula into the small bowel, where it ultimately causes obstruction at the ileum. Patients typically present with symptoms/signs of small bowel obstruction, and an abdominal x-ray may reveal gas within the gallbladder and biliary tree.

References

- Gallstone ileus: case report and literature review.

Anatomy Gastrointestinal & Nutrition Cholecystitis

https://t.me/USMLEWorldStep1

A 55-year-old man undergoing evaluation for fatigue and exertional dyspnea is diagnosed with macrocytic anemia. Upper gastrointestinal endoscopy is consistent with atrophic gastritis. He is prescribed intramuscular cyanocobalamin, with the resulting changes shown in the graph below:

The blue curve most likely corresponds to which of the following parameters?

- A. Erythrocyte count
- B. Gastrin
- C. Haptoglobin
- D. Methylmalonic acid
- E. Reticulocyte count

Submit

https://t.me/USMLEWorldStep1

A 55-year-old man undergoing evaluation for fatigue and exertional dyspnea is diagnosed with macrocytic anemia.

Upper

cyano

The bl

Exhibit Display

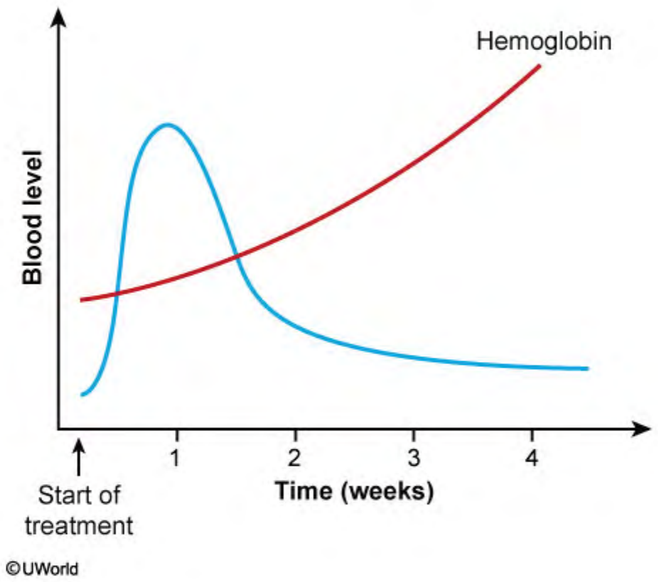

Zoom In | Zoom Out | Reset | New | Existing | My Notebook

Submit

https://t.me/USMLEWorldStep1

A 55-year-old man undergoing evaluation for fatigue and exertional dyspnea is diagnosed with macrocytic anemia. Upper gastrointestinal endoscopy is consistent with atrophic gastritis. He is prescribed intramuscular cyanocobalamin, with the resulting changes shown in the graph below:

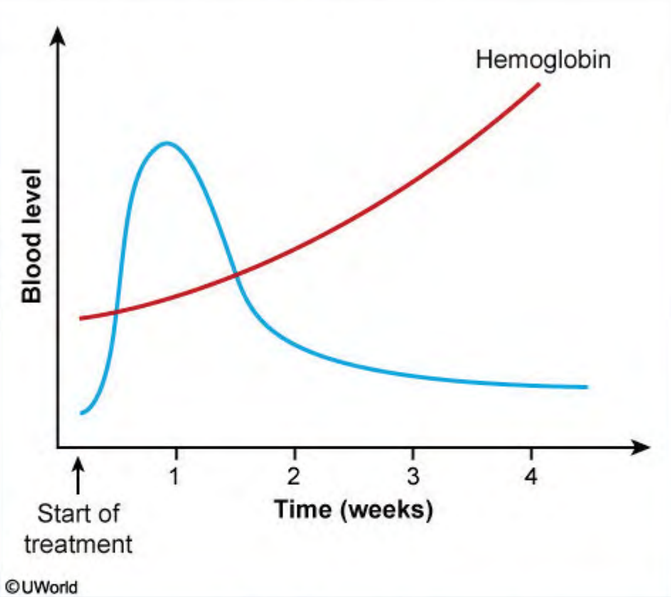

The blue curve most likely corresponds to which of the following parameters?

- A. Erythrocyte count (5%)
- ✗ B. Gastrin (5%)
- C. Haptoglobin (6%)
- D. Methylmalonic acid (32%)
- ✓ E. Reticulocyte count (50%)

Incorrect
Correct answer
50%
08 secs
2023

https://t.me/USMLEWorldStep1

Explanation

The graph shows the treatment response to vitamin B_{12} (cyanocobalamin) in a patient with **vitamin B_{12} deficiency** secondary to atrophic gastritis. Vitamin B_{12} deficiency impairs nucleic acid metabolism, causing delayed nuclear maturation and reduced cell division of erythrocyte precursors in the bone marrow (**megaloblastic anemia**).

Once vitamin B_{12} **replacement therapy** is begun, the rate of effective erythropoiesis increases and immature erythrocytes (**reticulocytes**) are released from the bone marrow into the bloodstream. The peripheral reticulocyte count begins rising within 3 to 4 days and **peaks at around 1 week**, as indicated by the blue curve. The response peaks early because the reticulocytes initially released following vitamin replacement remain in the circulation longer (due to the delayed nuclear maturation) than reticulocytes later released (mature at normal rates). However, the erythrocyte count takes longer to normalize (hemoglobin levels rise ~1 g/week) and the anemia typically takes as long as 8 weeks to correct.

(Choice A) The erythrocyte count curve would be expected to follow the hemoglobin curve upward as the total red blood cell pool gradually returns to normal levels.

(Choice B) In chronic atrophic gastritis, parietal cell loss results in profound hypochlorhydria, increased serum gastrin levels, and inadequate intrinsic factor production. This patient most likely has elevated gastrin levels that would be unaffected by vitamin B_{12} replacement.

(Choice C) Vitamin B_{12} deficiency causes increased red blood cell breakdown due to ineffective erythropoiesis, and the resulting release of free hemoglobin leads to a decrease in serum haptoglobin levels. Haptoglobin levels would normalize (increase) with therapy.

(Choice D) Methylmalonic acid is elevated in vitamin B_{12} deficiency due to decreased metabolism and would decline with vitamin B_{12} supplementation. In this case, the blue curve rises after the beginning of treatment, which would not be expected.

Educational objective:
Atrophic gastritis can result in profound hypochlorhydria, inadequate intrinsic factor production, vitamin B_{12}

https://t.me/USMLEWorldStep1

The graph shows the treatment response to vitamin B_{12} (cyanocobalamin) in a patient with **vitamin B_{12} deficiency** secondary to atrophic gastritis. Vitamin B_{12} deficiency impairs nucleic acid metabolism, causing delayed nuclear maturation and reduced cell division of erythrocyte precursors in the bone marrow (**megaloblastic anemia**).

Once vitamin B_{12} **replacement therapy** is begun, the rate of effective erythropoiesis increases and immature erythrocytes (**reticulocytes**) are released from the bone marrow into the bloodstream. The peripheral reticulocyte count begins rising within 3 to 4 days and **peaks at around 1 week**, as indicated by the blue curve. The response peaks early because the reticulocytes initially released following vitamin replacement remain in the circulation longer (due to the delayed nuclear maturation) than reticulocytes later released (mature at normal rates). However, the erythrocyte count takes longer to normalize (hemoglobin levels rise ~1 g/week) and the anemia typically takes as long as 8 weeks to correct.

(Choice A) The erythrocyte count curve would be expected to follow the hemoglobin curve upward as the total red blood cell pool gradually returns to normal levels.

(Choice B) In chronic atrophic gastritis, parietal cell loss results in profound hypochlorhydria, increased serum gastrin levels, and inadequate intrinsic factor production. This patient most likely has elevated gastrin levels that would be unaffected by vitamin B_{12} replacement.

(Choice C) Vitamin B_{12} deficiency causes increased red blood cell breakdown due to ineffective erythropoiesis, and the resulting release of free hemoglobin leads to a decrease in serum haptoglobin levels. Haptoglobin levels would normalize (increase) with therapy.

(Choice D) Methylmalonic acid is elevated in vitamin B_{12} deficiency due to decreased metabolism and would decline with vitamin B_{12} supplementation. In this case, the blue curve rises after the beginning of treatment, which would not be expected.

Educational objective:
Atrophic gastritis can result in profound hypochlorhydria, inadequate intrinsic factor production, vitamin B_{12} deficiency, and elevated methylmalonic acid levels. Once vitamin B_{12} replacement therapy is initiated, the reticulocyte count increases dramatically and peaks around 1 week; hemoglobin levels and erythrocyte counts rise more gradually and take up to 8 weeks to normalize.

https://t.me/USMLEWorldStep1

Explanation

Exhibit Display

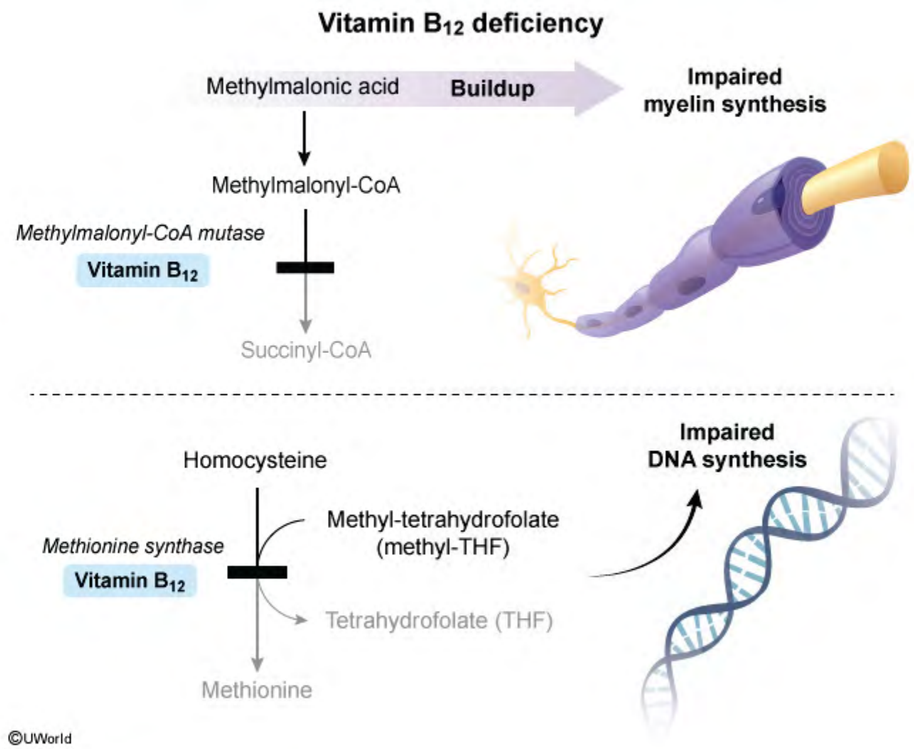

Zoom In | Zoom Out | Reset | New | Existing | My Notebook

The gr
secon
matura

Once
erythr
count
peaks
longer
Howev
typical

(Choi
blood

(Choi
gastri
would

(Choi
and th
would

(Choi
decline
would

Educa
Atrophic gastritis can result in profound hypochlorhydria, inadequate intrinsic factor production, vitamin B_{12}

https://t.me/USMLEWorldStep1

A 56-year-old man comes to the cardiology clinic because of fatigue, palpitations, and exertional dyspnea over the last several weeks. On physical examination, his heart rate is irregular and measures 122 beats per minute, while his blood pressure is 110/70 mm Hg. The patient undergoes further work-up, including ECG, radiographic studies, and laboratory studies. His ECG shows atrial fibrillation and trans-esophageal echocardiography reveals a thrombus in a dilated left atrium. In the event of an interruption of blood flow secondary to arterial occlusion, which of the following organs would be least vulnerable to infarction?

- A. Spleen
- B. Brain
- C. Kidney
- D. Liver
- E. Heart

Submit

https://t.me/USMLEWorldStep1

A 56-year-old man comes to the cardiology clinic because of fatigue, palpitations, and exertional dyspnea over the last several weeks. On physical examination, his heart rate is irregular and measures 122 beats per minute, while his blood pressure is 110/70 mm Hg. The patient undergoes further work-up, including ECG, radiographic studies, and laboratory studies. His ECG shows atrial fibrillation and trans-esophageal echocardiography reveals a thrombus in a dilated left atrium. In the event of an interruption of blood flow secondary to arterial occlusion, which of the following organs would be least vulnerable to infarction?

- ✗ A. Spleen (9%)
- B. Brain (7%)
- C. Kidney (4%)
- ✓ D. Liver (67%)
- E. Heart (11%)

Incorrect
Correct answer
D

67%
Answered correctly

04 secs
Time Spent

2023
Version

Explanation

Infarcts in an otherwise normal liver are rare because it has a dual blood supply: the portal vein and hepatic artery. Should the hepatic artery become occluded, the portal venous supply and retrograde arterial flow through accessory vessels (e.g., from the inferior phrenic, adrenal, intercostal arteries, etc.) is typically sufficient to sustain the liver parenchyma. The notable exception is when a transplanted liver undergoes hepatic artery thrombosis. In this case, the liver can develop biliary tree infarction and organ failure because the collateral blood supply is severed during transplantation.

(Choice A) The spleen is relatively vulnerable to infarction because the perfusion via the splenic artery is end-arterial. Wedge-shaped, capsule-based splenic infarcts occur and are a known complication of sickle cell anemia,

https://t.me/USMLEWorldStep1

Infarcts in an otherwise normal liver are rare because it has a dual blood supply: the portal vein and hepatic artery. Should the hepatic artery become occluded, the portal venous supply and retrograde arterial flow through accessory vessels (e.g., from the inferior phrenic, adrenal, intercostal arteries, etc.) is typically sufficient to sustain the liver parenchyma. The notable exception is when a transplanted liver undergoes hepatic artery thrombosis. In this case, the liver can develop biliary tree infarction and organ failure because the collateral blood supply is severed during transplantation.

(Choice A) The spleen is relatively vulnerable to infarction because the perfusion via the splenic artery is end-arterial. Wedge-shaped, capsule-based splenic infarcts occur and are a known complication of sickle cell anemia, infective endocarditis, and cardiac mural thrombosis.

(Choice B) Irreversible damage appears to occur in the most vulnerable of neurons after approximately 5 minutes of complete ischemia.

(Choice C) The kidney, similar to the spleen, has an end-arterial blood supply, and is generally able to tolerate warm ischemia for at least 30 minutes. Longer periods of complete ischemia result in immediate functional loss; late recovery of renal function is incomplete or absent.

(Choice E) The myocardium can endure complete arterial ischemia for twenty or thirty minutes without severe consequences. Briefer periods of ischemia do not result in necrosis, but rather myocardial stunning. Coronary artery embolism is an uncommon cause of myocardial infarction; nonetheless, it should be considered in myocardial-infarcted patients with atrial fibrillation, infective endocarditis, left atrial or ventricular thrombus, and in patients undergoing cardiac catheterization.

Educational objective:
Organ susceptibility to infarction after occlusion of a feeding artery is ranked from greatest to least as follows: central nervous system, myocardium, kidney, spleen, and liver. The presence of a dual and/or collateral blood supply (as seen in the liver, which is supplied by the hepatic artery and portal vein) enables an organ to tolerate arterial occlusion better than those with end-arterial circulations.

References

- Regulation of hepatic blood flow: the hepatic arterial buffer response revisited.

https://t.me/USMLEWorldStep1

A 14-month-old girl is brought to the office due to a 2-month history of diarrhea. Her parents report that she has 3-5 loose, nonbloody bowel movements daily with occasional episodes of vomiting. She was breastfed exclusively until age 9 months and has since had a well-varied diet including whole milk, fruits, vegetables, bread, and meats. However, the girl has been less interested in food over the past several weeks. There is no history of travel or contacts with similar symptoms. On physical examination, the patient appears well but has lost 1.1 kg (2.5 lb) in the last 2 months. After laboratory evaluation, duodenal biopsy findings are shown in the exhibit. Which of the following would most likely improve this patient's symptoms?

- A. Acid reduction therapy
- B. Anti-inflammatory medications
- C. Antibiotic therapy
- D. Enzyme supplementation
- E. Modified dairy diet
- F. Modified grain diet

Submit

https://t.me/USMLEWorldStep1

A 14-month-old girl is brought to the office due to a 2-month history of diarrhea. Her parents report that she has 3-
5 loos
until a
Howev
contac
the las
followi

Sub

Exhibit Display

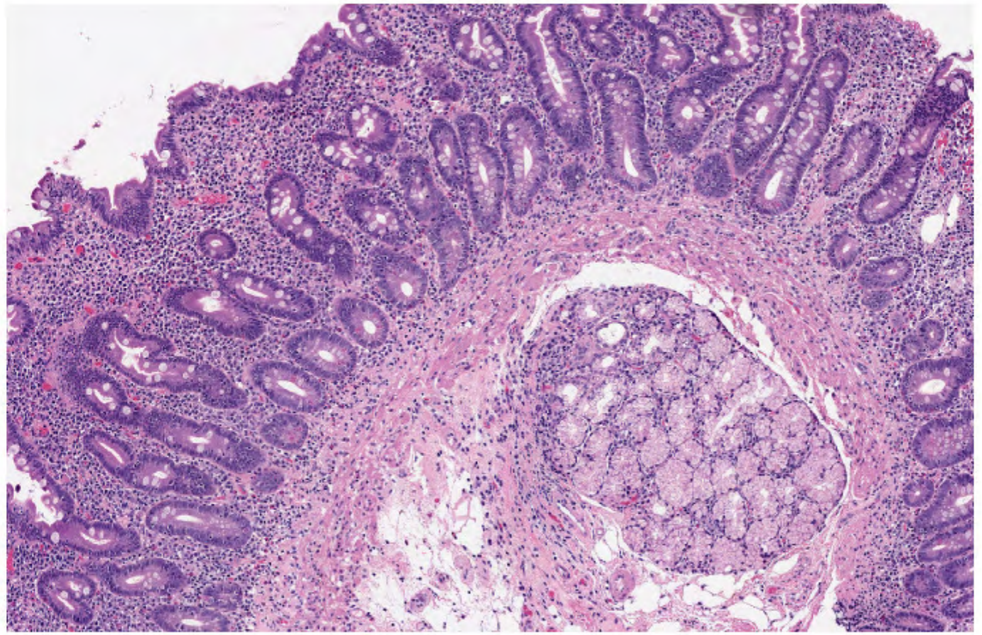

Zoom In | Zoom Out | Reset | New | Existing | My Notebook

https://t.me/USMLEWorldStep1

A 14-month-old girl is brought to the office due to a 2-month history of diarrhea. Her parents report that she has 3-5 loose, nonbloody bowel movements daily with occasional episodes of vomiting. She was breastfed exclusively until age 9 months and has since had a well-varied diet including whole milk, fruits, vegetables, bread, and meats. However, the girl has been less interested in food over the past several weeks. There is no history of travel or contacts with similar symptoms. On physical examination, the patient appears well but has lost 1.1 kg (2.5 lb) in the last 2 months. After laboratory evaluation, duodenal biopsy findings are shown in the exhibit. Which of the following would most likely improve this patient's symptoms?

- A. Acid reduction therapy (2%)
- B. Anti-inflammatory medications (7%)
- ✗ C. Antibiotic therapy (2%)
- D. Enzyme supplementation (3%)
- E. Modified dairy diet (7%)
- ✓ F. Modified grain diet (75%)

Incorrect
Correct answer
F

75%
Answered correctly

19 secs
Time Spent

2023
Version

Explanation

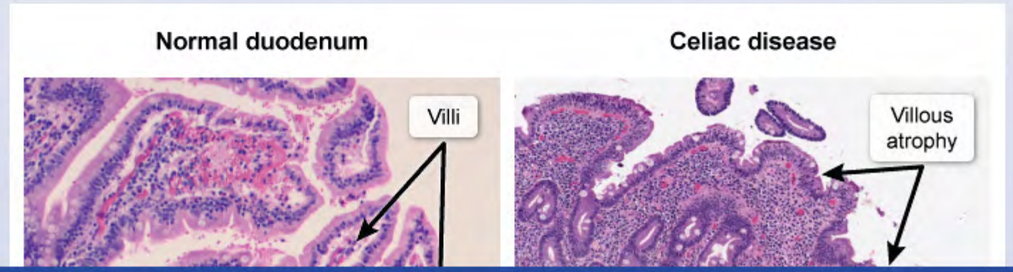

https://t.me/USMLEWorldStep1

B. Anti-inflammatory medications (7%)

Exhibit Display

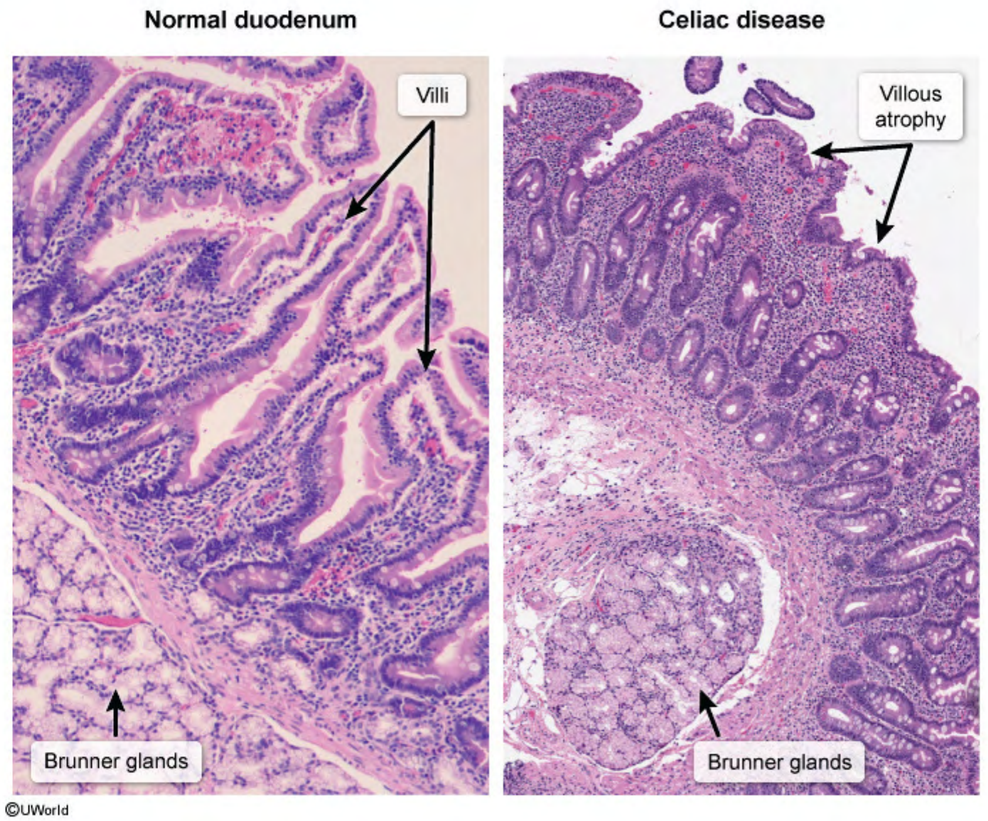

Zoom In | Zoom Out | Reset | New | Existing | My Notebook

https://t.me/USMLEWorldStep1

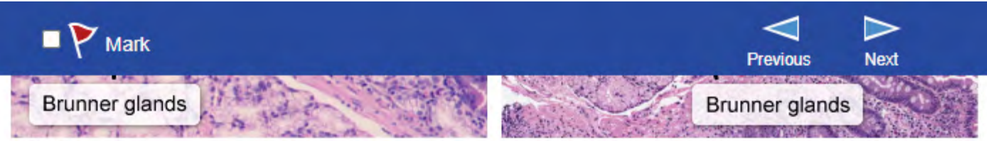

©UWorld

Celiac disease is a chronic malabsorptive disorder caused by a **hypersensitivity to gluten**, a protein found in wheat, barley, and rye. Gliadin (a gluten component) triggers an immune-mediated reaction causing **villous atrophy, crypt hyperplasia**, and intraepithelial lymphocyte infiltration. Normal intestinal villi allow for increased small intestinal surface area to begin the process of digestion and nutrient absorption. The atrophy in celiac disease causes impairment of nutrient absorption in the duodenum and proximal jejunum, regions where the concentration of gluten is the highest.

Classic celiac disease presents after introduction of gluten into the diet (between age 6-24 months) with symptoms of malabsorption (eg, diarrhea, steatorrhea, flatulence, nutrient deficiencies, weight loss). Other manifestations include delayed puberty and short stature in children and anemia in adults. Screening is with serology testing for elevated IgA anti-endomysial and **anti-tissue transglutaminase antibodies**; diagnosis is confirmed by endoscopic biopsy. With strict adherence to a **gluten-free diet**, symptom resolution occurs within weeks and is followed by normalization of histology and antibody levels.

(Choice A) Mild gastroesophageal reflux is physiologic in healthy infants, but it can lead to irritability, poor feeding, and inadequate weight gain when severe. The diagnosis is often made clinically and can be treated with conservative changes (eg, smaller feedings) and acid suppression (eg, proton pump inhibitor). Refractory cases may require biopsy, which shows esophageal inflammation.

(Choice B) Anti-inflammatory medications (eg, glucocorticoids, aminosalicylates) are the mainstay of treatment for inflammatory bowel disease (ulcerative colitis [UC] and Crohn disease [CD]). Symptoms include abdominal pain, bloody diarrhea, and weight loss. Colonoscopy may show diffuse colonic inflammation in UC and focal areas of small intestinal and colonic inflammation in CD.

(Choice C) Tropical sprue can occur with extended travel to the tropics and presents with chronic diarrhea, abdominal pain, and flatulence along with similar histologic findings to celiac disease (eg, villous atrophy). The etiology is likely infectious, and the disease is treated with antibiotics. However, this patient has no history of travel.

(Choices D and E) Lactase supplementation or limited lactose intake is recommended for patients with lactose

https://t.me/USMLEWorldStep1

of malabsorption (eg, diarrhea, steatorrhea, flatulence, nutrient deficiencies, weight loss). Other manifestations include delayed puberty and short stature in children and anemia in adults. Screening is with serology testing for elevated IgA anti-endomysial and **anti-tissue transglutaminase antibodies**; diagnosis is confirmed by endoscopic biopsy. With strict adherence to a **gluten-free diet**, symptom resolution occurs within weeks and is followed by normalization of histology and antibody levels.

(Choice A) Mild gastroesophageal reflux is physiologic in healthy infants, but it can lead to irritability, poor feeding, and inadequate weight gain when severe. The diagnosis is often made clinically and can be treated with conservative changes (eg, smaller feedings) and acid suppression (eg, proton pump inhibitor). Refractory cases may require biopsy, which shows esophageal inflammation.

(Choice B) Anti-inflammatory medications (eg, glucocorticoids, aminosalicylates) are the mainstay of treatment for inflammatory bowel disease (ulcerative colitis [UC] and Crohn disease [CD]). Symptoms include abdominal pain, bloody diarrhea, and weight loss. Colonoscopy may show diffuse colonic inflammation in UC and focal areas of small intestinal and colonic inflammation in CD.

(Choice C) Tropical sprue can occur with extended travel to the tropics and presents with chronic diarrhea, abdominal pain, and flatulence along with similar histologic findings to celiac disease (eg, villous atrophy). The etiology is likely infectious, and the disease is treated with antibiotics. However, this patient has no history of travel.

(Choices D and E) Lactase supplementation or limited lactose intake is recommended for patients with lactose intolerance, which classically presents in older children and adults with bloating, flatulence, abdominal discomfort, and diarrhea. Although biopsy is not indicated for diagnosis, histology would show normal small intestinal architecture with decreased lactase activity.

Educational objective:
Celiac disease (gluten-sensitive enteropathy) classically presents between age 6-24 months with abdominal pain, diarrhea, vomiting, and weight loss. Duodenal biopsy reveals crypt hyperplasia, villous atrophy, and intraepithelial lymphocyte infiltration. Treatment with a gluten-free diet resolves symptoms and normalizes serology and histology.

https://t.me/USMLEWorldStep1

Brunner glands

Brunner glands

Exhibit Display

Celiac disease

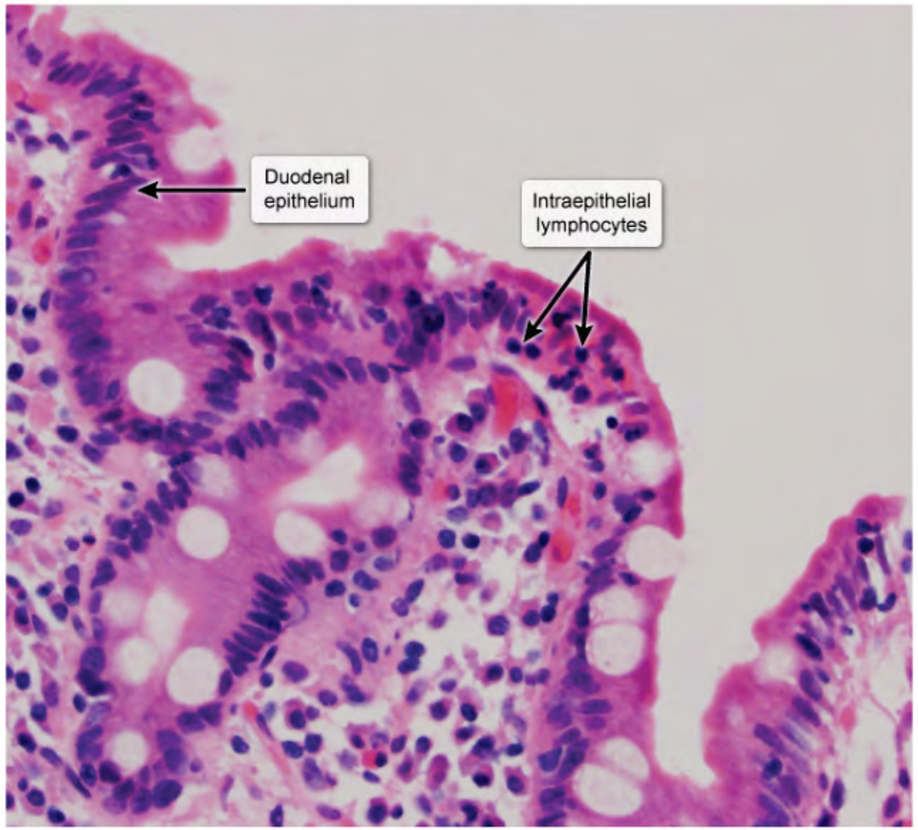

Zoom In | Zoom Out | Reset | New | Existing | My Notebook

Celiac
wheat
atroph
small i
diseas
concer

Classi
of mal
include
elevat
endos
followe

(Choic
and in
conser
may re

(Choic
inflam
bloody
small i

(Choic
abdom
etiolog
travel.

(Choices D and E) Lactase supplementation or limited lactose intake is recommended for patients with lactose

https://t.me/USMLEWorldStep1

A 64-year-old woman comes to the emergency department due to a 2-day history of worsening abdominal pain. She has a history of gallstones but has had no surgery due to high operative risk. Medical history includes chronic obstructive pulmonary disease, hypertension, and remote cervical cancer treated with surgery and chemotherapy. Abdominal CT scan shows multiple dilated small bowel loops with a decompressed distal ileum, and an abnormal bowel indicated by the arrow shown below:

Which of the following is the most likely cause of this patient's current condition?

- A. Gallstone ileus
- B. Incarcerated hernia
- C. Intestinal malrotation
- D. Intestinal volvulus
- E. Peritoneal adhesion

Submit

https://t.me/USMLEWorldStep1

A 64-year-old woman comes to the emergency department due to a 2-day history of worsening abdominal pain.
She ha
obstru
Abdon
bowel

Exhibit Display

©UWorld

Zoom In | Zoom Out | Reset | New | Existing | My Notebook

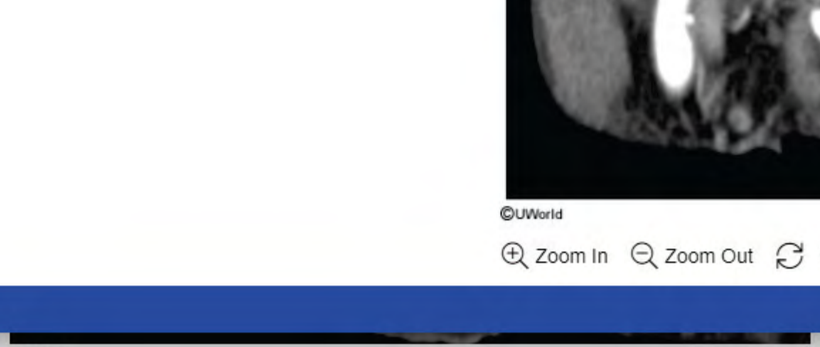

©UWorld

https://t.me/USMLEWorldStep1

©UWorld

Which of the following is the most likely cause of this patient's current condition?

- A. Gallstone ileus
- B. Incarcerated hernia
- C. Intestinal malrotation
- D. Intestinal volvulus
- E. Peritoneal adhesion

Submit

https://t.me/USMLEWorldStep1

©UWorld

Which of the following is the most likely cause of this patient's current condition?

- A. Gallstone ileus (33%)
- ✓ B. Incarcerated hernia (45%)
- C. Intestinal malrotation (1%)
- D. Intestinal volvulus (8%)
- E. Peritoneal adhesion (11%)

Correct

45% Answered correctly

19 secs Time Spent

2023 Version

https://t.me/USMLEWorldStep1

D. Intestinal volvulus (8%)

Exhibit Display

Incarcerated inguinal hernia causing small bowel obstruction

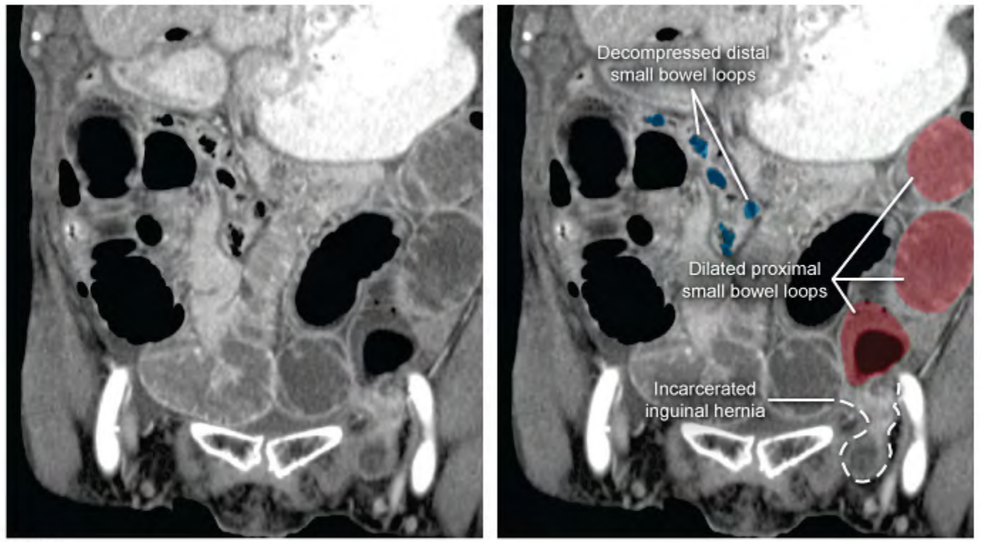

©UWorld

Zoom In | Zoom Out | Reset | New | Existing | My Notebook

loops) and **decompression of bowel distal** to the obstruction (eg, decompressed distal ileum). Patients with SBO typically have abdominal pain, nausea, vomiting (usually bilious), and abdominal distension and tenderness.

https://t.me/USMLEWorldStep1

©UWorld

This patient with worsening abdominal pain has CT scan findings concerning for **small bowel obstruction (SBO)**, a process in which a mechanical or functional obstruction disrupts the normal flow of intestinal intraluminal contents. SBO classically causes **dilation of bowel proximal** to the obstruction (eg, multiple dilated small bowel loops) and **decompression of bowel distal** to the obstruction (eg, decompressed distal ileum). Patients with SBO typically have abdominal pain, nausea, vomiting (usually bilious), and abdominal distension and tenderness.

Common causes of mechanical SBO include peritoneal adhesions, hernias, and tumors. Computed tomography is the diagnostic test of choice because it usually can identify the specific site of obstruction (ie, transition point), assess obstruction severity (partial vs complete), and identify potential complications (eg, bowel necrosis, perforation).

This patient's CT scan demonstrates a **small bowel** loop **extending outside the peritoneal cavity** into the left inguinal area, indicative of an **inguinal hernia** that has become trapped (ie, **incarcerated**) as the cause of SBO. Incarceration increases the risk of bowel strangulation (ie, ischemia leading to necrosis) and should prompt urgent surgical consultation.

(Choice A) Gallstone ileus occurs when a large gallstone erodes into the intestinal lumen and becomes impacted (eg, at the ileocecal valve), causing mechanical obstruction. CT scan commonly shows obstructing gallstones or pneumobilia due to retrograde passage of intestinal gas into the biliary tract.

(Choice C) Malrotation is characterized by incomplete physiologic rotation of the bowel in utero. Duodenal obstruction can occur due to abnormally positioned peritoneal bands; however, this occurs more commonly in infancy (vs adulthood). Imaging typically shows predominantly left-sided large bowel and right-sided small bowel.

(Choice D) Volvulus occurs when an intestinal loop twists around itself and its mesentery. It can result in SBO, but CT scan classically reveals mesenteric twisting ("whirl sign") as the transition point (vs an incarcerated inguinal hernia).

(Choice E) Peritoneal adhesions (fibrous bands) often form between intraabdominal organs and/or the abdominal wall following abdominal surgery and can cause mechanical SBO by trapping bowel loops during normal intestinal peristalsis. However, CT scan typically reveals an intraperitoneal transition point (vs an extraperitoneal hernia).

Educational objective:

https://t.me/USMLEWorldStep1

loops) and **decompression of bowel distal** to the obstruction (eg, decompressed distal ileum). Patients with SBO typically have abdominal pain, nausea, vomiting (usually bilious), and abdominal distension and tenderness.

Common causes of mechanical SBO include peritoneal adhesions, hernias, and tumors. Computed tomography is the diagnostic test of choice because it usually can identify the specific site of obstruction (ie, transition point), assess obstruction severity (partial vs complete), and identify potential complications (eg, bowel necrosis, perforation).

This patient's CT scan demonstrates a **small bowel** loop **extending outside the peritoneal cavity** into the left inguinal area, indicative of an **inguinal hernia** that has become trapped (ie, **incarcerated**) as the cause of SBO. Incarceration increases the risk of bowel strangulation (ie, ischemia leading to necrosis) and should prompt urgent surgical consultation.

(Choice A) Gallstone ileus occurs when a large gallstone erodes into the intestinal lumen and becomes impacted (eg, at the ileocecal valve), causing mechanical obstruction. CT scan commonly shows obstructing gallstones or pneumobilia due to retrograde passage of intestinal gas into the biliary tract.

(Choice C) Malrotation is characterized by incomplete physiologic rotation of the bowel in utero. Duodenal obstruction can occur due to abnormally positioned peritoneal bands; however, this occurs more commonly in infancy (vs adulthood). Imaging typically shows predominantly left-sided large bowel and right-sided small bowel.

(Choice D) Volvulus occurs when an intestinal loop twists around itself and its mesentery. It can result in SBO, but CT scan classically reveals mesenteric twisting ("whirl sign") as the transition point (vs an incarcerated inguinal hernia).

(Choice E) Peritoneal adhesions (fibrous bands) often form between intraabdominal organs and/or the abdominal wall following abdominal surgery and can cause mechanical SBO by trapping bowel loops during normal intestinal peristalsis. However, CT scan typically reveals an intraperitoneal transition point (vs an extraperitoneal hernia).

Educational objective:
Small bowel obstruction (SBO) occurs when a mechanical or functional obstruction disrupts the normal flow of intestinal intraluminal contents. A herniated bowel loop (eg, inguinal hernia) can cause SBO if it becomes trapped (ie, incarcerated) outside the peritoneal cavity.

https://t.me/USMLEWorldStep1

loops) and **decompression of bowel distal** to the obstruction (eg, decompressed distal ileum). Patients with SBO typical

Comm
the dia
assess
perfora

This p
inguina
Incarc
surgica

(Choi
(eg, at
pneum

(Choi
obstru
infancy

(Choi
but CT
hernia

(Choi
wall fo
perista

Educa
Small
intestinal intraluminal contents. A herniated bowel loop (eg, inguinal hernia) can cause SBO if it becomes trapped (ie, incarcerated) outside the peritoneal cavity.

Exhibit Display

Gallstone ileus

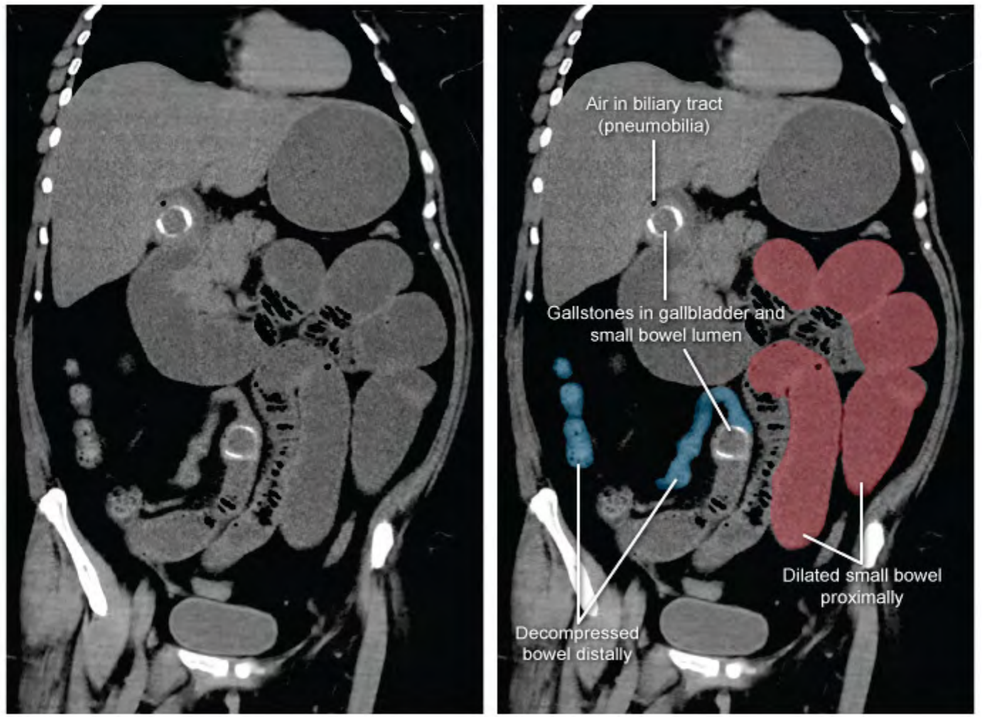

©UWorld

Zoom In | Zoom Out | Reset | New | Existing | My Notebook

https://t.me/USMLEWorldStep1

loops) and **decompression of bowel distal** to the obstruction (eg, decompressed distal ileum). Patients with SBO typical

Comm
the dia
assess
perfora

This p
inguina
Incarc
surgica

(Choi
(eg, at
pneum

(Choi
obstru
infancy

(Choi
but CT
hernia

(Choi
wall fo
perista

Educa
Small
intestinal intraluminal contents. A herniated bowel loop (eg, inguinal hernia) can cause SBO if it becomes trapped (ie, incarcerated) outside the peritoneal cavity.

Exhibit Display

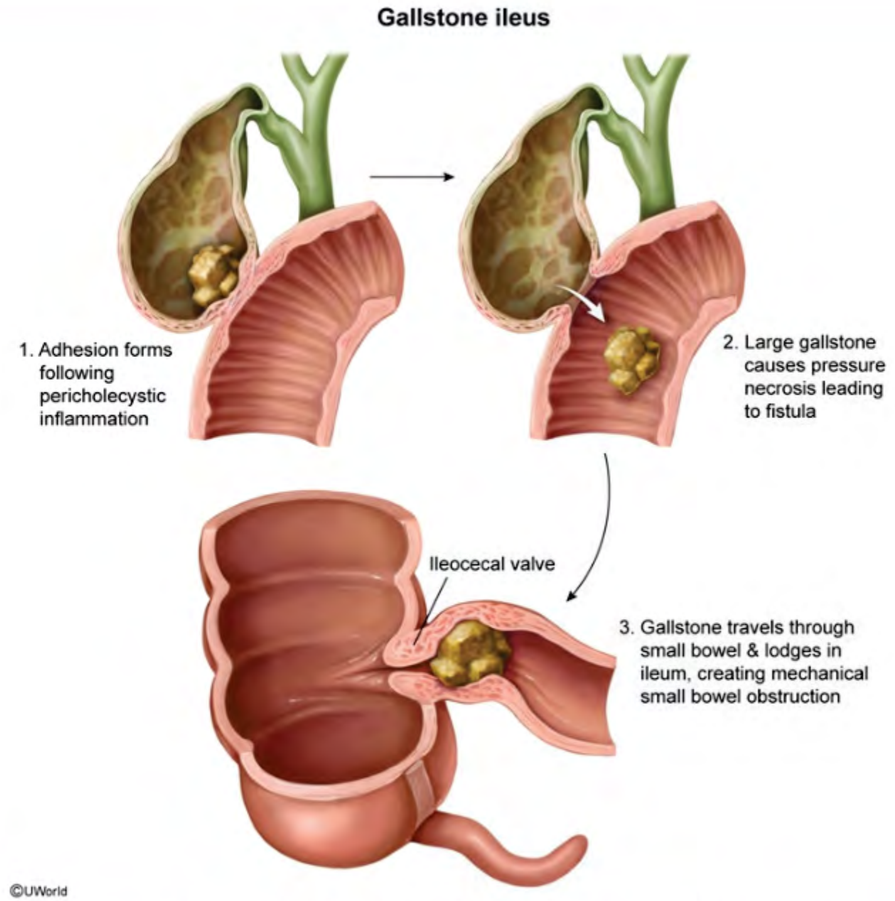

Zoom In Zoom Out Reset New | Existing My Notebook

https://t.me/USMLEWorldStep1

loops) and **decompression of bowel distal** to the obstruction (eg, decompressed distal ileum). Patients with SBO typical

Comm
the dia
assess
perfor

This p
inguin
Incarc
surgic

(Choi
(eg, at
pneum

(Choi
obstru
infanc

(Choi
but CT
hernia

(Choi
wall fo
perist

Educa
Small
intestinal intraluminal contents. A herniated bowel loop (eg, inguinal hernia) can cause SBO if it becomes trapped (ie, incarcerated) outside the peritoneal cavity.

Exhibit Display

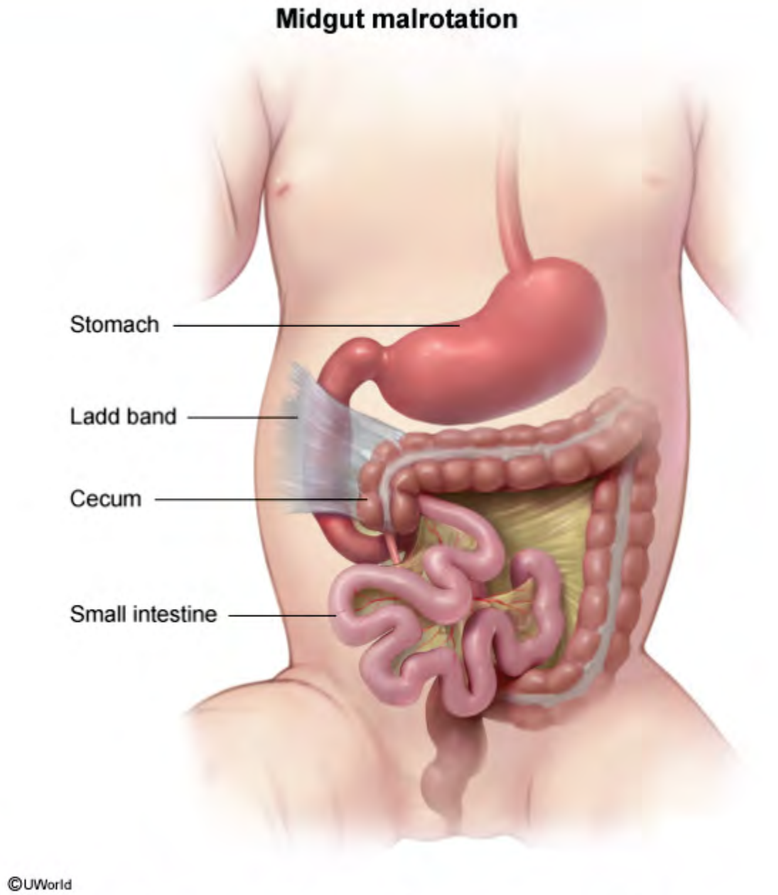

Zoom In | Zoom Out | Reset | New | Existing | My Notebook

https://t.me/USMLEWorldStep1

loops) and **decompression of bowel distal** to the obstruction (eg, decompressed distal ileum). Patients with SBO typical

Comm
the dia
assess
perfor

This p
inguin
Incarc
surgic

(Choi
(eg, at
pneum

(Choi
obstru
infanc

(Choi
but CT
hernia

(Choi
wall fo
perist

Educa
Small
intestinal intraluminal contents. A herniated bowel loop (eg, inguinal hernia) can cause SBO if it becomes trapped (ie, incarcerated) outside the peritoneal cavity.

Exhibit Display

Cecal volvulus

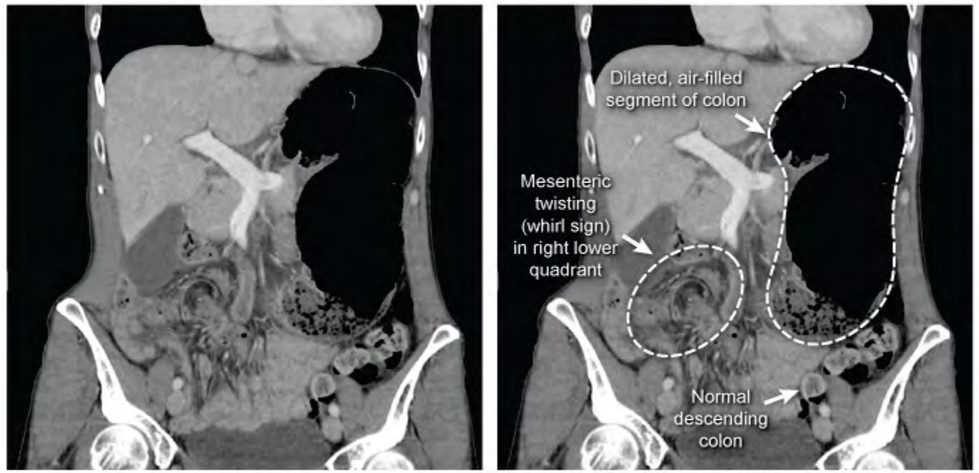

©UWorld

Zoom In | Zoom Out | Reset | New | Existing | My Notebook

https://t.me/USMLEWorldStep1

A 63-year-old woman dies of congestive heart failure. Autopsy shows a dilated heart with brownish pigmentation of the myocardium. Light microscopy of her liver after Prussian blue staining is shown in the image below:

The patient's brother died of profuse upper gastrointestinal bleeding at age 43. Assuming this patient's disorder is hereditary, which of the following most likely contributed to the delayed onset of her disease compared to her brother?

- A. Heterozygosity for *HFE* gene mutation
- B. High-dose vitamin C intake
- C. Incomplete penetrance of homozygotic *HFE* mutations
- D. Premenopausal menstrual bleeding
- E. Receipt of blood transfusions

Submit

https://t.me/USMLEWorldStep1

A 63-year-old woman dies of congestive heart failure. Autopsy shows a dilated heart with brownish pigmentation of the my

Exhibit Display

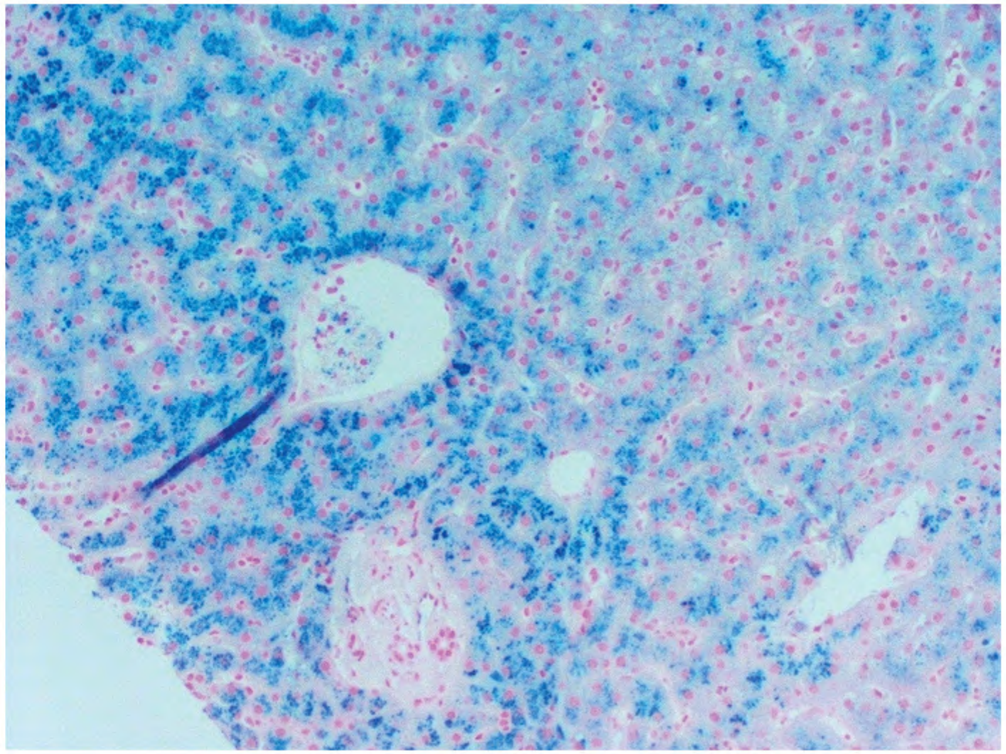

Zoom In | Zoom Out | Reset | New | Existing | My Notebook

The pa
heredi
brothe

C. Incomplete penetrance of homozygotic *HFE* mutations

https://t.me/USMLEWorldStep1

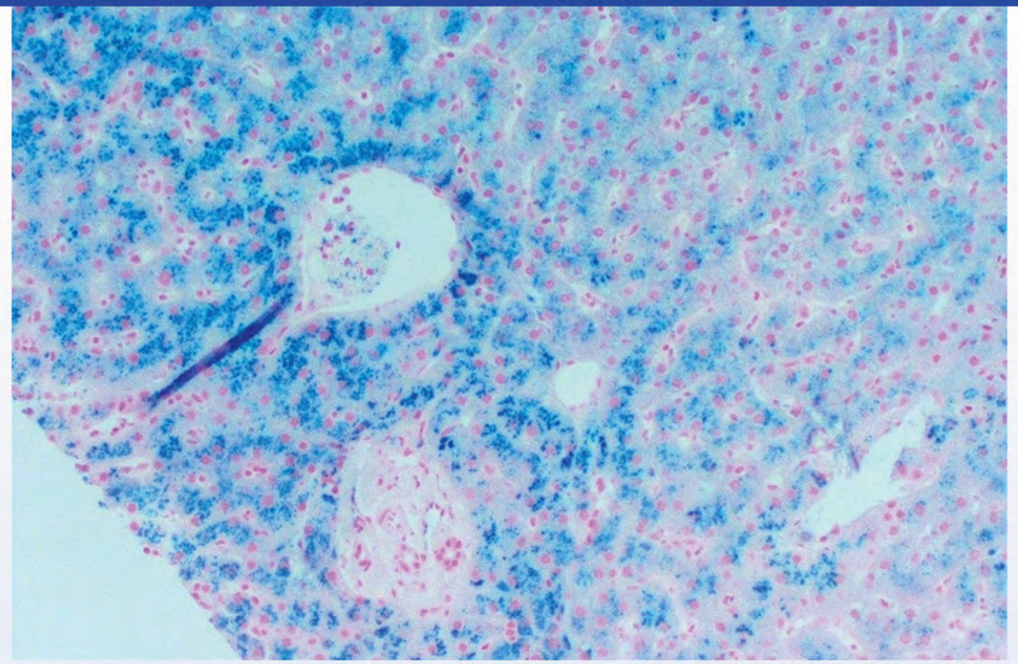

The patient's brother died of profuse upper gastrointestinal bleeding at age 43. Assuming this patient's disorder is hereditary, which of the following most likely contributed to the delayed onset of her disease compared to her brother?

- A. Heterozygosity for *HFE* gene mutation
- B. High-dose vitamin C intake
- C. Incomplete penetrance of homozygotic *HFE* mutations
- D. Premenopausal menstrual bleeding
- E. Receipt of blood transfusions

Submit

https://t.me/USMLEWorldStep1

B. High-dose vitamin C intake (0%)

Exhibit Display

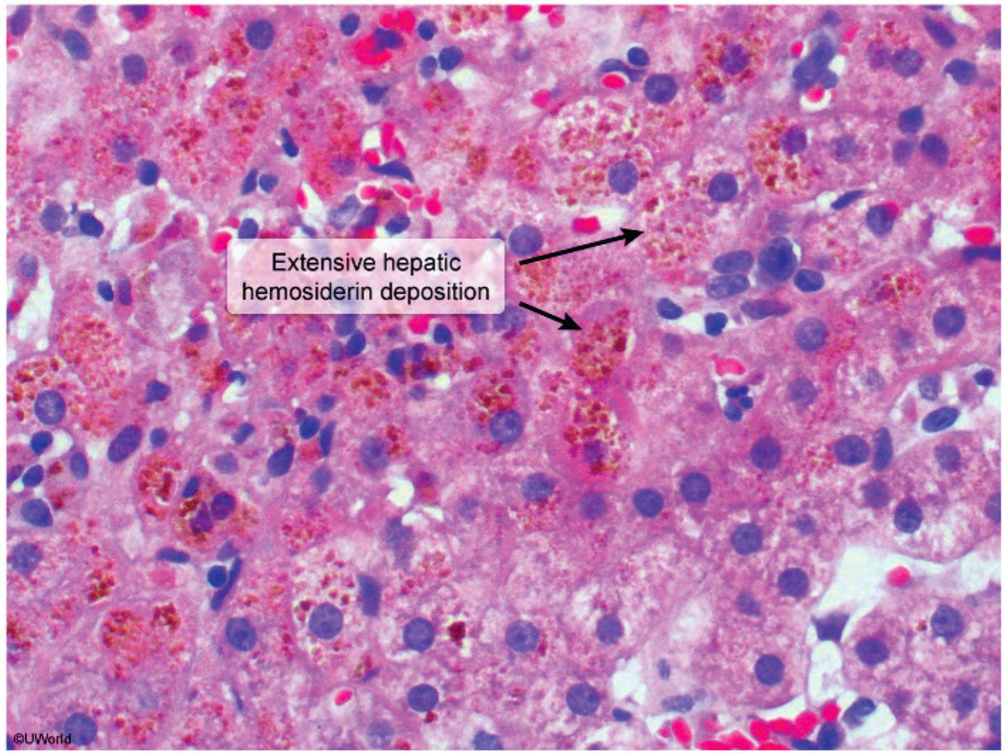

Zoom In | Zoom Out | Reset | New | Existing | My Notebook

https://t.me/USMLEWorldStep1

This patient has cardiomyopathy with visible brown discoloration, which could represent lipofuscin (age-related pigment) or hemosiderin (iron deposition). However, her liver specimen shows diffuse infiltration of iron (visible as blue pigment granules after **Prussian blue** staining), confirming a diagnosis of iron overload. Given that her brother likely developed cirrhosis complicated by variceal hemorrhage in his 40s, the most probable underlying cause is **hereditary hemochromatosis (HH)**.

Total iron stores in the body are tightly regulated at the point of intake, with gastrointestinal absorption adjusted to match daily losses. HH is an autosomal recessive disorder characterized by **increased intestinal iron absorption**; because there is no specific mechanism to excrete unneeded iron, the excess iron (typically 0.5-1.0 g/yr) accumulates in the parenchymal organs (eg, liver, heart).

HH is usually silent in early adulthood, manifesting only after >20 g of iron has accumulated in the body. Men typically begin to develop symptoms in their 30s and 40s. However, **premenopausal women** have ongoing **blood (and iron) losses** due to **menstruation**, which partially offsets the excess iron absorption. Women therefore **develop manifestations later**, typically several years after menopause (ie, variable expressivity based on sex).

(Choices A and C) Most patients with HH have inactivating mutations in the *HFE* gene that cause impaired hepcidin secretion. Disease development requires biallelic genetic mutations (ie, affecting both alleles); heterozygotes are unaffected. Although biallelic *HFE* inactivation is necessary to develop the condition, most patients (>70%) with biallelic mutations never develop HH (ie, the disease exhibits incomplete penetrance) due to genetic and environmental modifiers. However, this patient developed HH manifestations at a typical age for women, which would not be explained by heterozygosity or incomplete penetrance.

(Choice B) Ascorbic acid (vitamin C) and citric acid enhance the absorption of inorganic iron in the gastrointestinal tract and therefore might lead to earlier disease manifestations instead of slowing its onset.

(Choice E) Frequent blood transfusions can also lead to iron overload and hemosiderosis (iron accumulation in parenchymal tissues). The opposite, therapeutic phlebotomy, is the preferred treatment for HH and has been shown to slow its progression.

Educational objective:
Hereditary hemochromatosis is characterized by increased intestinal iron absorption with deposition of excess iron in parenchymal tissues. Men typically develop manifestations in their 30s and 40s. However, premenopausal

https://t.me/USMLEWorldStep1

brother likely developed cirrhosis complicated by variceal hemorrhage in his 40s, the most probable underlying cause is **hereditary hemochromatosis (HH)**.

Total iron stores in the body are tightly regulated at the point of intake, with gastrointestinal absorption adjusted to match daily losses. HH is an autosomal recessive disorder characterized by **increased intestinal iron absorption**; because there is no specific mechanism to excrete unneeded iron, the excess iron (typically 0.5-1.0 g/yr) accumulates in the parenchymal organs (eg, liver, heart).

HH is usually silent in early adulthood, manifesting only after >20 g of iron has accumulated in the body. Men typically begin to develop symptoms in their 30s and 40s. However, **premenopausal women** have ongoing **blood (and iron) losses** due to **menstruation**, which partially offsets the excess iron absorption. Women therefore **develop manifestations later**, typically several years after menopause (ie, variable expressivity based on sex).

(Choices A and C) Most patients with HH have inactivating mutations in the *HFE* gene that cause impaired hepcidin secretion. Disease development requires biallelic genetic mutations (ie, affecting both alleles); heterozygotes are unaffected. Although biallelic *HFE* inactivation is necessary to develop the condition, most patients (>70%) with biallelic mutations never develop HH (ie, the disease exhibits incomplete penetrance) due to genetic and environmental modifiers. However, this patient developed HH manifestations at a typical age for women, which would not be explained by heterozygosity or incomplete penetrance.

(Choice B) Ascorbic acid (vitamin C) and citric acid enhance the absorption of inorganic iron in the gastrointestinal tract and therefore might lead to earlier disease manifestations instead of slowing its onset.

(Choice E) Frequent blood transfusions can also lead to iron overload and hemosiderosis (iron accumulation in parenchymal tissues). The opposite, therapeutic phlebotomy, is the preferred treatment for HH and has been shown to slow its progression.

Educational objective:
Hereditary hemochromatosis is characterized by increased intestinal iron absorption with deposition of excess iron in parenchymal tissues. Men typically develop manifestations in their 30s and 40s. However, premenopausal women have ongoing blood and iron losses due to menstruation, which partially offsets the excess iron absorption and delays the onset of symptoms.

https://t.me/USMLEWorldStep1

A 46-year-old man is brought to the emergency department by paramedics after an episode of large-volume hematemesis. He was going over some papers at work when he suddenly felt nauseated and started vomiting up bright red blood. Physical examination reveals a palpable spleen. Endoscopy shows bleeding esophageal varices. A liver biopsy performed 2 days later shows no abnormalities. Which of the following is the most likely cause of this patient's condition?

- A. Acetaminophen toxicity
- B. Long-term alcohol consumption
- C. Budd-Chiari syndrome
- D. Constrictive pericarditis
- E. Portal vein thrombosis

Submit

https://t.me/USMLEWorldStep1

A 46-year-old man is brought to the emergency department by paramedics after an episode of large-volume hematemesis. He was going over some papers at work when he suddenly felt nauseated and started vomiting up bright red blood. Physical examination reveals a palpable spleen. Endoscopy shows bleeding esophageal varices. A liver biopsy performed 2 days later shows no abnormalities. Which of the following is the most likely cause of this patient's condition?

- A. Acetaminophen toxicity (3%)
- ✕ B. Long-term alcohol consumption (11%)
- C. Budd-Chiari syndrome (22%)
- D. Constrictive pericarditis (1%)
- ✓ E. Portal vein thrombosis (60%)

Incorrect
Correct answer
E

60%
Answered correctly

04 secs
Time Spent

2023
Version

Explanation

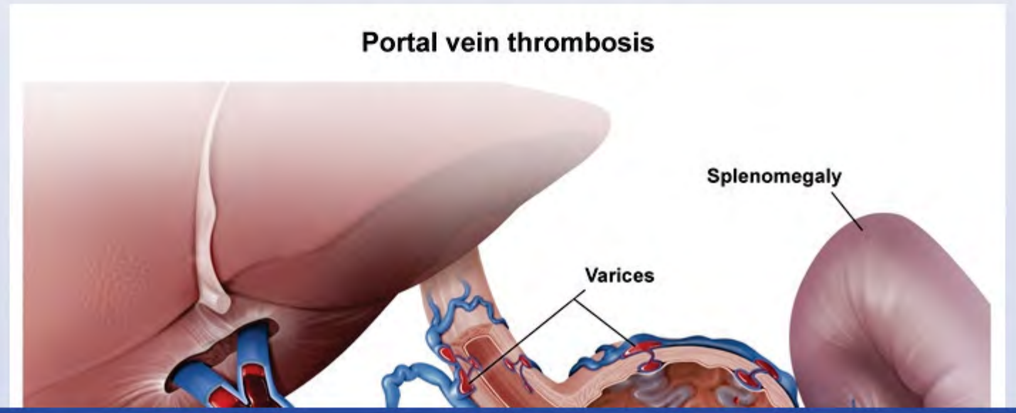

https://t.me/USMLEWorldStep1

A 46-year-old man is brought to the emergency department by paramedics after an episode of large-volume
hemat
bright
varice
cause

Exhibit Display

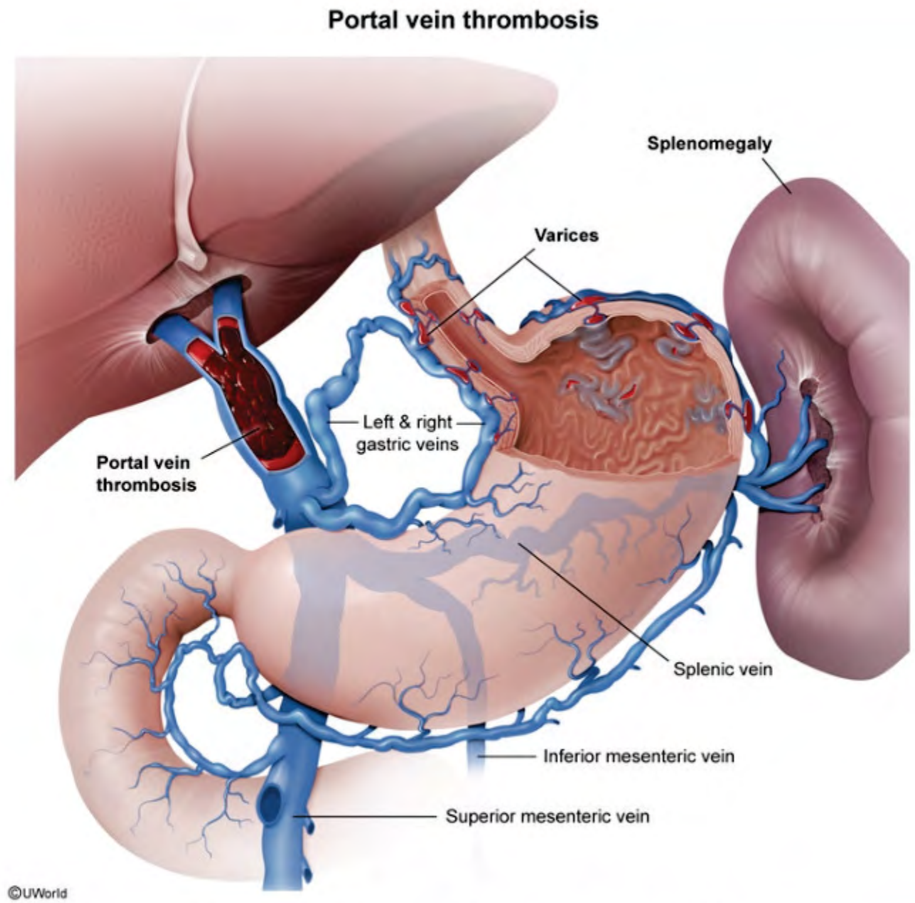

Zoom In | Zoom Out | Reset | New | Existing | My Notebook

https://t.me/USMLEWorldStep1

This patient is exhibiting signs of **portal hypertension**, including esophageal **varices** and **splenic enlargement**. Varices form in portal hypertension due to increased hydrostatic pressure in the portal system that causes blood to be shunted through portocaval anastomoses. This patient's **normal liver biopsy** indicates that a **presinusoidal process** is responsible for the portal hypertension. **Portal vein thrombosis** causes obstruction in portal venous flow upstream to the liver, causing portal hypertension while not affecting the liver parenchyma. **Ascites is uncommon** with portal vein thrombosis since sinusoidal hypertension does not develop.

(Choice A) Acetaminophen toxicity causes centrilobular hepatic necrosis and liver failure 24-48 hours following ingestion, depending on the amount consumed. This process would be obvious on liver biopsy.

(Choice B) Long-term alcohol consumption can causes hepatic cirrhosis, which can cause portal hypertension. However, hepatocyte injury and fibrosis would be evident on liver biopsy. Mallory-Weiss tears can also occur with heavy alcohol use, however, mucosal lacerations (not varices) would be seen on endoscopy.

(Choice C) In Budd-Chiari syndrome, there is occlusion of the hepatic vein, which drains blood from the liver and portal circulation into the systemic circulation. Liver biopsy shows centrilobular congestion and fibrosis.

(Choice D) Constrictive pericarditis causes blood to back up in the systemic venous circulation due to decreased cardiac output. This increases pressure within the liver in much the same way as Budd-Chiari syndrome and would present with similar findings.

Educational objective:
Portal vein thrombosis causes portal hypertension, splenomegaly, and varicosities at portocaval anastomoses. It does not cause histologic changes to the hepatic parenchyma. Ascites is uncommon as the obstruction is presinusoidal; ascites typically only develops in conditions that cause sinusoidal hypertension.

Pathology	Gastrointestinal & Nutrition	Portal vein thrombosis
Subject	System	Topic

Copyright © UWorld. All rights reserved.

https://t.me/USMLEWorldStep1

A 33-year-old primigravida comes to the office to discuss the results of prenatal testing. The patient is at 16 weeks gestation. Maternal serum alpha-fetoprotein is reduced, and ultrasound reveals increased nuchal translucency. Amniocentesis shows a fetal karyotype of 47,XX,+21. This fetus is at greatest risk of having which of the following embryologic malformations?

- A. Failed closure of the neural tube
- B. Failure of recanalization within the intestines
- C. Herniation of bowel through the anterior abdominal wall
- D. Hypertrophy of the muscular layers of the pylorus
- E. Incomplete division of the forebrain

Submit

https://t.me/USMLEWorldStep1

A 33-year-old primigravida comes to the office to discuss the results of prenatal testing. The patient is at 16 weeks gestation. Maternal serum alpha-fetoprotein is reduced, and ultrasound reveals increased nuchal translucency. Amniocentesis shows a fetal karyotype of 47,XX,+21. This fetus is at greatest risk of having which of the following embryologic malformations?

- A. Failed closure of the neural tube (8%)
- ✓ B. Failure of recanalization within the intestines (47%)
- ✗ C. Herniation of bowel through the anterior abdominal wall (24%)
- D. Hypertrophy of the muscular layers of the pylorus (15%)
- E. Incomplete division of the forebrain (4%)

Incorrect
Correct answer
B

47%
Answered correctly

03 secs
Time Spent

2023
Version

Explanation

Down syndrome comorbidities	
Neurologic	• Intellectual disability • Early-onset Alzheimer disease
Cardiac	• Complete atrioventricular septal defect • Ventricular septal defect • Atrial septal defect
Gastrointestinal	• Duodenal atresia • Hirschsprung disease
	• Hypothyroidism

https://t.me/USMLEWorldStep1

Down syndrome comorbidities	
Neurologic	• Intellectual disability • Early-onset Alzheimer disease
Cardiac	• Complete atrioventricular septal defect • Ventricular septal defect • Atrial septal defect
Gastrointestinal	• Duodenal atresia • Hirschsprung disease
Endocrine	• Hypothyroidism • Type 1 diabetes mellitus • Obesity • Short stature
Oncologic	• Acute leukemia
Orthopedic	• Atlantoaxial instability

Down syndrome (trisomy 21) is the most common trisomy in liveborn infants. The diagnosis is often suspected following abnormal prenatal screening (eg, **increased nuchal translucency** on ultrasound, **decreased maternal serum alpha-fetoprotein** [AFP]) and confirmed by chorionic villous sampling or amniocentesis. Most cases are caused by maternal meiotic nondisjunction, which results in 3 complete fetal copies of chromosome 21. The risk for meiotic nondisjunction increases with maternal age, and women age ≥35 are at highest risk.

The most common gastrointestinal abnormality associated with Down syndrome is **duodenal atresia**. Normally, in early gestation, epithelial proliferation briefly occludes the intestinal lumen and is followed by recanalization. **Failure** of the duodenal lumen **to recanalize** results in duodenal atresia and intestinal obstruction. During the first few days of life, infants classically have bilious emesis, and x-ray findings include the double bubble sign, which represents the dilated stomach and proximal duodenum.

https://t.me/USMLEWorldStep1

Orthopedic	• Atlantoaxial instability

Down syndrome (trisomy 21) is the most common trisomy in liveborn infants. The diagnosis is often suspected following abnormal prenatal screening (eg, **increased nuchal translucency** on ultrasound, **decreased maternal serum alpha-fetoprotein** [AFP]) and confirmed by chorionic villous sampling or amniocentesis. Most cases are caused by maternal meiotic nondisjunction, which results in 3 complete fetal copies of chromosome 21. The risk for meiotic nondisjunction increases with maternal age, and women age ≥35 are at highest risk.

The most common gastrointestinal abnormality associated with Down syndrome is **duodenal atresia**. Normally, in early gestation, epithelial proliferation briefly occludes the intestinal lumen and is followed by recanalization. **Failure** of the duodenal lumen **to recanalize** results in duodenal atresia and intestinal obstruction. During the first few days of life, infants classically have bilious emesis, and x-ray findings include the double bubble sign, which represents the dilated stomach and proximal duodenum.

Patients with Down syndrome are also at risk for imperforate anus and tracheoesophageal fistula.

(Choices A and C) Trisomies 13 and 18 may be associated with an increased risk for open neural tube and ventral wall defects (eg, omphalocele); trisomy 21 does not carry a similar risk. Moreover, these defects are associated with elevated AFP in the second trimester, and this patient's low AFP (consistent with trisomy 21) makes the presence of these defects unlikely.

(Choice D) Pyloric stenosis is caused by hypertrophy of the pylorus and presents at age 3-6 weeks with forceful, nonbilious emesis. Pyloric stenosis is not generally associated with Down syndrome.

(Choice E) Holoprosencephaly is a severe developmental defect of the forebrain (prosencephalon) that is associated with trisomy 13, not trisomy 21.

Educational objective:
Down syndrome (trisomy 21) is associated with decreased maternal serum alpha-fetoprotein and increased nuchal translucency. Duodenal atresia, the most commonly associated gastrointestinal complication, occurs due to failure of duodenal recanalization in early gestation.

Embryology Gastrointestinal & Nutrition Down syndrome

https://t.me/USMLEWorldStep1

Orthopedic	• Atlantoaxial instability

Exhibit Display

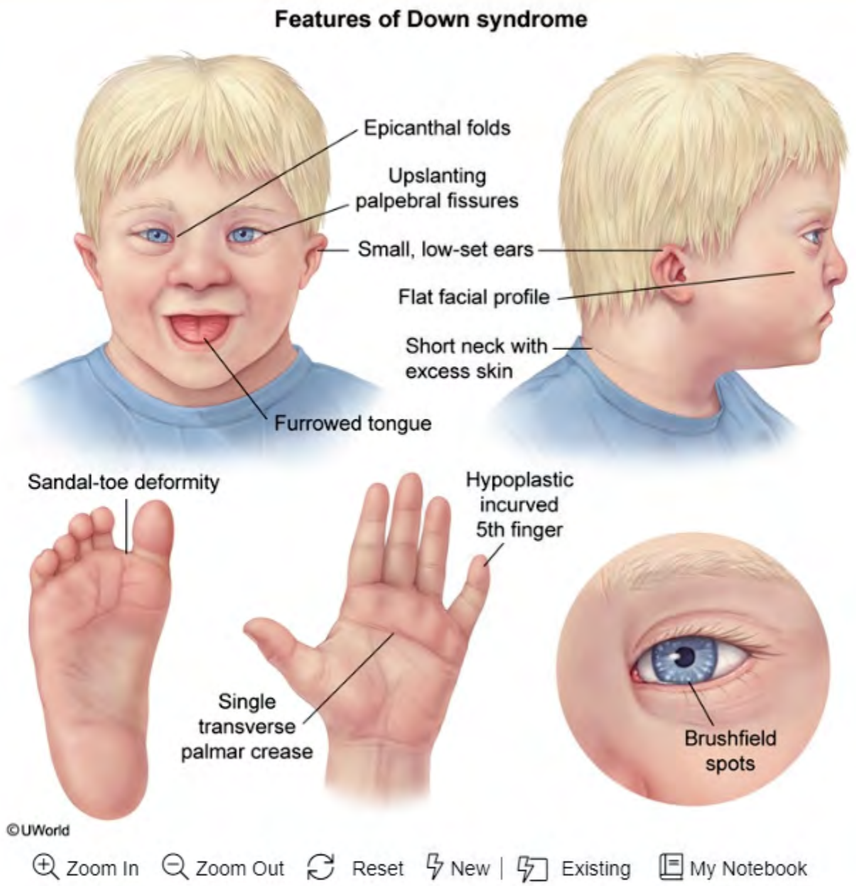

Zoom In | Zoom Out | Reset | New | Existing | My Notebook

Down
followi
serum
cause
for me

The m
early g
Failur
few da
repres

Patien

(Choi
ventra
associ
makes

(Choi
nonbili

(Choi
associ

Educa
Down
translucency. Duodenal atresia, the most commonly associated gastrointestinal complication, occurs due to failure of duodenal recanalization in early gestation.

Embryology | Gastrointestinal & Nutrition | Down syndrome

https://t.me/USMLEWorldStep1

Orthopedic	• Atlantoaxial instability

Exhibit Display

Down
followi
serum
cause
for me

The m
early g
Failur
few da
repres

Patien

(Choi
ventra
associ
makes

(Choi
nonbili

(Choi
associ

Educa
Down
translu
of duo

Duodenal atresia

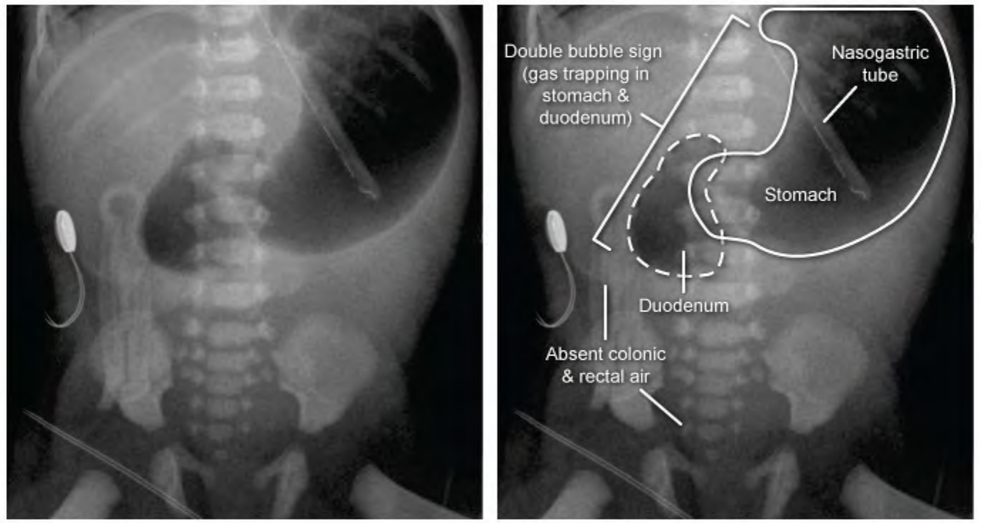

©UWorld

Zoom In | Zoom Out | Reset | New | Existing | My Notebook

Embryology | Gastrointestinal & Nutrition | Down syndrome

https://t.me/USMLEWorldStep1

Orthopedic	• Atlantoaxial instability

Down
followi
serum
cause
for me

The m
early g
Failur
few da
repres

Patien

(Choi
ventra
associ
makes

(Choi
nonbili

(Choi
associ

Educa
Down
translu
of duo

Exhibit Display

Open spina bifida

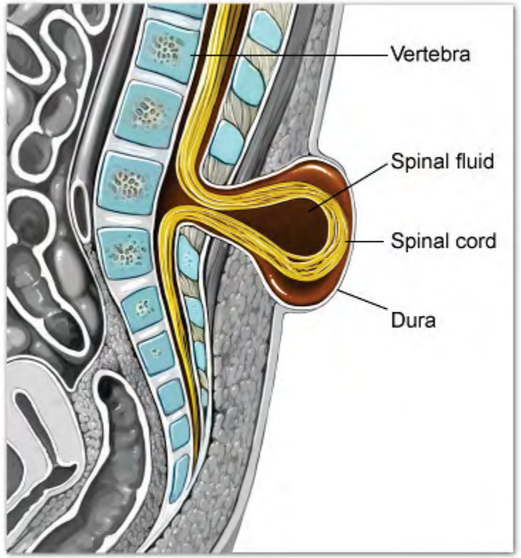

©UWorld

Zoom In | Zoom Out | Reset | New | Existing | My Notebook

Embryology | Gastrointestinal & Nutrition | Down syndrome

https://t.me/USMLEWorldStep1

Orthopedic	• Atlantoaxial instability

Down
follow
serum
cause
for me

The m
early g
Failur
few da
repres

Patien

(Choi
ventra
associ
makes

(Choi
nonbili

(Choi
associ

Educa
Down
translu
of duo

Exhibit Display

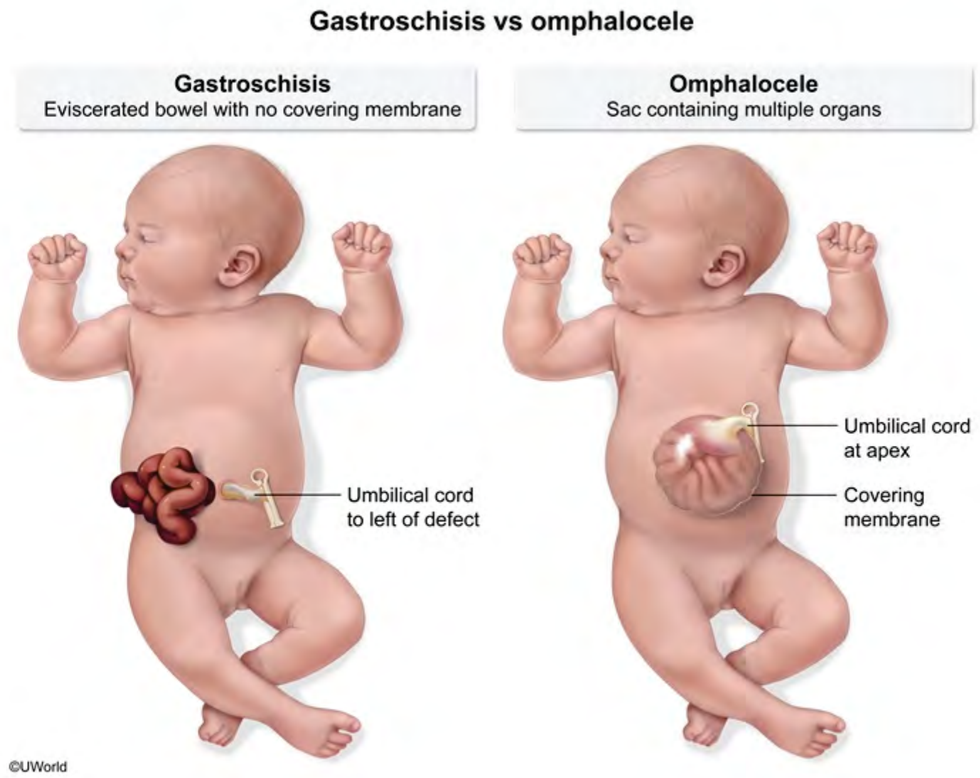

Zoom In Zoom Out Reset New | Existing My Notebook

Embryology Gastrointestinal & Nutrition Down syndrome

https://t.me/USMLEWorldStep1

Orthopedic	• Atlantoaxial instability

Down
followi
serum
cause
for me

The m
early g
Failur
few da
repres

Patien

(Choi
ventra
associ
makes

(Choi
nonbili

(Choi
associ

Educa
Down
translu
of duo

Exhibit Display

Infantile hypertrophic pyloric stenosis

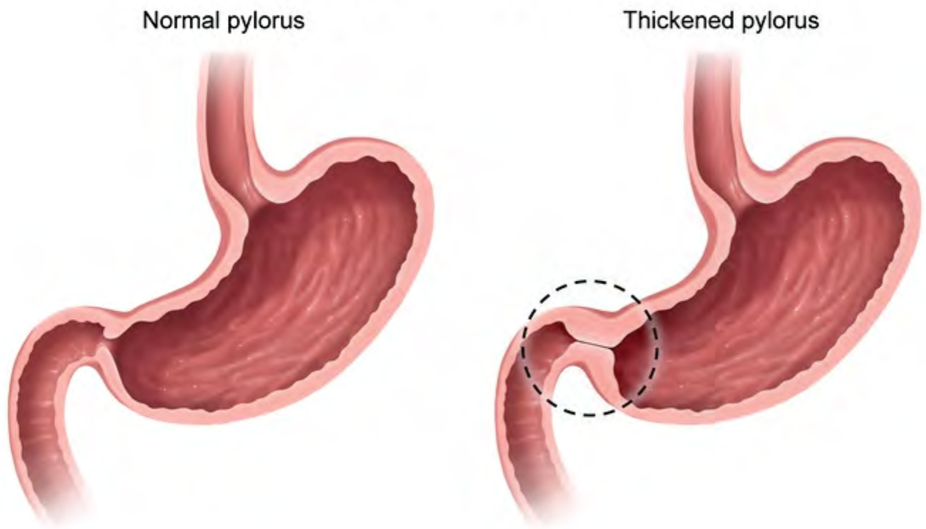

©UWorld

Zoom In | Zoom Out | Reset | New | Existing | My Notebook

Embryology | Gastrointestinal & Nutrition | Down syndrome

https://t.me/USMLEWorldStep1

Orthopedic	• Atlantoaxial instability

Down
followi
serum
cause
for me

The m
early g
Failur
few da
repres

Patien

(Choi
ventra
associ
makes

(Choi
nonbili

(Choi
associ

Educa
Down
translu
of duo

Exhibit Display

Holoprosencephaly spectrum



Median cleft lip/palate

Single-nostril nose, hypotelorism (close-set eyes)

Hypotelorism, proboscis (nonfunctioning nasal structure)

Single, central orbital fossa, proboscis

©UWorld

Zoom In | Zoom Out | Reset | New | Existing | My Notebook

Embryology | Gastrointestinal & Nutrition | Down syndrome

https://t.me/USMLEWorldStep1

A 62-year-old man comes to the office for evaluation of abdominal swelling. Over the last few weeks his abdomen has become more distended with associated mild discomfort and decreased appetite. Past medical history includes multiple admissions for alcohol-induced pancreatitis. The patient currently drinks 1 pint of liquor daily and does not use tobacco or illicit drugs. Physical examination reveals mildly icteric sclera and multiple spider angiomas on the upper chest. The abdomen is distended and there is dullness to percussion that changes location when the patient lays on either side. Serum sodium is 130 mEq/dL and creatinine is 1.1 mg/dL. Which of the following would most likely be seen in this patient?

	Serum antidiuretic hormone	Urine sodium	Total body volume
A.	↑	↓	↑
B.	↑	↓	↓
C.	↑	↑	normal
D.	↓	↑	normal
E.	↑	↑	↓

Submit

https://t.me/USMLEWorldStep1

A 62-year-old man comes to the office for evaluation of abdominal swelling. Over the last few weeks his abdomen has become more distended with associated mild discomfort and decreased appetite. Past medical history includes multiple admissions for alcohol-induced pancreatitis. The patient currently drinks 1 pint of liquor daily and does not use tobacco or illicit drugs. Physical examination reveals mildly icteric sclera and multiple spider angiomas on the upper chest. The abdomen is distended and there is dullness to percussion that changes location when the patient lays on either side. Serum sodium is 130 mEq/dL and creatinine is 1.1 mg/dL. Which of the following would most likely be seen in this patient?

	Serum antidiuretic hormone	Urine sodium	Total body volume	
✓ A.	↑	↓	↑	(62%)
✗ B.	↑	↓	↓	(3%)
C.	↑	↑	normal	(20%)
D.	↓	↑	normal	(8%)
E.	↑	↑	↓	(4%)

Incorrect
Correct answer
A

62%
Answered correctly

03 secs
Time Spent

2023
Version

Explanation

Pathogenesis of ascites in cirrhosis

https://t.me/USMLEWorldStep1

A 62-year-old man comes to the office for evaluation of abdominal swelling. Over the last few weeks his abdomen has be
include
does r
angior
when
followi

Exhibit Display

Pathogenesis of ascites in cirrhosis

Portal hypertension

↑ Local vasodilators

Splanchnic vasodilation

↓ Systemic pressure & renal hypoperfusion

Activation of RAAS

Sodium & water retention

↑ Splanchnic hydrostatic pressure

Low oncotic pressure from hypoalbuminemia

Ascites

RAAS = renin-angiotensin-aldosterone system.

©UWorld

Zoom In | Zoom Out | Reset | New | Existing | My Notebook

Inco
Corre
A

Expl

https://t.me/USMLEWorldStep1

RAAS = renin-angiotensin-aldosterone system. ©UWorld

This patient with a history of heavy alcohol use, abdominal swelling with shifting dullness to percussion (indicative of intraabdominal fluid), and stigmata of chronic liver disease (eg, spider angiomas, jaundice) has **ascites** due to cirrhosis. **Cirrhosis** occurs from progressive hepatic fibrosis, resulting **portal hypertension** due to increased sinusoidal blood flow resistance. There is also increased formation of vasodilatory factors (eg, nitric oxide), possibly due to bacterial products (eg, endotoxins) that accumulate because of reduced host defenses and increased portosystemic shunting. This results in the following hemodynamic alterations:

- Reduced systemic vascular resistance along with blood pooling in the splanchnic vascular bed leads to reduced blood pressure. Heart rate and cardiac output increase to compensate (hyperdynamic circulation).
- Reduced renal perfusion leads to activation of the renin-angiotensin-aldosterone system (RAAS) and **increased release of antidiuretic hormone (ADH)** in an effort to restore circulating volume.
- The combined aldosterone and ADH effects lead to **increased renal resorption of sodium** (ie, lower urine sodium) and water.

Although this restores renal perfusion, the resistance to splanchnic flow and hyperdynamic circulation promotes third-spacing of fluids into the abdominal cavity (ie, ascites) and interstitium (ie, edema). This is compounded by low serum oncotic pressure due to hypoalbuminemia from liver synthetic dysfunction. Therefore, despite **increased total body volume**, patients with cirrhosis remain intravascularly depleted and continue to release hypovolemic hormones. Eventually, the resultant elevated ADH secretion can lead to **hypervolemic hyponatremia**, which is common in patients with advanced cirrhosis.

(Choices B, C, D, and E) Splanchnic vasodilation results in renal hypoperfusion, stimulating increased ADH secretion and activation of the RAAS. This leads to increased renal resorption of sodium, lowering the urinary sodium concentration. Third-spacing of fluid results in increased total body volume.

Educational objective:
Portal hypertension in cirrhosis leads to vasodilation and decreased systemic perfusion pressure, which causes antidiuretic hormone release and activation of the renin-angiotensin-aldosterone system, promoting sodium and water retention. However, due to resistance to splanchnic flow, low oncotic pressure, and hyperdynamic

https://t.me/USMLEWorldStep1

of intraabdominal fluid), and stigmata of chronic liver disease (eg, spider angiomas, jaundice) has **ascites** due to cirrhosis. **Cirrhosis** occurs from progressive hepatic fibrosis, resulting **portal hypertension** due to increased sinusoidal blood flow resistance. There is also increased formation of vasodilatory factors (eg, nitric oxide), possibly due to bacterial products (eg, endotoxins) that accumulate because of reduced host defenses and increased portosystemic shunting. This results in the following hemodynamic alterations:

- Reduced systemic vascular resistance along with blood pooling in the splanchnic vascular bed leads to reduced blood pressure. Heart rate and cardiac output increase to compensate (hyperdynamic circulation).
- Reduced renal perfusion leads to activation of the renin-angiotensin-aldosterone system (RAAS) and **increased release of antidiuretic hormone (ADH)** in an effort to restore circulating volume.
- The combined aldosterone and ADH effects lead to **increased renal resorption of sodium** (ie, lower urine sodium) and water.

Although this restores renal perfusion, the resistance to splanchnic flow and hyperdynamic circulation promotes third-spacing of fluids into the abdominal cavity (ie, ascites) and interstitium (ie, edema). This is compounded by low serum oncotic pressure due to hypoalbuminemia from liver synthetic dysfunction. Therefore, despite **increased total body volume**, patients with cirrhosis remain intravascularly depleted and continue to release hypovolemic hormones. Eventually, the resultant elevated ADH secretion can lead to **hypervolemic hyponatremia**, which is common in patients with advanced cirrhosis.

(Choices B, C, D, and E) Splanchnic vasodilation results in renal hypoperfusion, stimulating increased ADH secretion and activation of the RAAS. This leads to increased renal resorption of sodium, lowering the urinary sodium concentration. Third-spacing of fluid results in increased total body volume.

Educational objective:
Portal hypertension in cirrhosis leads to vasodilation and decreased systemic perfusion pressure, which causes antidiuretic hormone release and activation of the renin-angiotensin-aldosterone system, promoting sodium and water retention. However, due to resistance to splanchnic flow, low oncotic pressure, and hyperdynamic circulation, the fluid is third-spaced into the extravascular compartments (eg, ascites). Therefore, despite increased total body volume, patients with cirrhosis remain intravascularly volume depleted.

References

https://t.me/USMLEWorldStep1

of intraabdominal fluid), and stigmata of chronic liver disease (eg, spider angiomas, jaundice) has **ascites** due to cirrhosis. **Cirrhosis** occurs from progressive hepatic fibrosis, resulting **portal hypertension** due to increased sinusoi possib increa

- R re
- R in
- T s

Althou third-s low se **increa** hypov **hypor**

(Choi secret sodiur

Educa Portal antidiu water circula increased total body volume, patients with cirrhosis remain intravascularly volume depleted.

References

Exhibit Display

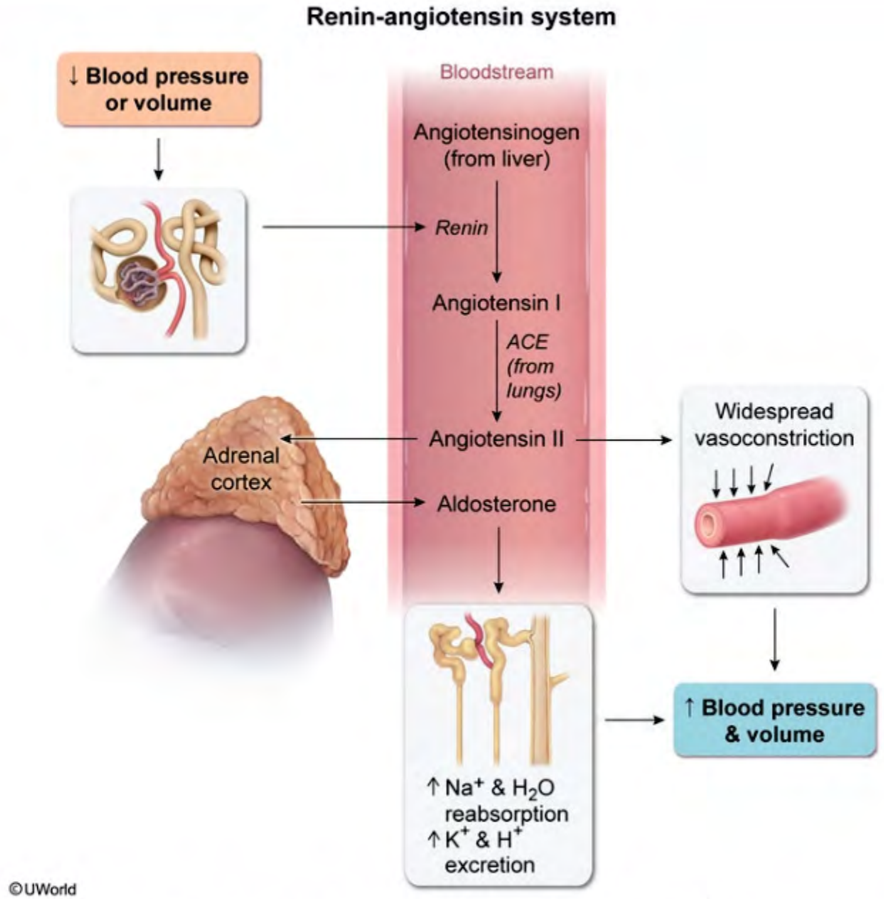

Zoom In | Zoom Out | Reset | New | Existing | My Notebook

https://t.me/USMLEWorldStep1

A 24-year-old, previously healthy woman comes to the emergency department due to hematemesis. The patient was binge drinking when she became very nauseated and began vomiting repeatedly. She reports vomiting approximately a cupful of bright red blood during the most recent episode. Blood pressure is 136/78 mm Hg and pulse is 96/min. Physical examination shows mild epigastric tenderness. Endoscopy reveals a longitudinal mucosal laceration in the distal esophagus with active bleeding. Endoscopic treatment is performed, but the bleeding recurs. Angiography with transarterial embolization of the bleeding vessel is planned. A distal branch of which of the following blood vessels is most likely to be embolized during this patient's procedure?

- A. Internal thoracic artery
- B. Left gastric artery
- C. Splenic artery
- D. Superior mesenteric artery
- E. Thoracic aorta

Submit

https://t.me/USMLEWorldStep1

A 24-year-old, previously healthy woman comes to the emergency department due to hematemesis. The patient was binge drinking when she became very nauseated and began vomiting repeatedly. She reports vomiting approximately a cupful of bright red blood during the most recent episode. Blood pressure is 136/78 mm Hg and pulse is 96/min. Physical examination shows mild epigastric tenderness. Endoscopy reveals a longitudinal mucosal laceration in the distal esophagus with active bleeding. Endoscopic treatment is performed, but the bleeding recurs. Angiography with transarterial embolization of the bleeding vessel is planned. A distal branch of which of the following blood vessels is most likely to be embolized during this patient's procedure?

- A. Internal thoracic artery (3%)
- ✓ B. Left gastric artery (81%)
- C. Splenic artery (5%)
- D. Superior mesenteric artery (2%)
- E. Thoracic aorta (6%)

Correct

81% Answered correctly

03 secs Time Spent

2023 Version

Explanation

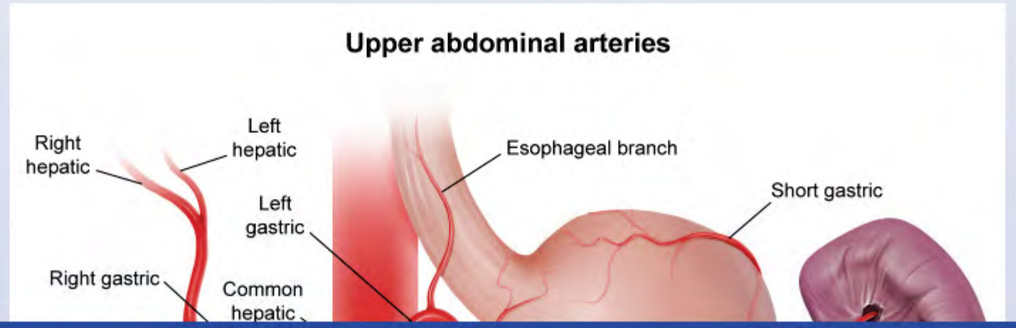

https://t.me/USMLEWorldStep1

A 24-year-old, previously healthy woman comes to the emergency department due to hematemesis. The patient was bi
approx
pulse i
mucos
bleedi
which

Cor

Expl

Exhibit Display

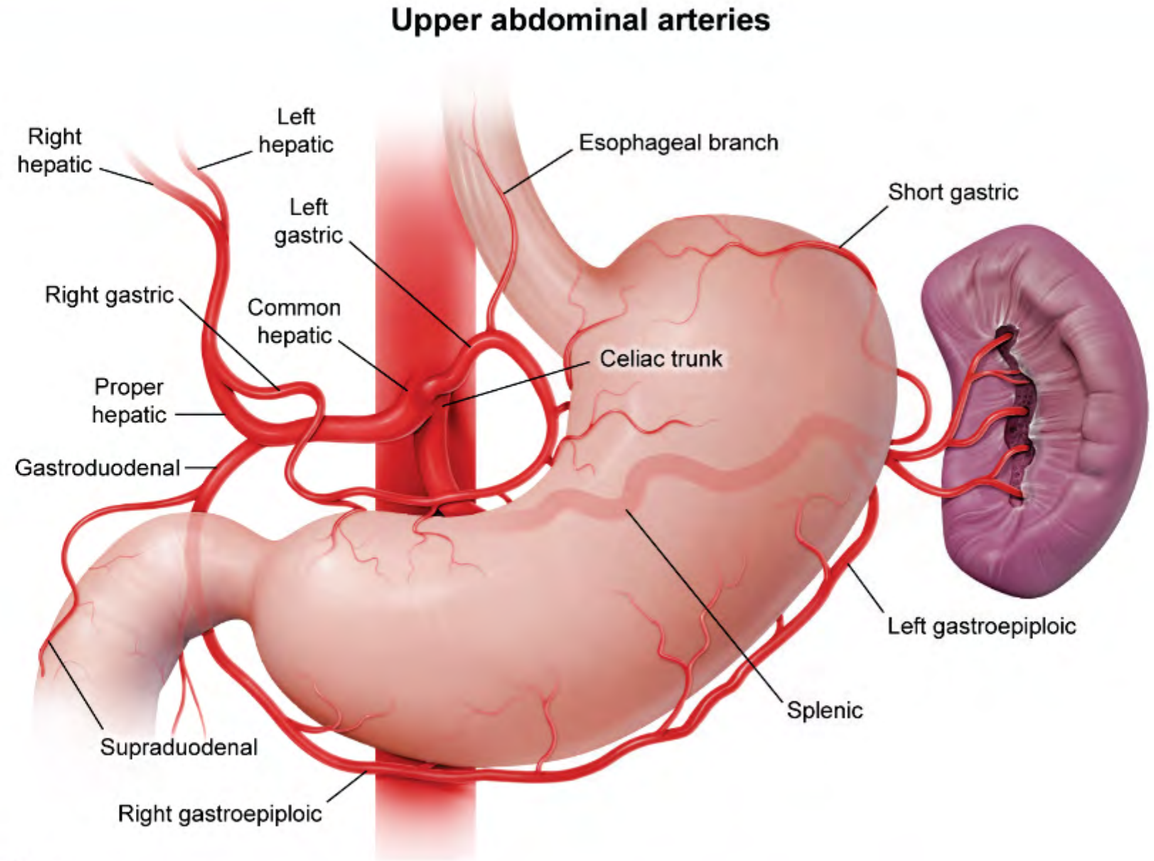

Zoom In | Zoom Out | Reset | New | Existing | My Notebook

https://t.me/USMLEWorldStep1

This patient has a mucosal laceration of the distal esophagus (**Mallory-Weiss tear**). It typically occurs during episodes of severe retching, which can raise intraabdominal pressure high enough to tear the superficial layers of the distal esophagus. Mallory-Weiss tears cause **hematemesis**, which is often self-limited, although severe bleeding may require endoscopy and/or angiography.

Arterial embolization in this patient should target branches of the **left gastric artery**, which arises from the celiac trunk and provides the primary arterial supply to the **distal esophagus**. Branches of the left inferior phrenic artery may also perfuse the distal esophagus but are a minor contributor.

More proximal segments of the esophagus are served by other primary arteries. The proximal esophagus receives arterial blood from branches of the inferior thyroid artery, whereas the midesophagus is supplied by branches of the thoracic aorta.

(Choice A) The internal thoracic artery (internal mammary artery) is derived from the subclavian artery and travels just deep to the anterior chest wall. Its terminal branches are the musculophrenic artery and the superior epigastric artery. The internal thoracic artery supplies the anterior chest wall and breasts but does not supply the esophagus.

(Choice C) In addition to the left gastric artery, the other major branches of the celiac trunk include the common hepatic and splenic arteries. The splenic artery is a tortuous vessel that runs posterior to the stomach and supplies the spleen but does not perfuse the esophagus.

(Choice D) The superior mesenteric artery branches directly from the abdominal aorta and provides arterial supply to the duodenum, small intestines, and proximal two-thirds of the colon (up to the splenic flexure). It does not supply the esophagus.

(Choice E) The midesophagus receives arterial blood from branches of the thoracic aorta; this patient's tear involves the distal esophagus, so these branches would not require embolization.

Educational objective:
Forceful retching can lead to superficial mucosal lacerations (eg, Mallory-Weiss tears) of the distal esophagus, an area that receives most of its arterial blood supply from branches of the left gastric artery. The proximal esophagus receives arterial blood from the inferior thyroid artery, whereas the midesophagus is supplied by branches of the thoracic aorta.

https://t.me/USMLEWorldStep1

This patient has a mucosal laceration of the distal esophagus (**Mallory-Weiss tear**). It typically occurs during episodes of severe retching, which can raise intraabdominal pressure high enough to tear the superficial layers of the dis
bleedi

Arteria
trunk a
may a

More p
arteria
thorac

(Choi
just de
artery.

(Choi
hepati
the sp

(Choi
to the
supply

(Choi
involve

Educa
Forcef
area th
receiv
thoracic aorta.

Exhibit Display

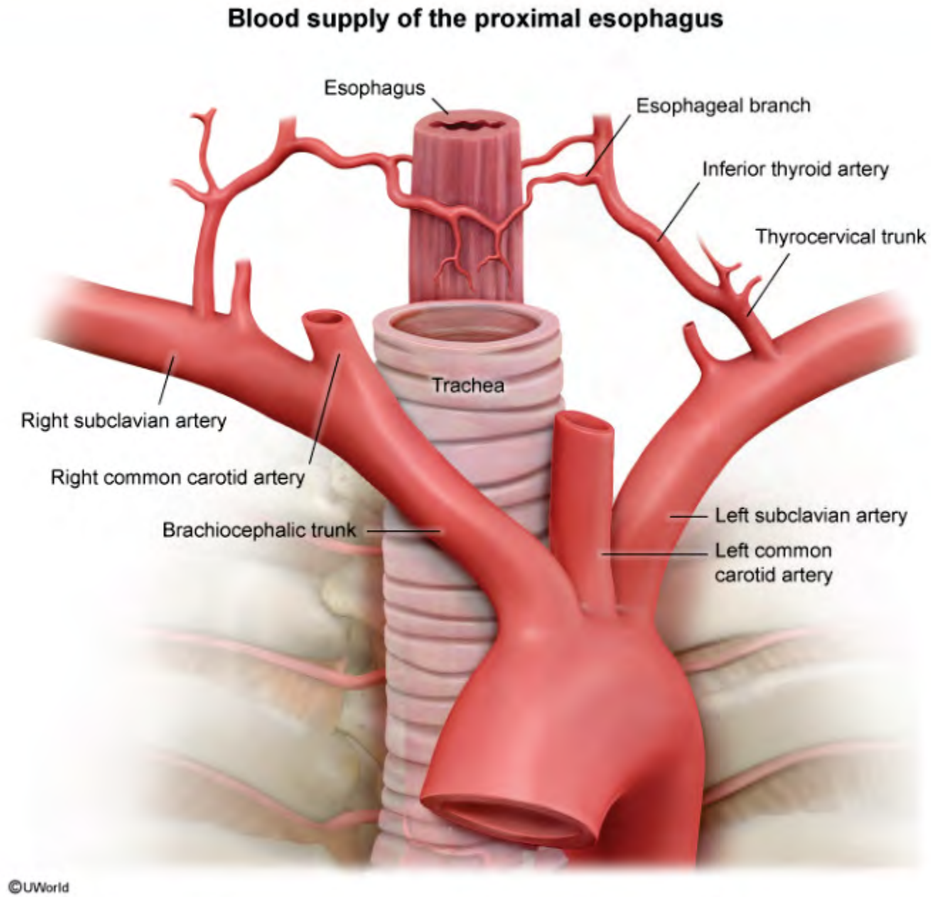

Zoom In Zoom Out Reset New | Existing My Notebook

https://t.me/USMLEWorldStep1

This patient has a mucosal laceration of the distal esophagus (**Mallory-Weiss tear**). It typically occurs during episodes of severe retching, which can raise intraabdominal pressure high enough to tear the superficial layers of the dis
bleedi

Arteria
trunk a
may a

More p
arteria
thorac

(Choi
just de
artery.

(Choi
hepati
the sp

(Choi
to the
supply

(Choi
involve

Educa
Forcef
area th
receiv
thoracic aorta.

Exhibit Display

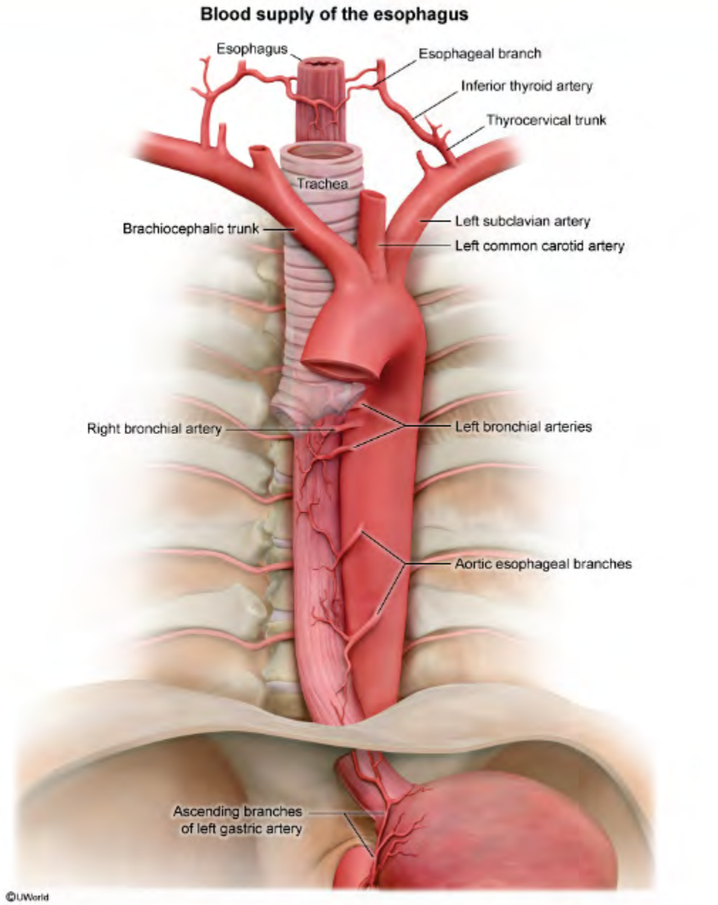

Zoom In | Zoom Out | Reset | New | Existing | My Notebook

https://t.me/USMLEWorldStep1

An 8-year-old boy with acute lymphoblastic leukemia receiving maintenance chemotherapy is hospitalized due to fever and neutropenia. Treatment with broad spectrum intravenous antibiotics is begun and the patient's fever resolves. His neutrophil count increases with granulocyte colony-stimulating factor therapy and blood cultures remain negative. On day 5 of hospitalization, the patient experiences nausea, abdominal cramping, and 6-8 episodes of watery diarrhea. Temperature is 37.7 C (99.9 F). Physical examination shows mild lower abdominal tenderness without guarding or rebound tenderness. Stool testing for occult blood is negative. Which of the following is the single best stool test to establish the cause of this patient's diarrhea?

- A. Culture on sorbitol-MacConkey agar
- B. Enzyme immunoassay for bacterial antigens
- C. Latex agglutination for viral antigens
- D. Microscopy after modified acid-fast staining
- E. Microscopy for ova and parasites
- F. PCR for a bacterial toxin gene

Submit

https://t.me/USMLEWorldStep1

An 8-year-old boy with acute lymphoblastic leukemia receiving maintenance chemotherapy is hospitalized due to fever and neutropenia. Treatment with broad spectrum intravenous antibiotics is begun and the patient's fever resolves. His neutrophil count increases with granulocyte colony-stimulating factor therapy and blood cultures remain negative. On day 5 of hospitalization, the patient experiences nausea, abdominal cramping, and 6-8 episodes of watery diarrhea. Temperature is 37.7 C (99.9 F). Physical examination shows mild lower abdominal tenderness without guarding or rebound tenderness. Stool testing for occult blood is negative. Which of the following is the single best stool test to establish the cause of this patient's diarrhea?

- A. Culture on sorbitol-MacConkey agar (7%)
- ✗ B. Enzyme immunoassay for bacterial antigens (17%)
- C. Latex agglutination for viral antigens (5%)
- D. Microscopy after modified acid-fast staining (5%)
- E. Microscopy for ova and parasites (4%)
- ✓ F. PCR for a bacterial toxin gene (58%)

Incorrect
Correct answer
F

58%
Answered correctly

04 secs
Time Spent

2023
Version

Explanation

This child who developed profuse watery diarrhea, nausea, and abdominal cramping while on antibiotics should have stool samples evaluated for ***Clostridioides difficile*** infection (CDI).

Diagnostic testing includes:

- **Nucleic acid amplification test** (NAAT): Uses a **polymerase chain reaction** to detect genes present in toxigenic strains (eg, **toxin B**–encoding gene). This test is **highly sensitive and specific** for toxigenic strains but cannot differentiate active CDI from colonization, in which *C difficile* is present without active toxin

https://t.me/USMLEWorldStep1

Explanation

This child who developed profuse watery diarrhea, nausea, and abdominal cramping while on antibiotics should have stool samples evaluated for ***Clostridioides difficile*** infection (CDI).

Diagnostic testing includes:

- **Nucleic acid amplification test** (NAAT): Uses a **polymerase chain reaction** to detect genes present in toxigenic strains (eg, **toxin B**–encoding gene). This test is **highly sensitive and specific** for toxigenic strains but cannot differentiate active CDI from colonization, in which *C difficile* is present without active toxin production.
- **Enzyme immunoassay** (EIA): Uses antibodies to detect *C difficile* antigens or toxins. EIA for bacterial toxins is highly specific but has **poor sensitivity** as large amounts of toxin are required. In contrast, EIA for glutamate dehydrogenase (a bacterial antigen expressed by all *C difficile* isolates) has better sensitivity but cannot distinguish toxin-producing strains.

When clinical symptoms of CDI are present (ie, infection rather than colonization is already suspected), NAAT is considered the most sensitive method for diagnosis of CDI. EIA for bacterial toxins can be added as part of a multistep algorithm to increase specificity of active disease; however, it is not recommended for diagnostic use alone **(Choice B)**.

(Choice A) Culture on sorbitol-MacConkey agar is used to diagnose *Escherichia coli* O157:H7 (ie, enterohemorrhagic *E coli* [EHEC]). EHEC presents with bloody diarrhea; this patient's nonbloody diarrhea and recent antibiotic exposure makes CDI more likely.

(Choice C) Latex agglutination for viral antigens is used to diagnose rotavirus, which causes nonbloody diarrhea, vomiting, and fever; disease can be particularly severe in immunocompromised patients. However, incubation time is typically <48 hours, and it is unlikely that this patient would develop an infection after 5 days in the hospital.

(Choice D) Modified acid-fast staining is used to diagnose cryptosporidium infection, which causes chronic diarrhea (particularly in HIV-infected patients). This patient's current hospitalization and antibiotic use make CDI more likely.

https://t.me/USMLEWorldStep1

- **Enzyme immunoassay** (EIA): Uses antibodies to detect *C difficile* antigens or toxins. EIA for bacterial toxins is highly specific but has **poor sensitivity** as large amounts of toxin are required. In contrast, EIA for glutamate dehydrogenase (a bacterial antigen expressed by all *C difficile* isolates) has better sensitivity but cannot distinguish toxin-producing strains.

When clinical symptoms of CDI are present (ie, infection rather than colonization is already suspected), NAAT is considered the most sensitive method for diagnosis of CDI. EIA for bacterial toxins can be added as part of a multistep algorithm to increase specificity of active disease; however, it is not recommended for diagnostic use alone **(Choice B)**.

(Choice A) Culture on sorbitol-MacConkey agar is used to diagnose *Escherichia coli* O157:H7 (ie, enterohemorrhagic *E coli* [EHEC]). EHEC presents with bloody diarrhea; this patient's nonbloody diarrhea and recent antibiotic exposure makes CDI more likely.

(Choice C) Latex agglutination for viral antigens is used to diagnose rotavirus, which causes nonbloody diarrhea, vomiting, and fever; disease can be particularly severe in immunocompromised patients. However, incubation time is typically <48 hours, and it is unlikely that this patient would develop an infection after 5 days in the hospital.

(Choice D) Modified acid-fast staining is used to diagnose cryptosporidium infection, which causes chronic diarrhea (particularly in HIV-infected patients). This patient's current hospitalization and antibiotic use make CDI more likely.

(Choice E) Stool ova and parasites are used to diagnose intestinal parasites (eg, *Giardia*, *Entamoeba*). These can cause diarrhea, which can be particularly severe in immunocompromised patients, but are unlikely to be associated with hospitalization. *Entamoeba histolytica* typically presents with bloody stool after travel to resource-limited countries.

Educational objective:
Clostridioides difficile commonly presents with watery diarrhea and abdominal pain; hospitalization and antibiotic use increase the risk of contracting the disease. A nucleic acid amplification test is the most sensitive method for diagnosis of *C difficile* infection in patients with clinical symptoms.

https://t.me/USMLEWorldStep1

A 14-year-old girl is evaluated in the burn unit due to nausea and recurrent bilious vomiting occurring over the past 4 hours. Twelve days ago, the patient was admitted to the burn unit after she was in a house fire. Examination on admission showed deep and superficial, partial-thickness burns covering 40% of her body. The patient has been receiving intravenous fluids, analgesics, nutritional support, and wound care, with slow improvement in clinical status until today. Temperature is 38.3 C (100.9 F), blood pressure is 133/77 mm Hg, pulse is 108/min, and respirations are 22/min, findings consistent with those of previous days. Physical examination shows mild diaphoresis and mild upper abdominal distension. Multiple wound and blood cultures taken since admission are negative. CT scan of the abdomen with intravenous contrast demonstrates significant reduction of the angle between the superior mesenteric artery and the aorta, with compression of an intervening portion of the gastrointestinal tract. Impingement of which of the following structures is most likely responsible for this patient's current condition?

- A. Ascending segment of the duodenum
- B. Descending segment of the duodenum
- C. Duodenojejunal flexure
- D. Pyloric sphincter
- E. Superior segment of the duodenum
- F. Transverse segment of the duodenum

Submit

https://t.me/USMLEWorldStep1

A 14-year-old girl is evaluated in the burn unit due to nausea and recurrent bilious vomiting occurring over the past 4 hours. Twelve days ago, the patient was admitted to the burn unit after she was in a house fire. Examination on admission showed deep and superficial, partial-thickness burns covering 40% of her body. The patient has been receiving intravenous fluids, analgesics, nutritional support, and wound care, with slow improvement in clinical status until today. Temperature is 38.3 C (100.9 F), blood pressure is 133/77 mm Hg, pulse is 108/min, and respirations are 22/min, findings consistent with those of previous days. Physical examination shows mild diaphoresis and mild upper abdominal distension. Multiple wound and blood cultures taken since admission are negative. CT scan of the abdomen with intravenous contrast demonstrates significant reduction of the angle between the superior mesenteric artery and the aorta, with compression of an intervening portion of the gastrointestinal tract. Impingement of which of the following structures is most likely responsible for this patient's current condition?

- ✗ A. Ascending segment of the duodenum (4%)
- B. Descending segment of the duodenum (9%)
- C. Duodenojejunal flexure (9%)
- D. Pyloric sphincter (2%)
- E. Superior segment of the duodenum (6%)
- ✓ F. Transverse segment of the duodenum (68%)

Incorrect
Correct answer
F

68%
Answered correctly

31 secs
Time Spent

2023
Version

Explanation

https://t.me/USMLEWorldStep1

A 14-year-old girl is evaluated in the burn unit due to nausea and recurrent bilious vomiting occurring over the past
4 hour
admis
receiv
status
respira
diapho
negati
betwe
gastro
curren

Exhibit Display

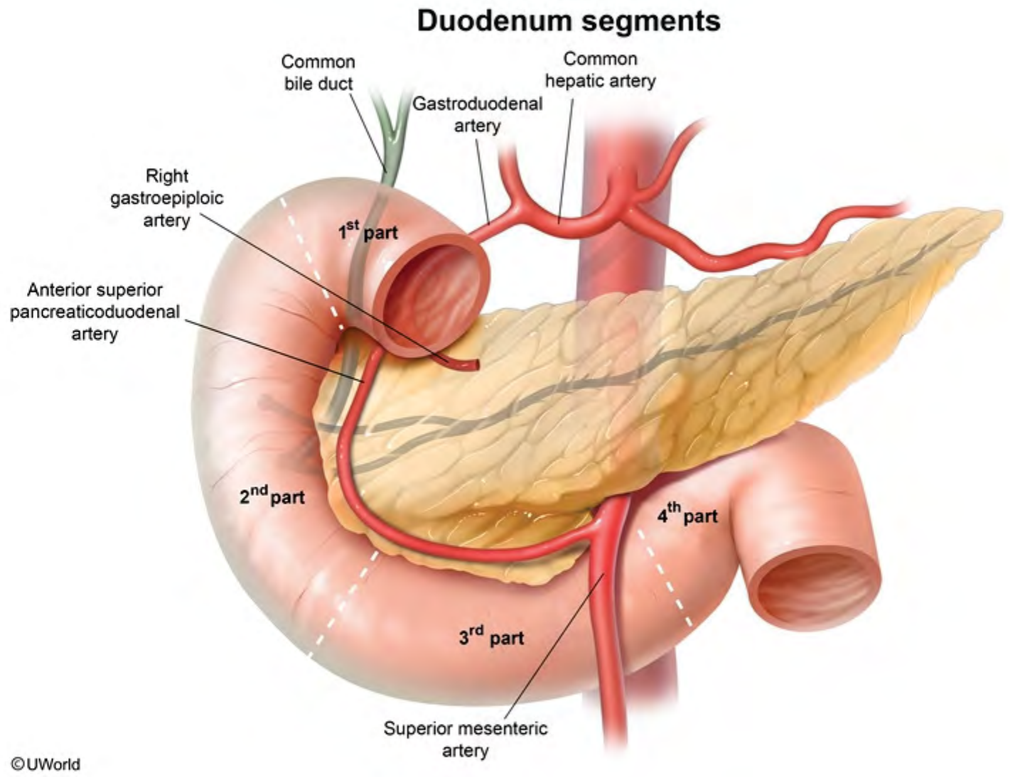

Zoom In | Zoom Out | Reset | New | Existing | My Notebook

Common bile duct
Common hepatic artery

https://t.me/USMLEWorldStep1

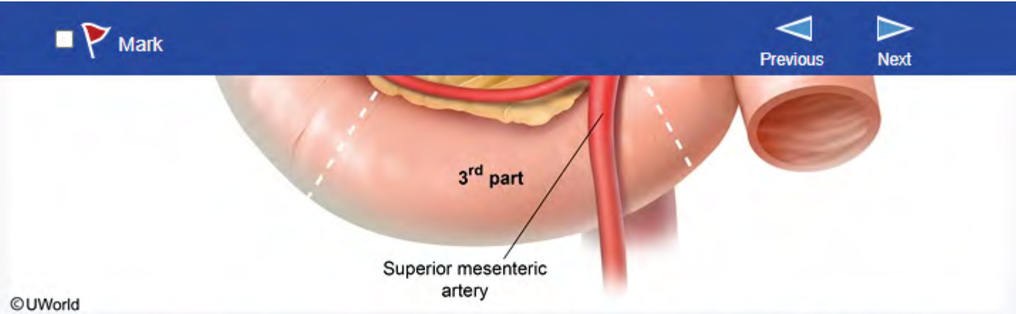

©UWorld

This 14-year-old patient with significant burn injuries developed symptoms of **bowel obstruction** (bilious vomiting, abdominal distension) following multiple days of hospitalization. The healing process after moderate to **severe burns** elicits a **hypermetabolic state**, mobilizing energy to cells involved in wound healing while countering heat and water loss from damaged insulating cutaneous tissue. This can lead to significant **consumption of adipose reserves**, including the fat pads that support abdominal structures.

The superior mesenteric artery (SMA) is supported by mesenteric fat that normally cushions the **transverse (third) segment of the duodenum**. With substantial lipolysis, consumption of the fat pad collapses the angle between the SMA and the aorta (aortomesenteric angle), compressing the duodenum (superior mesenteric artery syndrome). Because the obstruction is distal to biliary/pancreatic outflow from the duodenal papilla—located in the descending (second) segment of the duodenum **(Choice B)**—intestinal obstruction results in regurgitation of partially digested food (chyme) and biliary emesis.

(Choices A, C, D, and E) These structures do not pass under the SMA and are not susceptible to compression after mesenteric fat depletion.

Educational objective:
The transverse segment of the duodenum travels through a mesenteric fat pad that provides structural support for the superior mesenteric artery (SMA). Conditions that deplete mesenteric fat (eg, hypermetabolic states, starvation) may allow the SMA to compress the transverse segment against the aorta, causing progressive abdominal distension and recurrent bilious vomiting (ie, superior mesenteric artery syndrome).

Anatomy	Gastrointestinal & Nutrition	Bowel obstruction
Subject	System	Topic

Copyright © UWorld. All rights reserved.

https://t.me/USMLEWorldStep1

Exhibit Display

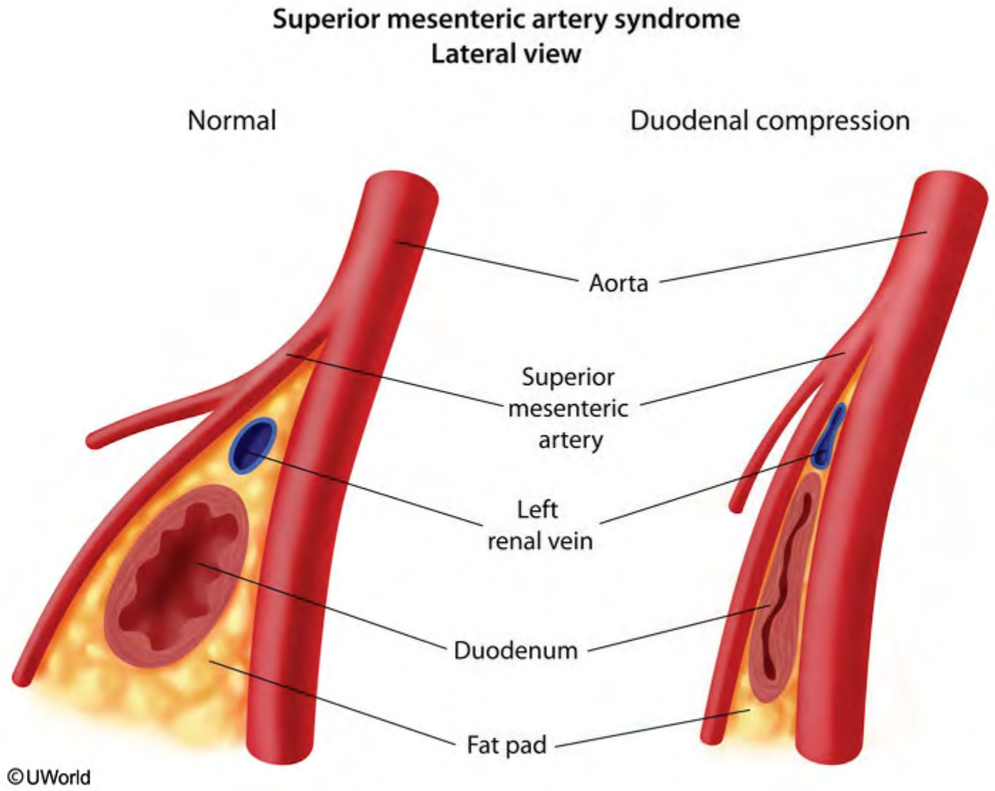

Zoom In | Zoom Out | Reset | New | Existing | My Notebook

This 1
abdom
burns
and w
reserv

The su
segm
the SM
syndro
descer
partial

(Choi
after n

Educa
The tra
the su
starva
abdom

Anatom
Subject

Copyright © UWorld. All rights reserved.

https://t.me/USMLEWorldStep1

A 64-year-old woman comes to the emergency department due to intractable nausea and vomiting. She has not been able to keep anything down and feels weak and tired. The patient has had no diarrhea, constipation, or abdominal pain. She was diagnosed with breast cancer 4 weeks ago and received her first cycle of chemotherapy 1 week ago. Vital signs are within normal limits. Mucous membranes are dry. Cardiopulmonary examination is normal. Bowel sounds are normal. Which of the following agents would be most helpful in treating this patient's symptoms?

- A. Histamine H_1 blocker
- B. Motilin receptor agonist
- C. Mu opioid receptor agonist
- D. Muscarinic M_1 receptor antagonist
- E. Serotonin 5-HT_3 receptor antagonist

Submit

https://t.me/USMLEWorldStep1

A 64-year-old woman comes to the emergency department due to intractable nausea and vomiting. She has not been able to keep anything down and feels weak and tired. The patient has had no diarrhea, constipation, or abdominal pain. She was diagnosed with breast cancer 4 weeks ago and received her first cycle of chemotherapy 1 week ago. Vital signs are within normal limits. Mucous membranes are dry. Cardiopulmonary examination is normal. Bowel sounds are normal. Which of the following agents would be most helpful in treating this patient's symptoms?

- A. Histamine H_1 blocker (3%)
- ✗ B. Motilin receptor agonist (2%)
- C. Mu opioid receptor agonist (5%)
- D. Muscarinic M_1 receptor antagonist (6%)
- ✓ E. Serotonin 5-HT_3 receptor antagonist (82%)

Incorrect
Correct answer
E

82%
Answered correctly

03 secs
Time Spent

2023
Version

Explanation

Characteristics of antiemetic drugs

Drug class	Examples	Clinical uses
Antimuscarinics (anticholinergics)	• Scopolamine	• Motion sickness • Hyperemesis gravidarum (promethazine)
Antihistamines	• Diphenhydramine • Meclizine • Promethazine	

https://t.me/USMLEWorldStep1

Characteristics of antiemetic drugs		
Drug class	**Examples**	**Clinical uses**
Antimuscarinics (anticholinergics)	• Scopolamine	• Motion sickness • Hyperemesis gravidarum (promethazine)
Antihistamines	• Diphenhydramine • Meclizine • Promethazine	
Dopamine receptor antagonists	• Prochlorperazine • Metoclopramide	• Chemotherapy-induced emesis
Serotonin (5-HT_3) receptor antagonists	• Ondansetron • Granisetron	
Neurokinin 1 (NK1) receptor antagonists	• Aprepitant • Fosaprepitant	

The vomiting reflex can be activated by either humoral or neuronal stimuli. The **area postrema** in the fourth ventricle has a **chemoreceptor trigger zone** that can respond to many neurotransmitters, drugs, or toxins. The **nucleus tractus solitarius** (NTS) in the medulla receives information from the area postrema, gastrointestinal (GI) tract via the vagus nerve, vestibular system, and central nervous system (eg, meninges, hypothalamus). Neurons from the NTS project to other medullary nuclei and coordinate the vomiting process. The 5 major receptors involved in stimulating the vomiting reflex in the area postrema and adjacent vomiting center nuclei are M_1 muscarinic, D_2 dopaminergic, H_1 histaminic, 5-HT_3 serotonergic, and neurokinin 1 (NK1) receptors.

5-HT_3 receptor antagonists (eg, ondansetron, granisetron, dolasetron) are highly effective in preventing **chemotherapy-induced vomiting**. These agents act by 2 primary mechanisms: blocking **vagus**-mediated nausea and vomiting (from the GI tract stimuli) and blocking central **serotonin** receptors in the area postrema and the NTS. Other agents useful for chemotherapy-induced vomiting include NK1 **receptor antagonists** (eg, aprepitant), which inhibit substance P and help prevent both acute vomiting and delayed emesis; and dopamine receptor antagonists (eg, metoclopramide), which are associated with drowsiness and dystonic reactions.

https://t.me/USMLEWorldStep1

Neurokinin 1 (NK1) receptor antagonists	• Aprepitant • Fosaprepitant	

The vomiting reflex can be activated by either humoral or neuronal stimuli. The **area postrema** in the fourth ventricle has a **chemoreceptor trigger zone** that can respond to many neurotransmitters, drugs, or toxins. The **nucleus tractus solitarius** (NTS) in the medulla receives information from the area postrema, gastrointestinal (GI) tract via the vagus nerve, vestibular system, and central nervous system (eg, meninges, hypothalamus). Neurons from the NTS project to other medullary nuclei and coordinate the vomiting process. The 5 major receptors involved in stimulating the vomiting reflex in the area postrema and adjacent vomiting center nuclei are M_1 muscarinic, D_2 dopaminergic, H_1 histaminic, 5-HT_3 serotonergic, and neurokinin 1 (NK1) receptors.

5-HT_3 receptor antagonists (eg, ondansetron, granisetron, dolasetron) are highly effective in preventing **chemotherapy-induced vomiting**. These agents act by 2 primary mechanisms: blocking **vagus**-mediated nausea and vomiting (from the GI tract stimuli) and blocking central **serotonin** receptors in the area postrema and the NTS. Other agents useful for chemotherapy-induced vomiting include NK1 **receptor antagonists** (eg, aprepitant), which inhibit substance P and help prevent both acute vomiting and delayed emesis; and dopamine receptor antagonists (eg, metoclopramide), which are associated with drowsiness and dystonic reactions.

(Choices A and D) Histamine blockers and antimuscarinic/anticholinergic agents are most helpful for vestibular nausea and vomiting.

(Choice B) Motilin regulates interdigestive migrating contractions. Erythromycin is a motilin receptor agonist used for gastroparesis.

(Choice C) Mu opioid receptor agonists (eg, morphine) are useful for cancer-related pain control but often have side effects such as nausea and vomiting.

Educational objective:
Ondansetron inhibits serotonin (5-HT_3) receptors and is used primarily to treat nausea and vomiting following chemotherapy. 5-HT_3 receptors are located peripherally in the presynaptic nerve terminals of the vagus nerve in the gastrointestinal tract. These receptors are also present centrally in the chemoreceptor trigger zone and the solitary nucleus and tract.

https://t.me/USMLEWorldStep1

Neurokinin 1 (NK1) receptor antagonists	• Aprepitant • Fosaprepitant

The vo
ventric
nucle
tract v
from th
involve
musca

5-HT$_3$
chem
nause
the NT
aprepi
recept

(Choi
nause

(Choi
for gas

(Choi
side ef

Educa
Ondan
chemo
the ga
solitary nucleus and tract.

Exhibit Display

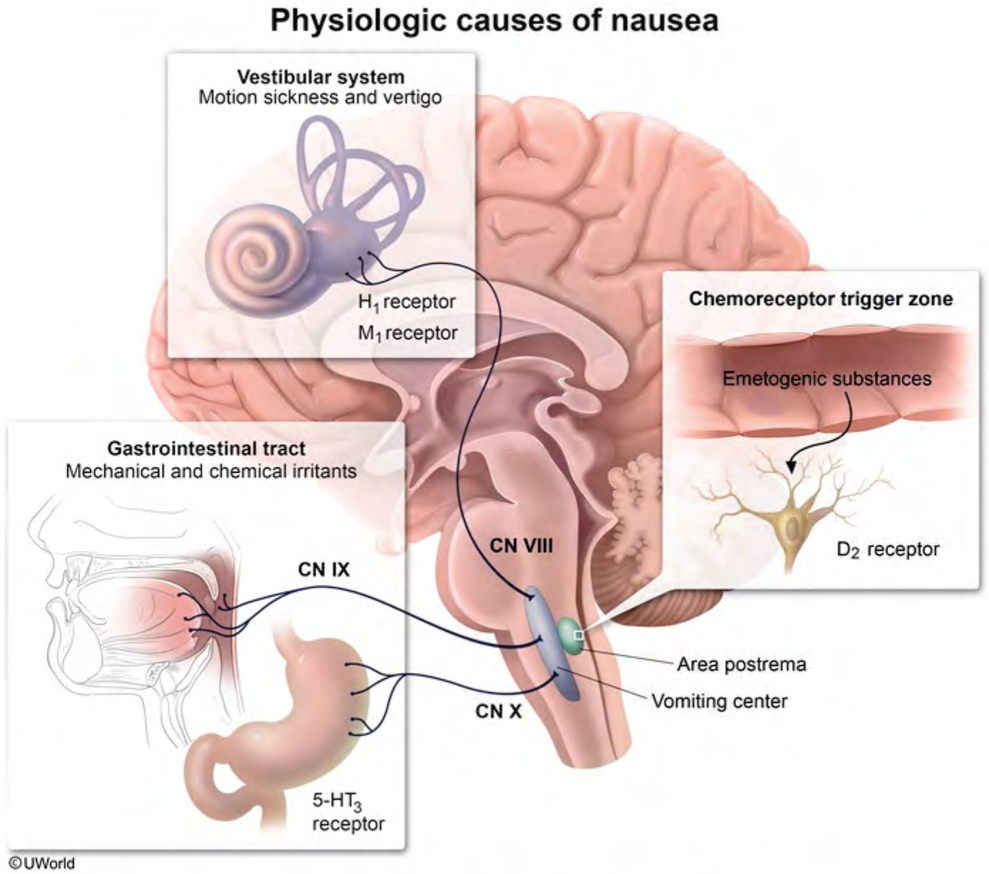

Zoom In | Zoom Out | Reset | New | Existing | My Notebook

https://t.me/USMLEWorldStep1

A 68-year-old woman comes to the office for a preventive visit. The patient feels well, and recently lost 4 kg (8.8 lb) on a new diet and exercise regimen. She has no recent history of abdominal pain, jaundice, or changes in her stools. Past medical history is notable for hypertension and hypercholesterolemia, for which the patient takes appropriate medications. She does not use tobacco, alcohol, or illicit drugs. Vital signs are normal. On examination, the abdomen is soft and nontender, and no hepatosplenomegaly is noted. However, a firm mass is palpated in the right upper quadrant. CT scan of the abdomen is ordered and is given in the exhibit. This patient is at elevated risk for which of the following conditions?

- A. Ascending cholangitis
- B. Cholangiocarcinoma
- C. Gallbladder adenocarcinoma
- D. Hepatocellular carcinoma
- E. Liver cirrhosis

Submit

https://t.me/USMLEWorldStep1

A 68-year-old woman comes to the office for a preventive visit. The patient feels well, and recently lost 4 kg (8.8 lb) on a new diet and exercise regimen. She has no recent history of abdominal pain, jaundice, or changes in her stools. Past medical history is notable for hypertension and hypercholesterolemia, for which the patient takes appropriate medications. She does not use tobacco, alcohol, or illicit drugs. Vital signs are normal. On examination, the abdomen is soft and nontender, and no hepatosplenomegaly is noted. However, a firm mass is palpated in the right upper quadrant. CT scan of the abdomen is ordered and is given in the exhibit. This patient is at elevated risk for which of the following conditions?

- A. Ascending cholangitis (13%)
- ✗ B. Cholangiocarcinoma (22%)
- ✓ C. Gallbladder adenocarcinoma (49%)
- D. Hepatocellular carcinoma (11%)
- E. Liver cirrhosis (2%)

Incorrect
Correct answer
C

49%
Answered correctly

03 secs
Time Spent

2023
Version

Explanation

Porcelain gallbladder

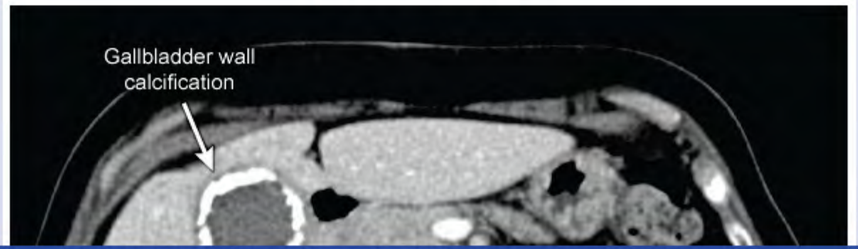

https://t.me/USMLEWorldStep1

A 68-year-old woman comes to the office for a preventive visit. The patient feels well, and recently lost 4 kg (8.8 lb)
on a n
stools.
approp
exami
palpat
at elev

Inco
Corre
C

Expl

Exhibit Display

Porcelain gallbladder

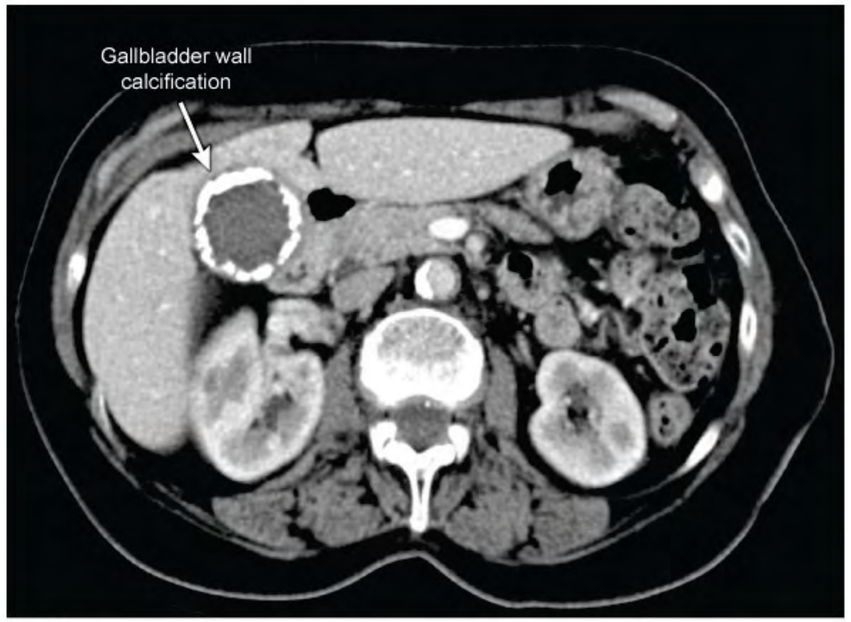

©UWorld

Zoom In Zoom Out Reset New | Existing My Notebook

https://t.me/USMLEWorldStep1

©UWorld

This patient, with a firm, palpable gallbladder and extensive calcification throughout the gallbladder wall, has typical findings of **porcelain gallbladder**. Patients with this condition may present with right upper quadrant abdominal pain but many are asymptomatic, with findings detected incidentally on imaging done for other reasons. Radiographic features may include a **thickened gallbladder wall** with a rim of patchy or uniform **calcification**.

Porcelain gallbladder is a potential manifestation of **chronic cholecystitis** and is often found in association with multiple gallstones. The pathogenesis is due to dystrophic intramural deposition of calcium salts in the setting of chronic inflammation. Gross findings include a bluish, brittle, thickened gallbladder wall with a "crunchy" texture. Microscopic findings can include calcified plaques within the muscularis or spotty calcification in the mucosa. Porcelain gallbladder is associated with an increased risk of **adenocarcinoma of the gallbladder**.

(Choice A) Acute ascending cholangitis is typically due to gram-negative infection of the intrahepatic biliary tree. It is a consequence of biliary obstruction (eg, choledocholithiasis) and presents with fever, right upper quadrant abdominal pain, and jaundice.

(Choice B) The risk of cholangiocarcinoma is increased in fibrotic diseases of the bile ducts, such as primary sclerosing cholangitis, congenital fibropolycystic diseases, and chronic infection with *Clonorchis sinensis* (liver fluke).

(Choices D and E) The risk of hepatocellular carcinoma is increased in many chronic inflammatory diseases of the liver, especially those progressing to cirrhosis. Common conditions include chronic viral hepatitis and alcohol-associated liver disease.

Educational objective:
Porcelain gallbladder is a potential manifestation of chronic cholecystitis and is often found in association with multiple gallstones. It is due to dystrophic intramural deposition of calcium salts in the setting of chronic inflammation. Porcelain gallbladder is associated with an increased risk of adenocarcinoma of the gallbladder.

Pathology	Gastrointestinal & Nutrition	Porcelain gallbladder
Subject	System	Topic

Copyright © UWorld. All rights reserved.

https://t.me/USMLEWorldStep1

©UWorld

This p
findin
pain b
Radio

Porcel
multipl
chroni
Micros
Porcel

(Choi
It is a
abdom

(Choi
sclero
fluke).

(Choi
the liv
associ

Educa
Porcel
multipl
inflam

Patholo
Subject System Topic

Copyright © UWorld. All rights reserved.

Exhibit Display

Chronic cholecystitis

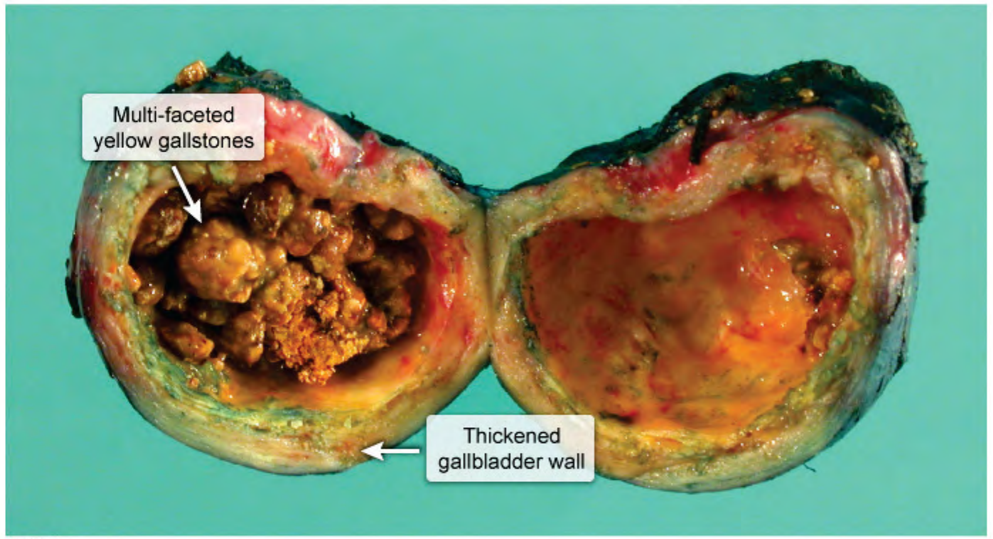

©UWorld

Zoom In Zoom Out Reset New | Existing My Notebook

https://t.me/USMLEWorldStep1

In an animal experiment, the pancreatic duct is cannulated and different secretory stimuli are applied to the gland.
The following tracings are obtained by measuring pancreatic fluid constituents:

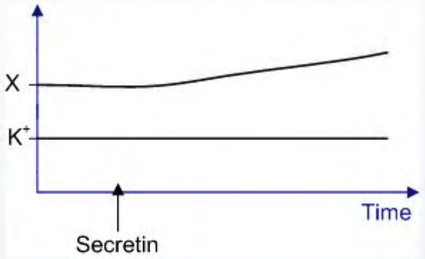

Substance 'X' is most likely which of the following?

- A. Sodium
- B. Chloride
- C. Trypsinogen
- D. Bicarbonate
- E. Phosphate

Submit

https://t.me/USMLEWorldStep1

In an animal experiment, the pancreatic duct is cannulated and different secretory stimuli are applied to the gland. The following tracings are obtained by measuring pancreatic fluid constituents:

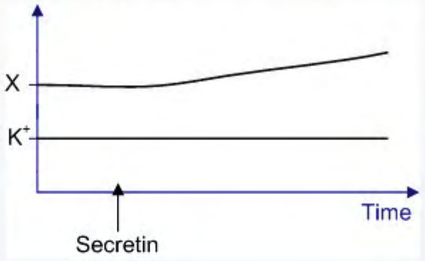

Substance 'X' is most likely which of the following?

- ✗ A. Sodium (1%)
- B. Chloride (3%)
- C. Trypsinogen (13%)
- ✓ D. Bicarbonate (80%)
- E. Phosphate (0%)

Incorrect
Correct answer
D

80%
Answered correctly

07 secs
Time Spent

2023
Version

Explanation

Secretin is a hormone produced by duodenal S-cells and released in response to increased duodenal H^+ concentrations. Secretin stimulates pancreatic ductal cells to increase bicarbonate secretion in order to neutralize the acidity of the gastric contents entering the duodenum. Remember that pancreatic juice is an isotonic secretion, which normally contains Na^+ and K^+ in the same concentrations as found in plasma, a higher $HCO3^-$ concentration

https://t.me/USMLEWorldStep1

Incorrect
Correct answer
D

80%
Answered correctly

07 secs
Time Spent

2023
Version

Explanation

Secretin is a hormone produced by duodenal S-cells and released in response to increased duodenal H^+ concentrations. Secretin stimulates pancreatic ductal cells to increase bicarbonate secretion in order to neutralize the acidity of the gastric contents entering the duodenum. Remember that pancreatic juice is an isotonic secretion, which normally contains Na^+ and K^+ in the same concentrations as found in plasma, a higher $HCO3^-$ concentration than in plasma and a lower Cl^- concentration than in plasma. As pancreatic juice flow rates and secretin stimulation increase, the concentration of HCO_3^- increases and the concentration of Cl^- decreases.

(Choice A) Regardless of flow rate or hormonal stimulation, the sodium concentration of pancreatic secretions is identical to that of plasma.

(Choice B) The chloride content of pancreatic secretions decreases as the bicarbonate content increases, because chloride and bicarbonate are exchanged for one another at the apical surfaces of pancreatic ductal cells.

(Choice C) Trypsinogen is a pancreatic proenzyme that is converted to its active form, trypsin, by enterokinase in the intestinal brush border. Active trypsin can also activate trypsinogen. Cholecystokinin and cholinergic stimulation increase the secretion of pancreatic enzymes.

(Choice E) Phosphate secretion is not regulated in the pancreas.

Educational Objective:
Duodenal S-cells secrete secretin in response to increasing H^+ concentrations. Secretin increases pancreatic bicarbonate secretion. The chloride content of pancreatic secretions decreases in proportion to bicarbonate concentration increases.

Physiology	Gastrointestinal & Nutrition	Pancreas physiology
Subject	System	Topic

Copyright © UWorld. All rights reserved.

https://t.me/USMLEWorldStep1

A 42-year-old woman comes to the office with persistent hyperlipidemia despite 6 months of maintaining a healthy diet and exercising regularly. Although her past medical history is significant for biliary colic secondary to gallstones, the patient has refused elective cholecystectomy. Her father died of a myocardial infarction at age 54, and her mother has diabetes mellitus. The patient's temperature is 36.1 C (97 F), blood pressure is 122/79 mm Hg, pulse is 78/min, and respirations are 14/min. Examination shows no abnormalities. Laboratory studies obtained 1 week ago show elevated serum triglycerides and LDL cholesterol levels. Drug therapy is discussed with the patient. Given this patient's preexisting gallbladder disease, which of the following drugs should be avoided?

- A. Atorvastatin
- B. Ezetimibe
- C. Fish oil
- D. Gemfibrozil
- E. Niacin

Submit

https://t.me/USMLEWorldStep1

A 42-year-old woman comes to the office with persistent hyperlipidemia despite 6 months of maintaining a healthy diet and exercising regularly. Although her past medical history is significant for biliary colic secondary to gallstones, the patient has refused elective cholecystectomy. Her father died of a myocardial infarction at age 54, and her mother has diabetes mellitus. The patient's temperature is 36.1 C (97 F), blood pressure is 122/79 mm Hg, pulse is 78/min, and respirations are 14/min. Examination shows no abnormalities. Laboratory studies obtained 1 week ago show elevated serum triglycerides and LDL cholesterol levels. Drug therapy is discussed with the patient. Given this patient's preexisting gallbladder disease, which of the following drugs should be avoided?

- A. Atorvastatin (7%)
- ✗ B. Ezetimibe (18%)
- C. Fish oil (4%)
- ✓ D. Gemfibrozil (64%)
- E. Niacin (6%)

Incorrect
Correct answer
D

64%
Answered correctly

05 secs
Time Spent

2023
Version

Explanation

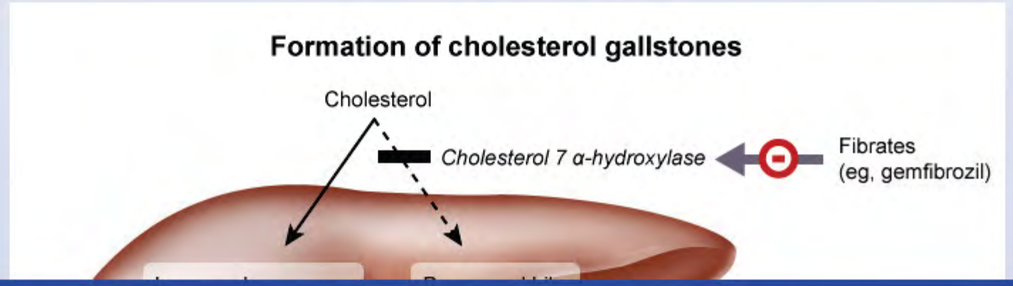

https://t.me/USMLEWorldStep1

A 42-year-old woman comes to the office with persistent hyperlipidemia despite 6 months of maintaining a healthy diet ar
gallsto
and he
Hg, pu
obtain
with th
avoide

Exhibit Display

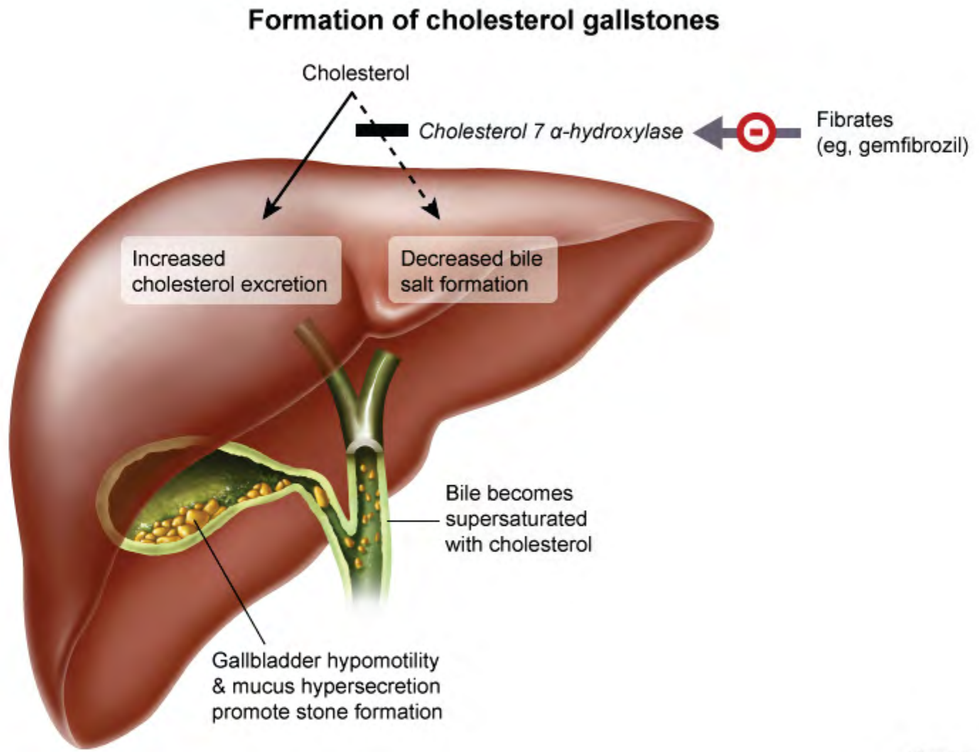

Zoom In | Zoom Out | Reset | New | Existing | My Notebook

https://t.me/USMLEWorldStep1

©UWorld

In patients with significant **hypertriglyceridemia**, fibrates are particularly effective due to their ability to upregulate lipoprotein lipase resulting in increased oxidation of fatty acids (liver, muscles). Gemfibrozil and other **fibrates** inhibit the rate-limiting enzyme in bile acid synthesis, cholesterol 7-alpha-hydroxylase. The reduced bile acid production results in **decreased cholesterol solubility** and increased microcrystal precipitation, thereby **promoting gallstone formation**. As a result, fibrates should be used with caution in patients with preexisting gallbladder disease. Patients on fibrate therapy should also be monitored for myopathy, a risk significantly increased when fibrates are used concurrently with statins.

(Choice A) Long-term use of statins (eg, atorvastatin) is associated with decreased risk of gallstone disease as inhibition of HMG-CoA reductase reduces cholesterol biosynthesis and bile supersaturation. Side effects of statin therapy include hepatic dysfunction (elevated aminotransferases) and myopathy.

(Choice B) Ezetimibe blocks intestinal cholesterol absorption, decreasing liver cholesterol stores and reducing biliary cholesterol content. Adverse effects associated with ezetimibe include elevated transaminases (increased with concurrent use of statins) and diarrhea.

(Choice C) Fish oil supplements containing high concentrations of omega-3 fatty acids increase bile acid synthesis, decrease cholesterol saturation in bile, and increase gallbladder motility. The net effect is a decreased risk of gallstone formation.

(Choice E) Niacin increases HDL (via reduced catabolism) and lowers triglyceride levels (through inhibition of VLDL secretion). It is associated with lower rates of gallstone disease. Niacin commonly promotes flushing, a temporary prostaglandin-mediated effect often blunted by use of nonsteroidal anti-inflammatory drugs.

Educational objective:
Gemfibrozil (and other fibrates) can reduce cholesterol solubility and promote gallstone formation by reducing bile acid synthesis. Caution should be used when prescribing fibrate therapy to patients with underlying gallbladder disease.

References

- Triglycerides and gallstone formation.

https://t.me/USMLEWorldStep1

Researchers studying neural crest cell migration in a human fetus observe normal activity beginning at the 8th week of embryogenesis with interruption during the 12th week, when migration is typically completed. Which of the following structures is most likely to lack innervation as a result of this disruption?

- A. Esophagus
- B. Duodenum
- C. Jejunum
- D. Ileum
- E. Cecum
- F. Transverse colon
- G. Rectum

Submit

https://t.me/USMLEWorldStep1

Researchers studying neural crest cell migration in a human fetus observe normal activity beginning at the 8th week of embryogenesis with interruption during the 12th week, when migration is typically completed. Which of the following structures is most likely to lack innervation as a result of this disruption?

- A. Esophagus (6%)
- B. Duodenum (3%)
- C. Jejunum (1%)
- ✗ D. Ileum (3%)
- E. Cecum (5%)
- F. Transverse colon (10%)
- ✓ G. Rectum (68%)

Incorrect
Correct answer
G

68%
Answered correctly

03 secs
Time Spent

2023
Version

Explanation

Hirschsprung disease	
Pathophysiology	• Failure of neural crest cell migration caudally to distal colon • Absent parasympathetic ganglia in affected submucosal & myenteric plexus • Chronically contracted colonic segment
Clinical features	• Delayed passage of meconium in neonates • Chronic constipation • Abdominal distension

https://t.me/USMLEWorldStep1

Hirschsprung disease	
Pathophysiology	• Failure of neural crest cell migration caudally to distal colon • Absent parasympathetic ganglia in affected submucosal & myenteric plexus • Chronically contracted colonic segment
Clinical features	• Delayed passage of meconium in neonates • Chronic constipation • Abdominal distension
Evaluation	• Contrast enema: narrow rectosigmoid area with dilated proximal colon • Rectal suction biopsy (diagnostic): absent submucosal ganglia

Normally, **neural crest cells** start migrating to the intestinal wall in early embryogenesis and give rise to **ganglion cells** of the submucosal (Meissner) and myenteric (Auerbach) plexus of the bowel wall. These parasympathetic ganglia are responsible for intestinal peristalsis. Neural crest cells enter the developing foregut mesenchyme and then **migrate caudally** along the entire length of the bowel; they are present in the wall of proximal colon by the 8th week of gestation and in the rectum by the 12th week.

The **arrest of migration** of neural crest cells causes **Hirschsprung disease**, in which a distal segment of colon lacks ganglion cells. Because neural crest cells migrate caudally, the **rectum is always involved**. The absence of parasympathetic ganglia in the colonic wall causes the affected segment to be narrowed because it cannot relax. The passage of intestinal contents through this area is difficult, and compensatory dilation of the proximal colon occurs.

Newborns with Hirschsprung disease often **fail to pass meconium** within 48 hours of birth. They may also develop signs of intestinal obstruction, such as bilious vomiting and abdominal distension. The bowel is filled with stool, but the rectum is empty; anal sphincter tone is usually increased.

(Choice A) Degeneration of neural crest cells forming the myenteric plexus in the esophagus causes achalasia (ie, esophageal dilation with absent peristalsis). However, the condition is most often due to autoimmune destruction of mature neurons; failed neural crest migration is a very rare etiology.

(Choices B, C, D, E, and F) Although total colonic aganglionosis can occur, the cecum and transverse colon are

https://t.me/USMLEWorldStep1

Normally, **neural crest cells** start migrating to the intestinal wall in early embryogenesis and give rise to **ganglion cells** of the submucosal (Meissner) and myenteric (Auerbach) plexus of the bowel wall. These parasympathetic ganglia are responsible for intestinal peristalsis. Neural crest cells enter the developing foregut mesenchyme and then **migrate caudally** along the entire length of the bowel; they are present in the wall of proximal colon by the 8th week of gestation and in the rectum by the 12th week.

The **arrest of migration** of neural crest cells causes **Hirschsprung disease**, in which a distal segment of colon lacks ganglion cells. Because neural crest cells migrate caudally, the **rectum is always involved**. The absence of parasympathetic ganglia in the colonic wall causes the affected segment to be narrowed because it cannot relax. The passage of intestinal contents through this area is difficult, and compensatory dilation of the proximal colon occurs.

Newborns with Hirschsprung disease often **fail to pass meconium** within 48 hours of birth. They may also develop signs of intestinal obstruction, such as bilious vomiting and abdominal distension. The bowel is filled with stool, but the rectum is empty; anal sphincter tone is usually increased.

(Choice A) Degeneration of neural crest cells forming the myenteric plexus in the esophagus causes achalasia (ie, esophageal dilation with absent peristalsis). However, the condition is most often due to autoimmune destruction of mature neurons; failed neural crest migration is a very rare etiology.

(Choices B, C, D, E, and F) Although total colonic aganglionosis can occur, the cecum and transverse colon are not commonly involved in Hirschsprung disease. Total intestinal aganglionosis (eg, duodenum, jejunum, ileum) has also been described but is extremely rare. The rectum is most likely to be affected by a problem with neural crest cell migration, as it is at the very end of the migration path.

Educational objective:
Hirschsprung disease is caused by abnormal migration of neural crest cells (ganglion cell precursors) during embryogenesis. Because neural crest cells migrate caudally down the bowel from the foregut, the rectum is always affected.

References

- The developmental etiology and pathogenesis of Hirschsprung disease.

https://t.me/USMLEWorldStep1

Exhibit Display

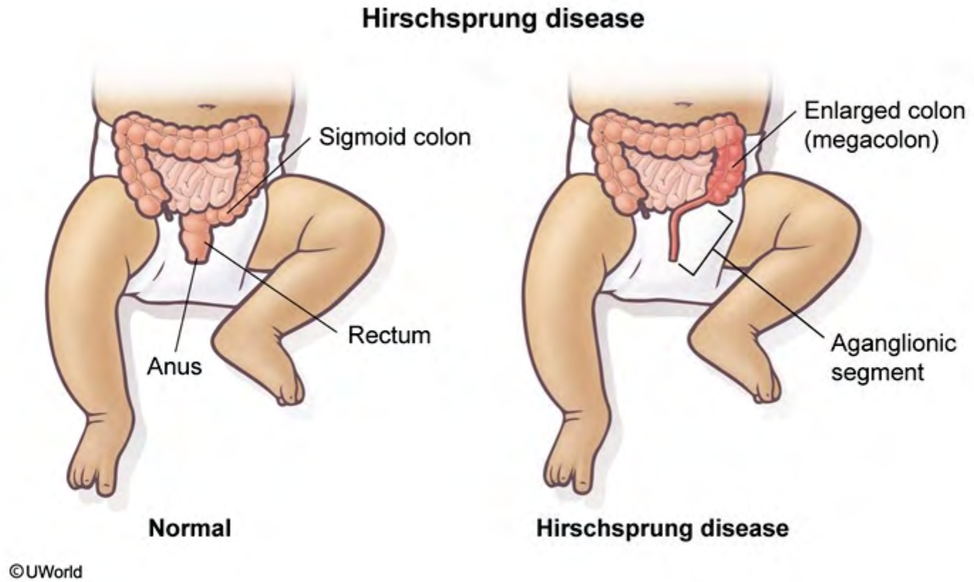

Zoom In | Zoom Out | Reset | New | Existing | My Notebook

Norma
cells
gangli
then **m**
8th we

The **a**
lacks
parasy
The pa
occurs

Newbo
develo
stool,

(Choi
(ie, es
destru

(Choi
not co
also b
cell mi

Educa
Hirsch
embry
always affected.

References

- The developmental etiology and pathogenesis of Hirschsprung disease.

https://t.me/USMLEWorldStep1

A 44-year-old woman comes to the office due to indigestion. The patient says she often develops right upper quadrant abdominal discomfort and nausea with fatty meals, which subside spontaneously after several hours. She does not use tobacco, alcohol, or illicit drugs. The patient immigrated to the United States from Nepal 10 years ago. Abdominal ultrasound reveals numerous gallstones, and she undergoes elective laparoscopic cholecystectomy. The stones in her gallbladder have very low cholesterol content and appear small, dark, and spiculated. Which of the following conditions most likely predisposed this patient to gallstone formation?

- A. Chronic hemolysis
- B. Metabolic syndrome
- C. Multiparity
- D. Oral contraceptive use
- E. Rapid weight loss

Submit

https://t.me/USMLEWorldStep1

A 44-year-old woman comes to the office due to indigestion. The patient says she often develops right upper quadrant abdominal discomfort and nausea with fatty meals, which subside spontaneously after several hours. She does not use tobacco, alcohol, or illicit drugs. The patient immigrated to the United States from Nepal 10 years ago. Abdominal ultrasound reveals numerous gallstones, and she undergoes elective laparoscopic cholecystectomy. The stones in her gallbladder have very low cholesterol content and appear small, dark, and spiculated. Which of the following conditions most likely predisposed this patient to gallstone formation?

- ✓ A. Chronic hemolysis (89%)
- B. Metabolic syndrome (3%)
- ✗ C. Multiparity (2%)
- D. Oral contraceptive use (1%)
- E. Rapid weight loss (2%)

Incorrect
Correct answer
A

89%
Answered correctly

03 secs
Time Spent

2023
Version

Explanation

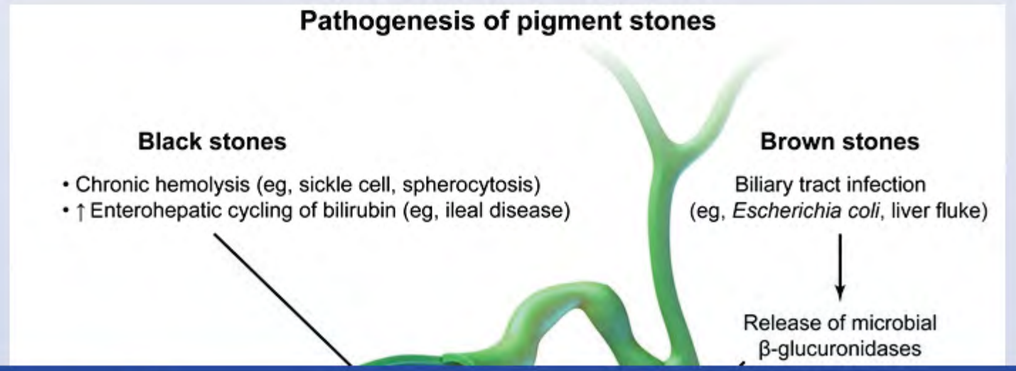

https://t.me/USMLEWorldStep1

A 44-year-old woman comes to the office due to indigestion. The patient says she often develops right upper quadra
She d
years
cholec
spicula

Inco
Corre
A

Expl

Exhibit Display

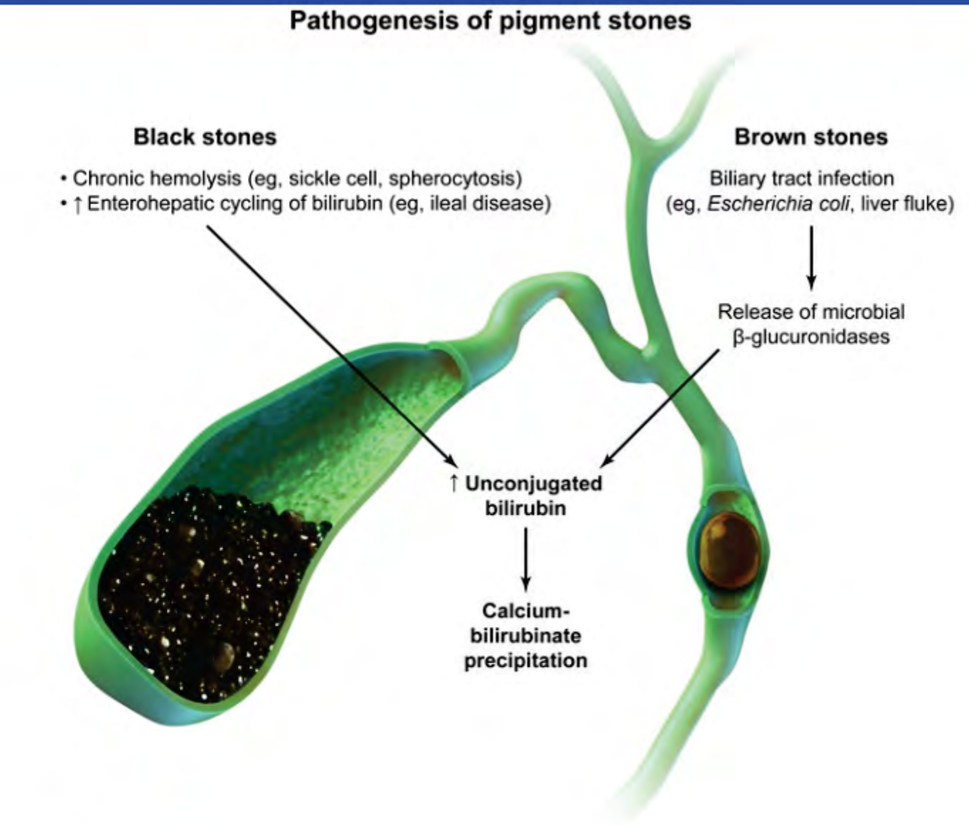

Zoom In | Zoom Out | Reset | New | Existing | My Notebook

https://t.me/USMLEWorldStep1

©UWorld

Gallstones are formed by the aggregation of bile constituents and are categorized as cholesterol stones, pigment stones, or mixed stones. **Pigment gallstones**, which account for only 10%-25% of gallstone cases in the United States, are most common in rural Asian populations. These stones can be brown to black and arise from conditions that increase the amount of **unconjugated bilirubin** in bile, which promotes calcium bilirubinate precipitation. Brown pigment stones are associated with biliary tract infections (microbes producing β-glucuronidases), whereas **black stones** occur in the setting of chronic **hemolysis** (eg, sickle cell anemia, β-thalassemia, hereditary spherocytosis) and increased enterohepatic cycling of bilirubin (eg, **ileal disease**).

Grossly, black pigment stones are usually present in significant numbers and are small, spiculated, and friable. Because these stones contain high amounts of calcium carbonates and phosphates, they are often radiopaque and appear on x-ray.

(Choices B, C, D, and E) Obesity/metabolic syndrome, multiparity, oral contraceptive use, and rapid weight loss are significant risk factors for development of cholesterol gallstones.

Educational objective:
Black pigment stones arise from conditions that increase the amount of unconjugated bilirubin in bile, which promotes calcium bilirubinate precipitation. This may occur in the setting of chronic hemolysis (eg, sickle cell anemia, β-thalassemia, hereditary spherocytosis) and increased enterohepatic cycling of bilirubin (eg, ileal disease).

References

- New pathophysiological concepts underlying pathogenesis of pigment gallstones.

Pathology	Gastrointestinal & Nutrition	Gallstone disease
Subject	System	Topic

Copyright © UWorld. All rights reserved.

https://t.me/USMLEWorldStep1

Exhibit Display

Gallstones

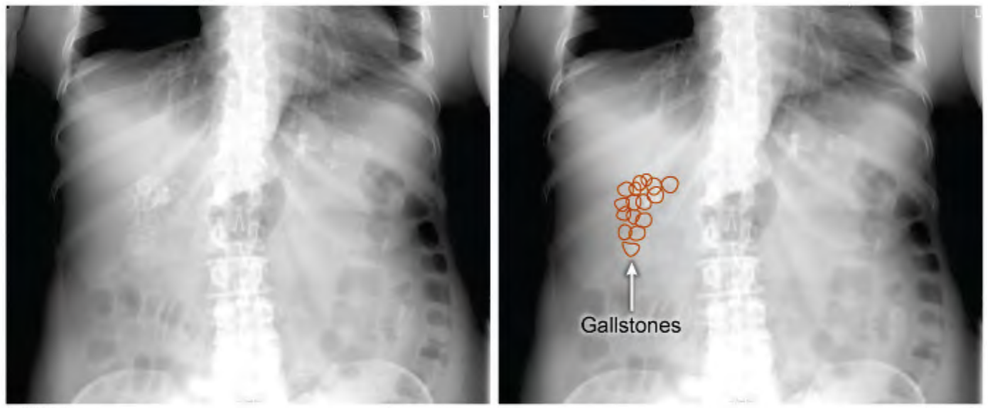

©UWorld

Zoom In | Zoom Out | Reset | New | Existing | My Notebook

Gallsto
stones
States
conditi
precip
glucur
thalas

Grossl
Becau
and ap

(Choi
are sig

Educa
Black
promo
anemi
diseas

Refere
- Ne

Pathol
Subject

Copyright © UWorld. All rights reserved.

https://t.me/USMLEWorldStep1

A 54-year-old man with a history of cirrhosis is brought to the emergency department by his wife, who found him agitated and confused. She reports that he was nauseous and vomited bright red blood several times yesterday. His cirrhosis is secondary to chronic hepatitis C infection, and he has received treatment for esophageal varices in the past. Physical examination reveals abdominal distension, decreased liver span, and testicular atrophy. A jerky, irregular flexion-extension tremor involving his hands is seen with wrist extension. Which of the following is most likely to be elevated in this patient's astrocytes?

- A. α-ketoglutarate
- B. Alanine
- C. Aspartate
- D. Carbamoyl phosphate
- E. Glutamine

Submit

https://t.me/USMLEWorldStep1

A 54-year-old man with a history of cirrhosis is brought to the emergency department by his wife, who found him agitated and confused. She reports that he was nauseous and vomited bright red blood several times yesterday. His cirrhosis is secondary to chronic hepatitis C infection, and he has received treatment for esophageal varices in the past. Physical examination reveals abdominal distension, decreased liver span, and testicular atrophy. A jerky, irregular flexion-extension tremor involving his hands is seen with wrist extension. Which of the following is most likely to be elevated in this patient's astrocytes?

- A. α-ketoglutarate (17%)
- ✗ B. Alanine (13%)
- C. Aspartate (10%)
- D. Carbamoyl phosphate (14%)
- ✓ E. Glutamine (44%)

Incorrect
Correct answer
E

44%
Answered correctly

03 secs
Time Spent

2023
Version

Explanation

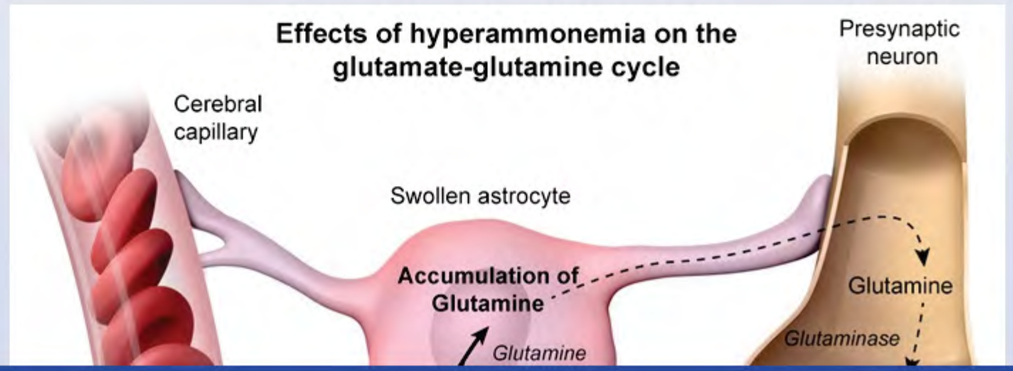

https://t.me/USMLEWorldStep1

A 54-year-old man with a history of cirrhosis is brought to the emergency department by his wife, who found him agitate
His cir
the pa
irregul
likely t

Exhibit Display

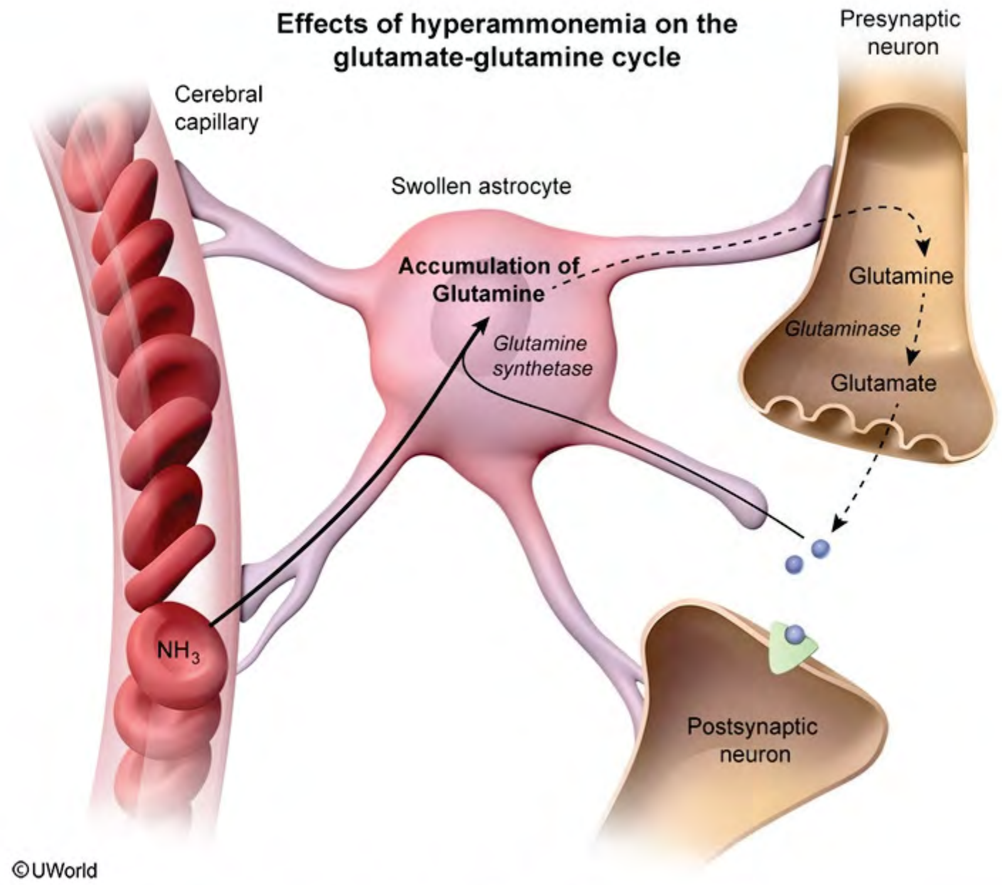

Zoom In | Zoom Out | Reset | New | Existing | My Notebook

https://t.me/USMLEWorldStep1

©UWorld

This patient has hepatic encephalopathy, likely due to his recent gastrointestinal bleeding causing a corresponding increase in nitrogen absorption by the gut. The pathogenesis of hepatic encephalopathy is related to increased circulatory levels of **ammonia** and other neurotoxins due to failure of the liver to metabolize waste products.

Under normal conditions, astrocytes regulate neurotransmission by taking up glutamate present in the synapse, preventing excessive neuronal excitation. Through the action of glutamine synthetase, glutamate undergoes a condensation reaction with ammonia to form glutamine (a non-neuroactive compound). Glutamine is then released by the astrocytes and taken up by neurons, where it is converted back to glutamate for use as a neurotransmitter (glutamate-glutamine cycle).

When **excess ammonia** is present in the blood, it crosses the blood-brain barrier and is taken up by astrocytes, **increasing glutamine production**. The presence of excess glutamine within astrocytes leads to increased intracellular osmolarity, causing astrocyte swelling and impaired glutamine release. Hyperammonemia consequently decreases the amount of glutamine available for conversion to glutamate in neurons, resulting in **disruption of excitatory neurotransmission**.

(Choice A) α-ketoglutarate functions as a key intermediate in the TCA cycle and as a nitrogen transporter in metabolic reactions. In the setting of hyperammonemia, ammonia is detoxified to glutamate via glutamate dehydrogenase, depleting α-ketoglutarate and impairing energy metabolism in the brain.

(Choice B) Alanine is an amino group transporter in the glucose-alanine cycle in liver and muscle tissue. This process allows tissues that use amino acids for fuel to shunt excess nitrogen back to the liver.

(Choice C) Aspartate is a nonessential amino acid that functions as a substrate in the urea cycle and as part of the malate-aspartate shuttle that transfers cytosolic-reducing equivalents into the mitochondrial matrix.

(Choice D) Carbamoyl phosphate is a urea cycle intermediate synthesized by carbamoyl phosphate synthetase I, which transfers an ammonia molecule from glutamine or glutamate to a phosphorylated bicarbonate. Carbamoyl phosphate production is decreased in patients with advanced liver disease.

Educational objective:
Hyperammonemia in advanced liver failure occurs as a direct result of the cirrhotic liver's inability to metabolize

https://t.me/USMLEWorldStep1

circulatory levels of **ammonia** and other neurotoxins due to failure of the liver to metabolize waste products.

Under normal conditions, astrocytes regulate neurotransmission by taking up glutamate present in the synapse, preventing excessive neuronal excitation. Through the action of glutamine synthetase, glutamate undergoes a condensation reaction with ammonia to form glutamine (a non-neuroactive compound). Glutamine is then released by the astrocytes and taken up by neurons, where it is converted back to glutamate for use as a neurotransmitter (glutamate-glutamine cycle).

When **excess ammonia** is present in the blood, it crosses the blood-brain barrier and is taken up by astrocytes, **increasing glutamine production**. The presence of excess glutamine within astrocytes leads to increased intracellular osmolarity, causing astrocyte swelling and impaired glutamine release. Hyperammonemia consequently decreases the amount of glutamine available for conversion to glutamate in neurons, resulting in **disruption of excitatory neurotransmission**.

(Choice A) α-ketoglutarate functions as a key intermediate in the TCA cycle and as a nitrogen transporter in metabolic reactions. In the setting of hyperammonemia, ammonia is detoxified to glutamate via glutamate dehydrogenase, depleting α-ketoglutarate and impairing energy metabolism in the brain.

(Choice B) Alanine is an amino group transporter in the glucose-alanine cycle in liver and muscle tissue. This process allows tissues that use amino acids for fuel to shunt excess nitrogen back to the liver.

(Choice C) Aspartate is a nonessential amino acid that functions as a substrate in the urea cycle and as part of the malate-aspartate shuttle that transfers cytosolic-reducing equivalents into the mitochondrial matrix.

(Choice D) Carbamoyl phosphate is a urea cycle intermediate synthesized by carbamoyl phosphate synthetase I, which transfers an ammonia molecule from glutamine or glutamate to a phosphorylated bicarbonate. Carbamoyl phosphate production is decreased in patients with advanced liver disease.

Educational objective:
Hyperammonemia in advanced liver failure occurs as a direct result of the cirrhotic liver's inability to metabolize nitrogenous waste products. Ammonia crosses the blood-brain barrier and causes excess glutamine to accumulate within astrocytes. This decreases the amount of glutamine available for conversion to glutamate in the neurons, resulting in disruption of excitatory neurotransmission.

https://t.me/USMLEWorldStep1

Exhibit Display

Hepatic encephalopathy	
Precipitating factors	• Drugs (eg, sedatives, narcotics) • Hypovolemia (eg, diarrhea) • Electrolyte changes (eg, hypokalemia) • ↑ Nitrogen load (eg, GI bleeding) • Infection (eg, pneumonia, UTI, SBP) • Portosystemic shunting (eg, TIPS)
Clinical presentation	• Sleep pattern changes • Altered mental status • Ataxia • Asterixis
Treatment	• Correct precipitating causes (eg, fluids, antibiotics) • ↓ Blood ammonia concentration (eg, lactulose, rifaximin)

GI = gastrointestinal; **SBP** = spontaneous bacterial peritonitis; **TIPS** = transjugular intrahepatic portosystemic shunt; **UTI** = urinary tract infection.

New | Existing | My Notebook

This p
increa
circula

Under
prever
conde
by the
(glutar

When
increa
intrace
conse
disrup

(Choi
metab
dehyd

(Choi
proces

(Choi
the ma

(Choi
which transfers an ammonia molecule from glutamine or glutamate to a phosphorylated bicarbonate. Carbamoyl

https://t.me/USMLEWorldStep1

Postsynaptic neuron

Exhibit Display

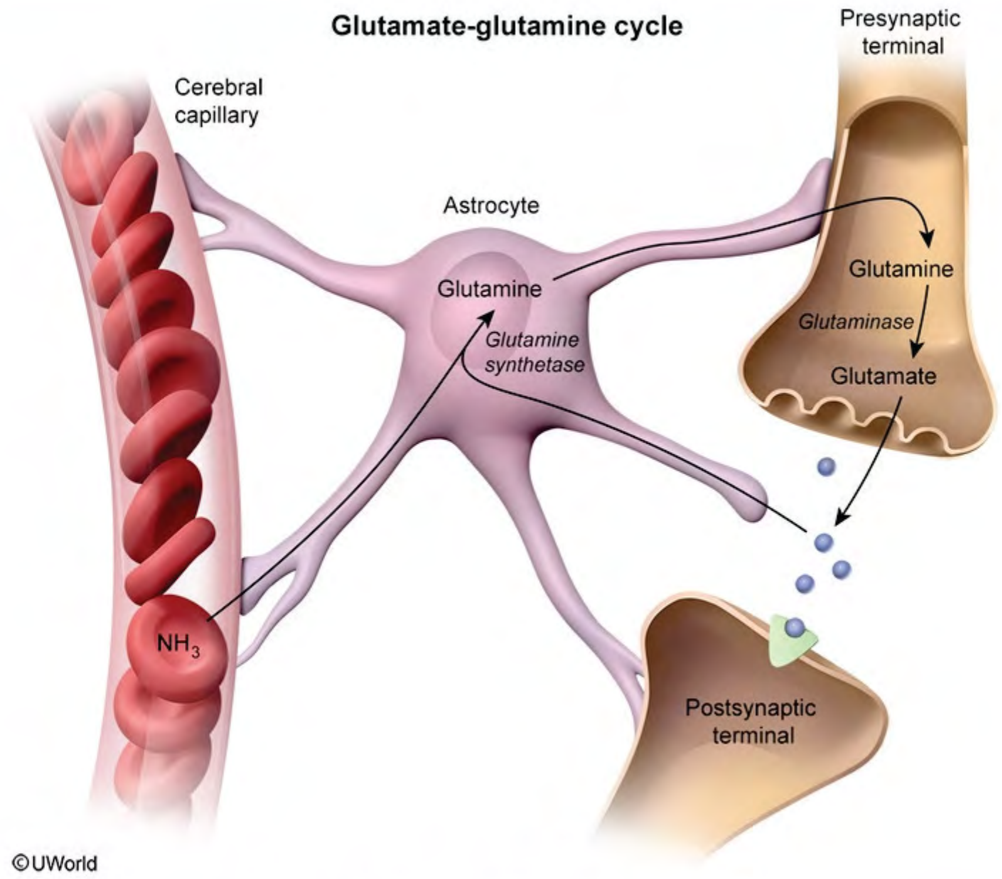

Zoom In | Zoom Out | Reset | New | Existing | My Notebook

This p
increa
circula

Under
prever
conde
by the
(glutar

When
increa
intrace
conse
disrup

(Choi
metab
dehyd

(Choi
proces

(Choi
the ma

(Choi
which transfers an ammonia molecule from glutamine or glutamate to a phosphorylated bicarbonate. Carbamoyl

https://t.me/USMLEWorldStep1

©UWorld

This p
increa
circula

Under
prever
conde
by the
(glutar

When
increa
intrace
conse
disrup

(Choi
metab
dehyd

(Choi
proces

(Choi
the ma

(Choi
which
phosp

Educa

Hyperammonemia in advanced liver failure occurs as a direct result of the cirrhotic liver's inability to metabolize

Exhibit Display

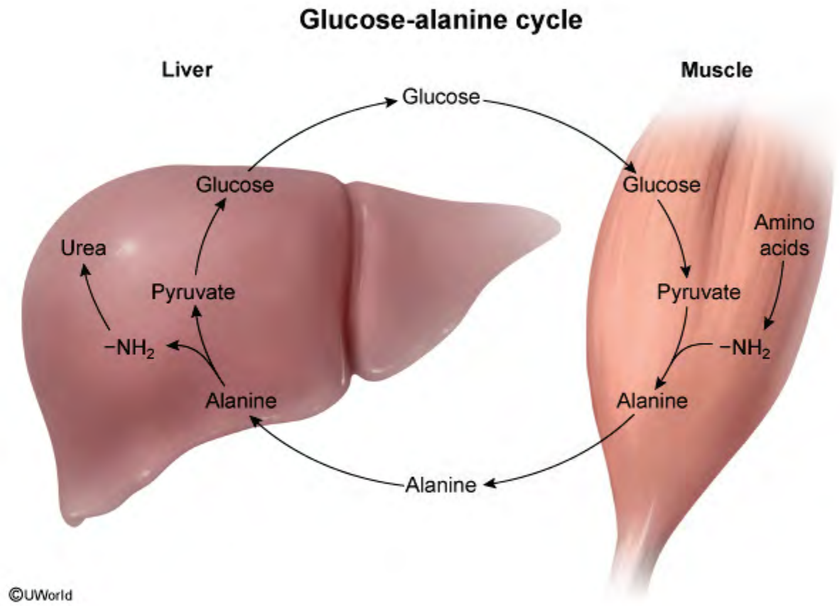

Zoom In | Zoom Out | Reset | New | Existing | My Notebook

https://t.me/USMLEWorldStep1

A 64-year-old woman is diagnosed with rheumatoid arthritis after coming to the office with symmetrical joint pain, swelling, and morning stiffness. The patient has a remote history of peptic ulcer disease and was treated with multidrug therapy for *Helicobacter pylori* eradication; a follow-up *H pylori* stool antigen test was negative and she had no recurrent symptoms. The patient is started on methotrexate and high-dose ibuprofen therapy. In addition, daily lansoprazole is prescribed for protection against the adverse gastrointestinal effects of ibuprofen. Three months later, joint symptoms were greatly improved. Ibuprofen and lansoprazole were discontinued. However, 2 weeks later, she begins experiencing heartburn after meals. Which of the following is the most likely cause of this patient's new gastrointestinal symptoms?

- A. Downregulation of vagal stimulation
- B. Gastrin-mediated rebound acid hypersecretion
- C. Increased prostaglandin production after ibuprofen discontinuation
- D. Recolonization with *Helicobacter pylori*
- E. Upregulation of somatostatin receptors

Submit

https://t.me/USMLEWorldStep1

A 64-year-old woman is diagnosed with rheumatoid arthritis after coming to the office with symmetrical joint pain, swelling, and morning stiffness. The patient has a remote history of peptic ulcer disease and was treated with multidrug therapy for *Helicobacter pylori* eradication; a follow-up *H pylori* stool antigen test was negative and she had no recurrent symptoms. The patient is started on methotrexate and high-dose ibuprofen therapy. In addition, daily lansoprazole is prescribed for protection against the adverse gastrointestinal effects of ibuprofen. Three months later, joint symptoms were greatly improved. Ibuprofen and lansoprazole were discontinued. However, 2 weeks later, she begins experiencing heartburn after meals. Which of the following is the most likely cause of this patient's new gastrointestinal symptoms?

- ✗ A. Downregulation of vagal stimulation (1%)
- ✓ B. Gastrin-mediated rebound acid hypersecretion (85%)
- C. Increased prostaglandin production after ibuprofen discontinuation (6%)
- D. Recolonization with *Helicobacter pylori* (4%)
- E. Upregulation of somatostatin receptors (1%)

Incorrect
Correct answer
B

85%
Answered correctly

03 secs
Time Spent

2023
Version

Explanation

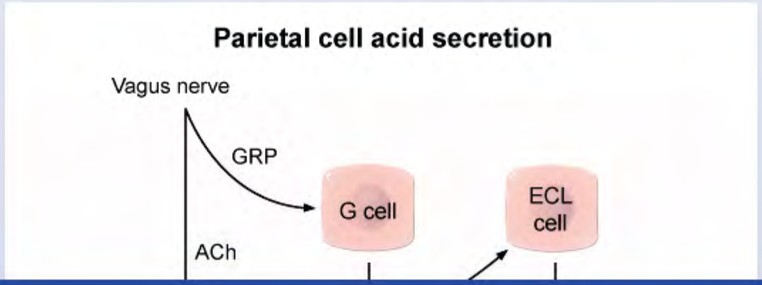

https://t.me/USMLEWorldStep1

A 64-year-old woman is diagnosed with rheumatoid arthritis after coming to the office with symmetrical joint pain, swellin
multid
had no
daily la
month
weeks
patien

Exhibit Display

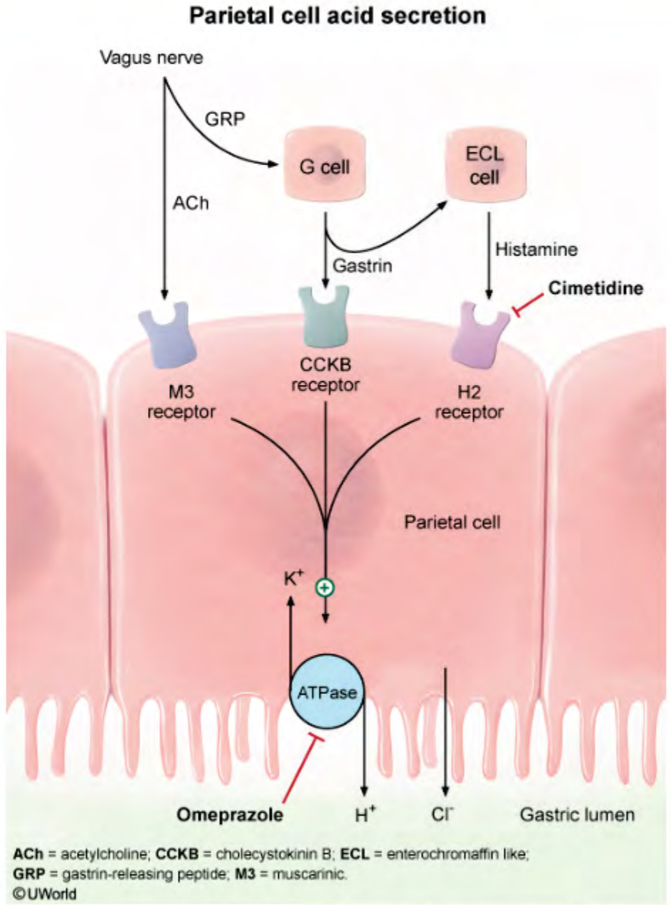

Zoom In | Zoom Out | Reset | New | Existing | My Notebook

https://t.me/USMLEWorldStep1

Release of gastrin, a hormone produced by G cells in the gastric antrum, is stimulated by dietary protein intake, gastrin-releasing peptide (released in response to vagal stimuli), and increased gastric pH. Gastrin induces acid production directly by binding parietal cells and indirectly by binding enterochromaffin-like (ECL) cells and inducing histamine release.

Proton pump inhibitors (PPIs) (eg, omeprazole, lansoprazole) inhibit the hydrogen-potassium-ATPase pump and **decrease hydrochloric acid** production regardless of stimuli. The resultant increase in gastric pH leads to **increased gastrin** formation, which induces hypertrophy of the ECL and parietal cells. **Withdrawal** of the PPI results in overstimulation of the parietal cells with hyperfunctioning of the unblocked ATPase, leading to **rebound gastric acid hypersecretion** and reflux symptoms. PPIs can be slowly tapered to help prevent this adverse effect.

(Choice A) Acetylcholine (released with vagal stimulation) binds to parietal cell muscarinic (M3) receptors and promotes the secretion of hydrochloric acid. Downregulation of vagal tone would likely relieve, rather than cause, the patient's symptoms.

(Choice C) Prostaglandins decrease acid production by inhibiting the downstream messenger of histamine and increases bicarbonate formation from gastric epithelial cells. Nonsteroidal anti-inflammatory drugs (eg ibuprofen) inhibit prostaglandin formation and increase the risk of gastritis and peptic ulcer formation. Increased prostaglandin formation after drug withdrawal would be protective against gastritis.

(Choice D) Chronic *Helicobacter pylori* infection causes atrophic gastritis with parietal cell destruction. The effects of hypergastrinemia are masked in these patients due to the inability of the remaining parietal cells to create large volumes of acid. Reinfection is very rare, and the correlation with PPI withdrawal makes rebound hypersecretion more likely.

(Choice E) Somatostatin inhibits histamine and gastrin release; upregulation would lead to reduced gastric acid formation.

Educational objective:
Elevated gastric pH stimulates secretion of gastrin, a polypeptide hormone that increases gastric acid production. Proton pump inhibitors block gastric acid production by parietal cells; the resultant increase in pH leads to

https://t.me/USMLEWorldStep1

histamine release.

Proton pump inhibitors (PPIs) (eg, omeprazole, lansoprazole) inhibit the hydrogen-potassium-ATPase pump and **decrease hydrochloric acid** production regardless of stimuli. The resultant increase in gastric pH leads to **increased gastrin** formation, which induces hypertrophy of the ECL and parietal cells. **Withdrawal** of the PPI results in overstimulation of the parietal cells with hyperfunctioning of the unblocked ATPase, leading to **rebound gastric acid hypersecretion** and reflux symptoms. PPIs can be slowly tapered to help prevent this adverse effect.

(Choice A) Acetylcholine (released with vagal stimulation) binds to parietal cell muscarinic (M3) receptors and promotes the secretion of hydrochloric acid. Downregulation of vagal tone would likely relieve, rather than cause, the patient's symptoms.

(Choice C) Prostaglandins decrease acid production by inhibiting the downstream messenger of histamine and increases bicarbonate formation from gastric epithelial cells. Nonsteroidal anti-inflammatory drugs (eg ibuprofen) inhibit prostaglandin formation and increase the risk of gastritis and peptic ulcer formation. Increased prostaglandin formation after drug withdrawal would be protective against gastritis.

(Choice D) Chronic *Helicobacter pylori* infection causes atrophic gastritis with parietal cell destruction. The effects of hypergastrinemia are masked in these patients due to the inability of the remaining parietal cells to create large volumes of acid. Reinfection is very rare, and the correlation with PPI withdrawal makes rebound hypersecretion more likely.

(Choice E) Somatostatin inhibits histamine and gastrin release; upregulation would lead to reduced gastric acid formation.

Educational objective:
Elevated gastric pH stimulates secretion of gastrin, a polypeptide hormone that increases gastric acid production. Proton pump inhibitors block gastric acid production by parietal cells; the resultant increase in pH leads to hypergastrinemia, which can cause rebound hypersecretion of gastric acid when the drug is withdrawn.

Pharmacology	Gastrointestinal & Nutrition	Peptic ulcer disease
Subject	System	Topic

https://t.me/USMLEWorldStep1

A 72-year-old woman comes to the office for follow-up of chronic abdominal pain. She has had several episodes of left lower quadrant pain requiring hospitalization. Despite treatment, her symptoms continue to recur. Elective surgery is performed and a segment of resected and opened sigmoid colon is shown below.

Which of the following most likely contributed to this patient's condition?

- A. Consumption of high-fiber foods
- B. Frequent consumption of seeds and nuts
- C. High dietary intake of fat and red meat
- D. Infection with *Helicobacter pylori*
- E. Prolonged and excessive alcohol intake

Submit

https://t.me/USMLEWorldStep1

A 72-year-old woman comes to the office for follow-up of chronic abdominal pain. She has had several episodes of left lo
surger

Exhibit Display

Zoom In Zoom Out Reset New | Existing My Notebook

Which

E. Prolonged and excessive alcohol intake

https://t.me/USMLEWorldStep1

surgery is performed and a segment of resected and opened sigmoid colon is shown below.

Which of the following most likely contributed to this patient's condition?

- A. Consumption of high-fiber foods
- B. Frequent consumption of seeds and nuts
- C. High dietary intake of fat and red meat
- D. Infection with *Helicobacter pylori*
- E. Prolonged and excessive alcohol intake

Submit

https://t.me/USMLEWorldStep1

surgery is performed and a segment of resected and opened sigmoid colon is shown below.

Which of the following most likely contributed to this patient's condition?

- ✗ A. Consumption of high-fiber foods (3%)
- B. Frequent consumption of seeds and nuts (13%)
- ✓ C. High dietary intake of fat and red meat (77%)
- D. Infection with *Helicobacter pylori* (1%)
- E. Prolonged and excessive alcohol intake (4%)

Incorrect
Correct answer
C

77%
Answered correctly

31 secs
Time Spent

2023
Version

https://t.me/USMLEWorldStep1

Explanation

Diverticular disease	
Etiology	• Diverticulosis: ↑ intraluminal pressure causing herniation through points of weakness (vasa recta penetration) • Diverticular bleeding: injury to exposed vasa recta • Diverticulitis: trapped food particles & ↑ intraluminal pressure causing microperforation
Symptoms	• Diverticulosis: none • Diverticular bleeding: painless hematochezia • Diverticulitis: left lower quadrant pain, nausea, vomiting, fever
Risk factors	• Diet high in red meat & fat & low in fiber • Obesity, physical inactivity, smoking

This patient's gross pathology demonstrates multiple sac-like outpouchings from the sigmoid colon, which is consistent with diverticulosis. **Diverticulosis** occurs due to excessive colonic contractions that cause increased intraluminal pressure; this forces the mucosa and submucosa to herniate through the muscularis at naturally weak areas where the vasa recta penetrate. It is an exceedingly common disorder, particularly in Western nations, and its incidence increases with age.

Diverticulosis may be clinically silent, but up to 30% of patients develop complications, including diverticular bleeding and diverticulitis. **Diverticular bleeding** occurs with injury to the exposed vasa recta within the colonic lumen and typically presents with **painless** hematochezia. **Diverticulitis** is caused by trapped food particles or excessive intraluminal pressure within the diverticula, leading to focal necrosis and microperforation. Patients develop **abdominal pain** (usually in the **left lower quadrant**), fever, nausea and vomiting, and alterations in bowel habits (eg, diarrhea, constipation). Diverticulitis is typically managed with antibiotics and bowel rest; however, surgery may be required for recurrent disease.

The risk for diverticular disease is increased by dietary factors, including **diets high in red meat**, high in **fat**, and

https://t.me/USMLEWorldStep1

factors	• Obesity, physical inactivity, smoking

This patient's gross pathology demonstrates multiple sac-like outpouchings from the sigmoid colon, which is consistent with diverticulosis. **Diverticulosis** occurs due to excessive colonic contractions that cause increased intraluminal pressure; this forces the mucosa and submucosa to herniate through the muscularis at naturally weak areas where the vasa recta penetrate. It is an exceedingly common disorder, particularly in Western nations, and its incidence increases with age.

Diverticulosis may be clinically silent, but up to 30% of patients develop complications, including diverticular bleeding and diverticulitis. **Diverticular bleeding** occurs with injury to the exposed vasa recta within the colonic lumen and typically presents with **painless** hematochezia. **Diverticulitis** is caused by trapped food particles or excessive intraluminal pressure within the diverticula, leading to focal necrosis and microperforation. Patients develop **abdominal pain** (usually in the **left lower quadrant**), fever, nausea and vomiting, and alterations in bowel habits (eg, diarrhea, constipation). Diverticulitis is typically managed with antibiotics and bowel rest; however, surgery may be required for recurrent disease.

The risk for diverticular disease is increased by dietary factors, including **diets high in red meat**, high in **fat**, and low in fiber **(Choice A)**. Other risk factors include obesity, physical inactivity, and smoking.

(Choice B) Although previously thought to be associated with diverticular diseases, the ingestion of nuts, seeds, and popcorn is not correlated with increased risk of diverticulosis, diverticular bleeding, or diverticulitis.

(Choice D) *Helicobacter pylori* infection is associated with peptic ulcer and gastric cancer but does not increase the risk of diverticular disease.

(Choice E) Excessive alcohol intake is associated with liver cirrhosis and squamous cell carcinoma of the esophagus; it is not associated with diverticular disease.

Educational objective:
Colonic diverticulosis refers to multiple sac-like outpouchings within the sigmoid colon. Complications include diverticular bleeding and diverticulitis. Risk factors for diverticulosis include a diet high in red meat and fat and low in fiber, as well as obesity and physical inactivity.

References

https://t.me/USMLEWorldStep1

factors	• Obesity, physical inactivity, smoking

This p
consis
intralu
areas
its inci

Diverti
bleedi
lumen
excess
develo
habits
surger

The ris
low in

(Choi
and po

(Choi
the ris

(Choi
esoph

Educa
Coloni
diverti
in fiber, as well as obesity and physical inactivity.

References

Exhibit Display

Colonic diverticulosis

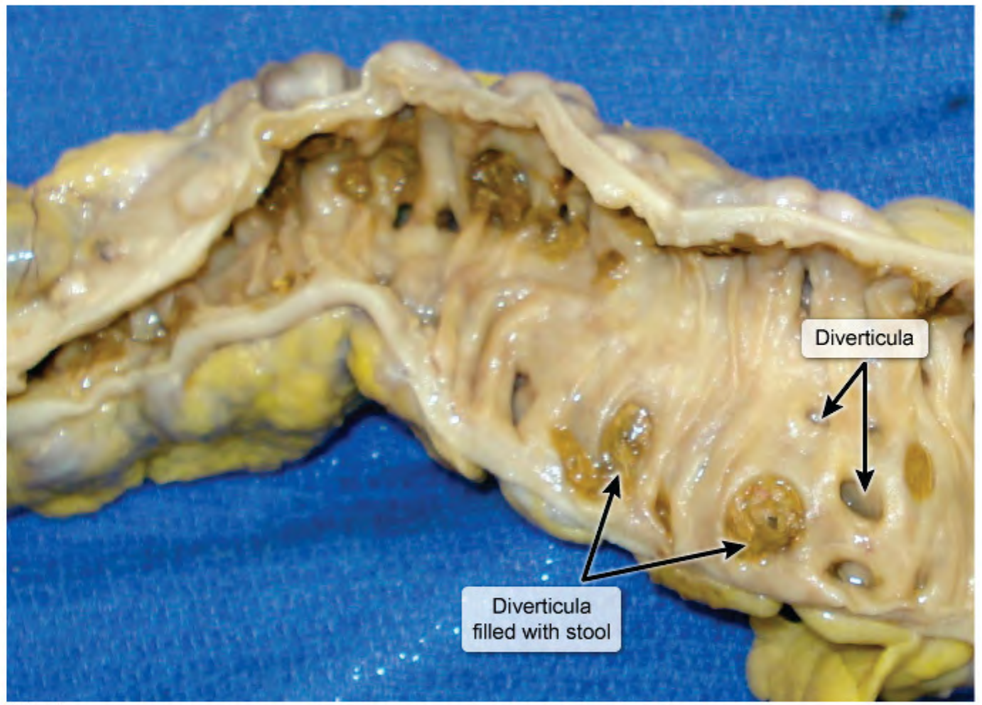

©UWorld

Zoom In | Zoom Out | Reset | New | Existing | My Notebook

https://t.me/USMLEWorldStep1

A 3-month-old boy is evaluated for large-volume diarrhea and failure to thrive. The patient was born via spontaneous vaginal delivery at 38 weeks gestation. His mother reports that the pregnancy was uncomplicated and there is no family history of gastrointestinal disease. Physical examination shows mild abdominal distension, muscle wasting, and pitting edema. Histochemical evaluation reveals absence of enteropeptidase activity in the proximal intestinal villi. Activity of which of the following substances is most likely impaired in this patient?

- A. Amylase
- B. Bile salts
- C. Lactase
- D. Pepsin
- E. Secretin
- F. Trypsin

Submit

https://t.me/USMLEWorldStep1

A 3-month-old boy is evaluated for large-volume diarrhea and failure to thrive. The patient was born via spontaneous vaginal delivery at 38 weeks gestation. His mother reports that the pregnancy was uncomplicated and there is no family history of gastrointestinal disease. Physical examination shows mild abdominal distension, muscle wasting, and pitting edema. Histochemical evaluation reveals absence of enteropeptidase activity in the proximal intestinal villi. Activity of which of the following substances is most likely impaired in this patient?

- A. Amylase (2%)
- ✕ B. Bile salts (1%)
- C. Lactase (13%)
- D. Pepsin (10%)
- E. Secretin (3%)
- ✓ F. Trypsin (69%)

Incorrect
Correct answer
F

69%
Answered correctly

04 secs
Time Spent

2023
Version

Explanation

https://t.me/USMLEWorldStep1

A 3-month-old boy is evaluated for large-volume diarrhea and failure to thrive. The patient was born via
sponta
and th
muscle
proxim

Exhibit Display

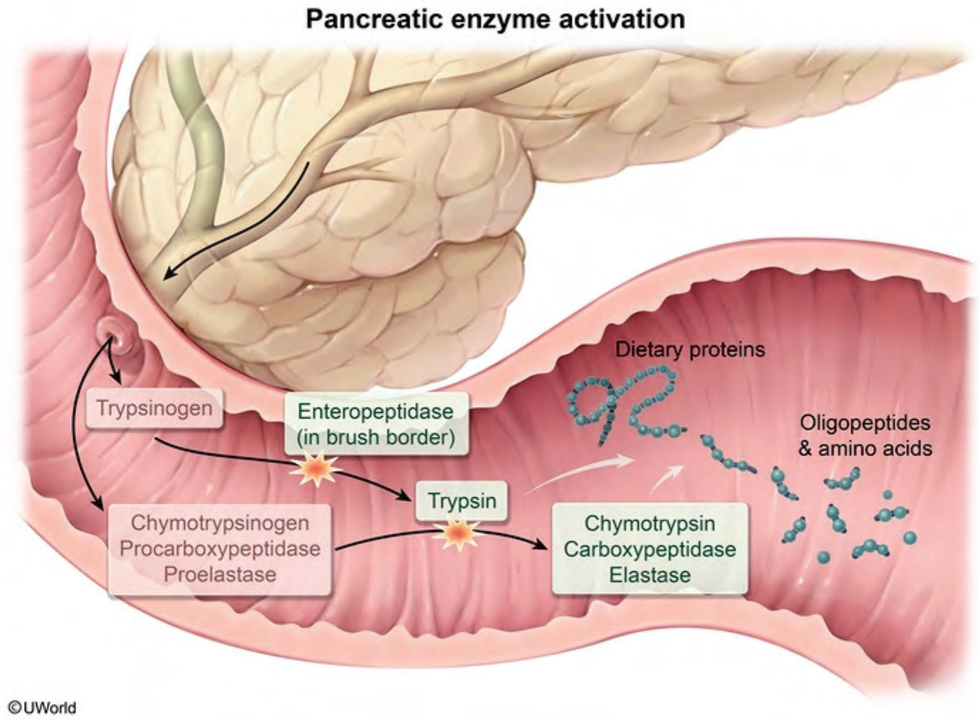

Zoom In | Zoom Out | Reset | New | Existing | My Notebook

Inco
Corre
F

Expl

https://t.me/USMLEWorldStep1

©UWorld

Although chemical digestion of proteins begins in the stomach, the majority of enzymatic breakdown and absorption occurs in the small intestine. Dietary proteins exist predominately as polypeptides; in order to be absorbed, they must be hydrolyzed to tripeptides, dipeptides, and amino acids. Hydrolysis begins in the stomach with the activation of pepsin by hydrochloric acid; it continues in the proximal small intestine, catalyzed by the pancreatic enzymes trypsin, chymotrypsin, carboxypeptidase, and elastase.

Pancreatic enzymes, including trypsin, are secreted in their inactive forms. **Enteropeptidase**, a duodenal brush border enzyme, is responsible for **activation of trypsin** from its inactive precursor, trypsinogen. Once active, trypsin functions to cleave peptide bonds in dietary proteins and activate the other pancreatic enzymes. Enteropeptidase **deficiency** leads to both **protein and fat malabsorption** as trypsin is required to activate enzymes required for both lipid and protein digestion. The disease causes **diarrhea, failure to thrive, and edema** (due to hypoproteinemia).

(Choice A) Amylase is produced by the salivary glands and pancreas; it catalyzes the hydrolysis of complex carbohydrates to simple sugars.

(Choice B) Bile salts are formed through bile acid conjugation with amino acids glycine and taurine. This increases their solubility, allowing them to aid in lipid digestion and absorption through the formation of micelles.

(Choice C) Lactase is produced by the intestinal brush border and is responsible for the hydrolysis of lactose to glucose and galactose. Lactase non-persistence commonly develops during mid-childhood, resulting in lactose intolerance.

(Choice D) Chief cells of the stomach release the inactive form of pepsin, pepsinogen. Exposure to hydrochloric acid in the stomach activates pepsin, initiating protein digestion.

(Choice E) Secretin is a peptide hormone secreted by the S cells of the duodenum; it stimulates the secretion of bicarbonate from the pancreas and inhibits gastric acid secretion in the stomach. Neutralization of the acidic pH of food entering the duodenum from the stomach is necessary for the proper function of pancreatic enzymes.

Educational objective:
The duodenal brush border enzyme enteropeptidase activates trypsin from its inactive precursor, trypsinogen.

https://t.me/USMLEWorldStep1

absorbed, they must be hydrolyzed to tripeptides, dipeptides, and amino acids. Hydrolysis begins in the stomach with the activation of pepsin by hydrochloric acid; it continues in the proximal small intestine, catalyzed by the pancreatic enzymes trypsin, chymotrypsin, carboxypeptidase, and elastase.

Pancreatic enzymes, including trypsin, are secreted in their inactive forms. **Enteropeptidase**, a duodenal brush border enzyme, is responsible for **activation of trypsin** from its inactive precursor, trypsinogen. Once active, trypsin functions to cleave peptide bonds in dietary proteins and activate the other pancreatic enzymes. Enteropeptidase **deficiency** leads to both **protein and fat malabsorption** as trypsin is required to activate enzymes required for both lipid and protein digestion. The disease causes **diarrhea, failure to thrive, and edema** (due to hypoproteinemia).

(Choice A) Amylase is produced by the salivary glands and pancreas; it catalyzes the hydrolysis of complex carbohydrates to simple sugars.

(Choice B) Bile salts are formed through bile acid conjugation with amino acids glycine and taurine. This increases their solubility, allowing them to aid in lipid digestion and absorption through the formation of micelles.

(Choice C) Lactase is produced by the intestinal brush border and is responsible for the hydrolysis of lactose to glucose and galactose. Lactase non-persistence commonly develops during mid-childhood, resulting in lactose intolerance.

(Choice D) Chief cells of the stomach release the inactive form of pepsin, pepsinogen. Exposure to hydrochloric acid in the stomach activates pepsin, initiating protein digestion.

(Choice E) Secretin is a peptide hormone secreted by the S cells of the duodenum; it stimulates the secretion of bicarbonate from the pancreas and inhibits gastric acid secretion in the stomach. Neutralization of the acidic pH of food entering the duodenum from the stomach is necessary for the proper function of pancreatic enzymes.

Educational objective:
The duodenal brush border enzyme enteropeptidase activates trypsin from its inactive precursor, trypsinogen. Trypsin degrades complex polypeptides to dipeptides, tripeptides, and amino acids while activating other pancreatic enzymes. Enteropeptidase deficiency impairs both protein and fat absorption, leading to diarrhea, failure to thrive, and hypoproteinemia.

https://t.me/USMLEWorldStep1

A 36-year-old man comes to the office for follow-up regarding hepatitis C. The patient was last seen 3 years ago for a 2-week history of fatigue, nausea, and decreased appetite; at that time, he was diagnosed with hepatitis C infection due to injection drug use. The patient was offered treatment but declined. He is currently healthy and feels well. There is no family history of liver disease. The patient currently does not use illicit drugs or alcohol. Vital signs are normal. BMI is 26 kg/m^2. Examination is normal. Laboratory results are as follows:

Albumin	3.6 g/dL
Total bilirubin	1.7 mg/dL
Aspartate aminotransferase (SGOT)	54 U/L
Alanine aminotransferase (SGPT)	62 U/L
Hepatitis B surface antigen	negative
Hepatitis B surface antibody	positive
Anti–hepatitis C virus antibody	positive
Hepatitis C RNA	positive
HIV antibody	negative

Liver ultrasound is negative for cirrhosis or masses. If a liver biopsy is performed, which of the following histologic findings would most likely be present in this patient?

- A. Dilated sinusoids with clumped red blood cells
- B. Dysplastic hepatocytes in small clusters and rows
- C. Epithelioid granulomas with prominent fibrosis
- D. Large amount of brown to black pigment in hepatocytes
- E. Lymphocytic infiltration of portal tracts

https://t.me/USMLEWorldStep1

for a 2-week history of fatigue, nausea, and decreased appetite; at that time, he was diagnosed with hepatitis C infection due to injection drug use. The patient was offered treatment but declined. He is currently healthy and feels well. There is no family history of liver disease. The patient currently does not use illicit drugs or alcohol. Vital signs are normal. BMI is 26 kg/m^2. Examination is normal. Laboratory results are as follows:

Albumin	3.6 g/dL
Total bilirubin	1.7 mg/dL
Aspartate aminotransferase (SGOT)	54 U/L
Alanine aminotransferase (SGPT)	62 U/L
Hepatitis B surface antigen	negative
Hepatitis B surface antibody	positive
Anti–hepatitis C virus antibody	positive
Hepatitis C RNA	positive
HIV antibody	negative

Liver ultrasound is negative for cirrhosis or masses. If a liver biopsy is performed, which of the following histologic findings would most likely be present in this patient?

- A. Dilated sinusoids with clumped red blood cells (4%)
- B. Dysplastic hepatocytes in small clusters and rows (15%)
- C. Epithelioid granulomas with prominent fibrosis (11%)
- ✗ D. Large amount of brown to black pigment in hepatocytes (5%)
- ✓ E. Lymphocytic infiltration of portal tracts (63%)

Incorrect
Correct answer
E

63%
Answered correctly

05 secs
Time Spent

2023
Version

https://t.me/USMLEWorldStep1

Explanation

Manifestations of hepatitis C			
	Acute HCV	**Chronic HCV**	**HCV-related cirrhosis**
Time from initial infection	• <6 months	• ≥6 months	• ≥20 years
Laboratory findings	• Negative anti-HCV • Positive HCV RNA • ↑ Aminotransferases	• Positive anti-HCV • Positive HCV RNA • ↑ Aminotransferases	• ↑ bilirubin • Hypoalbuminemia • Prolonged PT • Thrombocytopenia
Pathology findings	• Panlobular lymphocytic inflammation • Hepatocyte injury (eg, ballooning degeneration) • Hepatocyte death (eg, apoptotic bodies)	• Portal lymphocytic inflammation (eg, lymphoid follicles) • Fibrosis • Interface activity	• Extensive fibrosis & bridging fibrous septa • Regenerative parenchymal nodules
AP = alkaline phosphatase; **HCV** = hepatitis C virus; **PT** = prothrombin time.			

This patient has **chronic hepatitis C virus** (HCV), which is confirmed with **positive** tests for **anti-HCV antibodies** and HCV RNA. Intravenous drug users, those who engage in high-risk sexual behavior, patients receiving hemodialysis, and individuals with inadvertent blood exposure are at increased risk.

Acute HCV, lasting approximately 6 months after initial infection, is characterized by negative anti-HCV antibodies and positive HCV RNA. Histologic findings are similar to those of other acute viral hepatitides and include panlobular lymphocytic inflammation (ie, inflammation involving entire lobule) and hepatocyte injury (eg, **ballooning degeneration**), which may lead to cell death (eg, necrosis, apoptosis [ie, **Councilman body**]).

https://t.me/USMLEWorldStep1

This patient has **chronic hepatitis C virus** (HCV), which is confirmed with **positive** tests for **anti-HCV antibodies** and HCV RNA. Intravenous drug users, those who engage in high-risk sexual behavior, patients receiving hemodialysis, and individuals with inadvertent blood exposure are at increased risk.

Acute HCV, lasting approximately 6 months after initial infection, is characterized by negative anti-HCV antibodies and positive HCV RNA. Histologic findings are similar to those of other acute viral hepatitides and include panlobular lymphocytic inflammation (ie, inflammation involving entire lobule) and hepatocyte injury (eg, **ballooning degeneration**), which may lead to cell death (eg, necrosis, apoptosis [ie, **Councilman body**]).

Most cases (~80%) progress to chronic HCV, which is predominantly characterized by **portal tract–based lymphocytic infiltration**, including lymphoid **follicles**, and **fibrosis**. Chronic inflammation causes persistent hepatocyte injury and can involve the hepatocytes adjacent to the portal tracts (ie, **interface activity**). After several decades, chronic HCV can progress to cirrhosis characterized by abnormal hepatic architecture with extensive fibrosis and the formation of bridging fibrous septa that surround regenerative parenchymal nodules.

(Choice A) Congestive hepatopathy results from right-sided heart failure and increased hydrostatic pressure within hepatic sinusoids, which dilate due to the intraluminal accumulation of clumped red blood cells. This predominantly affects the centrilobular regions of the liver and may cause necrosis.

(Choice B) Hepatocellular carcinoma is characterized by dysplastic hepatocytes arranged in clusters and thickened rows. Although it can develop in patients with HCV-related cirrhosis, it is usually identified by ultrasound, which was negative in this patient.

(Choice C) Hepatic sarcoidosis is characterized by aggregates of epithelioid cells (ie, activated macrophages) forming granulomas; when severe, fibrosis and cirrhosis can occur.

(Choice D) Dubin-Johnson syndrome impairs the ability of hepatocytes to excrete conjugated bilirubin into bile canaliculi. The liver grossly appears black, and microscopy shows large amounts of dark brown to black pigment within hepatocyte lysosomes.

Educational objective:
Acute hepatitis C is characterized by panlobular lymphocytic inflammation with hepatocyte injury (eg, ballooning degeneration) and cell death (eg, Councilman bodies). Chronic hepatitis C leads predominantly to portal

https://t.me/USMLEWorldStep1

hemodialysis, and individuals with inadvertent blood exposure are at increased risk.

Acute HCV, lasting approximately 6 months after initial infection, is characterized by negative anti-HCV antibodies and positive HCV RNA. Histologic findings are similar to those of other acute viral hepatitides and include panlobular lymphocytic inflammation (ie, inflammation involving entire lobule) and hepatocyte injury (eg, **ballooning degeneration**), which may lead to cell death (eg, necrosis, apoptosis [ie, **Councilman body**]).

Most cases (~80%) progress to chronic HCV, which is predominantly characterized by **portal tract–based lymphocytic infiltration**, including lymphoid **follicles**, and **fibrosis**. Chronic inflammation causes persistent hepatocyte injury and can involve the hepatocytes adjacent to the portal tracts (ie, **interface activity**). After several decades, chronic HCV can progress to cirrhosis characterized by abnormal hepatic architecture with extensive fibrosis and the formation of bridging fibrous septa that surround regenerative parenchymal nodules.

(Choice A) Congestive hepatopathy results from right-sided heart failure and increased hydrostatic pressure within hepatic sinusoids, which dilate due to the intraluminal accumulation of clumped red blood cells. This predominantly affects the centrilobular regions of the liver and may cause necrosis.

(Choice B) Hepatocellular carcinoma is characterized by dysplastic hepatocytes arranged in clusters and thickened rows. Although it can develop in patients with HCV-related cirrhosis, it is usually identified by ultrasound, which was negative in this patient.

(Choice C) Hepatic sarcoidosis is characterized by aggregates of epithelioid cells (ie, activated macrophages) forming granulomas; when severe, fibrosis and cirrhosis can occur.

(Choice D) Dubin-Johnson syndrome impairs the ability of hepatocytes to excrete conjugated bilirubin into bile canaliculi. The liver grossly appears black, and microscopy shows large amounts of dark brown to black pigment within hepatocyte lysosomes.

Educational objective:
Acute hepatitis C is characterized by panlobular lymphocytic inflammation with hepatocyte injury (eg, ballooning degeneration) and cell death (eg, Councilman bodies). Chronic hepatitis C leads predominantly to portal lymphocytic infiltration, including lymphoid follicle formation, and fibrosis. Histologic findings of cirrhosis include extensive fibrosis and the formation of bridging septa that surround regenerative nodules.

References

https://t.me/USMLEWorldStep1

This patient has **chronic hepatitis C virus** (HCV), which is confirmed with **positive** tests for **anti-HCV antibodies**
and H
hemoc

Acute
and pc
panlob
balloc

Most c
lymph
hepato
severa
extens

(Choi
within
predor

(Choi
thicker
which

(Choi
formin

(Choi
canali
within

Educa
Acute hepatitis C is characterized by panlobular lymphocytic inflammation with hepatocyte injury (eg, ballooning
degeneration) and cell death (eg, Councilman bodies). Chronic hepatitis C leads predominantly to portal

Exhibit Display

Acute viral hepatitis

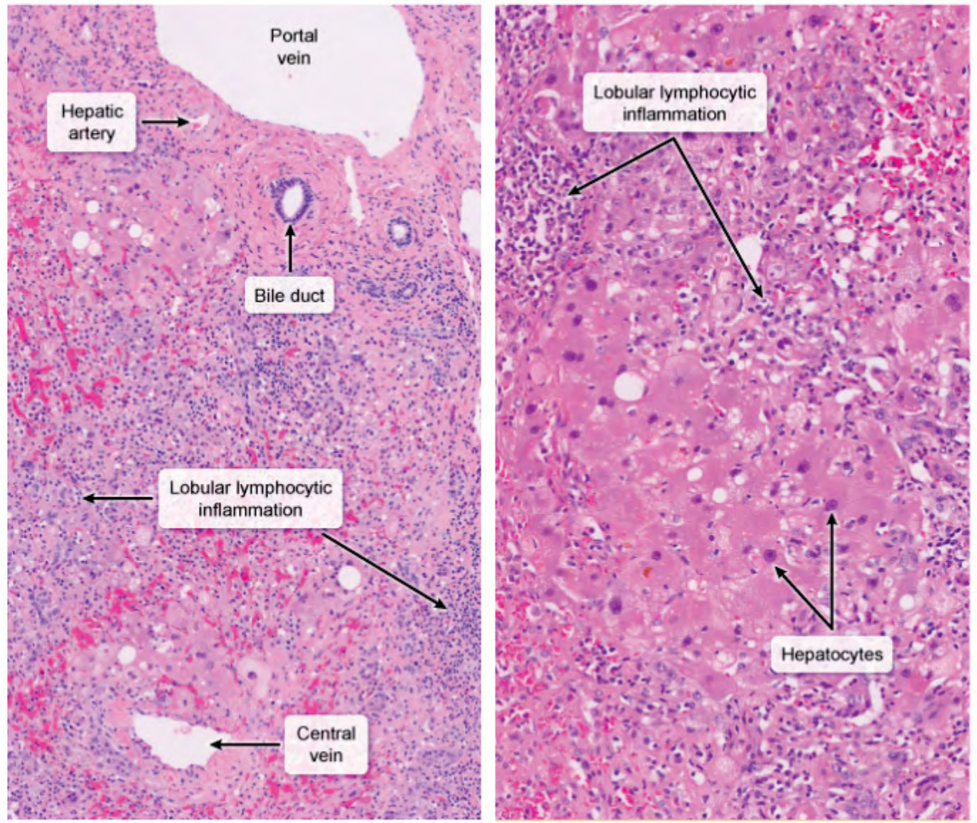

©UWorld

Zoom In | Zoom Out | Reset | New | Existing | My Notebook

https://t.me/USMLEWorldStep1

This patient has **chronic hepatitis C virus** (HCV), which is confirmed with **positive** tests for **anti-HCV antibodies**
and H
hemoc

Acute
and pc
panlob
balloc

Most c
lymph
hepato
severa
extens

(Choi
within
predor

(Choi
thicker
which

(Choi
formin

(Choi
canali
within

Educa

Acute hepatitis C is characterized by panlobular lymphocytic inflammation with hepatocyte injury (eg, ballooning
degeneration) and cell death (eg, Councilman bodies). Chronic hepatitis C leads predominantly to portal

Exhibit Display

Ballooning degeneration

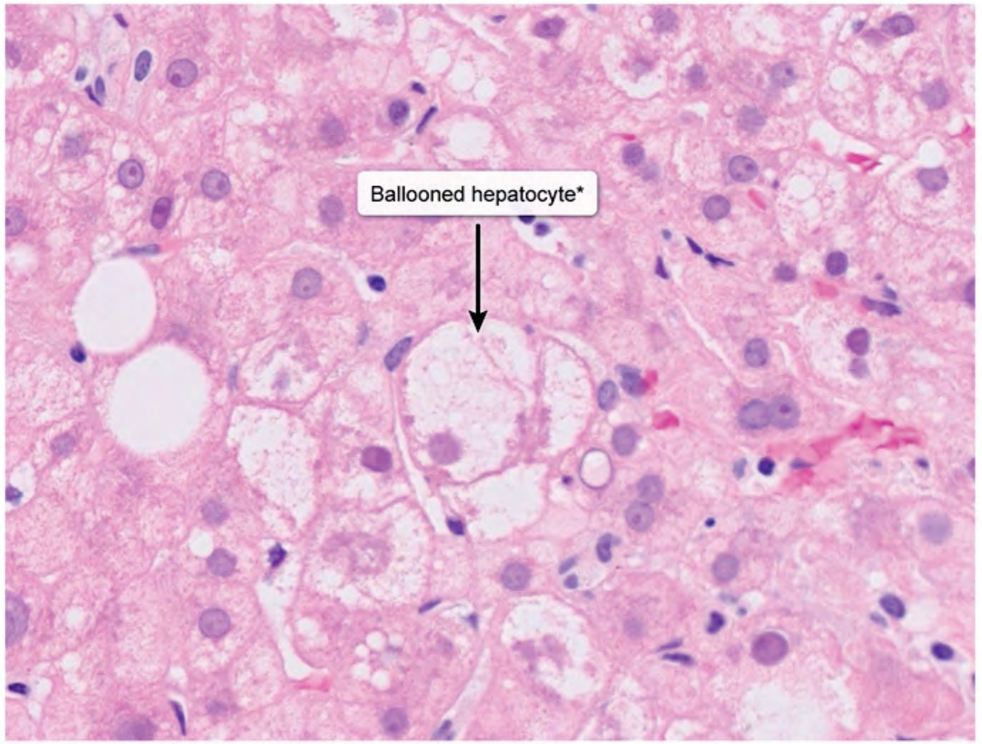

*Hepatocyte injury characterized by cell swelling and cytoplasmic clearing.

©UWorld

Zoom In Zoom Out Reset New | Existing My Notebook

https://t.me/USMLEWorldStep1

This patient has **chronic hepatitis C virus** (HCV), which is confirmed with **positive** tests for **anti-HCV antibodies**
and H
hemoc

Acute
and pc
panlob
balloc

Most c
lymph
hepatc
severa
extens

(Choi
within
predor

(Choi
thicker
which

(Choi
formin

(Choi
canali
within

Educa

Acute hepatitis C is characterized by panlobular lymphocytic inflammation with hepatocyte injury (eg, ballooning
degeneration) and cell death (eg, Councilman bodies). Chronic hepatitis C leads predominantly to portal

Exhibit Display

Apoptotic hepatocyte

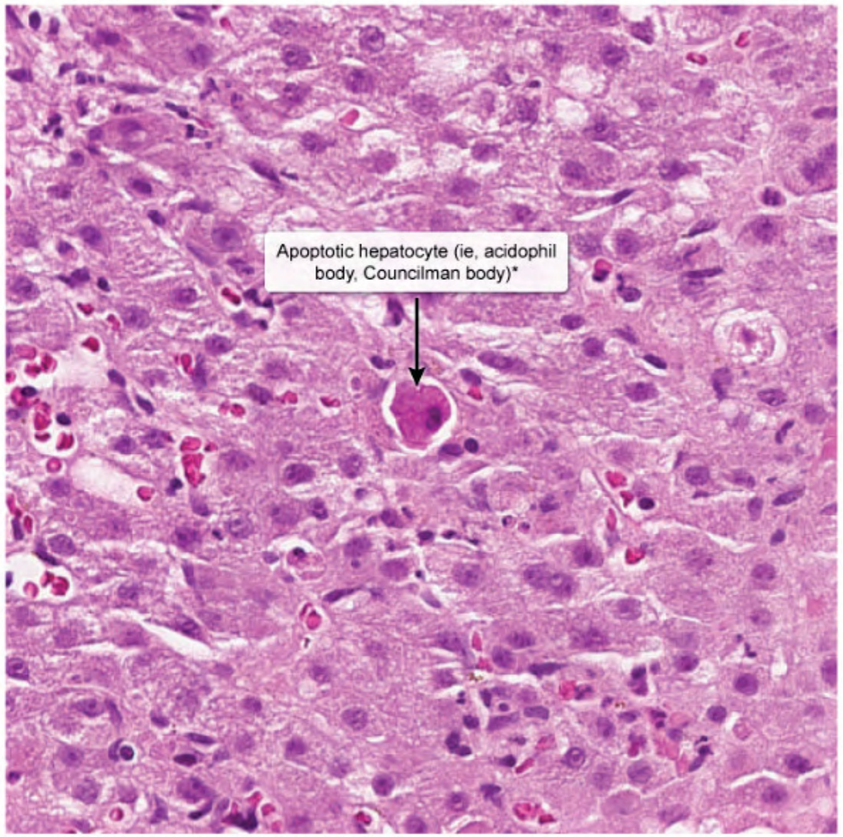

*Dense pink cytoplasm and small, dark (ie, pyknotic) nucleus.

©UWorld

Zoom In | Zoom Out | Reset | New | Existing | My Notebook

https://t.me/USMLEWorldStep1

This patient has **chronic hepatitis C virus** (HCV), which is confirmed with **positive** tests for **anti-HCV antibodies**
and H
hemoc

Acute
and pc
panlob
balloc

Most c
lymph
hepato
severa
extens

(Choi
within
predor

(Choi
thicker
which

(Choi
formin

(Choi
canali
within

Educa
Acute hepatitis C is characterized by panlobular lymphocytic inflammation with hepatocyte injury (eg, ballooning
degeneration) and cell death (eg, Councilman bodies). Chronic hepatitis C leads predominantly to portal

Exhibit Display

Chronic hepatitis C with cirrhosis

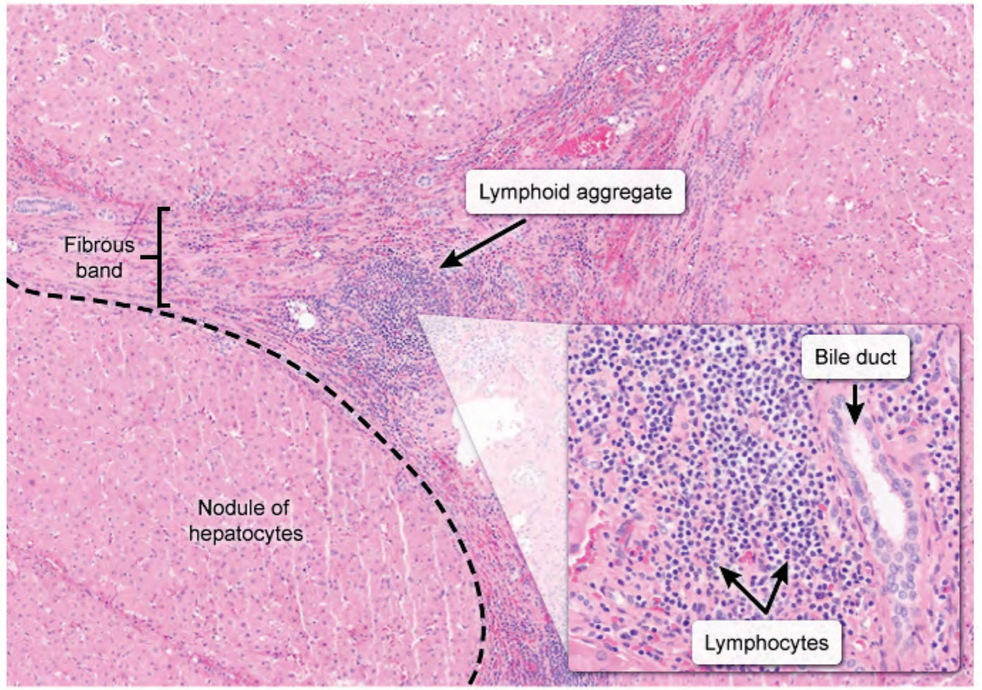

©UWorld

Zoom In | Zoom Out | Reset | New | Existing | My Notebook

https://t.me/USMLEWorldStep1

This patient has **chronic hepatitis C virus** (HCV), which is confirmed with **positive** tests for **anti-HCV antibodies**
and H
hemoc

Acute
and pc
panlob
balloc

Most c
lymph
hepato
severa
extens

(Choi
within
predor

(Choi
thicker
which

(Choi
formin

(Choi
canali
within

Educa

Acute hepatitis C is characterized by panlobular lymphocytic inflammation with hepatocyte injury (eg, ballooning degeneration) and cell death (eg, Councilman bodies). Chronic hepatitis C leads predominantly to portal

Exhibit Display

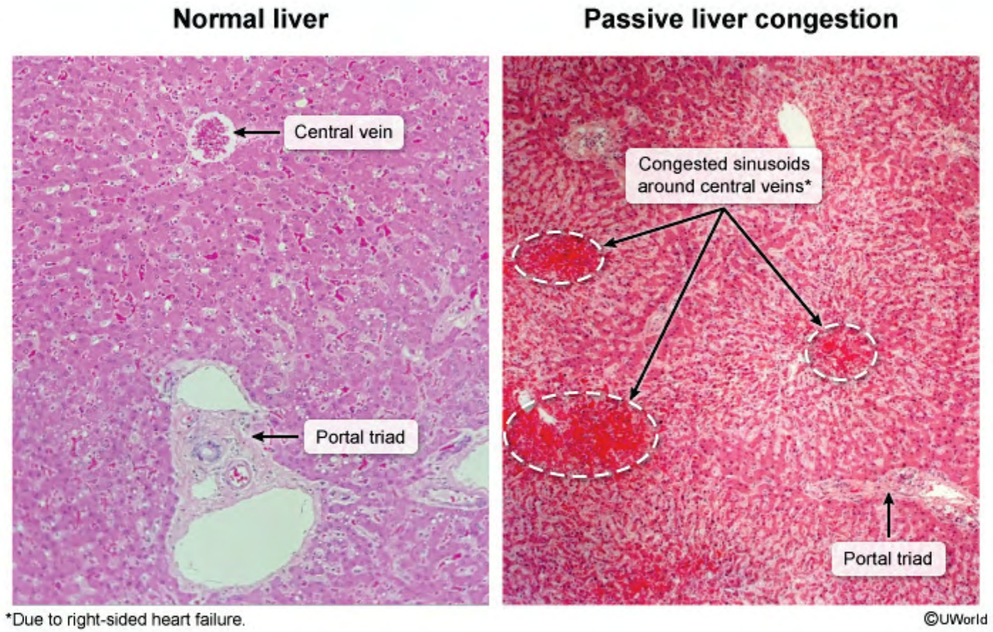

Zoom In | Zoom Out | Reset | New | Existing | My Notebook

https://t.me/USMLEWorldStep1

This patient has **chronic hepatitis C virus** (HCV), which is confirmed with **positive** tests for **anti-HCV antibodies**
and H
hemoc

Acute
and pc
panlob
balloc

Most c
lymph
hepato
severa
extens

(Choi
within
predor

(Choi
thicker
which

(Choi
formin

(Choi
canali
within

Educa

Acute hepatitis C is characterized by panlobular lymphocytic inflammation with hepatocyte injury (eg, ballooning
degeneration) and cell death (eg, Councilman bodies). Chronic hepatitis C leads predominantly to portal

Exhibit Display

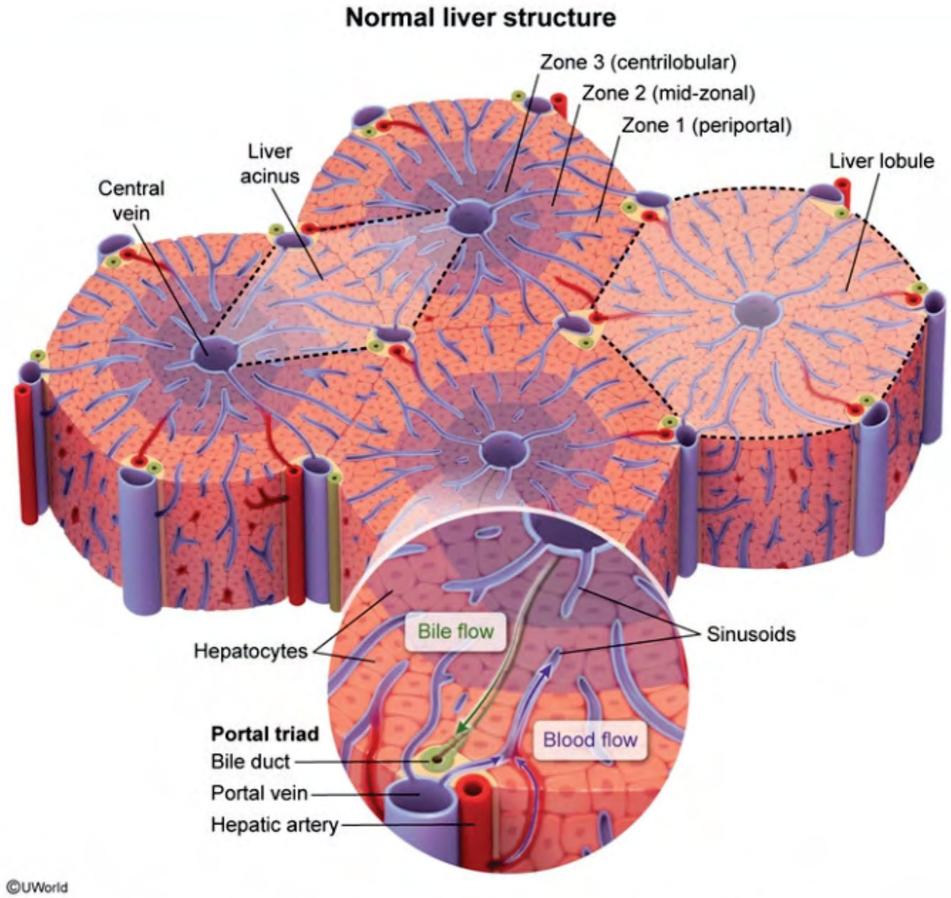

Zoom In | Zoom Out | Reset | New | Existing | My Notebook

https://t.me/USMLEWorldStep1

This patient has **chronic hepatitis C virus** (HCV), which is confirmed with **positive** tests for **anti-HCV antibodies**
and H
hemoc

Acute
and pc
panlob
balloc

Most c
lymph
hepato
severa
extens

(Choi
within
predor

(Choi
thicker
which

(Choi
formin

(Choi
canali
within

Educa
Acute hepatitis C is characterized by panlobular lymphocytic inflammation with hepatocyte injury (eg, ballooning
degeneration) and cell death (eg, Councilman bodies). Chronic hepatitis C leads predominantly to portal

Exhibit Display

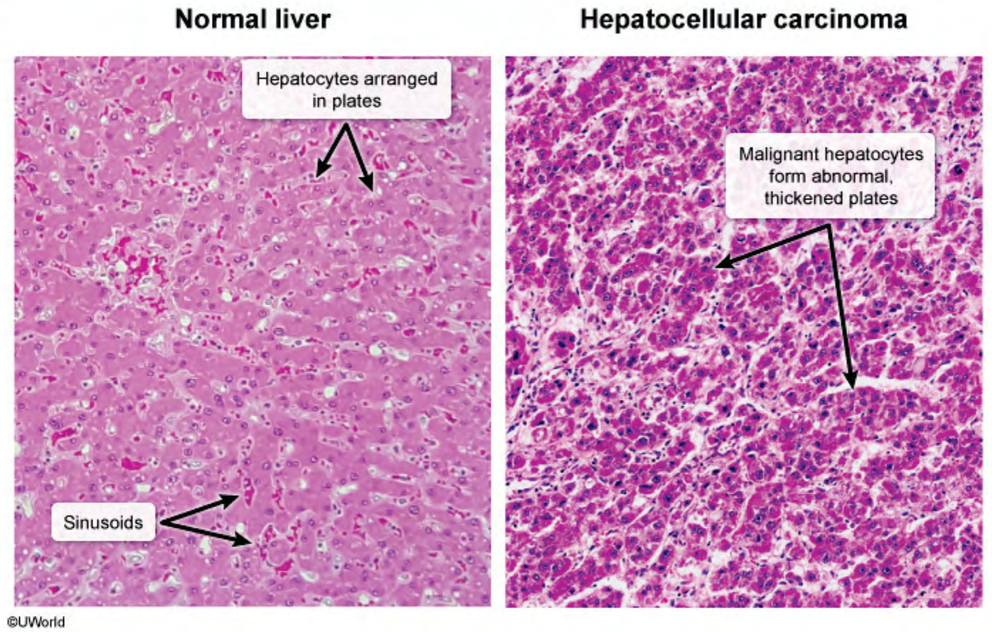

Zoom In | Zoom Out | Reset | New | Existing | My Notebook

https://t.me/USMLEWorldStep1

This patient has **chronic hepatitis C virus** (HCV), which is confirmed with **positive** tests for **anti-HCV antibodies**
and H
hemoc

Acute
and pc
panlob
balloc

Most c
lymph
hepato
severa
extens

(Choi
within
predor

(Choi
thicker
which

(Choi
formin

(Choi
canali
within

Educa
Acute hepatitis C is characterized by panlobular lymphocytic inflammation with hepatocyte injury (eg, ballooning
degeneration) and cell death (eg, Councilman bodies). Chronic hepatitis C leads predominantly to portal

Exhibit Display

Hepatic sarcoidosis

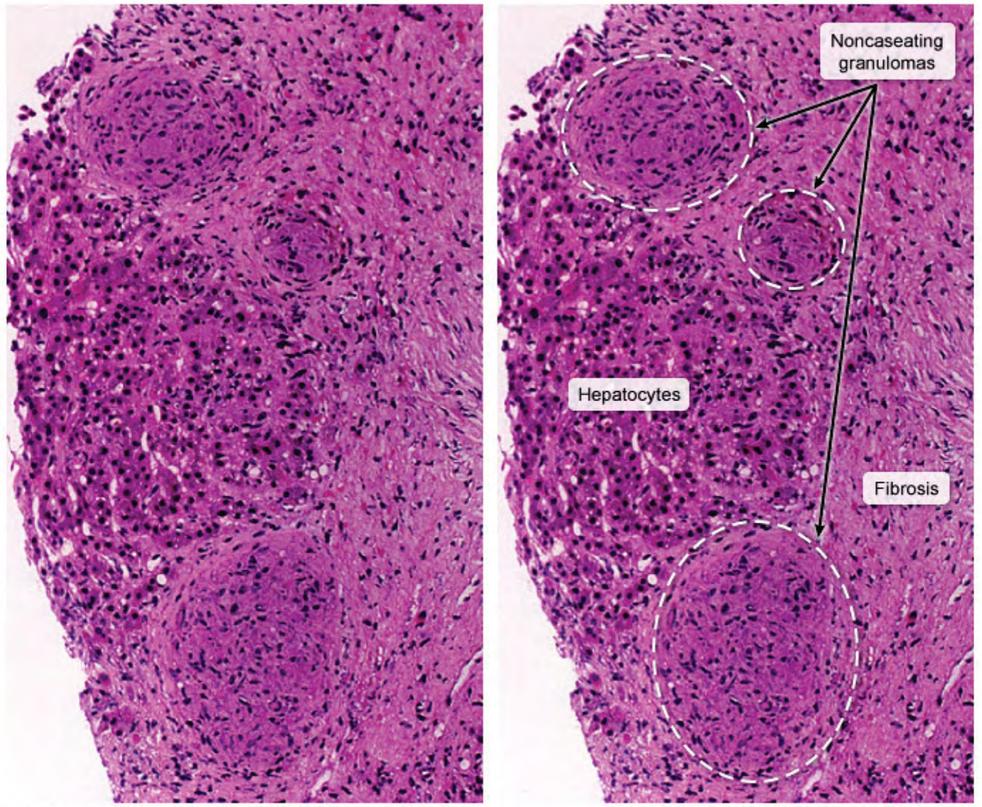

Zoom In | Zoom Out | Reset | New | Existing | My Notebook

https://t.me/USMLEWorldStep1

This patient has **chronic hepatitis C virus** (HCV), which is confirmed with **positive** tests for **anti-HCV antibodies** and H
hemoc

Acute
and pc
panlob
balloc

Most c
lymph
hepatc
severa
extens

(Choi
within
predor

(Choi
thicker
which

(Choi
formin

(Choi
canali
within

Educa

Acute hepatitis C is characterized by panlobular lymphocytic inflammation with hepatocyte injury (eg, ballooning degeneration) and cell death (eg, Councilman bodies). Chronic hepatitis C leads predominantly to portal

Exhibit Display

Bilirubin metabolism

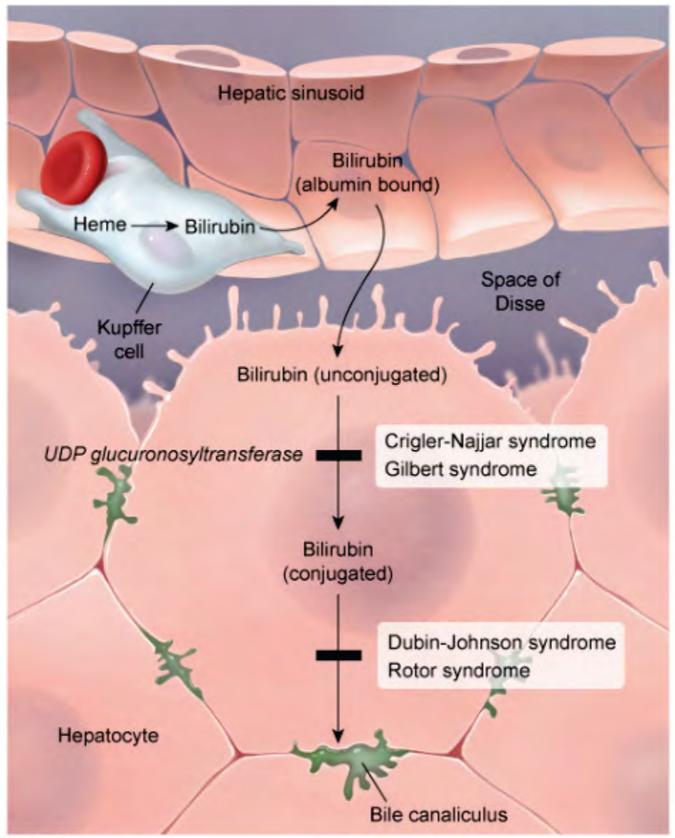

Zoom In | Zoom Out | Reset | New | Existing | My Notebook

https://t.me/USMLEWorldStep1

A 4-week-old boy is brought to the office for a routine well-baby visit. The boy has been exclusively breastfeeding every 2-3 hours and is making 6 or 7 wet diapers a day. His urine has appeared dark yellow, and he has had a few pale-colored stools. His parents also noticed that his skin has appeared yellow for the past 2 weeks, but they were not concerned as they heard from friends that yellow skin is common with breastfeeding. The patient was born full term without complications by vaginal delivery to a primigravida. On physical examination, he is well-appearing with icteric sclerae and jaundice of the head and upper chest. Abdominal examination reveals a mildly enlarged and firm liver. Liver function results are as follows:

Total bilirubin	7.3 mg/dL
Direct bilirubin	5 mg/dL

Which of the following is the most likely mechanism for the patient's presentation?

- A. Extrahepatic obstruction of bile ducts
- B. Genetic mutation causing reduced glucuronidation
- C. Impaired galactose metabolism
- D. Increased enterohepatic circulation of bilirubin
- E. Maternal antibody-mediated red blood cell destruction

Submit

https://t.me/USMLEWorldStep1

A 4-week-old boy is brought to the office for a routine well-baby visit. The boy has been exclusively breastfeeding every 2-3 hours and is making 6 or 7 wet diapers a day. His urine has appeared dark yellow, and he has had a few pale-colored stools. His parents also noticed that his skin has appeared yellow for the past 2 weeks, but they were not concerned as they heard from friends that yellow skin is common with breastfeeding. The patient was born full term without complications by vaginal delivery to a primigravida. On physical examination, he is well-appearing with icteric sclerae and jaundice of the head and upper chest. Abdominal examination reveals a mildly enlarged and firm liver. Liver function results are as follows:

Total bilirubin	7.3 mg/dL
Direct bilirubin	5 mg/dL

Which of the following is the most likely mechanism for the patient's presentation?

- ✓ A. Extrahepatic obstruction of bile ducts (62%)
- ✗ B. Genetic mutation causing reduced glucuronidation (20%)
- C. Impaired galactose metabolism (3%)
- D. Increased enterohepatic circulation of bilirubin (9%)
- E. Maternal antibody-mediated red blood cell destruction (3%)

Incorrect
Correct answer
A

62%
Answered correctly

04 secs
Time Spent

2023
Version

Explanation

Biliary atresia

Portal tract edema & inflammation

Intrahepatic bile

Fibrosis

https://t.me/USMLEWorldStep1

A. Extrahepatic obstruction of bile ducts (62%)

B. Genetic mutation causing reduced glucuronidation (20%)

Exhibit Display

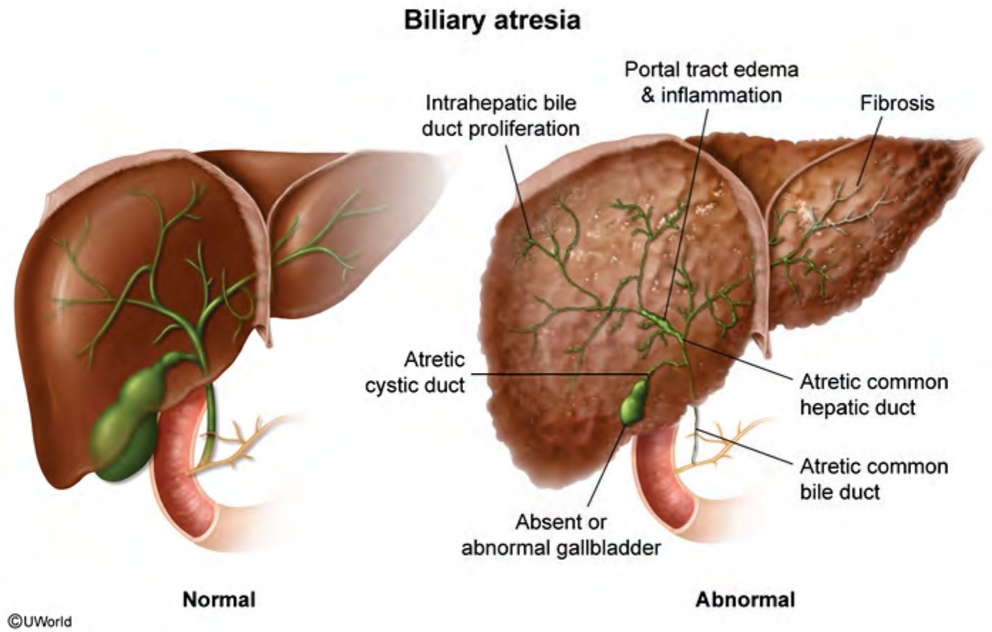

Zoom In | Zoom Out | Reset | New | Existing | My Notebook

©UWorld

Biliary atresia is a progressive, complete or partial **obstruction** of **extrahepatic bile ducts**. The biliary tree is

https://t.me/USMLEWorldStep1

Biliary atresia is a progressive, complete or partial **obstruction** of **extrahepatic bile ducts**. The biliary tree is normal at birth and subsequently undergoes destruction that is thought to be immune-related or viral-induced. Infants may appear healthy at birth, but then present with **jaundice** within the first 2 months of life, along with **dark urine** and **acholic** (pale or clay-colored) **stools** due to excessive renal excretion of bilirubin and lack of intestinal bile, respectively. Physical examination may also reveal firm hepatomegaly due to inflammation. Laboratory findings, including **elevated direct bilirubin** and gamma-glutamyl transferase, are consistent with cholestasis.

Liver biopsy is usually diagnostic and reveals intrahepatic bile duct proliferation, portal tract edema, and fibrosis. Urgent surgical intervention is required, as lack of intervention can lead to death (due to cirrhosis) usually within 2 years.

(Choice B) Gilbert syndrome is an inherited, benign condition of reduced production of glucuronyl transferase, a hepatic enzyme responsible for glucuronidation (ie, conversion of bilirubin to its excretable form). Patients are usually asymptomatic except at times of stress (eg, fasting, illness) during which mild, indirect hyperbilirubinemia and jaundice are present.

(Choice C) Galactosemia (galactose-1-phosphate uridyl transferase [GALT] deficiency) is characterized by defective metabolism of galactose, a breakdown product of lactose that is then normally metabolized to glucose. Both direct and indirect bilirubin levels may be elevated. However, infants would present with vomiting, diarrhea, and lethargy during the first few days of life due to inability to digest breast milk or formula.

(Choice D) Breast milk jaundice causes an indirect hyperbilirubinemia that peaks at age 2 weeks. The pathogenesis likely involves an enzyme, beta-glucuronidase, in breast milk that deconjugates bilirubin. This causes increased absorption and, therefore, increased enterohepatic circulation of bilirubin. Urine and stool appearance are unaffected.

(Choice E) Hemolytic disease of the newborn can result from Rh incompatibility (eg, Rh-positive infant and Rh-negative mother) or ABO incompatibility (eg, A+ infant and O+ mother). Patients develop jaundice on the first day of life due to indirect hyperbilirubinemia, and a positive direct Coombs (antiglobulin) test confirms the presence of antibody-mediated hemolysis.

Educational objective:

https://t.me/USMLEWorldStep1

Infants may appear healthy at birth, but then present with **jaundice** within the first 2 months of life, along with **dark urine** and **acholic** (pale or clay-colored) **stools** due to excessive renal excretion of bilirubin and lack of intestinal bile, respectively. Physical examination may also reveal firm hepatomegaly due to inflammation. Laboratory findings, including **elevated direct bilirubin** and gamma-glutamyl transferase, are consistent with cholestasis.

Liver biopsy is usually diagnostic and reveals intrahepatic bile duct proliferation, portal tract edema, and fibrosis. Urgent surgical intervention is required, as lack of intervention can lead to death (due to cirrhosis) usually within 2 years.

(Choice B) Gilbert syndrome is an inherited, benign condition of reduced production of glucuronyl transferase, a hepatic enzyme responsible for glucuronidation (ie, conversion of bilirubin to its excretable form). Patients are usually asymptomatic except at times of stress (eg, fasting, illness) during which mild, indirect hyperbilirubinemia and jaundice are present.

(Choice C) Galactosemia (galactose-1-phosphate uridyl transferase [GALT] deficiency) is characterized by defective metabolism of galactose, a breakdown product of lactose that is then normally metabolized to glucose. Both direct and indirect bilirubin levels may be elevated. However, infants would present with vomiting, diarrhea, and lethargy during the first few days of life due to inability to digest breast milk or formula.

(Choice D) Breast milk jaundice causes an indirect hyperbilirubinemia that peaks at age 2 weeks. The pathogenesis likely involves an enzyme, beta-glucuronidase, in breast milk that deconjugates bilirubin. This causes increased absorption and, therefore, increased enterohepatic circulation of bilirubin. Urine and stool appearance are unaffected.

(Choice E) Hemolytic disease of the newborn can result from Rh incompatibility (eg, Rh-positive infant and Rh-negative mother) or ABO incompatibility (eg, A+ infant and O+ mother). Patients develop jaundice on the first day of life due to indirect hyperbilirubinemia, and a positive direct Coombs (antiglobulin) test confirms the presence of antibody-mediated hemolysis.

Educational objective:
Biliary atresia, or obstruction of extrahepatic bile ducts, presents with jaundice, dark urine, and acholic stools in the first 2 months of life due to conjugated hyperbilirubinemia. Biopsy reveals intrahepatic bile duct proliferation, portal tract edema, and fibrosis.

https://t.me/USMLEWorldStep1

Infants may appear healthy at birth, but then present with **jaundice** within the first 2 months of life, along with **dark urine** and **acholic** (pale or clay-colored) **stools** due to excessive renal excretion of bilirubin and lack of intestinal bile, re
finding

Liver b
Urgen
years.

(Choi
hepati
usuall
and ja

(Choi
defect
Both d
and le

(Choi
pathog
cause
appea

(Choi
negati
of life
antibo

Educa
Biliary
first 2 months of life due to conjugated hyperbilirubinemia. Biopsy reveals intrahepatic bile duct proliferation, portal tract edema, and fibrosis.

Exhibit Display

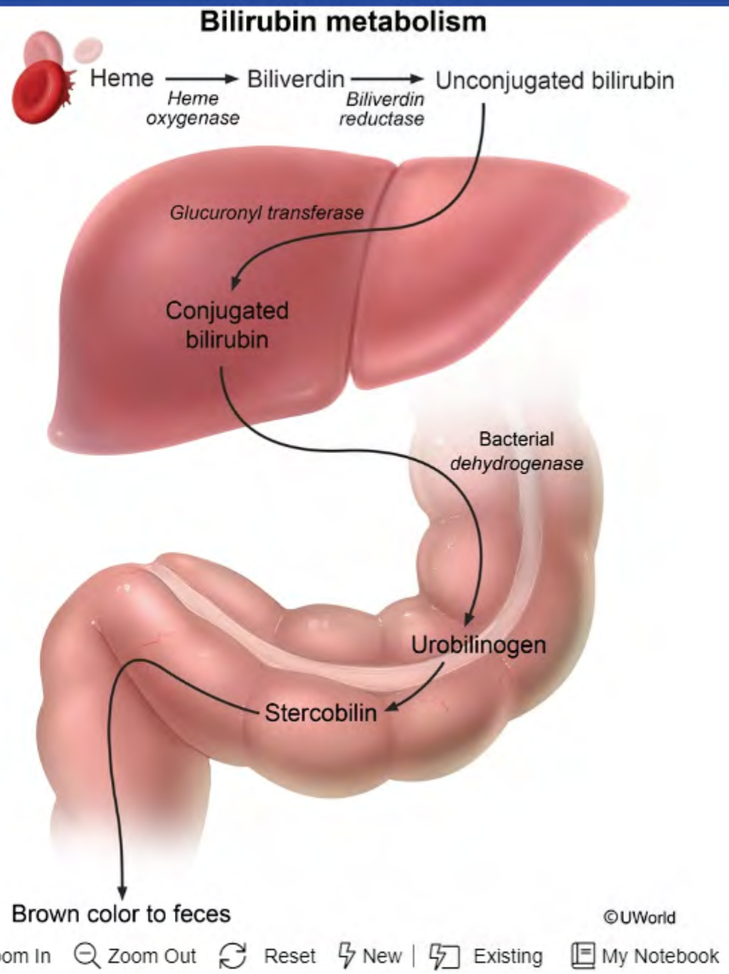

Zoom In | Zoom Out | Reset | New | Existing | My Notebook

https://t.me/USMLEWorldStep1

A 34-year-old man comes to the office to establish medical care. The patient recently emigrated from Eastern Asia. He has no chronic medical conditions but reports intermittent abdominal discomfort and episodic diarrhea over the past several months. He has also experienced an occasional dry cough and throat irritation. Physical examination shows no abnormalities. Serologic testing for *Strongyloides stercoralis* IgG is positive. Which of the following findings would be most suggestive of active infection by the pathogen?

- A. Multiloculated liver cyst
- B. Perianal egg deposition
- C. Proglottids in the stool
- D. Rhabditiform larvae in the stool
- E. Trophozoites and cysts in the stool

Submit

https://t.me/USMLEWorldStep1

A 34-year-old man comes to the office to establish medical care. The patient recently emigrated from Eastern Asia. He has no chronic medical conditions but reports intermittent abdominal discomfort and episodic diarrhea over the past several months. He has also experienced an occasional dry cough and throat irritation. Physical examination shows no abnormalities. Serologic testing for *Strongyloides stercoralis* IgG is positive. Which of the following findings would be most suggestive of active infection by the pathogen?

- ✗ A. Multiloculated liver cyst (4%)
- B. Perianal egg deposition (10%)
- C. Proglottids in the stool (12%)
- ✓ D. Rhabditiform larvae in the stool (49%)
- E. Trophozoites and cysts in the stool (22%)

Incorrect
Correct answer
D

49%
Answered correctly

03 secs
Time Spent

2023
Version

Explanation

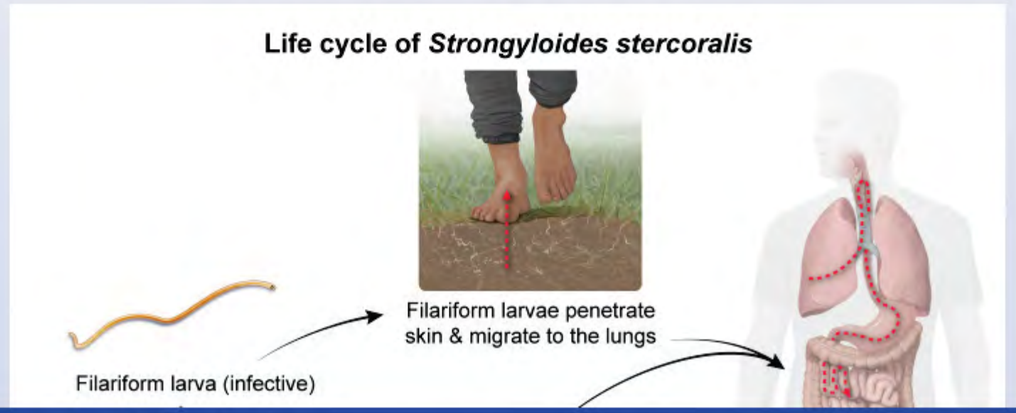

https://t.me/USMLEWorldStep1

A 34-year-old man comes to the office to establish medical care. The patient recently emigrated from Eastern Asia. over th examin followi

Exhibit Display

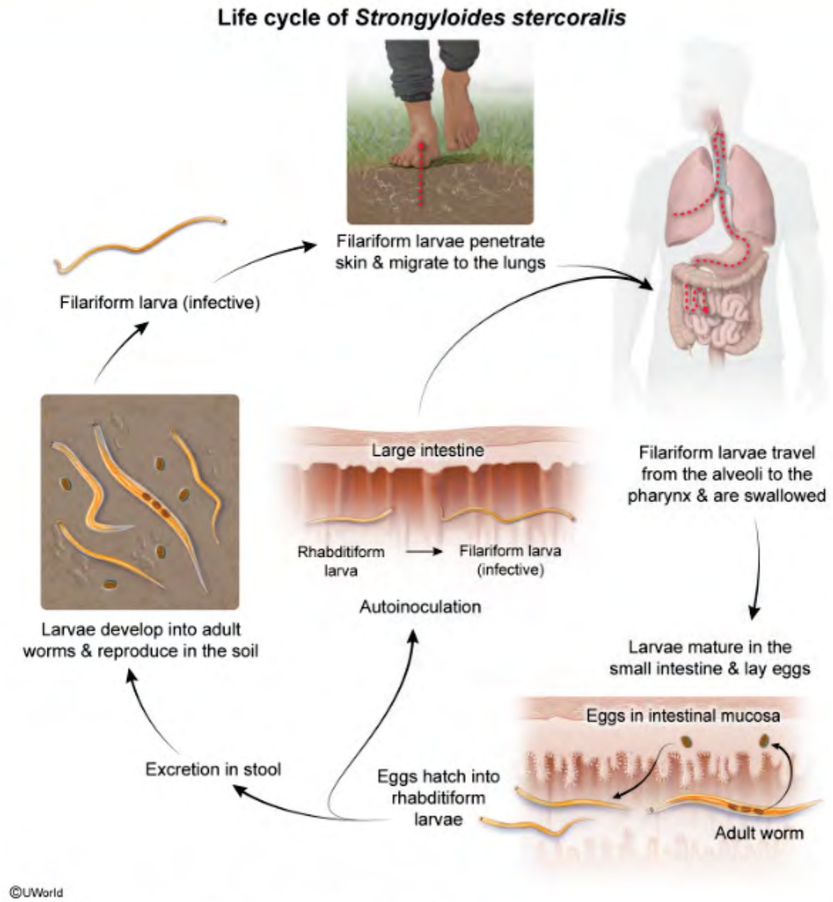

Zoom In | Zoom Out | Reset | New | Existing | My Notebook

Filariform larva (infective)

https://t.me/USMLEWorldStep1

©UWorld

Strongyloides stercoralis is a roundworm endemic to tropical and subtropical areas of Southeast Asia, Africa, and Western Pacific nations. It is transmitted when **filariform larvae** (infective) in soil contaminated with human feces come into **direct contact** with skin (eg, walking barefoot).

After penetrating the skin, larva migrate through the bloodstream/lymphatics to the lungs, enter the alveoli, and ascend the tracheobronchial tree to become swallowed. The larvae then burrow into the intestinal mucosa, where they mature. Adult worms lay eggs that hatch within the intestinal lumen, forming **rhabditiform larvae** (noninfective) that are excreted in **stool**. Rhabditiform larvae can also transform into filariform larvae that reinfect the host through the intestinal mucosa or perianal skin (**autoinoculation**).

Most patients are asymptomatic, but **pulmonary** (eg, dyspnea, wheezing, dry cough) or **gastrointestinal** symptoms (eg, constipation, diarrhea, abdominal pain) can occur. Patients may also develop linear, pruritic, erythematous streaks (**larva currens**) on the thighs and buttocks due to subcutaneous migration of filariform larvae after autoinoculation of the perianal skin.

Although serology can aid in the diagnosis, positive *S stercoralis* IgG can indicate current or resolved infection (IgG often persists following eradication); **active infection** is diagnosed when rhabditiform larvae are identified in stool. Eggs and adult parasites are usually seen only in intestinal biopsies.

(Choice A) *Echinococcus* is an animal tapeworm (eg, dogs, sheep) that can cause large liver cysts and pulmonary symptoms in humans. It is usually diagnosed with a combination of imaging (eg, hydatid cysts are visualized on liver ultrasound) and serologic tests.

(Choice B) *Enterobius vermicularis* (pinworms) migrate out of the anus at night to deposit eggs on the surrounding perianal folds. Eggs can be detected by examining a piece of adhesive tape briefly applied to the perianal region shortly after the patient awakens. Perianal itching usually occurs.

(Choice C) Intestinal tapeworms (eg, *Taenia solium*, *Taenia saginata*, *Diphyllobothrium latum*) are flatworms made up of multiple segments (proglottids). These are shed from the distal end of the worm and can be detected in the stool of infected individuals. Most cases are asymptomatic.

(Choice E) Trophozoites and cysts are seen in the stool of patients with intestinal protozoal infections caused by

https://t.me/USMLEWorldStep1

ascend the tracheobronchial tree to become swallowed. The larvae then burrow into the intestinal mucosa, where they mature. Adult worms lay eggs that hatch within the intestinal lumen, forming **rhabditiform larvae** (noninfective) that are excreted in **stool**. Rhabditiform larvae can also transform into filariform larvae that reinfect the host through the intestinal mucosa or perianal skin (**autoinoculation**).

Most patients are asymptomatic, but **pulmonary** (eg, dyspnea, wheezing, dry cough) or **gastrointestinal** symptoms (eg, constipation, diarrhea, abdominal pain) can occur. Patients may also develop linear, pruritic, erythematous streaks (**larva currens**) on the thighs and buttocks due to subcutaneous migration of filariform larvae after autoinoculation of the perianal skin.

Although serology can aid in the diagnosis, positive *S stercoralis* IgG can indicate current or resolved infection (IgG often persists following eradication); **active infection** is diagnosed when rhabditiform larvae are identified in stool. Eggs and adult parasites are usually seen only in intestinal biopsies.

(Choice A) *Echinococcus* is an animal tapeworm (eg, dogs, sheep) that can cause large liver cysts and pulmonary symptoms in humans. It is usually diagnosed with a combination of imaging (eg, hydatid cysts are visualized on liver ultrasound) and serologic tests.

(Choice B) *Enterobius vermicularis* (pinworms) migrate out of the anus at night to deposit eggs on the surrounding perianal folds. Eggs can be detected by examining a piece of adhesive tape briefly applied to the perianal region shortly after the patient awakens. Perianal itching usually occurs.

(Choice C) Intestinal tapeworms (eg, *Taenia solium*, *Taenia saginata*, *Diphyllobothrium latum*) are flatworms made up of multiple segments (proglottids). These are shed from the distal end of the worm and can be detected in the stool of infected individuals. Most cases are asymptomatic.

(Choice E) Trophozoites and cysts are seen in the stool of patients with intestinal protozoal infections caused by *Giardia intestinalis* and *Entamoeba histolytica*. Patients typically have diarrhea but no pulmonary symptoms.

Educational objective:
Strongyloides stercoralis infection involves filariform (infective) larvae penetrating human skin, traveling to the lungs, and then being swallowed. The parasites mature in the small intestine, laying eggs in the mucosa that hatch into rhabditiform (noninfective) larvae. Rhabditiform larvae can be detected on stool microscopy, which is diagnostic of active infection.

https://t.me/USMLEWorldStep1

and Western Pacific nations. It is transmitted when **filariform larvae** (infective) in soil contaminated with human feces come into **direct contact** with skin (eg, walking barefoot).

After p
ascen
they m
(nonin
the ho

Most p
sympt
erythe
larvae

Althou
often p
Eggs a

(Choi
sympt
liver u

(Choi
surrou
perian

(Choi
up of r
stool c

(Choi
Giardi

Educational objective:

Strongyloides stercoralis infection involves filariform (infective) larvae penetrating human skin, traveling to the

Exhibit Display

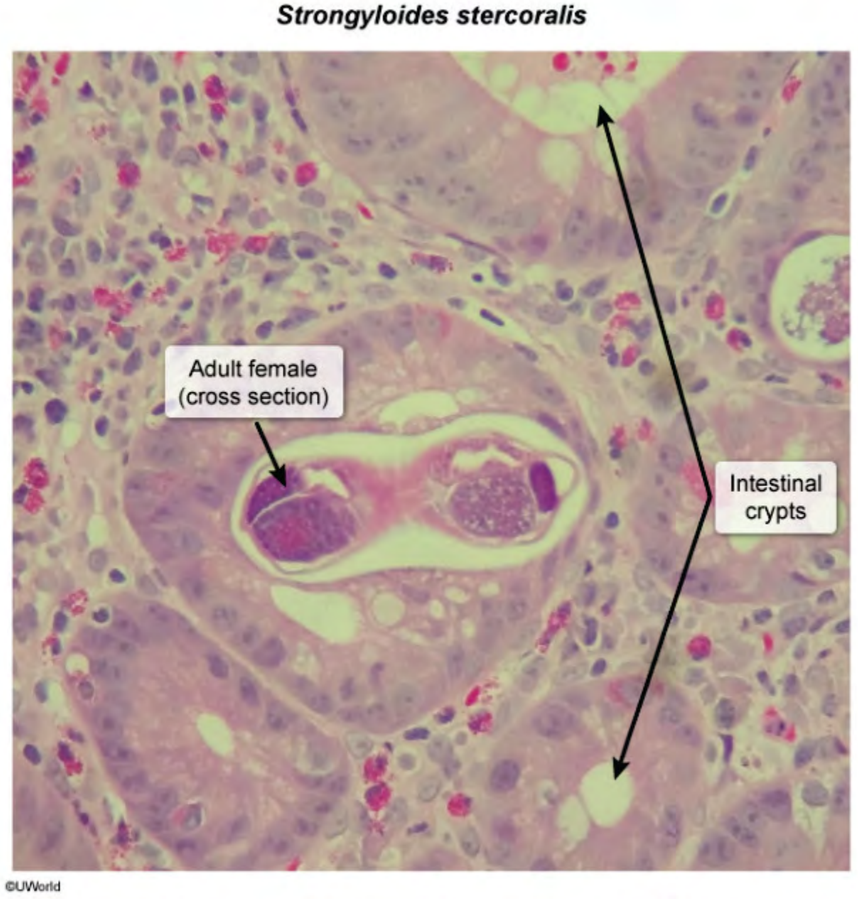

Zoom In Zoom Out Reset New | Existing My Notebook

and Western Pacific nations. It is transmitted when **filariform larvae** (infective) in soil contaminated with human feces come into **direct contact** with skin (eg, walking barefoot).

After p
ascen
they m
(nonin
the ho

Most p
sympt
erythe
larvae

Althou
often p
Eggs a

(Choi
sympt
liver u

(Choi
surrou
perian

(Choi
up of r
stool c

(Choi
Giardi

Educational objective:

Strongyloides stercoralis infection involves filariform (infective) larvae penetrating human skin, traveling to the

Exhibit Display

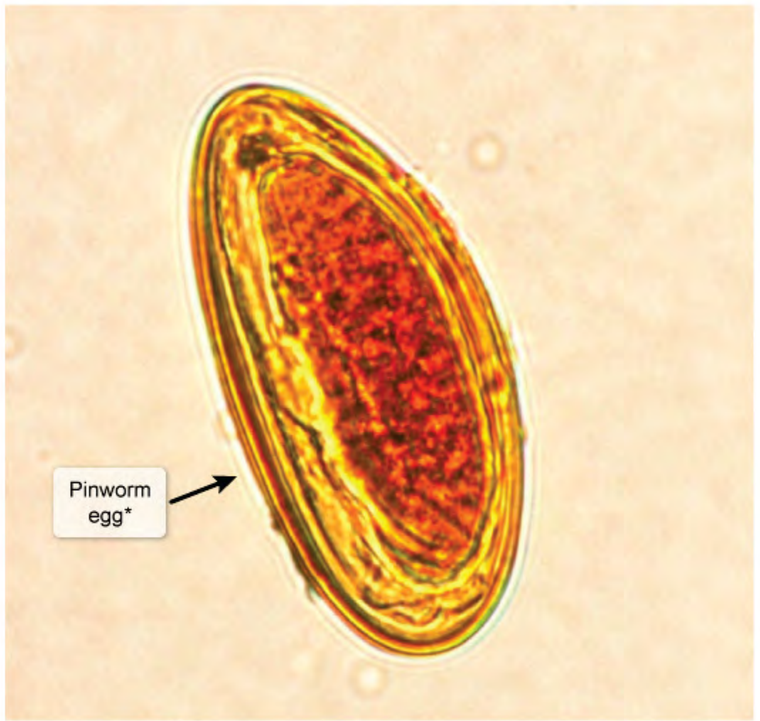

Zoom In | Zoom Out | Reset | New | Existing | My Notebook

https://t.me/USMLEWorldStep1

feces come into **direct contact** with skin (eg, walking barefoot).

After p
ascen
they m
(nonin
the ho

Most p
sympt
erythe
larvae

Althou
often p
Eggs a

(Choi
sympt
liver u

(Choi
surrou
perian

(Choi
up of r
stool c

(Choi Trophozoites and cysts are seen in the stool of patients with intestinal protozoal infections caused by *Giardia intestinalis* and *Entamoeba histolytica*. Patients typically have diarrhea but no pulmonary symptoms.

Educational objective:

Strongyloides stercoralis infection involves filariform (infective) larvae penetrating human skin, traveling to the

Exhibit Display

Giardia

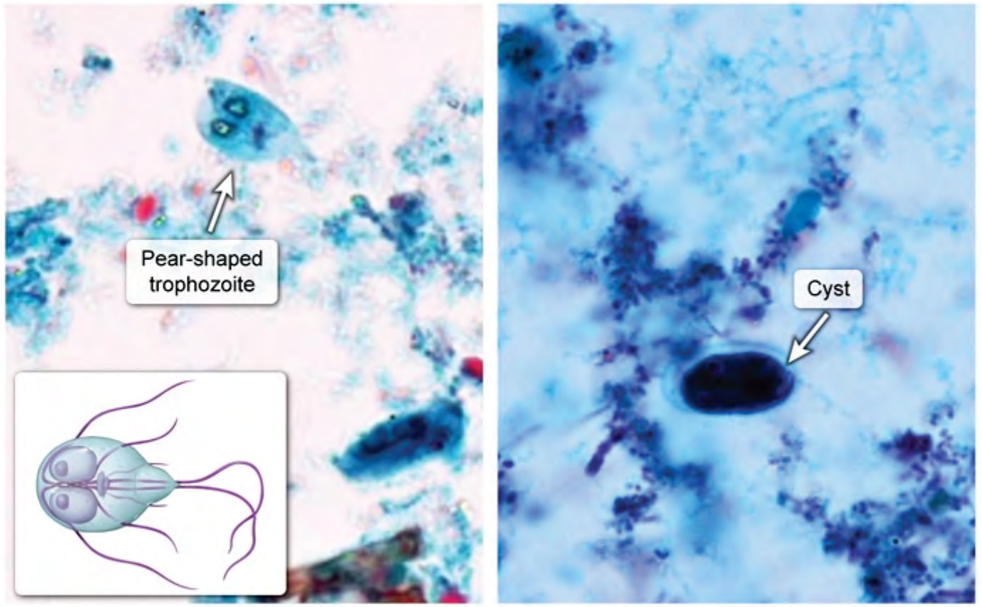

©UWorld

Zoom In | Zoom Out | Reset | New | Existing | My Notebook

https://t.me/USMLEWorldStep1

A 45-year-old man comes to the emergency department due to sudden-onset vomiting and severe upper abdominal pain that radiates to his back. The patient's total bilirubin is 0.9 mg/dL, aspartate aminotransferase (AST) is 98 U/L, alanine aminotransferase (ALT) is 32 U/L, and alkaline phosphatase is 98 U/L. Serum lipase is markedly increased. Abdominal ultrasound reveals a normal gallbladder and common bile duct. The diagnosis of acute pancreatitis is made, and a specific etiology is established. Which of the following additional laboratory findings is most specific for the underlying cause of this patient's pancreatitis?

- A. Mean corpuscular volume of 108 fL
- B. Serum calcium level of 8 mg/dL
- C. Serum glucose level of 180 mg/dL
- D. Serum sodium level of 150 mEq/L
- E. White blood cell count of 22,000/mm ^{3}

Submit

https://t.me/USMLEWorldStep1

A 45-year-old man comes to the emergency department due to sudden-onset vomiting and severe upper abdominal pain that radiates to his back. The patient's total bilirubin is 0.9 mg/dL, aspartate aminotransferase (AST) is 98 U/L, alanine aminotransferase (ALT) is 32 U/L, and alkaline phosphatase is 98 U/L. Serum lipase is markedly increased. Abdominal ultrasound reveals a normal gallbladder and common bile duct. The diagnosis of acute pancreatitis is made, and a specific etiology is established. Which of the following additional laboratory findings is most specific for the underlying cause of this patient's pancreatitis?

✓ A. Mean corpuscular volume of 108 fL (34%)
✗ B. Serum calcium level of 8 mg/dL (24%)
C. Serum glucose level of 180 mg/dL (16%)
D. Serum sodium level of 150 mEq/L (3%)
E. White blood cell count of 22,000/mm ^{3} (20%)

Incorrect
Correct answer
A

34%
Answered correctly

03 secs
Time Spent

2023
Version

Explanation

This patient's **acute pancreatitis** is likely related to **chronic alcohol use** given his **>2 AST:ALT ratio** and **absence of gallstones** on abdominal ultrasound. After gallstones, alcohol use is the second most common cause of acute pancreatitis. Ethanol induces pancreatic secretions with a high protein concentration and low fluid content. These viscous secretions are prone to precipitate and form plugs that can obstruct the lumina of the pancreatic ductules. Alcohol also causes spasms of the sphincter of Oddi and has a direct toxic effect on the acinar cells.

Alcohol-related acute pancreatitis is clinically **indistinguishable** from pancreatitis due to other causes. However, chronic alcohol use causes a number of systemic effects due to both the direct toxic actions of ethanol and alcohol-associated vitamin deficiencies. Even in the absence of anemia, **macrocytosis** (mean corpuscular volume >100

https://t.me/USMLEWorldStep1

This patient's **acute pancreatitis** is likely related to **chronic alcohol use** given his **>2 AST:ALT ratio** and **absence of gallstones** on abdominal ultrasound. After gallstones, alcohol use is the second most common cause of acute pancreatitis. Ethanol induces pancreatic secretions with a high protein concentration and low fluid content. These viscous secretions are prone to precipitate and form plugs that can obstruct the lumina of the pancreatic ductules. Alcohol also causes spasms of the sphincter of Oddi and has a direct toxic effect on the acinar cells.

Alcohol-related acute pancreatitis is clinically **indistinguishable** from pancreatitis due to other causes. However, chronic alcohol use causes a number of systemic effects due to both the direct toxic actions of ethanol and alcohol-associated vitamin deficiencies. Even in the absence of anemia, **macrocytosis** (mean corpuscular volume >100 fL) is often seen and is likely related to poor nutrition (eg, folate deficiency), liver disease, and/or direct toxicity of alcohol on the marrow.

(Choice B) In severe acute pancreatitis, necrosis can spread into the retroperitoneal fat, omentum, mesentery, and even beyond the abdominal cavity. Large amounts of calcium bind to the released free fatty acids, forming soaps that are deposited in the areas of necrosis, which may result in hypocalcemia. However, this is a nonspecific finding that can occur with pancreatitis of any etiology, not just alcohol-related pancreatitis.

(Choice C) Inflammation in acute pancreatitis may lead to dysfunction of the pancreatic islets with decreased secretion of insulin, resulting in hyperglycemia. This is a nonspecific finding that can occur with pancreatitis of any etiology, not just alcohol-related pancreatitis.

(Choice D) Hypernatremia may occur in the setting of severe acute pancreatitis due to large third-space fluid loss (ie, interstitial fluid accumulation) and decreased water intake, causing subsequent hypovolemia and renal sodium retention. This finding is also not specific for alcohol-related pancreatitis.

(Choice E) An increased white blood cell count is a nonspecific marker of inflammation and may occur with pancreatitis of any etiology.

Educational objective:
After gallstones, chronic alcohol use is the second most common cause of acute pancreatitis. Macrocytosis and an AST:ALT ratio >2 are indirect indicators of chronic alcohol consumption. Alcohol-related macrocytosis can occur independently of folate deficiency.

https://t.me/USMLEWorldStep1

A 10-year-old boy is brought to the emergency department due to difficulty swallowing. During dinner a few hours ago, a piece of chicken became stuck in the patient's mid-chest region. He has previously had the sensation of food becoming stuck, but it never lasted this long. The patient has vomited multiple times, but the chicken has not dislodged. Medical history is significant for eczema. He is drooling and visibly uncomfortable. Endoscopy is performed to remove the chicken from the esophagus and reveals multiple, vertically-stacked, ring-like indentations. Longitudinal crevices parallel to the length of the esophagus are also seen, along with scattered, small, whitish papules. Which of the following findings is most likely to be found on biopsy of this patient's esophagus?

- A. Eosinophilic infiltration of the esophageal mucosa
- B. Ganglionic degeneration within the myenteric plexus
- C. Intestinal metaplasia of the esophageal epithelium
- D. Replacement of the esophagus with fibrous tissue
- E. Squamous cells with eosinophilic intranuclear inclusions

Submit

https://t.me/USMLEWorldStep1

A 10-year-old boy is brought to the emergency department due to difficulty swallowing. During dinner a few hours ago, a piece of chicken became stuck in the patient's mid-chest region. He has previously had the sensation of food becoming stuck, but it never lasted this long. The patient has vomited multiple times, but the chicken has not dislodged. Medical history is significant for eczema. He is drooling and visibly uncomfortable. Endoscopy is performed to remove the chicken from the esophagus and reveals multiple, vertically-stacked, ring-like indentations. Longitudinal crevices parallel to the length of the esophagus are also seen, along with scattered, small, whitish papules. Which of the following findings is most likely to be found on biopsy of this patient's esophagus?

- ✓ A. Eosinophilic infiltration of the esophageal mucosa (68%)
- ✗ B. Ganglionic degeneration within the myenteric plexus (8%)
- C. Intestinal metaplasia of the esophageal epithelium (2%)
- D. Replacement of the esophagus with fibrous tissue (12%)
- E. Squamous cells with eosinophilic intranuclear inclusions (8%)

Incorrect
Correct answer
A

68%
Answered correctly

03 secs
Time Spent

2023
Version

Explanation

Eosinophilic esophagitis	
Pathogenesis	• Chronic Th2 cell–mediated disorder triggered by food antigens • Eosinophilic infiltration of the esophageal mucosa
Epidemiology	• Men > women • History of atopic conditions

https://t.me/USMLEWorldStep1

Explanation

Eosinophilic esophagitis	
Pathogenesis	• Chronic Th2 cell–mediated disorder triggered by food antigens • Eosinophilic infiltration of the esophageal mucosa
Epidemiology	• Men > women • History of atopic conditions
Clinical features	• Intermittent dysphagia • Reflux, vomiting, chest or abdominal pain • Esophageal food impaction
Th2 = T helper 2.	

This patient with a history of solid food dysphagia has an esophageal food impaction due to **eosinophilic esophagitis** (EOE). EOE is a chronic Th2 cell–mediated disorder triggered by food antigen exposure. When activated, Th2 cells release chemokines (eg, IL-13, IL-5) that stimulate eosinophilic recruitment to the esophageal mucosa.

EOE is most common in male individuals with a history of **atopic conditions** (eg, eczema, asthma). Patients often have intermittent **solid food dysphagia**. Other symptoms include vomiting, reflux, and chest and upper abdominal pain. When EOE is severe, food can become trapped in the esophagus (ie, **food impaction**), requiring endoscopy to remove the impacted food bolus.

Classic endoscopic findings include stacked, ring-like indentations with linear furrowing; and scattered, small, whitish papules (ie, **eosinophilic microabscesses**). Biopsies demonstrate eosinophilic mucosal infiltration.

(Choice B) Achalasia results from ganglionic degeneration within the esophageal myenteric plexus, leading to the inability to relax the lower esophageal sphincter. It typically causes dysphagia of both solids and liquids and is rare in children. There are no specific endoscopic findings; however, a barium swallow demonstrating a bird-beak appearance of the esophagus is characteristic.

https://t.me/USMLEWorldStep1

mucosa.

EOE is most common in male individuals with a history of **atopic conditions** (eg, eczema, asthma). Patients often have intermittent **solid food dysphagia**. Other symptoms include vomiting, reflux, and chest and upper abdominal pain. When EOE is severe, food can become trapped in the esophagus (ie, **food impaction**), requiring endoscopy to remove the impacted food bolus.

Classic endoscopic findings include stacked, ring-like indentations with linear furrowing; and scattered, small, whitish papules (ie, **eosinophilic microabscesses**). Biopsies demonstrate eosinophilic mucosal infiltration.

(Choice B) Achalasia results from ganglionic degeneration within the esophageal myenteric plexus, leading to the inability to relax the lower esophageal sphincter. It typically causes dysphagia of both solids and liquids and is rare in children. There are no specific endoscopic findings; however, a barium swallow demonstrating a bird-beak appearance of the esophagus is characteristic.

(Choice C) Barrett esophagus is a premalignant condition characterized by intestinal metaplasia of the esophageal epithelium. It typically develops in older patients with chronic gastroesophageal reflux but does not usually cause food impaction.

(Choice D) Systemic sclerosis results in esophageal smooth muscle fibrosis, leading to severe gastroesophageal reflux. It occurs more commonly in adult women and usually presents with thickened skin and Raynaud phenomenon. Endoscopy typically demonstrates a dilated esophagus.

(Choice E) Herpes simplex virus esophagitis is characterized histologically by eosinophilic intranuclear inclusions within esophageal squamous cells. It typically occurs in immunocompromised patients and results in severe odynophagia. Endoscopy demonstrates ulcerations with a volcano-like appearance.

Educational objective:
Eosinophilic esophagitis is a Th2 cell–mediated disorder leading to eosinophilic infiltration of the esophageal mucosa. It occurs most commonly in male individuals with a history of atopic conditions and typically presents with solid food dysphagia, reflux, and occasionally food impaction. Classic endoscopic findings include stacked, ring-like indentations; linear furrowing; and scattered, small, whitish papules (ie, eosinophilic microabscesses).

References

https://t.me/USMLEWorldStep1

This patient with a history of solid food dysphagia has an esophageal food impaction due to **eosinophilic**

esoph
activat
mucos

EOE is
have i
pain.
to rem

Classi
whitish

(Choi
inabilit
in chil
appea

(Choi
esoph
usuall

(Choi
reflux.
pheno

(Choi
within
odyno

Educa
Eosino
mucosa. It occurs most commonly in male individuals with a history of atopic conditions and typically presents with

Exhibit Display

Eosinophilic esophagitis

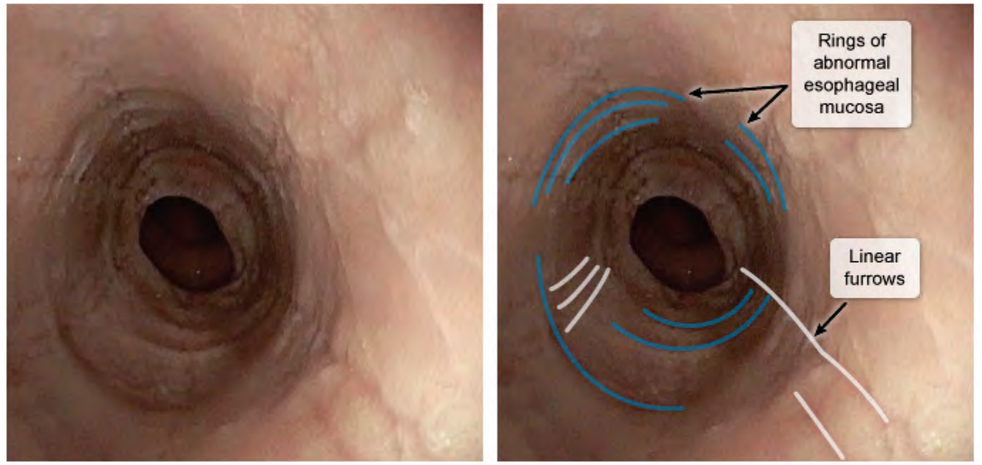

©UWorld

Zoom In | Zoom Out | Reset | New | Existing | My Notebook

https://t.me/USMLEWorldStep1

This patient with a history of solid food dysphagia has an esophageal food impaction due to **eosinophilic**

esoph
activat
mucos

EOE is
have i
pain.
to rem

Classi
whitish

(Choi
inabilit
in chil
appea

(Choi
esoph
usuall

(Choi
reflux.
pheno

(Choi
within
odyno

Educa
Eosino
mucosa. It occurs most commonly in male individuals with a history of atopic conditions and typically presents with

Exhibit Display

Eosinophilic esophagitis

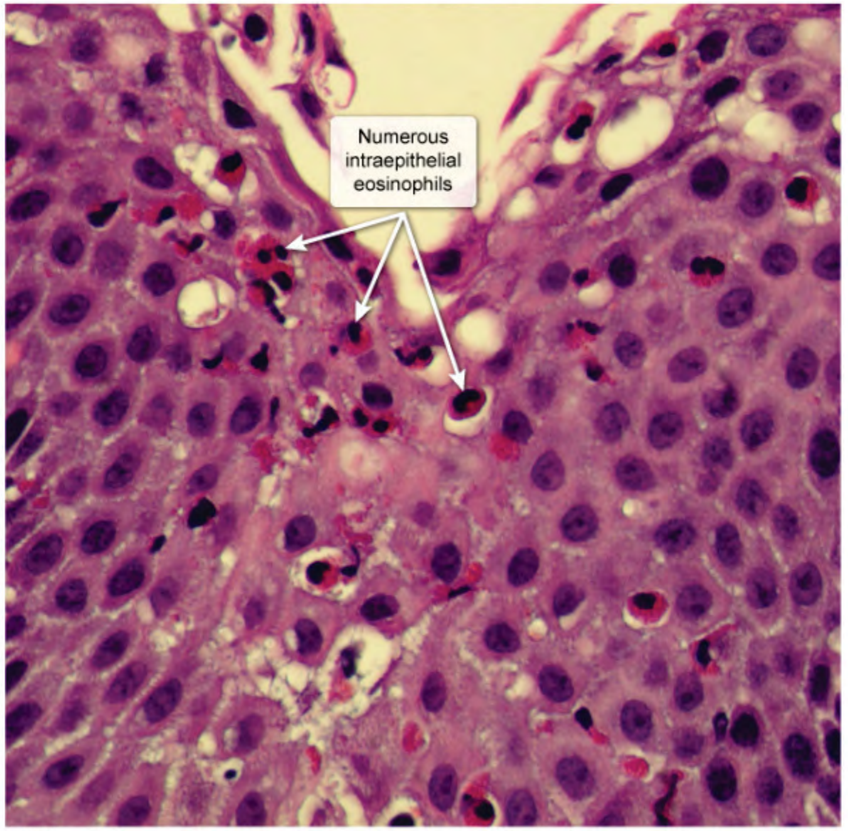

©UWorld

Zoom In | Zoom Out | Reset | New | Existing | My Notebook

https://t.me/USMLEWorldStep1

mucosa.

EOE is
have i
pain.
to rem

Classi
whitish

(Choi
inabilit
in chil
appea

(Choi
esoph
usuall

(Choi
reflux.
pheno

(Choi
within
odyno

Educa
Eosinc
mucos
solid f
like inc

References

Exhibit Display

Achalasia

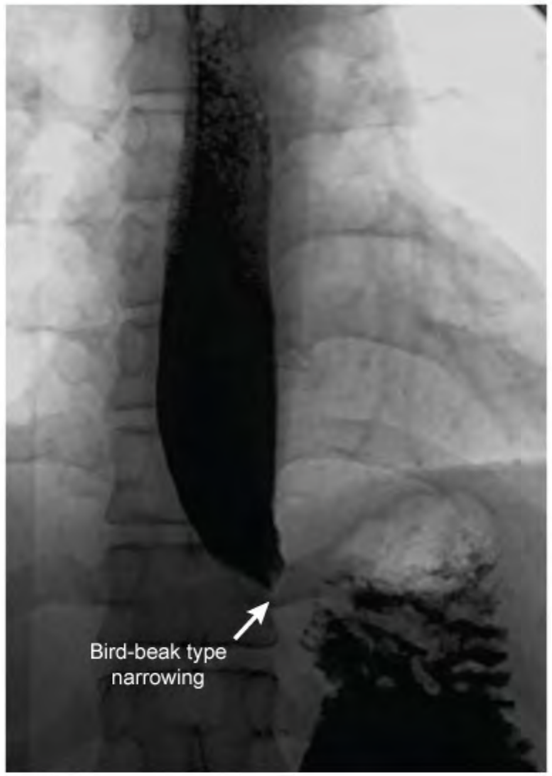

©UWorld

Zoom In Zoom Out Reset New | Existing My Notebook

https://t.me/USMLEWorldStep1

pain. When EOE is severe, food can become trapped in the esophagus (ie, **food impaction**), requiring endoscopy to remove the impacted food bolus.

Classi
whitish

(Choi
inabilit
in chil
appea

(Choi
esoph
usuall

(Choi
reflux.
pheno

(Choi
within
odyno

Educa
Eosinc
mucos
solid f
like inc

Refere
- Dia

Exhibit Display

Herpes simplex esophageal ulcers

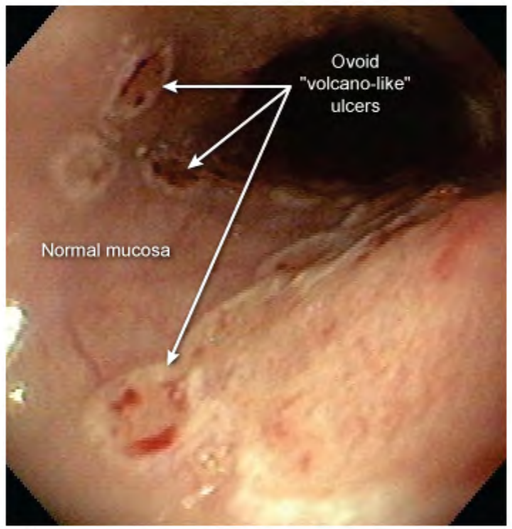

©UWorld

Zoom In | Zoom Out | Reset | New | Existing | My Notebook

Pathology (Subject) | Gastrointestinal & Nutrition (System) | Esophagitis (Topic)

https://t.me/USMLEWorldStep1

A 4-year-old girl is brought to the office after her parents noticed dark red blood on her toilet tissue after a bowel movement. She has had no abdominal pain, dysuria, or discomfort with defecation. The girl has no known medical conditions and takes no medications. Temperature is 36.7 C (98.1 F), blood pressure is 100/40 mm Hg, and pulse is 112/min. Examination shows a soft and nontender abdomen, and bowel sounds are present. Hemoglobin is 8 g/dL, and platelet count is 215,000/mm^3. Coagulation studies are normal. Sequential imaging using ^{99m}Tc-pertechnetate scintigraphy demonstrates focal radiotracer accumulation in the right lower quadrant. Which of the following embryologic processes most likely resulted in this patient's condition?

- A. Arrested hindgut descent along the inferior mesenteric artery
- B. Defective neural crest cell migration into the bowel wall
- C. Disrupted vascular flow to the ileum
- D. Failed obliteration of the vitelline duct
- E. Partial midgut rotation around the superior mesenteric artery

Submit

https://t.me/USMLEWorldStep1

A 4-year-old girl is brought to the office after her parents noticed dark red blood on her toilet tissue after a bowel movement. She has had no abdominal pain, dysuria, or discomfort with defecation. The girl has no known medical conditions and takes no medications. Temperature is 36.7 C (98.1 F), blood pressure is 100/40 mm Hg, and pulse is 112/min. Examination shows a soft and nontender abdomen, and bowel sounds are present. Hemoglobin is 8 g/dL, and platelet count is 215,000/mm^3. Coagulation studies are normal. Sequential imaging using ^{99m}Tc-pertechnetate scintigraphy demonstrates focal radiotracer accumulation in the right lower quadrant. Which of the following embryologic processes most likely resulted in this patient's condition?

- A. Arrested hindgut descent along the inferior mesenteric artery (5%)
- ✗ B. Defective neural crest cell migration into the bowel wall (6%)
- C. Disrupted vascular flow to the ileum (7%)
- ✓ D. Failed obliteration of the vitelline duct (70%)
- E. Partial midgut rotation around the superior mesenteric artery (10%)

Incorrect
Correct answer
D

70%
Answered correctly

03 secs
Time Spent

2023
Version

Explanation

Meckel diverticulum	
Pathogenesis	• Persistent vitelline (omphalomesenteric) duct • Often contains ectopic gastric mucosa → intestinal ulceration & bleeding
Epidemiology	Rule of 2s: • Presentation often by age 2 (but can occur at any age) • Usually <2 inches long

https://t.me/USMLEWorldStep1

Meckel diverticulum	
Pathogenesis	• Persistent vitelline (omphalomesenteric) duct • Often contains ectopic gastric mucosa → intestinal ulceration & bleeding
Epidemiology	Rule of 2s: • Presentation often by age 2 (but can occur at any age) • Usually <2 inches long • Location within 2 feet of ileocecal valve

Clinical presentation	• May be asymptomatic (incidental finding)
	• Painless rectal bleeding ± iron deficiency anemia
	• Acute abdominal pain due to complications:
	  ◦ Intussusception (recurrent, atypical)
	  ◦ Diverticulitis (mimics appendicitis)
	  ◦ Bowel obstruction, perforation (peritoneal signs)

Diagnosis	• Technetium-99m pertechnetate (Meckel) scan detects gastric mucosa

This patient with painless rectal bleeding has imaging findings consistent with a **Meckel diverticulum**, a congenital intestinal abnormality that results from failed obliteration of the **vitelline (omphalomesenteric) duct**. The vitelline duct is an embryologic remnant that connects the yolk sac to the primitive midgut, and duct closure normally occurs in early gestation. Incomplete closure results in an ileal outpouching with a fibrous connection to the umbilicus.

Meckel diverticulum often contains heterotopic **gastric mucosa**. Secretion of hydrochloric acid by gastric parietal cells causes ulceration and bleeding of local small bowel, resulting in typical findings of **painless lower gastrointestinal (GI) bleeding** and **anemia**, as seen in this patient. Less commonly, Meckel diverticulum can present with acute abdominal pain; for example, it can serve as a lead point for intussusception, causing colicky pain and currant jelly stools. Although presentation of Meckel diverticulum is most common at age <2, it can occur at any age.

https://t.me/USMLEWorldStep1

Diagnosis	• Technetium-99m pertechnetate (Meckel) scan detects gastric mucosa

This patient with painless rectal bleeding has imaging findings consistent with a **Meckel diverticulum**, a congenital intestinal abnormality that results from failed obliteration of the **vitelline (omphalomesenteric) duct**. The vitelline duct is an embryologic remnant that connects the yolk sac to the primitive midgut, and duct closure normally occurs in early gestation. Incomplete closure results in an ileal outpouching with a fibrous connection to the umbilicus.

Meckel diverticulum often contains heterotopic **gastric mucosa**. Secretion of hydrochloric acid by gastric parietal cells causes ulceration and bleeding of local small bowel, resulting in typical findings of **painless lower gastrointestinal (GI) bleeding** and **anemia**, as seen in this patient. Less commonly, Meckel diverticulum can present with acute abdominal pain; for example, it can serve as a lead point for intussusception, causing colicky pain and currant jelly stools. Although presentation of Meckel diverticulum is most common at age <2, it can occur at any age.

Diagnosis is made with ^{99m}Tc-pertechnetate scan (ie, Meckel scan). The radioisotope ^{99m}Tc-pertechnetate has an affinity for **parietal cells** of gastric mucosa, and increased uptake of the tracer in the periumbilical/right lower quadrant area is characteristic.

(Choice A) The hindgut, supplied by the inferior mesenteric artery, gives rise to the distal colon, rectum, and upper part of the anal canal. Arrest of hindgut descent in utero leads to an imperforate anus, which presents in neonates with failure to pass stool, not painless rectal bleeding.

(Choices B and C) Failure of craniocaudal neural crest cell migration results in an aganglionic sigmoid colon/rectum that is narrow and inactive (ie, Hirschsprung disease), and disrupted vascular flow to the ileum results in ileal atresia. Both conditions typically manifest with signs of obstruction (eg, abdominal distension, bilious emesis, failure to pass meconium) in a neonate, not painless GI bleeding in a 4-year-old.

(Choice E) Abnormal midgut rotation around the superior mesenteric artery describes intestinal malrotation. Patients may have hematochezia because the narrow mesenteric base seen in malrotation permits the small bowel to twist with subsequent ischemia (ie, volvulus). However, abdominal pain, vomiting, and signs of peritonitis are also typically present. Moreover, ^{99m}Tc-pertechnetate scintigraphy would not show abnormal uptake.

Educational objective:

https://t.me/USMLEWorldStep1

cells causes ulceration and bleeding of local small bowel, resulting in typical findings of **painless lower gastrointestinal (GI) bleeding** and **anemia**, as seen in this patient. Less commonly, Meckel diverticulum can present with acute abdominal pain; for example, it can serve as a lead point for intussusception, causing colicky pain and currant jelly stools. Although presentation of Meckel diverticulum is most common at age <2, it can occur at any age.

Diagnosis is made with ^{99m}Tc-pertechnetate scan (ie, Meckel scan). The radioisotope ^{99m}Tc-pertechnetate has an affinity for **parietal cells** of gastric mucosa, and increased uptake of the tracer in the periumbilical/right lower quadrant area is characteristic.

(Choice A) The hindgut, supplied by the inferior mesenteric artery, gives rise to the distal colon, rectum, and upper part of the anal canal. Arrest of hindgut descent in utero leads to an imperforate anus, which presents in neonates with failure to pass stool, not painless rectal bleeding.

(Choices B and C) Failure of craniocaudal neural crest cell migration results in an aganglionic sigmoid colon/rectum that is narrow and inactive (ie, Hirschsprung disease), and disrupted vascular flow to the ileum results in ileal atresia. Both conditions typically manifest with signs of obstruction (eg, abdominal distension, bilious emesis, failure to pass meconium) in a neonate, not painless GI bleeding in a 4-year-old.

(Choice E) Abnormal midgut rotation around the superior mesenteric artery describes intestinal malrotation. Patients may have hematochezia because the narrow mesenteric base seen in malrotation permits the small bowel to twist with subsequent ischemia (ie, volvulus). However, abdominal pain, vomiting, and signs of peritonitis are also typically present. Moreover, ^{99m}Tc-pertechnetate scintigraphy would not show abnormal uptake.

Educational objective:
Meckel diverticulum results from incomplete obliteration of the vitelline duct and usually presents with painless lower gastrointestinal bleeding. ^{99m}Tc-pertechnetate localizes to heterotopic gastric mucosa that is often contained within a Meckel diverticulum, and uptake in the periumbilical area or right lower quadrant is diagnostic.

Embryology	Gastrointestinal & Nutrition	Meckel diverticulum
Subject	System	Topic

Copyright © UWorld. All rights reserved.

https://t.me/USMLEWorldStep1

- Diverticulitis (mimics appendicitis)
- Bowel obstruction, perforation (peritoneal signs)

Exhibit Display

This p
intesti
duct is
occurs
umbili

Mecke
cells c
gastr
preser
pain a
at any

Diagn
affinity
quadra

(Choi
part of
with fa

(Choi
colon/
in ileal
emesis

(Choi

Patients may have hematochezia because the narrow mesenteric base seen in malrotation permits the small bowel

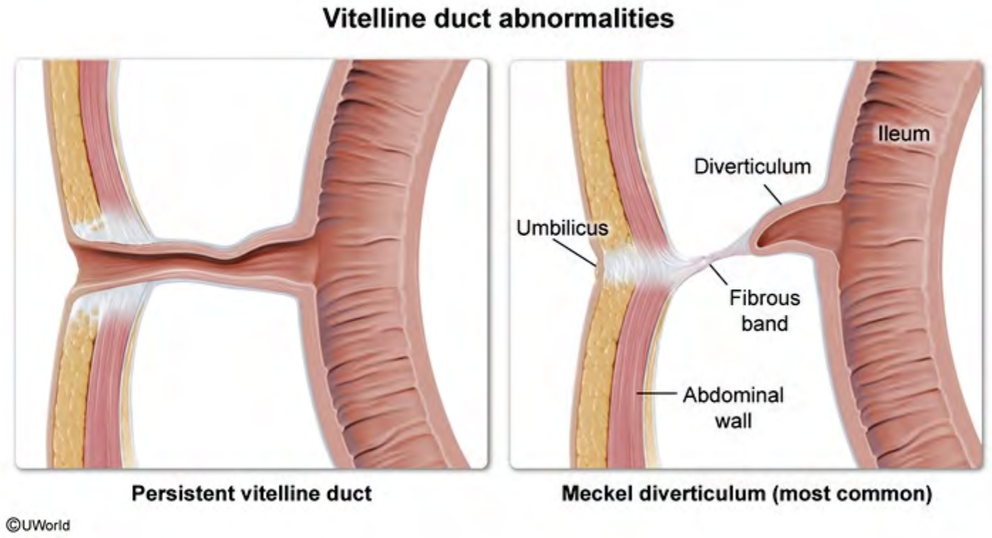

Zoom In | Zoom Out | Reset | New | Existing | My Notebook

https://t.me/USMLEWorldStep1

This patient with painless rectal bleeding has imaging findings consistent with a **Meckel diverticulum**, a congenital

intesti
duct is
occurs
umbili

Mecke
cells c
gastr
preser
pain a
at any

Diagn
affinity
quadra

(Choi
part of
with fa

(Choi
colon/
in ileal
emesi

(Choi
Patien
to twis
also ty

Educational objective:

Exhibit Display

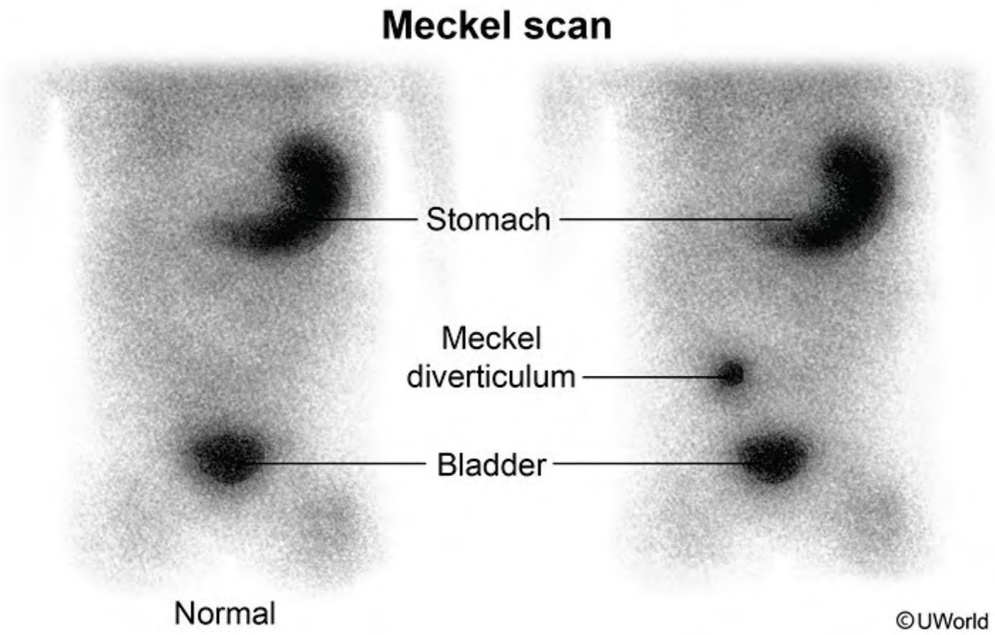

Zoom In | Zoom Out | Reset | New | Existing | My Notebook

https://t.me/USMLEWorldStep1

occurs in early gestation. Incomplete closure results in an ileal outpouching with a fibrous connection to the umbilicus.

Mecke
cells c
gastro
preser
pain a
at any

Diagn
affinity
quadra

(Choi
part of
with fa

(Choi
colon/
in ileal
emesis

(Choi
Patien
to twis
also ty

Educa
Mecke
lower

within a Meckel diverticulum, and uptake in the periumbilical area or right lower quadrant is diagnostic.

Exhibit Display

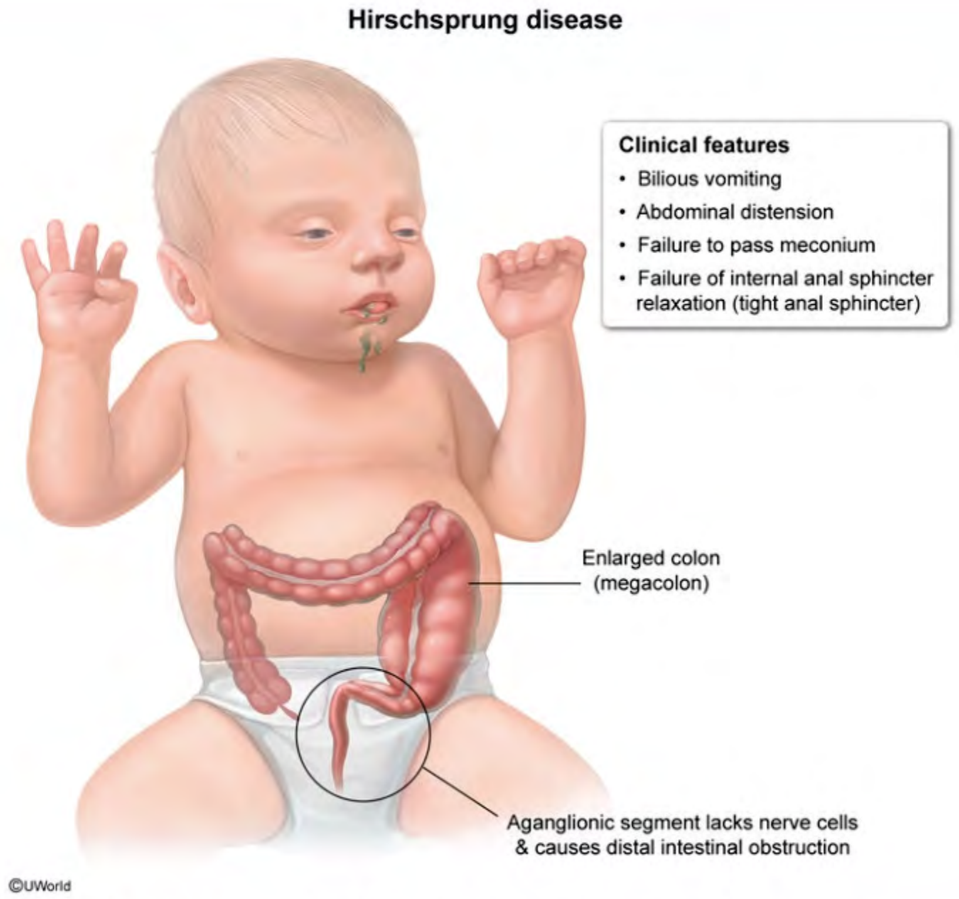

Zoom In | Zoom Out | Reset | New | Existing | My Notebook

https://t.me/USMLEWorldStep1

cells causes ulceration and bleeding of local small bowel, resulting in typical findings of **painless lower**

gastro
preser
pain a
at any

Diagn
affinity
quadra

(Choi
part of
with fa

(Choi
colon/
in ileal
emesis

(Choi
Patien
to twis
also ty

Educa
Mecke
lower
within

Exhibit Display

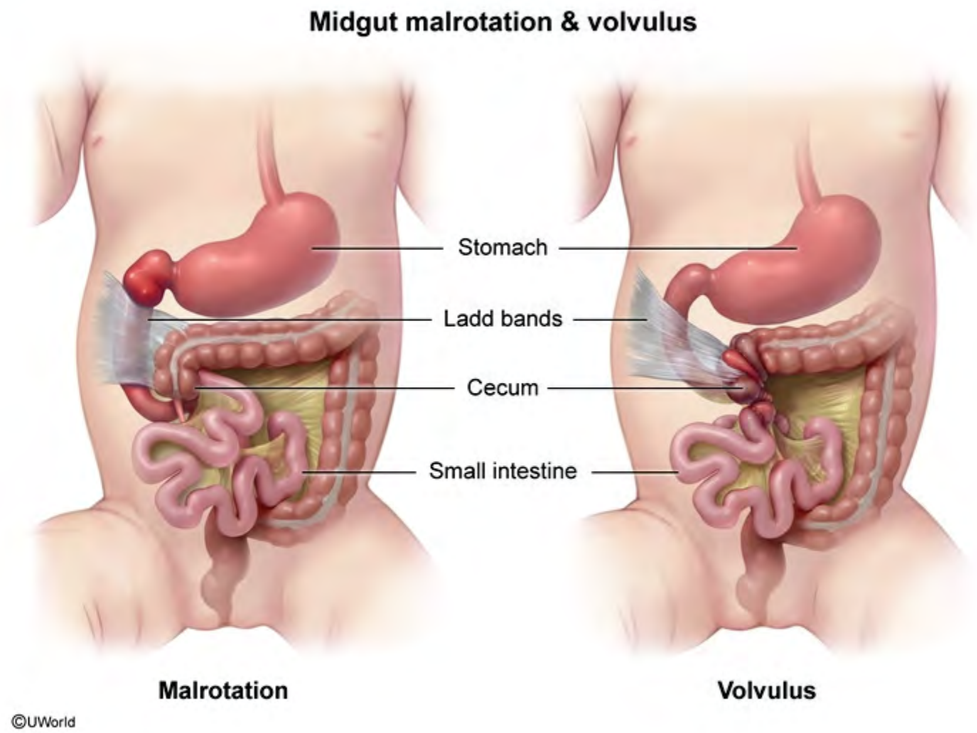

Zoom In | Zoom Out | Reset | New | Existing | My Notebook

Embryology
Subject

Gastrointestinal & Nutrition
System

Meckel diverticulum
Topic

Copyright © UWorld. All rights reserved.

https://t.me/USMLEWorldStep1

A 47-year-old man comes to the office due to dysphagia. The patient says that it feels like food has been getting stuck in his throat over the last month. He has changed his diet to accommodate his symptoms and now consumes only liquid foods. The patient has a long history of postprandial heartburn that sometimes awakens him from sleep. He has treated his heartburn with over-the-counter antacids but usually only has partial relief. A thoracic CT image near the level of the aortic arch is shown below. This patient's symptoms are most likely related to pathology involving which of the following structures?

- A. A
- B. B
- C. C
- D. D
- E. E

Submit

https://t.me/USMLEWorldStep1

A 47-year-old man comes to the office due to dysphagia. The patient says that it feels like food has been getting stuck i
consu
from s
thorac
to path

Exhibit Display

Zoom In Zoom Out Reset New | Existing My Notebook

Submit

https://t.me/USMLEWorldStep1

A 47-year-old man comes to the office due to dysphagia. The patient says that it feels like food has been getting stuck in his throat over the last month. He has changed his diet to accommodate his symptoms and now consumes only liquid foods. The patient has a long history of postprandial heartburn that sometimes awakens him from sleep. He has treated his heartburn with over-the-counter antacids but usually only has partial relief. A thoracic CT image near the level of the aortic arch is shown below. This patient's symptoms are most likely related to pathology involving which of the following structures?

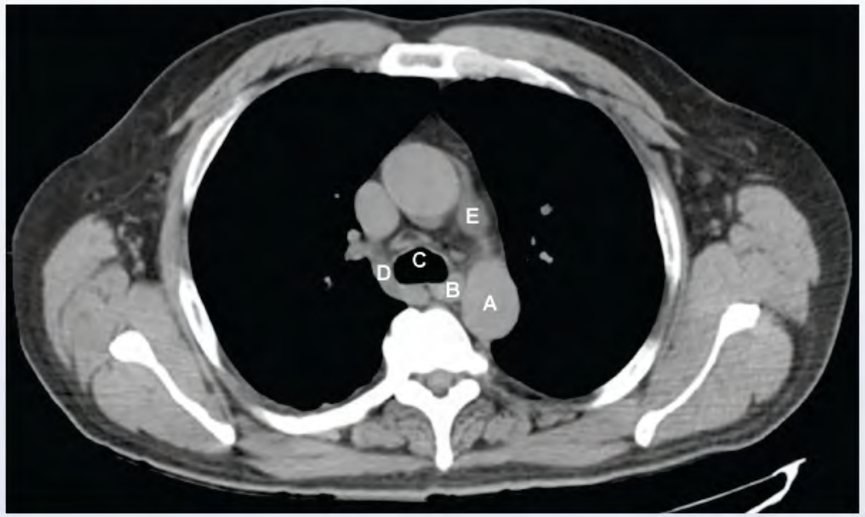

- A. A (3%)
- ✓ B. B (56%)
- C. C (26%)
- D. D (8%)
- E. E (4%)

Correct

56% Answered correctly

08 secs Time Spent

2023 Version

https://t.me/USMLEWorldStep1

Correct

56%
Answered correctly

08 secs
Time Spent

2023
Version

Exhibit Display

Chest CT

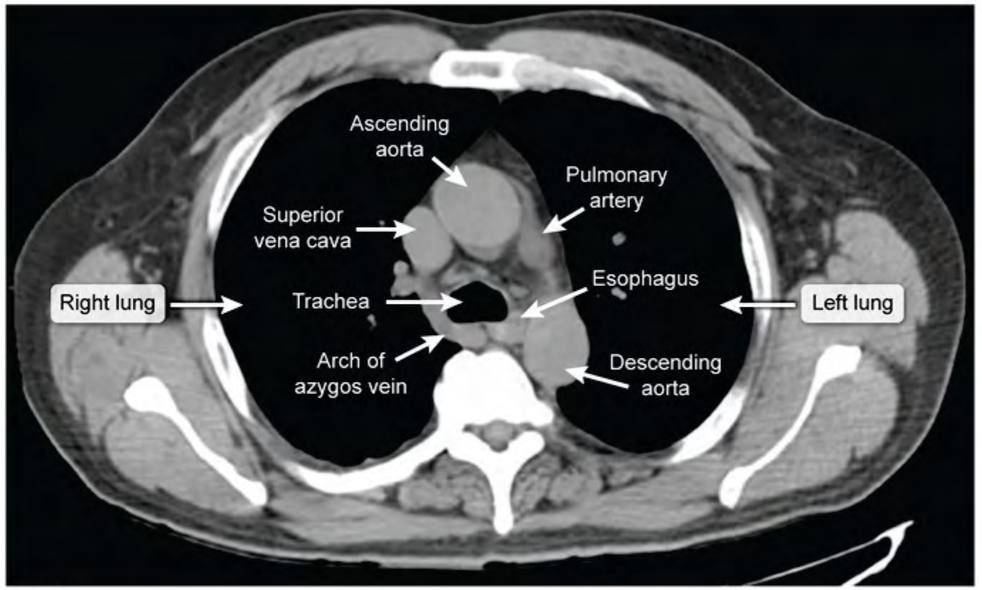

©UWorld

Zoom In | Zoom Out | Reset | New | Existing | My Notebook

Expl

This p
conditi
GERD

In the
no vis
allows one to differentiate it from the esophagus posteriorly and the great vessels anteriorly **(Choice C)**.

https://t.me/USMLEWorldStep1

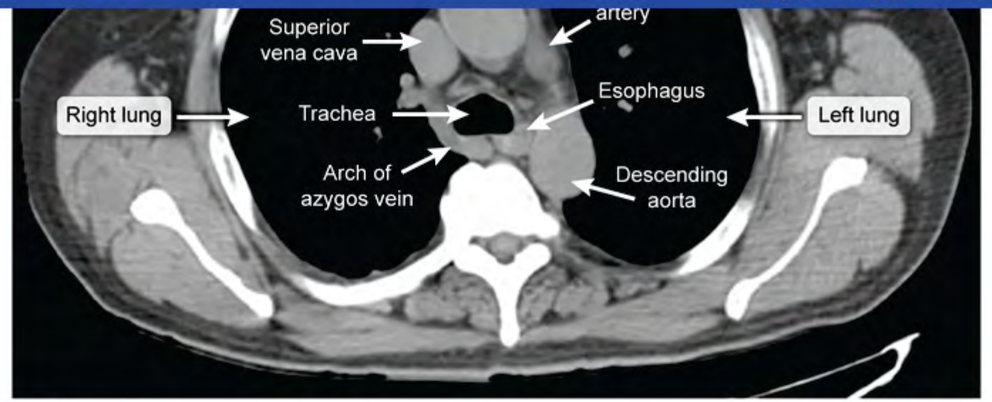

This patient's prolonged history of heartburn is suggestive of **gastroesophageal reflux disease** (GERD), a condition that affects the esophagus. **Dysphagia** (ie, difficulty swallowing) is common in patients with longstanding GERD and can be caused by impaired peristalsis, esophageal inflammation/stricture, or malignancy.

In the thorax, the **esophagus** courses between the **trachea and vertebral bodies** and is typically collapsed with **no visible lumen**. The trachea serves as a good landmark because the radiolucency of the air in this structure allows one to differentiate it from the esophagus posteriorly and the great vessels anteriorly **(Choice C)**.

(Choice A) This is the descending aorta.

(Choice D) This is the arch of the azygos vein as it curves over the right main bronchus to join with the superior vena cava. The azygos vein itself ascends along the thoracic vertebral column to the right of the esophagus.

(Choice E) This is a section of the top of the pulmonary artery as it passes underneath the aortic arch.

Educational objective:
The esophagus is located between the trachea and the vertebral bodies in the superior thorax. It is typically collapsed with no visible lumen on CT images of the chest.

Anatomy	Gastrointestinal & Nutrition	Gastroesophageal reflux disease
Subject	System	Topic

Copyright © UWorld. All rights reserved.

https://t.me/USMLEWorldStep1

A 54-year-old man comes to the office with abdominal pain, chronic diarrhea, and recent weight loss. He has had episodic abdominal pain in the past, but lately it has become persistent and worsens after eating. The patient does not use tobacco or illicit drugs but does consume alcohol regularly. An upright abdominal x-ray reveals calcifications in the epigastric area. Which of the following is the most likely cause of his diarrhea?

- A. Bile salt malabsorption
- B. Digestive enzyme deficiency
- C. Elevated portal venous pressure
- D. Excessive gastrin production
- E. Immune-mediated enteropathy
- F. Nutrient absorption interference by alcohol

Submit

https://t.me/USMLEWorldStep1

A 54-year-old man comes to the office with abdominal pain, chronic diarrhea, and recent weight loss. He has had episodic abdominal pain in the past, but lately it has become persistent and worsens after eating. The patient does not use tobacco or illicit drugs but does consume alcohol regularly. An upright abdominal x-ray reveals calcifications in the epigastric area. Which of the following is the most likely cause of his diarrhea?

- A. Bile salt malabsorption (11%)
- ✓ B. Digestive enzyme deficiency (70%)
- C. Elevated portal venous pressure (1%)
- D. Excessive gastrin production (8%)
- E. Immune-mediated enteropathy (2%)
- F. Nutrient absorption interference by alcohol (4%)

Correct | 70% Answered correctly | 04 secs Time Spent | 2023 Version

Explanation

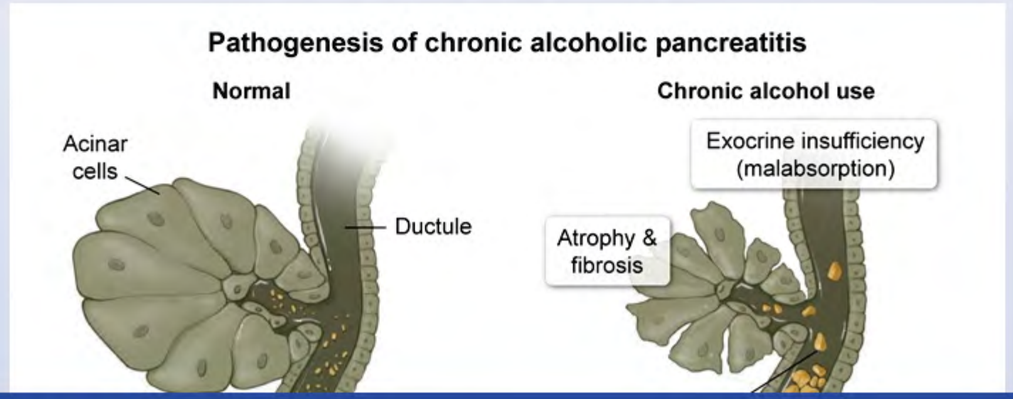

https://t.me/USMLEWorldStep1

E. Immune-mediated enteropathy (2%)

Exhibit Display

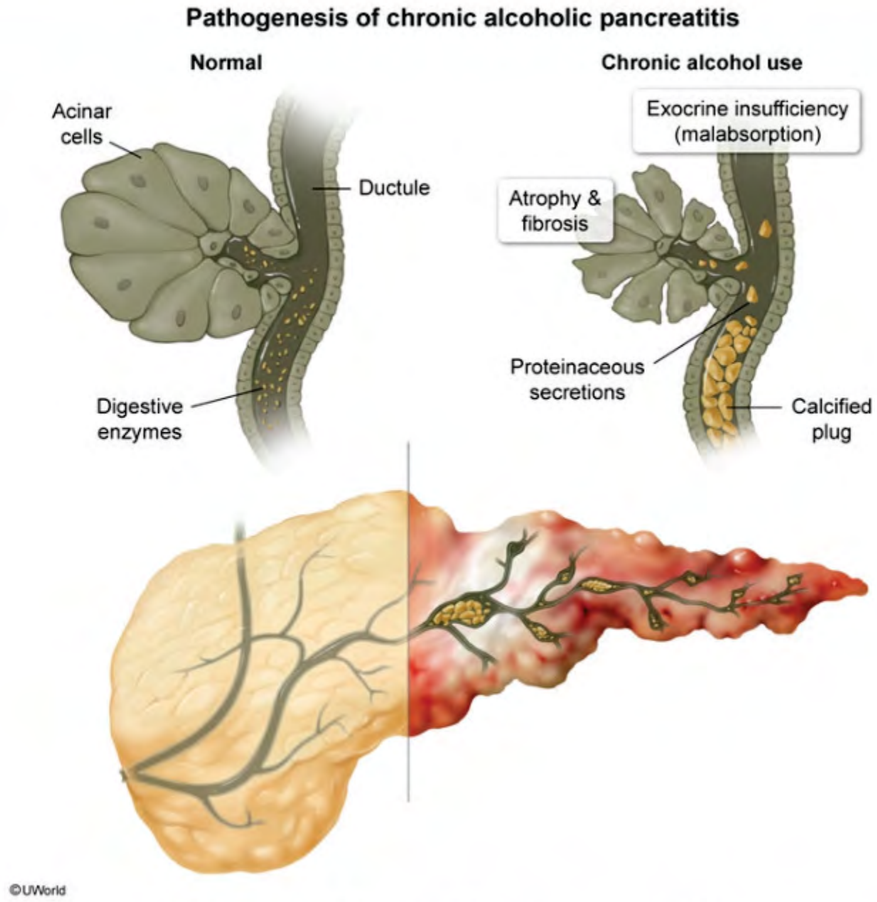

Zoom In | Zoom Out | Reset | New | Existing | My Notebook

https://t.me/USMLEWorldStep1

This patient's epigastric calcifications and history of alcohol use make **chronic pancreatitis** the most likely diagnosis. It is thought that **alcohol-related** chronic pancreatitis develops in part due to alcohol-induced secretion of protein-rich fluid. These proteinaceous secretions can precipitate within the pancreatic ducts, forming **ductal plugs** that may **calcify** and be detectable on abdominal imaging.

Ductal obstruction by such concretions may cause **exocrine insufficiency** due to atrophy of the pancreatic acinar cells and pancreatic fibrosis. Pancreatic exocrine insufficiency (eg, failure to secrete adequate amylases, proteases, and lipases) leads to **malabsorption** with consequent **diarrhea/steatorrhea**. **Weight loss** and bulky, frothy stools are typical clinical findings. This patient's abdominal pain is most likely due to the pancreatitis itself.

(Choice A) Bile salt malabsorption typically occurs with conditions affecting the terminal ileum (eg, ileal resection, Crohn ileitis). Patients may have diarrhea as a result of excessive bile salt accumulation in the colon (cholerheic enteropathy).

(Choice C) Portal hypertension (eg, due to liver cirrhosis) causes varices at sites of portocaval anastomoses, leading to anorectal varices, caput medusae over the abdomen, and esophageal varices. Bleeding esophageal varices can cause hematemesis and melena. Ascites is another sign of portal hypertension.

(Choice D) Gastrinomas (duodenal/pancreatic gastrin-secreting neuroendocrine tumors) cause hydrochloric acid hypersecretion, which can result in multiple and/or refractory peptic ulcers. Patients may also have diarrhea/malabsorption as digestive enzymes become deactivated by high gastric acid output.

(Choice E) Celiac disease classically presents with malabsorption due to immune-mediated enteropathy involving the proximal small intestine. This condition is triggered by the ingestion of foods containing gluten (eg, wheat).

(Choice F) Chronic alcohol use may result in the interference of nutrient/vitamin absorption due to intestinal mucosal injury. However, this patient's abdominal pain and epigastric calcifications suggest that his diarrhea is most likely a consequence of chronic pancreatitis.

Educational objective:
Diarrhea, weight loss, and epigastric calcifications in a patient with chronic alcohol use suggest chronic pancreatitis with resulting pancreatic exocrine insufficiency and malabsorption.

References

https://t.me/USMLEWorldStep1

Exhibit Display

This p
diagnc
of prot
plugs

Ductal
cells a
protea
frothy

(Choi
Crohn
entero

(Choi
leadin
varice

(Choi
hypers
diarrhe

(Choi
the pr

(Choi
mucos
most li

Educational objective:

Chronic pancreatitis

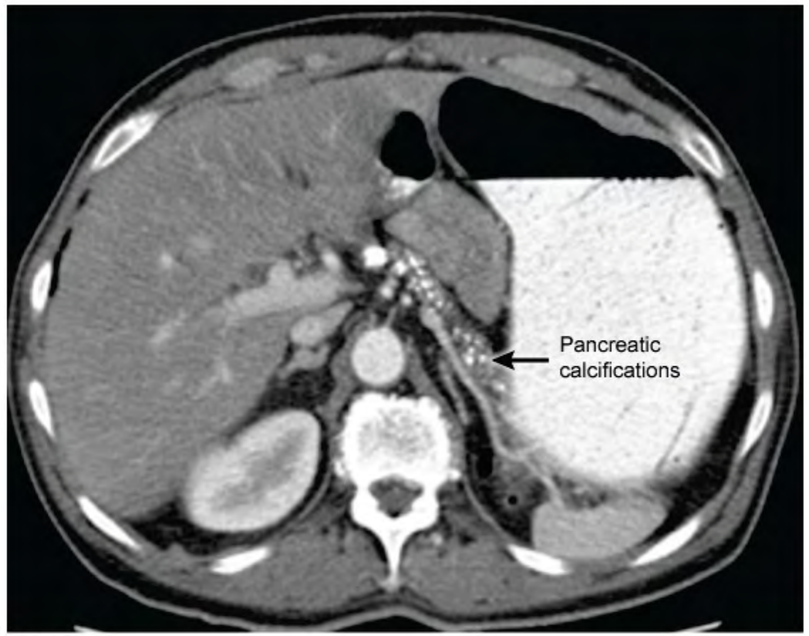

©UWorld

Zoom In | Zoom Out | Reset | New | Existing | My Notebook

https://t.me/USMLEWorldStep1

This patient's epigastric calcifications and history of alcohol use make **chronic pancreatitis** the most likely diagnosis. It is thought that **alcohol-related** chronic pancreatitis develops in part due to alcohol-induced secretion of protein-rich fluid. These proteinaceous secretions can precipitate within the pancreatic ducts, forming **ductal plugs** that may **calcify** and be detectable on abdominal imaging.

Ductal obstruction by such concretions may cause **exocrine insufficiency** due to atrophy of the pancreatic acinar cells and pancreatic fibrosis. Pancreatic exocrine insufficiency (eg, failure to secrete adequate amylases, proteases, and lipases) leads to **malabsorption** with consequent **diarrhea/steatorrhea**. **Weight loss** and bulky, frothy stools are typical clinical findings. This patient's abdominal pain is most likely due to the pancreatitis itself.

(Choice A) Bile salt malabsorption typically occurs with conditions affecting the terminal ileum (eg, ileal resection, Crohn ileitis). Patients may have diarrhea as a result of excessive bile salt accumulation in the colon (cholerheic enteropathy).

(Choice C) Portal hypertension (eg, due to liver cirrhosis) causes varices at sites of portocaval anastomoses, leading to anorectal varices, caput medusae over the abdomen, and esophageal varices. Bleeding esophageal varices can cause hematemesis and melena. Ascites is another sign of portal hypertension.

(Choice D) Gastrinomas (duodenal/pancreatic gastrin-secreting neuroendocrine tumors) cause hydrochloric acid hypersecretion, which can result in multiple and/or refractory peptic ulcers. Patients may also have diarrhea/malabsorption as digestive enzymes become deactivated by high gastric acid output.

(Choice E) Celiac disease classically presents with malabsorption due to immune-mediated enteropathy involving the proximal small intestine. This condition is triggered by the ingestion of foods containing gluten (eg, wheat).

(Choice F) Chronic alcohol use may result in the interference of nutrient/vitamin absorption due to intestinal mucosal injury. However, this patient's abdominal pain and epigastric calcifications suggest that his diarrhea is most likely a consequence of chronic pancreatitis.

Educational objective:
Diarrhea, weight loss, and epigastric calcifications in a patient with chronic alcohol use suggest chronic pancreatitis with resulting pancreatic exocrine insufficiency and malabsorption.

References

https://t.me/USMLEWorldStep1

A 38-year-old woman comes to the office due to intermittent abdominal pain and bloating since childhood. The patient does not drink milk because she does not like the taste and adds, "I eat ice cream, cheese, and yogurt, but they upset my stomach sometimes." There is no associated weight loss, abnormal bleeding, or joint pain. Past medical history is otherwise unremarkable, though the patient has not seen a physician for many years. Vital signs and physical examination are normal. Laboratory studies show normal hemoglobin, iron, and vitamin D levels. A biopsy sample of this patient's small bowel mucosa would most likely show which of the following?

- A. Atrophy of the intestinal villi
- B. Collections of neutrophils within crypt lumina
- C. Distended macrophages in lamina propria
- D. Infiltration of lamina propria with atypical lymphocytes
- E. Inflammation with scattered noncaseating granulomas
- F. Normal intestinal mucosa

Submit

https://t.me/USMLEWorldStep1

A 38-year-old woman comes to the office due to intermittent abdominal pain and bloating since childhood. The patient does not drink milk because she does not like the taste and adds, "I eat ice cream, cheese, and yogurt, but they upset my stomach sometimes." There is no associated weight loss, abnormal bleeding, or joint pain. Past medical history is otherwise unremarkable, though the patient has not seen a physician for many years. Vital signs and physical examination are normal. Laboratory studies show normal hemoglobin, iron, and vitamin D levels. A biopsy sample of this patient's small bowel mucosa would most likely show which of the following?

- ✗ A. Atrophy of the intestinal villi (7%)
- B. Collections of neutrophils within crypt lumina (1%)
- C. Distended macrophages in lamina propria (0%)
- D. Infiltration of lamina propria with atypical lymphocytes (1%)
- E. Inflammation with scattered noncaseating granulomas (0%)
- ✓ F. Normal intestinal mucosa (87%)

Incorrect
Correct answer
F

87%
Answered correctly

23 secs
Time Spent

2023
Version

Explanation

This patient, with gastrointestinal distress caused by consumption of lactose-containing dairy products, has typical features of **lactase deficiency**. Lactase deficiency results in incomplete hydrolysis of the disaccharide lactose into glucose and galactose. Undigested lactose in the bowel attracts excess water into the bowel lumen, leading to **osmotic diarrhea**. However, light and electron microscopic examinations show **normal bowel mucosa** in patients with primary lactase deficiency.

Primary lactase deficiency can be classified as congenital or acquired. The congenital variant is a rare autosomal recessive condition that presents with diarrhea after birth. The acquired variant is more common and typically

https://t.me/USMLEWorldStep1

This patient, with gastrointestinal distress caused by consumption of lactose-containing dairy products, has typical features of **lactase deficiency**. Lactase deficiency results in incomplete hydrolysis of the disaccharide lactose into glucose and galactose. Undigested lactose in the bowel attracts excess water into the bowel lumen, leading to **osmotic diarrhea**. However, light and electron microscopic examinations show **normal bowel mucosa** in patients with primary lactase deficiency.

Primary lactase deficiency can be classified as congenital or acquired. The congenital variant is a rare autosomal recessive condition that presents with diarrhea after birth. The acquired variant is more common and typically arises from decreased production of lactase by **mid childhood** (lactase nonpersistence).

(Choices A and E) Secondary lactase deficiency is seen in disorders that cause injury to the gastrointestinal mucosa. Celiac disease is characterized by atrophy of the intestinal villi and is due to exposure to gluten-containing wheat products. Crohn disease causes noncaseating granulomas, and usually presents with abdominal pain and a variety of other gastrointestinal symptoms. Lactase deficiency due to these conditions is usually seen in association with other features of malabsorption (eg, iron deficiency, vitamin D deficiency).

(Choice B) Diffuse inflammatory infiltrates with neutrophilic microabscesses in the crypt lumina can be seen in patients with ulcerative colitis, which usually presents with intermittent bloody diarrhea and abdominal pain.

(Choice C) Distended macrophages in the intestinal lamina propria are a typical finding in Whipple disease, which characteristically presents with malabsorptive diarrhea, weight loss, and joint pain.

(Choice D) Infiltration of the lamina propria with atypical lymphocytes would be expected in patients with gastrointestinal MALT (mucosa-associated lymphoid tissue) lymphomas. These often occur in the setting of chronic immune stimulation (eg, gastric MALT lymphoma with chronic *Helicobacter pylori* infection).

Educational objective:
The small bowel mucosa of patients with primary lactase deficiency is normal on histologic examination.

Pathophysiology	Gastrointestinal & Nutrition	Lactose intolerance
Subject	System	Topic

https://t.me/USMLEWorldStep1

This p
featur
glucos
osmo
with p

Primar
recess
arises

(Choi
mucos
contai
pain a
in ass

(Choi
patien

(Choi
charac

(Choi
gastro
chroni

Educa
The sr

Pathoph
Subject System Topic

Exhibit Display

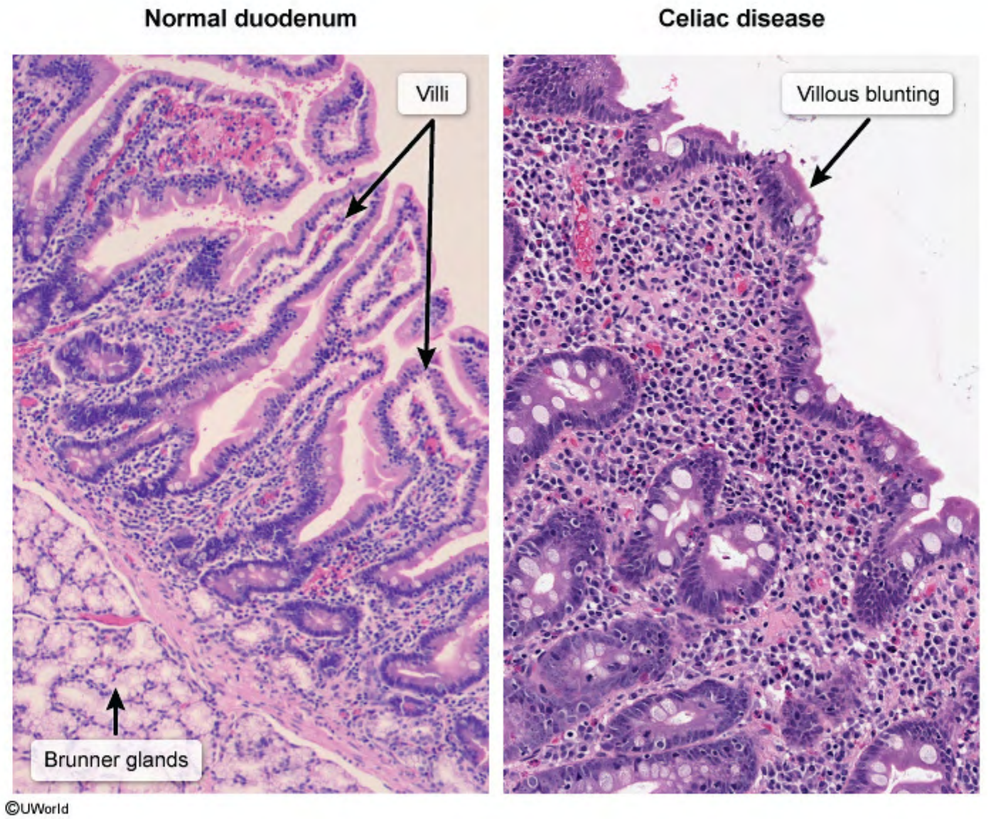

Zoom In Zoom Out Reset New | Existing My Notebook

https://t.me/USMLEWorldStep1

This p
featur
glucos
osmo
with p

Primar
recess
arises

(Choi
mucos
contai
pain a
in ass

(Choi
patien

(Choi
charac

(Choi
gastro
chroni

Educa
The sr

Pathoph
Subject System Topic

Exhibit Display

Crohn disease

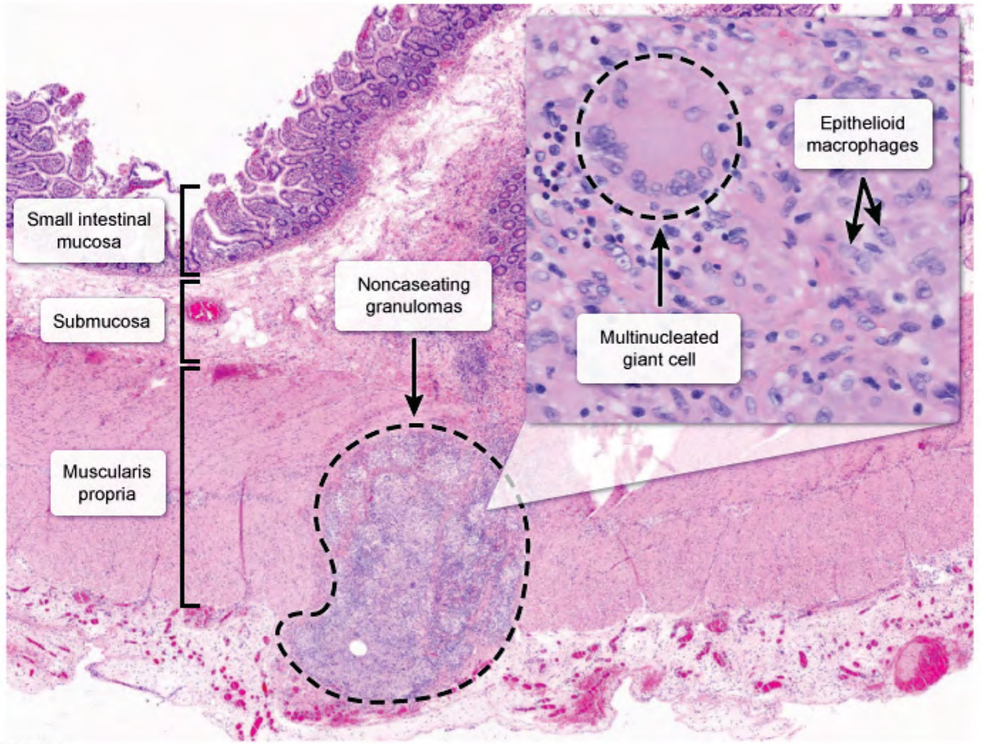

©UWorld

Zoom In Zoom Out Reset New | Existing My Notebook

https://t.me/USMLEWorldStep1

This p
featur
glucos
osmo
with p

Primar
recess
arises

(Choi
mucos
contai
pain a
in ass

(Choi
patien

(Choi
charac

(Choi
gastro
chroni

Educa
The sr

Pathoph
Subject System Topic

Exhibit Display

Ulcerative colitis

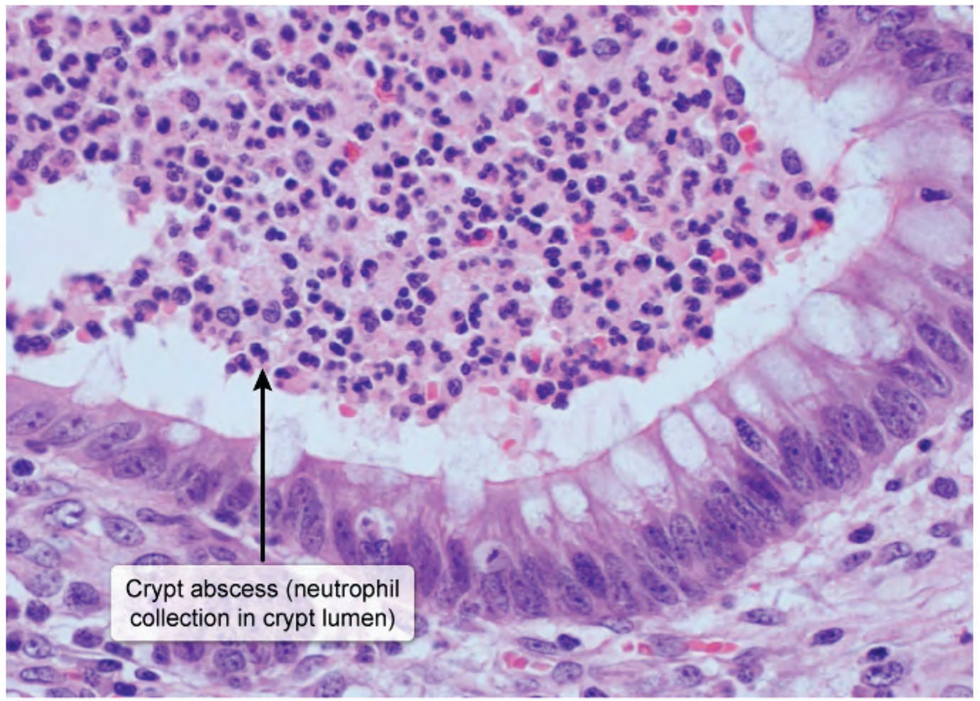

©UWorld

Zoom In Zoom Out Reset New | Existing My Notebook

https://t.me/USMLEWorldStep1

This p
featur
glucos
osmo
with p

Primar
recess
arises

(Choi
mucos
contai
pain a
in ass

(Choi
patien

(Choi
charac

(Choi
gastro
chroni

Educa
The sr

Pathoph
Subject System Topic

Exhibit Display

Whipple disease

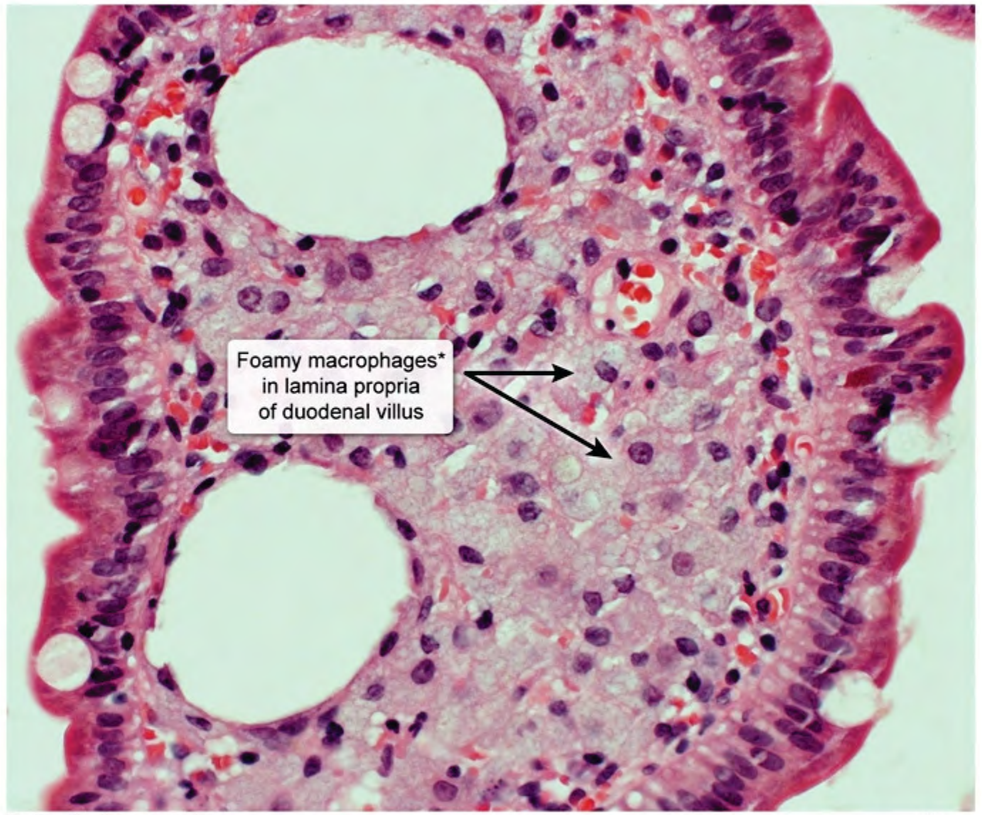

*Contain *Tropheryma whipplei*

©UWorld

Zoom In Zoom Out Reset New | Existing My Notebook

https://t.me/USMLEWorldStep1

A 42-year-old man comes to the office due to leg swelling. He has also had yellowing of the eyes and progressive abdominal distension for the past 3 weeks, as well as an associated 7-kg (15.4-lb) weight gain. The patient drinks at least 8 beers a day and in the past has been admitted to the hospital for intoxication and seizures. He denies smoking or intravenous drug use. Vital signs are within normal limits. Scleral icterus, spider angiomas, and palmar erythema are present. There is no jugular venous distension, and cardiac auscultation reveals a normal rate and rhythm. Breath sounds are normal. The abdomen is diffusely enlarged, and a fluid wave is easily elicited. Pitting edema is present in the bilateral lower extremities. Which of the following pathophysiologic changes is most likely present in this patient?

	Plasma oncotic pressure	Splanchnic vascular resistance	Effective arterial blood volume	Capillary permeability
○ A.	↓	↓	↓	Normal
○ B.	Normal	↑	↓	Normal
○ C.	↓	Normal	↑	↑
○ D.	Normal	Normal	Normal	↑
○ E.	↑	↓	Normal	Normal

Submit

https://t.me/USMLEWorldStep1

A 42-year-old man comes to the office due to leg swelling. He has also had yellowing of the eyes and progressive abdominal distension for the past 3 weeks, as well as an associated 7-kg (15.4-lb) weight gain. The patient drinks at least 8 beers a day and in the past has been admitted to the hospital for intoxication and seizures. He denies smoking or intravenous drug use. Vital signs are within normal limits. Scleral icterus, spider angiomas, and palmar erythema are present. There is no jugular venous distension, and cardiac auscultation reveals a normal rate and rhythm. Breath sounds are normal. The abdomen is diffusely enlarged, and a fluid wave is easily elicited. Pitting edema is present in the bilateral lower extremities. Which of the following pathophysiologic changes is most likely present in this patient?

	Plasma oncotic pressure	Splanchnic vascular resistance	Effective arterial blood volume	Capillary permeability	
✓ A.	↓	↓	↓	Normal	(63%)
✗ B.	Normal	↑	↓	Normal	(6%)
C.	↓	Normal	↑	↑	(24%)
D.	Normal	Normal	Normal	↑	(1%)
E.	↑	↓	Normal	Normal	(3%)

Incorrect
Correct answer
A

63%
Answered correctly

03 secs
Time Spent

2023
Version

Explanation

Pathogenesis of ascites in cirrhosis

https://t.me/USMLEWorldStep1

A 42-year-old man comes to the office due to leg swelling. He has also had yellowing of the eyes and progressive abdom
at leas
smoki
erythe
rhythm
edema
preser

Exhibit Display

Pathogenesis of ascites in cirrhosis

Portal hypertension

↑ Local vasodilators

Splanchnic vasodilation

↓ Systemic pressure & renal hypoperfusion

Activation of RAAS

Sodium & water retention

↑ Splanchnic hydrostatic pressure

Low oncotic pressure from hypoalbuminemia

Ascites

RAAS = renin-angiotensin-aldosterone system.

©UWorld

Zoom In | Zoom Out | Reset | New | Existing | My Notebook

Inco
Corre
A

Expl

https://t.me/USMLEWorldStep1

RAAS = renin-angiotensin-aldosterone system. ©UWorld

This patient has **ascites**, characterized by the accumulation of fluid within the peritoneal cavity. Ascites may occur in a variety of diseases (eg, peritoneal metastasis, congestive heart failure); however, in this patient with a history of heavy alcohol use and stigmata of chronic liver disease (eg, jaundice, spider angiomas, palmar erythema), it likely occurred from **cirrhosis**.

Cirrhosis is characterized by progressive liver fibrosis, which results in the formation of a high-resistance system (ie, **portal hypertension**). This results in the following alterations:

1. Nitric oxide is released, possibly due to stimulation by bacterial products (eg, endotoxin), which can more easily translocate from the gastrointestinal tract due to reduced host defenses (eg, impaired reticuloendothelial function) and portosystemic shunt formation (eg, decreased toxin clearance).
2. Splanchnic vasodilation occurs as a result, which **decreases the splanchnic vascular resistance** and **lowers the effective arterial blood volume** (EABV) due to blood pooling in the splanchnic vascular bed.
3. Low perfusion pressure results in activation of the renin-angiotensin-aldosterone system along with increased secretion of antidiuretic hormone, leading to **retention of sodium and water**.

Additionally, cirrhosis results in impaired synthetic function, leading to hypoalbuminemia and **low plasma oncotic pressure**, which reduces fluid resorption from the interstitium. Paired with portal hypertension (ie, increased hydrostatic pressure), these changes result in a vicious cycle of hypervolemia and third spacing, promoting the formation of ascites and peripheral edema. The capillaries remain physiologically normal, so **permeability is unchanged**.

(Choice B) Congestive heart failure causes low EABV (due to low cardiac output) with a consequent increase in sympathetic tone that results in increased splanchnic vascular resistance. Oncotic pressure and capillary permeability are unaffected.

(Choice C) Nephrotic syndrome causes edema due to increased permeability of the glomerular capillary wall, leading to loss of albumin, which decreases capillary oncotic pressure. Most patients also have a defect in sodium

https://t.me/USMLEWorldStep1

2. Splanchnic vasodilation occurs as a result, which **decreases the splanchnic vascular resistance** and **lowers the effective arterial blood volume** (EABV) due to blood pooling in the splanchnic vascular bed.

3. Low perfusion pressure results in activation of the renin-angiotensin-aldosterone system along with increased secretion of antidiuretic hormone, leading to **retention of sodium and water**.

Additionally, cirrhosis results in impaired synthetic function, leading to hypoalbuminemia and **low plasma oncotic pressure**, which reduces fluid resorption from the interstitium. Paired with portal hypertension (ie, increased hydrostatic pressure), these changes result in a vicious cycle of hypervolemia and third spacing, promoting the formation of ascites and peripheral edema. The capillaries remain physiologically normal, so **permeability is unchanged**.

(Choice B) Congestive heart failure causes low EABV (due to low cardiac output) with a consequent increase in sympathetic tone that results in increased splanchnic vascular resistance. Oncotic pressure and capillary permeability are unaffected.

(Choice C) Nephrotic syndrome causes edema due to increased permeability of the glomerular capillary wall, leading to loss of albumin, which decreases capillary oncotic pressure. Most patients also have a defect in sodium excretion from the kidneys, resulting in sodium retention and increased EABV. Splanchnic vascular resistance is unaffected.

(Choice D) Localized allergic reactions (eg, insect sting) can lead to increased capillary permeability, leading to dermal edema. Oncotic pressures, splanchnic vascular resistance, and EABV are unaffected.

(Choice E) Increased capillary oncotic pressure tends to inhibit fluid accumulation in the interstitial spaces, thereby decreasing peripheral edema and ascites.

Educational objective:
Ascites in cirrhosis develops from hemodynamic changes related to portal hypertension. Splanchnic vasodilation decreases the splanchnic vascular resistance and lowers the effective arterial blood volume, which causes activation of the renin-angiotensin-aldosterone system and promotes sodium and water retention. Additionally, low oncotic pressure (ie, hypoalbuminemia due to impaired hepatic function) reduces fluid resorption from the interstitium.

References

https://t.me/USMLEWorldStep1

2. Splanchnic vasodilation occurs as a result, which **decreases the splanchnic vascular resistance** and **lowers the effective arterial blood volume** (EABV) due to blood pooling in the splanchnic vascular bed.

3. L

s

Additi

press

hydros

format

uncha

(Choi

sympa

perme

(Choi

leadin

excret

unaffe

(Choi

derma

(Choi

thereb

Educa

Ascite

decrea

activat

oncoti

interstitium.

Exhibit Display

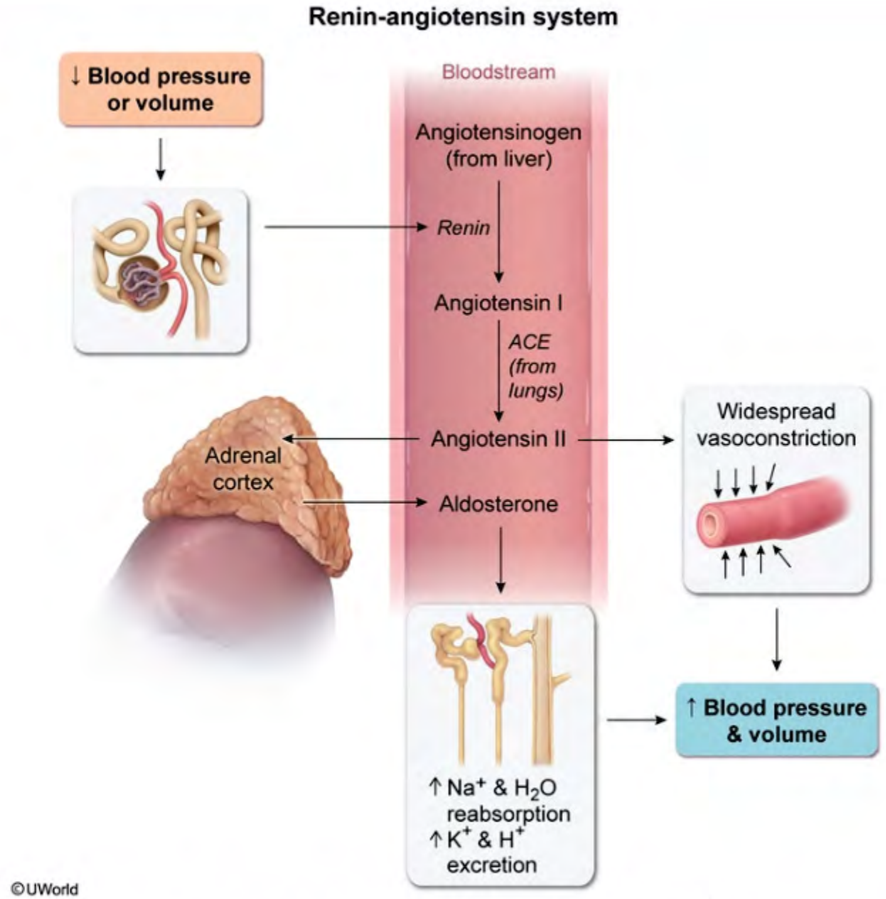

Zoom In | Zoom Out | Reset | New | Existing | My Notebook

https://t.me/USMLEWorldStep1

A 22-year-old woman comes to the office for a routine examination. The patient reports mild fatigue but is otherwise asymptomatic. She has no chronic medical conditions and takes no medications. She does not use tobacco, alcohol, or recreational drugs. The patient is not sexually active and has received all age-appropriate vaccinations. BMI is 30 kg/m^2. Blood pressure is 120/80 mm Hg and pulse is 78/min. Examination shows truncal obesity but is otherwise normal. Fasting laboratory results are as follows:

Glucose	127 mg/dL
Creatinine	1.0 mg/dL
Aspartate aminotransferase (SGOT)	76 U/L
Alanine aminotransferase (SGPT)	80 U/L
Total cholesterol	270 mg/dL
HDL-cholesterol	31 mg/dL
Triglycerides	247 mg/dL

If left untreated, this patient is at increased risk for which of the following complications?

- A. Acute hepatitis
- B. Adrenal insufficiency
- C. Aplastic anemia
- D. Cirrhosis
- E. Hepatic adenoma

Submit

https://t.me/USMLEWorldStep1

A 22-year-old woman comes to the office for a routine examination. The patient reports mild fatigue but is otherwise asymptomatic. She has no chronic medical conditions and takes no medications. She does not use tobacco, alcohol, or recreational drugs. The patient is not sexually active and has received all age-appropriate vaccinations. BMI is 30 kg/m^2. Blood pressure is 120/80 mm Hg and pulse is 78/min. Examination shows truncal obesity but is otherwise normal. Fasting laboratory results are as follows:

Glucose	127 mg/dL
Creatinine	1.0 mg/dL
Aspartate aminotransferase (SGOT)	76 U/L
Alanine aminotransferase (SGPT)	80 U/L
Total cholesterol	270 mg/dL
HDL-cholesterol	31 mg/dL
Triglycerides	247 mg/dL

If left untreated, this patient is at increased risk for which of the following complications?

- ✗ A. Acute hepatitis (16%)
- B. Adrenal insufficiency (13%)
- C. Aplastic anemia (1%)
- ✓ D. Cirrhosis (54%)
- E. Hepatic adenoma (12%)

Incorrect
Correct answer
D

54%
Answered correctly

03 secs
Time Spent

2023
Version

https://t.me/USMLEWorldStep1

Nonalcoholic fatty liver disease	
Definition	• Hepatic steatosis on imaging or biopsy • Exclusion of other etiologies (eg, alcohol, hepatitis C, glucocorticoids)
Clinical features	• Mostly asymptomatic • Metabolic syndrome • AST/ALT ratio <1 • Hyperechoic texture on ultrasound examination
Treatment	• Weight loss (eg, diet modification, exercise) • Consider bariatric surgery if BMI ≥35 kg/m^2
Prognosis	• Hepatic fibrosis associated with increased risk for cirrhosis & liver-related death

ALT = alanine aminotransferase; **AST** = aspartate aminotransferase.

This patient with **truncal obesity** (correlating to visceral adiposity), an elevated fasting glucose level, and dyslipidemia (ie, low HDL, high triglycerides) has **metabolic syndrome**. In addition, she has elevated hepatic aminotransferase levels indicative of hepatocellular injury. This presentation suggests **nonalcoholic fatty liver disease** (NAFLD), which commonly occurs in patients with metabolic syndrome due to the shared pathophysiology of insulin resistance.

Patients with NAFLD have an **increased risk of cirrhosis** due to chronic hepatocellular injury and inflammation triggered by hepatic free fatty acid accumulation. In the presence of inflammation, hepatic stellate (Ito) cells in the space of Disse are activated and transform into myofibroblasts that produce collagen in large quantities, leading to progressive fibrosis and ultimately cirrhosis.

Weight loss is the cornerstone of management and has been shown to reverse fibrosis.

(Choice A) NAFLD typically follows an indolent and asymptomatic course, requiring decades to progress to

https://t.me/USMLEWorldStep1

aminotransferase levels indicative of hepatocellular injury. This presentation suggests **nonalcoholic fatty liver disease** (NAFLD), which commonly occurs in patients with metabolic syndrome due to the shared pathophysiology of insulin resistance.

Patients with NAFLD have an **increased risk of cirrhosis** due to chronic hepatocellular injury and inflammation triggered by hepatic free fatty acid accumulation. In the presence of inflammation, hepatic stellate (Ito) cells in the space of Disse are activated and transform into myofibroblasts that produce collagen in large quantities, leading to progressive fibrosis and ultimately cirrhosis.

Weight loss is the cornerstone of management and has been shown to reverse fibrosis.

(Choice A) NAFLD typically follows an indolent and asymptomatic course, requiring decades to progress to cirrhosis. Acute hepatitis is not a clinical presentation of NAFLD.

(Choice B) Chronic adrenal insufficiency can cause fatigue, however, affected patients also frequently have weight loss, hypotension, and skin hyperpigmentation. Characteristic laboratory abnormalities include hyponatremia and hyperkalemia due to mineralocorticoid deficiency.

(Choice C) Certain strains of hepatitis viruses can cause aplastic anemia due to T-cell–mediated destruction of bone marrow cells. Viral hepatitis is unlikely in this patient without any risk factors.

(Choice E) Hepatic adenomas are solitary, benign liver tumors typically found in young women who are taking estrogen-containing oral contraceptive pills. NAFLD does not increase the risk of hepatic adenoma.

Educational objective:
Nonalcoholic fatty liver disease frequently develops in patients with metabolic syndrome (eg, obesity, dyslipidemia, insulin resistance) and can progress to cirrhosis due to chronic inflammation and hepatocyte injury.

References

- Liver fibrosis: mechanistic concepts and therapeutic perspectives.

Pathology	Gastrointestinal & Nutrition	Nonalcoholic fatty liver disease
Subject	System	Topic

Copyright © UWorld. All rights reserved.

https://t.me/USMLEWorldStep1

- Hyperechoic texture on ultrasound examination

Exhibit Display

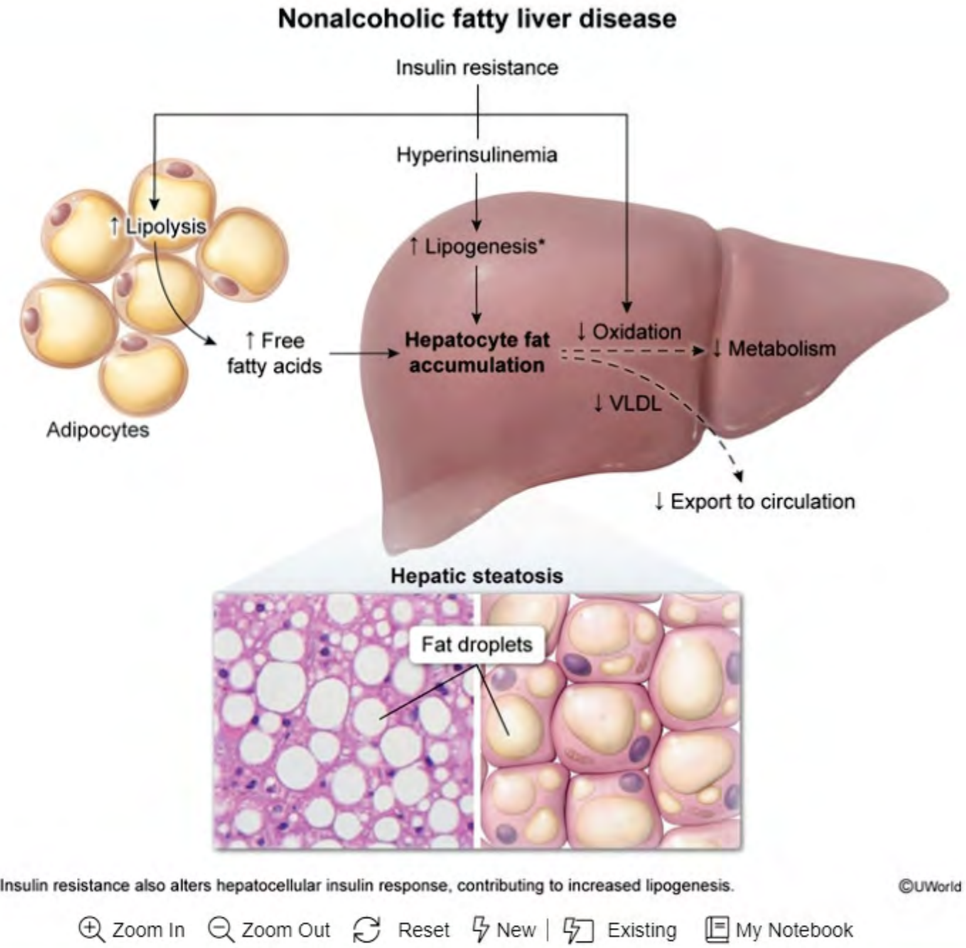

Zoom In | Zoom Out | Reset | New | Existing | My Notebook

This p
dyslipi
amino
diseas
of insu

Patien
trigger
space
progre

Weigh

(Choi
cirrhos

(Choi
weight
hypon

(Choi
bone r

(Choice E) Hepatic adenomas are solitary, benign liver tumors typically found in young women who are taking estrogen-containing oral contraceptive pills. NAFLD does not increase the risk of hepatic adenoma

https://t.me/USMLEWorldStep1

- Hyperechoic texture on ultrasound examination

Exhibit Display

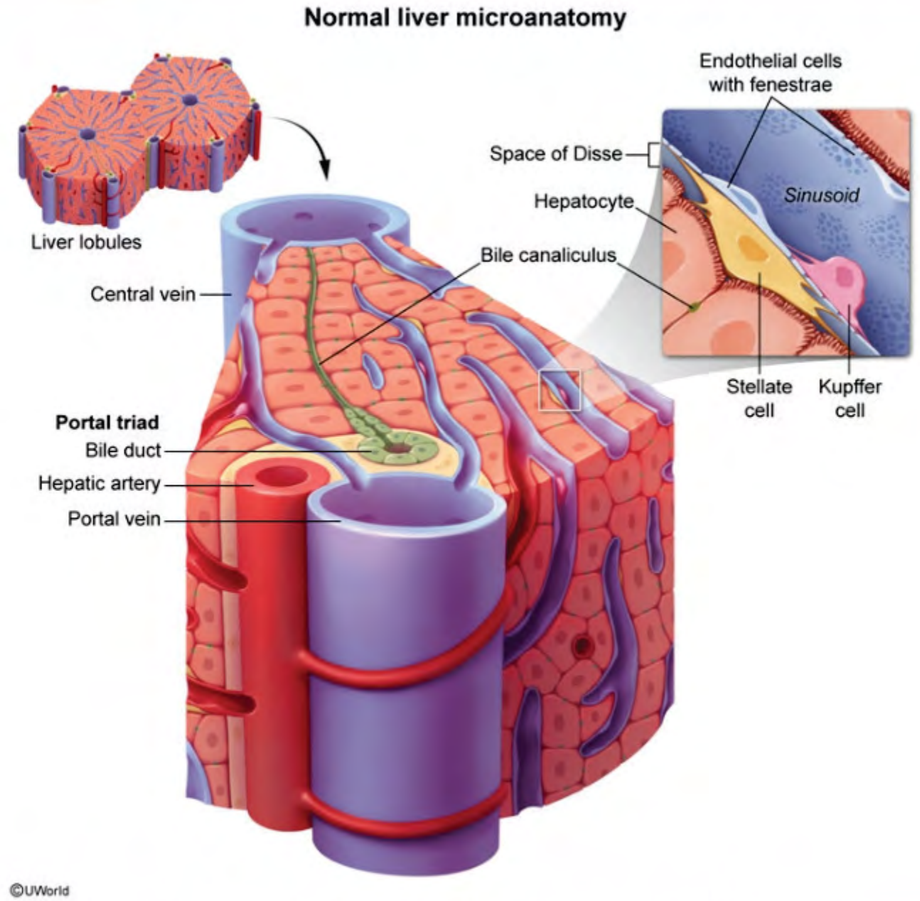

Zoom In | Zoom Out | Reset | New | Existing | My Notebook

This p
dyslipi
amino
diseas
of insu

Patien
trigger
space
progre

Weigh

(Choi
cirrhos

(Choi
weight
hypon

(Choi
bone r

(Choice E) Hepatic adenomas are solitary, benign liver tumors typically found in young women who are taking estrogen-containing oral contraceptive pills. NAFLD does not increase the risk of hepatic adenoma

https://t.me/USMLEWorldStep1

- Hyperechoic texture on ultrasound examination

Exhibit Display

Cirrhosis due to nonalcoholic fatty liver disease

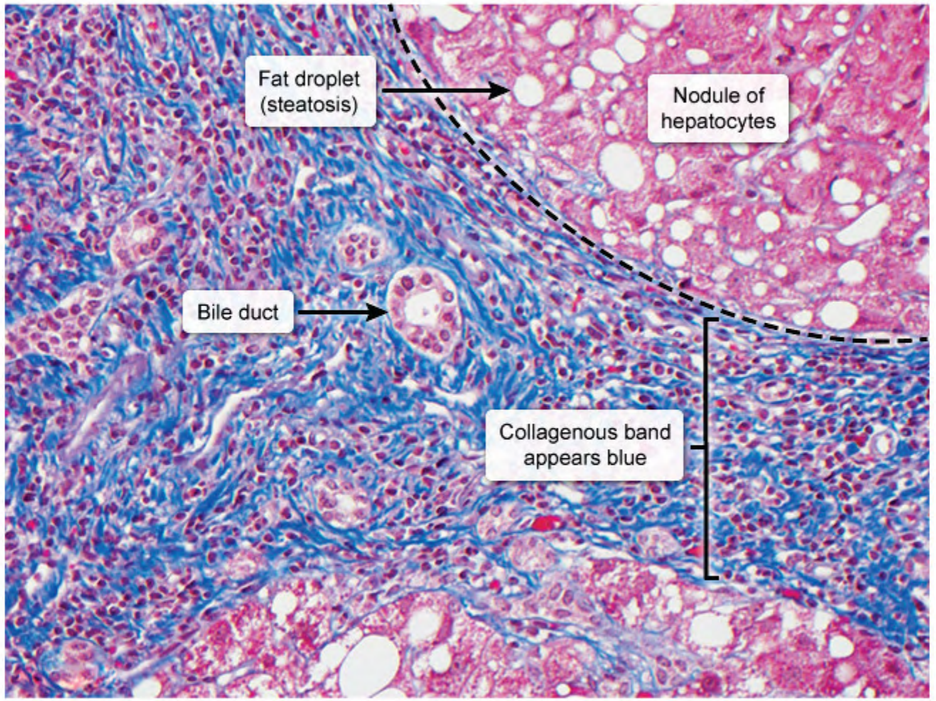

©UWorld

Trichrome stain

Zoom In | Zoom Out | Reset | New | Existing | My Notebook

This p
dyslipi
amino
diseas
of insu

Patien
trigger
space
progre

Weigh

(Choi
cirrhos

(Choi
weight
hypon

(Choi
bone r

(Choice E) Hepatic adenomas are solitary, benign liver tumors typically found in young women who are taking estrogen-containing oral contraceptive pills. NAFLD does not increase the risk of hepatic adenoma

https://t.me/USMLEWorldStep1

A 68-year-old man comes to the office due to fatigue, weight loss, and constipation. He has refused to undergo screening colonoscopy for several years because "nobody in my family had colon cancers." Past medical history is notable for emphysema and stable angina. The patient has smoked a pack of cigarettes daily for 50 years and drinks alcohol occasionally. Physical examination is unremarkable. He is referred for colonoscopy, which reveals a circumferential mass encircling the sigmoid colon. Pathology is positive for adenocarcinoma. CT scan of the chest, abdomen, and pelvis is negative for signs of metastasis. Serum carcinoembryonic antigen assay is ordered. The results of this assay would be most useful for which of the following aspects of this patient's care?

- A. Determining the need for surgery
- B. Determining the type of chemotherapy
- C. Grading of the tumor
- D. Monitoring for residual disease
- E. Staging of the tumor

Submit

https://t.me/USMLEWorldStep1

A 68-year-old man comes to the office due to fatigue, weight loss, and constipation. He has refused to undergo screening colonoscopy for several years because "nobody in my family had colon cancers." Past medical history is notable for emphysema and stable angina. The patient has smoked a pack of cigarettes daily for 50 years and drinks alcohol occasionally. Physical examination is unremarkable. He is referred for colonoscopy, which reveals a circumferential mass encircling the sigmoid colon. Pathology is positive for adenocarcinoma. CT scan of the chest, abdomen, and pelvis is negative for signs of metastasis. Serum carcinoembryonic antigen assay is ordered. The results of this assay would be most useful for which of the following aspects of this patient's care?

- A. Determining the need for surgery (1%)
- ✗ B. Determining the type of chemotherapy (8%)
- C. Grading of the tumor (3%)
- ✓ D. Monitoring for residual disease (80%)
- E. Staging of the tumor (5%)

Incorrect
Correct answer
D

80%
Answered correctly

03 secs
Time Spent

2023
Version

Explanation

Carcinoembryonic antigen (CEA) is a glycoprotein involved in cell adhesion. It is produced in the embryonic pancreas, liver, and intestine and is also detected in minute amounts in the serum of healthy adults. CEA levels are increased in most patients with colon cancer. Elevated **preoperative CEA** levels are associated with a worse **prognosis**, and failure to normalize following surgery suggests **residual disease**. During long-term follow-up, rising CEA levels are a sensitive indicator of colorectal cancer **recurrence**. However, CEA has low sensitivity and specificity for initial screening and diagnosis of colon cancer.

CEA levels are elevated in pancreatic, gastric, and breast malignancies along with other nonmalignant diseases

https://t.me/USMLEWorldStep1

Carcinoembryonic antigen (CEA) is a glycoprotein involved in cell adhesion. It is produced in the embryonic pancreas, liver, and intestine and is also detected in minute amounts in the serum of healthy adults. CEA levels are increased in most patients with colon cancer. Elevated **preoperative CEA** levels are associated with a worse **prognosis**, and failure to normalize following surgery suggests **residual disease**. During long-term follow-up, rising CEA levels are a sensitive indicator of colorectal cancer **recurrence**. However, CEA has low sensitivity and specificity for initial screening and diagnosis of colon cancer.

CEA levels are elevated in pancreatic, gastric, and breast malignancies along with other nonmalignant diseases (eg, inflammatory bowel disease, chronic obstructive pulmonary disease, cirrhosis, pancreatitis). CEA levels are also higher in smokers than nonsmokers.

(Choice A) Surgical resection is recommended for most patients with colon cancer unless there are unresectable metastases. The specific procedure recommended is dependent on stage and anatomical considerations rather than CEA levels.

(Choice B) Adjuvant chemotherapy is recommended for most patients with node-positive colorectal adenocarcinoma regardless of CEA levels.

(Choices C and E) Tumor grade describes the degree of tumor differentiation and is determined histologically. The stage of the tumor reflects the extent of its spread (eg, penetration of the bowel wall, lymph node invasion, distant metastases). Elevated CEA levels are associated with a worse prognosis regardless of tumor stage, but CEA measurement is not currently considered part of the initial staging evaluation.

Educational objective:
Carcinoembryonic antigen (CEA) levels are increased in colon cancer but are also elevated in a number of other conditions (eg, pancreatic cancer, COPD, cirrhosis). CEA cannot be used to diagnose colon cancer, but it is helpful for detecting residual disease and recurrence.

References

- Carcinoembryonic antigen in the staging and follow-up of patients with colorectal cancer.

Pathology Gastrointestinal & Nutrition Colorectal polyps and cancer

https://t.me/USMLEWorldStep1

A 65-year-old woman comes to the office after finding blood in her stool. She is physically active and exercises regularly. She does not use tobacco or alcohol. She has no history of peptic ulcer disease. Her physical examination is unremarkable. Colonoscopy reveals several large adenomatous polyps with severe dysplasia in the sigmoid colon. She undergoes resection of the sigmoid colon, and her carcinoembryonic antigen level is normal. The patient is interested in decreasing her chances of developing new polyps and colon cancer. The physician discusses exercise, healthy weight, and dietary factors associated with reduction of colon cancer risk, including increased fiber intake and reduced consumption of refined sugars and fat. Which of the following enzymes could be inhibited with medication to further reduce this patient's risk of developing recurrent adenoma?

- A. Angiotensin-converting enzyme
- B. Caspase
- C. Cyclooxygenase-2
- D. Glutamate dehydrogenase
- E. Phenylalanine hydroxylase
- F. Xanthine oxidase

Submit

https://t.me/USMLEWorldStep1

A 65-year-old woman comes to the office after finding blood in her stool. She is physically active and exercises regularly. She does not use tobacco or alcohol. She has no history of peptic ulcer disease. Her physical examination is unremarkable. Colonoscopy reveals several large adenomatous polyps with severe dysplasia in the sigmoid colon. She undergoes resection of the sigmoid colon, and her carcinoembryonic antigen level is normal. The patient is interested in decreasing her chances of developing new polyps and colon cancer. The physician discusses exercise, healthy weight, and dietary factors associated with reduction of colon cancer risk, including increased fiber intake and reduced consumption of refined sugars and fat. Which of the following enzymes could be inhibited with medication to further reduce this patient's risk of developing recurrent adenoma?

- A. Angiotensin-converting enzyme (2%)
- ✗ B. Caspase (11%)
- ✓ C. Cyclooxygenase-2 (60%)
- D. Glutamate dehydrogenase (13%)
- E. Phenylalanine hydroxylase (4%)
- F. Xanthine oxidase (8%)

Incorrect
Correct answer
C

60%
Answered correctly

03 secs
Time Spent

2023
Version

Explanation

https://t.me/USMLEWorldStep1

the sigmoid colon. She undergoes resection of the sigmoid colon, and her carcinoembryonic antigen level is
norma
physic
includi
enzym

Inco
Corre
C

Expl

Exhibit Display

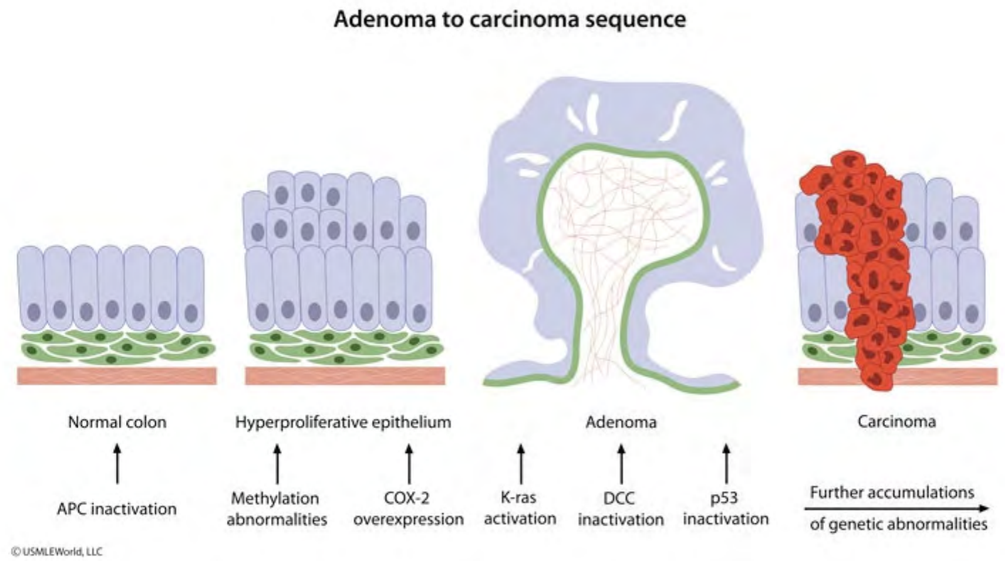

Zoom In Zoom Out Reset New | Existing My Notebook

https://t.me/USMLEWorldStep1

Adenomatous polyps contain dysplastic mucosa and are premalignant. They tend to develop in patients age >50 as a result of mutations in the *APC* tumor suppressor gene, which regulates cell growth and adhesion. Progression to adenocarcinoma proceeds as other mutations occur in genes such as *KRAS* and *TP53*. This accumulation of gene mutations is called the "**adenoma-to-carcinoma sequence**."

Increased activity of the enzyme **cyclooxygenase-2** (COX-2) has been found in many forms of colon adenocarcinoma and in inherited polyposes syndromes. This may be due to the need for COX-induced prostaglandin production, which leads to epithelial proliferation. Regular **aspirin** (a COX inhibitor) intake has been associated with lower rates of colonic adenoma and adenocarcinoma, although this must be balanced against bleeding risk.

(Choice A) Angiotensin-converting enzyme (ACE) converts angiotensin I to angiotensin II, which plays an important role in hypertension and congestive heart failure. ACE inhibitors are widely used to treat these conditions.

(Choice B) Caspases are cysteine proteases that are an essential component in cellular apoptosis. Inhibition of caspase activity would lead to cells that are resistant to apoptosis; this is one of the mechanisms involved in the progression of the adenoma-to-carcinoma sequence.

(Choices D and E) Glutamate dehydrogenase (produces ammonia for use in the urea cycle) and phenylalanine hydroxylase (converts phenylalanine to tyrosine) have not been implicated in the development of adenomatous polyps.

(Choice F) Xanthine oxidase is an enzyme that participates in uric acid synthesis. Allopurinol is a xanthine oxidase inhibitor used to lower serum levels of uric acid in gout and tumor lysis syndrome.

Educational objective:
Adenomatous polyps contain dysplastic mucosa and are premalignant. Regular screening with timely excision of polyps is effective for prevention of colon adenocarcinoma. Studies have linked increased activity of cyclooxygenase-2 to some forms of colon adenocarcinoma and suggest that regular aspirin use decreases adenomatous polyp formation.

References

https://t.me/USMLEWorldStep1

A 62-year-old man comes to the emergency department due to severe colicky upper abdominal pain, nausea, and vomiting. He reports several episodes of similar abdominal discomfort in the past. The patient does not use tobacco, alcohol, or illicit drugs. He immigrated to the United States from East Asia several years ago. Physical examination shows right upper quadrant abdominal tenderness. An imaging study shows several gallstones in the common bile duct and gallbladder. The stones are removed from the duct endoscopically, and a cholecystectomy is also performed. The gallstones are dark brown, soft, and composed primarily of calcium bilirubinate with variable amounts of cholesterol. Which of the following enzymes most likely played an important role in the pathogenesis of this patient's condition?

- A. 7-alpha-hydroxylase
- B. Aromatase
- C. Beta-glucuronidase
- D. Desmolase
- E. HMG-CoA reductase

Submit

https://t.me/USMLEWorldStep1

A 62-year-old man comes to the emergency department due to severe colicky upper abdominal pain, nausea, and vomiting. He reports several episodes of similar abdominal discomfort in the past. The patient does not use tobacco, alcohol, or illicit drugs. He immigrated to the United States from East Asia several years ago. Physical examination shows right upper quadrant abdominal tenderness. An imaging study shows several gallstones in the common bile duct and gallbladder. The stones are removed from the duct endoscopically, and a cholecystectomy is also performed. The gallstones are dark brown, soft, and composed primarily of calcium bilirubinate with variable amounts of cholesterol. Which of the following enzymes most likely played an important role in the pathogenesis of this patient's condition?

- ✗ A. 7-alpha-hydroxylase (27%)
- B. Aromatase (1%)
- ✓ C. Beta-glucuronidase (45%)
- D. Desmolase (3%)
- E. HMG-CoA reductase (22%)

Incorrect
Correct answer
C

45%
Answered correctly

03 secs
Time Spent

2023
Version

Explanation

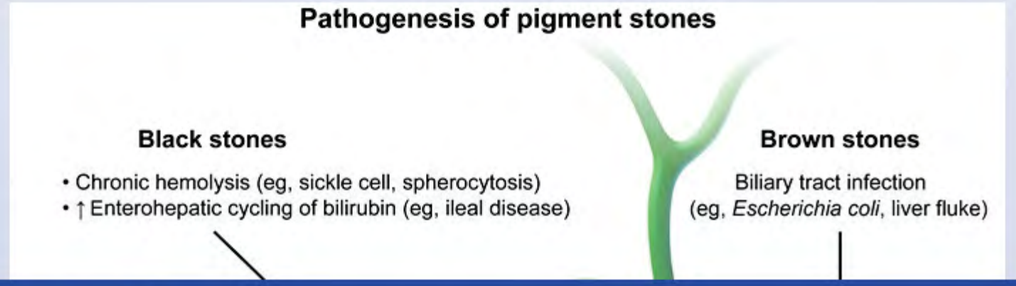

https://t.me/USMLEWorldStep1

A 62-year-old man comes to the emergency department due to severe colicky upper abdominal pain, nausea, and vomiti
tobacc
exami
comm
is also
variab
pathog

Exhibit Display

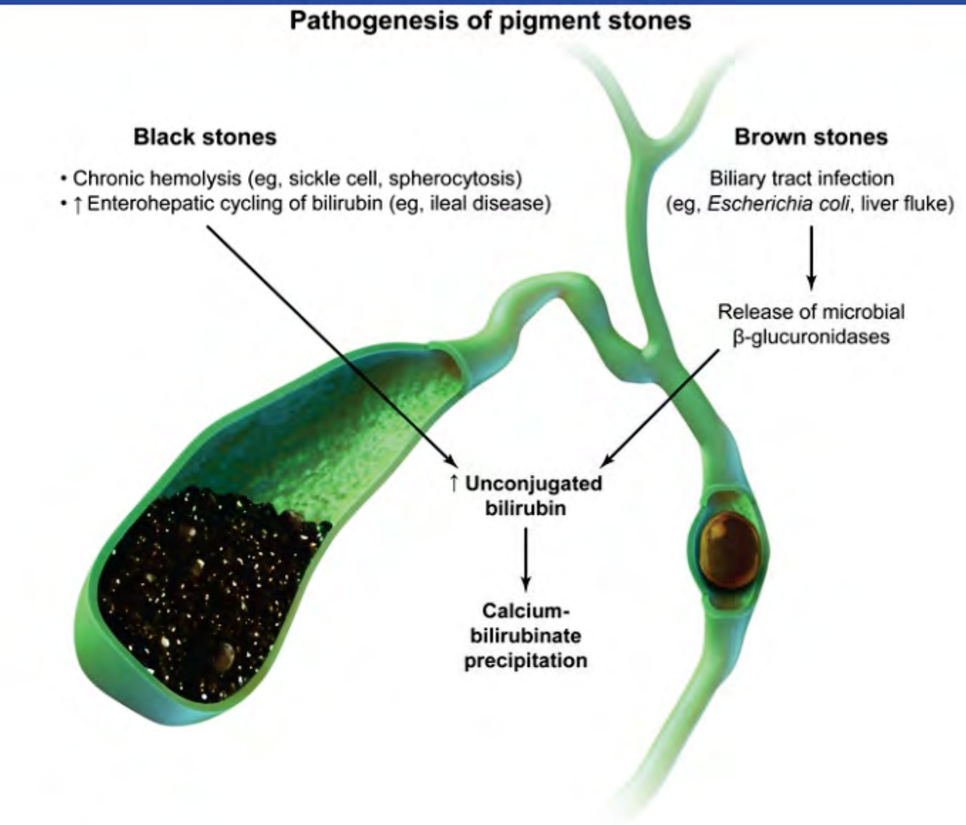

Zoom In | Zoom Out | Reset | New | Existing | My Notebook

• Chronic hemolysis (eg, sickle cell, spherocytosis)
• ↑ Enterohepatic cycling of bilirubin (eg, ileal disease)
Biliary tract infection
(eg, Escherichia coli, liver fluke)

https://t.me/USMLEWorldStep1

Gallstones can be categorized as cholesterol, pigment, or mixed stones. Cholesterol stones are formed when the ability of bile salts to solubilize cholesterol is overwhelmed by high concentrations of cholesterol in bile. Cholesterol stones are yellow to pale gray and hard. By contrast, **pigment gallstones** are composed of calcium salts of **unconjugated bilirubin**, are comparatively soft, and are dark brown to black.

Brown pigment stones typically arise secondary to bacterial (eg, *Escherichia coli*) or helminthic (eg, *Ascaris lumbricoides, Clonorchis sinensis*) **infection of the biliary tract**, which results in the release of **beta-glucuronidase** by injured hepatocytes and bacteria. This enzyme hydrolyzes bilirubin glucuronides and increases the amount of unconjugated bilirubin. The liver fluke *C sinensis* is a common cause of pigmented stones in East Asian countries and can have a prolonged quiescent phase before inducing symptoms.

Pigment stones may also occur in the absence of infection when excess bilirubin is excreted, such as with chronic **hemolytic anemia**. A small amount of conjugated bilirubin normally becomes deconjugated by endogenous beta-glucuronidase in the biliary tract. When large amounts of conjugated bilirubin are excreted into the bile, enough becomes deconjugated to promote black pigment stone formation.

(Choice A) Inhibition of 7-alpha-hydroxylase (eg, fibrates) reduces the conversion of cholesterol to bile acids and increases the risk of cholesterol stones. However, this patient's gallstones are composed primarily of unconjugated bilirubin, not cholesterol.

(Choices B and E) Aromatase catalyzes the conversion of androgens to estrogen, which increases hepatic cholesterol uptake. In addition, estrogens upregulate HMG Co-A reductase, which increases cholesterol synthesis. This increases biliary excretion of cholesterol, favoring formation of cholesterol stones, not pigment stones.

(Choice D) Desmolase (cholesterol side-chain cleavage enzyme) catalyzes the conversion of cholesterol to pregnenolone, which is the first step in the synthesis of steroid hormones.

Educational objective:
Brown pigment gallstones are composed of calcium salts of unconjugated bilirubin and arise secondary to bacterial or helminthic infection of the biliary tract. Beta-glucuronidase released by injured hepatocytes and bacteria hydrolyzes bilirubin glucuronides to unconjugated bilirubin. The liver fluke *Clonorchis sinensis* has a high prevalence in East Asian countries and is a common cause of pigment stones.

https://t.me/USMLEWorldStep1

A 3-week-old-girl in the neonatal intensive care unit develops abdominal distension, vomiting, and blood-streaked stools. She had previously tolerated formula feeds and had normal stool and urine output. She was born at 27 weeks gestation to an 18-year-old-mother. The pregnancy was complicated by premature rupture of membranes and preterm delivery. Abdominal x-ray shows thin curvilinear areas of lucency that parallel the bowel wall lumen. Which of the following is the most likely diagnosis?

- A. Duodenal atresia
- B. Hirschsprung disease
- C. Malrotation with volvulus
- D. Necrotizing enterocolitis
- E. Pyloric stenosis

Submit

https://t.me/USMLEWorldStep1

A 3-week-old-girl in the neonatal intensive care unit develops abdominal distension, vomiting, and blood-streaked stools. She had previously tolerated formula feeds and had normal stool and urine output. She was born at 27 weeks gestation to an 18-year-old-mother. The pregnancy was complicated by premature rupture of membranes and preterm delivery. Abdominal x-ray shows thin curvilinear areas of lucency that parallel the bowel wall lumen. Which of the following is the most likely diagnosis?

- A. Duodenal atresia (4%)
- ✕ B. Hirschsprung disease (6%)
- C. Malrotation with volvulus (19%)
- ✓ D. Necrotizing enterocolitis (67%)
- E. Pyloric stenosis (2%)

Incorrect
Correct answer
D

67%
Answered correctly

37 secs
Time Spent

2023
Version

Explanation

Necrotizing enterocolitis

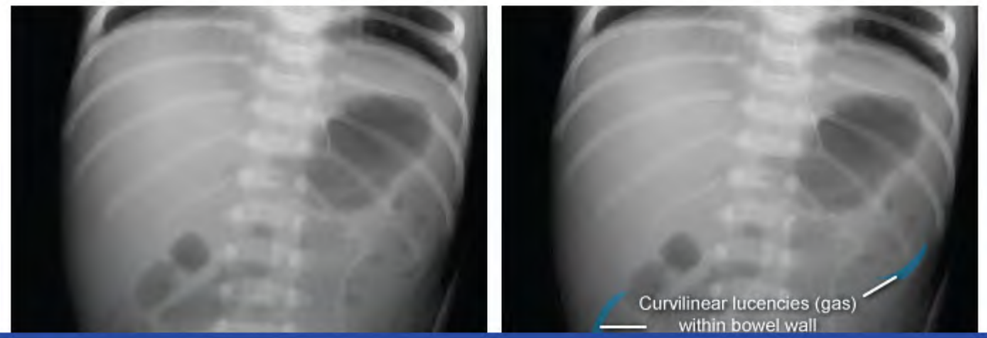

https://t.me/USMLEWorldStep1

A 3-week-old girl in the neonatal intensive care unit develops abdominal distension, vomiting, and blood-streaked stools.
weeks
and pr
Which

Inco
Corre
D

Expl

Exhibit Display

Necrotizing enterocolitis

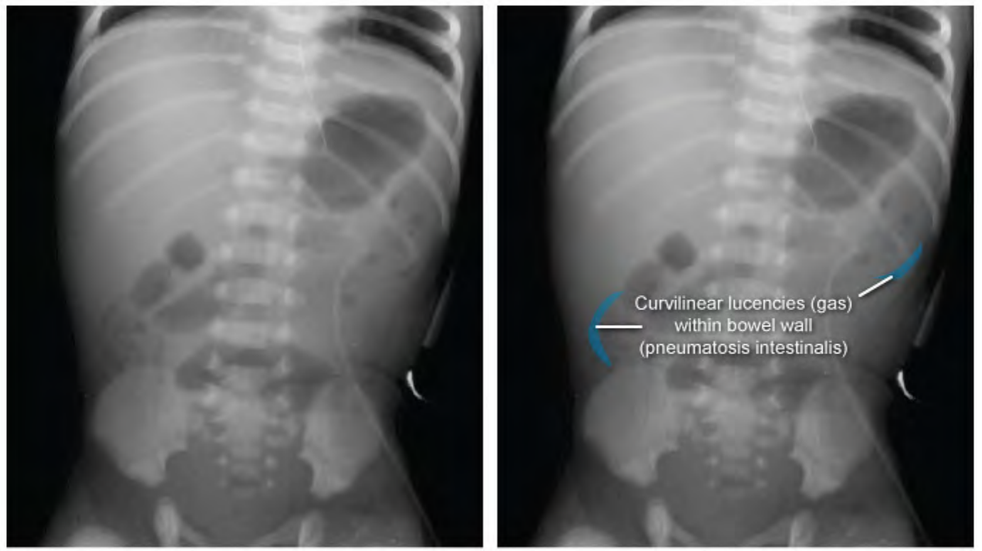

©UWorld

Zoom In | Zoom Out | Reset | New | Existing | My Notebook

https://t.me/USMLEWorldStep1

©UWorld

This infant has **pneumatosis intestinalis** (ie, air in the bowel wall), which can be seen on abdominal x-ray as thin curvilinear areas of lucency that parallel the lumen. In an infant with abdominal distension and bloody stools, this finding is diagnostic for **necrotizing enterocolitis** (NEC).

NEC is one of the most frequent gastrointestinal emergencies affecting newborns. It occurs predominantly in **preterm infants** secondary to gastrointestinal and immunologic immaturity. Upon initiation of enteral feeding, bacteria are introduced into the bowel where they proliferate excessively due to compromised immune clearance. Impaired mucosal barrier function allows the bacteria to invade the bowel wall, causing inflammation and **ischemic necrosis** of the terminal ileum and colon. As the disease progresses, the bowel becomes congested and gangrenous with the formation of **intramural gas collections**.

Up to 30% of affected neonates die, especially when disease is complicated by intestinal perforation. Survivors are at risk for strictures and **bowel obstruction** secondary to fibrosis that occurs as the inflammation subsides.

(Choice A) Duodenal atresia classically presents with the double bubble sign of air in the stomach and proximal duodenal pouch. Affected infants generally have bilious emesis shortly after birth.

(Choice B) Hirschsprung disease manifests with failure to pass meconium in the first 48 hours after birth. On x-ray, the large intestine appears dilated proximal to the aganglionic portion of bowel; contrast enema will show a narrow-caliber transition zone.

(Choice C) Malrotation of the bowel occurs when the midgut does not rotate normally during the first trimester, leaving the small and large bowel malpositioned. Malrotated bowel is at high risk of obstruction and ischemia due to twisting around its blood supply (volvulus). However, the finding of pneumatosis intestinalis is more specific for necrotizing enterocolitis.

(Choice E) Pyloric stenosis is caused by hypertrophy of the pyloric sphincter and leads to gastric outlet obstruction. It presents with nonbilious vomiting after feeding and a palpable ball of muscle ("olive") in the abdomen. Pyloric stenosis is not associated with bloody stools or pneumatosis intestinalis.

Educational objective:
Necrotizing enterocolitis is one of the most common gastrointestinal emergencies affecting newborns. It is

https://t.me/USMLEWorldStep1

finding is diagnostic for **necrotizing enterocolitis** (NEC).

NEC is one of the most frequent gastrointestinal emergencies affecting newborns. It occurs predominantly in **preterm infants** secondary to gastrointestinal and immunologic immaturity. Upon initiation of enteral feeding, bacteria are introduced into the bowel where they proliferate excessively due to compromised immune clearance. Impaired mucosal barrier function allows the bacteria to invade the bowel wall, causing inflammation and **ischemic necrosis** of the terminal ileum and colon. As the disease progresses, the bowel becomes congested and gangrenous with the formation of **intramural gas collections**.

Up to 30% of affected neonates die, especially when disease is complicated by intestinal perforation. Survivors are at risk for strictures and **bowel obstruction** secondary to fibrosis that occurs as the inflammation subsides.

(Choice A) Duodenal atresia classically presents with the double bubble sign of air in the stomach and proximal duodenal pouch. Affected infants generally have bilious emesis shortly after birth.

(Choice B) Hirschsprung disease manifests with failure to pass meconium in the first 48 hours after birth. On x-ray, the large intestine appears dilated proximal to the aganglionic portion of bowel; contrast enema will show a narrow-caliber transition zone.

(Choice C) Malrotation of the bowel occurs when the midgut does not rotate normally during the first trimester, leaving the small and large bowel malpositioned. Malrotated bowel is at high risk of obstruction and ischemia due to twisting around its blood supply (volvulus). However, the finding of pneumatosis intestinalis is more specific for necrotizing enterocolitis.

(Choice E) Pyloric stenosis is caused by hypertrophy of the pyloric sphincter and leads to gastric outlet obstruction. It presents with nonbilious vomiting after feeding and a palpable ball of muscle ("olive") in the abdomen. Pyloric stenosis is not associated with bloody stools or pneumatosis intestinalis.

Educational objective:
Necrotizing enterocolitis is one of the most common gastrointestinal emergencies affecting newborns. It is characterized by bacterial invasion and ischemic necrosis of the bowel wall, and is associated with prematurity and initiation of enteral feeding. Abdominal x-ray showing pneumatosis intestinalis (ie, air in the bowel wall) confirms the diagnosis.

https://t.me/USMLEWorldStep1

finding is diagnostic for **necrotizing enterocolitis** (NEC).

NEC is
preter
bacter
Impair
necro
gangre

Up to
at risk

(Choi
duode

(Choi
ray, th
narrow

(Choi
leaving
to twis
necrot

(Choi
obstru
abdom

Educa
Necrot
charac
initiati
the diagnosis.

Exhibit Display

Duodenal atresia

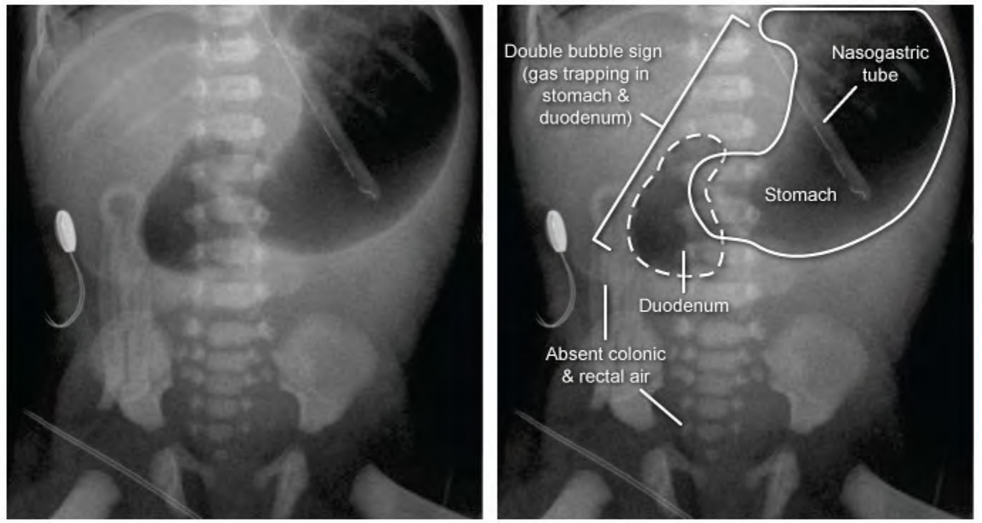

©UWorld

Zoom In | Zoom Out | Reset | New | Existing | My Notebook

https://t.me/USMLEWorldStep1

finding is diagnostic for **necrotizing enterocolitis** (NEC).

NEC is
preter
bacter
Impair
necro
gangre

Up to
at risk

(Choi
duode

(Choi
ray, th
narrow

(Choi
leaving
to twis
necrot

(Choi
obstru
abdom

Educa
Necrot
charac
initiati
the diagnosis.

Exhibit Display

Hirschsprung disease

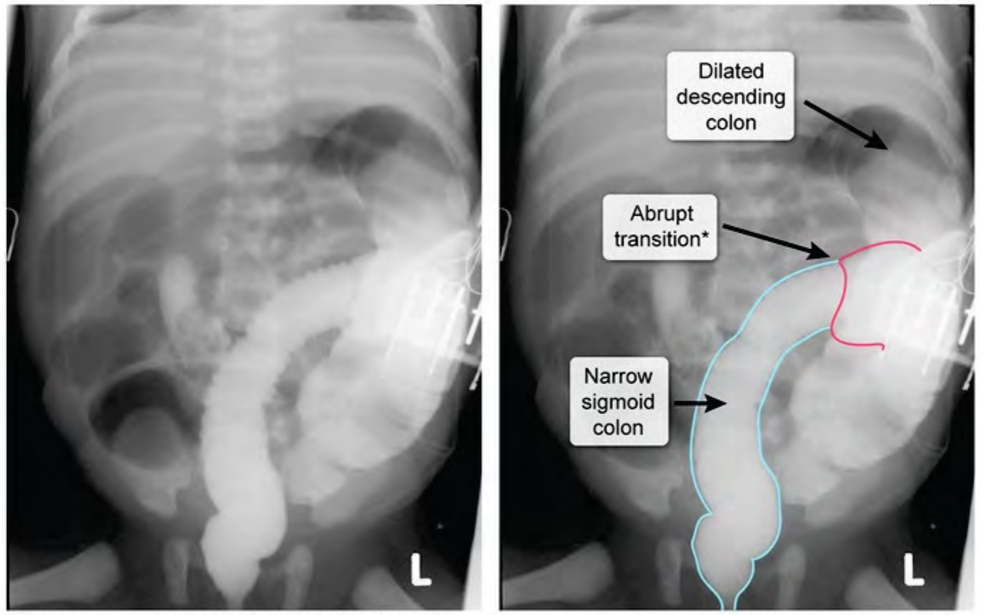

*Between narrow, aganglionic colon & dilated proximal colon.

©UWorld

Zoom In | Zoom Out | Reset | New | Existing | My Notebook

https://t.me/USMLEWorldStep1

A 3-year-old boy is brought to the emergency department by his parents after he develops acute abdominal pain and vomiting. Examination shows diffuse tenderness to palpation, and abdominal imaging reveals a foreign body lodged within the intestine, causing a small bowel obstruction. Laparotomy is performed to remove the foreign body; during the procedure, an incidental cyst is discovered. The cyst is connected by a fibrous band to the ileum and the umbilicus. The embryologic defect underlying the formation of this patient's cyst is also associated with which of the following?

- A. Gastroschisis
- B. Malrotation
- C. Meckel diverticulum
- D. Omphalocele
- E. Patent urachus
- F. Umbilical hernia

Submit

https://t.me/USMLEWorldStep1

A 3-year-old boy is brought to the emergency department by his parents after he develops acute abdominal pain and vomiting. Examination shows diffuse tenderness to palpation, and abdominal imaging reveals a foreign body lodged within the intestine, causing a small bowel obstruction. Laparotomy is performed to remove the foreign body; during the procedure, an incidental cyst is discovered. The cyst is connected by a fibrous band to the ileum and the umbilicus. The embryologic defect underlying the formation of this patient's cyst is also associated with which of the following?

- A. Gastroschisis (1%)
- ✗ B. Malrotation (7%)
- ✓ C. Meckel diverticulum (61%)
- D. Omphalocele (4%)
- E. Patent urachus (21%)
- F. Umbilical hernia (4%)

Incorrect
Correct answer
C

61%
Answered correctly

03 secs
Time Spent

2023
Version

Explanation

Vitelline duct abnormalities

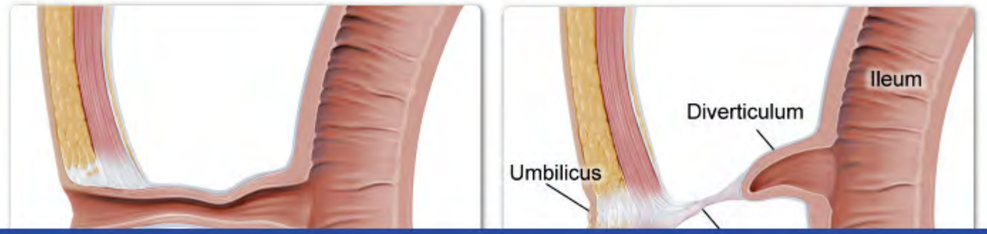

https://t.me/USMLEWorldStep1

Correct answer
C

61%
Answered correctly

03 secs
Time Spent

2023
Version

Exhibit Display

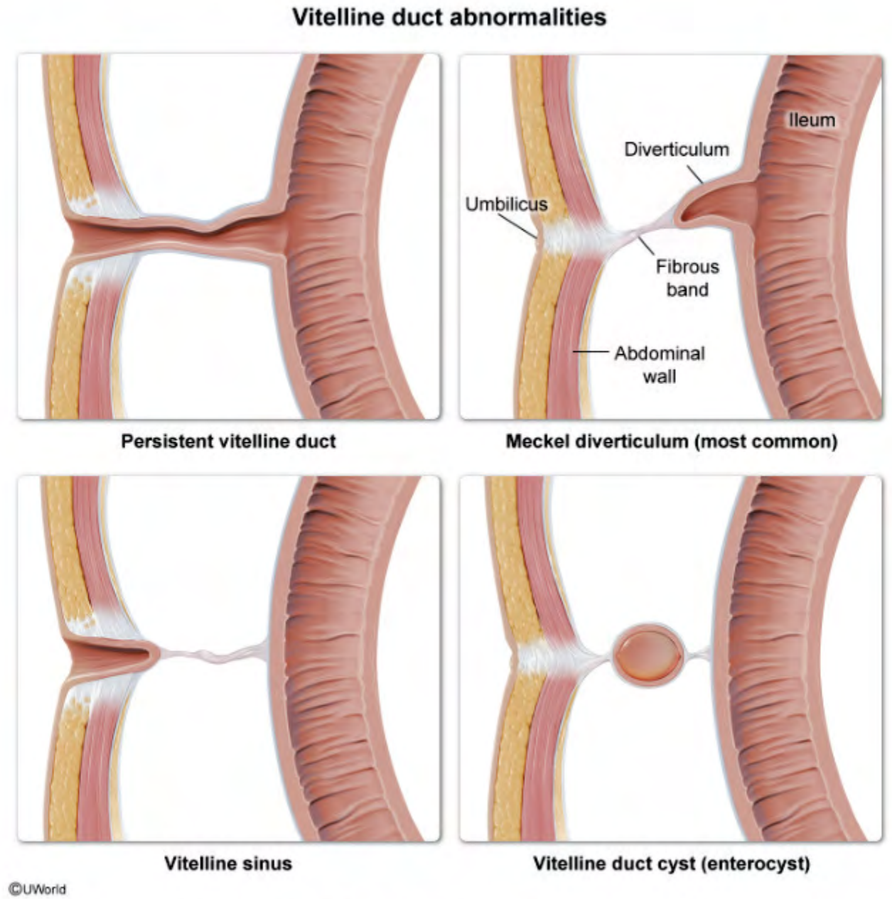

Zoom In | Zoom Out | Reset | New | Existing | My Notebook

Vitelline sinus
Vitelline duct cyst (enterocyst)
©UWorld

https://t.me/USMLEWorldStep1

Vitelline sinus

Vitelline duct cyst (enterocyst)

©UWorld

This patient has an abnormal fibrous connection between the ileum and the umbilicus, a finding that represents the **incomplete obliteration of the vitelline (omphalomesenteric) duct**. Normally, the vitelline duct connects the midgut lumen with the yolk sac cavity in early fetal development and obliterates in the first trimester. In this case, the incidental cyst within this embryologic remnant is consistent with a vitelline duct cyst.

Incomplete obliteration can result in a spectrum of anomalies:

- **Persistent vitelline duct** is due to the complete failure of duct closure and results in a patent connection between the intestinal lumen and the umbilicus. This causes meconium discharge from the umbilicus after birth.
- **Meckel diverticulum**, the most common vitelline duct anomaly, results from partial closure of the vitelline duct, with the patent portion attached to the ileum. A fibrous band may connect the tip of the diverticulum with the umbilicus. Patients classically have painless hematochezia due to intestinal ulceration from heterotopic gastric mucosa contained within the diverticulum.
- **Vitelline sinus** results from partial closure of the vitelline duct, with the patent portion at the umbilicus; serous umbilical drainage may occur.
- **Vitelline duct cyst**, as seen in this patient, forms when peripheral portions of the duct obliterate but the central part remains. Patients are usually asymptomatic.

(Choices A, D, and F) Gastroschisis and omphalocele are characterized by the incomplete closure of the abdominal wall, leading to protrusion of abdominal organs. Whereas gastroschisis occurs lateral to the umbilicus and eviscerated bowel is exposed, omphalocele is a midline defect covered within a peritoneal sac. An umbilical hernia, a common midline protrusion, is due to abdominal wall weakness. These defects are not associated with a vitelline cyst.

(Choice B) Malrotation results from failure of the midgut to rotate normally while it returns to the abdominal cavity during early fetal development. Patients have abnormal positioning of the intestine in the abdominal cavity and sometimes twisting of an intestinal loop (volvulus).

https://t.me/USMLEWorldStep1

birth.

- **Meckel diverticulum**, the most common vitelline duct anomaly, results from partial closure of the vitelline duct, with the patent portion attached to the ileum. A fibrous band may connect the tip of the diverticulum with the umbilicus. Patients classically have painless hematochezia due to intestinal ulceration from heterotopic gastric mucosa contained within the diverticulum.
- **Vitelline sinus** results from partial closure of the vitelline duct, with the patent portion at the umbilicus; serous umbilical drainage may occur.
- **Vitelline duct cyst**, as seen in this patient, forms when peripheral portions of the duct obliterate but the central part remains. Patients are usually asymptomatic.

(Choices A, D, and F) Gastroschisis and omphalocele are characterized by the incomplete closure of the abdominal wall, leading to protrusion of abdominal organs. Whereas gastroschisis occurs lateral to the umbilicus and eviscerated bowel is exposed, omphalocele is a midline defect covered within a peritoneal sac. An umbilical hernia, a common midline protrusion, is due to abdominal wall weakness. These defects are not associated with a vitelline cyst.

(Choice B) Malrotation results from failure of the midgut to rotate normally while it returns to the abdominal cavity during early fetal development. Patients have abnormal positioning of the intestine in the abdominal cavity and sometimes twisting of an intestinal loop (volvulus).

(Choice E) A patent urachus results from failure of the allantois (urachus) to obliterate and presents with urine drainage through the umbilicus. This anomaly is associated with a urachal cyst, which is connected by a fibrous band to the bladder (not the ileum) and umbilicus.

Educational objective:
The vitelline (omphalomesenteric) duct normally obliterates during early embryologic development. Incomplete obliteration can result in a spectrum of anomalies, including vitelline duct cyst (ie, cyst connected by fibrous bands to the ileum and umbilicus) and Meckel diverticulum.

Embryology | Gastrointestinal & Nutrition | Meckel diverticulum

https://t.me/USMLEWorldStep1

Vitelline sinus

Vitelline duct cyst (enterocyst)

Exhibit Display

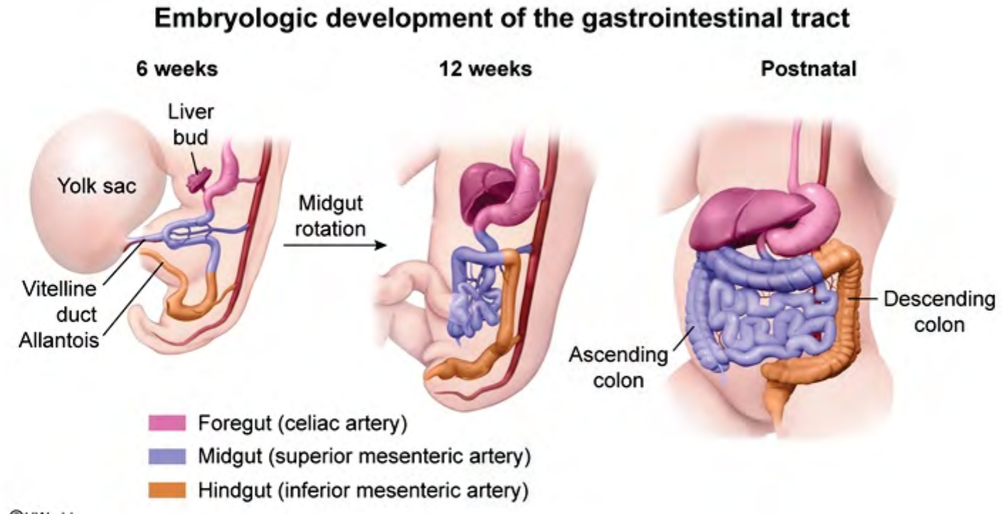

Zoom In | Zoom Out | Reset | New | Existing | My Notebook

This p
incom
midgu
the inc

Incom

- **P**
- **M**
- **V**
- **V**

(Choi
abdom
and ev
hernia
vitellin

(Choice B) Malrotation results from failure of the midgut to rotate normally while it returns to the abdominal cavity during early fetal development. Patients have abnormal positioning of the intestine in the abdominal cavity and sometimes twisting of an intestinal loop (volvulus).

https://t.me/USMLEWorldStep1

Vitelline sinus

Vitelline duct cyst (enterocyst)

Exhibit Display

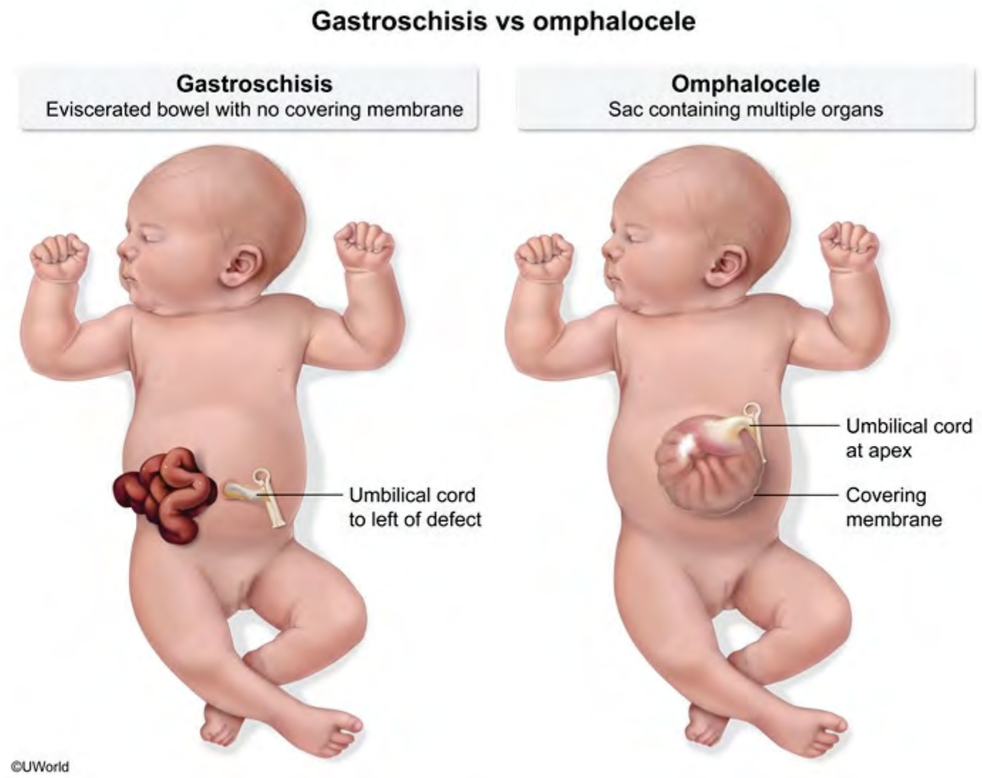

Zoom In Zoom Out Reset New | Existing My Notebook

This p
incom
midgu
the inc

Incom

- **P**
  b
  b
- **M**
  d
  th
  g
- **V**
  u
- **V**
  c

(Choi
abdom
and ev
hernia
vitellin

(Choi
during early fetal development. Patients have abnormal positioning of the intestine in the abdominal cavity and sometimes twisting of an intestinal loop (volvulus).

https://t.me/USMLEWorldStep1

Vitelline sinus

Vitelline duct cyst (enterocyst)

Exhibit Display

Umbilical hernia

Zoom In | Zoom Out | Reset | New | Existing | My Notebook

This p
incom
midgu
the inc

Incom

- **P**
  b
  b
- **M**
  d
  th
  g
- **V**
  u
- **V**
  c

(Choi
abdom
and ev
hernia
vitellin

(Choi
during early fetal development. Patients have abnormal positioning of the intestine in the abdominal cavity and sometimes twisting of an intestinal loop (volvulus).

https://t.me/USMLEWorldStep1

incomplete obliteration of the vitelline (omphalomesenteric) duct. Normally, the vitelline duct connects the midgu
the inc

Incom

- **P**
  b
  b
- **M**
  d
  th
  g
- **V**
  u
- **V**
  c

(Choi
abdom
and ev
hernia
vitellin

(Choi
during
somet

Exhibit Display

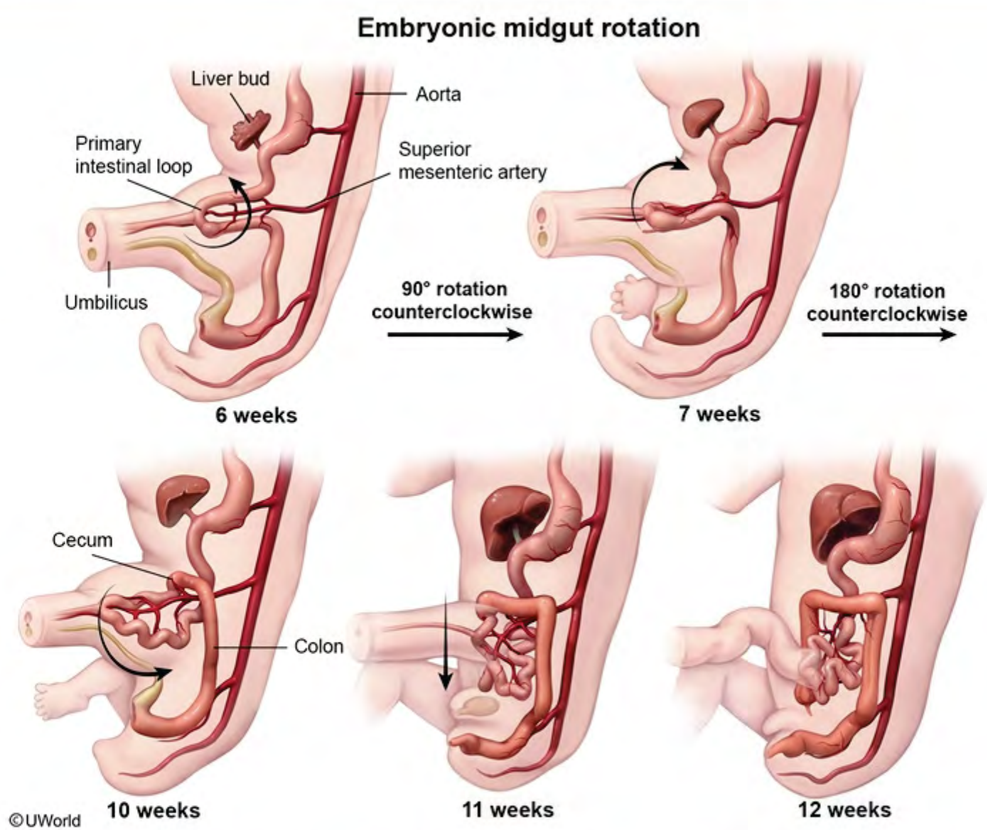

Zoom In | Zoom Out | Reset | New | Existing | My Notebook

(Choice E) A patent urachus results from failure of the allantois (urachus) to obliterate and presents with urine drainage through the umbilicus. This anomaly is associated with a urachal cyst, which is connected by a fibrous band to the bladder (not the ileum) and umbilicus.

https://t.me/USMLEWorldStep1

incomplete obliteration of the vitelline (omphalomesenteric) duct. Normally, the vitelline duct connects the midgu
the inc

Incom

- **P**
  b
  b
- **M**
  d
  th
  g
- **V**
  u
- **V**
  c

(Choi
abdom
and ev
hernia
vitellin

(Choi
during
somet

(Choi
drainage through the umbilicus. This anomaly is associated with a urachal cyst, which is connected by a fibrous band to the bladder (not the ileum) and umbilicus.

Exhibit Display

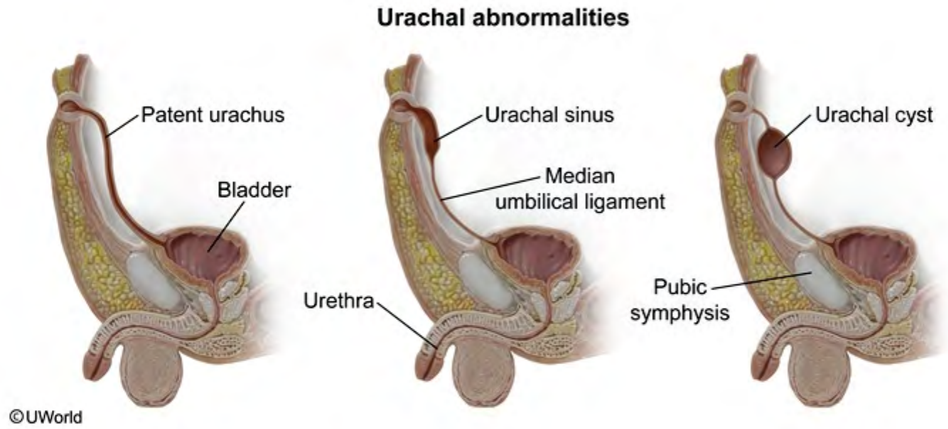

Zoom In Zoom Out Reset New | Existing My Notebook

https://t.me/USMLEWorldStep1

A 52-year-old postmenopausal woman comes to the office for evaluation of several months of episodic abdominal discomfort and nausea, especially after a fatty meal. She has no past medical history and does not use tobacco, alcohol, or illicit drugs. Her BMI is 33 kg/m^2. Physical examination shows a soft, nontender abdomen with normal bowel sounds. Liver span is 8 cm. Murphy sign is negative. Abdominal x-ray reveals no calcifications, but abdominal ultrasound shows a small, non-obstructing gallstone. The patient prefers nonoperative management. Which of the following would best treat this patient's condition?

- A. Bile acid supplement
- B. Cholestyramine therapy
- C. Estrogen replacement therapy
- D. Fenofibrate therapy
- E. Iron chelation therapy
- F. Phosphate-binding agent
- G. Rapid weight loss

Submit

https://t.me/USMLEWorldStep1

A 52-year-old postmenopausal woman comes to the office for evaluation of several months of episodic abdominal discomfort and nausea, especially after a fatty meal. She has no past medical history and does not use tobacco, alcohol, or illicit drugs. Her BMI is 33 kg/m^2. Physical examination shows a soft, nontender abdomen with normal bowel sounds. Liver span is 8 cm. Murphy sign is negative. Abdominal x-ray reveals no calcifications, but abdominal ultrasound shows a small, non-obstructing gallstone. The patient prefers nonoperative management. Which of the following would best treat this patient's condition?

- ✓ A. Bile acid supplement (46%)
- ✗ B. Cholestyramine therapy (31%)
- C. Estrogen replacement therapy (2%)
- D. Fenofibrate therapy (8%)
- E. Iron chelation therapy (0%)
- F. Phosphate-binding agent (4%)
- G. Rapid weight loss (5%)

Incorrect
Correct answer
A

46%
Answered correctly

03 secs
Time Spent

2023
Version

Explanation

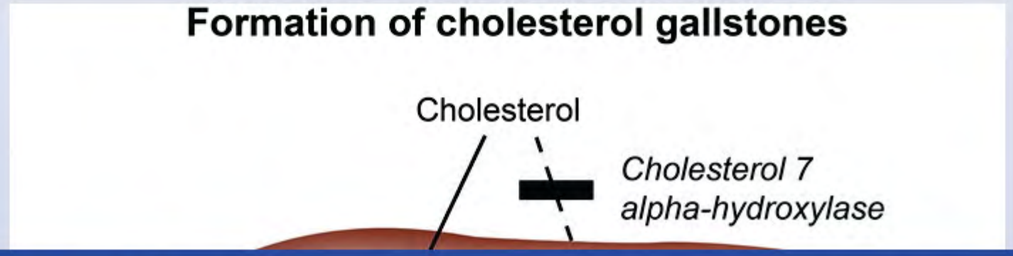

https://t.me/USMLEWorldStep1

A 52-year-old postmenopausal woman comes to the office for evaluation of several months of episodic abdominal
discon
alcoho
bowel
abdom
Which

Inco
Corre
A

Expl

Exhibit Display

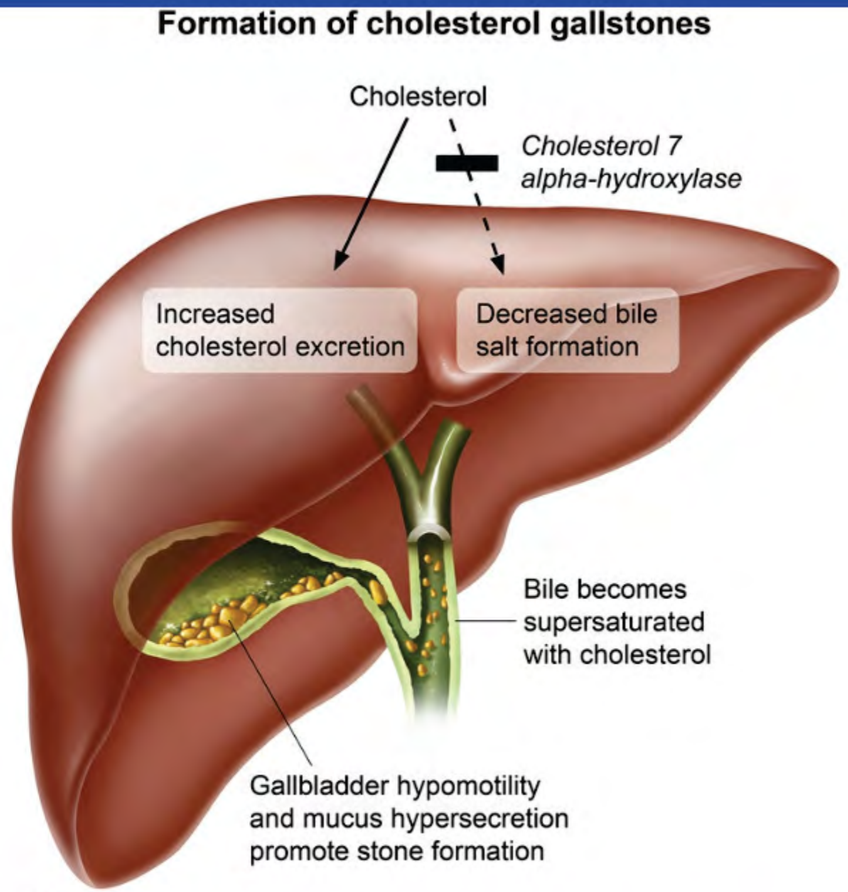

Zoom In | Zoom Out | Reset | New | Existing | My Notebook

https://t.me/USMLEWorldStep1

©UWorld

Cholesterol gallstones are the most common type of gallstone. They are primarily composed of cholesterol monohydrate crystals but can contain variable amounts of calcium salts, bilirubin, and mucin. Normally, bile acids and phospholipids solubilize the cholesterol to prevent stone formation. Decreased amounts of bile acids and phospholipids can cause the bile to become supersaturated with cholesterol, allowing it to crystallize and form cholesterol gallstones. Risk factors for stone formation include increasing age, obesity, excessive bile salt loss (eg, terminal ileum disease), and female sex.

Cholecystectomy is the preferred treatment for symptomatic gallstones. However, medical therapy is an option in patients refusing surgery or with high surgical risk. Administration of **hydrophilic bile acids** (eg, ursodeoxycholic acid) reduces cholesterol secretion and increases biliary bile acid concentration. This improves cholesterol solubility and **promotes gallstone dissolution**. Although the response to medical therapy is good in patients with mild symptoms and small stones, there is a high rate of gallstone recurrence.

(Choice B) Bile acid sequestrants (eg, cholestyramine) decrease enterohepatic recirculation of bile acids (increase gallstone risk). However, they also stimulate the conversion of cholesterol to bile acids and increase biliary motility (decrease gallstone risk). The net result is no significant change in the risk of gallstones.

(Choice C) Estrogen increases cholesterol secretion and progesterone reduces bile acid secretion, ultimately causing bile to become supersaturated with cholesterol. Progesterone also slows gallbladder emptying, which causes bile stasis and further promotes gallstone formation.

(Choice D) Fibrates increase cholesterol content in bile, which increases the risk of gallstones.

(Choice E) Iron chelation therapy is used to treat iron overload syndromes but has no significant effect on gallstones.

(Choice F) Phosphate-binding agents can lower serum phosphate in chronic kidney disease and dialysis patients but do not significantly affect gallstones.

(Choice G) Very low-calorie diets with decreased caloric intake and rapid weight loss can lead to bile stasis and increased cholesterol mobilization, increasing the risk of gallstone formation.

https://t.me/USMLEWorldStep1

cholesterol gallstones. Risk factors for stone formation include increasing age, obesity, excessive bile salt loss (eg, terminal ileum disease), and female sex.

Cholecystectomy is the preferred treatment for symptomatic gallstones. However, medical therapy is an option in patients refusing surgery or with high surgical risk. Administration of **hydrophilic bile acids** (eg, ursodeoxycholic acid) reduces cholesterol secretion and increases biliary bile acid concentration. This improves cholesterol solubility and **promotes gallstone dissolution**. Although the response to medical therapy is good in patients with mild symptoms and small stones, there is a high rate of gallstone recurrence.

(Choice B) Bile acid sequestrants (eg, cholestyramine) decrease enterohepatic recirculation of bile acids (increase gallstone risk). However, they also stimulate the conversion of cholesterol to bile acids and increase biliary motility (decrease gallstone risk). The net result is no significant change in the risk of gallstones.

(Choice C) Estrogen increases cholesterol secretion and progesterone reduces bile acid secretion, ultimately causing bile to become supersaturated with cholesterol. Progesterone also slows gallbladder emptying, which causes bile stasis and further promotes gallstone formation.

(Choice D) Fibrates increase cholesterol content in bile, which increases the risk of gallstones.

(Choice E) Iron chelation therapy is used to treat iron overload syndromes but has no significant effect on gallstones.

(Choice F) Phosphate-binding agents can lower serum phosphate in chronic kidney disease and dialysis patients but do not significantly affect gallstones.

(Choice G) Very low-calorie diets with decreased caloric intake and rapid weight loss can lead to bile stasis and increased cholesterol mobilization, increasing the risk of gallstone formation.

Educational objective:
Medical therapy to dissolve cholesterol gallstones is an option in patients refusing cholecystectomy or with high surgical risk. Hydrophilic bile acids (eg, ursodeoxycholic acid) improve cholesterol solubility by reducing the amount of cholesterol secreted into the bile and increasing biliary bile acid concentration.

References

- Targets for current pharmacologic therapy in cholesterol gallstone disease.

https://t.me/USMLEWorldStep1

Many drugs and toxins act by inhibiting substance flow across cell membranes. Which of the following inhibits primary active transport?

- A. Tetrodotoxin
- B. Verapamil
- C. Omeprazole
- D. Lidocaine
- E. Dofetilide

Submit

https://t.me/USMLEWorldStep1

Many drugs and toxins act by inhibiting substance flow across cell membranes. Which of the following inhibits primary active transport?

- A. Tetrodotoxin (12%)
- ✗ B. Verapamil (5%)
- ✓ C. Omeprazole (70%)
- D. Lidocaine (7%)
- E. Dofetilide (3%)

Incorrect
Correct answer
C

70%
Answered correctly

03 secs
Time Spent

2023
Version

Explanation

Transport of ions or molecules across cell membranes can be either passive (along the concentration gradient) or active (against the concentration gradient). The former does not require energy, while the latter utilizes energy from ATP. In primary active transport, the carrier molecules are enzymes that hydrolyze ATP (ATPases) and use the energy released to transport ions and molecules against their concentration gradients. Examples of such carriers are the Na/K ATPase, the H/K ATPase, and the Ca ATPase.

Synthesis of HCl by parietal cells of the gastric mucosa is dependent on the H/K ATPase, which is known as a proton pump. This carrier transports hydrogen ions into the gastric lumen in exchange for potassium ions.

Omeprazole and other proton pump inhibitors inhibit the H/K ATPase, thus decreasing the concentration of HCl in the gastric lumen. These medications are used for treatment of peptic ulcer disease, gastroesophageal reflux disease (GERD), and diseases associated with increased gastrin secretion such as the Zollinger-Ellison syndrome.

(Choice A) Tetrodotoxin, a potent neurotoxin found in pufferfish, functions by blocking the voltage-gated sodium channels in nerve cell membranes. It inhibits passive transport of sodium

https://t.me/USMLEWorldStep1

Explanation

Transport of ions or molecules across cell membranes can be either passive (along the concentration gradient) or active (against the concentration gradient). The former does not require energy, while the latter utilizes energy from ATP. In primary active transport, the carrier molecules are enzymes that hydrolyze ATP (ATPases) and use the energy released to transport ions and molecules against their concentration gradients. Examples of such carriers are the Na/K ATPase, the H/K ATPase, and the Ca ATPase.

Synthesis of HCl by parietal cells of the gastric mucosa is dependent on the H/K ATPase, which is known as a proton pump. This carrier transports hydrogen ions into the gastric lumen in exchange for potassium ions.

Omeprazole and other proton pump inhibitors inhibit the H/K ATPase, thus decreasing the concentration of HCl in the gastric lumen. These medications are used for treatment of peptic ulcer disease, gastroesophageal reflux disease (GERD), and diseases associated with increased gastrin secretion such as the Zollinger-Ellison syndrome.

(Choice A) Tetrodotoxin, a potent neurotoxin found in pufferfish, functions by blocking the voltage-gated sodium channels in nerve cell membranes. It inhibits passive transport of sodium.

(Choice B) Verapamil blocks L-type calcium channels, thus inhibiting passive transport of calcium ions in cardiomyocytes.

(Choice D) Lidocaine is a local anesthetic and a class IB antiarrhythmic agent that functions by blocking voltage-gated sodium channels in sensory neurons, Purkinje fibers and ventricular cells.

(Choice E) Dofetilide is a class III antiarrhythmic drug that blocks passive transport of potassium, specifically the delayed outward rectifier potassium current, in cardiomyocytes leading to a prolongation of the refractory period and of the QT interval.

Educational Objective:
Parietal cells release hydrogen ions into the gastric lumen by means of the H/K ATPase, which requires hydrolysis of ATP and is therefore an active transport mechanism. Omeprazole and other proton pump inhibitors suppress the activity of the gastric parietal cell H/K ATPase leading to an increase in the pH of the gastric lumen.

https://t.me/USMLEWorldStep1

A 26-year-old woman with anorexia nervosa is admitted to an eating disorder center for monitored refeeding and weight restoration. The patient reports a history of upper abdominal pain after eating and a frequent need to vomit to relieve symptoms. Blood pressure is 90/60 mm Hg and pulse is 50/min. BMI is 14.8 kg/m^2. On physical examination, the patient is cachectic with a sunken, nontender abdomen. A progressively increasing oral refeeding plan is prescribed. On the fourth day, the patient experiences severe abdominal pain, nausea, and vomiting after a meal. CT scan of the abdomen with oral contrast reveals a marked lack of intraabdominal fat, a significantly dilated stomach, and an abrupt cutoff of oral contrast at the third segment of the duodenum. Compression by which of the following structures is most likely causing this patient's gastrointestinal symptoms?

- A. Celiac artery
- B. Head of the pancreas
- C. Hepatoduodenal ligament
- D. Left renal vein
- E. Superior mesenteric artery

Submit

https://t.me/USMLEWorldStep1

A 26-year-old woman with anorexia nervosa is admitted to an eating disorder center for monitored refeeding and weight restoration. The patient reports a history of upper abdominal pain after eating and a frequent need to vomit to relieve symptoms. Blood pressure is 90/60 mm Hg and pulse is 50/min. BMI is 14.8 kg/m^2. On physical examination, the patient is cachectic with a sunken, nontender abdomen. A progressively increasing oral refeeding plan is prescribed. On the fourth day, the patient experiences severe abdominal pain, nausea, and vomiting after a meal. CT scan of the abdomen with oral contrast reveals a marked lack of intraabdominal fat, a significantly dilated stomach, and an abrupt cutoff of oral contrast at the third segment of the duodenum. Compression by which of the following structures is most likely causing this patient's gastrointestinal symptoms?

- A. Celiac artery (3%)
- B. Head of the pancreas (13%)
- ✗ C. Hepatoduodenal ligament (6%)
- D. Left renal vein (1%)
- ✓ E. Superior mesenteric artery (75%)

Incorrect
Correct answer
E

75%
Answered correctly

03 secs
Time Spent

2023
Version

Explanation

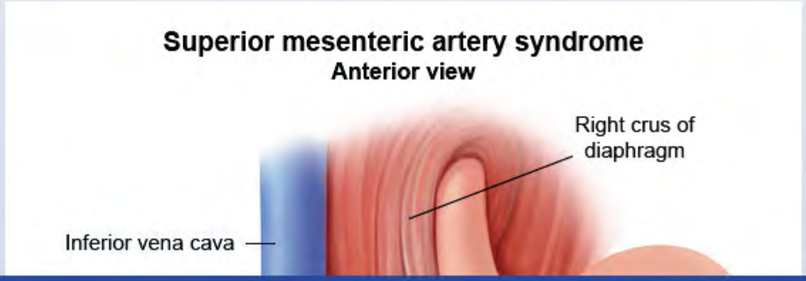

https://t.me/USMLEWorldStep1

Incorrect
Correct answer
E

75%
03 secs
2023

Exhibit Display

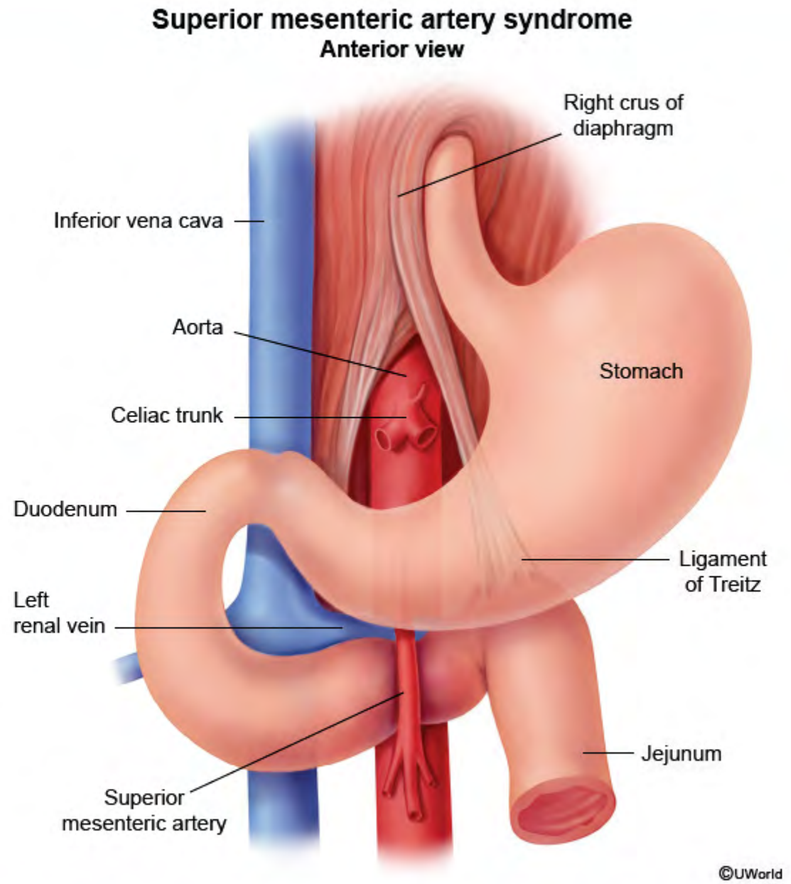

Zoom In | Zoom Out | Reset | New | Existing | My Notebook

This patient with a history of anorexia nervosa and a CT scan revealing obstruction of the **third (transverse)**

https://t.me/USMLEWorldStep1

This patient with a history of anorexia nervosa and a CT scan revealing obstruction of the **third (transverse) duodenal segment** has symptoms of **small bowel obstruction**. The duodenum represents the first third of the small intestine, coursing around the abdomen in the following manner:

- The superior segment extends rightward from the stomach intraperitoneally and is anchored to the liver by the hepatoduodenal ligament **(Choice C)**.
- The descending segment descends retroperitoneally (as with subsequent parts) and is connected to the adjacent head of the pancreas through a coalescence of hepatobiliary and pancreatic secretory ducts **(Choice B)**.
- The transverse segment extends leftward along the superiorly positioned left renal vein, both crossing through a **mesenteric fat pad** that separates the superior mesenteric artery from the abdominal aorta.
- The ascending segment ascends anteriorly into the intraperitoneal jejunum.

In states of extreme weight loss (eg, **severe anorexia nervosa**) and/or hypercatabolism (eg, refeeding hypermetabolism), **mesenteric fat is depleted**. This collapses the angle between the superior mesenteric artery (SMA) and aorta (aortomesenteric angle), allowing the SMA to impinge on intervening structures. This may result in partial to complete compression of the duodenum (ie, **superior mesenteric artery syndrome**), presenting with the obstructive symptoms found in this patient (eg, postprandial abdominal pain, emesis).

(Choice A) In contrast to the SMA, which emerges from the aorta at the level of the L1 vertebra, the celiac artery arises at the level between the T12-L1 vertebrae and does not course near the duodenum. Rarely, celiac artery aneurysms may erode into the gastric antrum.

(Choice D) Collapse of the SMA fat pad can also compress the left renal vein given its anatomic proximity to the origin of the aortomesenteric angle. In contrast to the manifestations of SMA syndrome, symptomatic occlusion of the left renal vein (nutcracker syndrome) manifests with left-sided flank pain and hematuria.

Educational objective:
Abdominal structures are susceptible to mass effect when supportive elements (eg, mesenteric fat) are depleted. Loss of mesenteric fat (eg, anorexia nervosa) allows the superior mesenteric artery to compress the transverse

https://t.me/USMLEWorldStep1

- The superior segment extends rightward from the stomach intraperitoneally and is anchored to the liver by the hepatoduodenal ligament **(Choice C)**.
- The descending segment descends retroperitoneally (as with subsequent parts) and is connected to the adjacent head of the pancreas through a coalescence of hepatobiliary and pancreatic secretory ducts **(Choice B)**.
- The transverse segment extends leftward along the superiorly positioned left renal vein, both crossing through a **mesenteric fat pad** that separates the superior mesenteric artery from the abdominal aorta.
- The ascending segment ascends anteriorly into the intraperitoneal jejunum.

In states of extreme weight loss (eg, **severe anorexia nervosa**) and/or hypercatabolism (eg, refeeding hypermetabolism), **mesenteric fat is depleted**. This collapses the angle between the superior mesenteric artery (SMA) and aorta (aortomesenteric angle), allowing the SMA to impinge on intervening structures. This may result in partial to complete compression of the duodenum (ie, **superior mesenteric artery syndrome**), presenting with the obstructive symptoms found in this patient (eg, postprandial abdominal pain, emesis).

(Choice A) In contrast to the SMA, which emerges from the aorta at the level of the L1 vertebra, the celiac artery arises at the level between the T12-L1 vertebrae and does not course near the duodenum. Rarely, celiac artery aneurysms may erode into the gastric antrum.

(Choice D) Collapse of the SMA fat pad can also compress the left renal vein given its anatomic proximity to the origin of the aortomesenteric angle. In contrast to the manifestations of SMA syndrome, symptomatic occlusion of the left renal vein (nutcracker syndrome) manifests with left-sided flank pain and hematuria.

Educational objective:
Abdominal structures are susceptible to mass effect when supportive elements (eg, mesenteric fat) are depleted. Loss of mesenteric fat (eg, anorexia nervosa) allows the superior mesenteric artery to compress the transverse segment of the duodenum, resulting in small bowel obstruction (ie, superior mesenteric artery syndrome).

Anatomy	Gastrointestinal & Nutrition	Bowel obstruction
Subject	System	Topic

https://t.me/USMLEWorldStep1

- The superior segment extends rightward from the stomach intraperitoneally and is anchored to the liver by the h
- T a **B**
- T a
- T

In stat hyperr (SMA) in part the ob

(Choi arises aneury

(Choi origin the lef

Educa Abdon Loss c segme

Exhibit Display

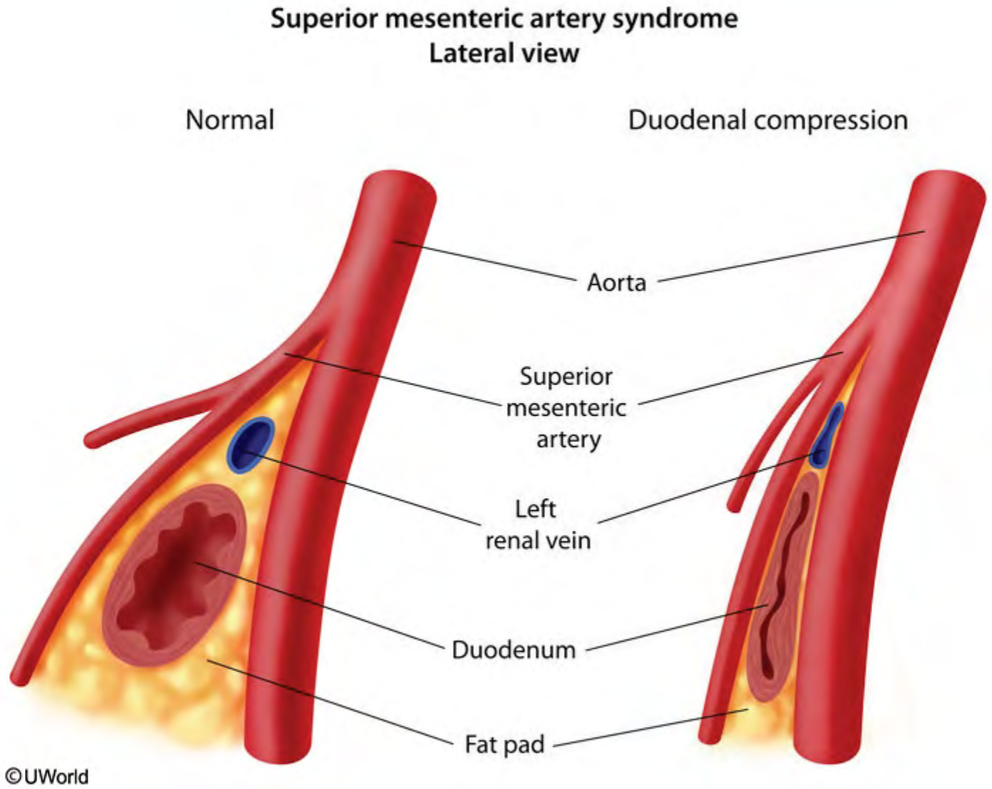

Zoom In | Zoom Out | Reset | New | Existing | My Notebook

Anatomy (Subject) | Gastrointestinal & Nutrition (System) | Bowel obstruction (Topic)

https://t.me/USMLEWorldStep1

A 54-year-old man comes to the emergency department after vomiting blood. He has also had melena, fatigue, and lethargy over the last 24 hours. The patient emigrated from sub-Saharan Africa 20 years ago and occasionally returns to visit friends and family. Temperature is 37.5 C (99.5 F), blood pressure is 90/60 mm Hg, and pulse is 115/min. Abdominal palpation reveals an enlarged liver and a spleen tip below the level of the umbilicus. Laboratory results are as follows:

Complete blood count

Hemoglobin	5.2 g/dL
Platelets	75,000/mm^3
Leukocytes	8,000/mm^3
Neutrophils	79%
Eosinophils	15%
Lymphocytes	6%

Upper endoscopy reveals bleeding esophageal varices. Which of the following is the most likely underlying cause of this patient's symptoms?

- A. Cysticercosis
- B. Hookworm infection
- C. Malaria
- D. Schistosomiasis
- E. Toxoplasmosis

Submit

https://t.me/USMLEWorldStep1

A 54-year-old man comes to the emergency department after vomiting blood. He has also had melena, fatigue, and lethargy over the last 24 hours. The patient emigrated from sub-Saharan Africa 20 years ago and occasionally returns to visit friends and family. Temperature is 37.5 C (99.5 F), blood pressure is 90/60 mm Hg, and pulse is 115/min. Abdominal palpation reveals an enlarged liver and a spleen tip below the level of the umbilicus. Laboratory results are as follows:

Complete blood count

Hemoglobin	5.2 g/dL
Platelets	75,000/mm^3
Leukocytes	8,000/mm^3
Neutrophils	79%
Eosinophils	15%
Lymphocytes	6%

Upper endoscopy reveals bleeding esophageal varices. Which of the following is the most likely underlying cause of this patient's symptoms?

- ✗ A. Cysticercosis (5%)
- B. Hookworm infection (12%)
- C. Malaria (18%)
- ✓ D. Schistosomiasis (62%)
- E. Toxoplasmosis (0%)

Incorrect
Correct answer
D

62%
Answered correctly

04 secs
Time Spent

2023
Version

https://t.me/USMLEWorldStep1

Schistosomiasis		
***Schistosoma* species**	**Location**	**Symptoms**
S haematobium	• North Africa • Sub-Saharan Africa • Middle East	**Urinary schistosomiasis** • Terminal hematuria, dysuria & frequent urination • Hydronephrosis, pyelonephritis & squamous cell carcinoma of the bladder
S mansoni	• Sub-Saharan Africa • Middle East • South America • Caribbean	**Intestinal schistosomiasis** • Diarrhea & abdominal pain • Intestinal ulceration → iron deficiency anemia **Hepatic schistosomiasis** • Hepatomegaly, splenomegaly • Periportal fibrosis & subsequent portal hypertension
S japonicum	• Asia, particularly China • Philippines • Japan	

Esophageal varices and splenomegaly are signs of **portal hypertension**, which usually indicates underlying hepatic fibrosis. Although chronic viral hepatitis and alcohol abuse are the leading causes of hepatic fibrosis in the United States, this patient's immigration/travel history and eosinophilia raise suspicion for **hepatosplenic schistosomiasis**, a parasitic blood fluke infection seen primarily in rural parts of **sub-Saharan Africa** and East Asia.

Exposure to *Schistosoma* occurs when humans swim in freshwater contaminated by infected snails (the intermediate host). Cercariae penetrate human skin and migrate to the liver, where they mature to adult worms. Adult worms then spread through the **portal circulation** to the mesenteric venules or venous plexus of the bladder. Here, they release eggs into host tissue that are excreted in the feces or urine.

https://t.me/USMLEWorldStep1

	• Caribbean	• Intestinal ulceration → iron deficiency anemia
S japonicum	• Asia, particularly China • Philippines • Japan	**Hepatic schistosomiasis** • Hepatomegaly, splenomegaly • Periportal fibrosis & subsequent portal hypertension

Esophageal varices and splenomegaly are signs of **portal hypertension**, which usually indicates underlying hepatic fibrosis. Although chronic viral hepatitis and alcohol abuse are the leading causes of hepatic fibrosis in the United States, this patient's immigration/travel history and eosinophilia raise suspicion for **hepatosplenic schistosomiasis**, a parasitic blood fluke infection seen primarily in rural parts of **sub-Saharan Africa** and East Asia.

Exposure to *Schistosoma* occurs when humans swim in freshwater contaminated by infected snails (the intermediate host). Cercariae penetrate human skin and migrate to the liver, where they mature to adult worms. Adult worms then spread through the **portal circulation** to the mesenteric venules or venous plexus of the bladder. Here, they release eggs into host tissue that are excreted in the feces or urine.

Although many patients with schistosomiasis are asymptomatic, chronic exposure to *Schistosoma* eggs can activate hepatic stellate cells, leading to collagen deposition in periportal spaces and progressive **periportal fibrosis**. Occlusion of periportal veins eventually blocks venous outflow from abdominal organs, leading to **congestive splenomegaly** and **gastroesophageal varices**. Patients frequently have anemia from intestinal/variceal bleeding, thrombocytopenia from splenic trapping of platelets, and **eosinophilia** in response to adult worms.

(Choice A) Cysticercosis is caused by ingestion of *Taenia solium* eggs from contaminated pork. Although initial infections are usually asymptomatic, patients may develop seizures years or decades later due to calcified granulomas at the site of previous brain infection. Muscle and subcutaneous tissue can also be involved, but the liver and hepatic venous system is generally not affected.

(Choice B) Hookworm infection is a common cause of chronic, iron-deficiency anemia and eosinophilia, but this organism does not invade the liver or portal venous system; therefore, gastric varices and hepatosplenomegaly would be atypical.

https://t.me/USMLEWorldStep1

bladder. Here, they release eggs into host tissue that are excreted in the feces or urine.

Although many patients with schistosomiasis are asymptomatic, chronic exposure to *Schistosoma* eggs can activate hepatic stellate cells, leading to collagen deposition in periportal spaces and progressive **periportal fibrosis**. Occlusion of periportal veins eventually blocks venous outflow from abdominal organs, leading to **congestive splenomegaly** and **gastroesophageal varices**. Patients frequently have anemia from intestinal/variceal bleeding, thrombocytopenia from splenic trapping of platelets, and **eosinophilia** in response to adult worms.

(Choice A) Cysticercosis is caused by ingestion of *Taenia solium* eggs from contaminated pork. Although initial infections are usually asymptomatic, patients may develop seizures years or decades later due to calcified granulomas at the site of previous brain infection. Muscle and subcutaneous tissue can also be involved, but the liver and hepatic venous system is generally not affected.

(Choice B) Hookworm infection is a common cause of chronic, iron-deficiency anemia and eosinophilia, but this organism does not invade the liver or portal venous system; therefore, gastric varices and hepatosplenomegaly would be atypical.

(Choice C) Malaria is common in patients who return to endemic areas (eg, sub-Saharan Africa) after being away (due to waning partial immunity). Although hepatosplenomegaly and anemia are common, most patients are acutely ill (eg, fever, chills, malaise), and portal hypertension and eosinophilia are generally not present.

(Choice E) Toxoplasmosis is most common in patients with AIDS. It usually presents with meningoencephalitis (eg, confusion, headache, vomiting). Upper gastrointestinal bleeding from esophageal varices and eosinophilia would be atypical.

Educational objective:
Schistosomiasis, a parasitic blood fluke infection, is common in rural portions of sub-Saharan Africa. Initial infection is often asymptomatic, but some patients develop chronic hepatosplenic (eg, portal hypertension, hepatosplenomegaly, esophageal varices) or urinary (eg, bladder cancer) complications years or decades later. The presence of eosinophilia is an important diagnostic clue.

Microbiology Gastrointestinal & Nutrition Schistosomiasis

https://t.me/USMLEWorldStep1

A 3-day-old boy is brought to the emergency department due to poor feeding, emesis, and lethargy over the past 24 hours. He was born via uncomplicated spontaneous vaginal delivery to a 30-year-old woman who had a normal pregnancy. The boy was discharged from the newborn nursery yesterday and was breastfeeding exclusively until the onset of symptoms. Stool and urine output were normal while he was in the hospital. The patient is afebrile and normotensive but tachycardic and tachypneic. He appears dehydrated, and the abdomen is distended. The patient vomits during the examination; the vomitus is shown in the exhibit. On laparotomy, fibrous bands are seen extending from the cecum and right colon to the retroperitoneum, causing extrinsic compression of the duodenum. Which of the following embryologic processes most likely failed in this patient?

- A. Fusion of the ventral and dorsal pancreatic buds
- B. Midgut rotation and intestinal fixation
- C. Neural crest cell migration into the bowel wall
- D. Obliteration of the omphalomesenteric duct
- E. Recanalization of the intestines

Submit

https://t.me/USMLEWorldStep1

A 3-day-old boy is brought to the emergency department due to poor feeding, emesis, and lethargy over the past
24 hou
pregna
the on
and no
patien
extenc
Which

Sub

Exhibit Display



Zoom In Zoom Out Reset New | Existing My Notebook

https://t.me/USMLEWorldStep1

A 3-day-old boy is brought to the emergency department due to poor feeding, emesis, and lethargy over the past 24 hours. He was born via uncomplicated spontaneous vaginal delivery to a 30-year-old woman who had a normal pregnancy. The boy was discharged from the newborn nursery yesterday and was breastfeeding exclusively until the onset of symptoms. Stool and urine output were normal while he was in the hospital. The patient is afebrile and normotensive but tachycardic and tachypneic. He appears dehydrated, and the abdomen is distended. The patient vomits during the examination; the vomitus is shown in the exhibit. On laparotomy, fibrous bands are seen extending from the cecum and right colon to the retroperitoneum, causing extrinsic compression of the duodenum. Which of the following embryologic processes most likely failed in this patient?

- A. Fusion of the ventral and dorsal pancreatic buds (7%)
- ✓ B. Midgut rotation and intestinal fixation (63%)
- C. Neural crest cell migration into the bowel wall (3%)
- D. Obliteration of the omphalomesenteric duct (14%)
- E. Recanalization of the intestines (10%)

Correct

63% Answered correctly

30 secs Time Spent

2023 Version

Explanation

https://t.me/USMLEWorldStep1

B. Midgut rotation and intestinal fixation (63%)

Exhibit Display

Midgut malrotation

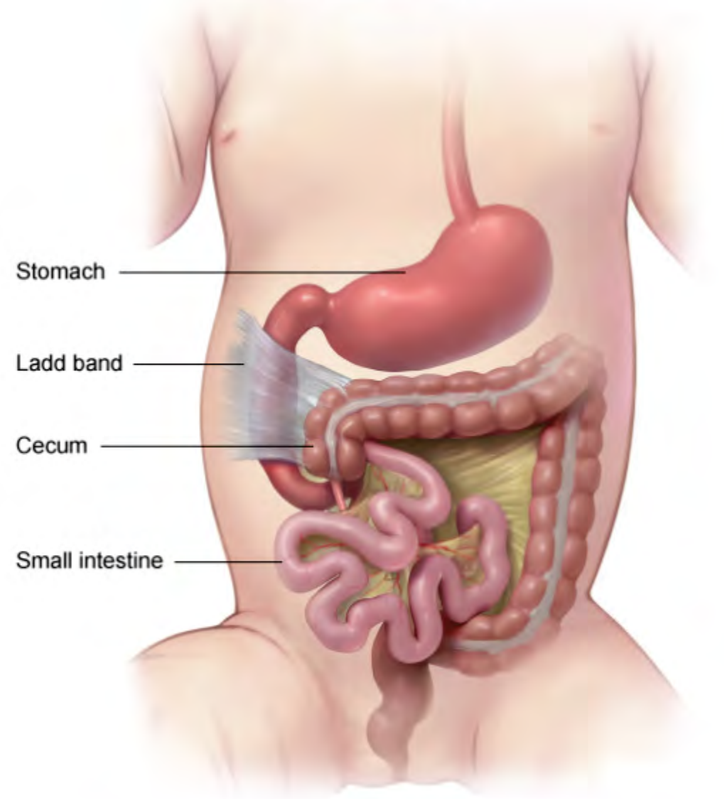

©UWorld

Zoom In | Zoom Out | Reset | New | Existing | My Notebook

https://t.me/USMLEWorldStep1

At 4-8 weeks gestation, the midgut (supplied by the superior mesenteric artery) herniates through the umbilical ring while undergoing rapid growth that the embryonic abdominal cavity cannot accommodate. During this process, the midgut rotates 90 degrees counterclockwise. The midgut returns to the abdominal cavity at 8-10 weeks gestation and turns an additional 180 degrees (**270 degrees counterclockwise** total). The intestines are then fixed to the parietal peritoneum of the posterior abdominal wall on a wide-based mesentery (extending from the duodenojejunal flexure in the left upper quadrant to the cecum in the right lower quadrant).

Incomplete rotation results in **midgut malrotation**. In these patients, the duodenojejunal flexure and cecum both rest in the right upper quadrant, and **fibrous (Ladd) bands** connect the cecum to the retroperitoneum by passing over the second part of the duodenum. These bands of tissue can **compress the duodenum**, leading to symptoms of **intestinal obstruction** in the newborn, as seen in this patient with bilious emesis and abdominal distension.

Midgut malrotation also results in a narrow mesenteric base that is vulnerable to twisting around the superior mesenteric artery, resulting in midgut volvulus. Volvulus, which can also cause bilious emesis in the newborn period, may compromise intestinal perfusion and lead to life-threatening bowel ischemia and necrosis.

(Choice A) Failure of ventral and dorsal pancreatic bud fusion results in pancreas divisum. This condition is usually asymptomatic and an incidental finding on imaging or autopsy.

(Choice C) Failure of neural crest cell migration causes Hirschsprung disease. The aganglionic colon segment cannot relax and is therefore narrow and obstructive. Neonates with this abnormality can develop bilious emesis, but delayed passage of meconium is typical (not seen here). In addition, this patient has fibrous bands compressing the duodenum, a finding inconsistent with the diagnosis of Hirschsprung disease.

(Choice D) The omphalomesenteric duct connects the midgut lumen with the yolk sac. Failed obliteration of the duct can lead to Meckel diverticulum, which most commonly presents with painless lower gastrointestinal bleeding. Emesis is not typical, and Ladd bands would not be seen.

(Choice E) Failure of gut recanalization describes duodenal atresia. Although patients with duodenal atresia may present with bilious emesis in the neonatal period, Ladd bands would not be present.

Educational objective:

https://t.me/USMLEWorldStep1

Incomplete rotation results in **midgut malrotation**. In these patients, the duodenojejunal flexure and cecum both rest in the right upper quadrant, and **fibrous (Ladd) bands** connect the cecum to the retroperitoneum by passing over the second part of the duodenum. These bands of tissue can **compress the duodenum**, leading to symptoms of **intestinal obstruction** in the newborn, as seen in this patient with bilious emesis and abdominal distension.

Midgut malrotation also results in a narrow mesenteric base that is vulnerable to twisting around the superior mesenteric artery, resulting in midgut volvulus. Volvulus, which can also cause bilious emesis in the newborn period, may compromise intestinal perfusion and lead to life-threatening bowel ischemia and necrosis.

(Choice A) Failure of ventral and dorsal pancreatic bud fusion results in pancreas divisum. This condition is usually asymptomatic and an incidental finding on imaging or autopsy.

(Choice C) Failure of neural crest cell migration causes Hirschsprung disease. The aganglionic colon segment cannot relax and is therefore narrow and obstructive. Neonates with this abnormality can develop bilious emesis, but delayed passage of meconium is typical (not seen here). In addition, this patient has fibrous bands compressing the duodenum, a finding inconsistent with the diagnosis of Hirschsprung disease.

(Choice D) The omphalomesenteric duct connects the midgut lumen with the yolk sac. Failed obliteration of the duct can lead to Meckel diverticulum, which most commonly presents with painless lower gastrointestinal bleeding. Emesis is not typical, and Ladd bands would not be seen.

(Choice E) Failure of gut recanalization describes duodenal atresia. Although patients with duodenal atresia may present with bilious emesis in the neonatal period, Ladd bands would not be present.

Educational objective:
Intestinal malrotation occurs when the midgut undergoes incomplete counterclockwise rotation during embryologic development. It often presents in the neonatal period with bilious emesis due to extrinsic duodenal compression by Ladd bands or due to midgut volvulus with intestinal ischemia.

Embryology	Gastrointestinal & Nutrition	Intestinal malrotation
Subject	System	Topic

https://t.me/USMLEWorldStep1

Exhibit Display

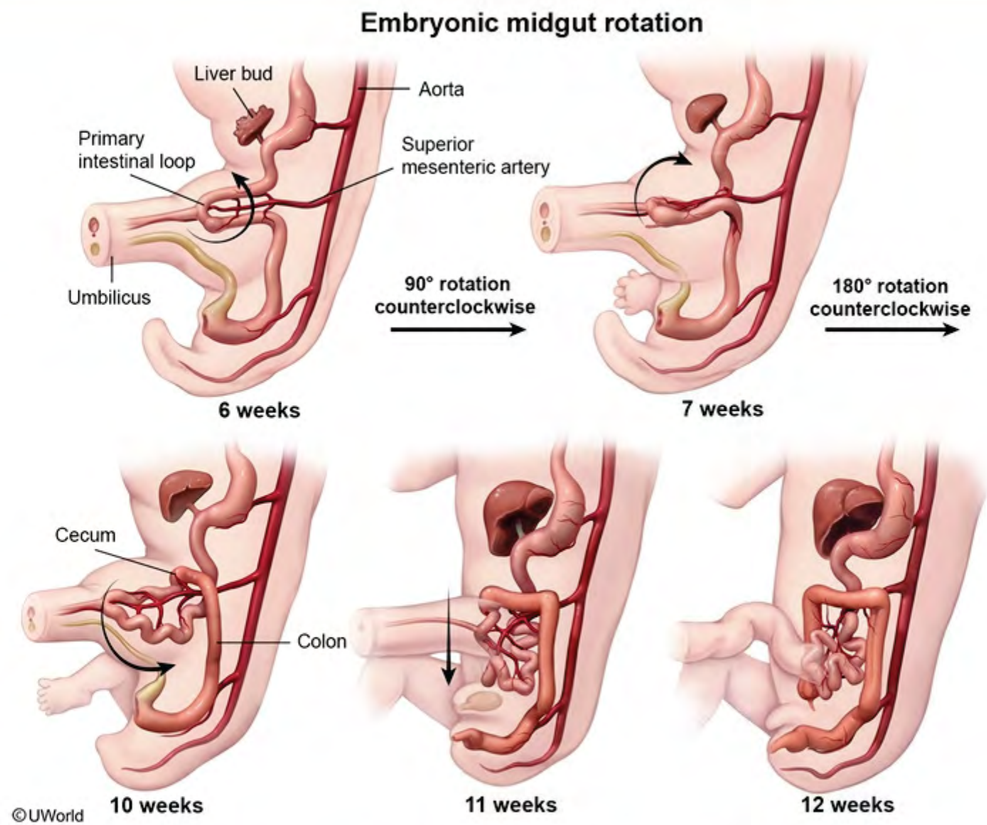

At 4-8
while u
midgu
and tu
parieta
duode

Incom
rest in
over th
sympt
distens

Midgu
meser
period

(Choi
usuall

(Choi
canno
but de
compr

(Choice D) The omphalomesenteric duct connects the midgut lumen with the yolk sac. Failed obliteration of the duct can lead to Meckel diverticulum, which most commonly presents with painless lower gastrointestinal bleeding. Emesis is not typical, and Ladd bands would not be seen.

https://t.me/USMLEWorldStep1

At 4-8 weeks gestation, the midgut (supplied by the superior mesenteric artery) herniates through the umbilical ring
while u
midgu
and tu
parieta
duode

Incom
rest in
over th
sympt
distens

Midgu
meser
period

(Choi
usuall

(Choi
canno
but de
compr

(Choi
duct c
bleedi

(Choi
present with bilious emesis in the neonatal period; Ladd bands would not be present.

Educational objective:

Exhibit Display

Midgut volvulus

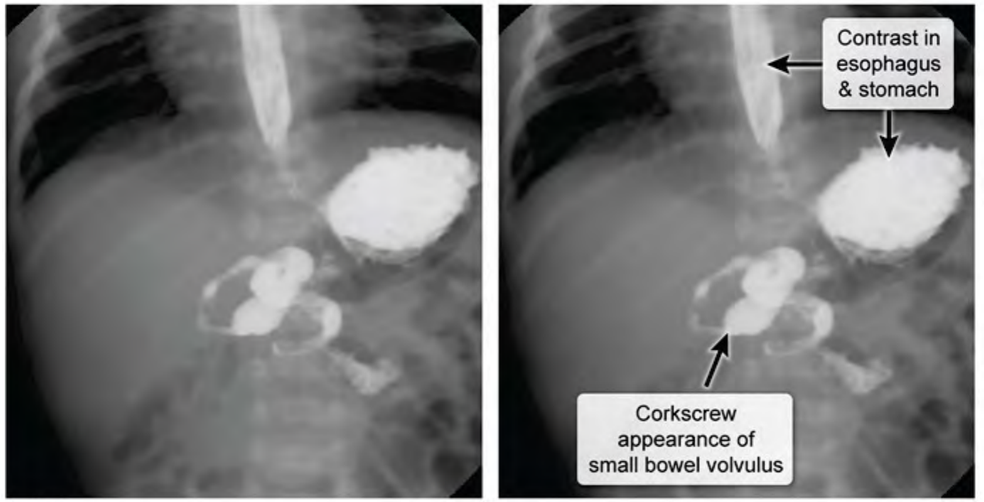

©UWorld

Zoom In | Zoom Out | Reset | New | Existing | My Notebook

https://t.me/USMLEWorldStep1

At 4-8 weeks gestation, the midgut (supplied by the superior mesenteric artery) herniates through the umbilical ring
while
midgu
and tu
parieta
duode

Incom
rest in
over th
sympt
distens

Midgu
meser
period

(Choi
usuall

(Choi
canno
but de
compr

(Choi
duct c
bleedi

Exhibit Display

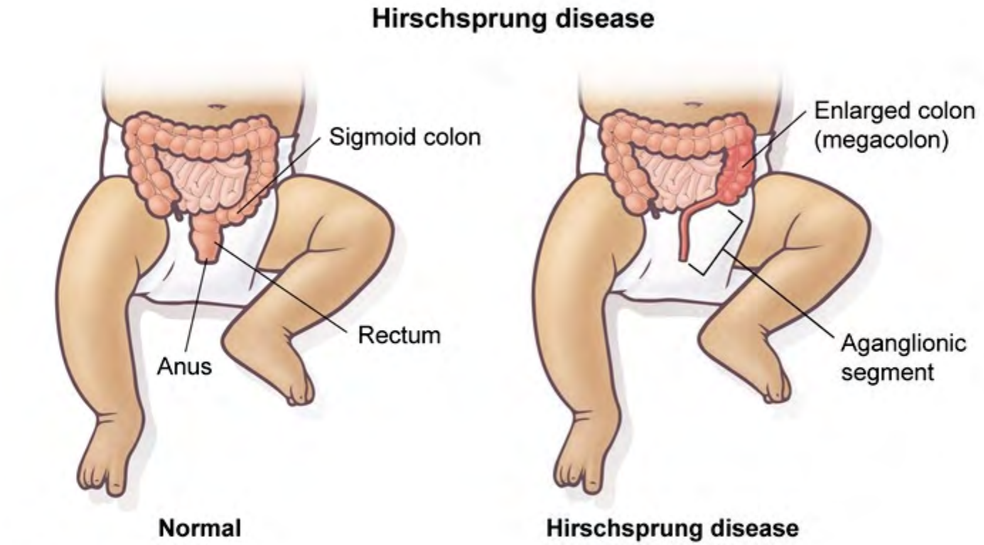

Zoom In | Zoom Out | Reset | New | Existing | My Notebook

(Choice E) Failure of gut recanalization describes duodenal atresia. Although patients with duodenal atresia may present with bilious emesis in the neonatal period, Ladd bands would not be present.

Educational objective:

https://t.me/USMLEWorldStep1

©UWorld

At 4-8 weeks gestation, the midgut (supplied by the superior mesenteric artery) herniates through the umbilical ring while u
midgu
and tu
parieta
duode

Incom
rest in
over th
sympt
distens

Midgu
meser
period

(Choi
usuall

(Choi
canno
but de
compr

(Choi
duct c
bleedi

(Choi
present with bilious emesis in the neonatal period; Ladd bands would not be present.

Educational objective:

Exhibit Display

Vitelline duct abnormalities

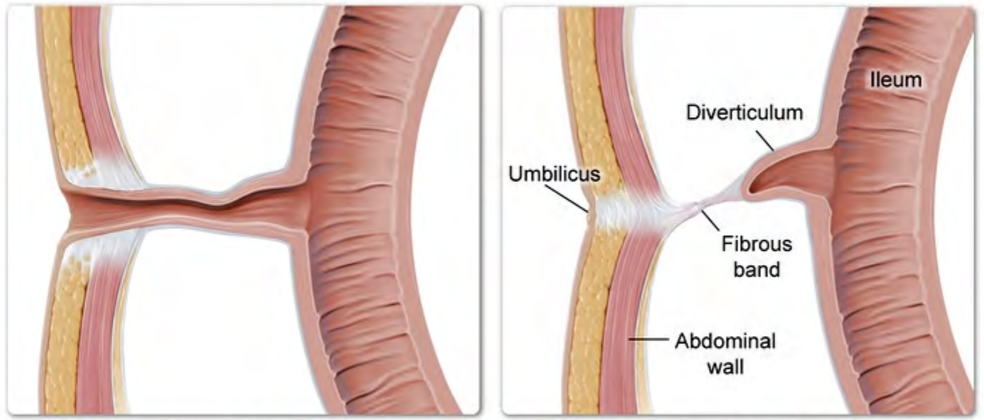

Persistent vitelline duct

Meckel diverticulum (most common)

©UWorld

Zoom In | Zoom Out | Reset | New | Existing | My Notebook

https://t.me/USMLEWorldStep1

At 4-8 weeks gestation, the midgut (supplied by the superior mesenteric artery) herniates through the umbilical ring
while u
midgu
and tu
parieta
duode

Incom
rest in
over th
sympt
distens

Midgu
meser
period

(Choi
usuall

(Choi
canno
but de
compr

(Choi
duct c
bleedi

(Choi
present with bilious emesis in the neonatal period; Ladd bands would not be present.

Educational objective:

Exhibit Display

Duodenal atresia

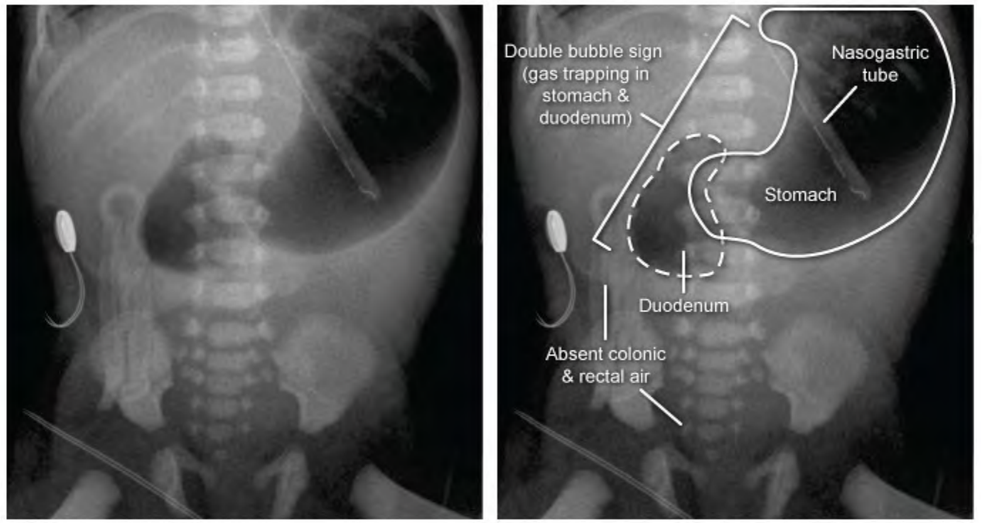

©UWorld

Zoom In | Zoom Out | Reset | New | Existing | My Notebook

https://t.me/USMLEWorldStep1

A 34-year-old man with upper gastrointestinal bleeding is brought to the local emergency department by ambulance. He was found in front of a grocery store after customers called emergency medical services. The patient is unable to provide any information, but his medical records show a history of alcohol use disorder. After undergoing emergency evaluation and appropriate resuscitation, his condition stabilizes. Gastric lavage fluid initially contained blood but cleared quickly. Upper endoscopy shows a linear mucosal tear at the gastroesophageal junction. The process directly responsible for causing this patient's mucosal tear will most likely result in which of the following acid-base disturbances?

- A. High anion gap metabolic acidosis
- B. Metabolic alkalosis
- C. Normal anion gap metabolic acidosis
- D. Respiratory acidosis
- E. Respiratory alkalosis

Submit

https://t.me/USMLEWorldStep1

A 34-year-old man with upper gastrointestinal bleeding is brought to the local emergency department by ambulance. He was found in front of a grocery store after customers called emergency medical services. The patient is unable to provide any information, but his medical records show a history of alcohol use disorder. After undergoing emergency evaluation and appropriate resuscitation, his condition stabilizes. Gastric lavage fluid initially contained blood but cleared quickly. Upper endoscopy shows a linear mucosal tear at the gastroesophageal junction. The process directly responsible for causing this patient's mucosal tear will most likely result in which of the following acid-base disturbances?

- A. High anion gap metabolic acidosis (15%)
- ✓ B. Metabolic alkalosis (72%)
- C. Normal anion gap metabolic acidosis (9%)
- D. Respiratory acidosis (1%)
- E. Respiratory alkalosis (1%)

Correct | 72% Answered correctly | 03 secs Time Spent | 2023 Version

Explanation

Characteristics of gastroesophageal mural injury		
	Mallory-Weiss syndrome	**Boerhaave syndrome**
Etiology	• Forceful retching • **Mucosal** tear • Submucosal venous or arterial plexus bleeding	• Forceful retching • **Transmural** tear • Spillage of esophageal air/fluid into surrounding tissues

https://t.me/USMLEWorldStep1

Characteristics of gastroesophageal mural injury		
	Mallory-Weiss syndrome	**Boerhaave syndrome**
Etiology	• Forceful retching • **Mucosal** tear • Submucosal venous or arterial plexus bleeding	• Forceful retching • **Transmural** tear • Spillage of esophageal air/fluid into surrounding tissues
Clinical presentation	• Epigastric/back pain • **Hematemesis** (bright red or coffee-ground) • Possible hypovolemia	• Chest/back/epigastric pain • **Crepitus, crunching sound** (Hamman sign) • Odynophagia, dyspnea, fever, sepsis
Studies	• **Upper GI endoscopy** confirms diagnosis (& can treat persistent bleeding)	• Chest x-ray: pneumothorax, pneumomediastinum, pleural effusion • **Esophagography or CT scan with water-soluble contrast** confirms diagnosis
Management	• Acid suppression • **Most heal spontaneously**	• Acid suppression, antibiotics, NPO • **Emergency surgical consultation**
GI = gastrointestinal.		

This patient has a **Mallory-Weiss tear** of the gastric mucosa near the gastroesophageal junction. Mallory-Weiss tears are caused by high intragastric pressure being transmitted to the esophagus through a tight lower esophageal sphincter. They are most commonly caused by repetitive **retching and vomiting** but can also occur with straining during defecation or heavy lifting, seizures, blunt abdominal injury, and upper gastrointestinal endoscopy. Repetitive vomiting leads to **metabolic alkalosis** due to net loss of acidic gastric secretions.

(Choice A) Unlike methanol or ethylene glycol, acute ethanol intoxication does not usually cause high anion gap metabolic acidosis, but chronic alcohol use can cause ketoacidosis in malnourished patients. Ethanol abuse is a

https://t.me/USMLEWorldStep1

Management	• Acid suppression • **Most heal spontaneously**	• Acid suppression, antibiotics, NPO • **Emergency surgical consultation**

GI = gastrointestinal.

This patient has a **Mallory-Weiss tear** of the gastric mucosa near the gastroesophageal junction. Mallory-Weiss tears are caused by high intragastric pressure being transmitted to the esophagus through a tight lower esophageal sphincter. They are most commonly caused by repetitive **retching and vomiting** but can also occur with straining during defecation or heavy lifting, seizures, blunt abdominal injury, and upper gastrointestinal endoscopy. Repetitive vomiting leads to **metabolic alkalosis** due to net loss of acidic gastric secretions.

(Choice A) Unlike methanol or ethylene glycol, acute ethanol intoxication does not usually cause high anion gap metabolic acidosis, but chronic alcohol use can cause ketoacidosis in malnourished patients. Ethanol abuse is a common predisposing factor for Mallory-Weiss tears; however, it is the repetitive vomiting and retching that directly cause the tears.

(Choice C) Normal anion gap metabolic acidosis is usually caused by loss of bicarbonate, which can occur with prolonged diarrhea. Recurrent vomiting causes metabolic alkalosis, not acidosis.

(Choices D and E) Respiratory acidosis usually occurs in patients with chronic obstructive pulmonary disease or central nervous system depression (eg, narcotic overdose). Respiratory alkalosis occurs with hyperventilation (eg, panic attacks, pulmonary emboli).

Educational objective:
A Mallory-Weiss tear is a tear in the gastric mucosa near the gastroesophageal junction. It typically results from repetitive forceful vomiting, which can also cause metabolic alkalosis.

References

- Diagnosis and management of upper gastrointestinal bleeding.

Pathophysiology	Gastrointestinal & Nutrition	Mallory-weiss syndrome
Subject	System	Topic

Copyright © UWorld. All rights reserved.

https://t.me/USMLEWorldStep1

A 16-year-old boy is brought to the emergency department due to severe retrosternal burning pain and odynophagia for the past 12 hours. The patient has had no fever, sore throat, nausea, vomiting, or abdominal pain. Medical history includes nodulocystic acne, for which he began taking oral doxycycline a week ago. Vital signs are within normal limits. Physical examination shows a normal oropharynx, clear lungs, normal heart sounds, and a nontender abdomen. Upper gastrointestinal endoscopy reveals a small, punched-out ulcer in the proximal esophagus and normal-appearing gastroduodenal mucosa. Doxycycline is presumed to be the culprit. This medication most likely led to this patient's current condition through which of the following mechanisms?

- A. Alteration of commensal microbial flora
- B. Decrease in esophageal sphincter tone
- C. Drug-induced direct mucosal injury
- D. Increase in gastric acid production
- E. Suppression of T-cell immune response

Submit

https://t.me/USMLEWorldStep1

A 16-year-old boy is brought to the emergency department due to severe retrosternal burning pain and odynophagia for the past 12 hours. The patient has had no fever, sore throat, nausea, vomiting, or abdominal pain. Medical history includes nodulocystic acne, for which he began taking oral doxycycline a week ago. Vital signs are within normal limits. Physical examination shows a normal oropharynx, clear lungs, normal heart sounds, and a nontender abdomen. Upper gastrointestinal endoscopy reveals a small, punched-out ulcer in the proximal esophagus and normal-appearing gastroduodenal mucosa. Doxycycline is presumed to be the culprit. This medication most likely led to this patient's current condition through which of the following mechanisms?

- ✗ A. Alteration of commensal microbial flora (23%)
- B. Decrease in esophageal sphincter tone (8%)
- ✓ C. Drug-induced direct mucosal injury (51%)
- D. Increase in gastric acid production (9%)
- E. Suppression of T-cell immune response (6%)

Incorrect
Correct answer
C

51%
Answered correctly

04 secs
Time Spent

2023
Version

Explanation

Pill esophagitis occurs when caustic medications come in contact with the esophageal mucosa for a prolonged time, leading to **direct mucosal injury**. Common culprits include **tetracyclines** (eg, doxycycline), bisphosphonates (eg, alendronate), potassium chloride, and nonsteroidal anti-inflammatory drugs. This complication usually develops in locations where the esophageal lumen is **compressed** by other anatomic structures. The aortic arch and carina may impede the movement of pills through the proximal esophagus, whereas the gastroesophageal junction or severe left atrial enlargement can lead to pills lodging in the distal esophagus.

https://t.me/USMLEWorldStep1

Pill esophagitis occurs when caustic medications come in contact with the esophageal mucosa for a prolonged time, leading to **direct mucosal injury**. Common culprits include **tetracyclines** (eg, doxycycline), bisphosphonates (eg, alendronate), potassium chloride, and nonsteroidal anti-inflammatory drugs. This complication usually develops in locations where the esophageal lumen is **compressed** by other anatomic structures. The aortic arch and carina may impede the movement of pills through the proximal esophagus, whereas the gastroesophageal junction or severe left atrial enlargement can lead to pills lodging in the distal esophagus.

Pill esophagitis causes odynophagia and retrosternal chest pain and is usually diagnosed by upper gastrointestinal endoscopy, which reveals **discrete ulcerations** at the location of medication-induced caustic injury. To avoid this complication, patients should remain upright after swallowing high-risk medications and consume plenty of water to facilitate rapid passage through the esophagus.

(Choice A) Alteration of commensal microbial flora due to antibiotic use increases the risk for esophageal candidiasis, a disorder caused by overproliferation of *Candida albicans*. However, endoscopy would show white, cottage cheese–like plaques.

(Choice B) Lower esophageal sphincter hypotonicity predisposes to gastroesophageal reflux disease (GERD), which can cause irregularly shaped or linear ulcerations in the distal esophagus. However, the proximal esophagus is almost never involved in GERD.

(Choice D) Overproduction of gastrin (eg, Zollinger-Ellison syndrome) leads to excess stomach acid secretion and peptic/duodenal ulcer formation. Esophageal ulcers would not be expected.

(Choice E) Patients with T-cell immunodeficiencies (eg, HIV/AIDs) may develop esophageal ulcerations related to cytomegalovirus or herpes simplex virus; these are rare causes of esophageal ulcers in immunocompetent individuals.

Educational objective:
Pill esophagitis, which can be caused by tetracyclines (eg, doxycycline), results from prolonged contact of caustic medication with the esophageal mucosa. It most often occurs in locations where the esophagus is in close proximity to other anatomic structures, such as where the proximal esophagus comes in contact with the aortic

https://t.me/USMLEWorldStep1

bisphosphonates (eg, alendronate), potassium chloride, and nonsteroidal anti-inflammatory drugs. This complication usually develops in locations where the esophageal lumen is **compressed** by other anatomic structures. The aortic arch and carina may impede the movement of pills through the proximal esophagus, whereas the gastroesophageal junction or severe left atrial enlargement can lead to pills lodging in the distal esophagus.

Pill esophagitis causes odynophagia and retrosternal chest pain and is usually diagnosed by upper gastrointestinal endoscopy, which reveals **discrete ulcerations** at the location of medication-induced caustic injury. To avoid this complication, patients should remain upright after swallowing high-risk medications and consume plenty of water to facilitate rapid passage through the esophagus.

(Choice A) Alteration of commensal microbial flora due to antibiotic use increases the risk for esophageal candidiasis, a disorder caused by overproliferation of *Candida albicans*. However, endoscopy would show white, cottage cheese–like plaques.

(Choice B) Lower esophageal sphincter hypotonicity predisposes to gastroesophageal reflux disease (GERD), which can cause irregularly shaped or linear ulcerations in the distal esophagus. However, the proximal esophagus is almost never involved in GERD.

(Choice D) Overproduction of gastrin (eg, Zollinger-Ellison syndrome) leads to excess stomach acid secretion and peptic/duodenal ulcer formation. Esophageal ulcers would not be expected.

(Choice E) Patients with T-cell immunodeficiencies (eg, HIV/AIDs) may develop esophageal ulcerations related to cytomegalovirus or herpes simplex virus; these are rare causes of esophageal ulcers in immunocompetent individuals.

Educational objective:
Pill esophagitis, which can be caused by tetracyclines (eg, doxycycline), results from prolonged contact of caustic medication with the esophageal mucosa. It most often occurs in locations where the esophagus is in close proximity to other anatomic structures, such as where the proximal esophagus comes in contact with the aortic arch and the carina.

References

- Drug-induced esophagitis

https://t.me/USMLEWorldStep1

A 70-year-old man comes to the office due to persistent epigastric discomfort and nausea for the past several months. He has also noticed black-colored stools on several occasions. Medical history is notable for hypertension and osteoarthritis. The patient emigrated from rural China 5 years ago to live with his daughter. He does not use tobacco, alcohol, or illicit drugs. Physical examination shows a thin male with pale mucous membranes, an enlarged left supraclavicular lymph node, and epigastric tenderness on deep palpation. Stool testing for occult blood is positive. Upper gastrointestinal endoscopy reveals a 3-cm ulceration at the gastric antrum, with a heaped-up irregular border. Biopsy from the edge of the ulcer reveals glandular structures containing intestinal-like columnar cells. Which of the following most likely predisposed this patient to his current condition?

- A. Chronic use of nonsteroidal anti-inflammatory drugs
- B. Excessive consumption of salt-preserved foods
- C. Frequent intake of high-temperature beverages
- D. Functional disruption of gastroesophageal junction
- E. Increased gastrin production from a pancreatic mass

Submit

https://t.me/USMLEWorldStep1

A 70-year-old man comes to the office due to persistent epigastric discomfort and nausea for the past several months. He has also noticed black-colored stools on several occasions. Medical history is notable for hypertension and osteoarthritis. The patient emigrated from rural China 5 years ago to live with his daughter. He does not use tobacco, alcohol, or illicit drugs. Physical examination shows a thin male with pale mucous membranes, an enlarged left supraclavicular lymph node, and epigastric tenderness on deep palpation. Stool testing for occult blood is positive. Upper gastrointestinal endoscopy reveals a 3-cm ulceration at the gastric antrum, with a heaped-up irregular border. Biopsy from the edge of the ulcer reveals glandular structures containing intestinal-like columnar cells. Which of the following most likely predisposed this patient to his current condition?

- A. Chronic use of nonsteroidal anti-inflammatory drugs (22%)
- ✓ B. Excessive consumption of salt-preserved foods (58%)
- C. Frequent intake of high-temperature beverages (5%)
- D. Functional disruption of gastroesophageal junction (4%)
- E. Increased gastrin production from a pancreatic mass (9%)

Correct

58% Answered correctly

04 secs Time Spent

2023 Version

Explanation

Gastric adenocarcinoma	
Risk factors	• High-salt diet • N-nitroso–containing compounds (eg, processed meat, tobacco) • Chronic *Helicobacter pylori* infection • Autoimmune chronic atrophic gastritis

https://t.me/USMLEWorldStep1

Gastric adenocarcinoma	
Risk factors	• High-salt diet • N-nitroso–containing compounds (eg, processed meat, tobacco) • Chronic *Helicobacter pylori* infection • Autoimmune chronic atrophic gastritis • Obesity
Clinical features	• Early satiety, weight loss • Epigastric pain, melena • Left supraclavicular &/or umbilical lymphadenopathy
Gross appearance/ histopathology	Intestinal type: • Ulcerated mass with irregular rolled or heaped-up edges • Glandular structures with intestinal-like columnar or cuboidal cells (similar to colon adenocarcinoma) Diffuse: • Plaque-like infiltration of stomach (eg, linitis plastica) • Signet-ring cells without glandular structures

This patient with epigastric pain, occasional melena, and left supraclavicular lymphadenopathy (ie, Virchow node) has intestinal-type **gastric adenocarcinoma**, the most common primary gastric malignancy. It is typically visualized endoscopically as an **ulcerated mass** with irregular folded or heaped-up edges. Histologically, intestinal-type gastric cancer resembles colon adenocarcinoma and is characterized by **glandular** structures containing **intestinal-like columnar** (or cuboidal) cells.

Gastric cancer occurs with the highest incidence in patients from **Eastern Asia**, Eastern Europe, and South America, possibly due to the increased consumption of **salt-preserved foods** (eg, salt-cured fish), which directly damage the gastric epithelium and potentiate the effects of carcinogens. Common carcinogens associated with gastric cancer include n-nitroso–containing compounds (eg, tobacco, processed meat) and chronic *Helicobacter pylori* infection, both of which may also be present at increased levels in these populations. Other risk factors

https://t.me/USMLEWorldStep1

	• Plaque-like infiltration of stomach (eg, linitis plastica) • Signet-ring cells without glandular structures

This patient with epigastric pain, occasional melena, and left supraclavicular lymphadenopathy (ie, Virchow node) has intestinal-type **gastric adenocarcinoma**, the most common primary gastric malignancy. It is typically visualized endoscopically as an **ulcerated mass** with irregular folded or heaped-up edges. Histologically, intestinal-type gastric cancer resembles colon adenocarcinoma and is characterized by **glandular** structures containing **intestinal-like columnar** (or cuboidal) cells.

Gastric cancer occurs with the highest incidence in patients from **Eastern Asia**, Eastern Europe, and South America, possibly due to the increased consumption of **salt-preserved foods** (eg, salt-cured fish), which directly damage the gastric epithelium and potentiate the effects of carcinogens. Common carcinogens associated with gastric cancer include n-nitroso–containing compounds (eg, tobacco, processed meat) and chronic *Helicobacter pylori* infection, both of which may also be present at increased levels in these populations. Other risk factors include obesity and autoimmune atrophic gastritis.

(Choices A and E) Chronic nonsteroidal anti-inflammatory drug use and gastrin-producing tumors (ie, Zollinger-Ellison syndrome) are associated with benign peptic ulcer disease, not gastric adenocarcinoma. Benign ulcers are typically clean-based with regular borders (as opposed to this patient's ulcerated lesion with irregular, heaped-up borders); in addition, intestinal metaplasia is unexpected.

(Choice C) Excessive consumption of hot beverages is associated with esophageal squamous cell carcinoma, not gastric adenocarcinoma.

(Choice D) Disruption of the lower esophageal sphincter enables gastric acid to reflux into the esophagus, which predisposes patients to esophageal intestinal metaplasia (eg, Barrett esophagus) and ultimately esophageal adenocarcinoma. However, this is not a risk factor for gastric adenocarcinoma.

Educational objective:
Intestinal-type gastric adenocarcinoma is visualized endoscopically as an ulcerated mass with irregular folded or heaped-up edges. Histologically, it resembles colon adenocarcinoma and is characterized by glandular structures containing intestinal-like columnar (or cuboidal) cells. Risk factors include *Helicobacter pylori* infection, a high-salt diet, n-nitroso–containing compounds, and autoimmune atrophic gastritis.

https://t.me/USMLEWorldStep1

A 46-year-old woman with a history of hiatal hernia and severe gastroesophageal reflux undergoes antireflux surgery. The reflux symptoms were refractory to medical therapy, so an endoscopic fundoplication procedure is performed. During surgery, the hiatal defect is repaired, and the gastric fundus is mobilized and wrapped around the lower esophagus to reinforce the lower esophageal sphincter. No esophageal or gastric injuries occurred, but a neural structure traversing the esophageal hiatus of the diaphragm was inadvertently injured. Which of the following is the most likely potential effect of this operative injury?

- A. Delayed gastric emptying
- B. Diaphragmatic paralysis
- C. Fecal incontinence
- D. Gastric acid hypersecretion
- E. Permanent loss of intestinal peristalsis

Submit

https://t.me/USMLEWorldStep1

A 46-year-old woman with a history of hiatal hernia and severe gastroesophageal reflux undergoes antireflux surgery. The reflux symptoms were refractory to medical therapy, so an endoscopic fundoplication procedure is performed. During surgery, the hiatal defect is repaired, and the gastric fundus is mobilized and wrapped around the lower esophagus to reinforce the lower esophageal sphincter. No esophageal or gastric injuries occurred, but a neural structure traversing the esophageal hiatus of the diaphragm was inadvertently injured. Which of the following is the most likely potential effect of this operative injury?

- ✓ A. Delayed gastric emptying (44%)
- B. Diaphragmatic paralysis (38%)
- C. Fecal incontinence (1%)
- D. Gastric acid hypersecretion (8%)
- E. Permanent loss of intestinal peristalsis (7%)

Correct

44% Answered correctly

04 secs Time Spent

2023 Version

Explanation

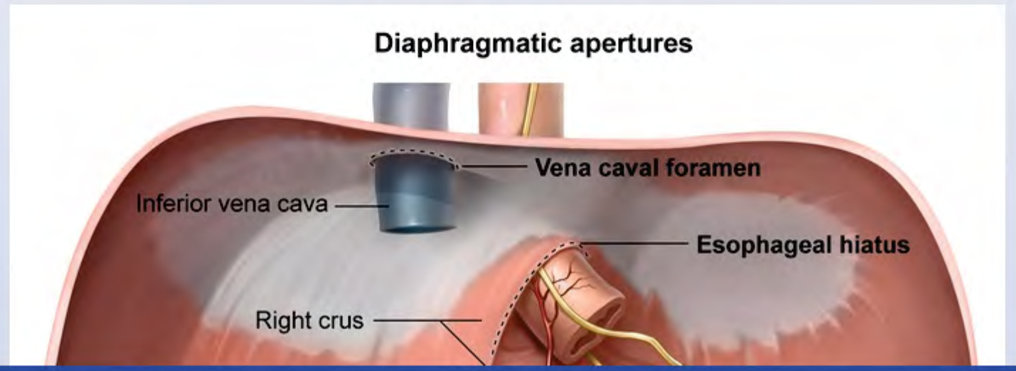

https://t.me/USMLEWorldStep1

Exhibit Display

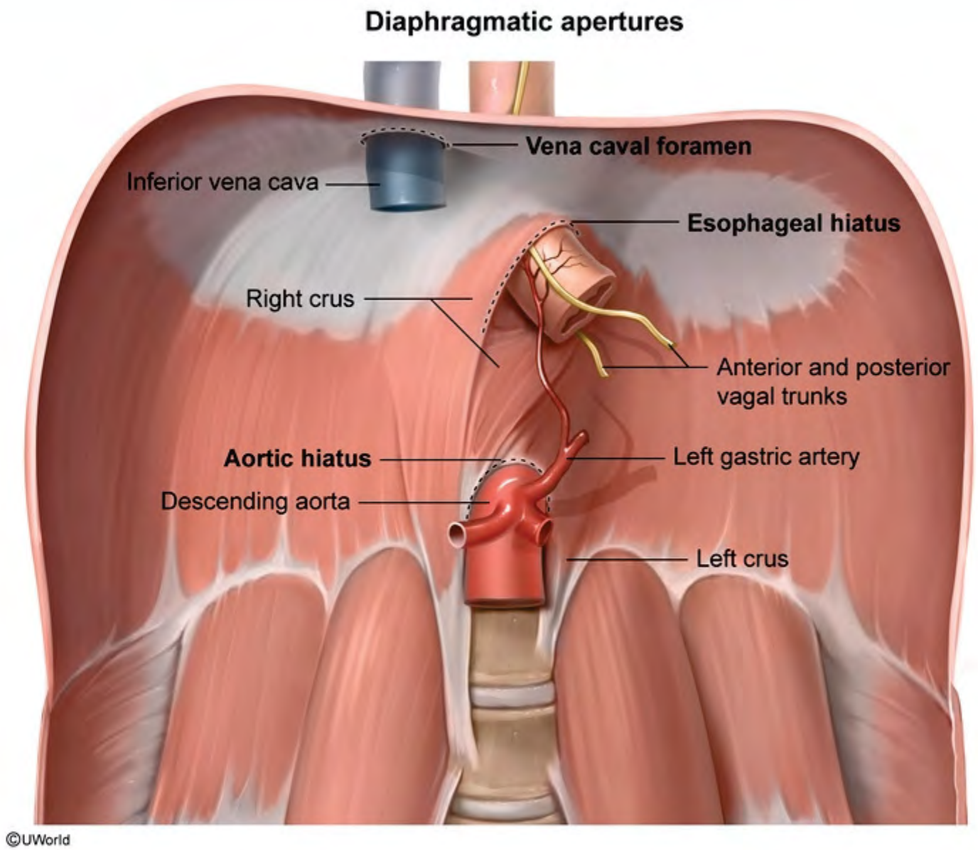

Zoom In | Zoom Out | Reset | New | Existing | My Notebook

Fundoplication is a surgical procedure used to treat refractory gastroesophageal reflux associated with an

https://t.me/USMLEWorldStep1

©UWorld

Fundoplication is a surgical procedure used to treat refractory gastroesophageal reflux associated with an esophageal hiatal hernia. In the procedure, the esophageal hiatus is tightened, and the gastric fundus is wrapped around the lower esophageal sphincter, thereby preventing gastric acid from entering the esophagus.

However, the **anterior and posterior vagal trunks** (branches of the vagus nerve) also pass through the esophageal hiatus and are vulnerable to injury during fundoplication. These nerves supply parasympathetic innervation to the gastrointestinal tract and stimulate gastric muscle contraction and motility. Injury to the vagal trunks can lead to **delayed gastric emptying** (ie, gastroparesis), manifesting with abdominal pain, early satiety, and postprandial emesis.

(Choice B) The phrenic nerve innervates the diaphragm; it originates from the C3-C5 nerve roots and passes through the mediastinum between the heart and the lungs. It is unlikely to be injured during fundoplication because its terminal motor branches transit the venal caval foramen, not the esophageal hiatus.

(Choice C) Tonic contraction of the pelvic floor muscles (eg, levator ani) is necessary for preventing fecal incontinence. They receive parasympathetic innervation from the pelvic splanchnic nerves, not the vagus nerve, and their function would be unaffected by vagal injury.

(Choice D) The vagus nerve stimulates gastric parietal cell production of hydrochloric acid; injury may therefore lead to decreased gastric acid secretion (ie, hypochlorhydria), not increased secretion.

(Choice E) Intestinal peristalsis is mediated largely by the enteric nervous system. Although vagus nerve injury may cause transient intestinal dysmotility due to sudden loss of parasympathetic input, it would not cause long-term dysfunction.

Educational objective:
Branches of the vagus nerve (ie, anterior and posterior vagal trunks) pass through the esophageal hiatus. Damage to these branches, which can occur during esophageal hiatal hernia repair (eg, fundoplication), may result in delayed gastric emptying and gastric hypochlorhydria.

References

- Central nervous system control of gastrointestinal motility and secretion and modulation of gastrointestinal functions

https://t.me/USMLEWorldStep1

©UWorld

Fundoplication is a surgical procedure used to treat refractory gastroesophageal reflux associated with an esoph
aroun

Howev
esoph
innerv
trunks
and pc

(Choi
throug
becau

(Choi
inconti
and th

(Choi
lead to

(Choi
may c
term d

Educa
Branch
Damag
in dela

Refere
- Central nervous system control of gastrointestinal motility and secretion and modulation of gastrointestinal functions

Exhibit Display

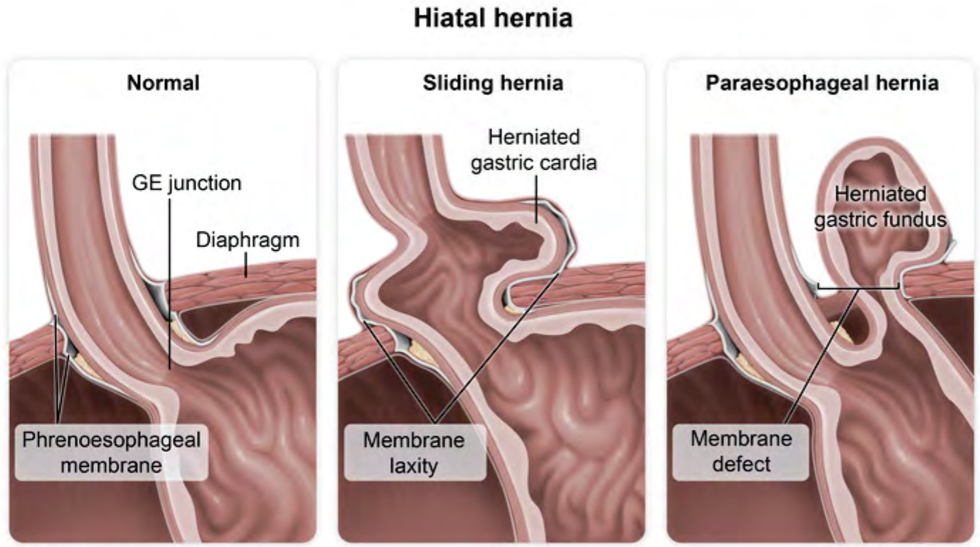

GE = gastroesophageal.
©UWorld

Zoom In | Zoom Out | Reset | New | Existing | My Notebook

https://t.me/USMLEWorldStep1

©UWorld

Fundoplication is a surgical procedure used to treat refractory gastroesophageal reflux associated with an
esoph
aroun

Howev
esoph
innerv
trunks
and pc

(Choi
throug
becau

(Choi
inconti
and th

(Choi
lead to

(Choi
may c
term d

Educa
Branch
Dama
in dela

Refere
- Central nervous system control of gastrointestinal motility and secretion and modulation of gastrointestinal
functions

Exhibit Display

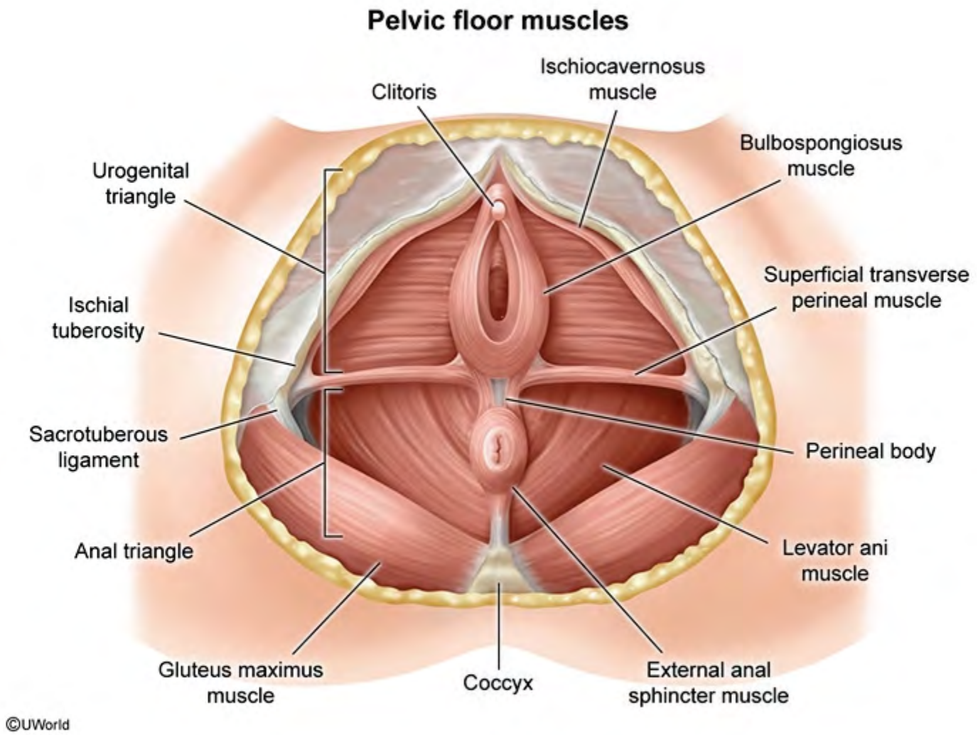

Zoom In | Zoom Out | Reset | New | Existing | My Notebook

https://t.me/USMLEWorldStep1

A 33-year-old woman with a 9-year history of ulcerative colitis comes to the office due to concern about her risk of colon cancer. One of her close family friends died recently from this cancer. The patient wants to "undergo all the tests for colon cancer." She has no other comorbid conditions and is under the care of a gastroenterologist who has kept her disease well controlled with sulfasalazine. Compared with sporadic colorectal carcinoma, colorectal malignancy arising in this patient would more likely exhibit which of the following features?

- A. Early *APC* gene mutation
- B. Low-grade histology
- C. Multifocal origin
- D. Origin from an adenomatous polyp

Submit

https://t.me/USMLEWorldStep1

A 33-year-old woman with a 9-year history of ulcerative colitis comes to the office due to concern about her risk of colon cancer. One of her close family friends died recently from this cancer. The patient wants to "undergo all the tests for colon cancer." She has no other comorbid conditions and is under the care of a gastroenterologist who has kept her disease well controlled with sulfasalazine. Compared with sporadic colorectal carcinoma, colorectal malignancy arising in this patient would more likely exhibit which of the following features?

- A. Early *APC* gene mutation (24%)
- ✗ B. Low-grade histology (14%)
- ✓ C. Multifocal origin (48%)
- D. Origin from an adenomatous polyp (12%)

Incorrect
Correct answer
C

48%
Answered correctly

03 secs
Time Spent

2023
Version

Explanation

Colitis-associated vs sporadic colorectal cancer

	Colitis-associated	Sporadic
Age	• Younger (age 40-55)	• Older (age >60)
Origin of dysplasia	• Flat (nonpolypoid) lesions	• Polypoid lesions
Location	• Proximal > distal (particularly with CD)	• Distal > proximal
Tumors	• Multifocal	• Singular

https://t.me/USMLEWorldStep1

Colitis-associated vs sporadic colorectal cancer		
	Colitis-associated	**Sporadic**
Age	• Younger (age 40-55)	• Older (age >60)
Origin of dysplasia	• Flat (nonpolypoid) lesions	• Polypoid lesions
Location	• Proximal > distal (particularly with CD)	• Distal > proximal
Tumors	• Multifocal	• Singular
Histology	• Mucinous and/or signet ring cells • Poorly differentiated	• Rarely mucinous • Well differentiated
Mutations	• Early *p53* mutation • Late *APC* gene mutation	• Early *APC* gene mutation • Late *p53* mutation
APC = adenomatous polyposis coli; **CD** = Crohn disease.		

Inflammatory bowel disease (IBD) is associated with a significant risk for colorectal carcinoma (CRC); up to 30% of patients with IBD develop CRC in their lifetime. Patients with ulcerative colitis, particularly pancolitis, are at highest risk. **Colitis-associated colorectal cancer** (CA-CRC) occurs in areas of chronic inflammation, and the risk is proportionate to the duration and severity of inflammation.

(Choices A, B, and D) Unlike sporadic CRC, which typically progresses slowly from a singular dysplastic polyp, CA-CRC is typically more **aggressive**, often evolves from flat (**nonpolypoid**) lesions, and is frequently **multifocal** (ie, multiple synchronous carcinomas) at diagnosis. CA-CRC often affects a **younger** population than sporadic CRC. These malignancies are more likely to have a **higher histopathologic grade**, with poorly differentiated or anaplastic cells and a high number of mucinous or signet ring cells. The molecular pathogenesis of CA-CRC is also different than that of sporadic disease, with *p53* mutations occurring early in the course of malignant

https://t.me/USMLEWorldStep1

	• Late *APC* gene mutation	• Late *p53* mutation
APC = adenomatous polyposis coli; **CD** = Crohn disease.		

Inflammatory bowel disease (IBD) is associated with a significant risk for colorectal carcinoma (CRC); up to 30% of patients with IBD develop CRC in their lifetime. Patients with ulcerative colitis, particularly pancolitis, are at highest risk. **Colitis-associated colorectal cancer** (CA-CRC) occurs in areas of chronic inflammation, and the risk is proportionate to the duration and severity of inflammation.

(Choices A, B, and D) Unlike sporadic CRC, which typically progresses slowly from a singular dysplastic polyp, CA-CRC is typically more **aggressive**, often evolves from flat (**nonpolypoid**) lesions, and is frequently **multifocal** (ie, multiple synchronous carcinomas) at diagnosis. CA-CRC often affects a **younger** population than sporadic CRC. These malignancies are more likely to have a **higher histopathologic grade**, with poorly differentiated or anaplastic cells and a high number of mucinous or signet ring cells. The molecular pathogenesis of CA-CRC is also different than that of sporadic disease, with *p53* mutations occurring early in the course of malignant development and *APC* mutations occurring much later.

Given the high risk for CRC and the difficulty of colonoscopic visualization of flat or multifocal lesions, it is important to regularly monitor IBD via colonoscopy with random biopsies.

Educational objective:
Inflammatory bowel disease, especially ulcerative pancolitis, is associated with a significant risk for colorectal carcinoma. Compared with sporadic colorectal cancer, colitis-associated colorectal cancer is more likely to occur at a younger age, is typically more aggressive with a higher histopathologic grade, often evolves from flat (nonpolypoid) lesions, and is frequently multifocal. Patients should be monitored regularly via colonoscopy with random biopsies.

References

- Current management of inflammatory bowel disease and colorectal cancer.

Pathology	Gastrointestinal & Nutrition	Colorectal polyps and cancer
Subject	System	Topic

Copyright © UWorld. All rights reserved.

https://t.me/USMLEWorldStep1

A 34-year-old man comes to the office due to epigastric pain. He has had the pain for several months and describes it as being worse at night and relieved by eating. The patient has no significant medical history and takes no medications. He does not use tobacco, alcohol, or recreational drugs. The patient immigrated to the United States from China 4 years ago. Vital signs are within normal limits. Physical examination shows mild epigastric tenderness to deep palpation. Laboratory testing demonstrates iron deficiency anemia and the presence of fecal occult blood. Upper gastrointestinal endoscopy reveals a 1-cm ulcer in the first portion of the duodenum. Additional test results are pending. In addition to proton pump inhibitor therapy, which of the following would be most appropriate to prevent ulcer recurrence based on this patient's most likely diagnosis?

- A. Antibiotics
- B. Gastric cytoprotectants
- C. Glucocorticoids
- D. H_2-receptor blockers
- E. Prokinetic agents
- F. Prostaglandin analogues

Submit

https://t.me/USMLEWorldStep1

A 34-year-old man comes to the office due to epigastric pain. He has had the pain for several months and describes it as being worse at night and relieved by eating. The patient has no significant medical history and takes no medications. He does not use tobacco, alcohol, or recreational drugs. The patient immigrated to the United States from China 4 years ago. Vital signs are within normal limits. Physical examination shows mild epigastric tenderness to deep palpation. Laboratory testing demonstrates iron deficiency anemia and the presence of fecal occult blood. Upper gastrointestinal endoscopy reveals a 1-cm ulcer in the first portion of the duodenum. Additional test results are pending. In addition to proton pump inhibitor therapy, which of the following would be most appropriate to prevent ulcer recurrence based on this patient's most likely diagnosis?

- ✓ A. Antibiotics (70%)
- B. Gastric cytoprotectants (6%)
- C. Glucocorticoids (0%)
- D. H_2-receptor blockers (13%)
- E. Prokinetic agents (1%)
- F. Prostaglandin analogues (7%)

Correct

70% Answered correctly

03 secs Time Spent

2023 Version

Explanation

***Helicobacter pylori* & duodenal ulcers**

https://t.me/USMLEWorldStep1

Exhibit Display

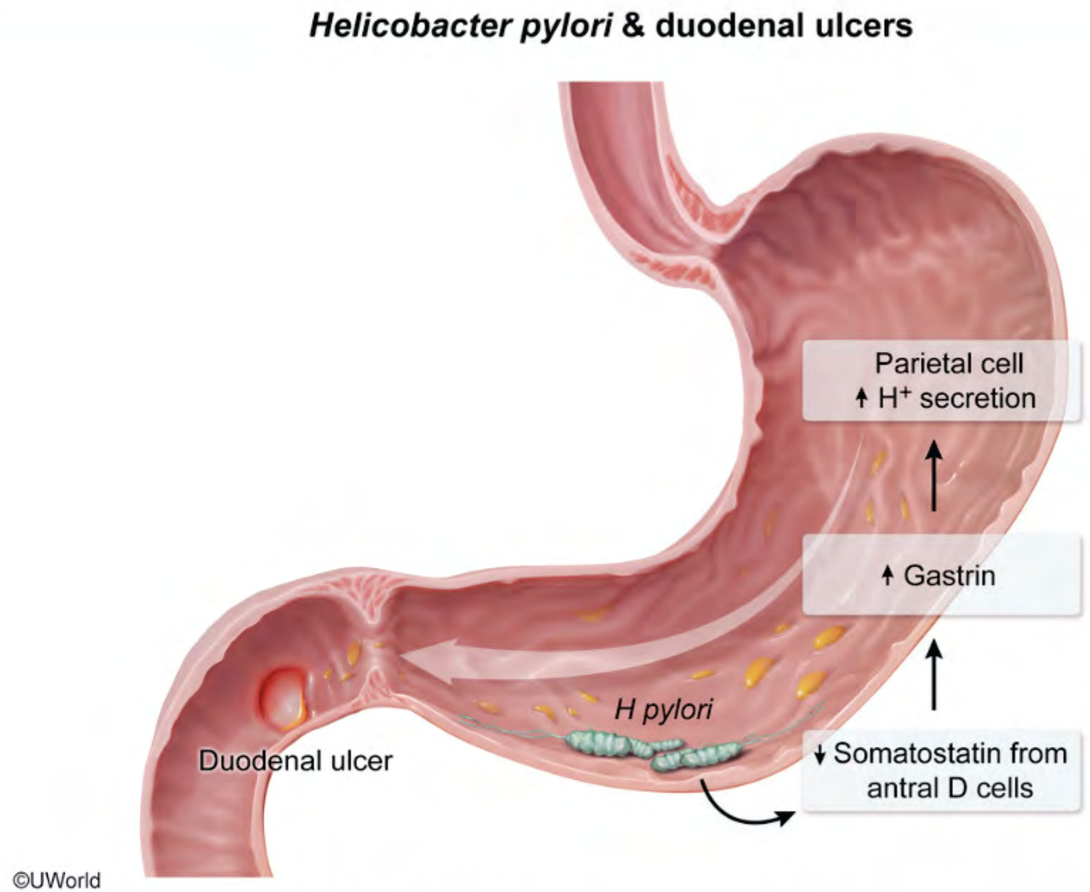

Zoom In | Zoom Out | Reset | New | Existing | My Notebook

This p
patien
associated with nonsteroidal anti-inflammatory drug (NSAID) use, which is unlikely in this patient who takes no medications. More than 50% of the world population is colonized with *H pylori*, with a particularly high prevalence

https://t.me/USMLEWorldStep1

©UWorld

This patient's symptoms and endoscopic findings are consistent with duodenal **peptic ulcer disease** (PUD). Most patients with duodenal ulcers have concomitant ***Helicobacter pylori*** infection. The remaining cases are typically associated with nonsteroidal anti-inflammatory drug (NSAID) use, which is unlikely in this patient who takes no medications. More than 50% of the world population is colonized with *H pylori*, with a particularly high prevalence in Asia and South America.

Treatment of the patient's condition and prevention of ulcer recurrence require eradication of *H pylori* infection. Effective regimens typically involve a combination of **antibiotics** (eg, tetracycline, metronidazole) and proton pump inhibitors (eg, omeprazole), sometimes with bismuth subsalicylate. The antibiotic regimen can be tailored based on local resistance patterns (ie, triple vs quadruple therapy).

(Choice B) Gastric cytoprotectants (eg, sucralfate) bind to the base of mucosal ulcers and protect them against gastric acid. These agents help duodenal ulcers heal but would be less effective in preventing ulcer recurrence compared with eradication of *H pylori*.

(Choice C) Glucocorticoids should be avoided in patients with PUD because they can promote peptic ulcer formation, especially when combined with NSAIDs.

(Choice D) Proton pump inhibitors suppress gastric acid secretion to a greater extent than H_2-receptor blockers (eg, famotidine), allowing for superior ulcer healing during PUD treatment. However, neither medication would prevent ulcer recurrence, which requires *H pylori* eradication.

(Choice E) Metoclopramide is a dopamine antagonist with prokinetic and antiemetic properties that can be used to treat gastrointestinal motility disorders (eg, gastroparesis); however, it does not significantly affect PUD.

(Choice F) Prostaglandin analogues such as misoprostol are used to prevent NSAID-induced peptic ulcers.

Educational objective:
Most duodenal peptic ulcers are caused by *Helicobacter pylori* infection. Treatment and prevention of disease recurrence focus on eradicating the infection with antibiotics (eg, tetracycline, metronidazole), typically in combination with proton pump inhibitors (eg, omeprazole) and, often, bismuth subsalicylate (quadruple therapy).

https://t.me/USMLEWorldStep1

A 68-year-old woman comes to the emergency department due to shortness of breath, poor appetite, and abdominal distension for the past 3 months. Her symptoms have progressively worsened, and now she is unable to perform her daily activities. The patient has a history of coronary artery disease and underwent coronary artery bypass grafting 3 years ago. She also has myelodysplastic syndrome for which she receives intermittent blood transfusions. Physical examination shows jugular venous distension, abdominal distension, hepatomegaly, and lower extremity edema. A representative liver biopsy image is shown in the exhibit. Which of the following is the most likely cause of this patient's liver findings?

- A. Autoimmune biliary destruction
- B. Excessive deposition of iron
- C. Hepatitis virus infection
- D. Metastatic spread to the liver
- E. Passive hepatic congestion

Submit

https://t.me/USMLEWorldStep1

A 68-year-old woman comes to the emergency department due to shortness of breath, poor appetite, and abdom
to perf
bypas
transfu
lower
most li

Sub

Exhibit Display

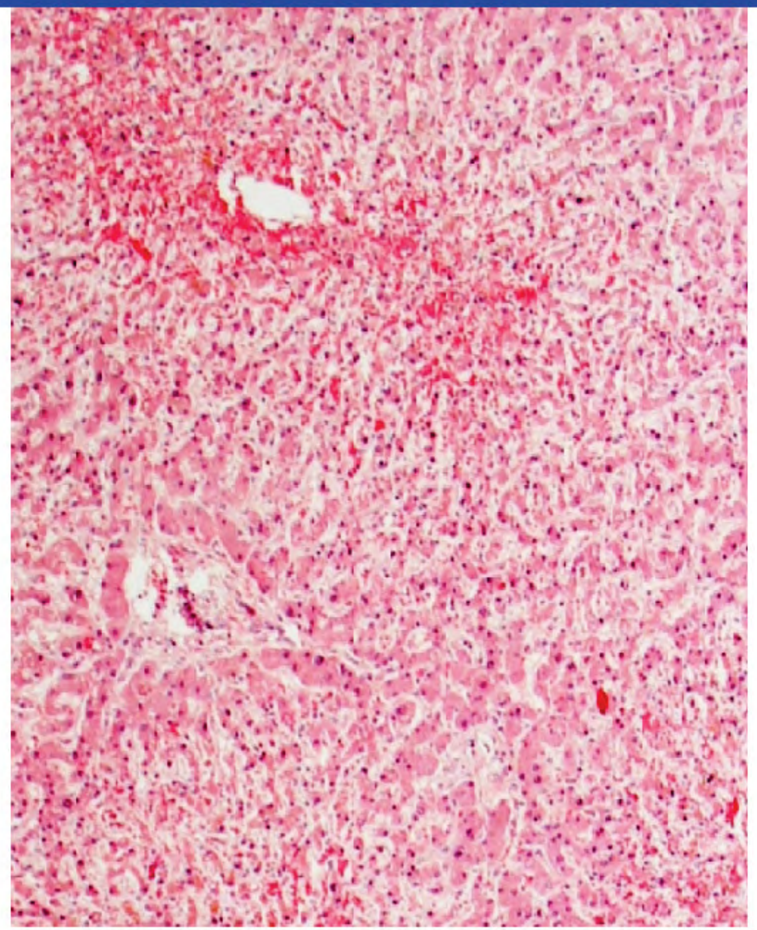

Zoom In Zoom Out Reset New | Existing My Notebook

https://t.me/USMLEWorldStep1

A 68-year-old woman comes to the emergency department due to shortness of breath, poor appetite, and abdominal distension for the past 3 months. Her symptoms have progressively worsened, and now she is unable to perform her daily activities. The patient has a history of coronary artery disease and underwent coronary artery bypass grafting 3 years ago. She also has myelodysplastic syndrome for which she receives intermittent blood transfusions. Physical examination shows jugular venous distension, abdominal distension, hepatomegaly, and lower extremity edema. A representative liver biopsy image is shown in the exhibit. Which of the following is the most likely cause of this patient's liver findings?

- A. Autoimmune biliary destruction (3%)
- B. Excessive deposition of iron (26%)
- ✗ C. Hepatitis virus infection (8%)
- D. Metastatic spread to the liver (2%)
- ✓ E. Passive hepatic congestion (58%)

Incorrect
Correct answer
E

58%
Answered correctly

13 secs
Time Spent

2023
Version

Explanation

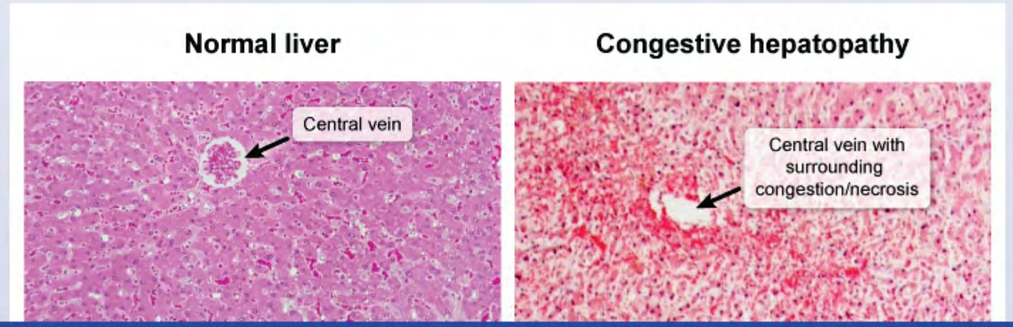

https://t.me/USMLEWorldStep1

A 68-year-old woman comes to the emergency department due to shortness of breath, poor appetite, and abdom
to perf
bypas
transfu
lower
most li

Exhibit Display

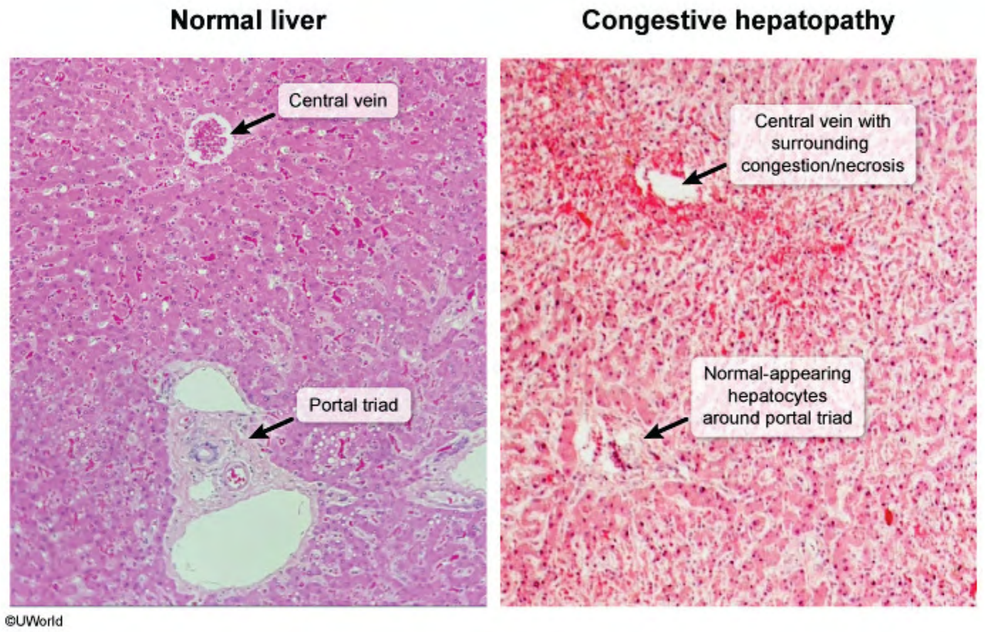

Zoom In Zoom Out Reset New | Existing My Notebook

This patient's shortness of breath—accompanied by abdominal distension (ascites), hepatomegaly, jugular venous distension, and lower extremity edema—is consistent with **right-sided heart failure**; her liver biopsy demonstrates evidence of **congestive hepatopathy**.

In congestive hepatopathy, outflow of blood from the hepatic veins is impeded by elevated right atrial and vena caval pressures, which leads to **increased hydrostatic pressure** in the central veins of the liver. There is consequent seepage of fluid into the surrounding hepatocytes with resulting congestion and hepatic necrosis. The hepatocellular damage favors the centrilobular areas (zone 3) where congestion is most prominent. On microscopy, patchy hemorrhage is seen surrounding the central veins consistent with **centrilobular necrosis**. These areas of necrosis contrast with the relatively normal-appearing hepatocytes in the periportal regions (zone 1), creating an overall heterogenous appearance sometimes referred to as "**nutmeg liver**."

In addition to signs and symptoms of right-sided heart failure, patients with congestive hepatopathy may have localized right upper quadrant pain (due to stretching of the hepatic capsule), and laboratory results may demonstrate modest elevations in serum bilirubin and transaminases.

(Choice A) Autoimmune destruction of intrahepatic biliary ducts occurs in primary biliary cholangitis (formerly primary biliary cirrhosis). Because intrahepatic bile ducts are concentrated in the periportal regions, histopathology demonstrates periductal fibrosis predominantly in those regions.

(Choice B) Excessive hepatic deposition of iron most commonly occurs due to hemochromatosis. Patients receiving frequent blood transfusions are also at risk; however, histopathology would demonstrate periportal fibrosis and numerous brown pigments representing iron deposits. Fibrosis favors the periportal regions likely because those hepatocytes are exposed to the highest concentrations of iron-rich blood coming from the portal vein.

(Choice C) Histopathology in chronic viral hepatitis (eg, chronic hepatitis C) reveals dense infiltrate of mononuclear inflammatory cells in the periportal regions; there is often gradual development of periportal fibrosis that may eventually bridge to the centrilobular regions.

(Choice D) Histopathology of metastatic spread to the liver is unlikely to demonstrate a consistent pattern of lobular necrosis, but it can reveal an abrupt demarcation between normal hepatocellular tissue and the metastatic tumor.

https://t.me/USMLEWorldStep1

hepatocellular damage favors the centrilobular areas (zone 3) where congestion is most prominent. On microscopy, patchy hemorrhage is seen surrounding the central veins consistent with **centrilobular necrosis**. These areas of necrosis contrast with the relatively normal-appearing hepatocytes in the periportal regions (zone 1), creating an overall heterogenous appearance sometimes referred to as "**nutmeg liver**."

In addition to signs and symptoms of right-sided heart failure, patients with congestive hepatopathy may have localized right upper quadrant pain (due to stretching of the hepatic capsule), and laboratory results may demonstrate modest elevations in serum bilirubin and transaminases.

(Choice A) Autoimmune destruction of intrahepatic biliary ducts occurs in primary biliary cholangitis (formerly primary biliary cirrhosis). Because intrahepatic bile ducts are concentrated in the periportal regions, histopathology demonstrates periductal fibrosis predominantly in those regions.

(Choice B) Excessive hepatic deposition of iron most commonly occurs due to hemochromatosis. Patients receiving frequent blood transfusions are also at risk; however, histopathology would demonstrate periportal fibrosis and numerous brown pigments representing iron deposits. Fibrosis favors the periportal regions likely because those hepatocytes are exposed to the highest concentrations of iron-rich blood coming from the portal vein.

(Choice C) Histopathology in chronic viral hepatitis (eg, chronic hepatitis C) reveals dense infiltrate of mononuclear inflammatory cells in the periportal regions; there is often gradual development of periportal fibrosis that may eventually bridge to the centrilobular regions.

(Choice D) Histopathology of metastatic spread to the liver is unlikely to demonstrate a consistent pattern of lobular necrosis, but it can reveal an abrupt demarcation between normal hepatocellular tissue and the metastatic tumor.

Educational objective:
Congestive hepatopathy is a common complication of right-sided heart failure. Patchy hemorrhage and necrosis predominantly affect the centrilobular regions (zone 3) where hepatic congestion is most prominent. The centrilobular necrosis, combined with relatively normal-appearing periportal regions (zone 1), creates an overall heterogenous appearance sometimes referred to as "nutmeg liver."

https://t.me/USMLEWorldStep1

This patient's shortness of breath—accompanied by abdominal distension (ascites), hepatomegaly, jugular venous distens
evider

In con
caval p
conse
hepato
micros
These
1), cre

In add
localiz
demor

(Choi
primar
demor

(Choi
receivi
fibrosis
becau
vein.

(Choi
monor
that m

(Choi
lobular necrosis, but it can reveal an abrupt demarcation between normal hepatocellular tissue and the metastatic tumor

Exhibit Display

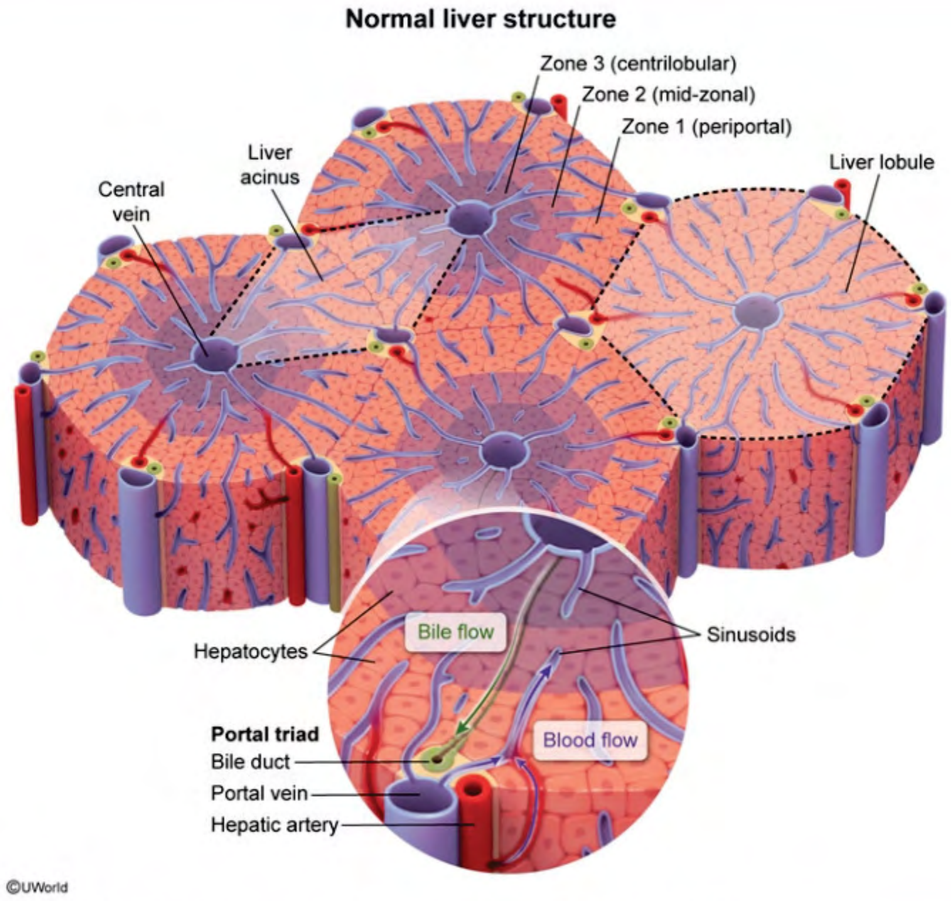

Zoom In | Zoom Out | Reset | New | Existing | My Notebook

https://t.me/USMLEWorldStep1

This patient's shortness of breath—accompanied by abdominal distension (ascites), hepatomegaly, jugular venous
disten
evider

In con
caval
conse
hepat
micros
These
1), cre

In add
localiz
demor

(Choi
primar
demor

(Choi
receiv
fibrosi
becau
vein.

(Choi
monor
that m

(Choi
lobular necrosis, but it can reveal an abrupt demarcation between normal hepatocellular tissue and the metastatic
tumor

Exhibit Display

Primary biliary cholangitis

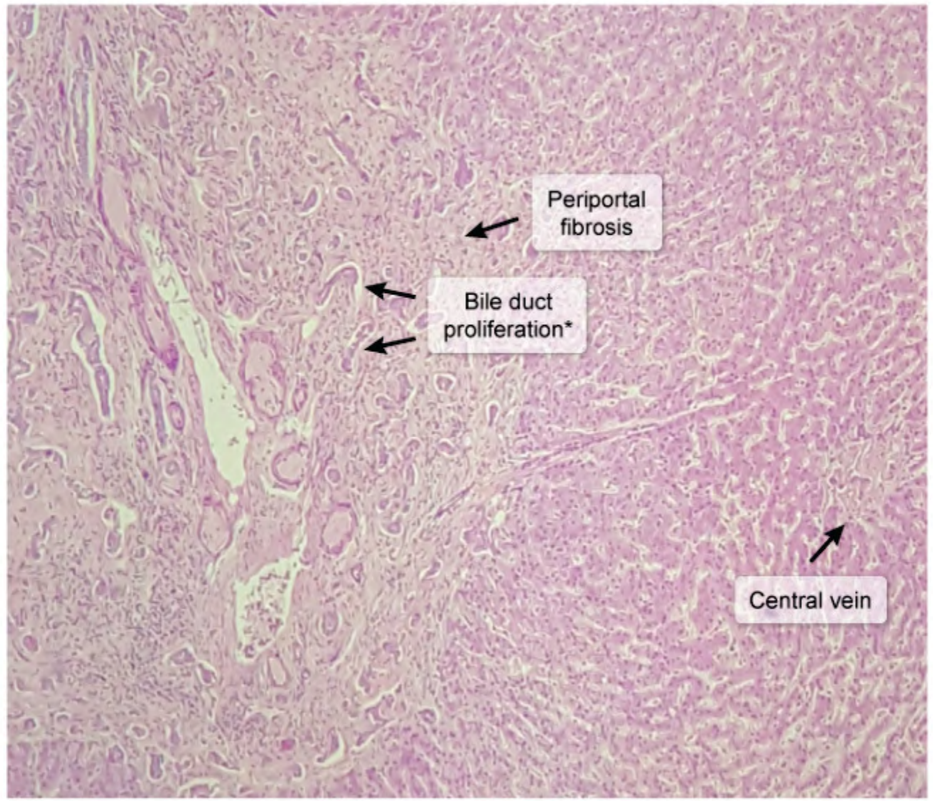

*Follow initial immune-mediated bile duct destruction.

©UWorld

Zoom In | Zoom Out | Reset | New | Existing | My Notebook

https://t.me/USMLEWorldStep1

In congestive hepatopathy, outflow of blood from the hepatic veins is impeded by elevated right atrial and vena caval p
conse
hepat
micros
These
1), cre

In add
localiz
demor

(Choi
primar
demor

(Choi
receiv
fibrosi
becau
vein.

(Choi
monor
that m

(Choi
lobular
tumor.

Educa

Congestive hepatopathy is a common complication of right-sided heart failure. Patchy hemorrhage and necrosis predominantly affect the centrilobular regions (zone 3) where hepatic congestion is most prominent. The

Exhibit Display

Hemochromatosis

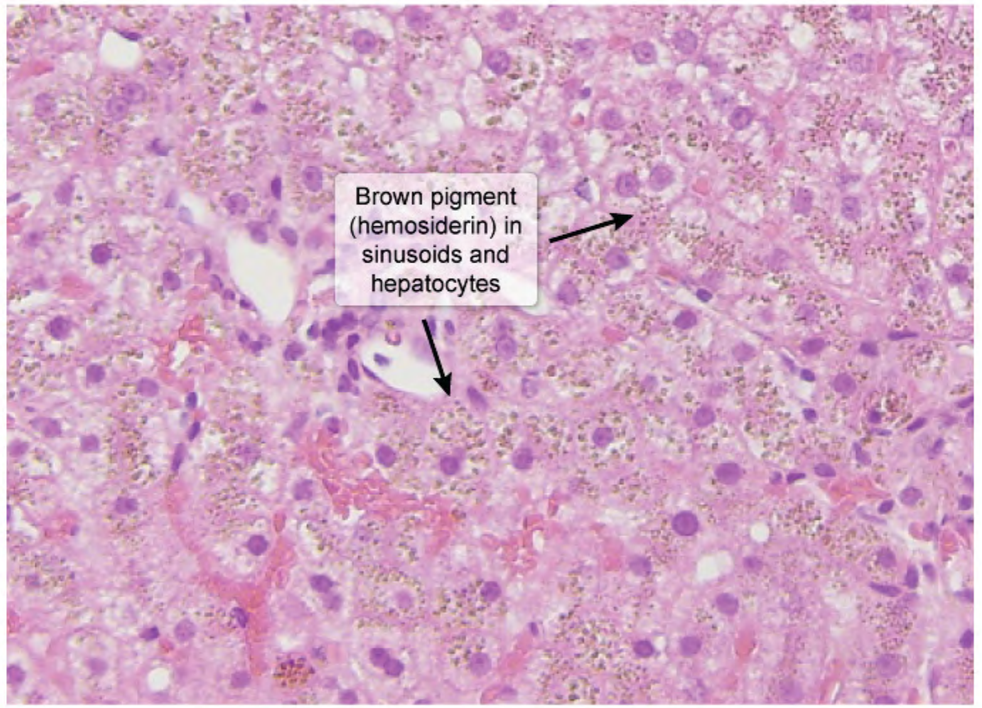

Liver biopsy – H&E

©UWorld

Zoom In | Zoom Out | Reset | New | Existing | My Notebook

https://t.me/USMLEWorldStep1

In congestive hepatopathy, outflow of blood from the hepatic veins is impeded by elevated right atrial and vena caval p
conse
hepat
micros
These
1), cre

In add
localiz
demor

(Choi
primar
demor

(Choi
receiv
fibrosi
becau
vein.

(Choi
monor
that m

(Choi
lobular
tumor.

Educa
Congestive hepatopathy is a common complication of right-sided heart failure. Patchy hemorrhage and necrosis predominantly affect the centrilobular regions (zone 3) where hepatic congestion is most prominent. The

Exhibit Display

Hemochromatosis

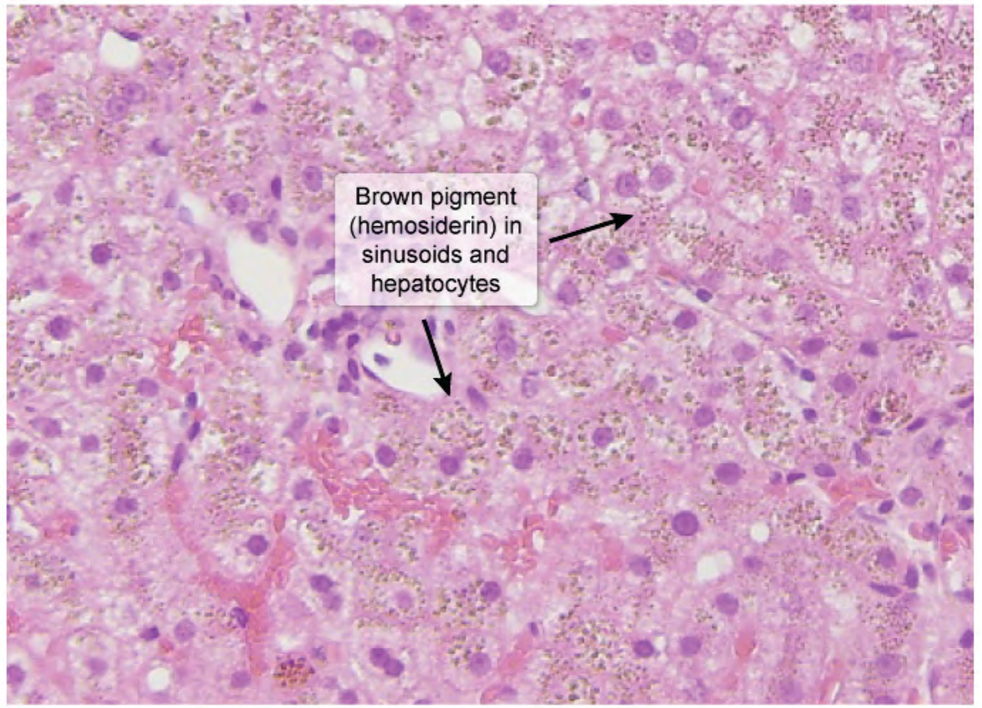

Liver biopsy – H&E

©UWorld

Zoom In | Zoom Out | Reset | New | Existing | My Notebook

https://t.me/USMLEWorldStep1

hepatocellular damage favors the centrilobular areas (zone 3) where congestion is most prominent. On microscopy, patchy hemorrhage is seen surrounding the central veins consistent with **centrilobular necrosis**.

These

1), cre

In add

localiz

demor

(Choi

primar

demor

(Choi

receiv

fibrosi

becau

vein.

(Choi

monor

that m

(Choi

lobular

tumor.

Educa

Conge

predor

centril

heterogeneous appearance sometimes referred to as "nutmeg liver."

Exhibit Display

Acute hepatitis

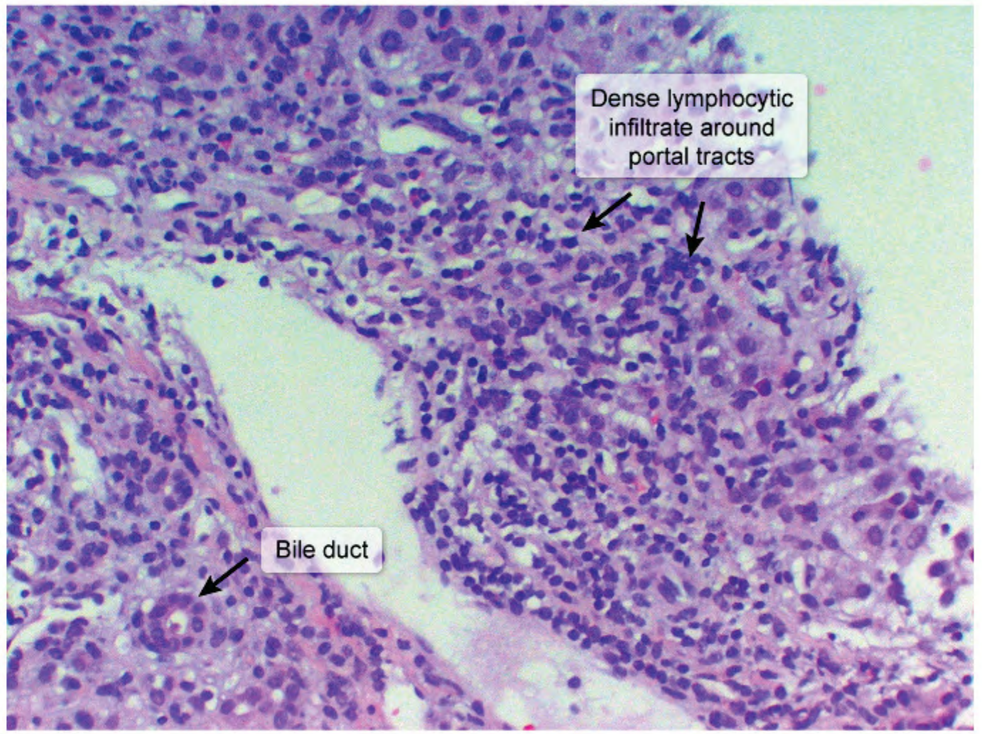

©UWorld

Zoom In | Zoom Out | Reset | New | Existing | My Notebook

https://t.me/USMLEWorldStep1

hepatocellular damage favors the centrilobular areas (zone 3) where congestion is most prominent. On microscopy, patchy hemorrhage is seen surrounding the central veins consistent with **centrilobular necrosis**.

These

1), cre

In add

localiz

demor

(Choi

primar

demor

(Choi

receiv

fibrosi

becau

vein.

(Choi

monor

that m

(Choi

lobular

tumor.

Educa

Conge

predor

centril

heterogeneous appearance sometimes referred to as "nutmeg liver."

Exhibit Display

Malignant clear cell renal carcinoma

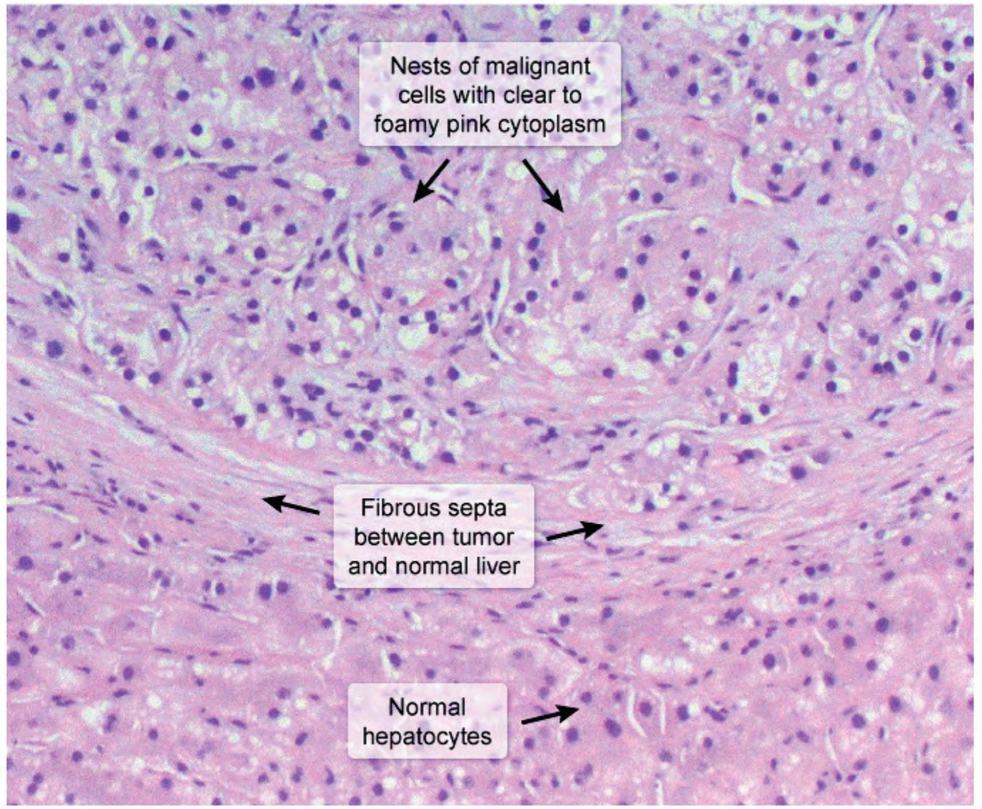

©UWorld

Zoom In | Zoom Out | Reset | New | Existing | My Notebook

https://t.me/USMLEWorldStep1

Biochemists identify a mutation affecting the trypsinogen molecule that disrupts a critical site on the protein involved in inhibiting the active trypsin moiety. This mutation prevents trypsin from being permanently inactivated by enzymatic cleavage. Patients with this mutation would most likely suffer from which of the following conditions?

- A. Gastric cancer
- B. Liver cirrhosis
- C. Megaloblastic anemia
- D. Pancreatitis
- E. Peptic ulcer

Submit

https://t.me/USMLEWorldStep1

Biochemists identify a mutation affecting the trypsinogen molecule that disrupts a critical site on the protein involved in inhibiting the active trypsin moiety. This mutation prevents trypsin from being permanently inactivated by enzymatic cleavage. Patients with this mutation would most likely suffer from which of the following conditions?

- ✗ A. Gastric cancer (1%)
- B. Liver cirrhosis (4%)
- C. Megaloblastic anemia (4%)
- ✓ D. Pancreatitis (77%)
- E. Peptic ulcer (11%)

Incorrect
Correct answer
D

77%
Answered correctly

03 secs
Time Spent

2023
Version

Explanation

Pancreatic enzymes (except amylase and lipase) are synthesized and secreted in inactive form to protect the pancreas from autodigestion. These proenzymes (zymogens) are then activated by trypsin in the duodenal lumen after trypsinogen is converted into its active form, **trypsin**, by the action of duodenal enterokinase. Trypsin can also activate other trypsinogen molecules; therefore, even small amounts of it can result in an **activation cascade**. Because of trypsin's central role in the activation of pancreatic digestive proenzymes, multiple protective mechanisms exist to limit the amount of trypsinogen that becomes prematurely activated:

- Serine peptidase inhibitor Kazal-type 1 (**SPINK1**) is secreted by pancreatic acinar cells and functions as a **trypsin inhibitor**. It impedes the activity of trypsinogen molecules that become prematurely activated within the pancreas.
- In addition to functioning as its own activator, trypsin can serve as its own inhibitor by cleaving active trypsin molecules at a second site, rendering them inactive.

https://t.me/USMLEWorldStep1

Explanation

Pancreatic enzymes (except amylase and lipase) are synthesized and secreted in inactive form to protect the pancreas from autodigestion. These proenzymes (zymogens) are then activated by trypsin in the duodenal lumen after trypsinogen is converted into its active form, **trypsin**, by the action of duodenal enterokinase. Trypsin can also activate other trypsinogen molecules; therefore, even small amounts of it can result in an **activation cascade**. Because of trypsin's central role in the activation of pancreatic digestive proenzymes, multiple protective mechanisms exist to limit the amount of trypsinogen that becomes prematurely activated:

- Serine peptidase inhibitor Kazal-type 1 (**SPINK1**) is secreted by pancreatic acinar cells and functions as a **trypsin inhibitor**. It impedes the activity of trypsinogen molecules that become prematurely activated within the pancreas.
- In addition to functioning as its own activator, trypsin can serve as its own inhibitor by cleaving active trypsin molecules at a second site, rendering them inactive.

Hereditary pancreatitis is a rare disorder that results from mutations involving the trypsinogen or *SPINK1* gene. The most common mutation leads to the production of **abnormal trypsin** that is not susceptible to **inactivating cleavage** by trypsin. Because a small amount of trypsinogen normally activates prematurely within the pancreatic acini and ducts, these protective mechanisms are critical for preventing recurrent attacks of acute pancreatitis.

(Choices A and E) Peptic ulcer disease and gastric adenocarcinoma are strongly associated with *Helicobacter pylori* infection.

(Choice B) Patients with mutations affecting the serum protease inhibitor, alpha-1-antitrypsin, can have emphysema and liver cirrhosis. However, there is no association between cirrhosis and trypsinogen gene mutations.

(Choice C) Megaloblastic anemia is due to deficiencies of vitamin B_{12} and folate. It is also associated with a number of drugs (eg, methotrexate, phenytoin) and certain inborn metabolic errors.

Educational objective:

https://t.me/USMLEWorldStep1

also activate other trypsinogen molecules; therefore, even small amounts of it can result in an **activation cascade**. Because of trypsin's central role in the activation of pancreatic digestive proenzymes, multiple protective mechanisms exist to limit the amount of trypsinogen that becomes prematurely activated:

- Serine peptidase inhibitor Kazal-type 1 (**SPINK1**) is secreted by pancreatic acinar cells and functions as a **trypsin inhibitor**. It impedes the activity of trypsinogen molecules that become prematurely activated within the pancreas.
- In addition to functioning as its own activator, trypsin can serve as its own inhibitor by cleaving active trypsin molecules at a second site, rendering them inactive.

Hereditary pancreatitis is a rare disorder that results from mutations involving the trypsinogen or *SPINK1* gene. The most common mutation leads to the production of **abnormal trypsin** that is not susceptible to **inactivating cleavage** by trypsin. Because a small amount of trypsinogen normally activates prematurely within the pancreatic acini and ducts, these protective mechanisms are critical for preventing recurrent attacks of acute pancreatitis.

(Choices A and E) Peptic ulcer disease and gastric adenocarcinoma are strongly associated with *Helicobacter pylori* infection.

(Choice B) Patients with mutations affecting the serum protease inhibitor, alpha-1-antitrypsin, can have emphysema and liver cirrhosis. However, there is no association between cirrhosis and trypsinogen gene mutations.

(Choice C) Megaloblastic anemia is due to deficiencies of vitamin B_{12} and folate. It is also associated with a number of drugs (eg, methotrexate, phenytoin) and certain inborn metabolic errors.

Educational objective:
Multiple inhibitory mechanisms exist to prevent premature activation of trypsinogen before it reaches the duodenal lumen, including cleavage inactivation of trypsin by trypsin itself and production of trypsin inhibitors (eg, SPINK1). Gene mutations that render trypsin insensitive to cleavage inactivation cause hereditary pancreatitis.

Pathophysiology	Gastrointestinal & Nutrition	Acute pancreatitis
Subject	System	Topic

Copyright © UWorld. All rights reserved.

https://t.me/USMLEWorldStep1

Exhibit Display

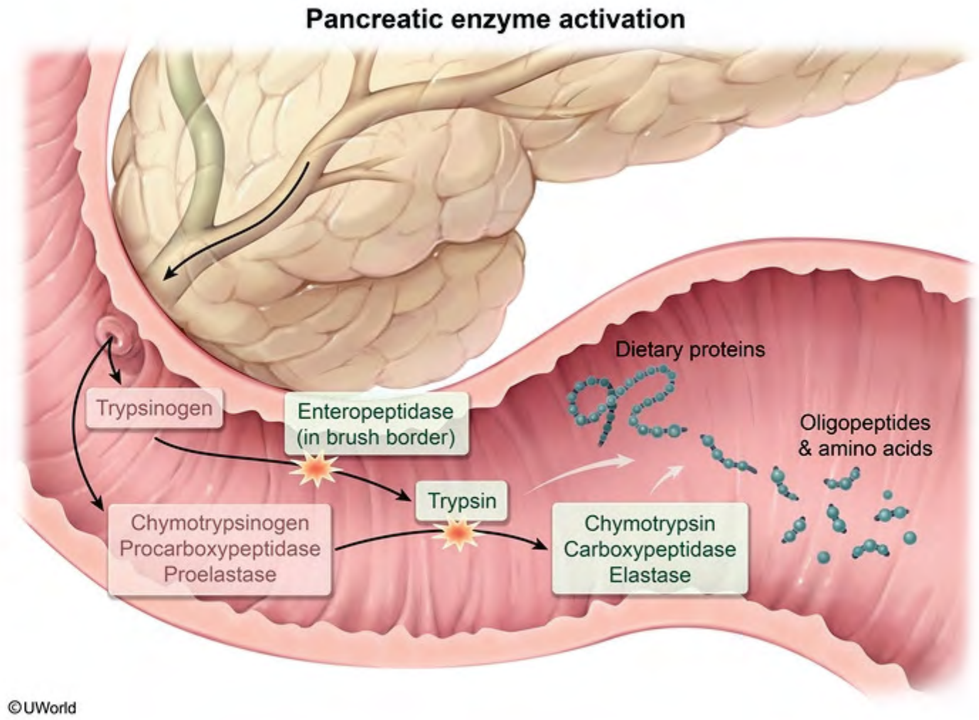

Zoom In | Zoom Out | Reset | New | Existing | My Notebook

Expl

Pancre
pancre
after tr
also a
casca
mecha

- S
  tr
  th
- In
  m

Hered
The m
cleava
acini a

(Choi
pylori

(Choi
emphy
mutati

(Choice C) Megaloblastic anemia is due to deficiencies of vitamin B_{12} and folate. It is also associated with a number of drugs (eg, methotrexate, phenytoin) and certain inborn metabolic errors.

Educational objective:

https://t.me/USMLEWorldStep1

A 46-year-old obese man is referred to a dietitian for evaluation of his food intake. He has been trying to lose weight but has been unsuccessful. The patient is 172.7 cm (5 ft 8 in) tall and weighs 113 kg (250 lb). Analysis of his food intake shows that he is consuming 3600 Calories a day. The dietitian recommends increasing physical activity and implementing a dietary plan. In the first phase, the patient is advised to reduce his daily dietary intake to 3,000 Calories, with 30% coming from protein. How much protein per day will this patient consume on the new dietary plan?

- A. 130 g
- B. 160 g
- C. 180 g
- D. 225 g
- E. 250 g

Submit

https://t.me/USMLEWorldStep1

A 46-year-old obese man is referred to a dietitian for evaluation of his food intake. He has been trying to lose weight but has been unsuccessful. The patient is 172.7 cm (5 ft 8 in) tall and weighs 113 kg (250 lb). Analysis of his food intake shows that he is consuming 3600 Calories a day. The dietitian recommends increasing physical activity and implementing a dietary plan. In the first phase, the patient is advised to reduce his daily dietary intake to 3,000 Calories, with 30% coming from protein. How much protein per day will this patient consume on the new dietary plan?

- A. 130 g (8%)
- ✕ B. 160 g (6%)
- C. 180 g (17%)
- ✓ D. 225 g (58%)
- E. 250 g (8%)

Incorrect
Correct answer
D

58%
Answered correctly

03 secs
Time Spent

2023
Version

Explanation

Dietary energy comes predominantly from protein, carbohydrate, and fat. Metabolism yields 4 Calories (Cal) per gram of protein or carbohydrate and 9 Cal per gram of fat. Ethanol yields 7 Cal per gram.

This patient is instructed to consume 3000 Cal per day, 900 (30%) of which are to be from protein. Because 1 g of protein yields 4 Cal of energy, this patient should consume (900 Cal /4 Cal) = 225 g/day of protein.

Educational objective:
Metabolism of 1 g of protein or carbohydrate produces 4 Calories of energy; metabolism of 1 g of fat produces 9 Calories.

https://t.me/USMLEWorldStep1

his food intake shows that he is consuming 3600 Calories a day. The dietitian recommends increasing physical activity and implementing a dietary plan. In the first phase, the patient is advised to reduce his daily dietary intake to 3,000 Calories, with 30% coming from protein. How much protein per day will this patient consume on the new dietary plan?

- A. 130 g (8%)
- ✕ B. 160 g (6%)
- C. 180 g (17%)
- ✓ D. 225 g (58%)
- E. 250 g (8%)

Incorrect
Correct answer
D

58%
Answered correctly

03 secs
Time Spent

2023
Version

Explanation

Dietary energy comes predominantly from protein, carbohydrate, and fat. Metabolism yields 4 Calories (Cal) per gram of protein or carbohydrate and 9 Cal per gram of fat. Ethanol yields 7 Cal per gram.

This patient is instructed to consume 3000 Cal per day, 900 (30%) of which are to be from protein. Because 1 g of protein yields 4 Cal of energy, this patient should consume (900 Cal /4 Cal) = 225 g/day of protein.

Educational objective:
Metabolism of 1 g of protein or carbohydrate produces 4 Calories of energy; metabolism of 1 g of fat produces 9 Calories.

Biochemistry	Gastrointestinal & Nutrition	Obesity
Subject	System	Topic

Copyright © UWorld. All rights reserved.

https://t.me/USMLEWorldStep1

A 33-year-old man with a 2-year history of Crohn ileocolitis comes to the clinic with left-sided flank pain that started in the morning. The pain is 8 on a scale of 0-10 in intensity and is characterized as sharp. The pain is also colicky and radiates to the left groin. The patient has no nausea or vomiting. He is in moderate distress and has trouble lying still during the examination. Urinalysis shows hematuria. A day later, the patient passes a urinary stone. Abdominal imaging reveals several additional kidney stones. Which of the following is the most likely underlying cause of this patient's kidney stones?

- A. Defective amino acid transport
- B. Increased bone resorption
- C. Rapid cell turnover
- D. Reduced intestinal calcium oxalate formation
- E. Urinary tract infection

Submit

https://t.me/USMLEWorldStep1

A 33-year-old man with a 2-year history of Crohn ileocolitis comes to the clinic with left-sided flank pain that started in the morning. The pain is 8 on a scale of 0-10 in intensity and is characterized as sharp. The pain is also colicky and radiates to the left groin. The patient has no nausea or vomiting. He is in moderate distress and has trouble lying still during the examination. Urinalysis shows hematuria. A day later, the patient passes a urinary stone. Abdominal imaging reveals several additional kidney stones. Which of the following is the most likely underlying cause of this patient's kidney stones?

- A. Defective amino acid transport (8%)
- ✗ B. Increased bone resorption (8%)
- C. Rapid cell turnover (7%)
- ✓ D. Reduced intestinal calcium oxalate formation (72%)
- E. Urinary tract infection (2%)

Incorrect
Correct answer
D

72%
Answered correctly

03 secs
Time Spent

2023
Version

Explanation

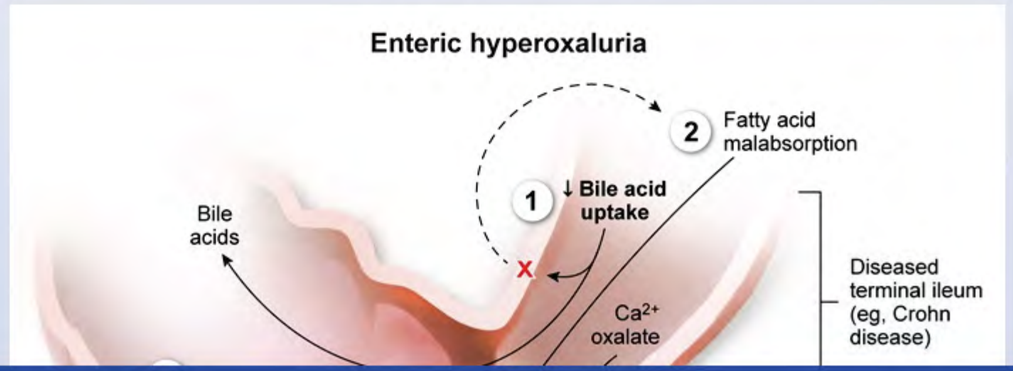

https://t.me/USMLEWorldStep1

A 33-year-old man with a 2-year history of Crohn ileocolitis comes to the clinic with left-sided flank pain that started in the
and ra
lying s
Abdon
cause

Exhibit Display

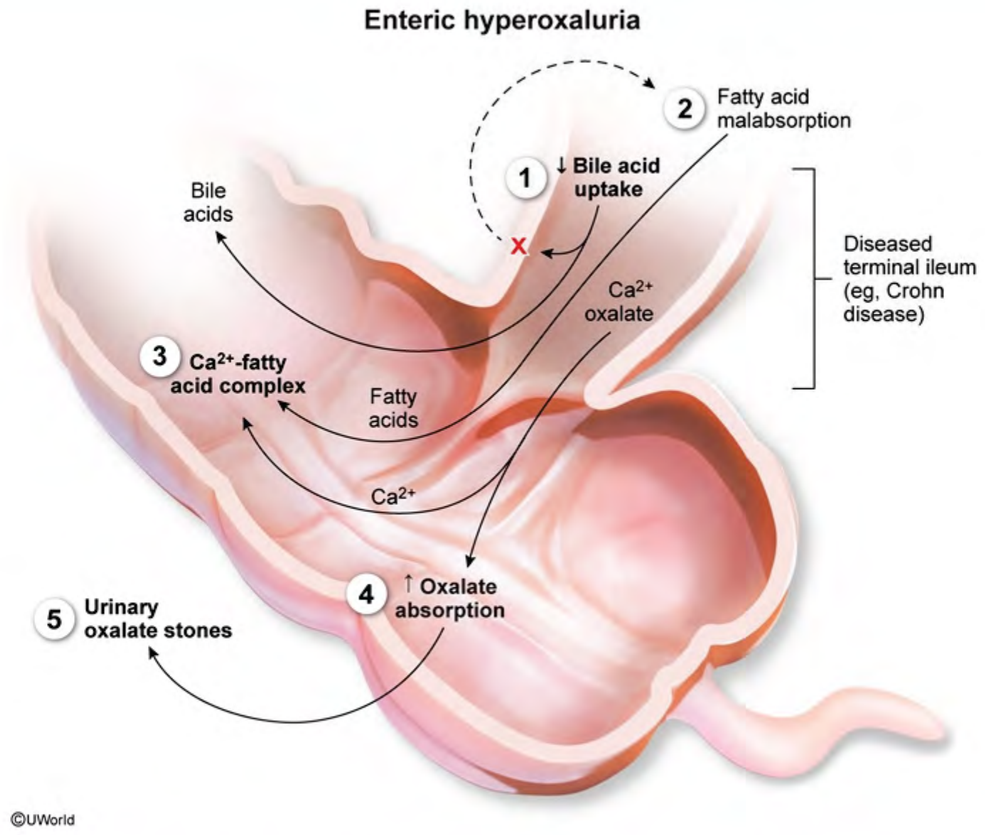

Zoom In | Zoom Out | Reset | New | Existing | My Notebook

https://t.me/USMLEWorldStep1

Crohn disease is an inflammatory bowel disease characterized by patchy granulomatous inflammation. Any area of the gastrointestinal tract may be involved, but involvement of the **terminal ileum** is especially common. Bile acids, which facilitate the absorption of fats and fat-soluble vitamins, are normally reabsorbed in the ileum, recycled in the liver, and then reused in the absorptive process. When the terminal ileum is inflamed, bile acids are lost in the feces, leading to **impaired fat absorption**.

In the healthy bowel, dietary calcium binds to dietary oxalate, producing insoluble calcium oxalate salts that are eliminated in the feces. But in malabsorptive syndromes such as Crohn disease, calcium forms soap complexes with the excess fat in the intestinal lumen and is unavailable for complexing with oxalate. As a result, free **oxalate absorption** is increased and subsequently filtered into the urine, promoting the formation of **oxalate kidney stones** (enteric oxaluria).

(Choice A) Cystinuria is an autosomal recessive condition characterized by defective dibasic amino acid transport in the proximal renal tubules. The urine becomes supersaturated with cystine, leading to formation of cystine stones beginning in childhood or adolescence. Crohn disease can cause malabsorption of dietary protein and amino acids, but this is due to inflammation, not abnormal amino acid transporters; patients are not predisposed to cystine stones.

(Choice B) Patients with Crohn disease commonly develop vitamin/nutrient deficiencies (eg, vitamin D, calcium) due to malabsorption, which can reduce bone mineral density and increase the risk of fractures. Secondary hyperparathyroidism may be present, but unlike primary hyperparathyroidism does not promote kidney stone formation.

(Choice C) Uric acid stones may develop from conditions associated with rapid cell turnover (eg, myeloproliferative disease, hemolytic anemia) due to chronically increased uric acid production. The stones seen in Crohn disease are composed of calcium oxalate rather than uric acid.

(Choice E) Alkalinization of the urine by urease-producing organisms (eg, *Proteus*, *Klebsiella*) in the upper urinary tract can promote formation of stones made up of magnesium ammonium phosphate (struvite) and calcium carbonate apatite. Although patients with Crohn disease can develop enterovesicular fistulas and recurrent urinary tract infections, this patient has no features of urinary infection (eg, fever, dysuria, pyuria).

https://t.me/USMLEWorldStep1

eliminated in the feces. But in malabsorptive syndromes such as Crohn disease, calcium forms soap complexes with the excess fat in the intestinal lumen and is unavailable for complexing with oxalate. As a result, free **oxalate absorption** is increased and subsequently filtered into the urine, promoting the formation of **oxalate kidney stones** (enteric oxaluria).

(Choice A) Cystinuria is an autosomal recessive condition characterized by defective dibasic amino acid transport in the proximal renal tubules. The urine becomes supersaturated with cystine, leading to formation of cystine stones beginning in childhood or adolescence. Crohn disease can cause malabsorption of dietary protein and amino acids, but this is due to inflammation, not abnormal amino acid transporters; patients are not predisposed to cystine stones.

(Choice B) Patients with Crohn disease commonly develop vitamin/nutrient deficiencies (eg, vitamin D, calcium) due to malabsorption, which can reduce bone mineral density and increase the risk of fractures. Secondary hyperparathyroidism may be present, but unlike primary hyperparathyroidism does not promote kidney stone formation.

(Choice C) Uric acid stones may develop from conditions associated with rapid cell turnover (eg, myeloproliferative disease, hemolytic anemia) due to chronically increased uric acid production. The stones seen in Crohn disease are composed of calcium oxalate rather than uric acid.

(Choice E) Alkalinization of the urine by urease-producing organisms (eg, *Proteus*, *Klebsiella*) in the upper urinary tract can promote formation of stones made up of magnesium ammonium phosphate (struvite) and calcium carbonate apatite. Although patients with Crohn disease can develop enterovesicular fistulas and recurrent urinary tract infections, this patient has no features of urinary infection (eg, fever, dysuria, pyuria).

Educational objective:
Crohn disease is associated with oxalate kidney stones. Impaired bile acid absorption in the terminal ileum leads to loss of bile acids in feces with subsequent fat malabsorption. Intestinal lipids then bind calcium ions, and the resulting soap complex is excreted. Free oxalate (normally bound by calcium to form an unabsorbable complex) is absorbed and forms urinary calculi (enteric oxaluria).

References

- Urolithiasis in inflammatory bowel disease and bariatric surgery

https://t.me/USMLEWorldStep1

A 46-year-old homeless man comes to the emergency department with fever and chest pain that worsens with swallowing. The patient has been hospitalized several times recently with *Pneumocystis jirovecii* pneumonia. He has a history of intravenous drug use. His temperature is 37.8 C (100 F). Oropharyngeal examination is remarkable only for poor dentition. Esophagogastroduodenoscopy is performed and reveals esophageal hyperemia and linear ulcerations. Which of the following is the most likely cause of this patient's condition?

- A. *Babesia microti*
- B. *Cryptococcus neoformans*
- C. Cytomegalovirus
- D. *Isospora belli*
- E. *Toxoplasma gondii*
- F. *Trypanosoma cruzi*
- G. Varicella zoster virus

Submit

https://t.me/USMLEWorldStep1

A 46-year-old homeless man comes to the emergency department with fever and chest pain that worsens with swallowing. The patient has been hospitalized several times recently with *Pneumocystis jirovecii* pneumonia. He has a history of intravenous drug use. His temperature is 37.8 C (100 F). Oropharyngeal examination is remarkable only for poor dentition. Esophagogastroduodenoscopy is performed and reveals esophageal hyperemia and linear ulcerations. Which of the following is the most likely cause of this patient's condition?

- A. *Babesia microti* (2%)
- B. *Cryptococcus neoformans* (5%)
- ✓ C. Cytomegalovirus (77%)
- D. *Isospora belli* (3%)
- E. *Toxoplasma gondii* (2%)
- F. *Trypanosoma cruzi* (7%)
- G. Varicella zoster virus (1%)

Correct

77% Answered correctly

04 secs Time Spent

2023 Version

Explanation

HIV-associated esophagitis		
Pathogen	**Endoscopic findings**	**Microscopic findings**
Candida albicans	Patches of adherent, gray/white **pseudomembranes** on erythematous mucosa	**Yeast** cells & pseudohyphae invading mucosal cells

https://t.me/USMLEWorldStep1

Explanation

HIV-associated esophagitis		
Pathogen	**Endoscopic findings**	**Microscopic findings**
Candida albicans	Patches of adherent, gray/white **pseudomembranes** on erythematous mucosa	**Yeast** cells & pseudohyphae invading mucosal cells
HSV-1	Small **vesicles** → **"punched-out" ulcers**	Eosinophilic intranuclear inclusions **(Cowdry type A)** in multinuclear squamous cells at ulcer margins
CMV	**Linear** ulcerations	Intranuclear & cytoplasmic **inclusions**
CMV = cytomegalovirus; **HSV** = herpes simplex virus.		

Pneumocystis jirovecii affects almost exclusively immunocompromised individuals; therefore, it is likely that this patient has HIV. He has now developed the painful swallowing characteristic of **esophagitis**. The 3 main causes of HIV-associated esophagitis are *Candida* (most common), cytomegalovirus (CMV), and herpes simplex virus (HSV). All can manifest as dysphagia (difficulty swallowing) and/or odynophagia (pain on swallowing) and can be difficult to distinguish clinically; however, accurate diagnosis is essential for treatment. **CMV esophagitis** is typically characterized endoscopically by **large, shallow linear ulcerations** (most commonly in the distal esophagus) with intranuclear and cytoplasmic inclusions seen microscopically.

(Choice A) *Babesia microti* is transmitted by a tick bite and causes babesiosis. It is endemic in the northeastern United States and manifests with flulike symptoms, hepatosplenomegaly, and anemia. It often affects asplenic patients.

https://t.me/USMLEWorldStep1

CMV = cytomegalovirus; **HSV** = herpes simplex virus.

Pneumocystis jirovecii affects almost exclusively immunocompromised individuals; therefore, it is likely that this patient has HIV. He has now developed the painful swallowing characteristic of **esophagitis**. The 3 main causes of HIV-associated esophagitis are *Candida* (most common), cytomegalovirus (CMV), and herpes simplex virus (HSV). All can manifest as dysphagia (difficulty swallowing) and/or odynophagia (pain on swallowing) and can be difficult to distinguish clinically; however, accurate diagnosis is essential for treatment. **CMV esophagitis** is typically characterized endoscopically by **large, shallow linear ulcerations** (most commonly in the distal esophagus) with intranuclear and cytoplasmic inclusions seen microscopically.

(Choice A) *Babesia microti* is transmitted by a tick bite and causes babesiosis. It is endemic in the northeastern United States and manifests with flulike symptoms, hepatosplenomegaly, and anemia. It often affects asplenic patients.

(Choice B) *Cryptococcosis* causes meningitis (not esophagitis) in patients with HIV.

(Choice D) *Isospora belli* causes profuse watery diarrhea in patients with HIV. It has no role in the development of esophagitis.

(Choice E) In patients with HIV, *Toxoplasma gondii* causes ring-enhancing brain lesions and chorioretinitis.

(Choice F) *Trypanosoma cruzi* causes Chagas disease (American trypanosomiasis). Chronic disease leads to cardiomyopathy, achalasia, megacolon, and megaureter.

(Choice G) HSV, not varicella zoster virus (VZV), causes esophagitis in patients with HIV. VZV causes chickenpox (varicella) and shingles (zoster).

Educational objective:
Infectious esophagitis is common in patients with HIV. The most common cause is *Candida albicans*, although cytomegalovirus and herpes simplex virus are also frequently implicated. Diagnosis is based on endoscopic and microscopic findings.

Microbiology	Gastrointestinal & Nutrition	Esophagitis
Subject	System	Topic

https://t.me/USMLEWorldStep1

A 27-year-old woman, gravida 1 para 0, with gestational diabetes mellitus comes to the hospital at 38 weeks gestation for evaluation of abdominal pain. The patient is scheduled for an elective cesarean section at 39 weeks as a recent ultrasound revealed that the estimated fetal weight is 5200 g (11 lb 4 oz). Examination reveals that the patient is in active labor and the fetus is in breech presentation; an urgent cesarean section is performed. During the surgery, the rectus abdominus muscle is split vertically, but space appears to be limited. In anticipation of a large-for-gestational-age baby, a decision is made to transect the rectus abdominis muscle. If the rectus abdominis muscle is incised laterally, which of the following structures is at greatest risk of injury?

- A. Deep circumflex iliac artery
- B. Deep inguinal ring
- C. Femoral sheath
- D. Inferior epigastric artery
- E. Lateral femoral cutaneous nerve
- F. Superior epigastric artery

Submit

https://t.me/USMLEWorldStep1

A 27-year-old woman, gravida 1 para 0, with gestational diabetes mellitus comes to the hospital at 38 weeks gestation for evaluation of abdominal pain. The patient is scheduled for an elective cesarean section at 39 weeks as a recent ultrasound revealed that the estimated fetal weight is 5200 g (11 lb 4 oz). Examination reveals that the patient is in active labor and the fetus is in breech presentation; an urgent cesarean section is performed. During the surgery, the rectus abdominus muscle is split vertically, but space appears to be limited. In anticipation of a large-for-gestational-age baby, a decision is made to transect the rectus abdominis muscle. If the rectus abdominis muscle is incised laterally, which of the following structures is at greatest risk of injury?

- ✗ A. Deep circumflex iliac artery (1%)
- B. Deep inguinal ring (4%)
- C. Femoral sheath (4%)
- ✓ D. Inferior epigastric artery (73%)
- E. Lateral femoral cutaneous nerve (4%)
- F. Superior epigastric artery (11%)

Incorrect
Correct answer
D

73%
Answered correctly

03 secs
Time Spent

2023
Version

Explanation

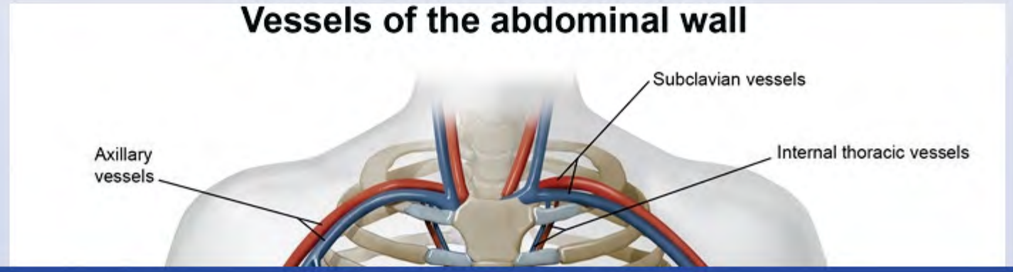

https://t.me/USMLEWorldStep1

Incorrect
Correct answer
D

73%
03 secs
2023

Exhibit Display

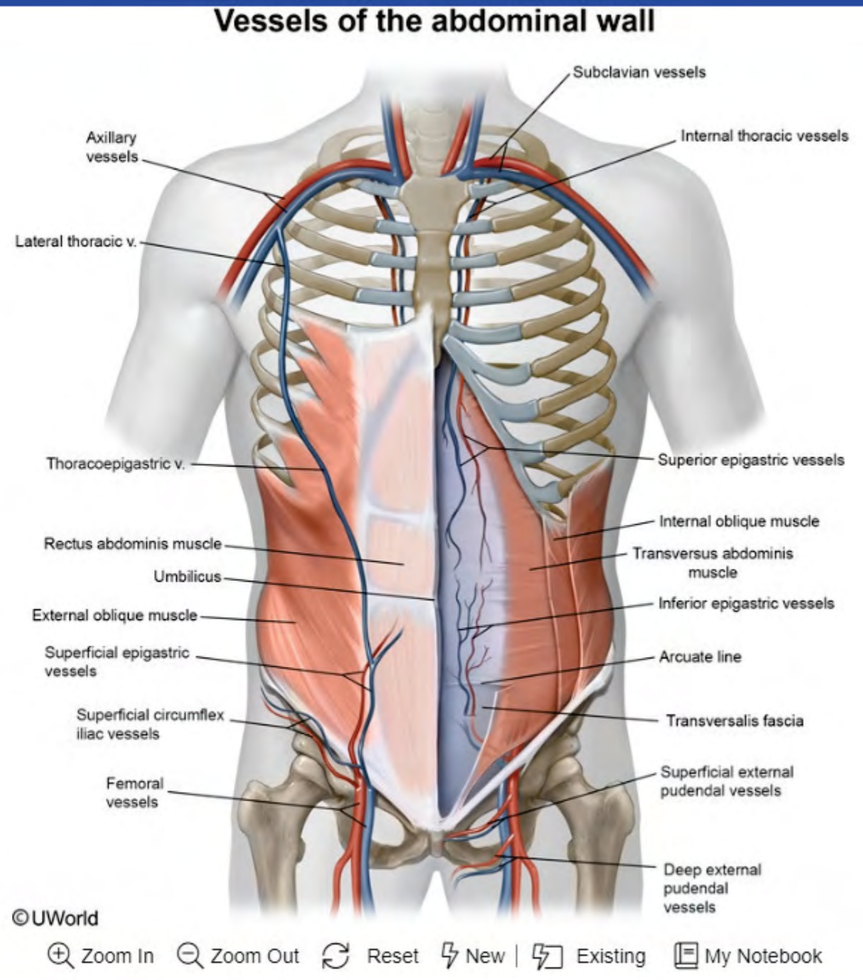

Zoom In | Zoom Out | Reset | New | Existing | My Notebook

https://t.me/USMLEWorldStep1

©UWorld

The rectus abdominis is a pair of vertically aligned muscles that connect the xiphoid process to the pubic symphysis. The **arcuate line** is a horizontal line located below the umbilicus that demarcates the lower limit of the posterior rectus sheath. Above the arcuate line, the rectus abdominis is surrounded by anterior and posterior sheaths; below, the muscle is covered only by the anterior sheath.

The superior **(Choice F)** and inferior epigastric arteries supply the superior and inferior portions of the rectus abdominis muscle, respectively. The epigastric artery ascends the posterior surface of the rectus abdominis muscle and enters the lateral aspect of this muscle at the arcuate line. Because there is **no supporting posterior sheath**, trauma to the **inferior epigastric artery** below the arcuate line can result in significant hemorrhage.

Regardless of the direction of skin incision, a **cesarean delivery** typically involves midline vertical separation of the rectus abdominis muscle. **Horizontal transection** of the **rectus abdominis** muscle may be considered when additional space is necessary (eg, due to fetal weight or position). If the **rectus abdominis** is **transected horizontally**, the **inferior epigastric arteries** must be identified and ligated bilaterally to prevent bleeding complications (eg, hematoma).

(Choice A) The deep circumflex iliac artery supplies blood to the anterior iliac crest and arises from the lateral aspect of the external iliac artery. It is located significantly laterally and inferiorly to the rectus abdominis muscle.

(Choice B) The inguinal canal contains structures (eg, ilioinguinal nerve, round ligament [women], spermatic cord [men]) between the abdomen and external genitalia. Men are more susceptible to inguinal hernias compared to women due to their relatively larger deep inguinal ring.

(Choice C) The femoral sheath is located in the inguinofemoral region and contains the femoral artery, femoral vein, and femoral canal.

(Choice E) The lateral femoral cutaneous nerve travels under the inguinal ligament. It provides sensory innervation to the anterolateral thigh. Entrapment (meralgia paresthetica) most commonly occurs in obese or pregnant persons or in those who wear garments that are tight around the hip.

Educational objective:
Horizontal transection of the rectus abdominis muscle must be performed with great caution as the inferior epigastric arteries enter this muscle at the level of the arcuate line. The inferior epigastric arteries below the

https://t.me/USMLEWorldStep1

posterior rectus sheath. Above the arcuate line, the rectus abdominis is surrounded by anterior and posterior sheaths; below, the muscle is covered only by the anterior sheath.

The superior **(Choice F)** and inferior epigastric arteries supply the superior and inferior portions of the rectus abdominis muscle, respectively. The epigastric artery ascends the posterior surface of the rectus abdominis muscle and enters the lateral aspect of this muscle at the arcuate line. Because there is **no supporting posterior sheath**, trauma to the **inferior epigastric artery** below the arcuate line can result in significant hemorrhage.

Regardless of the direction of skin incision, a **cesarean delivery** typically involves midline vertical separation of the rectus abdominis muscle. **Horizontal transection** of the **rectus abdominis** muscle may be considered when additional space is necessary (eg, due to fetal weight or position). If the **rectus abdominis** is **transected horizontally**, the **inferior epigastric arteries** must be identified and ligated bilaterally to prevent bleeding complications (eg, hematoma).

(Choice A) The deep circumflex iliac artery supplies blood to the anterior iliac crest and arises from the lateral aspect of the external iliac artery. It is located significantly laterally and inferiorly to the rectus abdominis muscle.

(Choice B) The inguinal canal contains structures (eg, ilioinguinal nerve, round ligament [women], spermatic cord [men]) between the abdomen and external genitalia. Men are more susceptible to inguinal hernias compared to women due to their relatively larger deep inguinal ring.

(Choice C) The femoral sheath is located in the inguinofemoral region and contains the femoral artery, femoral vein, and femoral canal.

(Choice E) The lateral femoral cutaneous nerve travels under the inguinal ligament. It provides sensory innervation to the anterolateral thigh. Entrapment (meralgia paresthetica) most commonly occurs in obese or pregnant persons or in those who wear garments that are tight around the hip.

Educational objective:
Horizontal transection of the rectus abdominis muscle must be performed with great caution as the inferior epigastric arteries enter this muscle at the level of the arcuate line. The inferior epigastric arteries below the arcuate line are susceptible to injury (eg, hematoma) due to lack of a supporting posterior rectus sheath.

References

Reviewing the vascular supply of the anterior abdominal wall: redefining anatomy for increasingly refined

https://t.me/USMLEWorldStep1

posterior rectus sheath. Above the arcuate line, the rectus abdominis is surrounded by anterior and posterior sheaths; below, the muscle is covered only by the anterior sheath.

The su
abdom
muscle
sheath

Regar
rectus
additio
horizo
compli

(Choi
aspect

(Choi
[men])
wome

(Choi
vein, a

(Choi
innerv
pregna

Educa
Horizo
epigas
arcuat

References

Exhibit Display

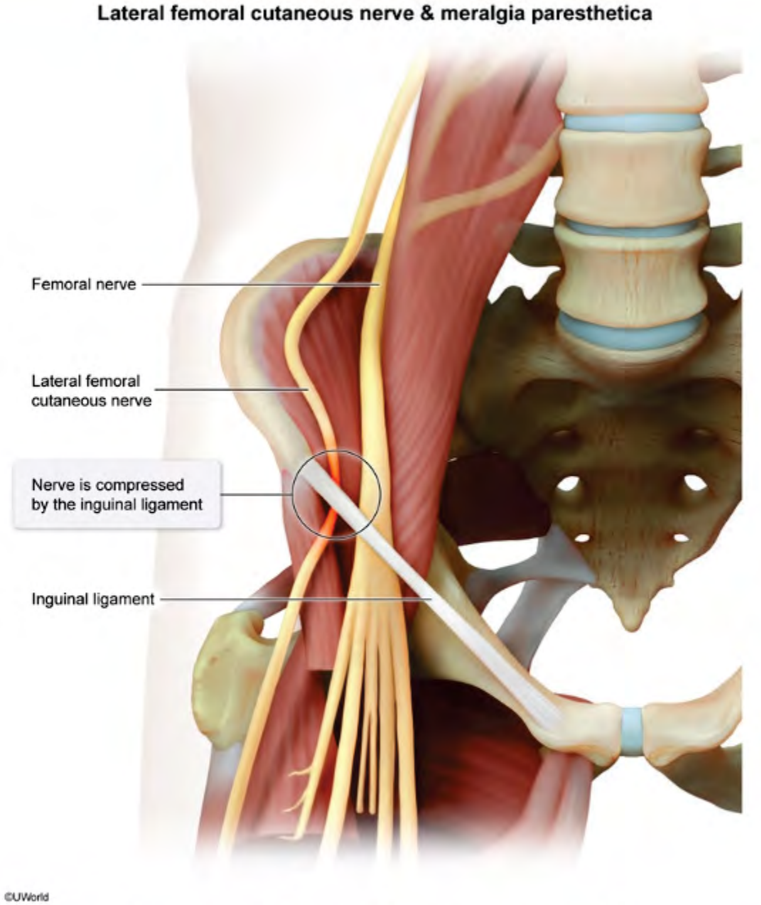

Zoom In | Zoom Out | Reset | New | Existing | My Notebook

https://t.me/USMLEWorldStep1

sheaths; below, the muscle is covered only by the anterior sheath.

The su
abdom
muscle
sheath

Regar
rectus
additio
horizo
compli

(Choi
aspect

(Choi
[men])
wome

(Choi
vein, a

(Choi
innerv
pregna

Educa
Horizo
epigas
arcuat

References

Exhibit Display

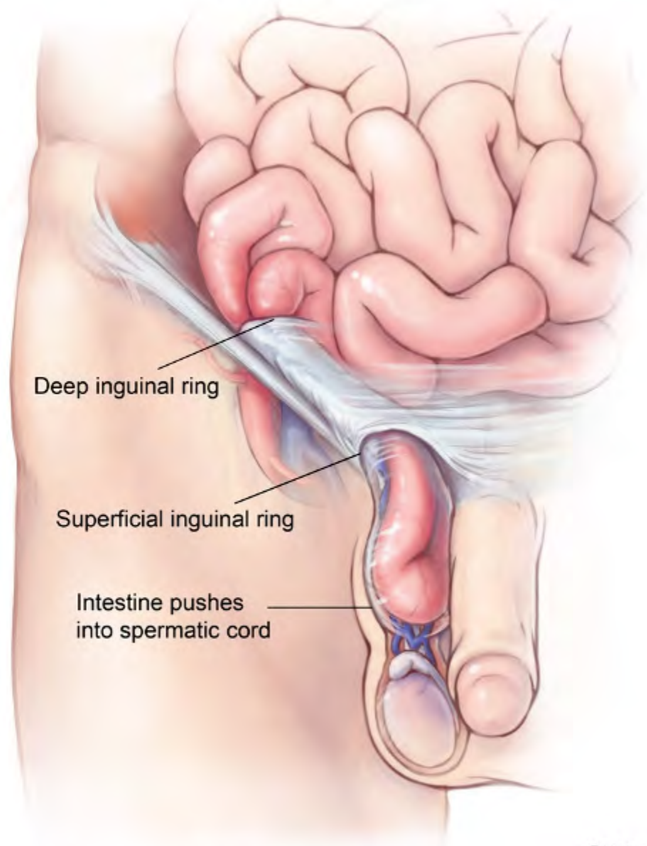

Zoom In | Zoom Out | Reset | New | Existing | My Notebook

https://t.me/USMLEWorldStep1

sheaths; below, the muscle is covered only by the anterior sheath.

The su
abdom
muscle
sheath

Regar
rectus
additio
horizo
compli

(Choi
aspect

(Choi
[men])
wome

(Choi
vein, a

(Choi
innerv
pregna

Educa
Horizo
epigas
arcuat

References

Exhibit Display

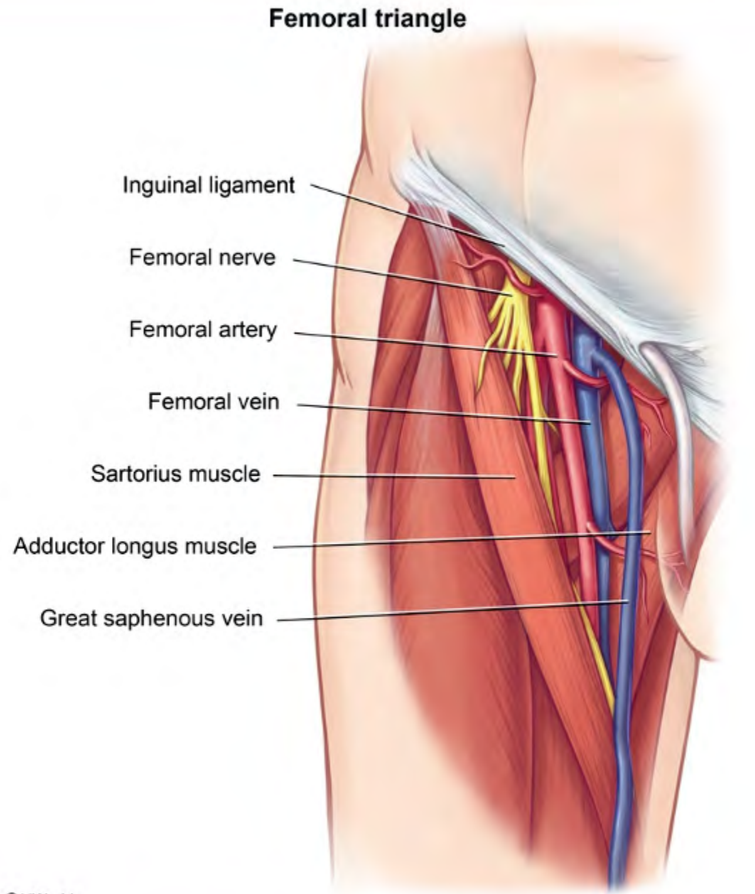

Zoom In | Zoom Out | Reset | New | Existing | My Notebook

https://t.me/USMLEWorldStep1

A 71-year-old man comes to the emergency department due to several episodes of bright red blood per rectum. His recent colonoscopy revealed numerous colonic diverticula. Laboratory studies on admission are notable for a hemoglobin of 8.2 g/dL with an unremarkable coagulation profile. An abdominal angiogram shows active bleeding from the sigmoid colon. Catheter embolization is planned via the femoral artery. During the procedure, the arterial catheter is most likely to proceed in which of the following orders?

- A. External iliac, common iliac, abdominal aorta, celiac
- B. External iliac, common iliac, abdominal aorta, inferior mesenteric
- C. External iliac, common iliac, abdominal aorta, superior mesenteric
- D. External iliac, internal iliac, internal pudendal
- E. External iliac, internal iliac, middle rectal

Submit

https://t.me/USMLEWorldStep1

A 71-year-old man comes to the emergency department due to several episodes of bright red blood per rectum. His recent colonoscopy revealed numerous colonic diverticula. Laboratory studies on admission are notable for a hemoglobin of 8.2 g/dL with an unremarkable coagulation profile. An abdominal angiogram shows active bleeding from the sigmoid colon. Catheter embolization is planned via the femoral artery. During the procedure, the arterial catheter is most likely to proceed in which of the following orders?

- ✗ A. External iliac, common iliac, abdominal aorta, celiac (1%)
- ✓ B. External iliac, common iliac, abdominal aorta, inferior mesenteric (86%)
- C. External iliac, common iliac, abdominal aorta, superior mesenteric (5%)
- D. External iliac, internal iliac, internal pudendal (3%)
- E. External iliac, internal iliac, middle rectal (3%)

Incorrect
Correct answer
B

86%
Answered correctly

03 secs
Time Spent

2023
Version

Explanation

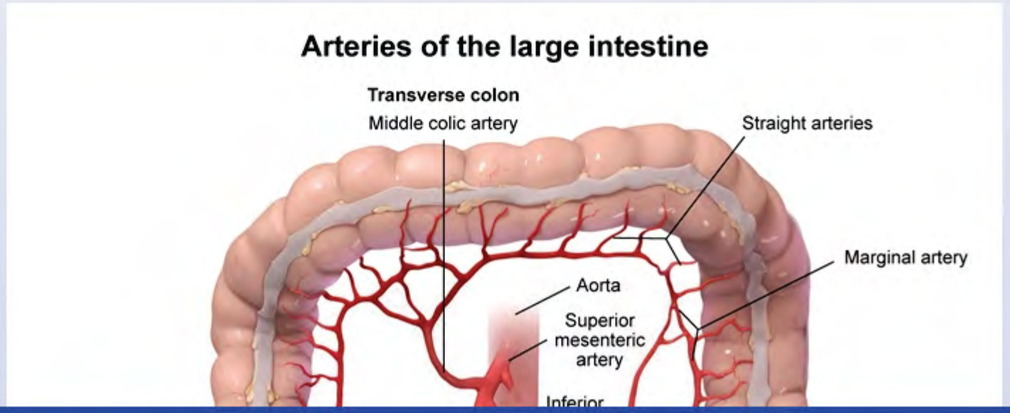

https://t.me/USMLEWorldStep1

D. External iliac, internal iliac, internal pudendal (3%)

Exhibit Display

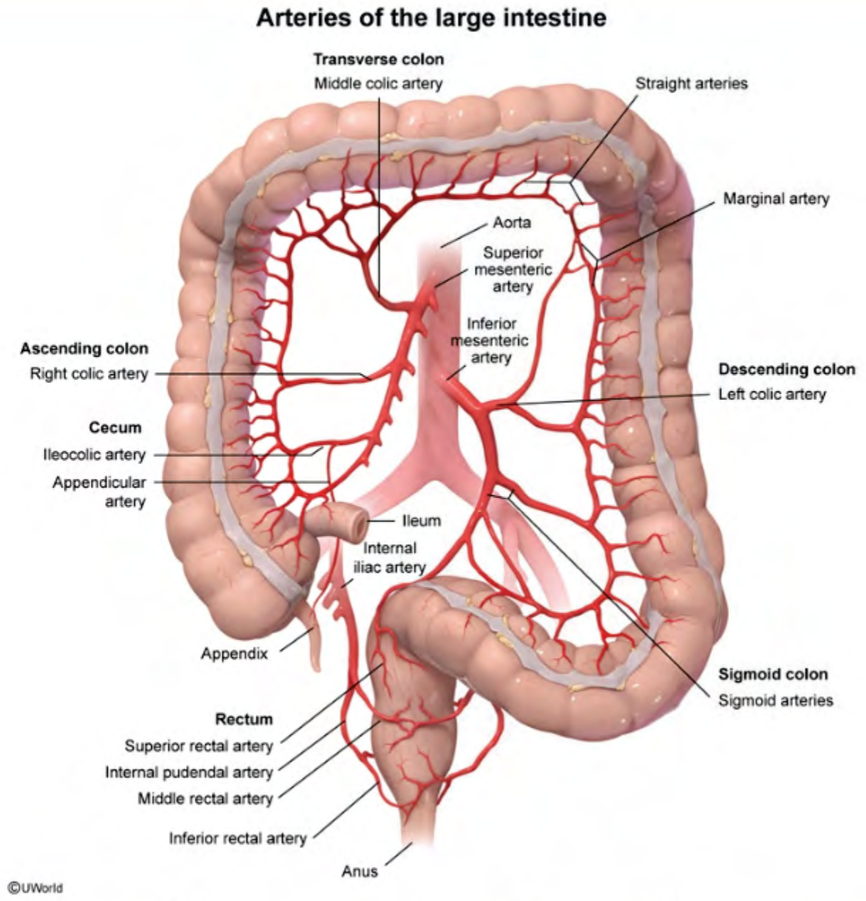

Zoom In | Zoom Out | Reset | New | Existing | My Notebook

https://t.me/USMLEWorldStep1

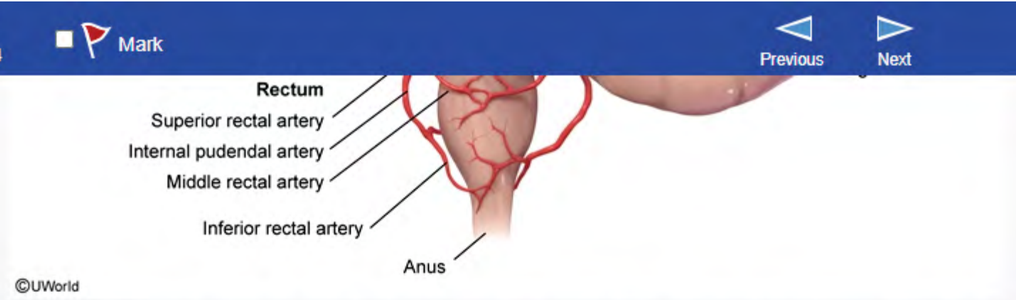

In this patient with recurrent gastrointestinal bleeding, arterial embolization (mechanical occlusion of the artery using coils or absorbable substances) is planned to stop the active bleeding originating from his sigmoid colon. The distal one-third of the transverse colon, descending colon, **sigmoid** colon, and rectum are all **hindgut** derivatives. Hindgut structures receive blood from the **inferior mesenteric artery** (IMA), a branch of the aorta. These structures are drained by the inferior mesenteric vein (IMV), which does not course with the IMA. The IMV drains blood from the hindgut into the splenic vein, which drains into the portal vein.

(Choice A) The celiac trunk supplies blood to most foregut structures from the lower esophagus to the second part of the duodenum. Foregut derivatives include the liver, pancreas, and gallbladder. The celiac trunk also supplies the spleen.

(Choice C) The superior mesenteric artery supplies blood to the midgut, which spans from the third part of the duodenum to the proximal two-thirds of the transverse colon.

(Choices D and E) The internal iliac artery supplies portions of the gut through branches such as the inferior rectal artery (a branch of the internal pudendal artery, which arises from the internal iliac artery) and the middle rectal artery (arises from the internal iliac). The internal pudendal artery supplies blood to the external genitalia. The superior rectal artery is a continuation of the IMA.

Educational objective:
The hindgut encompasses the distal one-third of the transverse colon, the descending colon, the sigmoid colon, and the rectum. These structures receive their main arterial blood supply from the inferior mesenteric artery.

Anatomy	Gastrointestinal & Nutrition	Gastrointestinal hemorrhage
Subject	System	Topic

Copyright © UWorld. All rights reserved.

https://t.me/USMLEWorldStep1

A 72-year-old man develops mild abdominal pain and bloody diarrhea after undergoing urgent cholecystectomy. The surgery was complicated by an episode of hypotension that was treated with bolus intravenous crystalloid fluids. The patient had no previous gastrointestinal bleeding. His last colonoscopy 10 years ago was normal. Past medical history is notable for hypertension, hyperlipidemia, type 2 diabetes mellitus, and a myocardial infarction 7 years ago. The patient smoked for 40 years and quit after the myocardial infarction. Colonoscopy would most likely show pathology in which of the following portions of the large bowel?

- A. Ascending colon
- B. Cecum
- C. Hepatic flexure
- D. Rectosigmoid junction
- E. Mid-transverse colon

Submit

https://t.me/USMLEWorldStep1

A 72-year-old man develops mild abdominal pain and bloody diarrhea after undergoing urgent cholecystectomy. The surgery was complicated by an episode of hypotension that was treated with bolus intravenous crystalloid fluids. The patient had no previous gastrointestinal bleeding. His last colonoscopy 10 years ago was normal. Past medical history is notable for hypertension, hyperlipidemia, type 2 diabetes mellitus, and a myocardial infarction 7 years ago. The patient smoked for 40 years and quit after the myocardial infarction. Colonoscopy would most likely show pathology in which of the following portions of the large bowel?

- A. Ascending colon (10%)
- ✗ B. Cecum (4%)
- C. Hepatic flexure (22%)
- ✓ D. Rectosigmoid junction (43%)
- E. Mid-transverse colon (18%)

Incorrect
Correct answer
D

43%
Answered correctly

04 secs
Time Spent

2023
Version

Explanation

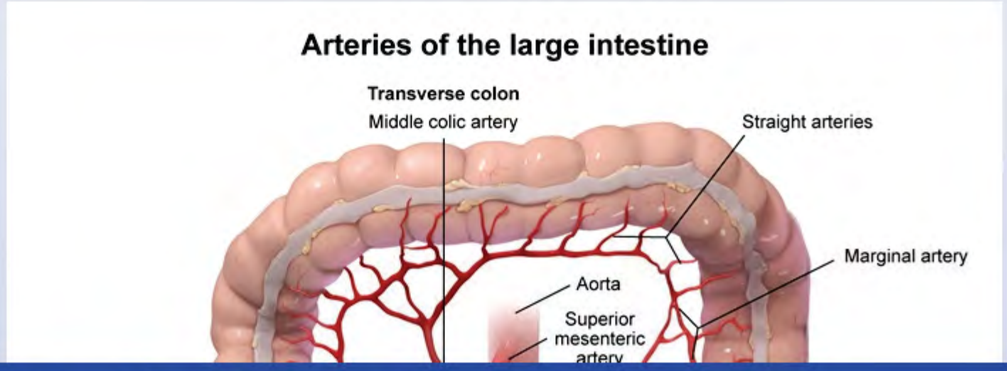

https://t.me/USMLEWorldStep1

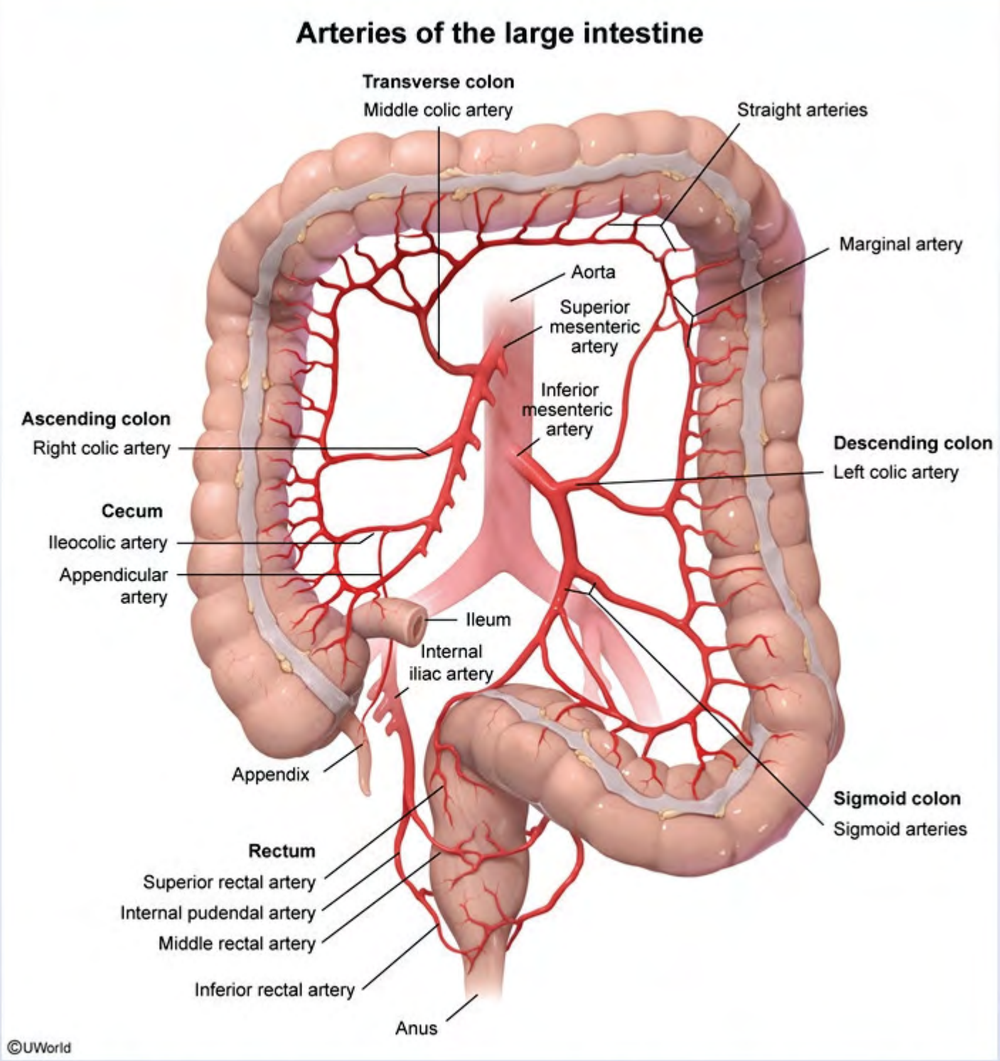

This patient with abdominal pain and bloody diarrhea following a complicated surgical procedure likely has acute nonocclusive **ischemic colitis**. The colon receives blood from the marginal artery of the colon (artery of Drummond), an anastomotic system of arteries that is in turn supplied by the superior (SMA) and inferior (IMA)

https://t.me/USMLEWorldStep1

Aorta
Superior mesenteric

Exhibit Display

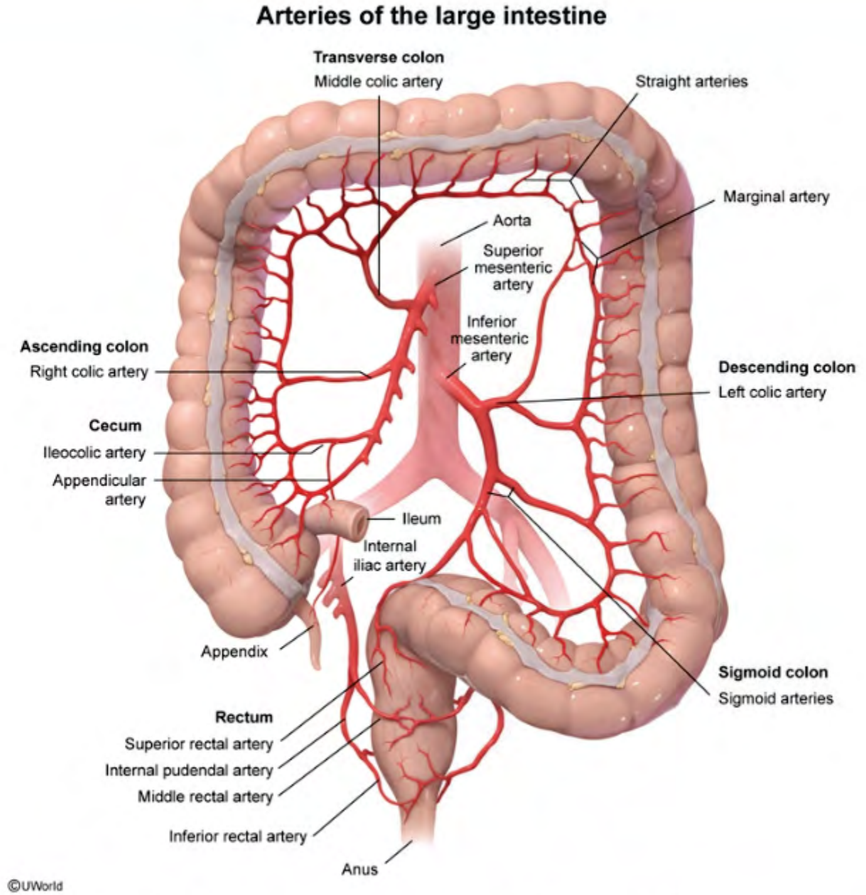

Zoom In | Zoom Out | Reset | New | Existing | My Notebook

This p
nonoc
Drumr
meser

In low-
diabet
distribu
and IM

commonly, **occlusive ischemia** can also be caused by thromboembolic (eg, hypercoagulable states, atrial fibrillation) or atheroembolic (eg, aortic instrumentation) events.

https://t.me/USMLEWorldStep1

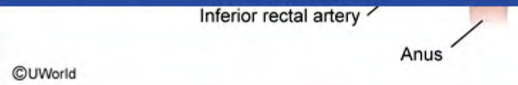

This patient with abdominal pain and bloody diarrhea following a complicated surgical procedure likely has acute nonocclusive **ischemic colitis**. The colon receives blood from the marginal artery of the colon (artery of Drummond), an anastomotic system of arteries that is in turn supplied by the superior (SMA) and inferior (IMA) mesenteric artery systems. The distal colon receives blood also from the internal iliac artery.

In low-flow states, as may be seen in severe hypotension in patients with underlying arterial insufficiency (eg, diabetes, atherosclerotic arterial disease), **nonocclusive ischemia** may occur at the margins of the anastomotic distributions. These "**watershed**" areas are primarily in the left colon at the **splenic flexure** (border between SMA and IMA supply) and **rectosigmoid junction** (border between sigmoid artery and superior rectal artery). Less commonly, **occlusive ischemia** can also be caused by thromboembolic (eg, hypercoagulable states, atrial fibrillation) or atheroembolic (eg, aortic instrumentation) events.

Impaired perfusion to the bowel leads to ischemia and necrosis of the intestinal wall. Complications can include acidosis, sepsis, gangrene, and perforation. Colonoscopy will reveal pale mucosa and petechial hemorrhages.

(Choices A, B, C, and E) The ascending colon, cecum, hepatic flexure, and most of the transverse colon are supplied by branches of the SMA. Mesenteric ischemia in these areas is significantly less common than in the watershed areas of the left colon. Ischemia is also uncommon in the rectum, which receives collateral blood supply via the rectal arteries.

Educational objective:
The splenic flexure and rectosigmoid junction lie between regions of perfusion of major arteries. These "watershed" areas are susceptible to ischemic damage during hypotensive states, especially in patients with underlying arterial insufficiency.

References

- Clinical approach to colonic ischemia.

Pathology	Gastrointestinal & Nutrition	Colonic ischemia
Subject	System	Topic

https://t.me/USMLEWorldStep1

A 6-year-old boy is brought to the emergency department due to abrupt-onset vomiting, lethargy, and altered mental status. For 4 days, the patient has had a fever, cough, and rhinorrhea, which were treated symptomatically with aspirin. He has no prior medical conditions, and his family history is unremarkable. Vital signs are normal. The patient is stuporous and does not respond to verbal commands. Hepatomegaly is present. There is no jaundice. Laboratory results are as follows:

Liver function studies	
Total bilirubin	1.2 mg/dL
Alkaline phosphatase	150 U/L
Aspartate aminotransferase (SGOT)	2,431 U/L
Alanine aminotransferase (SGPT)	3,402 U/L
Coagulation studies	
PT	30 sec
Activated PTT	68 sec
Blood, plasma, and serum	
Ammonia	462 µg/dL

Which of the following is the most likely cause of this patient's presentation?

A. Accumulation of a misfolded protein within hepatocytes
B. $CD8^+$ T-cell–mediated destruction of viral infected hepatocytes
C. Depletion of intracellular reduced glutathione
D. Excessive formation of superoxide in hepatocytes
E. Mitochondrial damage leading to impaired fatty acid metabolism

https://t.me/USMLEWorldStep1

with aspirin. He has no prior medical conditions, and his family history is unremarkable. Vital signs are normal. The patient is stuporous and does not respond to verbal commands. Hepatomegaly is present. There is no jaundice. Laboratory results are as follows:

Liver function studies	
Total bilirubin	1.2 mg/dL
Alkaline phosphatase	150 U/L
Aspartate aminotransferase (SGOT)	2,431 U/L
Alanine aminotransferase (SGPT)	3,402 U/L
Coagulation studies	
PT	30 sec
Activated PTT	68 sec
Blood, plasma, and serum	
Ammonia	462 µg/dL

Which of the following is the most likely cause of this patient's presentation?

- A. Accumulation of a misfolded protein within hepatocytes
- B. $CD8^+$ T-cell–mediated destruction of viral infected hepatocytes
- C. Depletion of intracellular reduced glutathione
- D. Excessive formation of superoxide in hepatocytes
- E. Mitochondrial damage leading to impaired fatty acid metabolism

Submit

https://t.me/USMLEWorldStep1

with aspirin. He has no prior medical conditions, and his family history is unremarkable. Vital signs are normal. The patient is stuporous and does not respond to verbal commands. Hepatomegaly is present. There is no jaundice. Laboratory results are as follows:

Liver function studies	
Total bilirubin	1.2 mg/dL
Alkaline phosphatase	150 U/L
Aspartate aminotransferase (SGOT)	2,431 U/L
Alanine aminotransferase (SGPT)	3,402 U/L
Coagulation studies	
PT	30 sec
Activated PTT	68 sec
Blood, plasma, and serum	
Ammonia	462 µg/dL

Which of the following is the most likely cause of this patient's presentation?

- A. Accumulation of a misfolded protein within hepatocytes (1%)
- ✗ B. $CD8^+$ T-cell–mediated destruction of viral infected hepatocytes (4%)
- C. Depletion of intracellular reduced glutathione (12%)
- D. Excessive formation of superoxide in hepatocytes (15%)
- ✓ E. Mitochondrial damage leading to impaired fatty acid metabolism (65%)

Incorrect
Correct answer
E

65%
Answered correctly

08 secs
Time Spent

2023
Version

https://t.me/USMLEWorldStep1

Explanation

Reye syndrome	
Pathophysiology	• Aspirin use in children during viral infection (eg, influenza, varicella) • Mitochondrial toxicity → impaired fatty acid metabolism • Microvesicular fat deposits in the liver • Hepatic dysfunction → hyperammonemia • Diffuse astrocyte swelling (ie, cerebral edema)

Clinical features	• Acute liver failure
	  ◦ Hepatomegaly
	  ◦ Elevated transaminases; coagulopathy
	• Rapidly progressive encephalopathy
	  ◦ Vomiting, lethargy, seizures, coma

Treatment	• Supportive

This patient likely has **Reye syndrome**, a rapidly progressive disorder characterized by acute liver failure (eg, hepatomegaly, elevated transaminases, coagulopathy) and encephalopathy.

Reye syndrome most commonly occurs in children who are given **salicylates** (eg, aspirin) during a **viral infection** (eg, influenza). In susceptible patients, salicylates can **damage mitochondria** within hepatocytes and inhibit enzymes involved in **fatty acid beta-oxidation**, the primary metabolic pathway hepatocytes depend on to maintain normal cellular function. Salicylate-induced hepatic injury prevents the liver from keeping up with metabolic demands, which often increase in the setting of a viral infection and predisposes patients to the development of **acute liver failure**.

Patients with Reye syndrome typically have vomiting and **encephalopathy** (eg, lethargy, altered mental status) related to the buildup of ammonia from liver failure. Seizures and coma may also occur. In addition to **hyperammonemia**, laboratory analysis typically shows markedly **elevated aminotransferases**, as seen in this patient. In addition, **PT** and **PTT** are often **prolonged** due to impaired hepatic synthetic function, but bilirubin is

https://t.me/USMLEWorldStep1

(eg, influenza). In susceptible patients, salicylates can **damage mitochondria** within hepatocytes and inhibit enzymes involved in **fatty acid beta-oxidation**, the primary metabolic pathway hepatocytes depend on to maintain normal cellular function. Salicylate-induced hepatic injury prevents the liver from keeping up with metabolic demands, which often increase in the setting of a viral infection and predisposes patients to the development of **acute liver failure**.

Patients with Reye syndrome typically have vomiting and **encephalopathy** (eg, lethargy, altered mental status) related to the buildup of ammonia from liver failure. Seizures and coma may also occur. In addition to **hyperammonemia**, laboratory analysis typically shows markedly **elevated aminotransferases**, as seen in this patient. In addition, **PT** and **PTT** are often **prolonged** due to impaired hepatic synthetic function, but bilirubin is generally normal to slightly elevated. There is no specific treatment for Reye syndrome other than supportive care.

(Choice A) Alpha-1 antitrypsin (A1A) deficiency causes abnormal A1A protein folding and accumulation within hepatocytes. Although it can cause chronic liver disease in childhood, this patient's acute hepatic dysfunction and encephalopathy after salicylate exposure is more characteristic of Reye syndrome.

(Choice B) Viral hepatitis induces a robust $CD8^+$ T-cell response against infected hepatocytes, which typically leads to elevations in aminotransferases. Although viral hepatitis may cause acute liver failure, it would be associated with increased bilirubin and jaundice (especially with marked AST/ALT elevation).

(Choice C) Acetaminophen overdose can cause acute liver failure through the depletion of intracellular glutathione, leading to an overabundance of hepatotoxic metabolites (eg, N-acetyl-p-benzoquinone imine). Salicylates do not deplete intracellular glutathione like acetaminophen does.

(Choice D) Reperfusion after ischemic insult to the liver can create hepatotoxic reactive oxygen species, such as superoxide. Reperfusion injury occurs in the setting of profound hypotension (eg, septic shock), which is not present in this patient.

Educational objective:
Reye syndrome is characterized by acute liver failure (eg, hepatomegaly, elevated aminotransferases, coagulopathy) and rapidly progressive encephalopathy related to hyperammonemia. It usually develops in susceptible children during a viral infection after administration of salicylates (eg, aspirin), which cause damage to the mitochondria and impair fatty acid beta-oxidation within hepatocytes.

https://t.me/USMLEWorldStep1

A 32-year-old woman comes to the office due to postprandial abdominal pain and nausea. The patient has no diarrhea, constipation, bloody stools, or vomiting. Medical history is significant for rheumatoid arthritis. The abdomen is mildly tender to palpation at the epigastrium but without distension or hepatosplenomegaly. Laboratory studies reveal anemia. A small gastric ulcer is seen during upper endoscopy, and biopsies are negative for *Helicobacter pylori*. Biopsies of the duodenum reveal numerous intraepithelial lymphocytes, villous atrophy, and crypt hyperplasia. Based on these biopsy findings, this patient is at increased risk for developing which of the following conditions later in life?

- A. Angiodysplasia of the small bowel
- B. Colon adenocarcinoma
- C. Portal vein thrombosis
- D. Pyloric stenosis
- E. T-cell lymphoma

Submit

https://t.me/USMLEWorldStep1

A 32-year-old woman comes to the office due to postprandial abdominal pain and nausea. The patient has no diarrhea, constipation, bloody stools, or vomiting. Medical history is significant for rheumatoid arthritis. The abdomen is mildly tender to palpation at the epigastrium but without distension or hepatosplenomegaly. Laboratory studies reveal anemia. A small gastric ulcer is seen during upper endoscopy, and biopsies are negative for *Helicobacter pylori*. Biopsies of the duodenum reveal numerous intraepithelial lymphocytes, villous atrophy, and crypt hyperplasia. Based on these biopsy findings, this patient is at increased risk for developing which of the following conditions later in life?

- A. Angiodysplasia of the small bowel (9%)
- ✗ B. Colon adenocarcinoma (17%)
- C. Portal vein thrombosis (2%)
- D. Pyloric stenosis (4%)
- ✓ E. T-cell lymphoma (66%)

Incorrect
Correct answer
E

66%
Answered correctly

04 secs
Time Spent

2023
Version

Explanation

Celiac disease	
Pathogenesis	• Gluten (gliadin) consumption → immune-mediated small intestine inflammation → chronic malabsorption
Symptoms	• Abdominal pain • Diarrhea, flatulence & bloating • Failure to thrive (children) or weight loss

https://t.me/USMLEWorldStep1

Celiac disease	
Pathogenesis	• Gluten (gliadin) consumption → immune-mediated small intestine inflammation → chronic malabsorption
Symptoms	• Abdominal pain • Diarrhea, flatulence & bloating • Failure to thrive (children) or weight loss • Iron deficiency anemia • Dermatitis herpetiformis
Diagnosis	• Serology: tissue transglutaminase IgA, antiendomysial antibodies • Duodenal biopsy: intraepithelial lymphocytes, villous atrophy, crypt hyperplasia
Associated conditions	• Autoimmune disorders (eg, type 1 diabetes) • Cancer risk: T-cell lymphoma

This patient's presentation (abdominal pain, anemia) and biopsy findings are suggestive of **celiac disease**, an immune-mediated disorder triggered by gluten, a protein found in wheat, barley, and rye. Diarrhea is also common in celiac disease but may be absent.

Gliadin, a breakdown product of gluten, is primarily responsible for causing chronic inflammatory changes of the small bowel. Classic histologic findings, which are most prominent in the proximal small bowel (eg, duodenum, proximal jejunum), include intraepithelial lymphocytosis, **villous atrophy**, and crypt hyperplasia.

Chronic lymphocytic recruitment and proliferation within the small-bowel mucosa predisposes to **monoclonal T-cell expansion**, putting these patients at risk for enteropathy-associated **T-cell lymphoma**. This small-bowel cancer is usually very aggressive and has a poor prognosis despite chemotherapy.

(Choice A) Angiodysplasias are dilated, tortuous veins that develop in the gastrointestinal tract, most commonly in the small bowel and cecum. Risk factors include advanced age, chronic kidney disease, and aortic stenosis. They have no association with celiac disease.

https://t.me/USMLEWorldStep1

Associated conditions	• Autoimmune disorders (eg, type 1 diabetes) • Cancer risk: T-cell lymphoma

This patient's presentation (abdominal pain, anemia) and biopsy findings are suggestive of **celiac disease**, an immune-mediated disorder triggered by gluten, a protein found in wheat, barley, and rye. Diarrhea is also common in celiac disease but may be absent.

Gliadin, a breakdown product of gluten, is primarily responsible for causing chronic inflammatory changes of the small bowel. Classic histologic findings, which are most prominent in the proximal small bowel (eg, duodenum, proximal jejunum), include intraepithelial lymphocytosis, **villous atrophy**, and crypt hyperplasia.

Chronic lymphocytic recruitment and proliferation within the small-bowel mucosa predisposes to **monoclonal T-cell expansion**, putting these patients at risk for enteropathy-associated **T-cell lymphoma**. This small-bowel cancer is usually very aggressive and has a poor prognosis despite chemotherapy.

(Choice A) Angiodysplasias are dilated, tortuous veins that develop in the gastrointestinal tract, most commonly in the small bowel and cecum. Risk factors include advanced age, chronic kidney disease, and aortic stenosis. They have no association with celiac disease.

(Choice B) In addition to small-bowel lymphoma, celiac disease is a risk factor for small-bowel adenocarcinoma. Unlike ulcerative colitis, familial adenomatous polyposis, and Lynch syndrome, celiac disease does not predispose to colon adenocarcinoma.

(Choice C) Portal vein thrombosis can create portal hypertension, predisposing to ascites and varices. This can occur in patients with hypercoagulable conditions such as polycythemia vera, as well as those with cirrhosis and hepatocellular carcinoma. Celiac disease does not predispose to portal vein thrombosis.

(Choice D) Pyloric stenosis is a congenital disorder that results from pyloric smooth muscle hypertrophy and typically presents with profuse vomiting in infants. It is not associated with celiac disease.

Educational objective:
Celiac disease, an immune-mediated disorder triggered by gluten, causes small intestinal intraepithelial lymphocytosis, villous atrophy, and crypt hyperplasia. Monoclonal T-cell expansion can occur in the small-bowel mucosa of patients, leading to enteropathy-associated T-cell lymphoma.

https://t.me/USMLEWorldStep1

Associated conditions	• Autoimmune disorders (eg, type 1 diabetes) • Cancer risk: T-cell lymphoma

Exhibit Display

Celiac disease

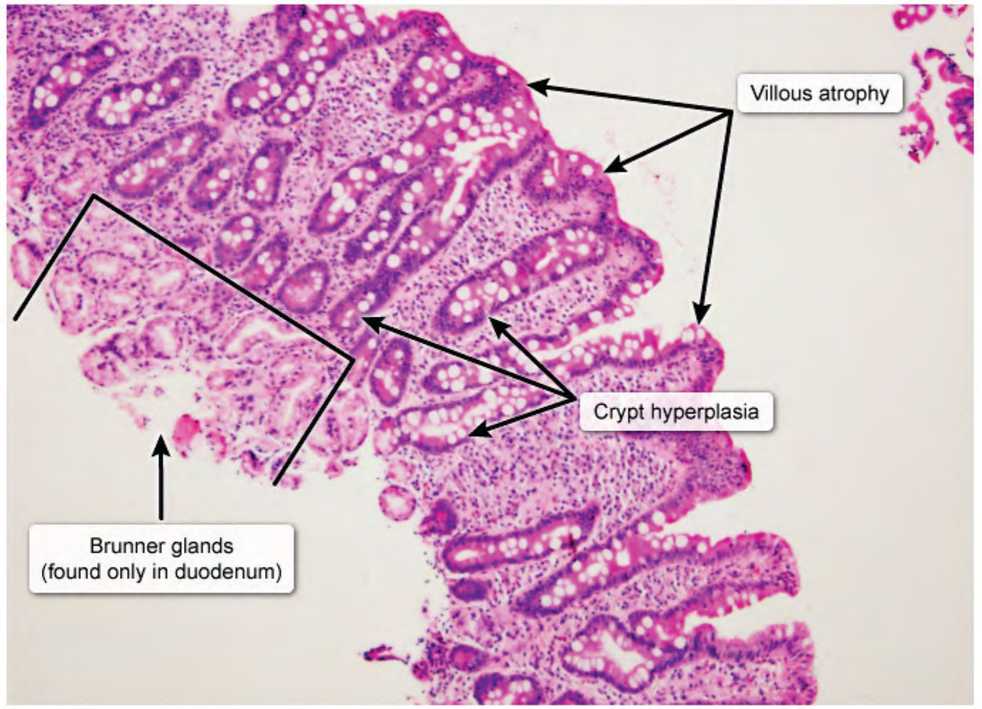

©UWorld

Zoom In | Zoom Out | Reset | New | Existing | My Notebook

This p
immun
in celia

Gliadi
small
proxim

Chron
cell ex
cancer

(Choi
the sm
have r

(Choi
Unlike
to colo

(Choi
occur
hepato

(Choi
typical

Educa
Celiac
lymphocytosis, villous atrophy, and crypt hyperplasia. Monoclonal T-cell expansion can occur in the small bowel
mucosa of patients, leading to enteropathy-associated T-cell lymphoma.

https://t.me/USMLEWorldStep1

A 50-year-old woman comes to the office for a preventive examination. She feels well and has no ongoing symptoms. Medical and family histories are unremarkable. The patient does not use tobacco or alcohol. Blood pressure is 132/76 mm Hg and pulse is 72/min. BMI is 25 kg/m^2. Physical examination is normal. The patient is up to date on breast and cervical screenings but has not undergone colon cancer screening. She is referred for colonoscopy, during which a single colon polyp is discovered. The polyp is removed and sent for microscopic examination. Which of the following pathologic findings would be associated with the greatest risk of malignant transformation?

- A. 1-cm sessile hyperplastic polyp
- B. 2-cm sessile lymphoid polyp
- C. 2-cm tubular adenomatous polyp
- D. 2-cm villous adenomatous polyp
- E. 3-cm pedunculated hamartomatous polyp

Submit

https://t.me/USMLEWorldStep1

A 50-year-old woman comes to the office for a preventive examination. She feels well and has no ongoing symptoms. Medical and family histories are unremarkable. The patient does not use tobacco or alcohol. Blood pressure is 132/76 mm Hg and pulse is 72/min. BMI is 25 kg/m^2. Physical examination is normal. The patient is up to date on breast and cervical screenings but has not undergone colon cancer screening. She is referred for colonoscopy, during which a single colon polyp is discovered. The polyp is removed and sent for microscopic examination. Which of the following pathologic findings would be associated with the greatest risk of malignant transformation?

- ✗ A. 1-cm sessile hyperplastic polyp (7%)
- B. 2-cm sessile lymphoid polyp (7%)
- C. 2-cm tubular adenomatous polyp (8%)
- ✓ D. 2-cm villous adenomatous polyp (72%)
- E. 3-cm pedunculated hamartomatous polyp (3%)

Incorrect
Correct answer
D

72%
Answered correctly

03 secs
Time Spent

2023
Version

Explanation

Common colonic polyps	
Neoplastic	**Nonneoplastic**
• Sessile serrated polyp • Adenomatous (villous > tubular)	• Hyperplastic • Inflammatory • Hamartomatous

Colonic polyps are protrusions above the mucosa that may appear pedunculated or sessile (ie, without a stalk) and

https://t.me/USMLEWorldStep1

Common colonic polyps	
Neoplastic	**Nonneoplastic**
• Sessile serrated polyp • Adenomatous (villous > tubular)	• Hyperplastic • Inflammatory • Hamartomatous

Colonic polyps are protrusions above the mucosa that may appear pedunculated or sessile (ie, without a stalk) and can be differentiated as nonneoplastic or neoplastic. **Neoplastic polyps** include **adenomatous** polyps (eg, tubular, villous, tubulovillous) and **sessile serrated** polyps. These polyps have the potential to transform into colonic adenocarcinoma.

Increasing polyp size is the most important characteristic that **correlates with malignancy risk**. Other risk factors include degree of dysplasia (eg, high-grade dysplasia) and architectural pattern. Villous adenomas are more likely to undergo malignant transformation than tubular adenomas **(Choice C)**.

Most colon polyps are nonneoplastic and do not transform into colonic adenocarcinoma; such types include:

- Hyperplastic polyps, the most common nonneoplastic polyp, are typically small and comprise a proliferation of nondysplastic epithelial cells forming crypts **(Choice A)**.
- Inflammatory polyps comprise distorted crypts surrounded by inflammatory cells and are due to repeated injury and regeneration (eg, inflammatory bowel disease).
- Hamartomatous polyps (eg, juvenile polyps) consist of disorganized tissue native to the colon (eg, crypts, smooth muscle). Solitary, sporadic hamartomatous polyps typically have no risk for malignant transformation **(Choice E)**. Multiple polyps occur in hamartomatous polyposis syndromes (eg, juvenile polyposis syndrome), which confer an increased risk of malignancy.

(Choice B) Solitary lymphoid polyps often comprise benign, reactive, hyperplastic lymphoid follicles (eg, following infection) that bulge into the mucosa, appearing polypoid on colonoscopy.

https://t.me/USMLEWorldStep1

• Sessile serrated polyp • Adenomatous (villous > tubular)	• Hyperplastic • Inflammatory • Hamartomatous

Colonic polyps are protrusions above the mucosa that may appear pedunculated or sessile (ie, without a stalk) and can be differentiated as nonneoplastic or neoplastic. **Neoplastic polyps** include **adenomatous** polyps (eg, tubular, villous, tubulovillous) and **sessile serrated** polyps. These polyps have the potential to transform into colonic adenocarcinoma.

Increasing polyp size is the most important characteristic that **correlates with malignancy risk**. Other risk factors include degree of dysplasia (eg, high-grade dysplasia) and architectural pattern. Villous adenomas are more likely to undergo malignant transformation than tubular adenomas **(Choice C)**.

Most colon polyps are nonneoplastic and do not transform into colonic adenocarcinoma; such types include:

- Hyperplastic polyps, the most common nonneoplastic polyp, are typically small and comprise a proliferation of nondysplastic epithelial cells forming crypts **(Choice A)**.
- Inflammatory polyps comprise distorted crypts surrounded by inflammatory cells and are due to repeated injury and regeneration (eg, inflammatory bowel disease).
- Hamartomatous polyps (eg, juvenile polyps) consist of disorganized tissue native to the colon (eg, crypts, smooth muscle). Solitary, sporadic hamartomatous polyps typically have no risk for malignant transformation **(Choice E)**. Multiple polyps occur in hamartomatous polyposis syndromes (eg, juvenile polyposis syndrome), which confer an increased risk of malignancy.

(Choice B) Solitary lymphoid polyps often comprise benign, reactive, hyperplastic lymphoid follicles (eg, following infection) that bulge into the mucosa, appearing polypoid on colonoscopy.

Educational objective:
Adenomatous and sessile serrated polyps are neoplastic polyps that have malignant potential. Increasing polyp size is the most important risk factor for cancer; villous histology and high-grade dysplasia are additional risk factors.

https://t.me/USMLEWorldStep1

- Sessile serrated polyp
- Hyperplastic

Exhibit Display

Colonic villous adenoma

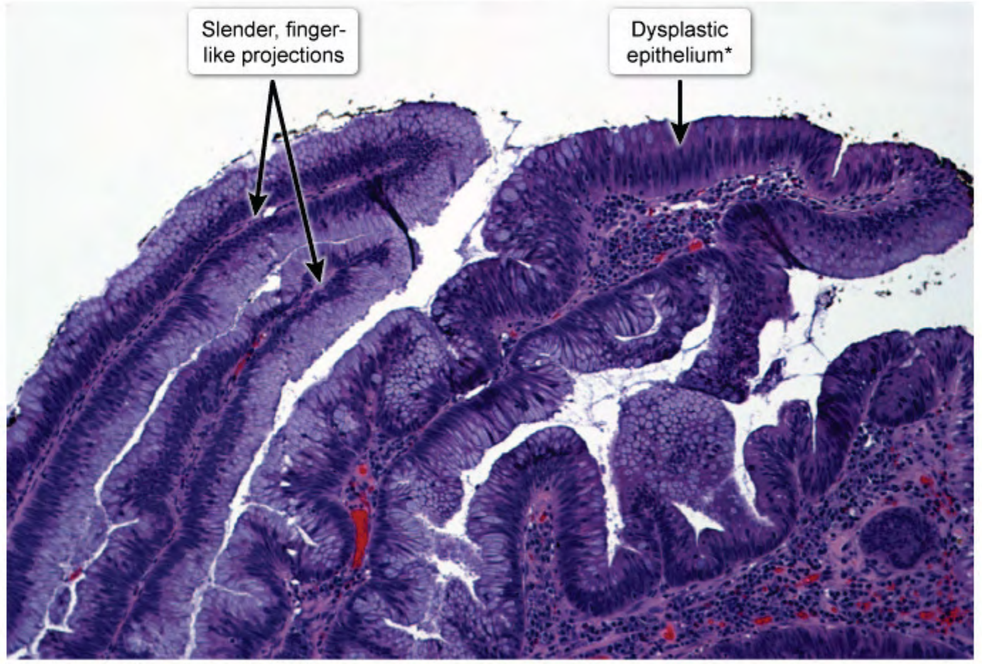

*Crowded cells with dark, elongated nuclei

©UWorld

Zoom In | Zoom Out | Reset | New | Existing | My Notebook

Coloni
can be
tubula
coloni

Increa
factors
more l

Most c

- H
- In
- H

(Choi
infecti

Educa
Adeno
size is
factors.

https://t.me/USMLEWorldStep1

- Sessile serrated polyp
- Hyperplastic

Exhibit Display

Coloni
can be
tubula
coloni

Increa
factors
more l

Most c

- H
- In
- H

(Choi
infecti

Educa
Adeno
size is
factors.

Normal colonic mucosa

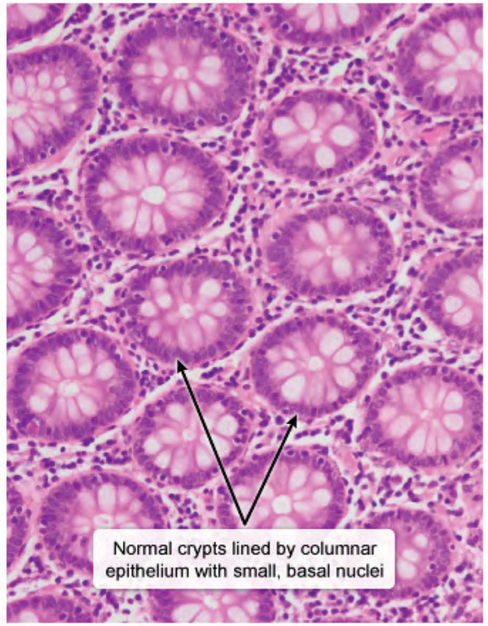

Tubular adenoma

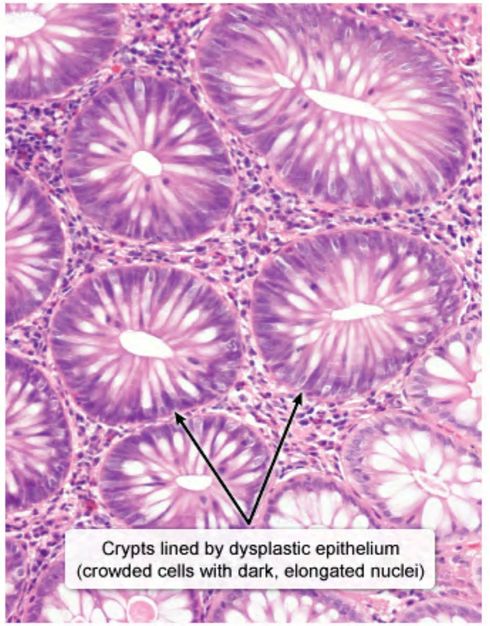

©UWorld

Zoom In | Zoom Out | Reset | New | Existing | My Notebook

https://t.me/USMLEWorldStep1

- Sessile serrated polyp
- Hyperplastic

Exhibit Display

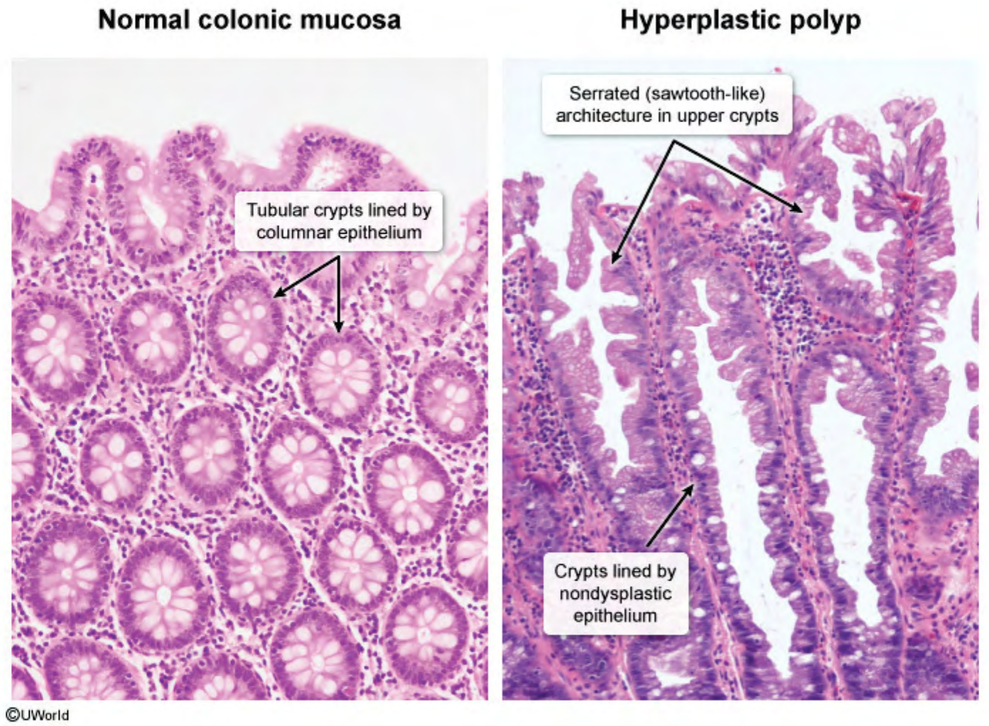

Zoom In | Zoom Out | Reset | New | Existing | My Notebook

Coloni
can be
tubula
coloni

Increa
factors
more l

Most c

- H
- In
- H

(Choi
infecti

Educa
Adenc
size is
factors.

https://t.me/USMLEWorldStep1

A 45-year-old woman recently diagnosed with Sjögren's syndrome complains of severe pruritus that slowly progressed over the last year. She says that pruritus is especially prominent over palms and soles and is unbearable during the night. Laboratory testing shows:

Total bilirubin	1.0 mg/dL
Direct bilirubin	0.8 mg/dL
Alkaline phosphatase	720 U/L
Aspartate aminotransferase (SGOT)	48 U/L
Alanine aminotransferase (SGPT)	40 U/L

This patient most likely has which of the following conditions?

- A. Viral hepatitis B
- B. Viral hepatitis C
- C. Alcohol-induced hepatitis
- D. Budd-Chiari syndrome
- E. Primary biliary cholangitis
- F. Hemochromatosis
- G. Wilson's disease

Submit

https://t.me/USMLEWorldStep1

A 45-year-old woman recently diagnosed with Sjögren's syndrome complains of severe pruritus that slowly progressed over the last year. She says that pruritus is especially prominent over palms and soles and is unbearable during the night. Laboratory testing shows:

Total bilirubin	1.0 mg/dL
Direct bilirubin	0.8 mg/dL
Alkaline phosphatase	720 U/L
Aspartate aminotransferase (SGOT)	48 U/L
Alanine aminotransferase (SGPT)	40 U/L

This patient most likely has which of the following conditions?

- A. Viral hepatitis B (0%)
- ✗ B. Viral hepatitis C (0%)
- C. Alcohol-induced hepatitis (2%)
- D. Budd-Chiari syndrome (3%)
- ✓ E. Primary biliary cholangitis (90%)
- F. Hemochromatosis (1%)
- G. Wilson's disease (0%)

Incorrect
Correct answer
E

90%
Answered correctly

04 secs
Time Spent

2023
Version

Explanation

https://t.me/USMLEWorldStep1

G. Wilson's disease (0%)

Incc
Corre
E

Expl

Exhibit Display

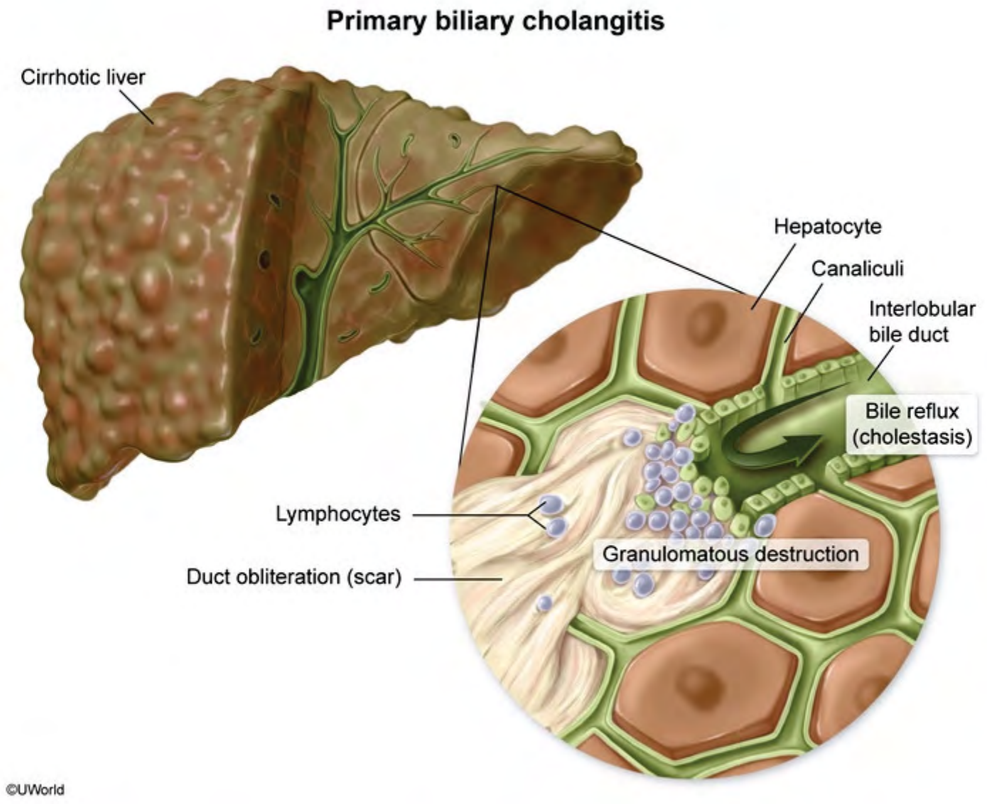

Zoom In Zoom Out Reset New | Existing My Notebook

This p
autoimmune destruction of the intrahepatic bile ducts and cholestasis. The condition presents most commonly in

https://t.me/USMLEWorldStep1

This patient is suffering from **primary biliary cholangitis** (PBC), a chronic liver disease characterized by autoimmune destruction of the intrahepatic bile ducts and cholestasis. The condition presents most commonly in **middle-aged women** and is insidious in onset. **Pruritus** is usually the first symptom and may be very severe, especially at night. Fatigue is also often reported. Physical findings typically include hepatosplenomegaly and xanthomatous lesions in the eyelids or in the skin and tendons. As the disease progresses, jaundice, steatorrhea, and portal hypertension may develop.

Abnormalities on laboratory testing are consistent with cholestasis and include **elevated alkaline phosphatase** cholesterol, and bile acids (causing pruritus) due to spillage of bile into the blood. Diagnosis is confirmed with demonstration of **anti-mitochondrial antibodies** in the serum. Associated conditions include **autoimmune diseases** such as Sjögren's syndrome, Raynaud's syndrome, systemic sclerosis, and Hashimoto's thyroiditis.

(Choices A and B) Expected laboratory findings in a patient with acute viral hepatitis include significant elevations in ALT and AST (with ALT > AST), followed by rises in bilirubin.

(Choice C) Alcohol-induced hepatitis is typically associated with a significant drinking history and is commonly characterized by an AST:ALT ratio greater than 2:1.

(Choice D) Budd-Chiari syndrome arises secondary to thrombotic occlusion of the hepatic veins and/or the intra- or suprahepatic inferior vena cava. The venous occlusion causes the sinusoidal pressure to increase, ultimately leading to portal hypertension, ascites, hepatomegaly, and splenomegaly.

(Choices F and G) Hemochromatosis and Wilson's disease cause hepatocellular injury and thus are associated with elevated ALT and AST rather than cholestatic picture.

Educational objective:
Primary biliary cholangitis is a chronic liver disease characterized by autoimmune destruction of the intrahepatic bile ducts and cholestasis (elevated alkaline phosphatase). The condition is most common in middle-aged women, with severe pruritus (especially at night) often one of the first reported symptoms.

https://t.me/USMLEWorldStep1

A 40-year-old female presented to the physician for evaluation of worsening fatigue. She has no other medical problems. She does not use tobacco, alcohol or drugs. Vital signs are within normal limits. Physical examination is within normal limits. Laboratory evaluation shows an alkaline phosphatase level of 180 U/L. Which of the following should be checked next?

- A. Unconjugated bilirubin level
- B. Lactate dehydrogenase level
- C. Serum ammonia levels
- D. Prothrombin time
- E. γ-glutamyl transpeptidase
- F. Aspartate aminotransferase

Submit

https://t.me/USMLEWorldStep1

A 40-year-old female presented to the physician for evaluation of worsening fatigue. She has no other medical problems. She does not use tobacco, alcohol or drugs. Vital signs are within normal limits. Physical examination is within normal limits. Laboratory evaluation shows an alkaline phosphatase level of 180 U/L. Which of the following should be checked next?

- A. Unconjugated bilirubin level (18%)
- ✕ B. Lactate dehydrogenase level (11%)
- C. Serum ammonia levels (4%)
- D. Prothrombin time (6%)
- ✓ E. γ-glutamyl transpeptidase (42%)
- F. Aspartate aminotransferase (17%)

Incorrect
Correct answer
E

42%
Answered correctly

03 secs
Time Spent

2023
Version

Explanation

Broadly speaking, laboratory tests used in the evaluation of hepatobiliary disease either assess liver functionality (eg, prothrombin time, bilirubin, albumin, cholesterol) or the structural integrity and cellular intactness of the liver (eg, transaminases) or the biliary tract (eg, alkaline phosphatase, γ-glutamyl transferase).

Alkaline phosphatase represents a group of enzymes associated with metabolic activity in a number of tissues, including liver, bone, intestine, kidney, placenta, leukocytes, and some neoplasms. Bone and liver are the primary sources of alkaline phosphatase, with threefold elevations considered a relatively nonspecific finding for many liver diseases. To clarify the importance of a moderately elevated alkaline phosphatase, the hepatic γ-glutamyl transpeptidase (GGTP) should be evaluated.

γ-glutamyl transpeptidase is an enzyme predominantly present in hepatocytes and biliary epithelia. While it too

https://t.me/USMLEWorldStep1

Explanation

Broadly speaking, laboratory tests used in the evaluation of hepatobiliary disease either assess liver functionality (eg, prothrombin time, bilirubin, albumin, cholesterol) or the structural integrity and cellular intactness of the liver (eg, transaminases) or the biliary tract (eg, alkaline phosphatase, γ-glutamyl transferase).

Alkaline phosphatase represents a group of enzymes associated with metabolic activity in a number of tissues, including liver, bone, intestine, kidney, placenta, leukocytes, and some neoplasms. Bone and liver are the primary sources of alkaline phosphatase, with threefold elevations considered a relatively nonspecific finding for many liver diseases. To clarify the importance of a moderately elevated alkaline phosphatase, the hepatic γ-glutamyl transpeptidase (GGTP) should be evaluated.

γ-glutamyl transpeptidase is an enzyme predominantly present in hepatocytes and biliary epithelia. While it too can be found in various extrahepatic tissues (organs such as kidney, spleen, pancreas, heart, lung, and brain), GGTP is not present to a significant extent in bone. It is therefore particularly useful in determining whether an elevated alkaline phosphatase is of hepatic or bony origin.

(Choice A) Measurement of unconjugated bilirubin (especially in contrast to conjugated bilirubin) can be of assistance in distinguishing hemolytic conditions from hepatic dysfunction or bile duct obstruction. This test is not particularly helpful in following up an elevated alkaline phosphatase.

(Choice B) Lactate dehydrogenase is a relatively nonspecific test that can be of some assistance in the evaluation of tissue injury or death. It is not the most helpful test in following up an elevated alkaline phosphatase.

(Choice C) Serum ammonia levels can be of assistance in determining the extent of liver failure or gastrointestinal bleeding, among other conditions. It is not the most helpful test in following up an elevated alkaline phosphatase.

(Choice D) Prothrombin time is of assistance in assessing coagulative ability and liver functionality, especially in the acute setting. It is not the most helpful test in following up an elevated alkaline phosphatase.

(Choice F) Aspartate aminotransferase is of assistance in assessing and monitoring hepatic damage. It is not the most helpful test in following up an elevated alkaline phosphatase.

https://t.me/USMLEWorldStep1

Broadly speaking, laboratory tests used in the evaluation of hepatobiliary disease either assess liver functionality (eg, prothrombin time, bilirubin, albumin, cholesterol) or the structural integrity and cellular intactness of the liver (eg, transaminases) or the biliary tract (eg, alkaline phosphatase, γ-glutamyl transferase).

Alkaline phosphatase represents a group of enzymes associated with metabolic activity in a number of tissues, including liver, bone, intestine, kidney, placenta, leukocytes, and some neoplasms. Bone and liver are the primary sources of alkaline phosphatase, with threefold elevations considered a relatively nonspecific finding for many liver diseases. To clarify the importance of a moderately elevated alkaline phosphatase, the hepatic γ-glutamyl transpeptidase (GGTP) should be evaluated.

γ-glutamyl transpeptidase is an enzyme predominantly present in hepatocytes and biliary epithelia. While it too can be found in various extrahepatic tissues (organs such as kidney, spleen, pancreas, heart, lung, and brain), GGTP is not present to a significant extent in bone. It is therefore particularly useful in determining whether an elevated alkaline phosphatase is of hepatic or bony origin.

(Choice A) Measurement of unconjugated bilirubin (especially in contrast to conjugated bilirubin) can be of assistance in distinguishing hemolytic conditions from hepatic dysfunction or bile duct obstruction. This test is not particularly helpful in following up an elevated alkaline phosphatase.

(Choice B) Lactate dehydrogenase is a relatively nonspecific test that can be of some assistance in the evaluation of tissue injury or death. It is not the most helpful test in following up an elevated alkaline phosphatase.

(Choice C) Serum ammonia levels can be of assistance in determining the extent of liver failure or gastrointestinal bleeding, among other conditions. It is not the most helpful test in following up an elevated alkaline phosphatase.

(Choice D) Prothrombin time is of assistance in assessing coagulative ability and liver functionality, especially in the acute setting. It is not the most helpful test in following up an elevated alkaline phosphatase.

(Choice F) Aspartate aminotransferase is of assistance in assessing and monitoring hepatic damage. It is not the most helpful test in following up an elevated alkaline phosphatase.

Educational Objective:
A moderately elevated alkaline phosphatase of unclear etiology should be followed up with γ-glutamyl transpeptidase.

https://t.me/USMLEWorldStep1

A 62-year-old man comes to the office due to watery diarrhea. He has also been having episodes of dyspnea and wheezing. His wife has noticed that he sometimes becomes very flushed and red. The patient has no abdominal pain, vomiting, cough, or fever. He has a history of hypertension and takes amlodipine. He does not use tobacco, alcohol, or illicit drugs. His blood pressure is 140/70 mm Hg and pulse is 82/min. Cardiopulmonary examination is unremarkable. The abdomen is soft and nontender. Chest x-ray is normal, and the abdominal CT scan reveals mass lesions in the right liver lobe and ileum. Surgery is scheduled to resect the tumors. Which of the following medications can be used to relieve this patient's symptoms prior to surgery?

- A. Cabergoline
- B. Leuprolide
- C. Octreotide
- D. Phenoxybenzamine
- E. Rituximab

Submit

https://t.me/USMLEWorldStep1

A 62-year-old man comes to the office due to watery diarrhea. He has also been having episodes of dyspnea and wheezing. His wife has noticed that he sometimes becomes very flushed and red. The patient has no abdominal pain, vomiting, cough, or fever. He has a history of hypertension and takes amlodipine. He does not use tobacco, alcohol, or illicit drugs. His blood pressure is 140/70 mm Hg and pulse is 82/min. Cardiopulmonary examination is unremarkable. The abdomen is soft and nontender. Chest x-ray is normal, and the abdominal CT scan reveals mass lesions in the right liver lobe and ileum. Surgery is scheduled to resect the tumors. Which of the following medications can be used to relieve this patient's symptoms prior to surgery?

- A. Cabergoline (4%)
- ✗ B. Leuprolide (5%)
- ✓ C. Octreotide (75%)
- D. Phenoxybenzamine (12%)
- E. Rituximab (2%)

Incorrect
Correct answer
C

75%
Answered correctly

03 secs
Time Spent

2023
Version

Explanation

Features of carcinoid syndrome	
Clinical manifestations	• Skin: flushing, telangiectasias, cyanosis • Gastrointestinal: watery diarrhea, cramping • Pulmonary: bronchospasm, dyspnea, wheezing • Cardiac: valvular fibrous plaques (right > left)
Diagnosis	• Elevated 24-hr urinary excretion of 5-HIAA

https://t.me/USMLEWorldStep1

Features of carcinoid syndrome	
Clinical manifestations	• Skin: flushing, telangiectasias, cyanosis • Gastrointestinal: watery diarrhea, cramping • Pulmonary: bronchospasm, dyspnea, wheezing • Cardiac: valvular fibrous plaques (right > left)
Diagnosis	• Elevated 24-hr urinary excretion of 5-HIAA • CT scan/MRI of abdomen & pelvis to localize tumor
Treatment	• Octreotide for symptomatic patients • Surgery for liver metastases
5-HIAA = 5-hydroxyindoleacetic acid.	

The combination of wheezing, diarrhea, and facial flushing in association with an ileal tumor with hepatic metastasis is suggestive of **carcinoid syndrome**. Carcinoid tumors (most common ileal tumors) secrete a number of biologically active substances including serotonin and can cause symptoms when they metastasize. Common manifestations of carcinoid syndrome include flushing, asthma-like symptoms (wheezing, dyspnea), diarrhea, and syncope (due to low blood pressure). Long-standing carcinoid syndrome can cause right-sided valvular heart disease.

The most definitive treatment for carcinoid syndrome is surgical excision. Medical therapy with octreotide can be used to control symptoms. **Octreotide** is a synthetic analog of somatostatin with a longer half-life. It acts on somatostatin receptors and inhibits secretion of many hormones and hormone-like substances. Octreotide is also used to inhibit secretory diarrhea in VIPomas (pancreatic endocrine tumors).

(Choice A) Cabergoline is a dopamine agonist used in growth hormone-secreting pituitary tumors or prolactinoma.

(Choice B) Leuprolide is a synthetic analog of gonadotropin-releasing hormone (GnRH). Continuous administration suppresses release of LH and FSH. Leuprolide is used in management of prostatic cancer, precocious puberty, and endometriosis.

https://t.me/USMLEWorldStep1

The combination of wheezing, diarrhea, and facial flushing in association with an ileal tumor with hepatic metastasis is suggestive of **carcinoid syndrome**. Carcinoid tumors (most common ileal tumors) secrete a number of biologically active substances including serotonin and can cause symptoms when they metastasize. Common manifestations of carcinoid syndrome include flushing, asthma-like symptoms (wheezing, dyspnea), diarrhea, and syncope (due to low blood pressure). Long-standing carcinoid syndrome can cause right-sided valvular heart disease.

The most definitive treatment for carcinoid syndrome is surgical excision. Medical therapy with octreotide can be used to control symptoms. **Octreotide** is a synthetic analog of somatostatin with a longer half-life. It acts on somatostatin receptors and inhibits secretion of many hormones and hormone-like substances. Octreotide is also used to inhibit secretory diarrhea in VIPomas (pancreatic endocrine tumors).

(Choice A) Cabergoline is a dopamine agonist used in growth hormone-secreting pituitary tumors or prolactinoma.

(Choice B) Leuprolide is a synthetic analog of gonadotropin-releasing hormone (GnRH). Continuous administration suppresses release of LH and FSH. Leuprolide is used in management of prostatic cancer, precocious puberty, and endometriosis.

(Choice D) Phenoxybenzamine is an alpha blocker that is used in treatment of pheochromocytoma.

(Choice E) Rituximab is a CD20 monoclonal antibody used to treat multiple myeloma, leukemia, and multiple autoimmune disorders.

Educational objective:
Carcinoid syndrome may accompany extraintestinal metastases of gastrointestinal carcinoid tumors. Octreotide is a synthetic somatostatin analog used to control the symptoms of carcinoid syndrome.

References

- Small bowel cancer in the United States: changes in epidemiology, treatment, and survival over the last 20 years.

Pharmacology	Gastrointestinal & Nutrition	Carcinoid tumors
Subject	System	Topic

https://t.me/USMLEWorldStep1

Treatment	• Octreotide for symptomatic patients • Surgery for liver metastases

5-HIAA = 5-hydroxyindoleacetic acid.

The combination of wheezing, diarrhea, and facial flushing in association with an ileal tumor with hepatic metastasis is suggestive of **carcinoid syndrome**. Carcinoid tumors (most common ileal tumors) secrete a number of biologically active substances including serotonin and can cause symptoms when they metastasize. Common manifestations of carcinoid syndrome include flushing, asthma-like symptoms (wheezing, dyspnea), diarrhea, and syncope (due to low blood pressure). Long-standing carcinoid syndrome can cause right-sided valvular heart disease.

The most definitive treatment for carcinoid syndrome is surgical excision. Medical therapy with octreotide can be used to control symptoms. **Octreotide** is a synthetic analog of somatostatin with a longer half-life. It acts on somatostatin receptors and inhibits secretion of many hormones and hormone-like substances. Octreotide is also used to inhibit secretory diarrhea in VIPomas (pancreatic endocrine tumors).

(Choice A) Cabergoline is a dopamine agonist used in growth hormone-secreting pituitary tumors or prolactinoma.

(Choice B) Leuprolide is a synthetic analog of gonadotropin-releasing hormone (GnRH). Continuous administration suppresses release of LH and FSH. Leuprolide is used in management of prostatic cancer, precocious puberty, and endometriosis.

(Choice D) Phenoxybenzamine is an alpha blocker that is used in treatment of pheochromocytoma.

(Choice E) Rituximab is a CD20 monoclonal antibody used to treat multiple myeloma, leukemia, and multiple autoimmune disorders.

Educational objective:
Carcinoid syndrome may accompany extraintestinal metastases of gastrointestinal carcinoid tumors. Octreotide is a synthetic somatostatin analog used to control the symptoms of carcinoid syndrome.

References

- Small bowel cancer in the United States: changes in epidemiology, treatment, and survival over the last 20 years.

https://t.me/USMLEWorldStep1

The following vignette applies to the next 2 items. The items in the set must be answered in sequential order. Once you click Proceed to Next Item, you will not be able to add or change an answer.

A 54-year-old man comes to the emergency department after an episode of bloody vomiting. He has had no fever, chills, abdominal pain, diarrhea, or constipation. The patient has a history of alcohol abuse with multiple previous hospital admissions due to alcohol withdrawal and generalized tonic-clonic seizures. He also has a history of intravenous drug abuse and is currently enrolled in a methadone maintenance program. Blood pressure is 96/62 mm Hg and pulse is 102/min. On examination, the patient appears comfortable but develops dizziness when asked to sit up. There is no jugular venous distension. The abdomen is distended with dullness to percussion at both flanks. The liver is enlarged on palpation, and the tip of the spleen is also palpable. There is trace pedal edema. Laboratory studies show:

Hemoglobin	9.7 g/dL
Mean corpuscular volume	98 fL
Leukocytes	5,000/mm^3
Platelets	78,000/mm^3

Item 1 of 2

Histopathologic examination of this patient's spleen is most likely to show which of the following?

- A. Extramedullary hematopoiesis
- B. Histiocytic proliferation
- C. Lymphoid follicle expansion
- D. Metastatic deposits
- E. Red pulp expansion

https://t.me/USMLEWorldStep1

Item 2 of 2

After initial stabilization with intravenous fluids and blood products, the patient develops another bout of bloody emesis. Urgent upper gastrointestinal endoscopy confirms esophageal varices. Which of the following peptides is most likely to immediately decrease the portal venous pressure in this patient?

- A. Cholecystokinin
- B. Glucagon
- C. Pentagastrin
- D. Secretin
- E. Somatostatin

Submit

https://t.me/USMLEWorldStep1

The following vignette applies to the next 2 items. The items in the set must be answered in sequential order. Once you click Proceed to Next Item, you will not be able to add or change an answer.

A 54-year-old man comes to the emergency department after an episode of bloody vomiting. He has had no fever, chills, abdominal pain, diarrhea, or constipation. The patient has a history of alcohol abuse with multiple previous hospital admissions due to alcohol withdrawal and generalized tonic-clonic seizures. He also has a history of intravenous drug abuse and is currently enrolled in a methadone maintenance program. Blood pressure is 96/62 mm Hg and pulse is 102/min. On examination, the patient appears comfortable but develops dizziness when asked to sit up. There is no jugular venous distension. The abdomen is distended with dullness to percussion at both flanks. The liver is enlarged on palpation, and the tip of the spleen is also palpable. There is trace pedal edema. Laboratory studies show:

Hemoglobin	9.7 g/dL
Mean corpuscular volume	98 fL
Leukocytes	5,000/mm^3
Platelets	78,000/mm^3

Item 1 of 2

Histopathologic examination of this patient's spleen is most likely to show which of the following?

- A. Extramedullary hematopoiesis (25%)
- ✗ B. Histiocytic proliferation (5%)
- C. Lymphoid follicle expansion (4%)
- D. Metastatic deposits (1%)
- ✓ E. Red pulp expansion (62%)

Incorrect
Correct answer
E

62%
Answered correctly

12 secs
Time Spent

2023
Version

https://t.me/USMLEWorldStep1

Explanation

This patient with a history of significant alcohol and intravenous drug abuse has evidence of **alcoholic liver disease** (ALD). His hematemesis, orthostatic symptoms, and normocytic anemia are likely due to acute bleeding from esophageal varices. Although chronic gastrointestinal blood loss can cause microcytic anemia due to depletion of iron stores and reduced hemoglobin synthesis, acute hemorrhage (as in this patient) is usually associated with normal mean corpuscular volume. ALD also causes thrombocytopenia due to decreased platelet production, increased destruction, and splenic sequestration.

Fibrosis and distortion of intrahepatic vasculature in ALD obstructs blood flow through the liver, leading to **portal hypertension**. Because the splenic vein is part of the portal circulation, any condition that causes portal hypertension can lead to **splenomegaly** with congestive hypersplenism. Venous congestion causes apparent **expansion of the red pulp** of the spleen, which is composed of blood-filled sinuses and cords lined by reticuloendothelial-type cells.

(Choice A) Extramedullary hematopoiesis results when hematopoietic precursor cells are displaced from the bone marrow and infiltrate the liver and spleen preferentially, resulting in splenomegaly. A common condition in which this occurs is myelofibrosis.

(Choices B and D) Histiocytic proliferation can cause splenomegaly in the setting of Langerhans cell histiocytosis (formerly known as histiocytosis X), but this is a rare disease with highest incidence in childhood. Metastatic tumors (eg, lung, breast, colorectal cancer) can infiltrate the spleen and lead to hypersplenism, but this patient has no history of malignancy. Given this patient's substance abuse history, ALD is much more likely.

(Choice C) Lymphoid follicle expansion can cause hypersplenism in the setting of systemic infections (eg, infectious mononucleosis) or as a result of immunologic diseases (eg, systemic lupus erythematosus, rheumatoid arthritis [Felty syndrome]).

Educational objective:
Portal hypertension, as seen in alcoholic liver disease, produces splenomegaly by causing congestion of blood within the spleen, which produces expansion of the red pulp.

https://t.me/USMLEWorldStep1

Item 2 of 2

After initial stabilization with intravenous fluids and blood products, the patient develops another bout of bloody emesis. Urgent upper gastrointestinal endoscopy confirms esophageal varices. Which of the following peptides is most likely to immediately decrease the portal venous pressure in this patient?

- A. Cholecystokinin (3%)
- ✗ B. Glucagon (4%)
- C. Pentagastrin (3%)
- D. Secretin (1%)
- ✓ E. Somatostatin (87%)

Incorrect
Correct answer
E

87%
Answered correctly

07 secs
Time Spent

2023
Version

Explanation

Prolonged **portal hypertension** in alcohol-associated liver disease can cause venous engorgement and dilation (ie, **varices**) at sites of portocaval anastomosis in the esophagus, rectum, umbilicus, and retroperitoneum. Subsequent rupture of esophageal varices can cause rapid blood loss and carries high mortality.

Acute management of variceal hemorrhage requires rapid lowering of portal pressure. **Somatostatin** and **octreotide** (a long-acting somatostatin analog) inhibit the release of endogenous hormones (eg, glucagon, vasoactive intestinal peptide) that induce splanchnic vasodilation, thereby indirectly **reducing portal blood flow**. Vasopressin directly causes splanchnic vasoconstriction and also can lower portal flow in acute variceal hemorrhage, but its use is limited by systemic vasoconstriction.

(Choices A, B, and D) Glucagon causes splanchnic vasodilation, raising portal pressure and worsening variceal bleeding. Cholecystokinin induces contraction of the gallbladder and expulsion of pancreatic exocrine secretions

https://t.me/USMLEWorldStep1

Explanation

Prolonged **portal hypertension** in alcohol-associated liver disease can cause venous engorgement and dilation (ie, **varices**) at sites of portocaval anastomosis in the esophagus, rectum, umbilicus, and retroperitoneum. Subsequent rupture of esophageal varices can cause rapid blood loss and carries high mortality.

Acute management of variceal hemorrhage requires rapid lowering of portal pressure. **Somatostatin** and **octreotide** (a long-acting somatostatin analog) inhibit the release of endogenous hormones (eg, glucagon, vasoactive intestinal peptide) that induce splanchnic vasodilation, thereby indirectly **reducing portal blood flow**. Vasopressin directly causes splanchnic vasoconstriction and also can lower portal flow in acute variceal hemorrhage, but its use is limited by systemic vasoconstriction.

(Choices A, B, and D) Glucagon causes splanchnic vasodilation, raising portal pressure and worsening variceal bleeding. Cholecystokinin induces contraction of the gallbladder and expulsion of pancreatic exocrine secretions into the duodenum, whereas the primary function of secretin is to alkalinize the duodenal contents; both of these hormones increase glucagon secretion and would therefore be counterproductive in this setting.

(Choice C) Pentagastrin is a synthetic gastrin analog that stimulates secretion of gastric acid. Its primary clinical use is as a diagnostic agent; pentagastrin induces a significant rise in calcitonin secretion in patients with medullary carcinoma of the thyroid and serotonin secretion in patients with carcinoid tumors.

Educational objective:
Acute management of variceal hemorrhage requires rapid lowering of portal pressure. Somatostatin and octreotide (a long-acting somatostatin analog) inhibit the release of hormones that induce splanchnic vasodilation, indirectly causing splanchnic vasoconstriction and reduced portal blood flow.

References

- Portal hypertension and variceal hemorrhage.
- Acute variceal bleeding.

Pathology	Gastrointestinal & Nutrition	Esophageal varices
Subject	System	Topic

https://t.me/USMLEWorldStep1

A 65-year-old man is found to have iron deficiency anemia. He has had no cough, abdominal pain, melena, or change in bowel habits but reports anorexia and a 5-kg (11-lb) weight loss in the past 2 months. Cardiopulmonary and abdominal examinations are unremarkable. Rectal examination shows guaiac-positive brown stool. A 3-cm mass is found on colonoscopy. Biopsy shows pleomorphic cells with large, dark nuclei forming irregular, crowded glands, some of which contain mucus. Imaging studies reveal multiple mass lesions in the liver and lungs. This patient's neoplasm most likely originated from which of the following locations?

- A. Adrenal gland
- B. Ascending colon
- C. Lungs
- D. Prostate
- E. Rectosigmoid colon

Submit

https://t.me/USMLEWorldStep1

A 65-year-old man is found to have iron deficiency anemia. He has had no cough, abdominal pain, melena, or change in bowel habits but reports anorexia and a 5-kg (11-lb) weight loss in the past 2 months. Cardiopulmonary and abdominal examinations are unremarkable. Rectal examination shows guaiac-positive brown stool. A 3-cm mass is found on colonoscopy. Biopsy shows pleomorphic cells with large, dark nuclei forming irregular, crowded glands, some of which contain mucus. Imaging studies reveal multiple mass lesions in the liver and lungs. This patient's neoplasm most likely originated from which of the following locations?

- A. Adrenal gland (1%)
- ✓ B. Ascending colon (54%)
- C. Lungs (5%)
- D. Prostate (6%)
- E. Rectosigmoid colon (31%)

Correct | 54% Answered correctly | 03 secs Time Spent | 2023 Version

Explanation

This elderly patient with weight loss, anorexia, and iron deficiency anemia (IDA) likely has **colon cancer**, the third most common cancer among men (after prostate and lung). It is the most common gastrointestinal malignancy and one of the most common causes of IDA in the elderly. **Right-sided colon cancers** (eg, **ascending colon**) tend to grow as large, bulky masses that protrude into the colonic lumen due to the relatively large caliber of the ascending colon. They are more likely to bleed and therefore more likely to cause IDA. The bleeding is usually occult and detected by positive fecal occult blood testing. By contrast, left-sided tumors (eg, rectosigmoid colon) tend to be smaller. They often infiltrate the wall of the colon, encircling it and narrowing the lumen. Therefore, they are more likely to cause obstruction, and patients generally have altered bowel habits, abdominal distension, and nausea and vomiting **(Choice E)**. Liver and lung are common sites of metastases

https://t.me/USMLEWorldStep1

Explanation

This elderly patient with weight loss, anorexia, and iron deficiency anemia (IDA) likely has **colon cancer**, the third most common cancer among men (after prostate and lung). It is the most common gastrointestinal malignancy and one of the most common causes of IDA in the elderly. **Right-sided colon cancers** (eg, **ascending colon**) tend to grow as large, bulky masses that protrude into the colonic lumen due to the relatively large caliber of the ascending colon. They are more likely to bleed and therefore more likely to cause IDA. The bleeding is usually occult and detected by positive fecal occult blood testing. By contrast, left-sided tumors (eg, rectosigmoid colon) tend to be smaller. They often infiltrate the wall of the colon, encircling it and narrowing the lumen. Therefore, they are more likely to cause obstruction, and patients generally have altered bowel habits, abdominal distension, and nausea and vomiting **(Choice E)**. Liver and lung are common sites of metastases.

(Choice A) Malignant adrenal tumors are rare and typically present with symptoms of excessive hormone secretion (eg, Cushing syndrome). They would not cause IDA.

(Choice C) Although this patient has lung lesions, most patients with lung cancer have referable symptoms at presentation (eg, cough, hemoptysis, dyspnea). Hepatic metastases can occur, but a colonic mass and IDA would be unusual.

(Choice D) Prostate cancer typically develops at the gland periphery, so most patients do not have referable symptoms and urinary symptoms tend to occur late in the disease. Colonic metastases and IDA would be unusual.

Educational objective:
Colon adenocarcinoma is the most common gastrointestinal malignancy. Right-sided lesions are more likely to bleed and cause iron deficiency anemia; left-sided lesions tend to present with obstructing symptoms (eg, altered bowel habits, constipation, abdominal distension, nausea and vomiting).

References

- Colorectal cancer statistics, 2014.
- Tumor location is a prognostic factor in poorly differentiated adenocarcinoma, mucinous adenocarcinoma, and signet ring cell carcinoma of the colon

https://t.me/USMLEWorldStep1

Expl

This e
most c
and or
tend to
ascen
occult
tend to
are mo
nause

(Choi
secret

(Choi
preser
be unu

(Choi
sympt

Educa
Colon
bleed
bowel

Refere

- Col
- Tumor location is a prognostic factor in poorly differentiated adenocarcinoma, mucinous adenocarcinoma, and signet ring cell carcinoma of the colon

Exhibit Display

Liver metastases (CT)

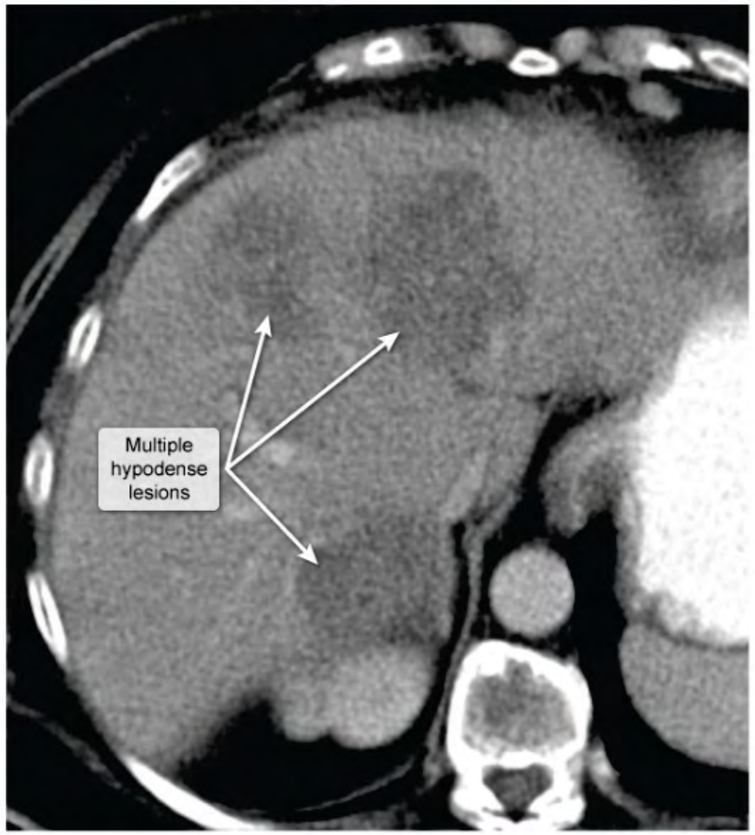

©UWorld

Zoom In | Zoom Out | Reset | New | Existing | My Notebook

https://t.me/USMLEWorldStep1

A 65-year-old woman comes to the emergency department due to nausea, vomiting, and abdominal pain that began about 6 hours ago. She has also had vague pelvic pain over the last few months but says her pain has never been this severe. Temperature is 38.4 C (101 F), blood pressure is 141/90 mm Hg, pulse is 92/min, and respirations are 18/min. Physical examination shows a moderately distended abdomen. There is a tender bulge below the inguinal ligament, lateral to the pubic tubercle. The overlying skin is erythematous. Which of the following structures is most likely immediately lateral to the bulge?

- A. Femoral vein
- B. Inferior epigastric vessels
- C. Pectineal ligament
- D. Rectus muscle sheath
- E. Round ligament
- F. Transversalis fascia

Submit

https://t.me/USMLEWorldStep1

A 65-year-old woman comes to the emergency department due to nausea, vomiting, and abdominal pain that began about 6 hours ago. She has also had vague pelvic pain over the last few months but says her pain has never been this severe. Temperature is 38.4 C (101 F), blood pressure is 141/90 mm Hg, pulse is 92/min, and respirations are 18/min. Physical examination shows a moderately distended abdomen. There is a tender bulge below the inguinal ligament, lateral to the pubic tubercle. The overlying skin is erythematous. Which of the following structures is most likely immediately lateral to the bulge?

- ✓ A. Femoral vein (71%)
- ✗ B. Inferior epigastric vessels (17%)
- C. Pectineal ligament (2%)
- D. Rectus muscle sheath (2%)
- E. Round ligament (3%)
- F. Transversalis fascia (2%)

Incorrect
Correct answer
A

71%
Answered correctly

03 secs
Time Spent

2023
Version

Explanation

https://t.me/USMLEWorldStep1

F. Transversalis fascia (2%)

Exhibit Display

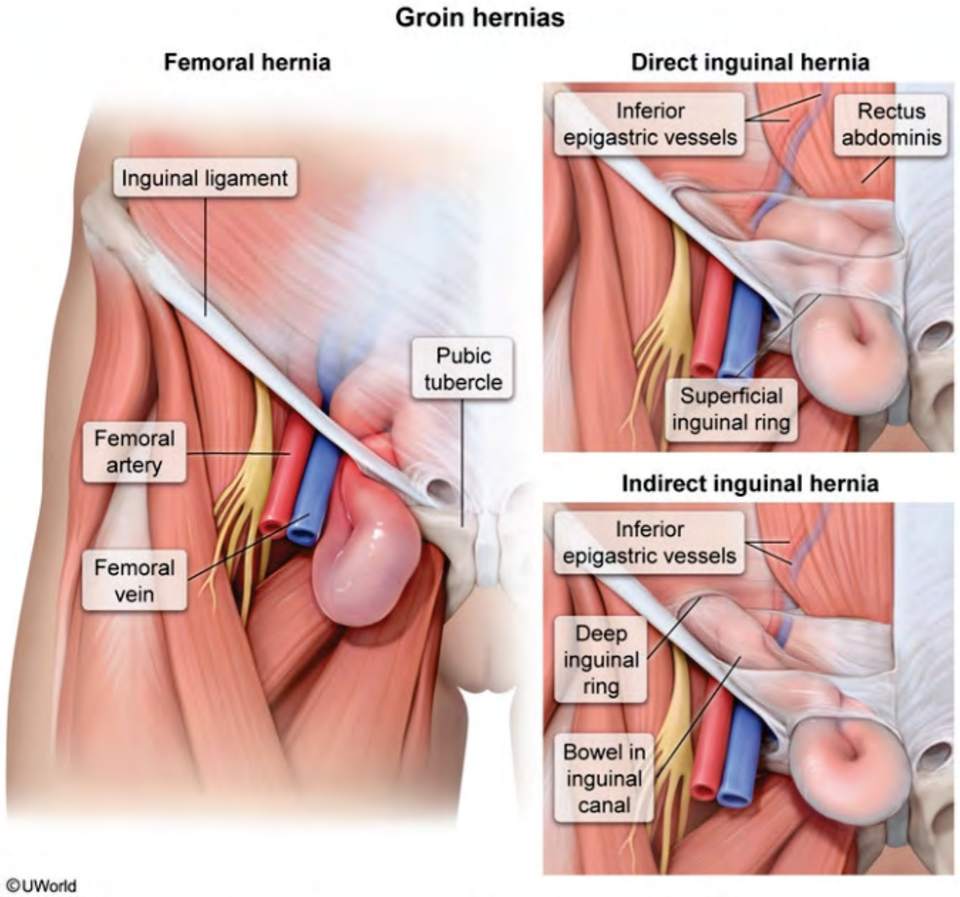

Zoom In | Zoom Out | Reset | New | Existing | My Notebook

https://t.me/USMLEWorldStep1

©UWorld

This patient has a **femoral hernia**, which characteristically presents with upper thigh, groin, or pelvic discomfort and a tender bulge **below the inguinal ligament**, lateral to the pubic tubercle and lacunar ligament. Femoral hernias are more common in women and tend to occur on the right side. Advanced age is the most important risk factor. Over time, the femoral ring becomes lax and can widen, allowing bowel to protrude into the femoral canal, the medial most compartment within the femoral sheath. The femoral vessels travel within other compartments of the femoral sheath, with the **femoral vein** running **immediately lateral** to the hernia.

Because the femoral canal is small, femoral hernias are prone to **incarceration**. Incarcerated hernias cannot be reduced; if a segment of bowel is present in the hernia sac, incarceration can cause bowel obstruction (eg, nausea, vomiting, abdominal pain and distension). Incarceration can also cause impaired blood flow to contents trapped in the hernia sac, resulting in **strangulation** (ischemia and necrosis) with potential systemic complications such as sepsis.

(Choice B) Direct inguinal hernias protrude through weakened transversalis fascia, medial to the inferior epigastric vessels, and emerge into the Hesselbach triangle. Indirect inguinal hernias protrude lateral to the inferior epigastric vessels before running through the deep (internal) inguinal ring and into the inguinal canal.

(Choice C) The pectineal ligament (inguinal ligament of Cooper) is a thickened part of the pectineal fascia. It overlies the pectineal ridge of the pubic bone and is located posterior to the femoral canal.

(Choice D) The rectus muscle sheath forms the medial border of the Hesselbach triangle. Direct inguinal hernias are located just lateral to the rectus abdominis muscle sheath.

(Choice E) The round ligament in women is homologous to the spermatic cord in men. It leaves the pelvis through the deep inguinal ring and passes through the inguinal canal.

(Choice F) The transversalis fascia is found between the transversalis muscle and the extraperitoneal fat. It forms the posterior wall of the inguinal canal. The deep (internal) inguinal ring is an opening in the transversalis fascia and is the site of protrusion of indirect inguinal hernias.

Educational objective:
Femoral hernias can present with groin discomfort and a tender bulge on the upper thigh inferior to the inguinal ligament, lateral to the pubic tubercle and lacunar ligament. The structure that lies immediately lateral to the hernia

https://t.me/USMLEWorldStep1

hernias are more common in women and tend to occur on the right side. Advanced age is the most important risk factor. Over time, the femoral ring becomes lax and can widen, allowing bowel to protrude into the femoral canal, the medial most compartment within the femoral sheath. The femoral vessels travel within other compartments of the femoral sheath, with the **femoral vein** running **immediately lateral** to the hernia.

Because the femoral canal is small, femoral hernias are prone to **incarceration**. Incarcerated hernias cannot be reduced; if a segment of bowel is present in the hernia sac, incarceration can cause bowel obstruction (eg, nausea, vomiting, abdominal pain and distension). Incarceration can also cause impaired blood flow to contents trapped in the hernia sac, resulting in **strangulation** (ischemia and necrosis) with potential systemic complications such as sepsis.

(Choice B) Direct inguinal hernias protrude through weakened transversalis fascia, medial to the inferior epigastric vessels, and emerge into the Hesselbach triangle. Indirect inguinal hernias protrude lateral to the inferior epigastric vessels before running through the deep (internal) inguinal ring and into the inguinal canal.

(Choice C) The pectineal ligament (inguinal ligament of Cooper) is a thickened part of the pectineal fascia. It overlies the pectineal ridge of the pubic bone and is located posterior to the femoral canal.

(Choice D) The rectus muscle sheath forms the medial border of the Hesselbach triangle. Direct inguinal hernias are located just lateral to the rectus abdominis muscle sheath.

(Choice E) The round ligament in women is homologous to the spermatic cord in men. It leaves the pelvis through the deep inguinal ring and passes through the inguinal canal.

(Choice F) The transversalis fascia is found between the transversalis muscle and the extraperitoneal fat. It forms the posterior wall of the inguinal canal. The deep (internal) inguinal ring is an opening in the transversalis fascia and is the site of protrusion of indirect inguinal hernias.

Educational objective:
Femoral hernias can present with groin discomfort and a tender bulge on the upper thigh inferior to the inguinal ligament, lateral to the pubic tubercle and lacunar ligament. The structure that lies immediately lateral to the hernia within the femoral sheath is the femoral vein. Incarceration and strangulation are common complications of femoral hernias.

https://t.me/USMLEWorldStep1

factor. Over time, the femoral ring becomes lax and can widen, allowing bowel to protrude into the femoral canal,

the me

the fer

Becau

reduce

vomiti

the he

sepsis

(Choi

epigas

inferio

(Choi

overlie

(Choi

are loc

(Choi

throug

(Choi

the po

and is

Educa

Femor

ligame

within

femoral hernias.

Exhibit Display

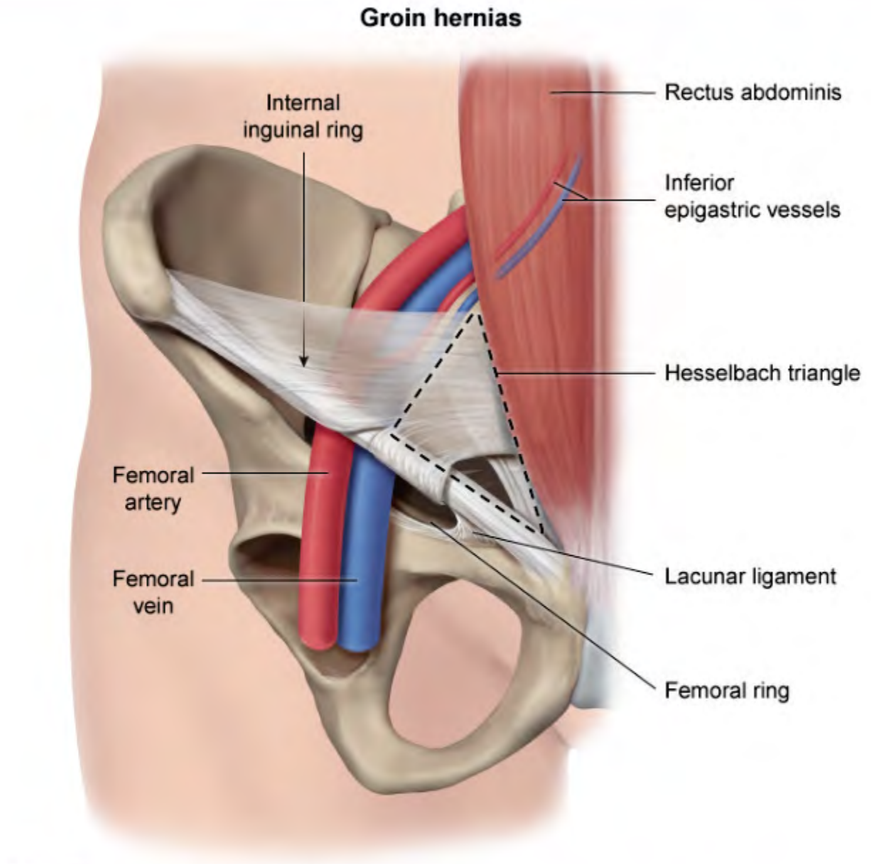

Zoom In Zoom Out Reset New | Existing My Notebook

https://t.me/USMLEWorldStep1

A 34-year-old man comes to the office due to upper abdominal pain. The patient has vague discomfort that happens mostly in the afternoon and at night and is partially relieved by food. He sometimes feels nauseated. He has had no vomiting, black or bloody stools, or weight loss. The patient takes no prescription or over-the-counter medications. Family history is negative for cancer. Upper gastrointestinal endoscopy reveals a small ulcer with a clean base in the duodenal bulb. Biopsy of which of the following sites is most likely to demonstrate the infectious agent responsible for this patient's current condition?

- A. Gastric antrum
- B. Gastric body
- C. Gastric fundus
- D. Lower duodenum
- E. Upper duodenum

Submit

https://t.me/USMLEWorldStep1

A 34-year-old man comes to the office due to upper abdominal pain. The patient has vague discomfort that happens mostly in the afternoon and at night and is partially relieved by food. He sometimes feels nauseated. He has had no vomiting, black or bloody stools, or weight loss. The patient takes no prescription or over-the-counter medications. Family history is negative for cancer. Upper gastrointestinal endoscopy reveals a small ulcer with a clean base in the duodenal bulb. Biopsy of which of the following sites is most likely to demonstrate the infectious agent responsible for this patient's current condition?

- ✓ A. Gastric antrum (73%)
- ✗ B. Gastric body (4%)
- C. Gastric fundus (5%)
- D. Lower duodenum (1%)
- E. Upper duodenum (14%)

Incorrect
Correct answer
A

73%
Answered correctly

03 secs
Time Spent

2023
Version

Explanation

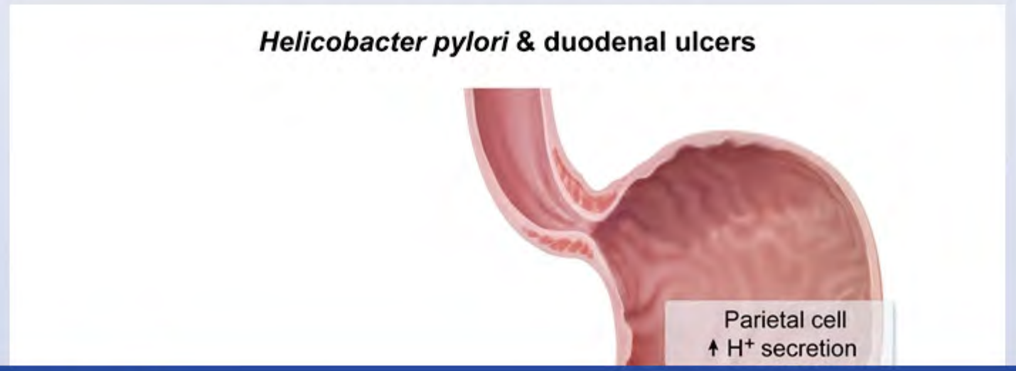

https://t.me/USMLEWorldStep1

Exhibit Display

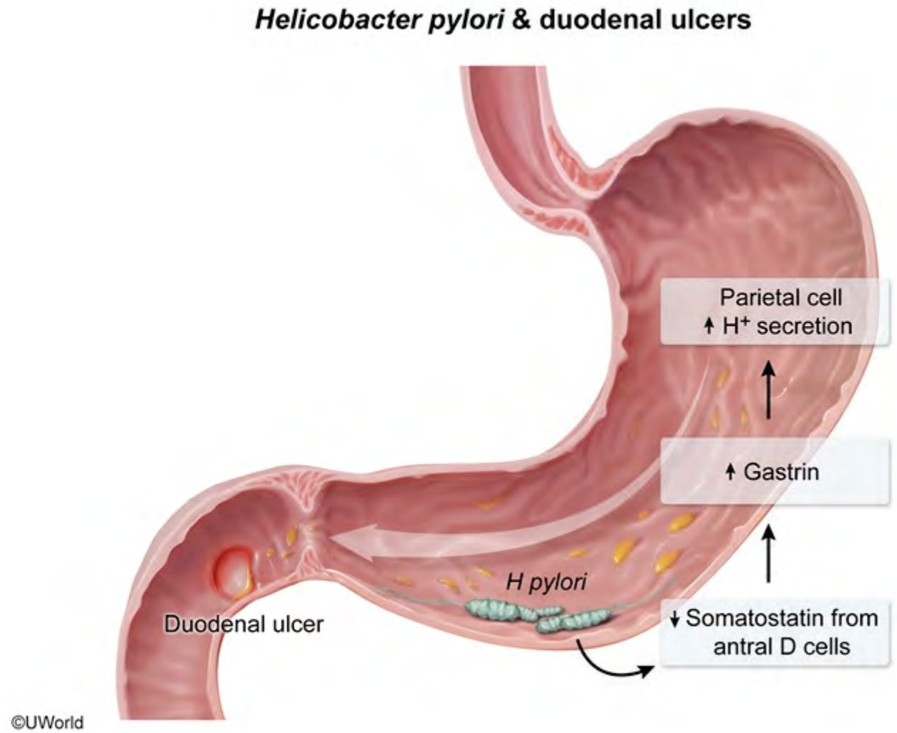

Zoom In | Zoom Out | Reset | New | Existing | My Notebook

Peptic
or use
H pylori infection. The site of ulcer formation is dependent on relative bacterial colonization density within the stomach. *H pylori* preferentially colonizes the gastric antrum, particularly early in the disease, although it may

https://t.me/USMLEWorldStep1

Peptic (eg, duodenal, gastric, gastroesophageal) ulcers are most commonly due to ***Helicobacter pylori*** infection or use of nonsteroidal anti-inflammatory drugs. Because this patient takes no medications, his ulcer is likely due to *H pylori* infection. The site of ulcer formation is dependent on relative bacterial colonization density within the stomach. *H pylori* preferentially colonizes the gastric antrum, particularly early in the disease, although it may occur in other areas of the stomach or spread with time.

Colonization of *H pylori* in the **gastric antrum** is associated with **decreased somatostatin** formation and increased gastrin secretion, which stimulate the parietal cells to produce **excess acid**. This results in an increased acid load emptying into the proximal duodenum, leading to **duodenal ulcer** (DU) formation. Biopsy of the antrum can confirm *H pylori* infection in patients with a DU, which characteristically presents with upper abdominal pain that improves with eating.

In contrast, **gastric ulcers** (GUs) are associated with colonization in the **gastric corpus** (body). The etiology of GUs is not acid related, as these patients typically have normal or reduced acid levels, but is thought to be due to **direct mucosal damage** and chronic inflammation. Unlike DU pain, GU pain often worsens with eating.

(Choices B and C) Patients with DUs who are infected with *H pylori* may test positive for the organism at multiple locations within the stomach. However, colonization density is highest within the antrum, not the gastric body or the gastric fundus; therefore, the antrum is the optimal site for biopsy.

(Choices D and E) Although the ulcer occurs in the duodenum, high concentrations of *H pylori* are not typically found in the duodenal regions, as *H pylori* can colonize only gastric tissue or areas of gastric metaplasia.

Educational objective:
Helicobacter pylori is a common cause of peptic ulcers. Duodenal ulcers are associated with heavy colonization in the gastric antrum, whereas colonization in the gastric corpus is associated with gastric ulcers.

Pathology	Gastrointestinal & Nutrition	Peptic ulcer disease
Subject	System	Topic

Copyright © UWorld. All rights reserved.

https://t.me/USMLEWorldStep1

Exhibit Display

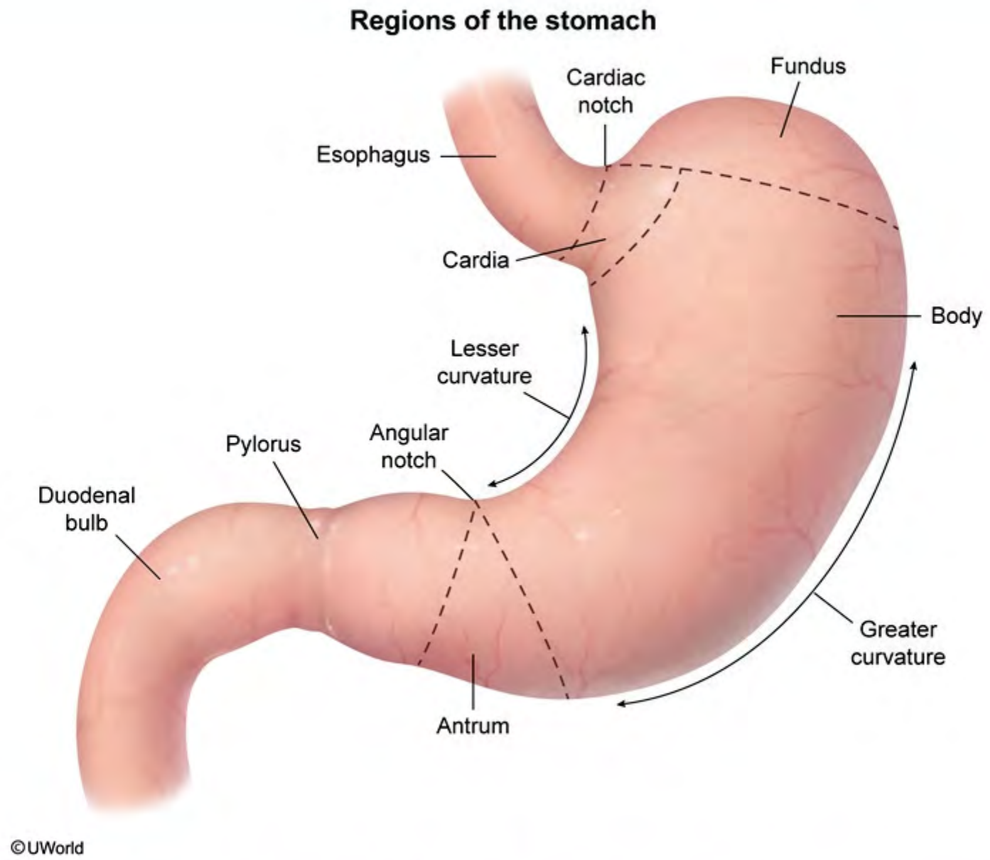

Zoom In | Zoom Out | Reset | New | Existing | My Notebook

Peptic
or use
H pylo
stoma
occur

Coloni
increa
acid lo
can co
that im

In con
GUs is
direct

(Choi
locatio
the ga

(Choi
found

Educa
Helico
the ga

Pathol
Subject

Copyright © UWorld. All rights reserved.

https://t.me/USMLEWorldStep1

A 17-year-old girl is brought to the office due to yellow eyes for the past day. The patient has no other symptoms, including fever, rash, abdominal pain, vomiting, or diarrhea. She has been preparing for her high school exit examination and has been quite stressed. Temperature is 37.1 C (98.8 F), blood pressure is 110/78 mm Hg, pulse is 80/min, and respirations are 14/min. Mild scleral icterus is present. The abdomen is soft with no hepatosplenomegaly. Serum laboratory results are as follows:

Hemoglobin	13.1 g/dL
Bilirubin, total	3.3 mg/dL
Bilirubin, direct	0.3 mg/dL
Aspartate aminotransferase (SGOT)	22 U/L
Alanine aminotransferase (SGPT)	21 U/L

Two weeks after her examination, the patient's symptoms resolve. Repeat testing shows a total bilirubin concentration of 1.5 mg/dL. Which of the following changes most likely contributed to this patient's hyperbilirubinemia?

	Hepatocyte bilirubin storage	Hepatocyte bilirubin excretion	Bilirubin conjugation
○ A.	Decreased	Decreased	Decreased
○ B.	Decreased	Increased	Increased
○ C.	Increased	Decreased	Normal
○ D.	Increased	Increased	Normal
○ E.	Increased	Normal	Decreased
○ F.	Normal	Normal	Decreased

Submit

https://t.me/USMLEWorldStep1

including fever, rash, abdominal pain, vomiting, or diarrhea. She has been preparing for her high school exit examination and has been quite stressed. Temperature is 37.1 C (98.8 F), blood pressure is 110/78 mm Hg, pulse is 80/min, and respirations are 14/min. Mild scleral icterus is present. The abdomen is soft with no hepatosplenomegaly. Serum laboratory results are as follows:

Hemoglobin	13.1 g/dL
Bilirubin, total	3.3 mg/dL
Bilirubin, direct	0.3 mg/dL
Aspartate aminotransferase (SGOT)	22 U/L
Alanine aminotransferase (SGPT)	21 U/L

Two weeks after her examination, the patient's symptoms resolve. Repeat testing shows a total bilirubin concentration of 1.5 mg/dL. Which of the following changes most likely contributed to this patient's hyperbilirubinemia?

		Hepatocyte bilirubin storage	Hepatocyte bilirubin excretion	Bilirubin conjugation	
	A.	Decreased	Decreased	Decreased	(13%)
	B.	Decreased	Increased	Increased	(4%)
✗	C.	Increased	Decreased	Normal	(10%)
	D.	Increased	Increased	Normal	(5%)
	E.	Increased	Normal	Decreased	(13%)
✓	F.	Normal	Normal	Decreased	(52%)

Incorrect
Correct answer
F

52%
Answered correctly

05 secs
Time Spent

2023
Version

https://t.me/USMLEWorldStep1

Explanation

Gilbert syndrome	
Epidemiology	• Most common inherited disorder of bilirubin metabolism
Pathogenesis	• ↓ Hepatic UDP glucuronosyltransferase activity → ↓ conjugation of bilirubin
Clinical findings	• Recurrent episodes of mild jaundice • Provoked by stress (eg, febrile illness, fasting, dehydration, vigorous exercise, menstruation, surgery)
Diagnosis	• ↑ Unconjugated bilirubin (ie, indirect hyperbilirubinemia) • Normal CBC, blood smear, reticulocyte count • Normal AST, ALT, alkaline phosphatase
Treatment	• Benign; no treatment required
ALT = alanine aminotransferase; **AST** = aspartate aminotransferase; **CBC** = complete blood count.	

This patient had self-resolving scleral icterus and **isolated indirect hyperbilirubinemia** associated with a period of stress. These findings are consistent with **Gilbert syndrome**, the most common inherited disorder of bilirubin metabolism.

Normal bilirubin metabolism begins with hepatic uptake of unconjugated bilirubin produced from red blood cell turnover. Within the liver, UDP glucuronosyltransferase conjugates bilirubin with glucuronic acid, after which conjugated bilirubin is excreted into bile canaliculi.

In Gilbert syndrome, a genetic mutation results in reduced enzymatic activity of UDP glucuronosyltransferase and therefore decreased bilirubin conjugation **(Choices B and D)**. Triggers associated with increased bilirubin production (eg, stress, illness, hemolysis) result in **episodic exacerbations** of indirect hyperbilirubinemia, as seen in this patient. Because bilirubin excretion into the bile duct is normal in Gilbert syndrome, hepatocyte bilirubin storage is also normal, as is liver histology **(Choices A and E)**.

https://t.me/USMLEWorldStep1

Treatment	• Benign; no treatment required

ALT = alanine aminotransferase; **AST** = aspartate aminotransferase; **CBC** = complete blood count.

This patient had self-resolving scleral icterus and **isolated indirect hyperbilirubinemia** associated with a period of stress. These findings are consistent with **Gilbert syndrome**, the most common inherited disorder of bilirubin metabolism.

Normal bilirubin metabolism begins with hepatic uptake of unconjugated bilirubin produced from red blood cell turnover. Within the liver, UDP glucuronosyltransferase conjugates bilirubin with glucuronic acid, after which conjugated bilirubin is excreted into bile canaliculi.

In Gilbert syndrome, a genetic mutation results in reduced enzymatic activity of UDP glucuronosyltransferase and therefore decreased bilirubin conjugation **(Choices B and D)**. Triggers associated with increased bilirubin production (eg, stress, illness, hemolysis) result in **episodic exacerbations** of indirect hyperbilirubinemia, as seen in this patient. Because bilirubin excretion into the bile duct is normal in Gilbert syndrome, hepatocyte bilirubin storage is also normal, as is liver histology **(Choices A and E)**.

Notably, impaired bilirubin conjugation also occurs in Crigler-Najjar syndrome, but patients typically have severe, chronic hyperbilirubinemia that begins in the neonatal period and can be associated with bilirubin-induced neurologic dysfunction.

(Choice C) Dubin-Johnson syndrome is a benign, inherited disorder of bilirubin metabolism characterized by defective hepatic excretion of bilirubin into the biliary system. Bilirubin conjugation is normal, but defective excretion results in increased hepatocyte storage of bilirubin, resulting in dense liver pigmentation. Although patients often have recurrent episodes of scleral icterus, elevated direct bilirubin is expected due to reflux of conjugated bilirubin back into the plasma.

Educational objective:
Gilbert syndrome is characterized by indirect hyperbilirubinemia due to decreased bilirubin conjugation. Patients have recurrent, self-resolving episodes of scleral icterus and jaundice triggered by stress.

Pathophysiology | Gastrointestinal & Nutrition | Hereditary hyperbilirubinemias

https://t.me/USMLEWorldStep1

Treatment	• Benign; no treatment required

AL

Exhibit Display

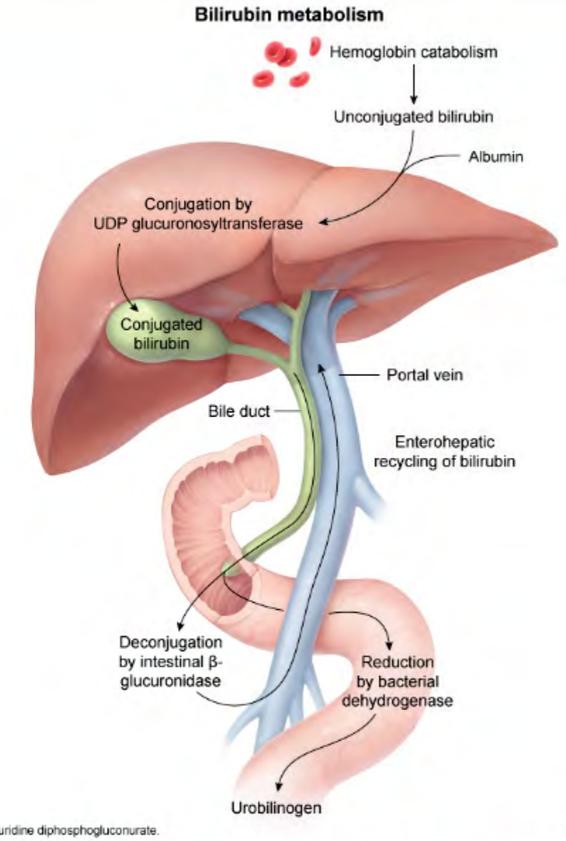

Zoom In | Zoom Out | Reset | New | Existing | My Notebook

This p
stress
metab

Norma
turnov
conjug

In Gilb
therefo
produc
in this
storag

Notabl
chroni
neurol

(Choi
defect
excret
patien
conjug

Educa
Gilbert
have recurrent, self-resolving episodes of scleral icterus and jaundice triggered by stress.

Pathophysiology | Gastrointestinal & Nutrition | Hereditary hyperbilirubinemias

https://t.me/USMLEWorldStep1

Treatment	• Benign; no treatment required

AL

Exhibit Display

This p
stress
metab

Norma
turnov
conjug

In Gilb
therefo
produc
in this
storag

Notabl
chroni
neurol

(Choi
defect
excret
patien
conjug

Educa
Gilbert
have r

Bilirubin metabolism

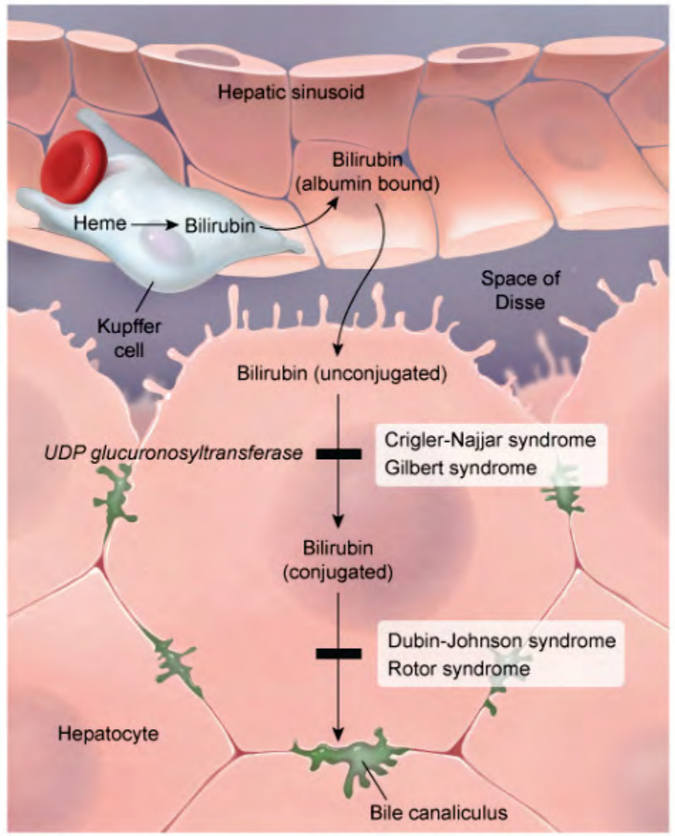

Zoom In | Zoom Out | Reset | New | Existing | My Notebook

Pathophysiology | Gastrointestinal & Nutrition | Hereditary hyperbilirubinemias

https://t.me/USMLEWorldStep1

A 45-year-old man with a history of alcohol use disorder, chronic hepatitis C, and HIV is brought to the emergency department due to altered mental status and abdominal distension. He is disoriented and unable to provide an adequate history. He is accompanied by a friend who reports that the patient has recently been drinking heavily. The patient's breath has a sweet, sulfurous odor. Physical examination shows gynecomastia, palmar erythema, and multiple spider angiomata. The abdomen is severely distended, and dilated periumbilical veins are noted. There is 3+ bilateral lower extremity edema. Genital examination shows testicular atrophy. Neurologic examination shows disorientation and asterixis. Abdominal imaging reveals splenomegaly. Development of this patient's gynecomastia most closely resembles the pathogenesis of which of the following additional findings in this patient?

- A. Altered mental status
- B. Dilated periumbilical veins
- C. Lower extremity edema
- D. Spider angiomata
- E. Splenomegaly
- F. Sweet, sulfurous breath odor

Submit

https://t.me/USMLEWorldStep1

A 45-year-old man with a history of alcohol use disorder, chronic hepatitis C, and HIV is brought to the emergency department due to altered mental status and abdominal distension. He is disoriented and unable to provide an adequate history. He is accompanied by a friend who reports that the patient has recently been drinking heavily. The patient's breath has a sweet, sulfurous odor. Physical examination shows gynecomastia, palmar erythema, and multiple spider angiomata. The abdomen is severely distended, and dilated periumbilical veins are noted. There is 3+ bilateral lower extremity edema. Genital examination shows testicular atrophy. Neurologic examination shows disorientation and asterixis. Abdominal imaging reveals splenomegaly. Development of this patient's gynecomastia most closely resembles the pathogenesis of which of the following additional findings in this patient?

- A. Altered mental status (8%)
- ✗ B. Dilated periumbilical veins (3%)
- C. Lower extremity edema (6%)
- ✓ D. Spider angiomata (67%)
- E. Splenomegaly (2%)
- F. Sweet, sulfurous breath odor (9%)

Incorrect
Correct answer
D

67%
Answered correctly

03 secs
Time Spent

2023
Version

Explanation

Signs of liver cirrhosis

https://t.me/USMLEWorldStep1

A 45-year-old man with a history of alcohol use disorder, chronic hepatitis C, and HIV is brought to the emergency depart
adequ
The pa
and m
There
exami
patien
patien

Exhibit Display

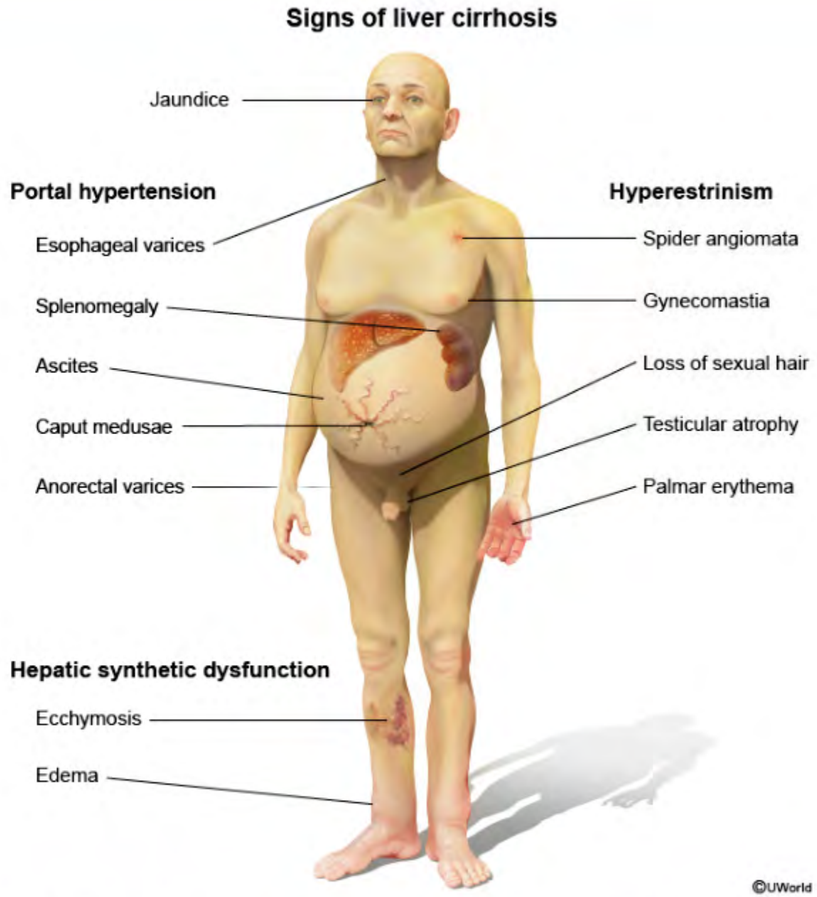

Zoom In | Zoom Out | Reset | New | Existing | My Notebook

Jaundice

https://t.me/USMLEWorldStep1

Exhibit Display

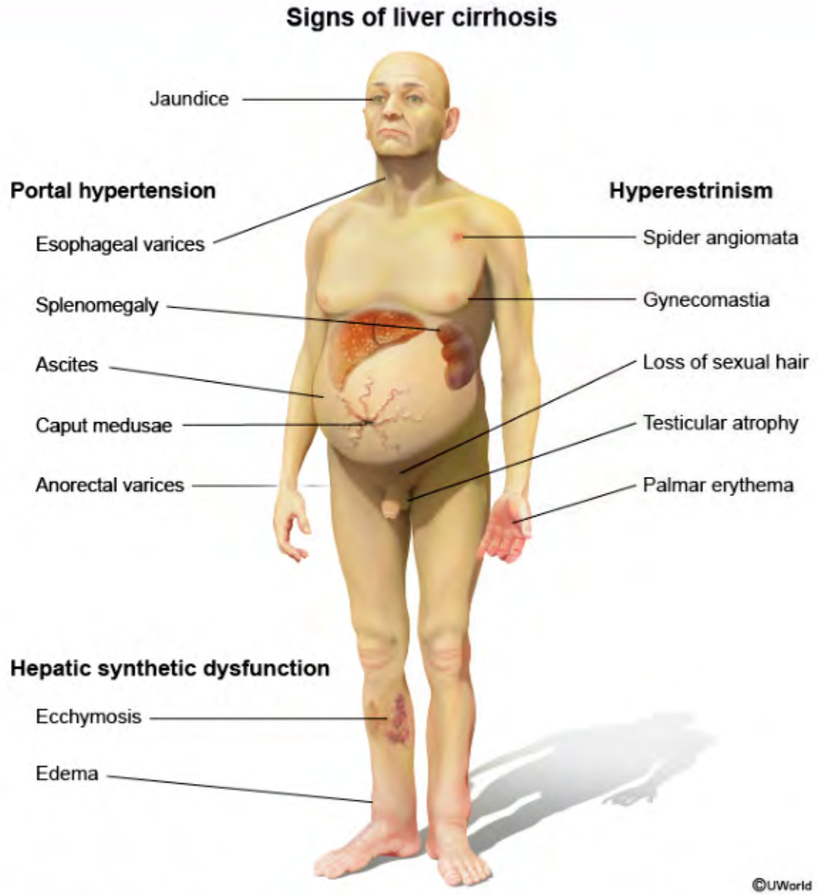

Zoom In | Zoom Out | Reset | New | Existing | My Notebook

This p
gynec

- Cirrhosis increases adrenal production of estrogen precursors (eg, androstenedione), which are subsequently aromatized to estrogens (eg, estrone)

https://t.me/USMLEWorldStep1

©UWorld

This patient has numerous clinical findings characteristic of **liver cirrhosis**. In patients with cirrhosis, **gynecomastia** arises from **hyperestrinism**, which has a number of contributing factors:

- Cirrhosis increases adrenal production of estrogen precursors (eg, androstenedione), which are subsequently aromatized to estrogens (eg, estrone)
- Estrogens induce sex hormone–binding globulin production, which results in increased testosterone binding and a further decrease in the free testosterone/estrogen ratio
- Impaired estrogen metabolism by the liver results in estrogen accumulation

Besides gynecomastia, hyperestrinism in patients with cirrhosis can promote the formation of **spider angiomata**. Spider angiomata are subcutaneous vascular lesions consisting of a central arteriole surrounded by smaller vessels that blanch on compression. They are most frequently found on the trunk, face, and upper limbs. Spider angiomata are likely due to **estrogen-induced arteriolar dilation** and are also seen in other hyperestrogenic states (eg, pregnancy). The number and size of angiomata generally correlate with the severity of liver disease.

(Choices A and F) Altered mental status and a sweet, sulfurous breath odor (fetor hepaticus) are signs of poor hepatic function and accumulation of metabolic toxins (eg, ammonia, dimethyl sulfide). In the healthy liver, ammonia is detoxified to urea, which is then excreted in the urine. In patients with cirrhosis, ammonia accumulates in the blood, resulting in impaired neurotransmission in the CNS and possible brain edema.

(Choices B and E) Portal hypertension arises from increased hepatic resistance to portal flow at the sinusoids. This causes increased hydrostatic pressure and dilation of the portosystemic collateral veins in the periumbilical system (caput medusae), lower rectum (anorectal varices), and lower esophagus (esophageal varices). Portal hypertension also leads to ascites and venous congestion of the spleen (splenomegaly).

(Choice C) The liver is the primary site of protein synthesis. Liver cirrhosis can result in decreased albumin production, leading to lower intravascular oncotic pressure with fluid extravasation and pitting edema in the lower extremities (pedal edema).

Educational objective:

In patients with cirrhosis, gynecomastia often occurs due to hyperestrinism, which can also promote the formation

https://t.me/USMLEWorldStep1

- Cirrhosis increases adrenal production of estrogen precursors (eg, androstenedione), which are subsequently aromatized to estrogens (eg, estrone)
- Estrogens induce sex hormone–binding globulin production, which results in increased testosterone binding and a further decrease in the free testosterone/estrogen ratio
- Impaired estrogen metabolism by the liver results in estrogen accumulation

Besides gynecomastia, hyperestrinism in patients with cirrhosis can promote the formation of **spider angiomata**. Spider angiomata are subcutaneous vascular lesions consisting of a central arteriole surrounded by smaller vessels that blanch on compression. They are most frequently found on the trunk, face, and upper limbs. Spider angiomata are likely due to **estrogen-induced arteriolar dilation** and are also seen in other hyperestrogenic states (eg, pregnancy). The number and size of angiomata generally correlate with the severity of liver disease.

(Choices A and F) Altered mental status and a sweet, sulfurous breath odor (fetor hepaticus) are signs of poor hepatic function and accumulation of metabolic toxins (eg, ammonia, dimethyl sulfide). In the healthy liver, ammonia is detoxified to urea, which is then excreted in the urine. In patients with cirrhosis, ammonia accumulates in the blood, resulting in impaired neurotransmission in the CNS and possible brain edema.

(Choices B and E) Portal hypertension arises from increased hepatic resistance to portal flow at the sinusoids. This causes increased hydrostatic pressure and dilation of the portosystemic collateral veins in the periumbilical system (caput medusae), lower rectum (anorectal varices), and lower esophagus (esophageal varices). Portal hypertension also leads to ascites and venous congestion of the spleen (splenomegaly).

(Choice C) The liver is the primary site of protein synthesis. Liver cirrhosis can result in decreased albumin production, leading to lower intravascular oncotic pressure with fluid extravasation and pitting edema in the lower extremities (pedal edema).

Educational objective:
In patients with cirrhosis, gynecomastia often occurs due to hyperestrinism, which can also promote the formation of spider angiomata.

References

- Gynecomastia

https://t.me/USMLEWorldStep1

©UWorld

This p
gynec

- C
  a
- E
  a
- In

Beside
Spider
vessel
angior
states

(Choi
hepati
ammo
in the

(Choi
This c
systen
hypert

(Choi
produc
extrem

Educational objective:
In patients with cirrhosis, gynecomastia often occurs due to hyperestrinism, which can also promote the formation

Exhibit Display

Spider angioma

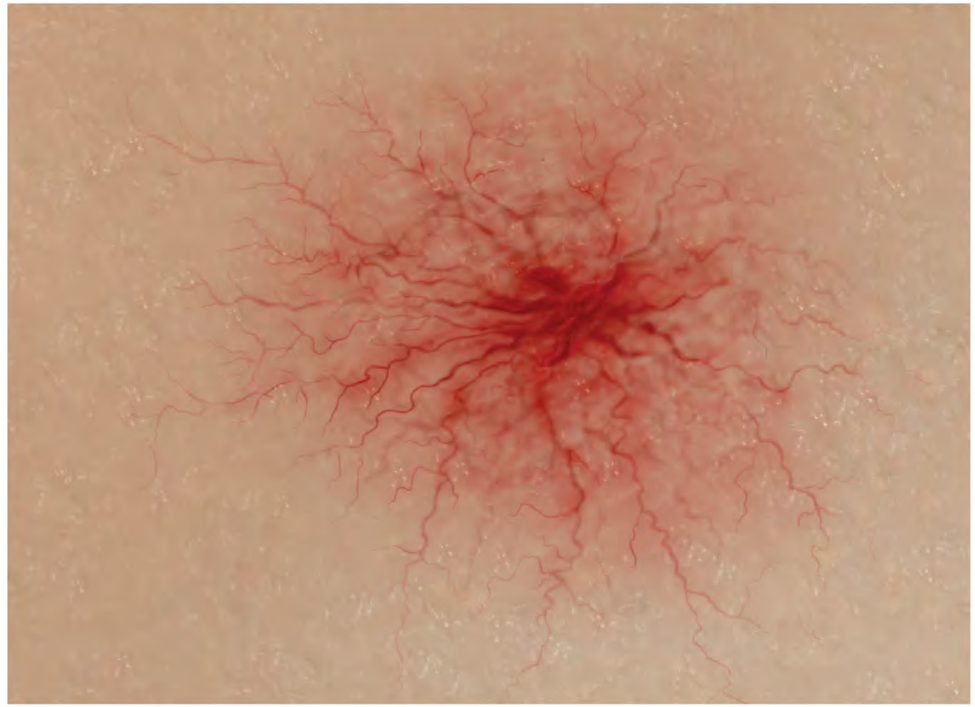

©UWorld

Zoom In | Zoom Out | Reset | New | Existing | My Notebook

https://t.me/USMLEWorldStep1

©UWorld

This p
gynec

- C
  a
- E
  a
- In

Beside
Spider
vessel
angior
states

(Choi
hepati
ammo
in the

(Choi
This c
systen
hypert

(Choi
produc
extremities (pedal edema).

Educational objective:
In patients with cirrhosis, gynecomastia often occurs due to hyperestrinism, which can also promote the formation

Exhibit Display

Caput medusae

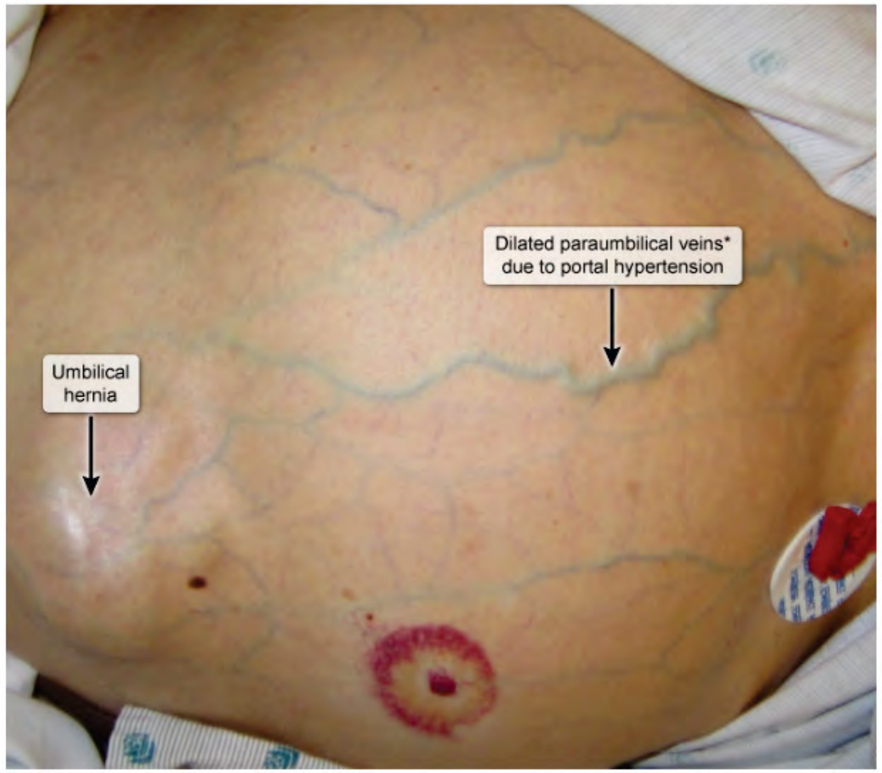

*Shunt blood from portal system to abdominal wall veins.

©UWorld

Zoom In | Zoom Out | Reset | New | Existing | My Notebook

https://t.me/USMLEWorldStep1

A 43-year-old man is hospitalized due to severe epigastric pain radiating to his back. He does not drink alcohol. Temperature is 37.9 C (100.2 F), blood pressure is 114/68 mm Hg, and pulse is 85/min. BMI is 34 kg/m^2. The patient appears restless. Physical examination shows significant epigastric tenderness. Laboratory results are as follows:

Serum chemistry

Glucose	120 mg/dL
Creatinine	1.2 mg/dL
Cholesterol	290 mg/dL
Triglycerides	1,200 mg/dL
Amylase	400 U/L

Administration of intravenous fluids and analgesics is begun. In addition, insulin is administered to rapidly reduce the elevated lipid levels. This medication is likely to improve this patient's condition by stimulating which of the following enzymes?

- A. AMP-activated protein kinase
- B. Hormone-sensitive lipase
- C. HMG-CoA reductase
- D. Lipoprotein lipase
- E. Pyruvate carboxylase

Submit

https://t.me/USMLEWorldStep1

A 43-year-old man is hospitalized due to severe epigastric pain radiating to his back. He does not drink alcohol. Temperature is 37.9 C (100.2 F), blood pressure is 114/68 mm Hg, and pulse is 85/min. BMI is 34 kg/m^2. The patient appears restless. Physical examination shows significant epigastric tenderness. Laboratory results are as follows:

Serum chemistry

Glucose	120 mg/dL
Creatinine	1.2 mg/dL
Cholesterol	290 mg/dL
Triglycerides	1,200 mg/dL
Amylase	400 U/L

Administration of intravenous fluids and analgesics is begun. In addition, insulin is administered to rapidly reduce the elevated lipid levels. This medication is likely to improve this patient's condition by stimulating which of the following enzymes?

- A. AMP-activated protein kinase (10%)
- ✗ B. Hormone-sensitive lipase (37%)
- C. HMG-CoA reductase (6%)
- ✓ D. Lipoprotein lipase (41%)
- E. Pyruvate carboxylase (3%)

Incorrect
Correct answer
D

41%
Answered correctly

06 mins, 31 secs
Time Spent

2023
Version

Explanation

https://t.me/USMLEWorldStep1

Explanation

Exhibit Display

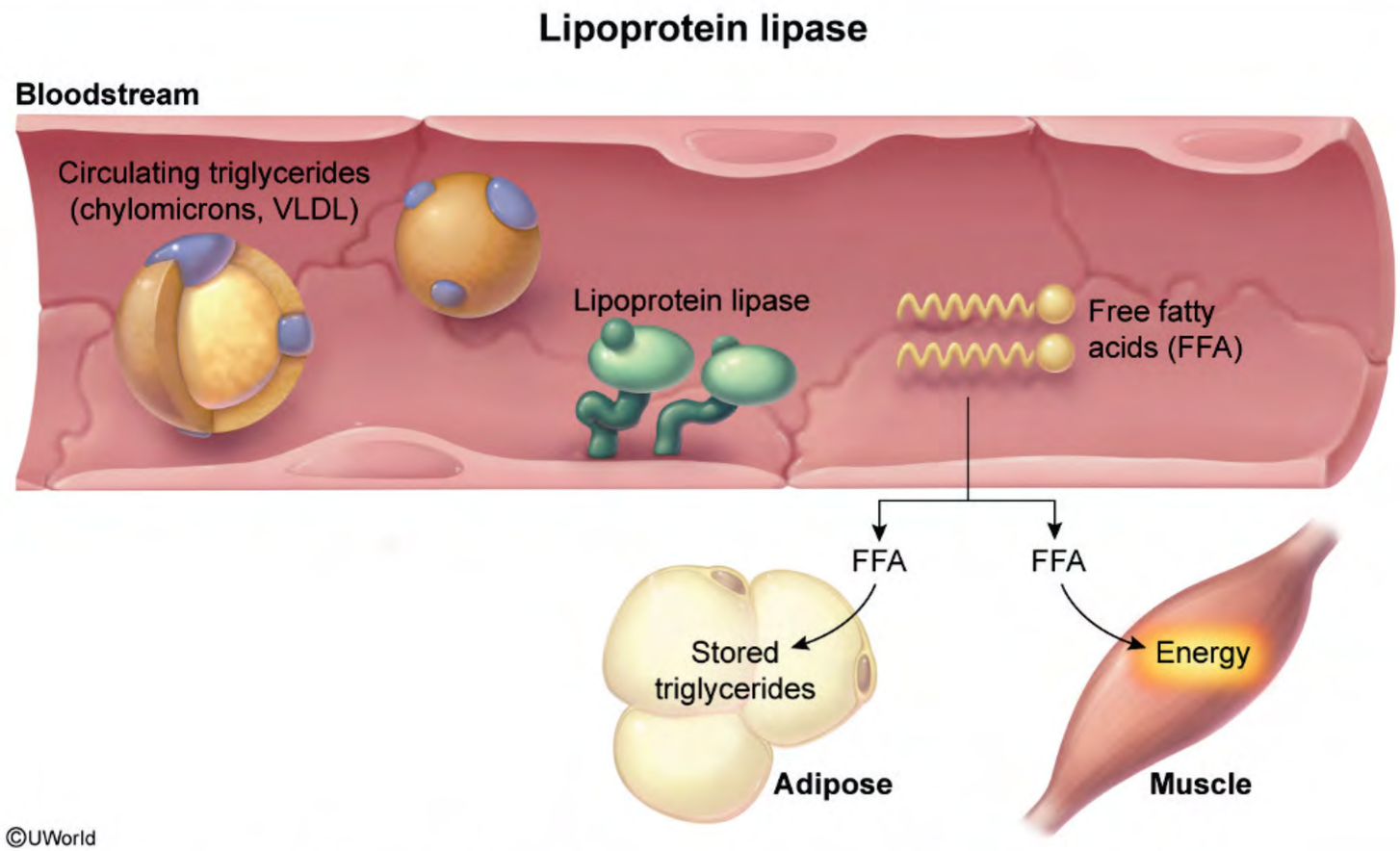

Zoom In Zoom Out Reset New | Existing My Notebook

This p
amyla
Triglyc
elevat

TIP is
VLDL
to yiel

Manag
upregulates **lipoprotein lipase**, which hydrolyzes triglycerides in chylomicrons and VLDL; the liberated fatty acids are largely taken up and **esterified** in adipose tissue, and plasma triglyceride levels are lowered. In addition,

https://t.me/USMLEWorldStep1

©UWorld

This patient has **acute pancreatitis** presenting with abdominal pain, epigastric tenderness, and an elevated serum amylase level. In addition, he has severe **hypertriglyceridemia**, which is the likely cause of his pancreatitis. Triglyceride-induced pancreatitis (TIP) is usually seen in patients with triglyceride levels >1,000 mg/dL. The risk is elevated in patients with diabetes mellitus, obesity, or excessive alcohol use.

TIP is initiated by impaired blood flow in pancreatic capillaries due to excessive concentrations of chylomicrons and VLDL particles. The resulting tissue ischemia releases pancreatic lipases into the plasma, hydrolyzing triglycerides to yield very high local concentrations of **inflammatory free fatty acids**.

Management of TIP requires rapid lowering of triglyceride levels, often with an **insulin infusion**. Insulin upregulates **lipoprotein lipase**, which hydrolyzes triglycerides in chylomicrons and VLDL; the liberated fatty acids are largely taken up and **esterified** in adipose tissue, and plasma triglyceride levels are lowered. In addition, insulin reduces the activity of hormone-sensitive lipase in adipose tissue **(Choice B)**, suppressing the release of fatty acids.

(Choice A) AMP-activated protein kinase (AAPK) suppresses sterol regulatory element-binding protein-1 and acetyl-CoA carboxylase, leading to decreased hepatic fatty acid synthesis and VLDL production. Metformin stimulates AAPK, leading to suppression of lipogenesis and lower circulating triglyceride levels. However, insulin does not increase AAPK activity.

(Choice C) HMG-CoA reductase catalyzes the rate-limiting step in cholesterol production. Insulin increases the activity of HMG-CoA reductase, promoting increased cholesterol synthesis; increasing HMG-CoA reductase activity will not lower serum triglyceride levels.

(Choice E) Pyruvate carboxylase catalyzes the conversion of pyruvate to oxaloacetate, which can be used to drive lipid synthesis (citrate-malate shuttle) or diverted to gluconeogenesis. Insulin downregulates (not upregulates) its activity in the liver, leading to reduced gluconeogenesis and hepatic fatty acid production.

Educational objective:
Triglyceride-induced pancreatitis is initiated by impaired blood flow in pancreatic capillaries due to excessive concentrations of chylomicrons and VLDL particles. Insulin upregulates lipoprotein lipase (an enzyme that

https://t.me/USMLEWorldStep1

Triglyceride-induced pancreatitis (TIP) is usually seen in patients with triglyceride levels >1,000 mg/dL. The risk is elevated in patients with diabetes mellitus, obesity, or excessive alcohol use.

TIP is initiated by impaired blood flow in pancreatic capillaries due to excessive concentrations of chylomicrons and VLDL particles. The resulting tissue ischemia releases pancreatic lipases into the plasma, hydrolyzing triglycerides to yield very high local concentrations of **inflammatory free fatty acids**.

Management of TIP requires rapid lowering of triglyceride levels, often with an **insulin infusion**. Insulin upregulates **lipoprotein lipase**, which hydrolyzes triglycerides in chylomicrons and VLDL; the liberated fatty acids are largely taken up and **esterified** in adipose tissue, and plasma triglyceride levels are lowered. In addition, insulin reduces the activity of hormone-sensitive lipase in adipose tissue **(Choice B)**, suppressing the release of fatty acids.

(Choice A) AMP-activated protein kinase (AAPK) suppresses sterol regulatory element-binding protein-1 and acetyl-CoA carboxylase, leading to decreased hepatic fatty acid synthesis and VLDL production. Metformin stimulates AAPK, leading to suppression of lipogenesis and lower circulating triglyceride levels. However, insulin does not increase AAPK activity.

(Choice C) HMG-CoA reductase catalyzes the rate-limiting step in cholesterol production. Insulin increases the activity of HMG-CoA reductase, promoting increased cholesterol synthesis; increasing HMG-CoA reductase activity will not lower serum triglyceride levels.

(Choice E) Pyruvate carboxylase catalyzes the conversion of pyruvate to oxaloacetate, which can be used to drive lipid synthesis (citrate-malate shuttle) or diverted to gluconeogenesis. Insulin downregulates (not upregulates) its activity in the liver, leading to reduced gluconeogenesis and hepatic fatty acid production.

Educational objective:
Triglyceride-induced pancreatitis is initiated by impaired blood flow in pancreatic capillaries due to excessive concentrations of chylomicrons and VLDL particles. Insulin upregulates lipoprotein lipase (an enzyme that hydrolyzes triglycerides in chylomicrons and VLDL) in adipose tissue capillaries; the liberated fatty acids are taken up by adipose cells, lowering serum triglyceride levels.

References

https://t.me/USMLEWorldStep1

VLDL particles. The resulting tissue ischemia releases pancreatic lipases into the plasma, hydrolyzing triglycerides to yiel

Manag
upregu
are lar
insulin
fatty a

(Choi
acetyl-
stimul
does r

(Choi
activity
will no

(Choi
drive li
upregu

Educa
Triglyc
concer
hydrol
up by

Refere
- Hyp

Exhibit Display

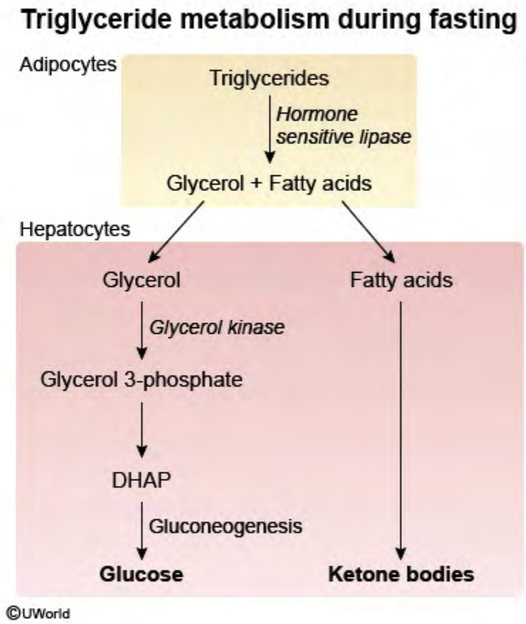

Zoom In | Zoom Out | Reset | New | Existing | My Notebook

Pharmacology (Subject) | Gastrointestinal & Nutrition (System) | Dyslipidemia (Topic)

https://t.me/USMLEWorldStep1

VLDL particles. The resulting tissue ischemia releases pancreatic lipases into the plasma, hydrolyzing triglycerides to yiel

Manag
upregu
are lar
insulin
fatty a

(Choi
acetyl-
stimula
does r

(Choi
activity
will no

(Choi
drive li
upregu

Educa
Triglyc
concer
hydrol
up by

Refere

- Hypertriglyceridemic pancreatitis treated with insulin therapy: a comparative review of 34 cases.

Exhibit Display

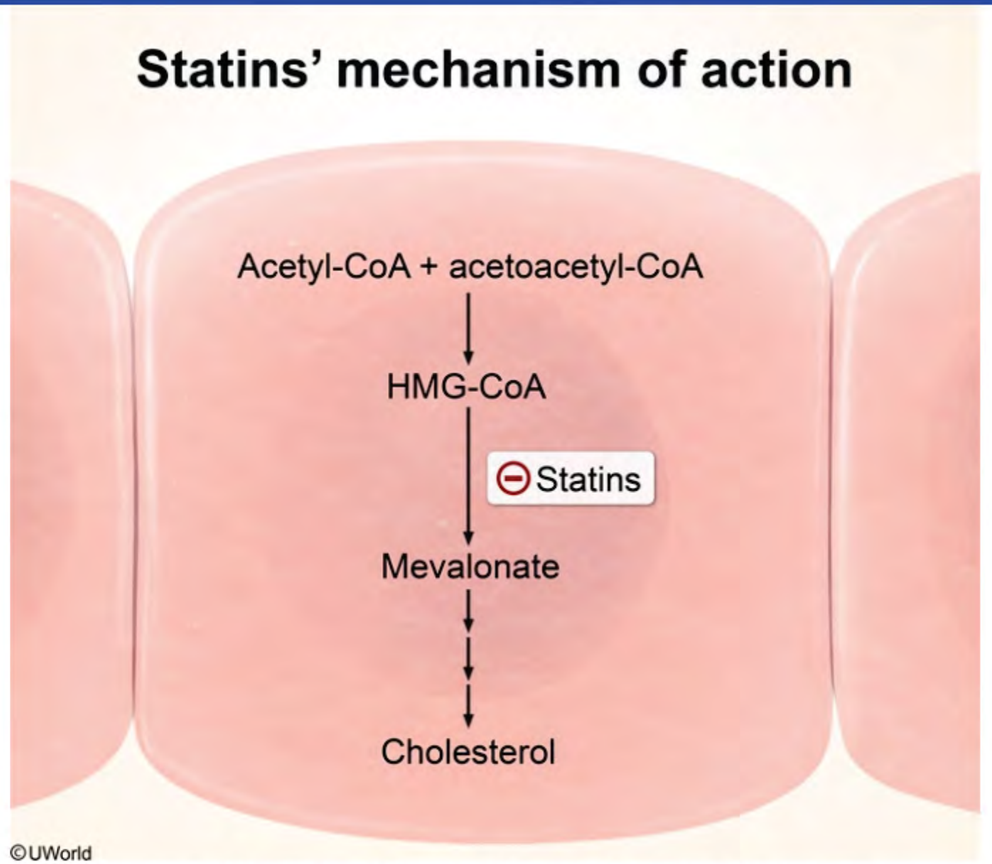

Zoom In Zoom Out Reset New | Existing My Notebook

Pharmacology
Subject

Gastrointestinal & Nutrition
System

Dyslipidemia
Topic

https://t.me/USMLEWorldStep1

VLDL particles. The resulting tissue ischemia releases pancreatic lipases into the plasma, hydrolyzing triglycerides to yiel

Manag
upregu
are lar
insulin
fatty a

(Choi
acetyl-
stimula
does r

(Choi
activity
will no

(Choi
drive li
upregu

Educa
Triglyc
concer
hydrol
up by

Refere
- Hyp

Exhibit Display

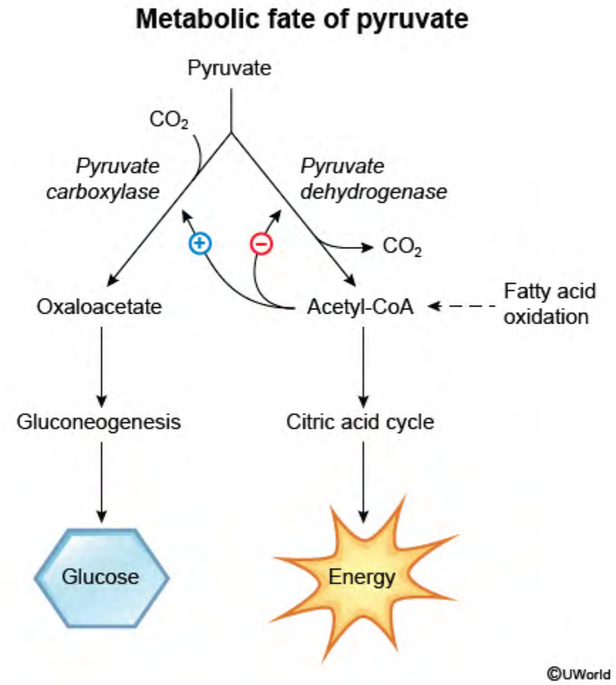

Zoom In | Zoom Out | Reset | New | Existing | My Notebook

Pharmacology (Subject) | Gastrointestinal & Nutrition (System) | Dyslipidemia (Topic)

https://t.me/USMLEWorldStep1

VLDL particles. The resulting tissue ischemia releases pancreatic lipases into the plasma, hydrolyzing triglycerides to yiel

Manag
upregu
are lar
insulin
fatty a

(Choi
acetyl-
stimula
does r

(Choi
activity
will no

(Choi
drive li
upregu

Educa
Triglyc
concer
hydrol
up by

Refere
- Hyp

Exhibit Display

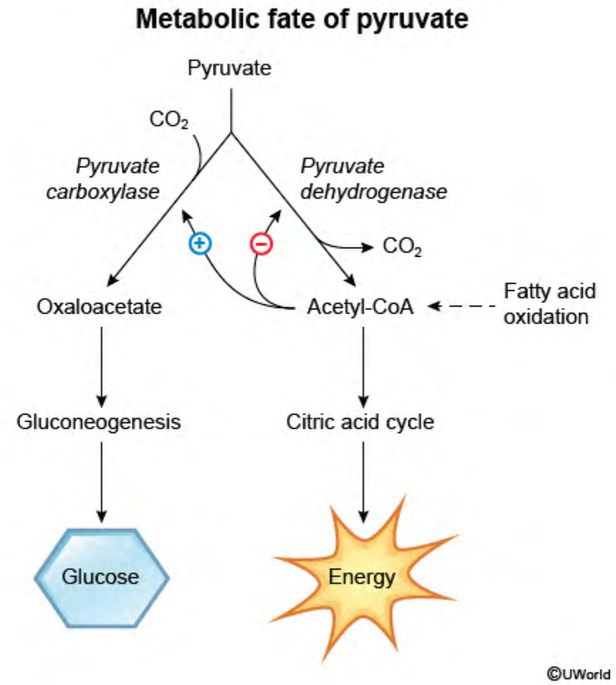

Zoom In | Zoom Out | Reset | New | Existing | My Notebook

Pharmacology (Subject) | Gastrointestinal & Nutrition (System) | Dyslipidemia (Topic)

https://t.me/USMLEWorldStep1

A 52-year-old woman is evaluated for a 6-month history of progressive fatigue and generalized pruritus. She has had no significant prior medical conditions or surgery and takes no medications. The patient does not use tobacco, alcohol, or illicit drugs. Her sister has Sjögren syndrome. Physical examination shows skin excoriations and mild hepatomegaly. Laboratory results are as follows.

Alkaline phosphatase	480 U/L
Aspartate aminotransferase (SGOT)	37 U/L
Alanine aminotransferase (SGPT)	49 U/L
Antimitochondrial antibody	positive

The pathogenesis of this patient's disease process most closely resembles that of which of the following conditions?

- A. Acetaminophen toxicity
- B. Alcohol-induced hepatitis
- C. Budd-Chiari syndrome
- D. Graft versus host disease
- E. Hemochromatosis
- F. Reye syndrome

Submit

https://t.me/USMLEWorldStep1

A 52-year-old woman is evaluated for a 6-month history of progressive fatigue and generalized pruritus. She has had no significant prior medical conditions or surgery and takes no medications. The patient does not use tobacco, alcohol, or illicit drugs. Her sister has Sjögren syndrome. Physical examination shows skin excoriations and mild hepatomegaly. Laboratory results are as follows.

Alkaline phosphatase	480 U/L
Aspartate aminotransferase (SGOT)	37 U/L
Alanine aminotransferase (SGPT)	49 U/L
Antimitochondrial antibody	positive

The pathogenesis of this patient's disease process most closely resembles that of which of the following conditions?

- ✗ A. Acetaminophen toxicity (2%)
- B. Alcohol-induced hepatitis (6%)
- C. Budd-Chiari syndrome (14%)
- ✓ D. Graft versus host disease (59%)
- E. Hemochromatosis (9%)
- F. Reye syndrome (7%)

Incorrect
Correct answer
D

59%
Answered correctly

03 secs
Time Spent

2023
Version

Explanation

Primary biliary cholangitis

https://t.me/USMLEWorldStep1

F. Reye syndrome (7%)

Inco
Corre
D

Expl

Exhibit Display

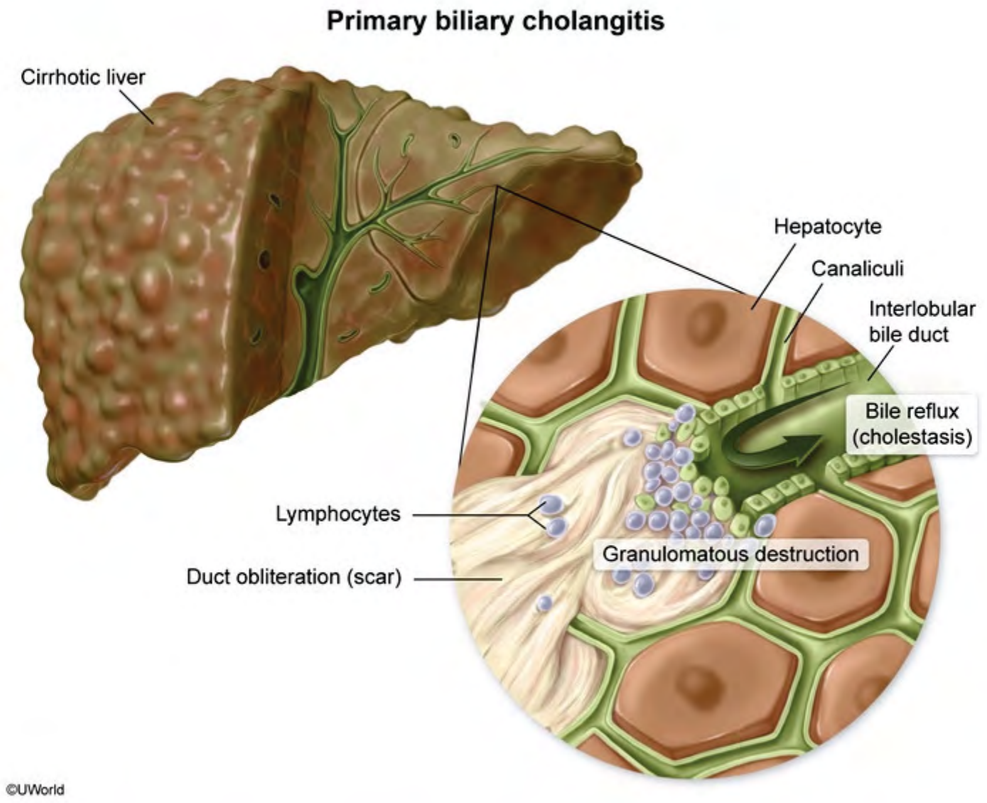

Zoom In | Zoom Out | Reset | New | Existing | My Notebook

Primary biliary cholangitis (PBC, formerly primary biliary cirrhosis) is a chronic **autoimmune liver disease** characterized by destruction of small and midsized intrahepatic bile ducts with resulting cholestasis. It is most

https://t.me/USMLEWorldStep1

Primary biliary cholangitis (PBC, formerly primary biliary cirrhosis) is a chronic **autoimmune liver disease** characterized by destruction of small and midsized intrahepatic bile ducts with resulting cholestasis. It is most common in middle-aged women and is frequently associated with other autoimmune disorders (eg, Sjögren syndrome, rheumatoid arthritis). Clinical features include fatigue, itching, and hepatomegaly. Serum alkaline phosphatase is elevated, and **antimitochondrial antibody** titers are positive in most cases. Biopsy findings in PBC typically show patchy **lymphocytic inflammation**, leading to granulomatous **destruction of intrahepatic bile ducts** (ie, florid duct lesion), with necrosis and micronodular regeneration of periportal tissues.

Of the diseases listed, only **graft versus host disease** (GVHD) causes similar **immune-mediated** destruction of intrahepatic bile ducts. GVHD occurs in immunocompromised patients following transplant of allogeneic bone marrow or other lymphocyte-rich tissues (eg, nonirradiated blood). Donor T-cells migrate into host tissues, where they recognize host major histocompatibility complex antigens as foreign. Liver involvement is often heralded by a rise in alkaline phosphatase and characterized histologically by **lymphocytic infiltration** and **destruction of small intrahepatic bile ducts**, highlighting the **immunologic etiology** of both diseases.

(Choice A) Serious acetaminophen overdose causes direct hepatocellular toxicity resulting in liver failure with centrilobular necrosis that can extend to include entire lobules.

(Choice B) Alcohol-induced hepatitis (due to toxicity from chronic ethanol ingestion) is characterized by hepatocellular swelling and necrosis, steatosis, Mallory bodies, neutrophilic infiltration, and fibrosis.

(Choice C) Budd-Chiari syndrome is due to occlusion of the hepatic veins with a resulting increase in intrahepatic pressure. Gross findings include hepatomegaly with a tense capsule and reddish-purple parenchyma. Typical microscopic findings include severe centrilobular congestion and necrosis.

(Choice E) Hemochromatosis is due to abnormal iron absorption and results in deposition of hemosiderin in the liver. Biopsy is characterized by visible iron within hepatocytes.

(Choice F) Reye syndrome occurs in children with underlying inborn errors in metabolism; acute viral illness (often with concomitant aspirin use) promotes mitochondrial injury and subsequent alterations in metabolism that result in encephalopathy and hepatic dysfunction. Biopsy demonstrates panlobular microvesicular steatosis.

Educational objective:

https://t.me/USMLEWorldStep1

bile ducts (ie, florid duct lesion), with necrosis and micronodular regeneration of periportal tissues.

Of the diseases listed, only **graft versus host disease** (GVHD) causes similar **immune-mediated** destruction of intrahepatic bile ducts. GVHD occurs in immunocompromised patients following transplant of allogeneic bone marrow or other lymphocyte-rich tissues (eg, nonirradiated blood). Donor T-cells migrate into host tissues, where they recognize host major histocompatibility complex antigens as foreign. Liver involvement is often heralded by a rise in alkaline phosphatase and characterized histologically by **lymphocytic infiltration** and **destruction of small intrahepatic bile ducts**, highlighting the **immunologic etiology** of both diseases.

(Choice A) Serious acetaminophen overdose causes direct hepatocellular toxicity resulting in liver failure with centrilobular necrosis that can extend to include entire lobules.

(Choice B) Alcohol-induced hepatitis (due to toxicity from chronic ethanol ingestion) is characterized by hepatocellular swelling and necrosis, steatosis, Mallory bodies, neutrophilic infiltration, and fibrosis.

(Choice C) Budd-Chiari syndrome is due to occlusion of the hepatic veins with a resulting increase in intrahepatic pressure. Gross findings include hepatomegaly with a tense capsule and reddish-purple parenchyma. Typical microscopic findings include severe centrilobular congestion and necrosis.

(Choice E) Hemochromatosis is due to abnormal iron absorption and results in deposition of hemosiderin in the liver. Biopsy is characterized by visible iron within hepatocytes.

(Choice F) Reye syndrome occurs in children with underlying inborn errors in metabolism; acute viral illness (often with concomitant aspirin use) promotes mitochondrial injury and subsequent alterations in metabolism that result in encephalopathy and hepatic dysfunction. Biopsy demonstrates panlobular microvesicular steatosis.

Educational objective:
Primary biliary cholangitis is a chronic autoimmune liver disease characterized by lymphocytic infiltrates and destruction of small and midsized intrahepatic bile ducts. Similar findings are seen in hepatic graft versus host disease, highlighting the immunologic etiology of both disorders.

References

- Aspects of the pathophysiology of primary biliary cirrhosis.

https://t.me/USMLEWorldStep1

syndrome, rheumatoid arthritis). Clinical features include fatigue, itching, and hepatomegaly. Serum alkaline phosphatase is elevated, and **antimitochondrial antibody** titers are positive in most cases. Biopsy findings in PBC ty
bile du

Of the
intrahe
marrov
they re
rise in
intrah

(Choi
centril

(Choi
hepato

(Choi
pressu
micros

(Choi
liver. I

(Choi
with co
encep

Educa
Primar
destru
disease, highlighting the immunologic etiology of both disorders.

Exhibit Display

Alcoholic liver disease

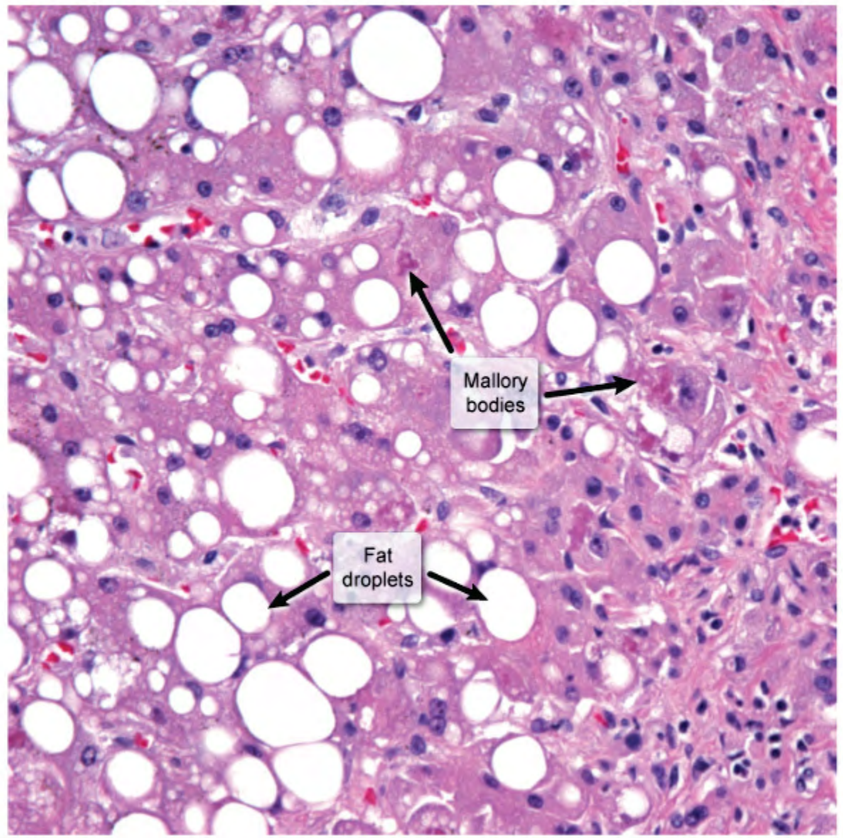

Zoom In | Zoom Out | Reset | New | Existing | My Notebook

https://t.me/USMLEWorldStep1

syndrome, rheumatoid arthritis). Clinical features include fatigue, itching, and hepatomegaly. Serum alkaline phosphatase is elevated, and **antimitochondrial antibody** titers are positive in most cases. Biopsy findings in PBC ty

bile du

Of the

intrahe

marrov

they re

rise in

intrah

(Choic

centril

(Choic

hepato

(Choic

pressu

micros

(Choic

liver. I

(Choic

with co

encep

Educa

Primar

destru

disease, highlighting the immunologic etiology of both disorders.

Exhibit Display

Hereditary hemochromatosis

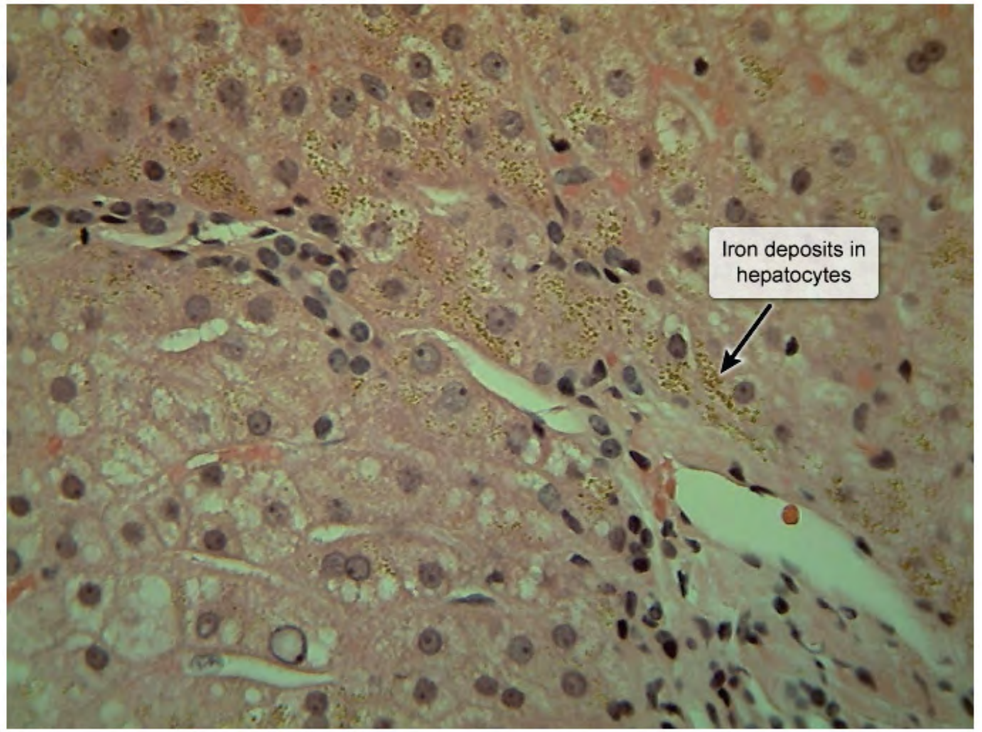

©UWorld

Zoom In | Zoom Out | Reset | New | Existing | My Notebook

https://t.me/USMLEWorldStep1

bile ducts (ie, florid duct lesion), with necrosis and microhodular regeneration of periportal tissues.

Of the diseases listed, only **graft versus host disease** (GVHD) causes similar **immune-mediated** destruction of intrahe
marrov
they re
rise in
intrah

(Choi
centril

(Choi
hepato

(Choi
pressu
micros

(Choi
liver. I

(Choi
with co
encep

Educa
Primar
destru
diseas

Refere
- Asp

Exhibit Display

Hereditary hemochromatosis

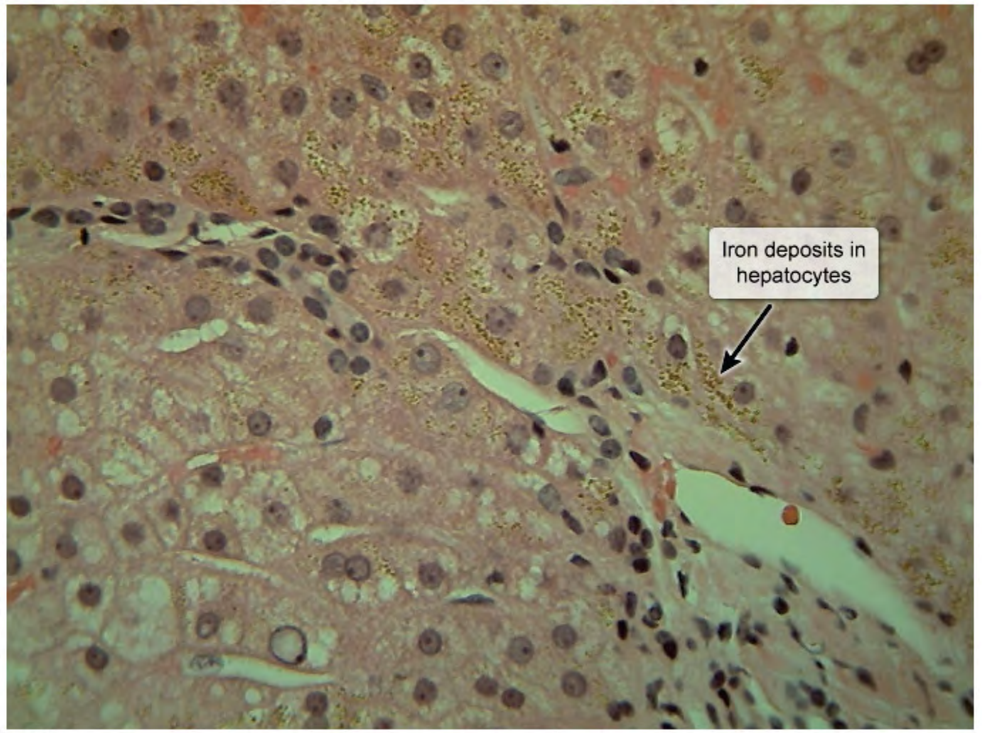

©UWorld

Zoom In | Zoom Out | Reset | New | Existing | My Notebook

https://t.me/USMLEWorldStep1

A 4-month-old boy is being evaluated in the emergency department due to persistent vomiting, fussiness, and feeding intolerance. Symptoms began earlier today. The emesis was initially clear but became bilious over the last few hours. The patient was born at 39 weeks gestation via spontaneous vaginal delivery. His newborn course was unremarkable. The patient has been exclusively breastfed since birth, and his last bowel movement occurred this morning. Temperature is 37.2 C (99 F). Blood pressure and pulse are normal. Physical examination shows abdominal distension. A vomit sample is consistent with bilious emesis. Which of the following is the most likely cause of this patient's presentation?

- A. Abnormal rotation of the ventral pancreatic bud
- B. Failure of esophageal endoderm proliferation
- C. Fibrous obliteration of the biliary ducts
- D. Hypertrophy of the pyloric muscle
- E. Incomplete obliteration of the allantois

Submit

https://t.me/USMLEWorldStep1

A 4-month-old boy is being evaluated in the emergency department due to persistent vomiting, fussiness, and feeding intolerance. Symptoms began earlier today. The emesis was initially clear but became bilious over the last few hours. The patient was born at 39 weeks gestation via spontaneous vaginal delivery. His newborn course was unremarkable. The patient has been exclusively breastfed since birth, and his last bowel movement occurred this morning. Temperature is 37.2 C (99 F). Blood pressure and pulse are normal. Physical examination shows abdominal distension. A vomit sample is consistent with bilious emesis. Which of the following is the most likely cause of this patient's presentation?

- ✓ A. Abnormal rotation of the ventral pancreatic bud
- ✗ B. Failure of esophageal endoderm proliferation
- C. Fibrous obliteration of the biliary ducts
- D. Hypertrophy of the pyloric muscle
- E. Incomplete obliteration of the allantois

Incorrect
Correct answer
A

Collecting Statistics

03 secs
Time Spent

2023
Version

Explanation

Annular pancreas development

https://t.me/USMLEWorldStep1

B. Failure of esophageal endoderm proliferation

Exhibit Display

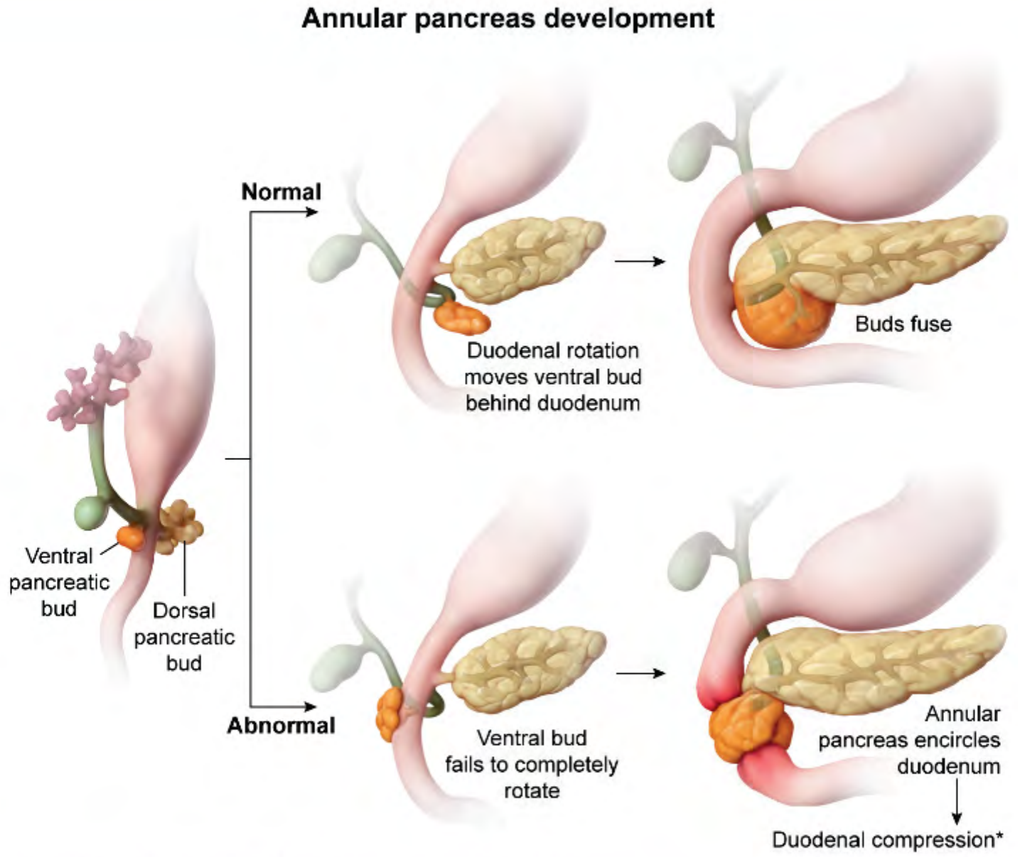

Zoom In | Zoom Out | Reset | New | Existing | My Notebook

https://t.me/USMLEWorldStep1

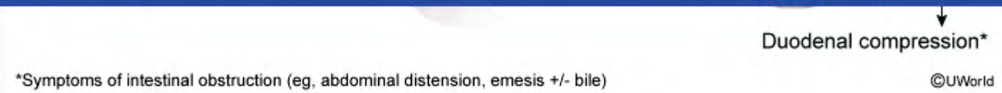

This patient has abdominal distension and bilious emesis, findings suggestive of **intestinal obstruction**. Because the pancreatic and bile ducts join and enter the duodenum at the major duodenal papilla, **bilious emesis** suggests obstruction **distal** to this anatomic location. Of the options, the only defect that could cause obstruction beyond this site is **annular pancreas,** a rare congenital anomaly that occurs when the ventral pancreatic bud fails to rotate completely in utero.

The ventral pancreatic bud is a foregut derivative that appears by the fifth week of gestation. It normally rotates behind the duodenum and fuses with the dorsal pancreatic bud during the seventh to eight weeks. The ventral pancreatic bud gives rise to the uncinate process of the pancreatic head and the main pancreatic duct (of Wirsung). The pancreatic tail, body, and the remainder of head derive from the dorsal bud.

In patients with annular pancreas, **incomplete ventral bud rotation** results in pancreatic tissue surrounding the second part of the duodenum; the majority of patients with annular pancreas are asymptomatic. However, in some individuals, the circumferential pancreatic tissue can compress the duodenal lumen, causing obstruction that can be either proximal to the major duodenal papilla (nonbilious emesis) or distal (bilious emesis, as in this patient). Annular pancreas can also result in obstructed pancreatic drainage (eg, pancreatitis).

(Choice B) Failure of endoderm proliferation as the esophagus is stretched by the rapidly growing heart and liver during the fourth and fifth week of development can cause esophageal atresia (eg, excessive drooling, feeding intolerance immediately after birth). Bilious emesis does not occur because the obstruction is always proximal to the major duodenal papilla.

(Choice C) Fibrous obliteration of the biliary ducts causes biliary atresia, and patients often develop jaundice and acholic stools in the first 2 months of life due to biliary obstruction. Signs and symptoms of intestinal obstruction would not be expected.

(Choice D) Hypertrophy of the pyloric muscle causes pyloric stenosis. Unlike this patient's bilious emesis, pyloric stenosis causes nonbilious emesis in the first 3-6 months of life due to gastric outlet obstruction (ie, proximal to the major duodenal papilla).

https://t.me/USMLEWorldStep1

pancreatic bud gives rise to the uncinate process of the pancreatic head and the main pancreatic duct (of Wirsung). The pancreatic tail, body, and the remainder of head derive from the dorsal bud.

In patients with annular pancreas, **incomplete ventral bud rotation** results in pancreatic tissue surrounding the second part of the duodenum; the majority of patients with annular pancreas are asymptomatic. However, in some individuals, the circumferential pancreatic tissue can compress the duodenal lumen, causing obstruction that can be either proximal to the major duodenal papilla (nonbilious emesis) or distal (bilious emesis, as in this patient). Annular pancreas can also result in obstructed pancreatic drainage (eg, pancreatitis).

(Choice B) Failure of endoderm proliferation as the esophagus is stretched by the rapidly growing heart and liver during the fourth and fifth week of development can cause esophageal atresia (eg, excessive drooling, feeding intolerance immediately after birth). Bilious emesis does not occur because the obstruction is always proximal to the major duodenal papilla.

(Choice C) Fibrous obliteration of the biliary ducts causes biliary atresia, and patients often develop jaundice and acholic stools in the first 2 months of life due to biliary obstruction. Signs and symptoms of intestinal obstruction would not be expected.

(Choice D) Hypertrophy of the pyloric muscle causes pyloric stenosis. Unlike this patient's bilious emesis, pyloric stenosis causes nonbilious emesis in the first 3-6 months of life due to gastric outlet obstruction (ie, proximal to the major duodenal papilla).

(Choice E) Incomplete obliteration of the allantois (connects the bladder to the umbilicus in utero) leads to a patent urachus or urachal cyst. Patients have increased risk for urinary tract infections, and young infants may have vomiting and irritability, but bilious emesis would not be present and persistent umbilical discharge is typical.

Educational objective:
Annular pancreas (ie, pancreatic tissue encircling the duodenum) is caused by abnormal rotation of the ventral pancreatic bud in utero. Although frequently asymptomatic, it can cause intestinal obstruction (eg, vomiting, abdominal distension), including bilious emesis if the constriction is distal to the major duodenal papilla.

Embryology	Gastrointestinal & Nutrition	Annular pancreas
Subject	System	Topic

https://t.me/USMLEWorldStep1

Wirsung). The pancreatic tail, body, and the remainder of head derive from the dorsal bud.

In pati
secon
individ
be eith
Annula

(Choi
during
intoler
the ma

(Choi
acholi
would

(Choi
stenos
major

(Choi
patent
have v

Educa
Annula
pancre
abdom

Embryo
Subject

Exhibit Display

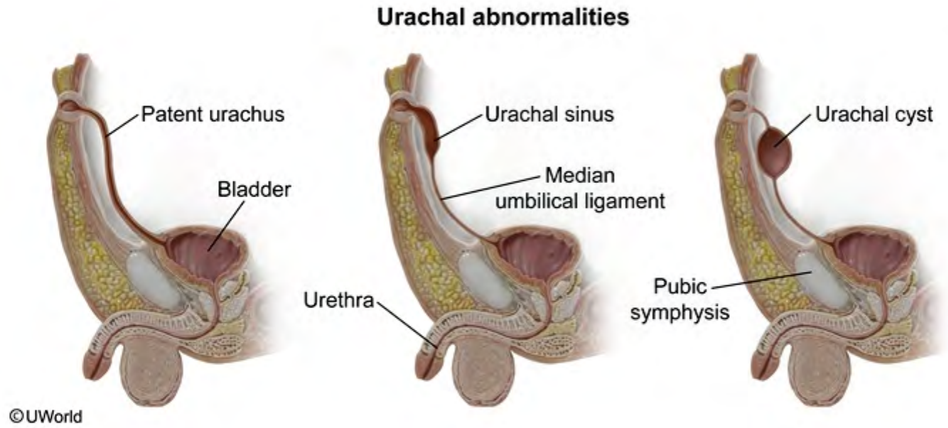

Zoom In Zoom Out Reset New | Existing My Notebook

Copyright © UWorld. All rights reserved.

https://t.me/USMLEWorldStep1

A 45-year-old woman comes to the office for progressive itchiness and fatigue. She also notes yellowing of the eyes and skin. Physical examination shows scleral icterus, multiple excoriations on both the upper and the lower extremities, and hepatomegaly. Laboratory results are as follows:

Liver function studies

Total bilirubin	5.3 mg/dL
Alkaline phosphatase	982 U/L
Aspartate aminotransferase (SGOT)	89 U/L
Alanine aminotransferase (SGPT)	67 U/L
Gamma-glutamyl transpeptidase	450 U/L (normal: 10-60 U/L)

Liver biopsy reveals dense lymphocytic infiltration of the portal triads, as well as granulomatous destruction of interlobular bile ducts. Which of the following is the most likely diagnosis?

- A. Acute hepatitis B
- B. Autoimmune hepatitis
- C. Primary biliary cholangitis
- D. Primary sclerosing cholangitis
- E. Sarcoidosis

Submit

https://t.me/USMLEWorldStep1

A 45-year-old woman comes to the office for progressive itchiness and fatigue. She also notes yellowing of the eyes and skin. Physical examination shows scleral icterus, multiple excoriations on both the upper and the lower extremities, and hepatomegaly. Laboratory results are as follows:

Liver function studies

Total bilirubin	5.3 mg/dL
Alkaline phosphatase	982 U/L
Aspartate aminotransferase (SGOT)	89 U/L
Alanine aminotransferase (SGPT)	67 U/L
Gamma-glutamyl transpeptidase	450 U/L (normal: 10-60 U/L)

Liver biopsy reveals dense lymphocytic infiltration of the portal triads, as well as granulomatous destruction of interlobular bile ducts. Which of the following is the most likely diagnosis?

- ✗ A. Acute hepatitis B (1%)
- B. Autoimmune hepatitis (5%)
- ✓ C. Primary biliary cholangitis (75%)
- D. Primary sclerosing cholangitis (14%)
- E. Sarcoidosis (3%)

Incorrect
Correct answer
C

75%
Answered correctly

03 secs
Time Spent

2023
Version

Explanation

https://t.me/USMLEWorldStep1

B. Autoimmune hepatitis (5%)

C. Primary biliary cholangitis (75%)

Incc
Corre
C

Expl

Exhibit Display

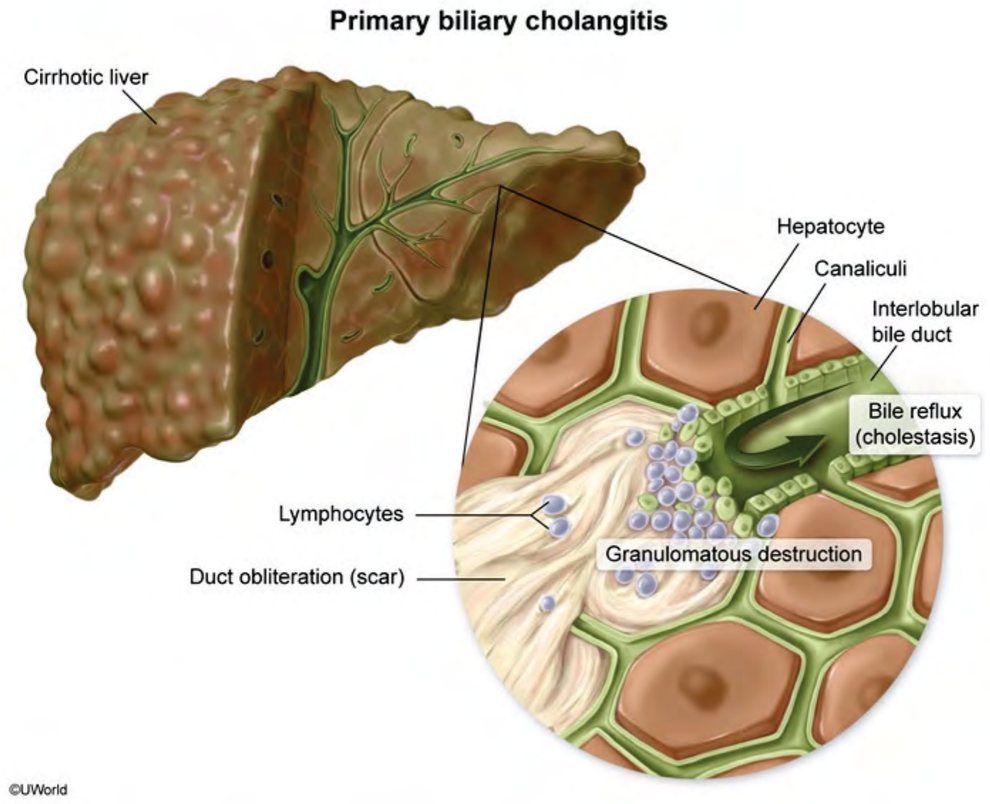

Zoom In | Zoom Out | Reset | New | Existing | My Notebook

https://t.me/USMLEWorldStep1

This patient with fatigue, pruritus, jaundice, and elevated alkaline phosphatase has liver biopsy results consistent with **primary biliary cholangitis** (PBC), a chronic autoimmune disorder that disproportionately affects **middle-aged women**. PBC is characterized by T-cell–mediated destruction of the small intralobular bile ducts, which is visualized histologically as a **dense lymphocytic inflammation** of portal tracts with **granulomatous destruction of interlobular bile ducts** (ie, florid duct lesions).

PBC typically develops insidiously; **fatigue** and **pruritus** are often the presenting symptoms. **Cholestasis** results in a characteristic pattern of liver injury (ie, **elevated alkaline phosphatase**, elevated gamma-glutamyl transferase, direct hyperbilirubinemia, normal or mildly elevated aminotransferases) and examination findings (eg, hepatomegaly, jaundice). Hypercholesterolemia is also common due to reduced cholesterol excretion. Elevated **antimitochondrial antibodies** are highly characteristic.

(Choices A and B) Acute hepatitis B and autoimmune hepatitis (AIH) both result in a hepatocellular, not a cholestatic, pattern of liver injury. Hepatitis B is characterized histologically by lobular mononuclear inflammation, hepatocyte balloon degeneration, and ground-glass hepatocytes, whereas AIH results in portal and periportal lymphoplasmacytic infiltration of the liver (ie, interface hepatitis).

(Choice D) Primary sclerosing cholangitis causes a cholestatic pattern of liver injury but it is identified histologically by fibrous obliteration of bile ducts, as well as concentric periductal deposition of connective tissue in an onion skin–like pattern. It is strongly associated with ulcerative colitis.

(Choice E) Sarcoidosis can cause a cholestatic pattern of liver injury but is characterized by noncaseating granulomas with hepatic fibrosis and a multinucleated giant cell formation. The dense portal lymphocytic infiltration characteristic of PBC is not seen. In addition, most patients have symptoms of systemic sarcoidosis (eg, cough, hilar lymphadenopathy).

Educational objective:
Primary biliary cholangitis is an autoimmune disorder that most commonly affects middle-aged women and is characterized by fatigue, pruritus, jaundice, cholestasis (eg, elevated alkaline phosphatase, elevated gamma-glutamyl transferase, direct hyperbilirubinemia), and antimitochondrial antibodies. Histologic findings include dense lymphocytic portal tract inflammation with granulomatous destruction of interlobular bile ducts.

https://t.me/USMLEWorldStep1

This patient with fatigue, pruritus, jaundice, and elevated alkaline phosphatase has liver biopsy results consistent with p
aged
visuali
of inte

PBC t
in a ch
transfe
hepato
antimi

(Choi
choles
hepato
lymph

(Choi
histolo
an oni

(Choi
granul
charac
hilar ly

Educa
Primar
charac
glutam

dense lymphocytic portal tract inflammation with granulomatous destruction of interlobular bile ducts.

Exhibit Display

Patterns of liver injury	
Hepatocellular	**Cholestatic**
• AST & ALT >> alkaline phosphatase • ↑ Bilirubin	• Alkaline phosphatase >> AST & ALT • ↑ Bilirubin • ↑ Gamma-glutamyl transferase
AST = aspartate transaminase; **ALT** = alanine aminotransferase.	

New | Existing | My Notebook

https://t.me/USMLEWorldStep1

This patient with fatigue, pruritus, jaundice, and elevated alkaline phosphatase has liver biopsy results consistent with p
aged
visuali
of inte

PBC t
in a ch
transfe
hepato
antimi

(Choi
choles
hepato
lymph

(Choi
histolo
an oni

(Choi
granul
charac
hilar ly

Educa
Primar
charac
glutam

dense lymphocytic portal tract inflammation with granulomatous destruction of interlobular bile ducts.

Exhibit Display

Chronic hepatitis B

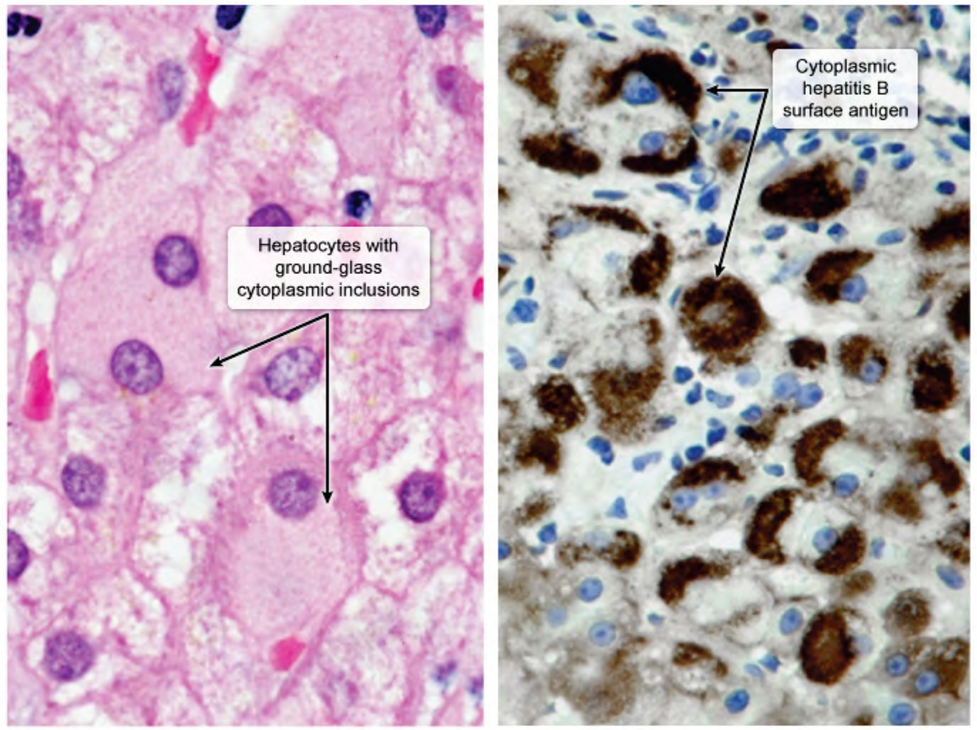

Hematoxylin & eosin stain

Hepatitis B surface antigen stain

©UWorld

Zoom In | Zoom Out | Reset | New | Existing | My Notebook

https://t.me/USMLEWorldStep1

This patient with fatigue, pruritus, jaundice, and elevated alkaline phosphatase has liver biopsy results consistent with p
aged
visuali
of inte

PBC t
in a ch
transfe
hepato
antimi

(Choi
choles
hepato
lymph

(Choi
histolo
an oni

(Choi
granul
charac
hilar ly

Educa
Primar
charac
glutam

dense lymphocytic portal tract inflammation with granulomatous destruction of interlobular bile ducts.

Exhibit Display

Primary sclerosing cholangitis

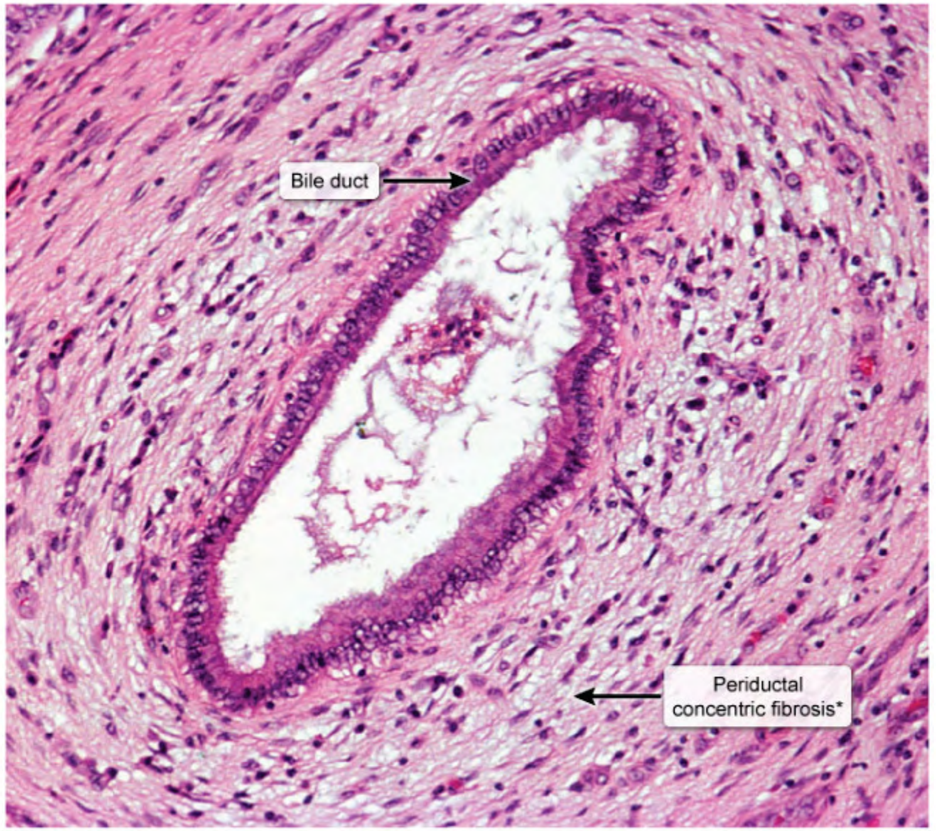

*"Onion-skin" appearance

©UWorld

Zoom In | Zoom Out | Reset | New | Existing | My Notebook

https://t.me/USMLEWorldStep1

This patient with fatigue, pruritus, jaundice, and elevated alkaline phosphatase has liver biopsy results consistent with pr
aged
visuali
of inte

PBC ty
in a ch
transfe
hepato
antimi

(Choic
choles
hepato
lymph

(Choic
histolo
an oni

(Choic
granul
charac
hilar ly

Educa
Primar
charac
glutam

dense lymphocytic portal tract inflammation with granulomatous destruction of interlobular bile ducts.

Exhibit Display

Sarcoidosis

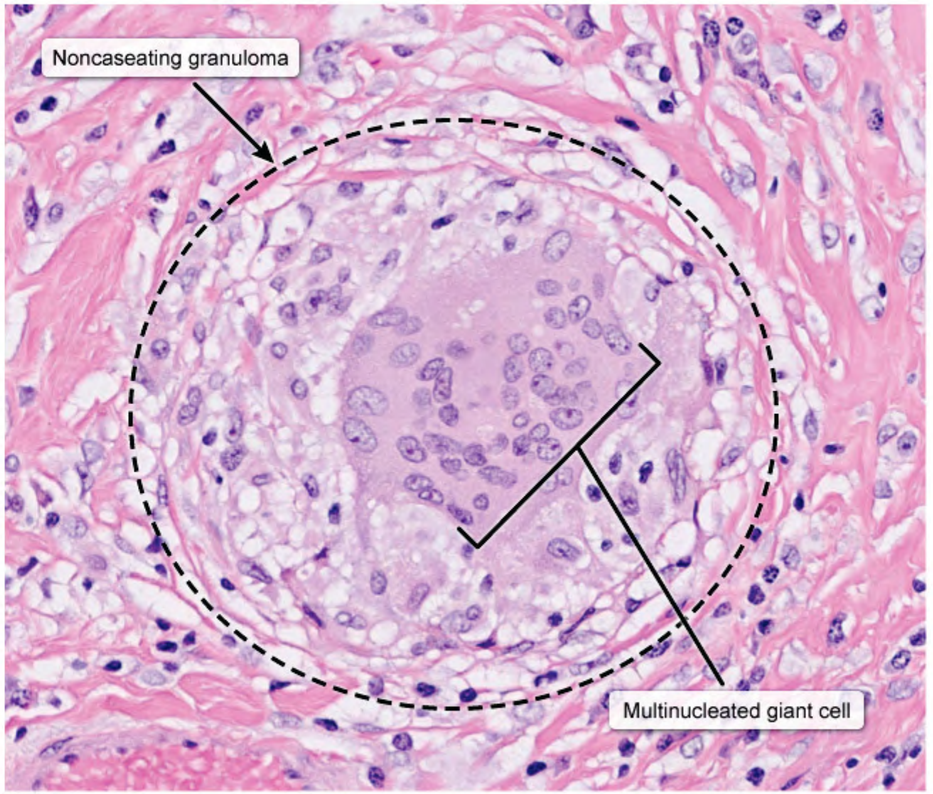

©UWorld

Zoom In | Zoom Out | Reset | New | Existing | My Notebook

https://t.me/USMLEWorldStep1

A 55-year-old man comes to the office due to swelling in his groin that he first noticed 2 weeks ago. Physical examination shows a bulge above the inguinal ligament that increases in size when the patient is asked to cough. He is referred to a surgeon and scheduled to undergo elective laparoscopic hernia repair. Which of the following landmarks will best aid the surgeon in distinguishing an indirect from a direct inguinal hernia?

- A. Femoral vein
- B. Inferior epigastric vessels
- C. Pectineal ligament
- D. Rectus muscle sheath
- E. Spermatic cord
- F. Transversalis fascia

Submit

https://t.me/USMLEWorldStep1

A 55-year-old man comes to the office due to swelling in his groin that he first noticed 2 weeks ago. Physical examination shows a bulge above the inguinal ligament that increases in size when the patient is asked to cough. He is referred to a surgeon and scheduled to undergo elective laparoscopic hernia repair. Which of the following landmarks will best aid the surgeon in distinguishing an indirect from a direct inguinal hernia?

- A. Femoral vein (2%)
- ✓ B. Inferior epigastric vessels (84%)
- C. Pectineal ligament (1%)
- D. Rectus muscle sheath (1%)
- E. Spermatic cord (5%)
- F. Transversalis fascia (4%)

Correct | 84% Answered correctly | 03 secs Time Spent | 2023 Version

Explanation

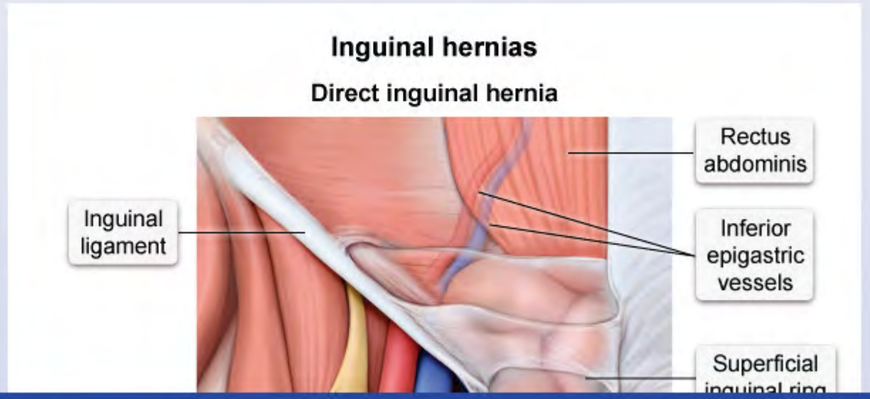

https://t.me/USMLEWorldStep1

A 55-year-old man comes to the office due to swelling in his groin that he first noticed 2 weeks ago. Physical
exami
He is
landm

Exhibit Display

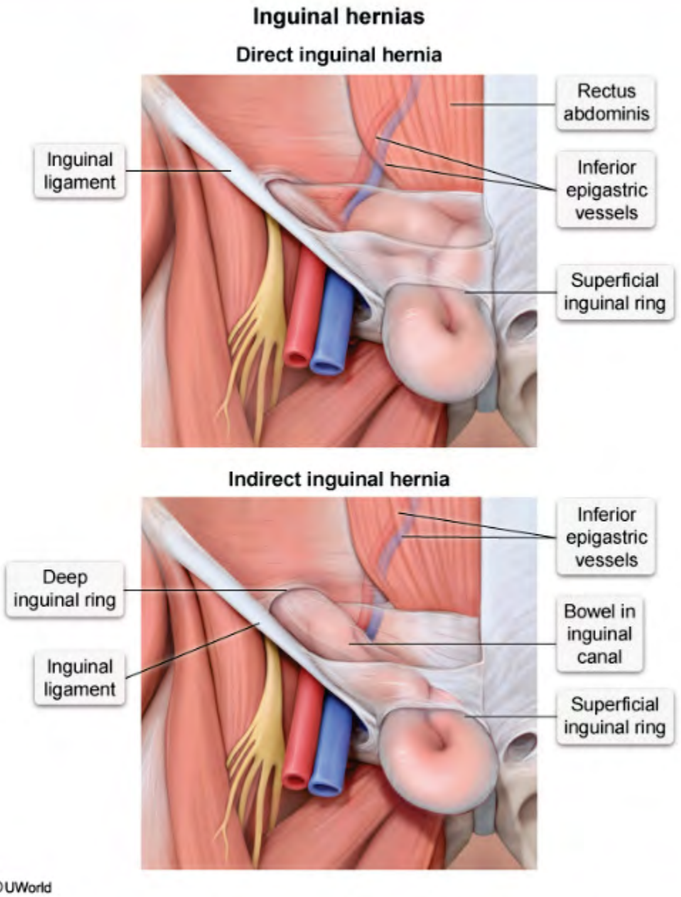

Zoom In | Zoom Out | Reset | New | Existing | My Notebook

Cor

Expl

https://t.me/USMLEWorldStep1

©UWorld

Inguinal hernias are located above the inguinal ligament and are much more common in men. The **inferior epigastric vessels** are clearly visible on the anterior abdominal wall during laparoscopic hernia repair and can be used as a landmark to **distinguish** between direct and indirect inguinal hernias.

Indirect inguinal hernias occur due to failure of the processus vaginalis to obliterate, allowing abdominal contents to protrude **lateral** to the inferior epigastric vessels through the deep (internal) inguinal ring. The abdominal contents follow the path of the inguinal canal and may exit through the superficial (external) inguinal ring into the scrotum.

Direct inguinal hernias occur due to weakness in the transversalis fascia that allows abdominal contents to protrude **medial** to the inferior epigastric vessels into the Hesselbach triangle. Compared to indirect inguinal hernias, direct hernias are less prone to incarceration due to their wide neck. It is also uncommon for them to descend into the scrotum as there is no direct path through the abdominal fascia.

(Choice A) The femoral vein runs directly lateral to femoral hernias, which protrude below the inguinal ligament into the femoral canal.

(Choice C) The pectineal ligament (inguinal ligament of Cooper) forms the posterior border of the femoral ring and would be located behind a femoral hernia that protrudes through the ring.

(Choice D) The rectus abdominis muscle sheath forms the most medial aspect of the Hesselbach triangle, which is the site of protrusion for direct inguinal hernias. Because both direct and indirect inguinal hernias lie lateral to the rectus abdominis muscle sheath, it would not be useful for distinguishing these two types of hernia.

(Choice E) Indirect inguinal hernias follow the path of the spermatic cord (or uterine round ligament) as it courses through the deep (internal) inguinal ring.

(Choice F) The transversalis fascia is the site of weakness in a direct inguinal hernia and lies posterior to indirect inguinal hernias as they extend through the inguinal canal.

Educational objective:
The inferior epigastric vessels are useful as a landmark during laparoscopic hernia repair to classify the type of

https://t.me/USMLEWorldStep1

epigastric vessels are clearly visible on the anterior abdominal wall during laparoscopic hernia repair and can be used as a landmark to **distinguish** between direct and indirect inguinal hernias.

Indirect inguinal hernias occur due to failure of the processus vaginalis to obliterate, allowing abdominal contents to protrude **lateral** to the inferior epigastric vessels through the deep (internal) inguinal ring. The abdominal contents follow the path of the inguinal canal and may exit through the superficial (external) inguinal ring into the scrotum.

Direct inguinal hernias occur due to weakness in the transversalis fascia that allows abdominal contents to protrude **medial** to the inferior epigastric vessels into the Hesselbach triangle. Compared to indirect inguinal hernias, direct hernias are less prone to incarceration due to their wide neck. It is also uncommon for them to descend into the scrotum as there is no direct path through the abdominal fascia.

(Choice A) The femoral vein runs directly lateral to femoral hernias, which protrude below the inguinal ligament into the femoral canal.

(Choice C) The pectineal ligament (inguinal ligament of Cooper) forms the posterior border of the femoral ring and would be located behind a femoral hernia that protrudes through the ring.

(Choice D) The rectus abdominis muscle sheath forms the most medial aspect of the Hesselbach triangle, which is the site of protrusion for direct inguinal hernias. Because both direct and indirect inguinal hernias lie lateral to the rectus abdominis muscle sheath, it would not be useful for distinguishing these two types of hernia.

(Choice E) Indirect inguinal hernias follow the path of the spermatic cord (or uterine round ligament) as it courses through the deep (internal) inguinal ring.

(Choice F) The transversalis fascia is the site of weakness in a direct inguinal hernia and lies posterior to indirect inguinal hernias as they extend through the inguinal canal.

Educational objective:
The inferior epigastric vessels are useful as a landmark during laparoscopic hernia repair to classify the type of inguinal hernia. Indirect inguinal hernias protrude through the deep inguinal ring into the inguinal canal lateral to the inferior epigastric vessels. In contrast, direct inguinal hernias protrude through Hesselbach's triangle medial to the inferior epigastric vessels.

https://t.me/USMLEWorldStep1

Exhibit Display

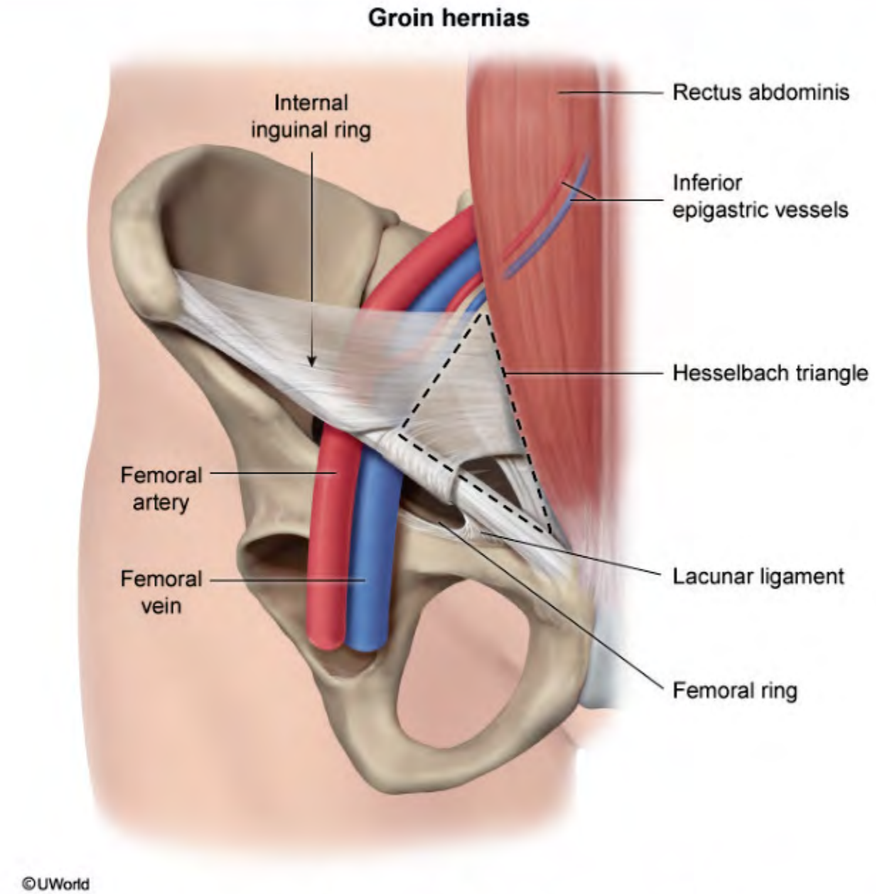

Zoom In | Zoom Out | Reset | New | Existing | My Notebook

Inguin
epigas
used a

Indire
to prot
conter
scrotu

Direct
protru
hernia
desce

(Choi
into th

(Choi
would

(Choi
is the
the re

(Choi
throug

(Choi
inguin

Educational objective:
The inferior epigastric vessels are useful as a landmark during laparoscopic hernia repair to classify the type of

https://t.me/USMLEWorldStep1

Exhibit Display

Femoral hernia

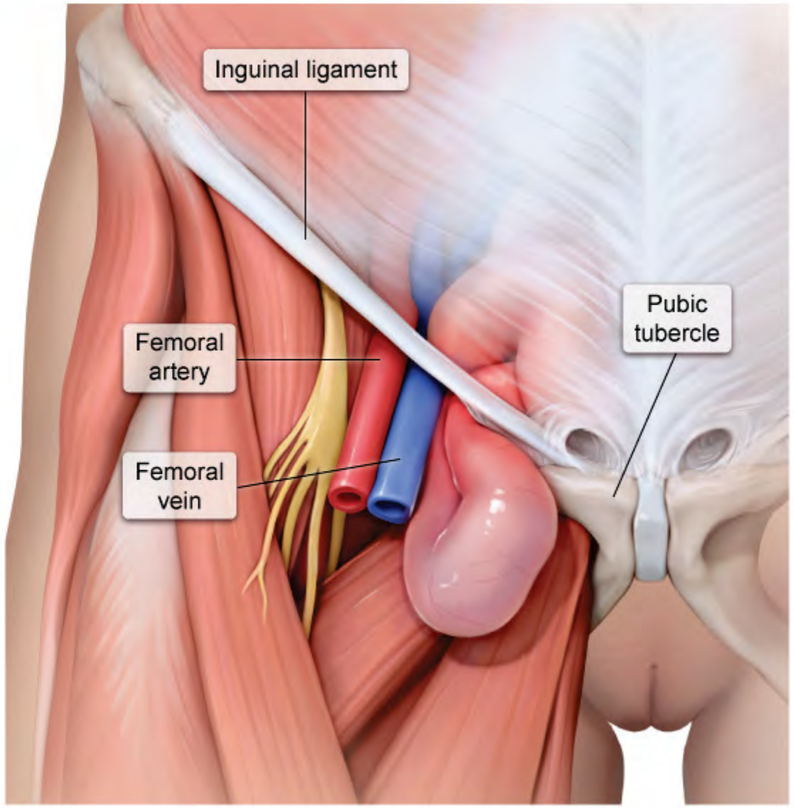

©UWorld

Zoom In | Zoom Out | Reset | New | Existing | My Notebook

Educational objective:

The inferior epigastric vessels are useful as a landmark during laparoscopic hernia repair to classify the type of

https://t.me/USMLEWorldStep1

Researchers studying gastrointestinal pathophysiology analyze hundreds of gastric mucosal biopsy specimens taken from patients who underwent endoscopy at a local tertiary care center. They notice that colonization of the gastric antrum with S-shaped, gram-negative bacteria is associated with a decreased number of somatostatin-producing antral cells. Depletion of these cells from the gastric antrum is most likely to cause which of the following conditions?

- A. Chronic pancreatitis
- B. Duodenal ulcers
- C. Gastric lymphoma
- D. Gastric ulcers
- E. Vitamin B_{12} deficiency

Submit

https://t.me/USMLEWorldStep1

Researchers studying gastrointestinal pathophysiology analyze hundreds of gastric mucosal biopsy specimens taken from patients who underwent endoscopy at a local tertiary care center. They notice that colonization of the gastric antrum with S-shaped, gram-negative bacteria is associated with a decreased number of somatostatin-producing antral cells. Depletion of these cells from the gastric antrum is most likely to cause which of the following conditions?

- ✗ A. Chronic pancreatitis (1%)
- ✓ B. Duodenal ulcers (62%)
- C. Gastric lymphoma (2%)
- D. Gastric ulcers (30%)
- E. Vitamin B_{12} deficiency (2%)

Incorrect
Correct answer
B

62%
Answered correctly

03 secs
Time Spent

2023
Version

Explanation

***Helicobacter pylori* & duodenal ulcers**

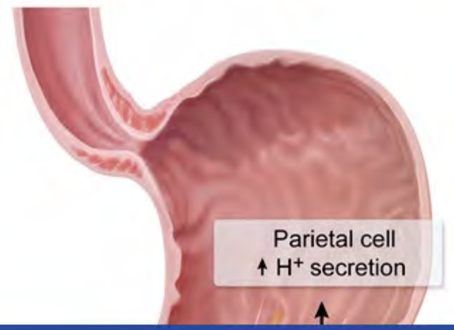

https://t.me/USMLEWorldStep1

Researchers studying gastrointestinal pathophysiology analyze hundreds of gastric mucosal biopsy specimens taken
gastric
produc
followi

Inco
Corre
B

Expl

Exhibit Display

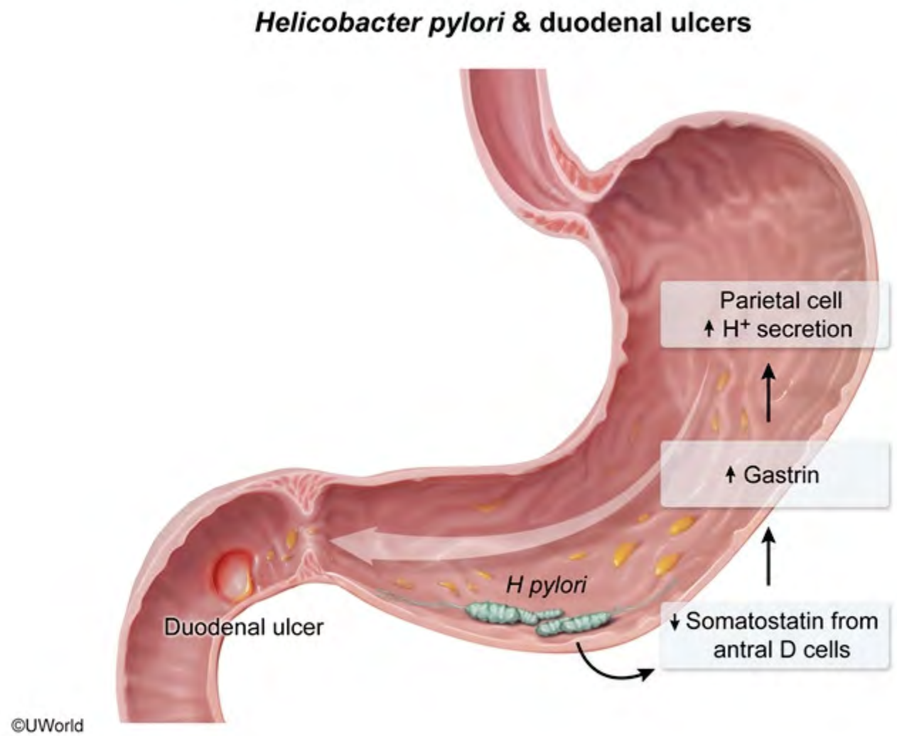

Zoom In | Zoom Out | Reset | New | Existing | My Notebook

↑ H+ secretion

https://t.me/USMLEWorldStep1

Helicobacter pylori is a motile, spiral-shaped, gram-negative bacteria found attached to the gastric mucosa or deep in the mucus layer overlying the gastric epithelium. It is protected from gastric acid by endogenous urease production: **urease** converts urea to ammonia, which alkalinizes the surrounding pH but injures gastric epithelial cells. Damage to the gastric mucosa is compounded by localized inflammation due to the immunologic response against *H pylori*.

Chronic inflammation due to *H pylori* colonization in the **gastric antrum** leads to **depletion of somatostatin-producing cells** (delta cells), which are located mostly in the antrum. Somatostatin inhibits gastrin release from G-cells. In its absence, **elevated gastrin** levels act directly (via cholecystokinin B receptors) and indirectly (via histamine release by enterochromaffin-like cells) to **increase acid secretion** by parietal cells. In addition, *H pylori* releases cytotoxins that inhibit duodenal production of bicarbonate. The resultant increased acid load is emptied into the under-protected duodenum, leading to **duodenal ulcer** formation.

In contrast, gastric ulcers occur when *H pylori* colonizes the gastric body (corpus) **(Choice D)**. Chronic inflammation leads to multifocal atrophic gastritis and a reduction in the number of acid-producing parietal cells, which are located mostly in the gastric body. Delta cells in the antrum are not markedly reduced, therefore acid secretion is often low to normal. Gastric ulcer formation results from direct mucosal damage caused by bacterial products (eg, ammonia, cytotoxins) and the resultant inflammatory response. Unlike antral-predominant disease, corpus-predominant disease is associated with metaplasia and malignancies (eg, gastric lymphoma, adenocarcinoma) **(Choice C)**.

(Choice A) Chronic pancreatitis is not associated with *H pylori* infection. It is most frequently caused by chronic alcoholism or obstruction of the pancreatic ducts due to gallstones or malignancy.

(Choice E) Vitamin B_{12} deficiency can result from autoimmune gastritis. Autoimmune gastritis is characterized by autoantibodies against gastric parietal cells leading to inflammation of the gastric mucosa, parietal cell destruction, and achlorhydria. Its etiology is at least partially genetic.

Educational objective:
Helicobacter pylori antral gastritis is associated with the formation of duodenal ulcers due to increased gastric acid production. This increase in acidity is caused by unchecked gastrin production due to the destruction of somatostatin-secreting cells in the gastric antrum.

https://t.me/USMLEWorldStep1

cells. Damage to the gastric mucosa is compounded by localized inflammation due to the immunologic response against *H pylori*.

Chronic inflammation due to *H pylori* colonization in the **gastric antrum** leads to **depletion of somatostatin-producing cells** (delta cells), which are located mostly in the antrum. Somatostatin inhibits gastrin release from G-cells. In its absence, **elevated gastrin** levels act directly (via cholecystokinin B receptors) and indirectly (via histamine release by enterochromaffin-like cells) to **increase acid secretion** by parietal cells. In addition, *H pylori* releases cytotoxins that inhibit duodenal production of bicarbonate. The resultant increased acid load is emptied into the under-protected duodenum, leading to **duodenal ulcer** formation.

In contrast, gastric ulcers occur when *H pylori* colonizes the gastric body (corpus) **(Choice D)**. Chronic inflammation leads to multifocal atrophic gastritis and a reduction in the number of acid-producing parietal cells, which are located mostly in the gastric body. Delta cells in the antrum are not markedly reduced, therefore acid secretion is often low to normal. Gastric ulcer formation results from direct mucosal damage caused by bacterial products (eg, ammonia, cytotoxins) and the resultant inflammatory response. Unlike antral-predominant disease, corpus-predominant disease is associated with metaplasia and malignancies (eg, gastric lymphoma, adenocarcinoma) **(Choice C)**.

(Choice A) Chronic pancreatitis is not associated with *H pylori* infection. It is most frequently caused by chronic alcoholism or obstruction of the pancreatic ducts due to gallstones or malignancy.

(Choice E) Vitamin B_{12} deficiency can result from autoimmune gastritis. Autoimmune gastritis is characterized by autoantibodies against gastric parietal cells leading to inflammation of the gastric mucosa, parietal cell destruction, and achlorhydria. Its etiology is at least partially genetic.

Educational objective:
Helicobacter pylori antral gastritis is associated with the formation of duodenal ulcers due to increased gastric acid production. This increase in acidity is caused by unchecked gastrin production due to the destruction of somatostatin-secreting cells in the gastric antrum.

Pathology	Gastrointestinal & Nutrition	Peptic ulcer disease
Subject	System	Topic

https://t.me/USMLEWorldStep1

Exhibit Display

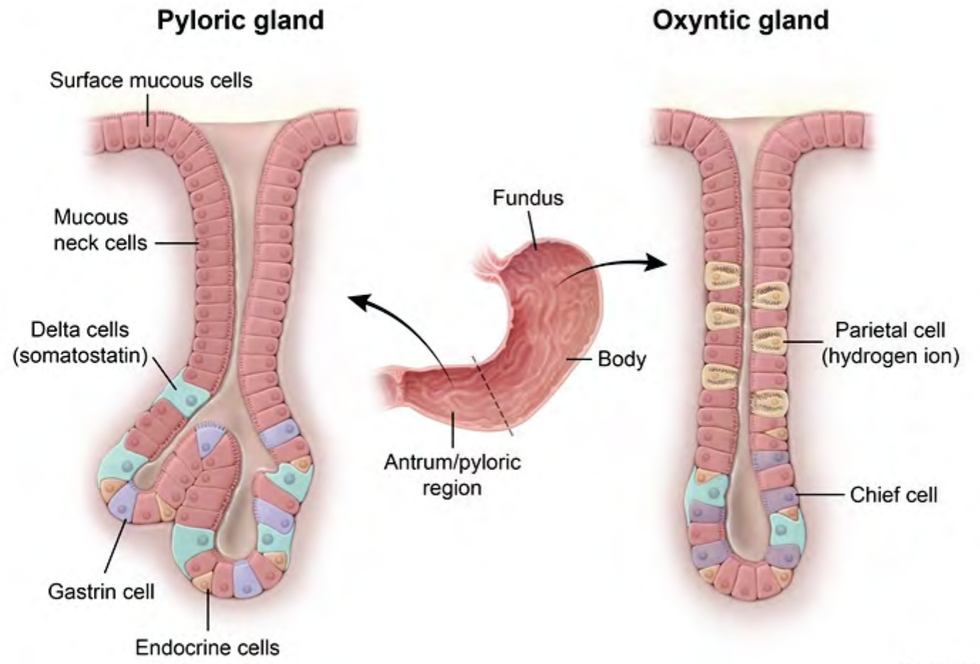

Zoom In | Zoom Out | Reset | New | Existing | My Notebook

Helico
deep i
produc
cells.
against

Chron
produ
G-cells
histam
releas
into th

In con
inflam
which
secret
produc
corpus
adeno

(Choi
alcoho

(Choi
autoar
and achlorhydria. Its etiology is at least partially genetic.

https://t.me/USMLEWorldStep1

Helicobacter pylori is a motile, spiral-shaped, gram-negative bacteria found attached to the gastric mucosa or deep i
produc
cells.
agains

Chron
produ
G-cells
histam
releas
into th

In con
inflam
which
secret
produc
corpus
adeno

(Choi
alcoho

(Choi
autoar
and ac

Educa
Helico
production. This increase in acidity is caused by unchecked gastrin production due to the destruction of somatostatin-secreting cells in the gastric antrum.

Exhibit Display

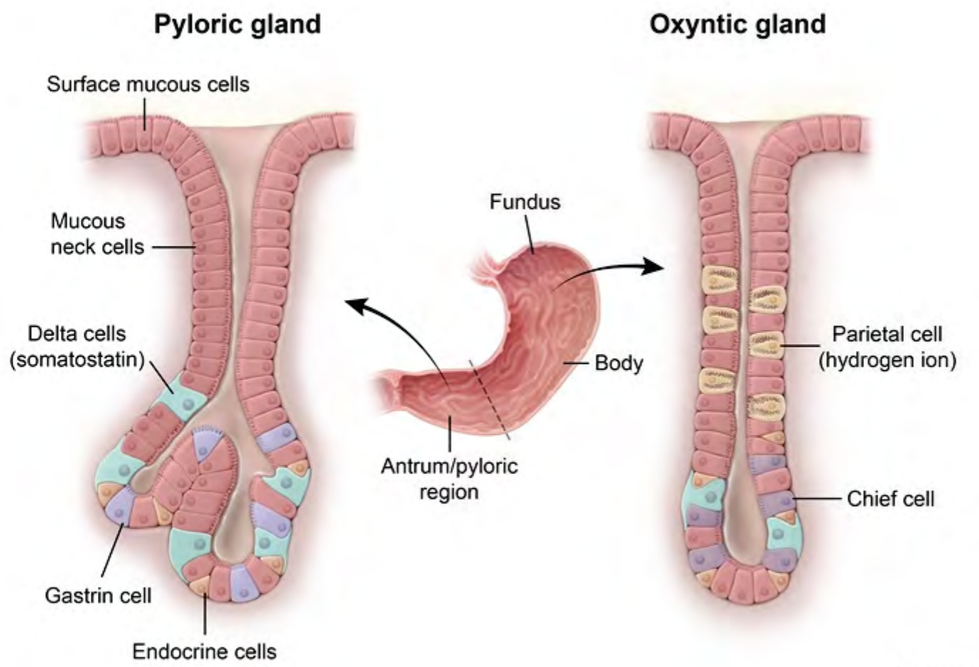

Zoom In | Zoom Out | Reset | New | Existing | My Notebook

https://t.me/USMLEWorldStep1

A 44-year-old woman comes to the clinic after several near collisions over the past month while driving at night. She also has generalized pruritus. The patient has not seen a physician for several years and has missed several scheduled appointments. She takes no medications. On physical examination, she has patchy areas of coarse, thickened skin on the extremities. Which of the following processes is most likely responsible for this patient's findings?

- A. Chronic kidney disease
- B. Inadequate sunlight exposure
- C. Prolonged biliary obstruction
- D. Recurrent microvascular vasoocclusion
- E. Strict vegan diet

Submit

https://t.me/USMLEWorldStep1

A 44-year-old woman comes to the clinic after several near collisions over the past month while driving at night. She also has generalized pruritus. The patient has not seen a physician for several years and has missed several scheduled appointments. She takes no medications. On physical examination, she has patchy areas of coarse, thickened skin on the extremities. Which of the following processes is most likely responsible for this patient's findings?

- ✗ A. Chronic kidney disease (5%)
- B. Inadequate sunlight exposure (3%)
- ✓ C. Prolonged biliary obstruction (57%)
- D. Recurrent microvascular vasoocclusion (12%)
- E. Strict vegan diet (20%)

Incorrect
Correct answer
C

57%
Answered correctly

03 secs
Time Spent

2023
Version

Explanation

Vitamin A		
	Deficiency	**Toxicity**
Causes	• Insufficient dietary intake (resource-limited regions) • Fat malabsorption (eg, pancreatic insufficiency, cholestasis, short bowel syndrome)	• Dietary excess (eg, eggs, liver, kidney) • Medications (eg, retinoids)
		• Benign intracranial hypertension

https://t.me/USMLEWorldStep1

Explanation

Vitamin A		
	Deficiency	**Toxicity**
Causes	• Insufficient dietary intake (resource-limited regions) • Fat malabsorption (eg, pancreatic insufficiency, cholestasis, short bowel syndrome)	• Dietary excess (eg, eggs, liver, kidney) • Medications (eg, retinoids)
Clinical features	• Night blindness • Dry eyes, Bitot spots • Hyperkeratosis • Diminished immune response	• Benign intracranial hypertension • Bone pain, fractures • Hepatomegaly • Dry skin & mucosa; alopecia • Teratogenic

This patient's impaired driving at night and coarse, thickened skin are suggestive of **vitamin A deficiency**. Vitamin A is a lipid-soluble vitamin necessary for vision (phototransduction, retinal and conjunctival development) and keratinocyte differentiation. Deficiency is characterized by **night blindness** and **xerophthalmia** (conjunctival and corneal dryness). In some patients, abnormal conjunctival keratinization may lead to Bitot spots, or foamy white plaques in the eye. Nonspecific dermatologic findings are also common and may include **hyperkeratosis** (thickened skin), as seen here.

Dietary intake of vitamin A comes from a combination of beta-carotene, a provitamin found in plants (eg, green leafy vegetables, carrots), and preformed vitamin A from animal sources (eg, eggs, liver, kidney). In resource-rich regions, most individuals have adequate dietary intake of vitamin A, but patients may develop deficiency due to fat malabsorption related to biliary obstruction, exocrine pancreatic insufficiency (eg, cystic fibrosis), or small-bowel resection (eg, Crohn disease, bariatric surgery).

This patient with generalized **pruritus** and signs of vitamin A deficiency should be evaluated for primary biliary

https://t.me/USMLEWorldStep1

This patient's impaired driving at night and coarse, thickened skin are suggestive of **vitamin A deficiency**. Vitamin A is a lipid-soluble vitamin necessary for vision (phototransduction, retinal and conjunctival development) and keratinocyte differentiation. Deficiency is characterized by **night blindness** and **xerophthalmia** (conjunctival and corneal dryness). In some patients, abnormal conjunctival keratinization may lead to Bitot spots, or foamy white plaques in the eye. Nonspecific dermatologic findings are also common and may include **hyperkeratosis** (thickened skin), as seen here.

Dietary intake of vitamin A comes from a combination of beta-carotene, a provitamin found in plants (eg, green leafy vegetables, carrots), and preformed vitamin A from animal sources (eg, eggs, liver, kidney). In resource-rich regions, most individuals have adequate dietary intake of vitamin A, but patients may develop deficiency due to fat malabsorption related to biliary obstruction, exocrine pancreatic insufficiency (eg, cystic fibrosis), or small-bowel resection (eg, Crohn disease, bariatric surgery).

This patient with generalized **pruritus** and signs of vitamin A deficiency should be evaluated for primary biliary cholangitis (PBC), an autoimmune disease most common in middle-aged women and characterized by destruction of small intrahepatic bile ducts. Because bile acids are important for solubilization and absorption of fats, patients with **chronic biliary obstruction** due to PBC may develop **deficiency of fat-soluble vitamins** (A, D, E, and K). Generalized pruritus is common due to bile acid accumulation in the skin; jaundice is often not apparent until later in the disease course.

(Choices A and B) Inadequate exposure to sunlight can cause vitamin D deficiency in individuals without adequate dietary vitamin D intake. Chronic kidney disease can also result in vitamin D deficiency due to reduced production of 1,25-dihydroxyvitamin D. Vitamin D deficiency is characterized by bone pain and fractures (eg, osteomalacia), not night blindness.

(Choice D) Sickle cell disease is a form of chronic hemolytic anemia that can cause retinopathy due to microvascular vasoocclusion, retinal ischemia, and neovascularization/hemorrhage. However, vision impairment would not be restricted to nighttime, and affected patients would likely have other vasoocclusive symptoms (eg, pain crises).

(Choice E) A strict vegan diet is a risk factor for vitamin B_{12} (cobalamin), not vitamin A, deficiency. Vitamin B_{12} deficiency presents with megaloblastic anemia (eg, fatigue, pallor) and neurologic deficits (eg, tingling, numbness).

https://t.me/USMLEWorldStep1

Dietary intake of vitamin A comes from a combination of beta-carotene, a provitamin found in plants (eg, green leafy vegetables, carrots), and preformed vitamin A from animal sources (eg, eggs, liver, kidney). In resource-rich regions, most individuals have adequate dietary intake of vitamin A, but patients may develop deficiency due to fat malabsorption related to biliary obstruction, exocrine pancreatic insufficiency (eg, cystic fibrosis), or small-bowel resection (eg, Crohn disease, bariatric surgery).

This patient with generalized **pruritus** and signs of vitamin A deficiency should be evaluated for primary biliary cholangitis (PBC), an autoimmune disease most common in middle-aged women and characterized by destruction of small intrahepatic bile ducts. Because bile acids are important for solubilization and absorption of fats, patients with **chronic biliary obstruction** due to PBC may develop **deficiency of fat-soluble vitamins** (A, D, E, and K). Generalized pruritus is common due to bile acid accumulation in the skin; jaundice is often not apparent until later in the disease course.

(Choices A and B) Inadequate exposure to sunlight can cause vitamin D deficiency in individuals without adequate dietary vitamin D intake. Chronic kidney disease can also result in vitamin D deficiency due to reduced production of 1,25-dihydroxyvitamin D. Vitamin D deficiency is characterized by bone pain and fractures (eg, osteomalacia), not night blindness.

(Choice D) Sickle cell disease is a form of chronic hemolytic anemia that can cause retinopathy due to microvascular vasoocclusion, retinal ischemia, and neovascularization/hemorrhage. However, vision impairment would not be restricted to nighttime, and affected patients would likely have other vasoocclusive symptoms (eg, pain crises).

(Choice E) A strict vegan diet is a risk factor for vitamin B_{12} (cobalamin), not vitamin A, deficiency. Vitamin B_{12} deficiency presents with megaloblastic anemia (eg, fatigue, pallor) and neurologic deficits (eg, tingling, numbness).

Educational objective:
Vitamin A deficiency causes night blindness and hyperkeratosis. Deficiency of this lipid-soluble vitamin can develop in patients with fat malabsorption due to chronic biliary obstruction, exocrine pancreatic insufficiency, or small-bowel resection.

References

- Vitamin A deficiency.

https://t.me/USMLEWorldStep1

This patient's impaired driving at night and coarse, thickened skin are suggestive of **vitamin A deficiency**. Vitamin A is a lipid-soluble vitamin necessary for vision (phototransduction, retinal and conjunctival development) and keratin
cornea
plaque
(thicke

Dietary
leafy v
region
malab
resect

This p
cholan
of sma
with **cl**
Gener
in the

(Choi
adequ
produc
osteon

(Choi
microv
would
pain c

(Choic

deficiency presents with megaloblastic anemia (eg, fatigue, pallor) and neurologic deficits (eg, tingling, numbness).

Exhibit Display

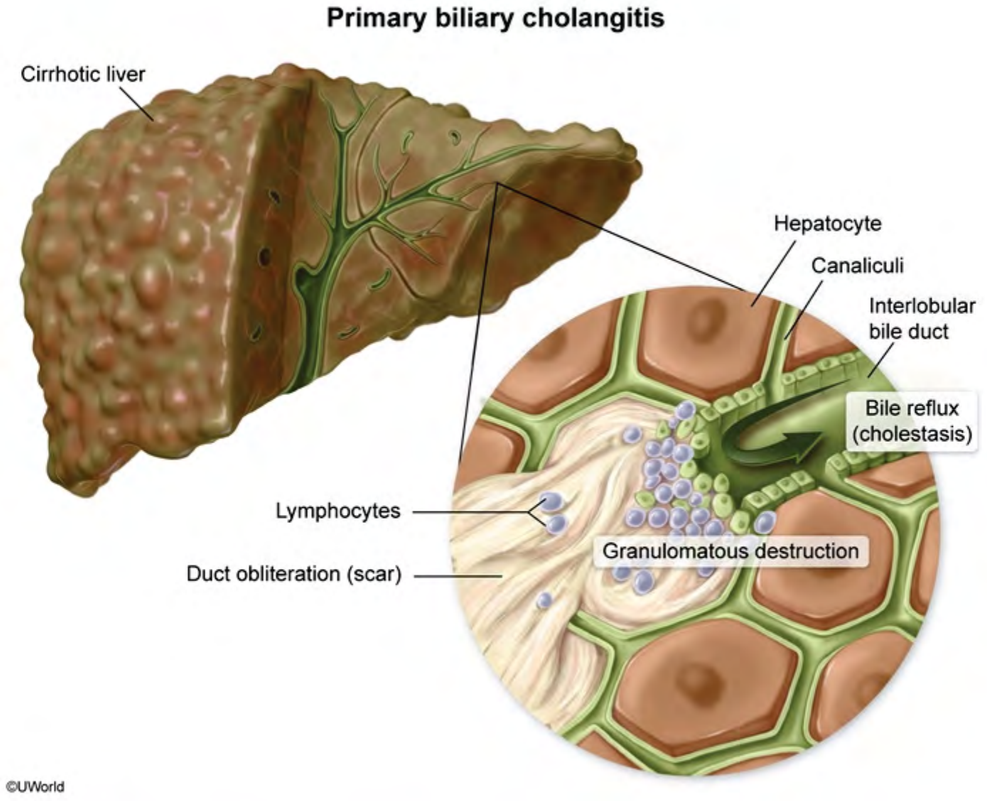

Zoom In | Zoom Out | Reset | New | Existing | My Notebook

https://t.me/USMLEWorldStep1

A 46-year-old man comes to the office due to intermittent, bloody diarrhea and abdominal pain for the past month. The patient has lost 12 lb (5.4 kg) during this period. He was diagnosed with HIV 5 years ago but has been inconsistent with his antiretroviral medications. Current CD4 count is 50/mm^3 and plasma HIV viral load is 650,000 copies/mL. Colonoscopy reveals multiple hemorrhagic, polypoidal lesions. Biopsy of these lesions reveals a proliferation of spindle-shaped cells and small blood vessels. Which of the following is the most likely cause of this patient's diarrhea?

- A. Adenocarcinoma
- B. *Cryptosporidium parvum*
- C. Cytomegalovirus
- D. *Entamoeba histolytica*
- E. Kaposi sarcoma
- F. Ulcerative colitis

Submit

https://t.me/USMLEWorldStep1

A 46-year-old man comes to the office due to intermittent, bloody diarrhea and abdominal pain for the past month. The patient has lost 12 lb (5.4 kg) during this period. He was diagnosed with HIV 5 years ago but has been inconsistent with his antiretroviral medications. Current CD4 count is 50/mm^3 and plasma HIV viral load is 650,000 copies/mL. Colonoscopy reveals multiple hemorrhagic, polypoidal lesions. Biopsy of these lesions reveals a proliferation of spindle-shaped cells and small blood vessels. Which of the following is the most likely cause of this patient's diarrhea?

- A. Adenocarcinoma (8%)
- B. *Cryptosporidium parvum* (16%)
- ✗ C. Cytomegalovirus (13%)
- D. *Entamoeba histolytica* (9%)
- ✓ E. Kaposi sarcoma (48%)
- F. Ulcerative colitis (3%)

Incorrect
Correct answer
E

48%
Answered correctly

03 secs
Time Spent

2023
Version

Explanation

Kaposi sarcoma	
Etiology	• Endothelial tumor caused by human herpesvirus type 8 • Most common malignancy in patients with untreated HIV • Endemic in certain African & Mediterranean

https://t.me/USMLEWorldStep1

Kaposi sarcoma	
Etiology	• Endothelial tumor caused by human herpesvirus type 8 • Most common malignancy in patients with untreated HIV • Endemic in certain African & Mediterranean regions
Manifestations	• Cutaneous lesions: ◦ Violaceous, red, or brown flat lesions → papules ◦ Most common along skin folds ◦ Pruritus, pain & friability are rare ◦ Lymphedema distal to lesions • Visceral lesions: ◦ Lungs & gastrointestinal tract most common ◦ May cause life-threatening bleeding
Histopathology	• Proliferation of spindle-shaped endothelial cells • Slit-like vascular spaces • Extravasated red blood cells

This patient with advanced HIV and diarrhea has endoscopic and histopathologic findings consistent with **Kaposi sarcoma** (KS). KS, a vascular neoplasm that often presents in **HIV-positive** individuals, is caused by ***human herpesvirus 8*** (HHV-8).

Skin involvement is characteristic (eg, purple papules on the lower extremities), but visceral involvement (eg, **gastrointestinal tract**, oral cavity, lung) may also occur, particularly in patients with advanced HIV. Gastrointestinal KS is usually asymptomatic, but some patients may experience bloody diarrhea, weight loss, and/or abdominal pain.

https://t.me/USMLEWorldStep1

	• Extravasated red blood cells

This patient with advanced HIV and diarrhea has endoscopic and histopathologic findings consistent with **Kaposi sarcoma** (KS). KS, a vascular neoplasm that often presents in **HIV-positive** individuals, is caused by ***human herpesvirus 8*** (HHV-8).

Skin involvement is characteristic (eg, purple papules on the lower extremities), but visceral involvement (eg, **gastrointestinal tract**, oral cavity, lung) may also occur, particularly in patients with advanced HIV. Gastrointestinal KS is usually asymptomatic, but some patients may experience bloody diarrhea, weight loss, and/or abdominal pain.

KS can often be distinguished endoscopically from infectious causes of diarrhea. It usually appears as red-violet maculopapular lesions, raised **hemorrhagic nodules**, or polypoid masses. Histopathology typically shows a proliferation of **spindle-shaped endothelial cells** with irregular, **slit-like vascular spaces** and extravasated red blood cells.

(Choice A) Colonic adenocarcinoma may appear polypoid endoscopically, but histopathology typically shows dysplastic epithelial cells with variable gland formation and/or mucin production, depending on the differentiation of the tumor.

(Choice B) Cryptosporidiosis can cause profuse, watery, nonbloody diarrhea, particularly in patients with AIDS. Endoscopy shows inflammation without ulcers, and microscopy shows basophilic organisms on the surface of intestinal epithelial cells.

(Choice C) Although cytomegalovirus colitis may present with diarrhea and abdominal pain, colonoscopy usually shows multiple ulcers and mucosal erosions. Histopathology shows characteristic cytomegalic cells with inclusion bodies.

(Choice D) *Entamoeba histolytica* can cause bloody diarrhea and abdominal pain. However, colonoscopy shows flask-shaped ulcers, and histopathology often shows trophozoites.

(Choice F) Although ulcerative colitis may present with bloody diarrhea and abdominal pain, colonoscopy typically shows erythematous, friable, granular mucosa and possibly pseudopolyps (isolated areas of regenerative mucosa). Histopathology often shows an inflammatory infiltrate involving the mucosa and submucosa with crypt

https://t.me/USMLEWorldStep1

maculopapular lesions, raised **hemorrhagic nodules**, or polypoid masses. Histopathology typically shows a proliferation of **spindle-shaped endothelial cells** with irregular, **slit-like vascular spaces** and extravasated red blood cells.

(Choice A) Colonic adenocarcinoma may appear polypoid endoscopically, but histopathology typically shows dysplastic epithelial cells with variable gland formation and/or mucin production, depending on the differentiation of the tumor.

(Choice B) Cryptosporidiosis can cause profuse, watery, nonbloody diarrhea, particularly in patients with AIDS. Endoscopy shows inflammation without ulcers, and microscopy shows basophilic organisms on the surface of intestinal epithelial cells.

(Choice C) Although cytomegalovirus colitis may present with diarrhea and abdominal pain, colonoscopy usually shows multiple ulcers and mucosal erosions. Histopathology shows characteristic cytomegalic cells with inclusion bodies.

(Choice D) *Entamoeba histolytica* can cause bloody diarrhea and abdominal pain. However, colonoscopy shows flask-shaped ulcers, and histopathology often shows trophozoites.

(Choice F) Although ulcerative colitis may present with bloody diarrhea and abdominal pain, colonoscopy typically shows erythematous, friable, granular mucosa and possibly pseudopolyps (isolated areas of regenerative mucosa). Histopathology often shows an inflammatory infiltrate involving the mucosa and submucosa with crypt abscesses.

Educational objective:
Kaposi sarcoma, a vascular neoplasm that often presents in HIV-positive individuals, may involve the gastrointestinal tract, causing bloody diarrhea, weight loss, and abdominal pain. Endoscopy characteristically reveals red-violet maculopapular lesions, raised hemorrhagic nodules, or polypoid masses. Histopathology often shows spindle-shaped endothelial cells, slit-like vascular spaces, and extravasated red blood cells.

Pathology	Gastrointestinal & Nutrition	Kaposi sarcoma
Subject	System	Topic

Copyright © UWorld. All rights reserved.

https://t.me/USMLEWorldStep1

	• Extravasated red blood cells

This p
sarco
herpe

Skin i
gastro
Gastro
and/or

KS ca
macul
prolife
blood

(Choi
dyspla
the tur

(Choi
Endos
intesti

(Choi
shows
bodies

(Choi
flask-s

(Choi
shows erythematous, friable, granular mucosa and possibly pseudopolyps (isolated areas of regenerative mucosa). Histopathology often shows an inflammatory infiltrate involving the mucosa and submucosa with crypt

Exhibit Display

Kaposi sarcoma

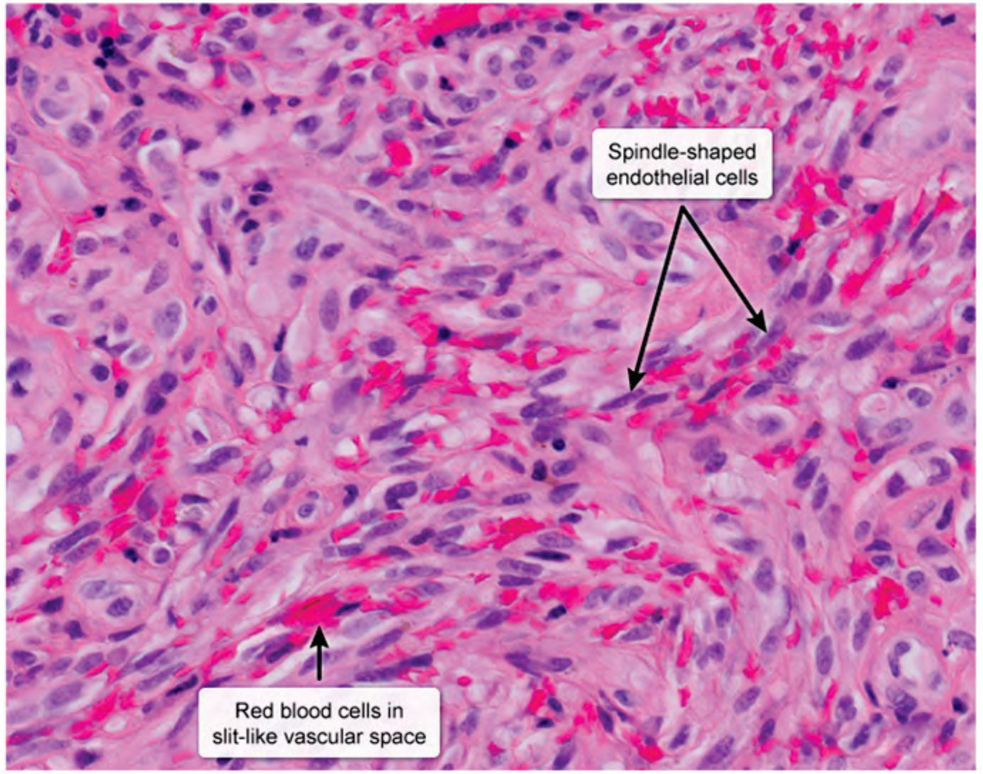

©UWorld

Zoom In | Zoom Out | Reset | New | Existing | My Notebook

https://t.me/USMLEWorldStep1

- Extravasated red blood cells

This p
sarco
herpe

Skin i
gastro
Gastro
and/or

KS ca
macul
prolife
blood

(Choi
dyspla
the tur

(Choi
Endos
intesti

(Choi
shows
bodies

(Choi
flask-s

(Choi
shows erythematous, friable, granular mucosa and possibly pseudopolyps (isolated areas of regenerative mucosa). Histopathology often shows an inflammatory infiltrate involving the mucosa and submucosa with crypt

Exhibit Display

Colonic adenocarcinoma

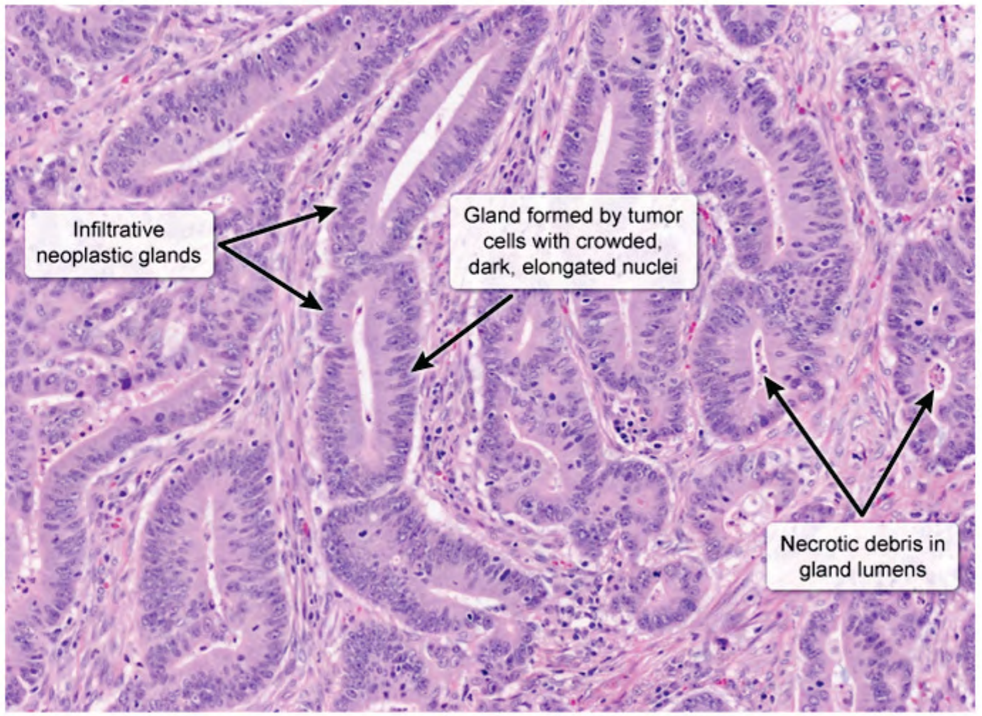

©UWorld

Zoom In | Zoom Out | Reset | New | Existing | My Notebook

https://t.me/USMLEWorldStep1

- Extravasated red blood cells

This p
sarco
herpe

Skin i
gastro
Gastro
and/or

KS ca
macul
prolife
blood

(Choi
dyspla
the tur

(Choi
Endos
intesti

(Choi
shows
bodies

(Choi
flask-s

(Choi
shows erythematous, friable, granular mucosa and possibly pseudopolyps (isolated areas of regenerative mucosa). Histopathology often shows an inflammatory infiltrate involving the mucosa and submucosa with crypt

Exhibit Display

Cryptosporidiosis

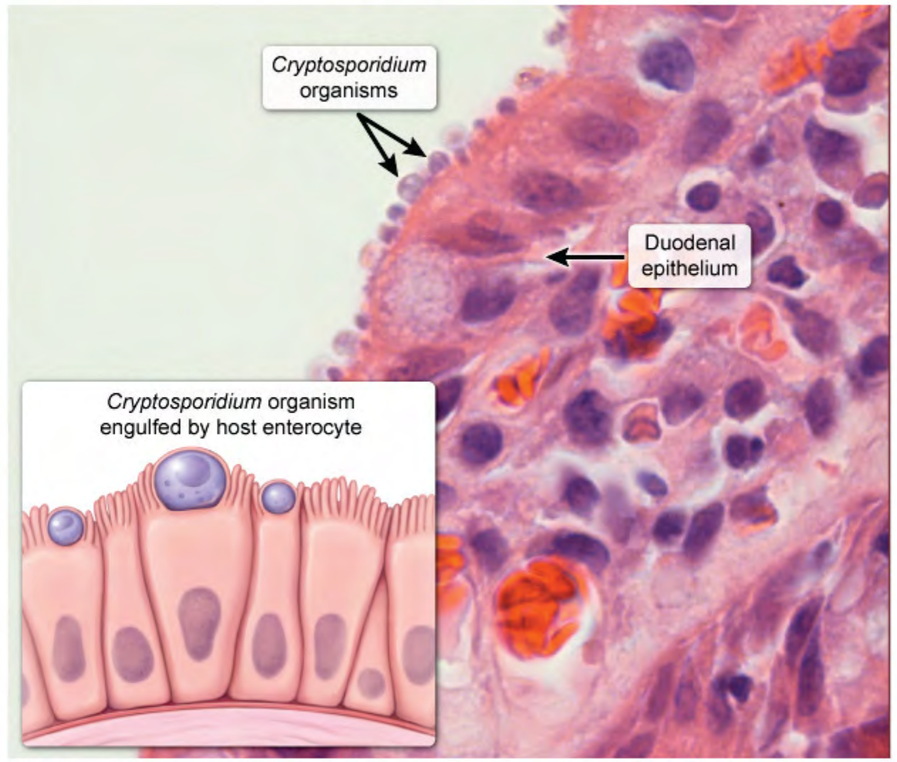

©UWorld

Zoom In | Zoom Out | Reset | New | Existing | My Notebook

https://t.me/USMLEWorldStep1

herpesvirus 8 (HHV-8).

Skin i
gastro
Gastro
and/or

KS ca
macul
prolife
blood

(Choi
dyspla
the tur

(Choi
Endos
intesti

(Choi
shows
bodies

(Choi
flask-s

(Choi
shows
mucos
absce

Educational objective:
Kaposi sarcoma, a vascular neoplasm that often presents in HIV-positive individuals, may involve the

Exhibit Display

Cytomegalovirus

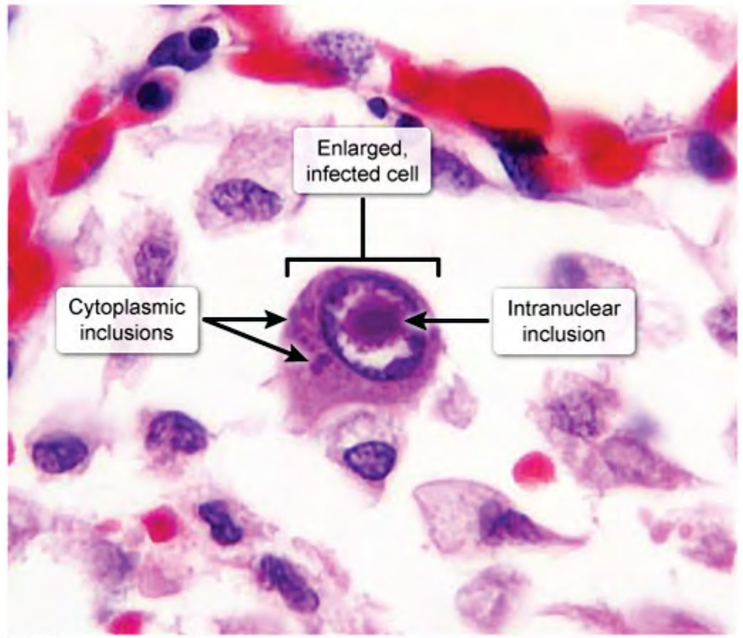

©UWorld

Zoom In Zoom Out Reset New | Existing My Notebook

https://t.me/USMLEWorldStep1

Gastrointestinal KS is usually asymptomatic, but some patients may experience bloody diarrhea, weight loss, and/or

KS ca
macul
prolife
blood

(Choi
dyspla
the tur

(Choi
Endos
intesti

(Choi
shows
bodies

(Choi
flask-s

(Choi
shows
mucos
absce

Educa
Kapos
gastrointestinal tract, causing bloody diarrhea, weight loss, and abdominal pain. Endoscopy characteristically reveals red-violet maculopapular lesions, raised hemorrhagic nodules, or polypoid masses. Histopathology often shows spindle-shaped endothelial cells, slit-like vascular spaces, and extravasated red blood cells.

Exhibit Display

Amebiasis

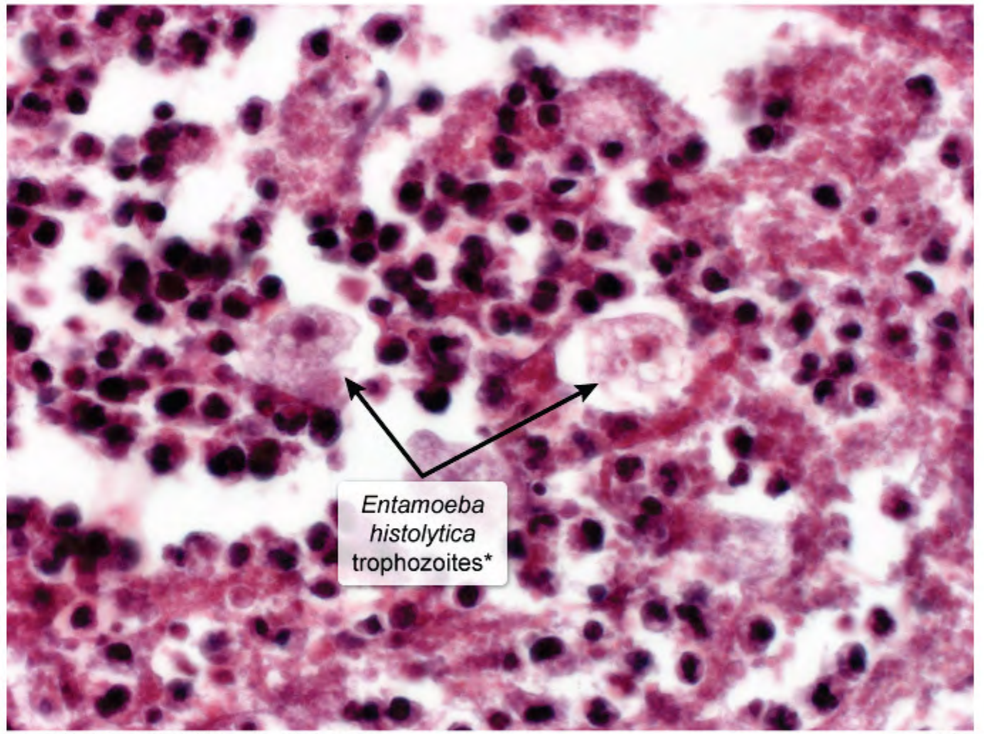

*Vacuolated cytoplasm with ingested erythrocytes.

©UWorld

Zoom In | Zoom Out | Reset | New | Existing | My Notebook

https://t.me/USMLEWorldStep1

Gastrointestinal KS is usually asymptomatic, but some patients may experience bloody diarrhea, weight loss, and/or

KS ca
macul
prolife
blood

(Choi
dyspla
the tur

(Choi
Endos
intesti

(Choi
shows
bodies

(Choi
flask-s

(Choi
shows
mucos
absce

Educa
Kapos
gastro
reveal
shows spindle-shaped endothelial cells, slit-like vascular spaces, and extravasated red blood cells.

Exhibit Display

Ulcerative colitis

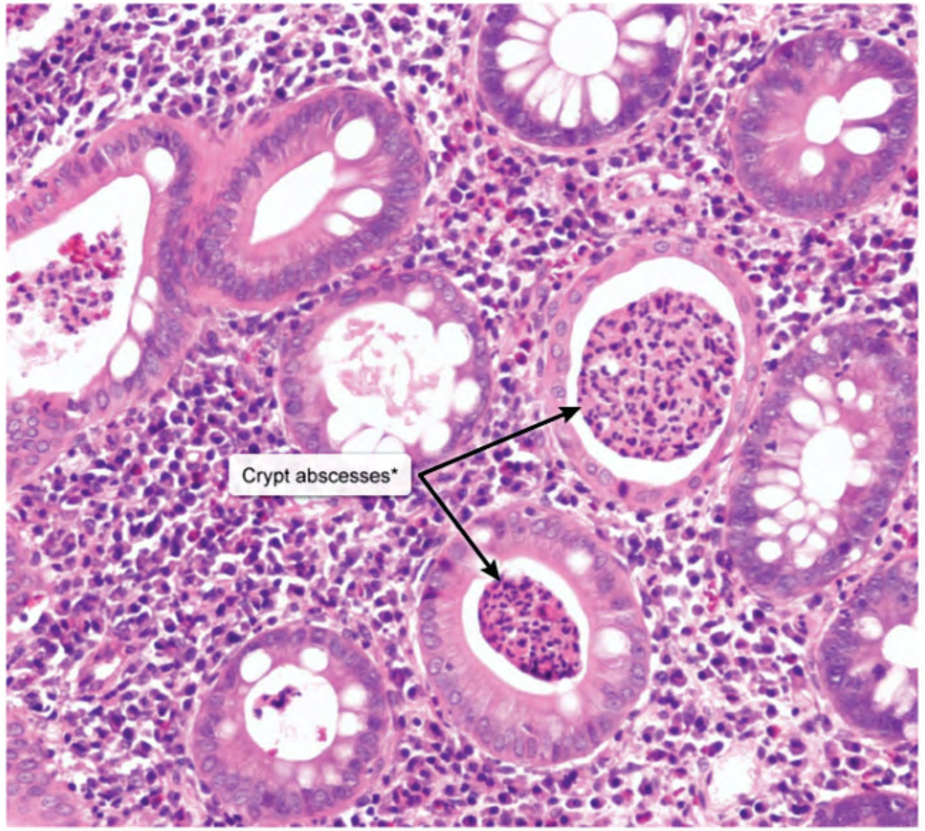

*Collection of neutrophils in crypt lumen.

©UWorld

Zoom In Zoom Out Reset New | Existing My Notebook

https://t.me/USMLEWorldStep1

A 34-year-old woman comes to the physician with abdominal pain and melena. She also complains of progressive fatigue and a 5 kg (11 lb) weight loss over the last 2 months. She has a strong family history of colon, endometrial, and ovarian cancer. Colonoscopy shows a protuberant, friable mass in the ascending colon, and biopsy is diagnostic for colon adenocarcinoma. Genetic analysis confirms a mutation consistent with Lynch syndrome (hereditary nonpolyposis colon cancer). Which of the following is most likely responsible for the development of colon cancer in this patient?

- A. Nucleotide mismatches that escape repair
- B. Covalent bonds between adjacent pyrimidines
- C. Insertion of abnormal bases (eg, uracil) into DNA
- D. Empty sugar-phosphate residues in the DNA molecule
- E. Double-strand breaks in DNA

Submit

https://t.me/USMLEWorldStep1

A 34-year-old woman comes to the physician with abdominal pain and melena. She also complains of progressive fatigue and a 5 kg (11 lb) weight loss over the last 2 months. She has a strong family history of colon, endometrial, and ovarian cancer. Colonoscopy shows a protuberant, friable mass in the ascending colon, and biopsy is diagnostic for colon adenocarcinoma. Genetic analysis confirms a mutation consistent with Lynch syndrome (hereditary nonpolyposis colon cancer). Which of the following is most likely responsible for the development of colon cancer in this patient?

- ✓ A. Nucleotide mismatches that escape repair (89%)
- B. Covalent bonds between adjacent pyrimidines (1%)
- C. Insertion of abnormal bases (eg, uracil) into DNA (3%)
- D. Empty sugar-phosphate residues in the DNA molecule (0%)
- E. Double-strand breaks in DNA (5%)

Correct

89% Answered correctly

03 secs Time Spent

2023 Version

Explanation

Lynch syndrome (hereditary nonpolyposis colon cancer) is an autosomal dominant disease caused by defective DNA mismatch repair. DNA replication occurs with a high degree of fidelity because mismatched nucleotides are repaired through the proofreading activity of DNA polymerases delta and epsilon. However, this proofreading functionality is not infallible; base substitutions and small insertion-deletion mismatches occur due to errors in base pairing every 10^9 bases on average. It is the function of the DNA mismatch repair system to fix these errors shortly after the daughter strands are synthesized. The mismatch repair system involves several genes, including MSH2 and MLH1, which code for components of the human MutS and MutL homologs. Mutations in these 2 genes account for around 90% of cases of Lynch syndrome.

https://t.me/USMLEWorldStep1

Lynch syndrome (hereditary nonpolyposis colon cancer) is an autosomal dominant disease caused by defective DNA mismatch repair. DNA replication occurs with a high degree of fidelity because mismatched nucleotides are repaired through the proofreading activity of DNA polymerases delta and epsilon. However, this proofreading functionality is not infallible; base substitutions and small insertion-deletion mismatches occur due to errors in base pairing every 10^6 bases on average. It is the function of the DNA mismatch repair system to fix these errors shortly after the daughter strands are synthesized. The mismatch repair system involves several genes, including MSH2 and MLH1, which code for components of the human MutS and MutL homologs. Mutations in these 2 genes account for around 90% of cases of Lynch syndrome.

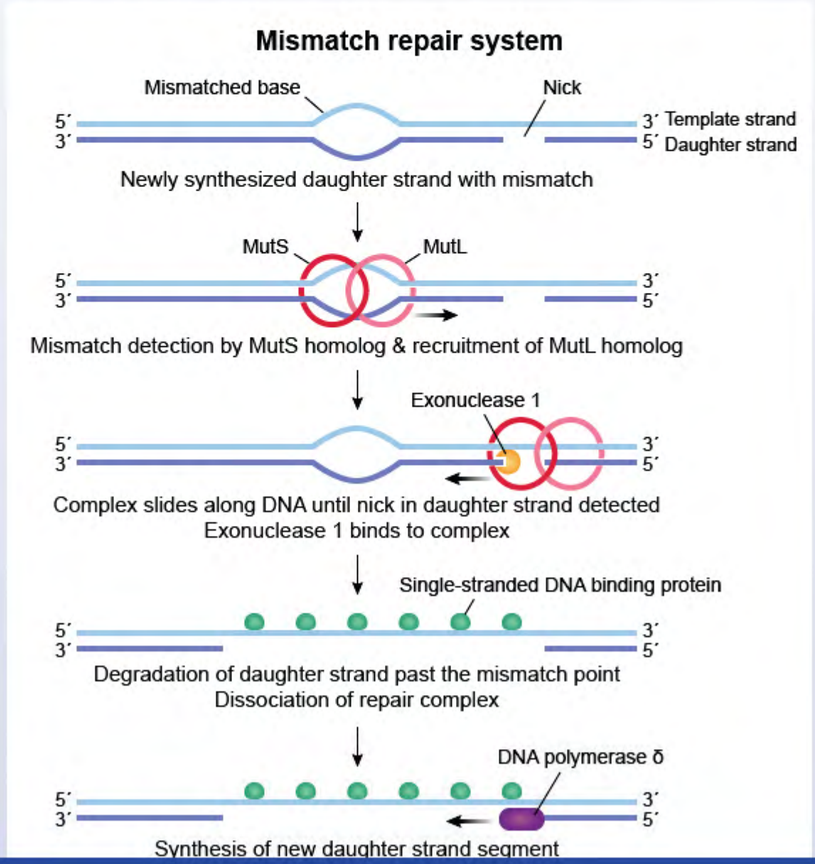

https://t.me/USMLEWorldStep1

Lynch syndrome (hereditary nonpolyposis colon cancer) is an autosomal dominant disease caused by defective DNA
repair
functio
pairing
after th
and M
accou

Exhibit Display

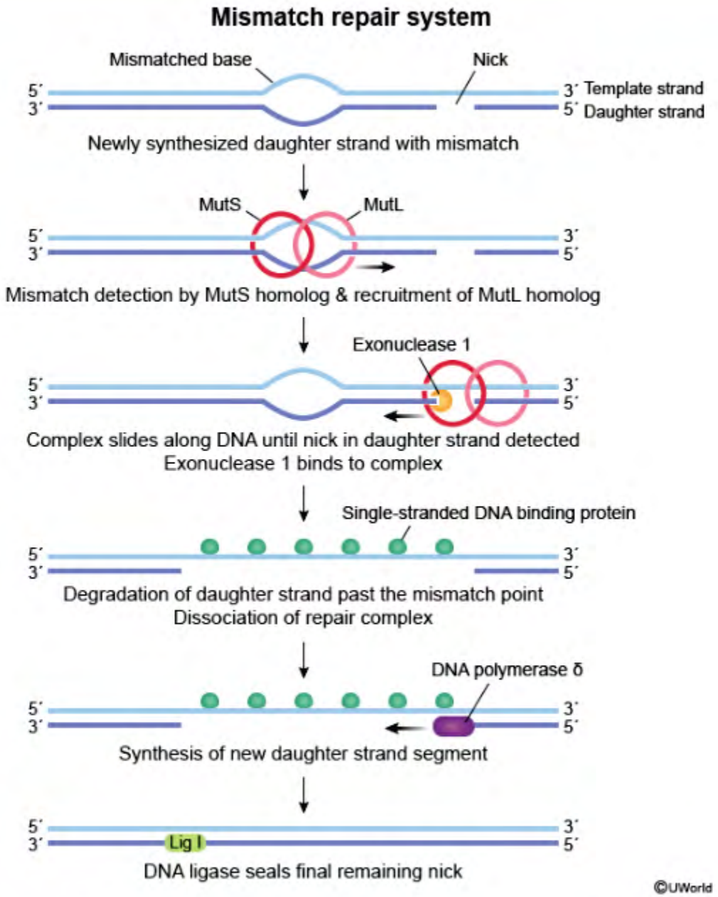

Zoom In | Zoom Out | Reset | New | Existing | My Notebook

Synthesis of new daughter strand segment

https://t.me/USMLEWorldStep1

DNA ligase seals final remaining nick

©UWorld

Mismatch repair begins with MutS homolog detecting a mismatch on the newly created daughter strand, which is distinguished from the parent strand by occasional nicks in the phosphodiester bonds. MutL homolog is then recruited, and the resulting complex slides along the DNA molecule until 1 of the daughter strand nicks is encountered. At this point, exonuclease 1 is loaded onto and activated by the repair complex. The daughter strand is then degraded backward past the initial mismatch point, leaving a variable gap of single-stranded DNA that is stabilized by ssDNA-binding protein. The complex then dissociates while DNA polymerase delta loads at the 3' end of the discontinuity and begins synthesizing a new daughter strand segment. Finally, DNA ligase I seals the remaining nick to complete the repair process.

(Choice B) Exposure to ultraviolet light can cause pyrimidine (usually thymine) dimers to form due to covalent joining of adjacent pyrimidines. Pyrimidine dimers interfere with DNA replication and are removed by nucleotide excision repair.

(Choices C and D) Several types of insults can alter the DNA bases. For example, nitrous acid can deaminate C, A, and G. There are also spontaneous changes, such as deamination of C to U and the constant low-level loss of purines via thermal disruption. Glycosylases are enzymes that detect and remove abnormal bases from DNA, creating an empty sugar-phosphate residue that is subsequently removed and replaced by the correct nucleotide (base excision repair).

(Choice E) Exposure to ionizing radiation causes double-stranded DNA breaks that are repaired by end-joining repair mechanisms. Non-homologous end joining, the main mechanism in primates, is more prone to cause mutations than homologous recombination.

Educational objective:
Lynch syndrome is an autosomal dominant disease caused by abnormal nucleotide mismatch repair. The mismatch repair system involves several genes, including MSH2 and MLH1, which code for components of the human MutS and MutL homologs. Mutations in these 2 genes account for around 90% of cases of Lynch syndrome.

https://t.me/USMLEWorldStep1

A 46-year-old HIV-positive man is hospitalized with fever, cramping abdominal pain, and watery diarrhea. Evaluation shows high fever, hypotension, tachycardia, and lower abdominal distension and tenderness. Abdominal x-ray reveals free intraperitoneal air, and the patient is taken for urgent exploratory laparotomy. Operative findings include an erythematous and dilated colon. A focus of bowel wall necrosis with perforation is resected. Histopathologic analysis reveals acute inflammatory changes, epithelial necrosis, and a layer of denuded epithelium, fibrin, and inflammatory cells overlaying the mucosa. Which of the following pathogens is most likely responsible for this patient's current condition?

- A. *Campylobacter jejuni*
- B. *Clostridioides difficile*
- C. *Salmonella typhi*
- D. *Shigella flexneri*
- E. *Vibrio cholerae*

Submit

https://t.me/USMLEWorldStep1

A 46-year-old HIV-positive man is hospitalized with fever, cramping abdominal pain, and watery diarrhea. Evaluation shows high fever, hypotension, tachycardia, and lower abdominal distension and tenderness. Abdominal x-ray reveals free intraperitoneal air, and the patient is taken for urgent exploratory laparotomy. Operative findings include an erythematous and dilated colon. A focus of bowel wall necrosis with perforation is resected. Histopathologic analysis reveals acute inflammatory changes, epithelial necrosis, and a layer of denuded epithelium, fibrin, and inflammatory cells overlaying the mucosa. Which of the following pathogens is most likely responsible for this patient's current condition?

- ✗ A. *Campylobacter jejuni* (9%)
- ✓ B. *Clostridioides difficile* (64%)
- C. *Salmonella typhi* (10%)
- D. *Shigella flexneri* (9%)
- E. *Vibrio cholerae* (6%)

Incorrect
Correct answer
B

64%
Answered correctly

04 secs
Time Spent

2023
Version

Explanation

This patient with diarrhea, abdominal pain, and fever developed a colonic perforation. Given his histologic findings consistent with pseudomembrane formation, this presentation is highly suggestive of ***Clostridioides difficile* infection** (CDI) (formerly *Clostridium* genus). *C difficile* is an anaerobic, spore-forming, toxigenic, gram-positive rod that causes infectious colitis. The most significant risk factor for the development of CDI is antibiotic use. Antibiotics (particularly clindamycin, fluoroquinolones, and cephalosporins) alter the normal bowel flora, thereby predisposing to *C difficile* overgrowth. Other risk factors include hospitalization, older age, and proton pump inhibitor use.

https://t.me/USMLEWorldStep1

This patient with diarrhea, abdominal pain, and fever developed a colonic perforation. Given his histologic findings consistent with pseudomembrane formation, this presentation is highly suggestive of ***Clostridioides difficile* infection** (CDI) (formerly *Clostridium* genus). *C difficile* is an anaerobic, spore-forming, toxigenic, gram-positive rod that causes infectious colitis. The most significant risk factor for the development of CDI is antibiotic use. Antibiotics (particularly clindamycin, fluoroquinolones, and cephalosporins) alter the normal bowel flora, thereby predisposing to *C difficile* overgrowth. Other risk factors include hospitalization, older age, and proton pump inhibitor use.

C difficile produces 2 toxins: Toxin A (enterotoxin) and Toxin B (cytotoxin). These toxins disrupt cellular cytoskeletons and intercellular tight junctions, leading to colonocyte apoptosis. The colonic mucosa responds to toxin exposure by forming yellow-white, patchy pseudomembranes, which consist of a **neutrophil-predominant** inflammatory infiltrate, **fibrin**, bacteria, and necrotic epithelium. Patients with severe disease may develop a nonobstructive colonic dilation known as **toxic megacolon**, which leads to increased risk of colonic perforation (as seen in this patient).

(Choice A) *Campylobacter jejuni* is associated with watery diarrhea that may become bloody, abdominal cramping, and fever. Neutrophilic infiltrate and crypt abscesses are identified on histology.

(Choice C) *Salmonella typhi* causes typhoid fever, which manifests with diarrhea, abdominal pain, high fever, and salmon-colored macules located mainly on the trunk. Histology demonstrates histiocytes, a lymphoplasmacytic inflammatory infiltrate, and associated hemorrhage.

(Choice D) *Shigella flexneri* infection is characterized by sudden onset of severe abdominal cramping, bloody diarrhea, vomiting, and high fever. Cryptitis, ulcerations, and crypt abscesses are identified on histology.

(Choice E) *Vibrio cholerae* causes cholera, which manifests with sudden onset, voluminous, "rice water" diarrhea and vomiting. Histology typically remains normal.

Educational objective:
Clostridioides (formerly *Clostridium*) *difficile* infection is associated with yellow-white, patchy pseudomembranes on the bowel mucosa. These pseudomembranes consist of a neutrophil-predominant inflammatory infiltrate, fibrin, bacteria, and necrotic epithelium. Patients may develop a nonobstructive colonic dilation known as toxic

https://t.me/USMLEWorldStep1

***difficile* infection** (CDI) (formerly *Clostridium* genus). *C difficile* is an anaerobic, spore-forming, toxigenic, gram-positive rod that causes infectious colitis. The most significant risk factor for the development of CDI is antibiotic use. Antibiotics (particularly clindamycin, fluoroquinolones, and cephalosporins) alter the normal bowel flora, thereby predisposing to *C difficile* overgrowth. Other risk factors include hospitalization, older age, and proton pump inhibitor use.

C difficile produces 2 toxins: Toxin A (enterotoxin) and Toxin B (cytotoxin). These toxins disrupt cellular cytoskeletons and intercellular tight junctions, leading to colonocyte apoptosis. The colonic mucosa responds to toxin exposure by forming yellow-white, patchy pseudomembranes, which consist of a **neutrophil-predominant** inflammatory infiltrate, **fibrin**, bacteria, and necrotic epithelium. Patients with severe disease may develop a nonobstructive colonic dilation known as **toxic megacolon**, which leads to increased risk of colonic perforation (as seen in this patient).

(Choice A) *Campylobacter jejuni* is associated with watery diarrhea that may become bloody, abdominal cramping, and fever. Neutrophilic infiltrate and crypt abscesses are identified on histology.

(Choice C) *Salmonella typhi* causes typhoid fever, which manifests with diarrhea, abdominal pain, high fever, and salmon-colored macules located mainly on the trunk. Histology demonstrates histiocytes, a lymphoplasmacytic inflammatory infiltrate, and associated hemorrhage.

(Choice D) *Shigella flexneri* infection is characterized by sudden onset of severe abdominal cramping, bloody diarrhea, vomiting, and high fever. Cryptitis, ulcerations, and crypt abscesses are identified on histology.

(Choice E) *Vibrio cholerae* causes cholera, which manifests with sudden onset, voluminous, "rice water" diarrhea and vomiting. Histology typically remains normal.

Educational objective:
Clostridioides (formerly *Clostridium*) *difficile* infection is associated with yellow-white, patchy pseudomembranes on the bowel mucosa. These pseudomembranes consist of a neutrophil-predominant inflammatory infiltrate, fibrin, bacteria, and necrotic epithelium. Patients may develop a nonobstructive colonic dilation known as toxic megacolon, which can lead to colonic perforation.

Microbiology Gastrointestinal & Nutrition Clostridioides difficile infection

https://t.me/USMLEWorldStep1

Correct answer
B

Answered correctly
Time Spent
Version

Exhibit Display

Pseudomembranous colitis

*Fibrin, neutrophils, and necrotic epithelium associated with *Clostridioides* (formerly *Clostridium*) *difficile*

©UWorld

Zoom In | Zoom Out | Reset | New | Existing | My Notebook

Expl

This p
consis
diffici
positiv
use. A
thereb
pump

C diffi
cytosk
toxin e
inflam
nonob
seen i

(Choi
cramp

(Choi
salmo
inflam

(Choi
diarrh

(Choi
and vomiting. Histology typically remains normal.

https://t.me/USMLEWorldStep1

Correct answer
B

Answered correctly
Time Spent
Version

Exhibit Display

Pseudomembranous colitis

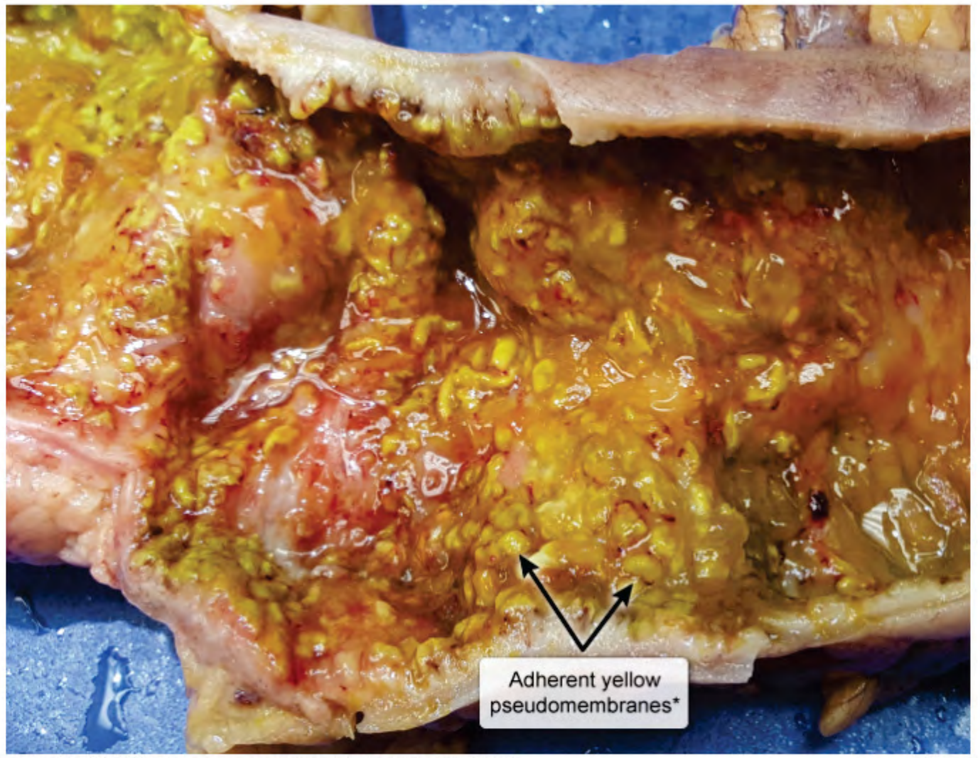

*Fibrin and inflammatory debris associated with *Clostridioides difficile*.

©UWorld

Zoom In | Zoom Out | Reset | New | Existing | My Notebook

This p
consis
diffici
positiv
use. A
thereb
pump

C diffi
cytosk
toxin e
inflam
nonob
seen i

(Choi
cramp

(Choi
salmo
inflam

(Choi
diarrhe

(Choice E) *Vibrio cholerae* causes cholera, which manifests with sudden onset, voluminous, "rice water" diarrhea and vomiting. Histology typically remains normal.

https://t.me/USMLEWorldStep1

A 60-year-old woman comes to the clinic for evaluation of fatigue and weakness. A few months ago, she began feeling more tired than usual during the day. The patient has also developed mild, intermittent abdominal discomfort. Over the last few weeks, she has fallen down several times. The patient has no known medical conditions and takes no medications. Vital signs are normal. Examination shows an ataxic gait. The patient has hyporeflexia in the bilateral lower extremities, and there is loss of vibratory sensation. Laboratory evaluation reveals anemia with evidence of hemolysis. Peripheral smear reveals normocytic erythrocytes with normal segmentation of neutrophils. Additional work-up confirms a micronutrient deficiency. However, the patient says she consumes a well-balanced diet, and she has no dietary restrictions. Which of the following is the most likely cause of this patient's nutritional deficiency?

- A. Decreased pancreatic amylase production
- B. Excessive liver hepcidin production
- C. Impaired hepatic bile acid secretion
- D. Increased production of gastric intrinsic factor
- E. Reduced renal hydroxylation

Submit

https://t.me/USMLEWorldStep1

A 60-year-old woman comes to the clinic for evaluation of fatigue and weakness. A few months ago, she began feeling more tired than usual during the day. The patient has also developed mild, intermittent abdominal discomfort. Over the last few weeks, she has fallen down several times. The patient has no known medical conditions and takes no medications. Vital signs are normal. Examination shows an ataxic gait. The patient has hyporeflexia in the bilateral lower extremities, and there is loss of vibratory sensation. Laboratory evaluation reveals anemia with evidence of hemolysis. Peripheral smear reveals normocytic erythrocytes with normal segmentation of neutrophils. Additional work-up confirms a micronutrient deficiency. However, the patient says she consumes a well-balanced diet, and she has no dietary restrictions. Which of the following is the most likely cause of this patient's nutritional deficiency?

- ✗ A. Decreased pancreatic amylase production (20%)
- B. Excessive liver hepcidin production (18%)
- ✓ C. Impaired hepatic bile acid secretion (42%)
- D. Increased production of gastric intrinsic factor (12%)
- E. Reduced renal hydroxylation (6%)

Incorrect
Correct answer
C

42%
Answered correctly

04 secs
Time Spent

2023
Version

Explanation

Vitamin E deficiency	
Etiology	• Fat malabsorption: cystic fibrosis, pancreatitis, cholestasis • Genetic: abetalipoproteinemia
	• Neuromuscular*

https://t.me/USMLEWorldStep1

Vitamin E deficiency	
Etiology	• Fat malabsorption: cystic fibrosis, pancreatitis, cholestasis • Genetic: abetalipoproteinemia

Clinical features	• Neuromuscular*
	  ◦ Spinocerebellar tract: ataxia
	  ◦ Dorsal columns: loss of vibration & proprioception
	  ◦ Peripheral nerves: decreased strength & sensation, hyporeflexia
	  ◦ Muscles: myopathic weakness
	• Hematologic: hemolytic anemia

Treatment	• High-dose vitamin E replacement
*Neurologic findings mimic Friedreich ataxia.	

This patient with a micronutrient deficiency has hemolytic anemia and neurologic deficits, findings consistent with **vitamin E deficiency**. Vitamin E is a **fat-soluble** vitamin responsible for preventing oxidative damage. The cells most susceptible to reactive oxygen species are erythrocytes (resulting in hemolysis) and neurons with long axons (ie, high surface area). Spinal cord involvement explains this patient's **loss of vibratory sensation** (dorsal columns) and **ataxia** (spinocerebellar tract); her **weakness** (eg, frequent falls) and **hyporeflexia** are secondary to peripheral neuropathies.

Deficiency of vitamin E is rare in resource-rich regions due to widespread availability in dietary sources; instead, the most common cause is **fat malabsorption**. Normally, bile salts emulsify lipid globules (containing fat-soluble vitamins A, D, E, and K) to form water-soluble micelles. Micelle formation allows pancreatic lipase to effectively hydrolyze fats, allowing for efficient absorption of fat-soluble vitamins. Patients at risk for deficiency include those with **impaired bile acid secretion** or exocrine pancreatic insufficiency (eg, chronic pancreatitis, cystic fibrosis).

In this case, symptoms of vitamin E deficiency in a woman with chronic fatigue and **vague abdominal pain** are suspicious for primary biliary cholangitis, an autoimmune disorder in which destruction of small, intrahepatic bile ducts causes impaired bile acid secretion due to obstruction of biliary flow.

(Choice A) Fat-soluble vitamin deficiencies can occur in exocrine pancreatic insufficiency due to decreased

https://t.me/USMLEWorldStep1

Deficiency of vitamin E is rare in resource-rich regions due to widespread availability in dietary sources; instead, the most common cause is **fat malabsorption**. Normally, bile salts emulsify lipid globules (containing fat-soluble vitamins A, D, E, and K) to form water-soluble micelles. Micelle formation allows pancreatic lipase to effectively hydrolyze fats, allowing for efficient absorption of fat-soluble vitamins. Patients at risk for deficiency include those with **impaired bile acid secretion** or exocrine pancreatic insufficiency (eg, chronic pancreatitis, cystic fibrosis).

In this case, symptoms of vitamin E deficiency in a woman with chronic fatigue and **vague abdominal pain** are suspicious for primary biliary cholangitis, an autoimmune disorder in which destruction of small, intrahepatic bile ducts causes impaired bile acid secretion due to obstruction of biliary flow.

(Choice A) Fat-soluble vitamin deficiencies can occur in exocrine pancreatic insufficiency due to decreased lipase, not amylase. In contrast, decreased pancreatic amylase results in impaired carbohydrate digestion.

(Choice B) Excessive liver hepcidin, which occurs with chronic inflammation/infection, down-regulates gastrointestinal iron absorption. Patients can have fatigue and weakness due to iron deficiency, but the associated anemia is microcytic, not normocytic or hemolytic. In addition, this patient's neurologic findings would not be expected.

(Choice D) Vitamin B_{12} (cobalamin) deficiency can present with anemia and neurologic findings. However, gastric intrinsic factor is required for absorption of vitamin B_{12}, and lack of (not excessive) intrinsic factor causes deficiency (pernicious anemia). Moreover, erythrocytes would be macrocytic, and neutrophils would be hypersegmented.

(Choice E) Renal hydroxylation converts 25-hydroxyvitamin D into the active form, 1,25-dihydroxyvitamin D. Reduced renal hydroxylation (eg, chronic kidney disease) predisposes to bone pain and fractures due to vitamin D deficiency.

Educational objective:
Fat-soluble vitamins (A, D, E, K) require micelle formation for absorption, and risk factors for deficiency include disorders affecting bile production (eg, primary biliary cholangitis). Vitamin E deficiency is characterized by hemolytic anemia and neurologic deficits (eg, ataxia, loss of vibratory sensation, hyporeflexia).

References

- Vitamin E deficiency.

https://t.me/USMLEWorldStep1

(ie, high surface area). Spinal cord involvement explains this patient's **loss of vibratory sensation** (dorsal columns) and **ataxia** (spinocerebellar tract); her **weakness** (eg, frequent falls) and **hyporeflexia** are secondary to periph

Deficie
the mo
vitami
hydrol
with **in**

In this
suspic
ducts

(Choi
lipase,

(Choi
gastro
anemi
expec

(Choi
intrinsi
(pernic

(Choi
Reduc
deficie

Educa
Fat-so
disorders affecting bile production (eg, primary biliary cholangitis). Vitamin E deficiency is characterized by hemolytic anemia and neurologic deficits (eg, ataxia, loss of vibratory sensation, hyporeflexia).

Exhibit Display

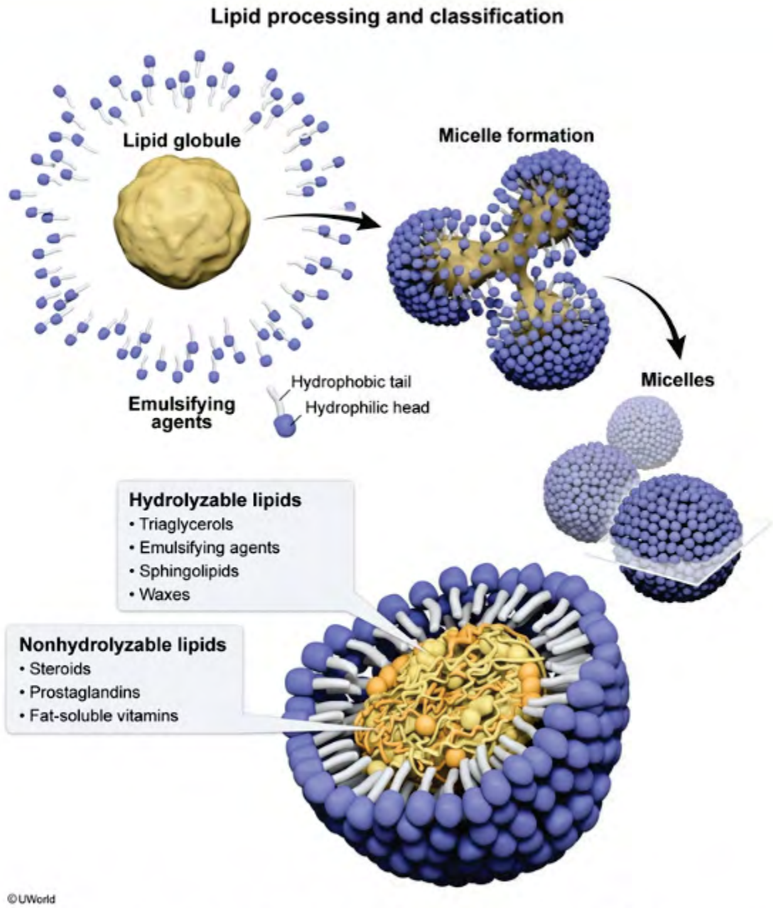

Zoom In | Zoom Out | Reset | New | Existing | My Notebook

https://t.me/USMLEWorldStep1

(ie, high surface area). Spinal cord involvement explains this patient's **loss of vibratory sensation** (dorsal columns) and **ataxia** (spinocerebellar tract); her **weakness** (eg, frequent falls) and **hyporeflexia** are secondary to periph

Deficie
the mo
vitami
hydrol
with **in**

In this
suspic
ducts

(Choi
lipase,

(Choi
gastro
anemi
expect

(Choi
intrinsi
(pernic

(Choi
Reduc
deficie

Educa
Fat-so
disorders affecting bile production (eg, primary biliary cholangitis). Vitamin E deficiency is characterized by hemolytic anemia and neurologic deficits (eg, ataxia, loss of vibratory sensation, hyporeflexia).

Exhibit Display

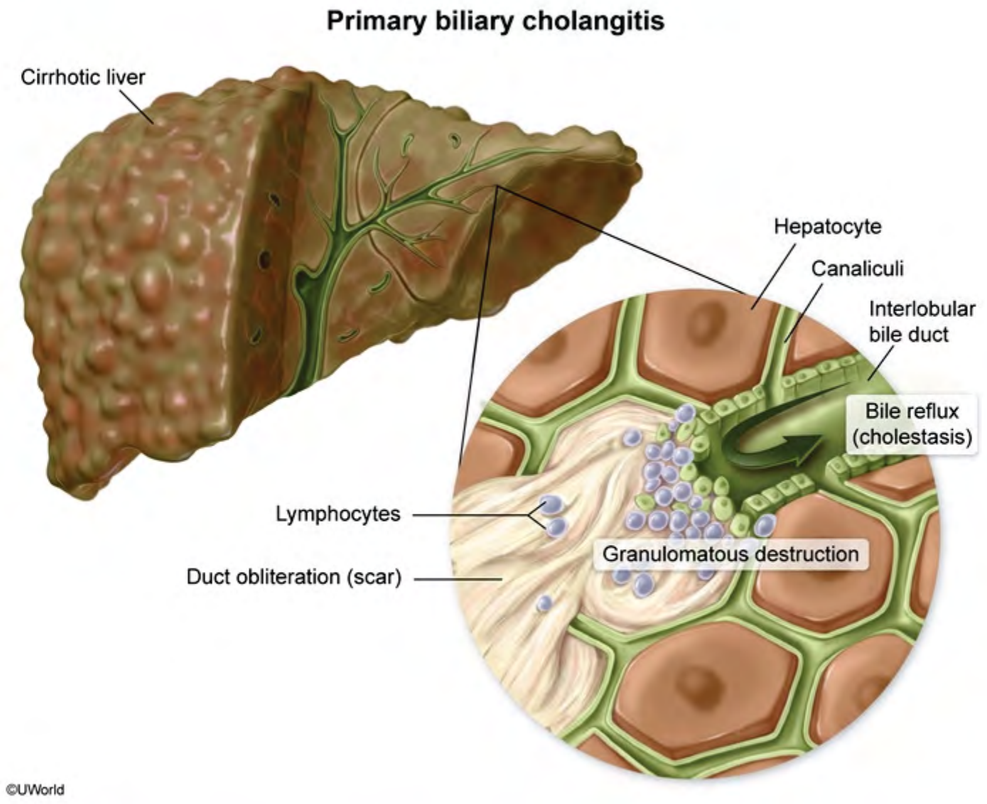

Zoom In | Zoom Out | Reset | New | Existing | My Notebook

https://t.me/USMLEWorldStep1

(ie, high surface area). Spinal cord involvement explains this patient's **loss of vibratory sensation** (dorsal columns) and **ataxia** (spinocerebellar tract); her **weakness** (eg, frequent falls) and **hyporeflexia** are secondary to periph

Deficie
the mo
vitami
hydrol
with **in**

In this
suspic
ducts

(Choi
lipase,

(Choi
gastro
anemi
expec

(Choi
intrinsi
(pernic

(Choi
Reduc
deficie

Educa
Fat-so
disorders affecting bile production (eg, primary biliary cholangitis). Vitamin E deficiency is characterized by hemolytic anemia and neurologic deficits (eg, ataxia, loss of vibratory sensation, hyporeflexia).

Exhibit Display

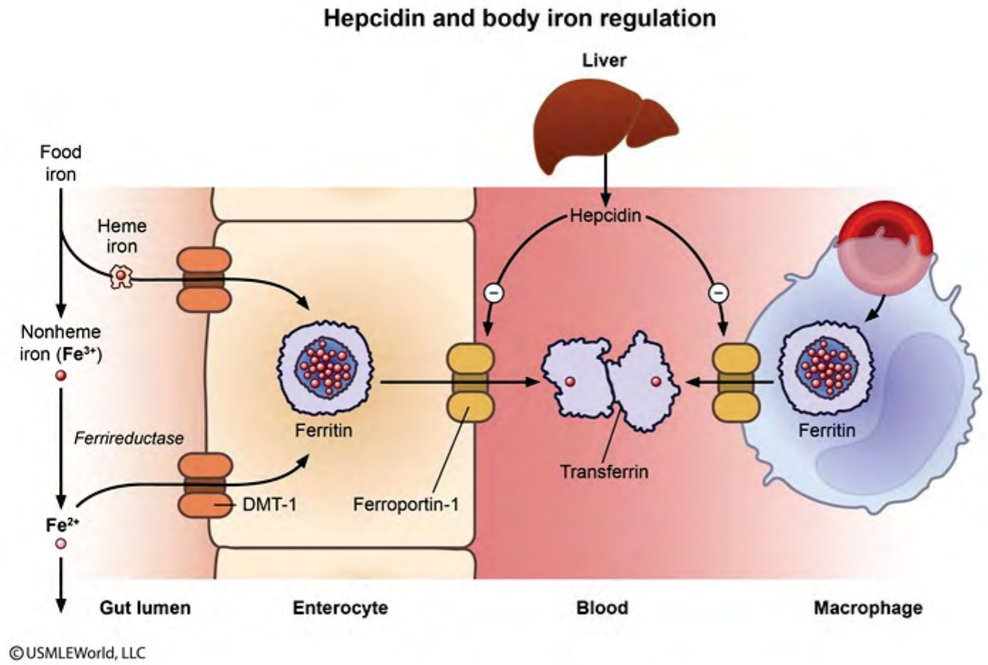

Zoom In Zoom Out Reset New | Existing My Notebook

https://t.me/USMLEWorldStep1

A 22-year-old male presents to the emergency department complaining of fever, abdominal pain, and vomiting. He has had these symptoms for the past four days, but has not sought medical attention because of concerns over the cost of treatment. On examination, the patient appears acutely ill. There is right lower quadrant tenderness with rebound as well as a palpable mass. CT scan of the abdomen and pelvis demonstrates a periappendiceal fluid collection. Culture of this fluid would most likely isolate which of the following organisms?

- A. *Staphylococcus aureus*
- B. *Actinomyces*
- C. *Candida albicans*
- D. *Bacteroides fragilis*
- E. *Entamoeba histolytica*

Submit

https://t.me/USMLEWorldStep1

A 22-year-old male presents to the emergency department complaining of fever, abdominal pain, and vomiting. He has had these symptoms for the past four days, but has not sought medical attention because of concerns over the cost of treatment. On examination, the patient appears acutely ill. There is right lower quadrant tenderness with rebound as well as a palpable mass. CT scan of the abdomen and pelvis demonstrates a periappendiceal fluid collection. Culture of this fluid would most likely isolate which of the following organisms?

- A. *Staphylococcus aureus* (13%)
- ✗ B. *Actinomyces* (3%)
- C. *Candida albicans* (0%)
- ✓ D. *Bacteroides fragilis* (73%)
- E. *Entamoeba histolytica* (9%)

Incorrect
Correct answer
D

73%
Answered correctly

04 secs
Time Spent

2023
Version

Explanation

This patient is suffering from perforated appendicitis that has evolved into an intraabdominal abscess. Although most infections within the abdominal cavity are polymicrobial, *B. fragilis* is a common anaerobic gram-negative bacillus that is frequently isolated, and of the choices given, it is the most likely organism to be identified in the culture of this patient's abscess. This organism expresses unique surface polysaccharides that have been shown to favor abscess formation. In addition to *B. fragilis*, common bacterial isolates from intraabdominal infections include other members of the normal colonic flora such as *Escherichia coli*, enterococci, and streptococci.

(Choice A) *S. aureus* is a gram-positive organism that can cause abscess formation on the skin, but is not typically isolated from an intraabdominal abscess.

(Choice B) *Actinomyces* species are anaerobic bacteria that can form abscesses in the cervicofacial region or

https://t.me/USMLEWorldStep1

Incorrect
Correct answer
D

73%
Answered correctly

04 secs
Time Spent

2023
Version

Explanation

This patient is suffering from perforated appendicitis that has evolved into an intraabdominal abscess. Although most infections within the abdominal cavity are polymicrobial, *B. fragilis* is a common anaerobic gram-negative bacillus that is frequently isolated, and of the choices given, it is the most likely organism to be identified in the culture of this patient's abscess. This organism expresses unique surface polysaccharides that have been shown to favor abscess formation. In addition to *B. fragilis*, common bacterial isolates from intraabdominal infections include other members of the normal colonic flora such as *Escherichia coli*, enterococci, and streptococci.

(Choice A) *S. aureus* is a gram-positive organism that can cause abscess formation on the skin, but is not typically isolated from an intraabdominal abscess.

(Choice B) *Actinomyces* species are anaerobic bacteria that can form abscesses in the cervicofacial region or abdominal cavity. However, they are much less common than *B. fragilis* and typically do not form abscesses this quickly.

(Choice C) *Candida albicans* can be isolated from an infection resulting from perforation of the proximal bowel such as a perforated peptic ulcer.

(Choice E) Infection with *E. histolytica* can result in the formation of an amebic liver abscess. This patient, however, has perforated appendicitis, which is not related to infection with *E. histolytica*.

Educational objective:
Intraabdominal infections are polymicrobial, with *B. fragilis* and *E. coli* being the most prominent organisms isolated.

Microbiology	Gastrointestinal & Nutrition	Appendicitis
Subject	System	Topic

Copyright © UWorld. All rights reserved.

https://t.me/USMLEWorldStep1

A 52-year-old man comes to the office for a painless mass in his right groin. He noticed the mass several weeks ago, and it has slowly enlarged. The patient has a history of HIV, for which he takes antiretroviral therapy. He has not had any new sexual partners recently. Temperature is 37.1 C (98.8 F). On examination, several enlarged, hard lymph nodes are palpated in the right inguinal area inferior to the inguinal ligament. An excisional biopsy is performed, and histopathology shows malignant cells. The malignant cells found in this patient most likely originated from which of the following sites?

- A. Dome of the bladder
- B. Lateral lobe of the prostate
- C. Orifice of the anal canal
- D. Upper pole of the testes
- E. Upper third of the rectum

Submit

https://t.me/USMLEWorldStep1

A 52-year-old man comes to the office for a painless mass in his right groin. He noticed the mass several weeks ago, and it has slowly enlarged. The patient has a history of HIV, for which he takes antiretroviral therapy. He has not had any new sexual partners recently. Temperature is 37.1 C (98.8 F). On examination, several enlarged, hard lymph nodes are palpated in the right inguinal area inferior to the inguinal ligament. An excisional biopsy is performed, and histopathology shows malignant cells. The malignant cells found in this patient most likely originated from which of the following sites?

- A. Dome of the bladder (5%)
- ✗ B. Lateral lobe of the prostate (12%)
- ✓ C. Orifice of the anal canal (54%)
- D. Upper pole of the testes (17%)
- E. Upper third of the rectum (10%)

Incorrect
Correct answer
C

54%
Answered correctly

03 secs
Time Spent

2023
Version

Explanation

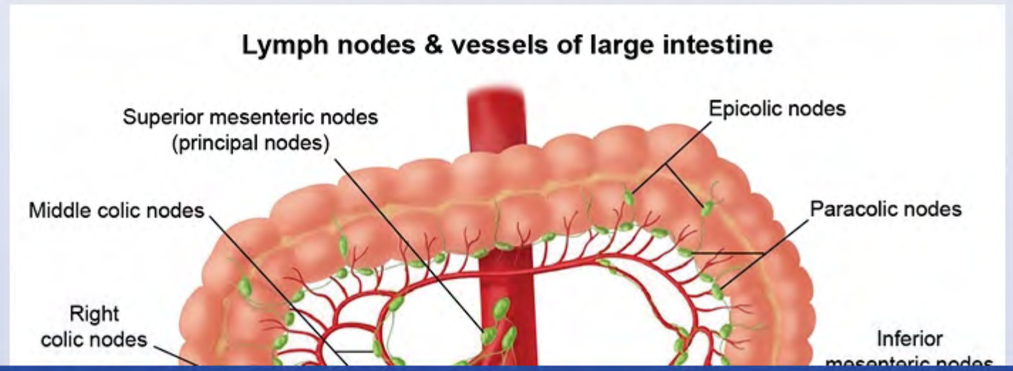

https://t.me/USMLEWorldStep1

C. Orifice of the anal canal (54%)

Exhibit Display

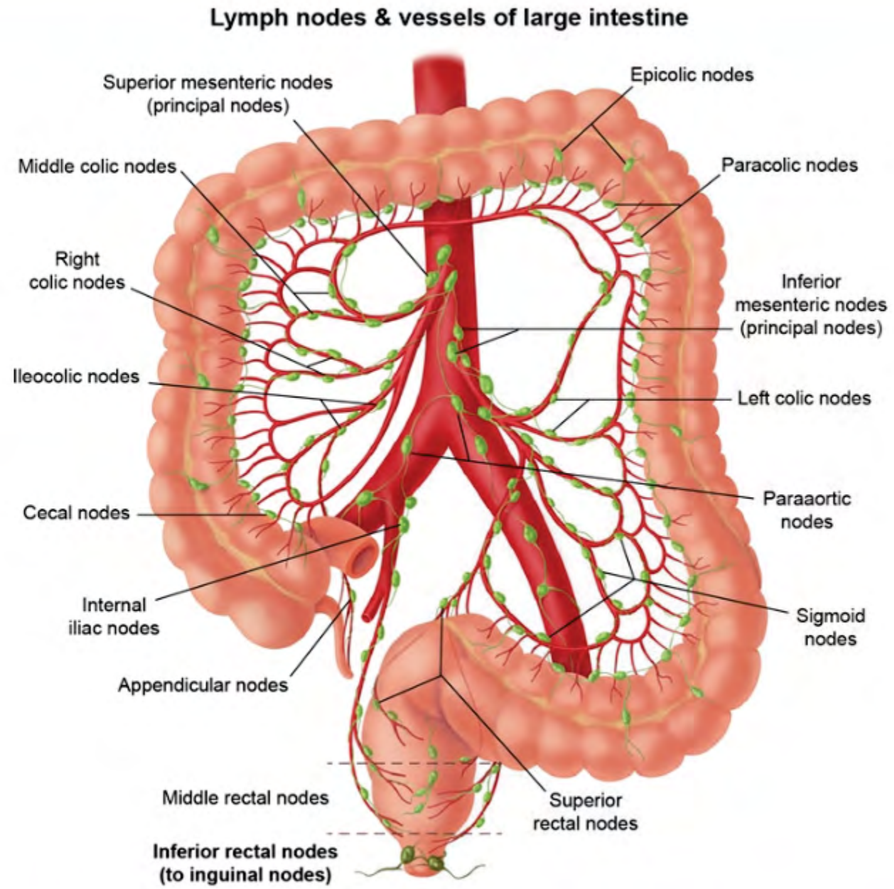

Zoom In | Zoom Out | Reset | New | Existing | My Notebook

https://t.me/USMLEWorldStep1

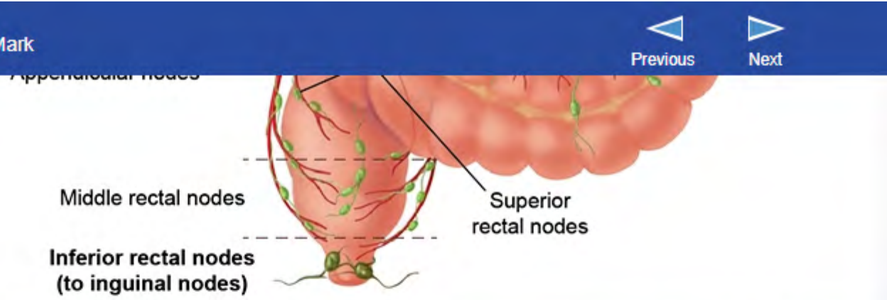

This patient has palpable, firm **superficial inguinal lymph nodes**. These nodes overlie the femoral nerve, artery, and vein in the femoral triangle, a region bound by the inguinal ligament, sartorius muscle, and adductor longus muscle. The superficial inguinal nodes drain **most cutaneous lymph** from the **umbilicus down**, including the external genitalia and anus (below the dentate line). In this patient, metastasis from a malignancy around the orifice of the **anal canal** most likely explains his inguinal lymphadenopathy.

Exceptions to this drainage pattern include the **glans penis** and skin of the **posterior calf** (popliteal lymph nodes), which bypass the superficial inguinal nodes to drain into the deep inguinal lymph nodes.

(Choice A) Lymph from the superior portion of the bladder drains to the external iliac nodes whereas lymph from the inferior portion of the bladder drains to the internal iliac nodes.

(Choice B) Lymph from the prostate drains primarily to the internal iliac nodes.

(Choice D) Lymph from the testes parallels the blood supply from the testicular arteries, which arise directly from the abdominal aorta. As such, testicular lymph drains to the abdominal para-aortic (retroperitoneal) lymph nodes.

(Choice E) Lymph from the upper third of the rectum drains to the inferior mesenteric lymph nodes.

Educational objective:
Most of the cutaneous lymph from the umbilicus down, including the anus below the dentate line, drains to the superficial inguinal lymph nodes. Exceptions are the glans penis and posterior calf, which drain to the deep inguinal nodes.

Anatomy	Gastrointestinal & Nutrition	Lymphatic drainage
Subject	System	Topic

Copyright © UWorld. All rights reserved.

https://t.me/USMLEWorldStep1

Exhibit Display

Lymph vessels & nodes of male genitalia

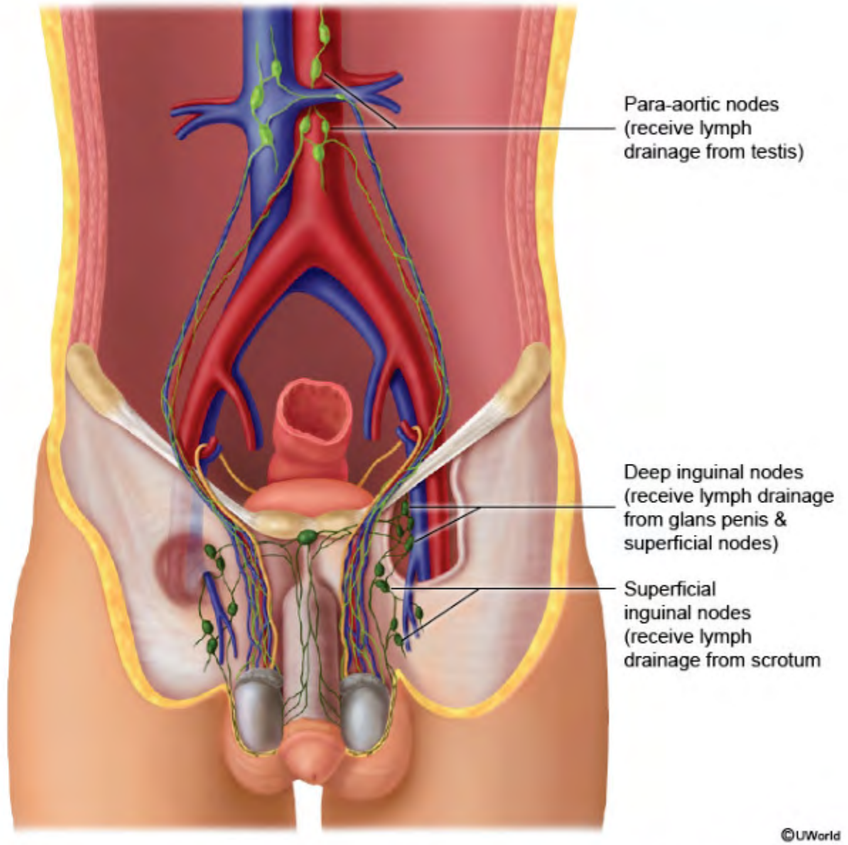

Zoom In | Zoom Out | Reset | New | Existing | My Notebook

This p
and ve
muscl
extern
orifice

Excep
nodes

(Choi
the inf

(Choi

(Choi
the ab

(Choi

Educa
Most c
superf
inguin

Anatom
Subject

Copyright © UWorld. All rights reserved.

https://t.me/USMLEWorldStep1

A 54-year-old man comes to the office due to several months of heartburn, acid regurgitation, and dysphagia. He has taken antacids and over-the-counter medications without relief. Medical history includes hypertension and hyperlipidemia. The patient does not use tobacco, alcohol, or illicit drugs. Vital signs are within normal limits. BMI is 32 kg/m^2. Physical examination is unremarkable. Upright chest x-ray shows an opacity with an air-fluid level behind the heart. A subsequent barium swallow reveals the proximal stomach herniating through the esophageal hiatus. Which of the following pathophysiological changes most likely contributed to this patient's current condition?

- A. Cephalad migration of the squamocolumnar junction with a fixed gastroesophageal junction
- B. Circumferential laxity of the phrenoesophageal membrane
- C. Diaphragmatic muscle paralysis due to C3-5 motor nerve injury
- D. Failure of the posterolateral diaphragmatic foramina to fuse
- E. Herniation of abdominal contents through the omental foramen

Submit

https://t.me/USMLEWorldStep1

A 54-year-old man comes to the office due to several months of heartburn, acid regurgitation, and dysphagia. He has taken antacids and over-the-counter medications without relief. Medical history includes hypertension and hyperlipidemia. The patient does not use tobacco, alcohol, or illicit drugs. Vital signs are within normal limits. BMI is 32 kg/m^2. Physical examination is unremarkable. Upright chest x-ray shows an opacity with an air-fluid level behind the heart. A subsequent barium swallow reveals the proximal stomach herniating through the esophageal hiatus. Which of the following pathophysiological changes most likely contributed to this patient's current condition?

- A. Cephalad migration of the squamocolumnar junction with a fixed gastroesophageal junction (20%)
- ✓ B. Circumferential laxity of the phrenoesophageal membrane (59%)
- C. Diaphragmatic muscle paralysis due to C3-5 motor nerve injury (1%)
- D. Failure of the posterolateral diaphragmatic foramina to fuse (9%)
- E. Herniation of abdominal contents through the omental foramen (8%)

Correct

59% Answered correctly

04 secs Time Spent

2023 Version

Explanation

https://t.me/USMLEWorldStep1

Correct

Answered correctly

Time Spent

Version

Exhibit Display

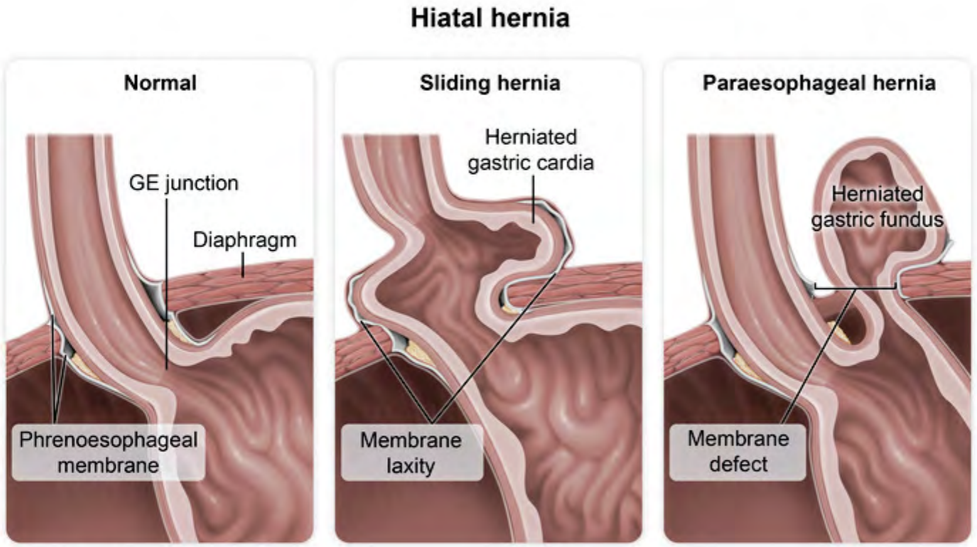

GE = gastroesophageal.

©UWorld

Zoom In | Zoom Out | Reset | New | Existing | My Notebook

This p
the dia
circum
disrup

- **S**
  m
  a

patients to reflux symptoms (eg, heartburn, regurgitation, epigastric/chest pain) due to incompetence of the lower esophageal sphincter.

https://t.me/USMLEWorldStep1



GE = gastroesophageal.
©UWorld

This patient has a **hiatal hernia**, a common disorder in which the contents of the abdominal cavity herniate through the diaphragm into the thoracic cavity at the esophageal hiatus. The distal esophagus is normally attached circumferentially to the diaphragm by the **phrenoesophageal membrane** at the gastroesophageal (GE) junction; disruptions in membrane integrity can result in hernia formation:

- **Sliding** hiatal hernias are the most common form and occur due to **laxity** of the phrenoesophageal membrane, which typically results from repetitive stress on the membrane (eg, coughing, vomiting). This allows the **GE junction** and **proximal stomach** to slide upward into the thoracic cavity and predisposes patients to reflux symptoms (eg, heartburn, regurgitation, epigastric/chest pain) due to incompetence of the lower esophageal sphincter.
- **Paraesophageal** hernias are rarer and occur due to a **defect** (hole) in the phrenoesophageal membrane. Laxity of the gastrocolic and gastrosplenic ligaments (which anchor the stomach in the abdomen) allows the **gastric fundus** to migrate into the thoracic cavity. Larger defects can also result in the subsequent herniation of the GE junction and surrounding structures (eg, bowel, spleen) into the chest. This predisposes patients to gastric volvulus, ulcerations, and respiratory complications (due to lung compression).

(Choice A) Barrett esophagus is the metaplastic replacement of normal squamous cells in the distal esophagus with squamocolumnar cells and occurs as a result of chronic acid reflux. Patients with Barrett esophagus are at increased risk of esophageal cancer, but it does not cause herniation.

(Choice C) Diaphragmatic muscle paralysis due to C3-5 motor nerve injury causes an elevated hemidiaphragm. Patients are typically asymptomatic (due to compensation by the other respiratory muscles), but dyspnea or orthopnea can occur. It is not associated with herniation of intrabdominal contents into the chest.

(Choice D) Failure of the posterolateral diaphragmatic foramina to fuse can cause a Bochdalek hernia. This congenital hernia is typically diagnosed pre- or perinatally; pulmonary hypoplasia with neonatal respiratory distress is common.

(Choice E) Herniation of the viscera through the omental foramen (foramen of Winslow) causes an intraabdominal

https://t.me/USMLEWorldStep1

patients to reflux symptoms (eg, heartburn, regurgitation, epigastric/chest pain) due to incompetence of the lower esophageal sphincter.

- **Paraesophageal** hernias are rarer and occur due to a **defect** (hole) in the phrenoesophageal membrane. Laxity of the gastrocolic and gastrosplenic ligaments (which anchor the stomach in the abdomen) allows the **gastric fundus** to migrate into the thoracic cavity. Larger defects can also result in the subsequent herniation of the GE junction and surrounding structures (eg, bowel, spleen) into the chest. This predisposes patients to gastric volvulus, ulcerations, and respiratory complications (due to lung compression).

(Choice A) Barrett esophagus is the metaplastic replacement of normal squamous cells in the distal esophagus with squamocolumnar cells and occurs as a result of chronic acid reflux. Patients with Barrett esophagus are at increased risk of esophageal cancer, but it does not cause herniation.

(Choice C) Diaphragmatic muscle paralysis due to C3-5 motor nerve injury causes an elevated hemidiaphragm. Patients are typically asymptomatic (due to compensation by the other respiratory muscles), but dyspnea or orthopnea can occur. It is not associated with herniation of intrabdominal contents into the chest.

(Choice D) Failure of the posterolateral diaphragmatic foramina to fuse can cause a Bochdalek hernia. This congenital hernia is typically diagnosed pre- or perinatally; pulmonary hypoplasia with neonatal respiratory distress is common.

(Choice E) Herniation of the viscera through the omental foramen (foramen of Winslow) causes an intraabdominal hernia known as lesser sac hernia. Lesser sac hernias are very rare, typically involve the small bowel, and cause severe abdominal pain due to bowel strangulation or obstruction.

Educational objective:
Hiatal hernias occur when contents of the abdominal cavity herniate through the diaphragm at the esophageal hiatus into the thoracic cavity. Sliding hiatal hernias occur due to laxity of the phrenoesophageal membrane, leading to herniation of the gastroesophageal junction and proximal stomach, whereas paraesophageal hernias occur due to defects in the membrane, resulting in the gastric fundus herniation.

Anatomy	Gastrointestinal & Nutrition	Hiatal hernia
Subject	System	Topic

https://t.me/USMLEWorldStep1

A 30-year-old man comes to the office due to a 4-month history of fatigue that is worse at the end of the day. The patient has also had abdominal bloating and intermittent loose stools after meals. His appetite is normal, and he has had no weight loss. Vital signs are normal. Examination shows pale mucosa. The abdomen is mildly distended and tympanic; there is no tenderness or organomegaly. Rectal examination reveals brown stool that is negative for fecal occult blood. Laboratory results are as follows:

Hematocrit	28%
Mean corpuscular volume	75 μm^3
Leukocytes	7,100/mm^3
Platelets	490,000/mm^3

C-reactive protein level is normal. Which of the following pathologic gastrointestinal tract findings is most likely to be present in this patient?

- A. Atrophic mucosa with loss of villi of the small intestine
- B. Autoimmune destruction of gastric parietal cells
- C. Chronic inflammation within the colonic mucosa and submucosa
- D. *Giardia* trophozoites lining the small intestinal mucosa
- E. Subepithelial collagen deposition in the colon

Submit

https://t.me/USMLEWorldStep1

A 30-year-old man comes to the office due to a 4-month history of fatigue that is worse at the end of the day. The patient has also had abdominal bloating and intermittent loose stools after meals. His appetite is normal, and he has had no weight loss. Vital signs are normal. Examination shows pale mucosa. The abdomen is mildly distended and tympanic; there is no tenderness or organomegaly. Rectal examination reveals brown stool that is negative for fecal occult blood. Laboratory results are as follows:

Hematocrit	28%
Mean corpuscular volume	75 μm^3
Leukocytes	7,100/mm^3
Platelets	490,000/mm^3

C-reactive protein level is normal. Which of the following pathologic gastrointestinal tract findings is most likely to be present in this patient?

- ✓ A. Atrophic mucosa with loss of villi of the small intestine (57%)
- B. Autoimmune destruction of gastric parietal cells (12%)
- C. Chronic inflammation within the colonic mucosa and submucosa (17%)
- D. *Giardia* trophozoites lining the small intestinal mucosa (7%)
- E. Subepithelial collagen deposition in the colon (4%)

Correct

57% Answered correctly

03 secs Time Spent

2023 Version

Explanation

Normal duodenum **Celiac disease**

https://t.me/USMLEWorldStep1

be present in this patient?

Exhibit Display

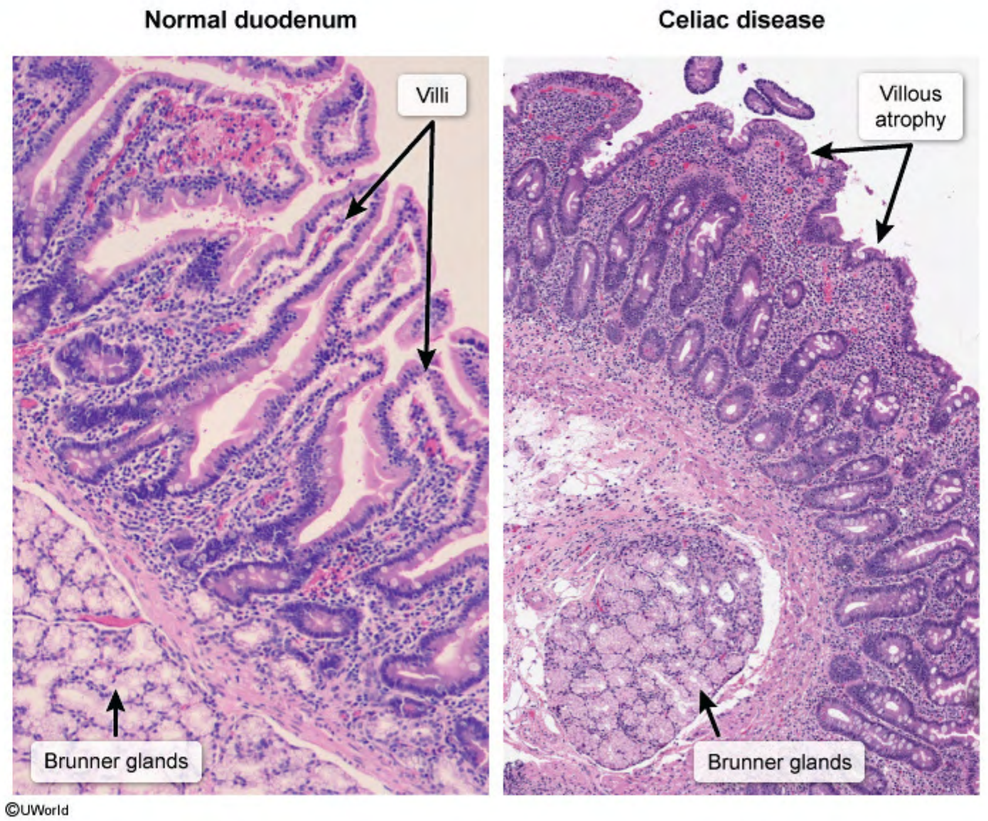

Zoom In Zoom Out Reset New | Existing My Notebook

https://t.me/USMLEWorldStep1

This patient's loose stools, abdominal cramps, and microcytic anemia are most likely due to **celiac disease**, an immune-mediated disorder of the small bowel caused by dietary gluten. Gliadin, a component of gluten, is responsible for triggering the T-cell–mediated reaction against the small-bowel mucosa seen in celiac disease. This is initially characterized by intraepithelial lymphocytosis, followed as the disease progresses by a **loss of small-bowel intestinal villi** and **mucosal atrophy**. This decreases the nutritional absorptive capabilities of the small bowel, particularly in the duodenum and proximal jejunum.

Because iron is absorbed primarily in the duodenum, **iron deficiency** leading to **microcytic anemia** is a common manifestation of celiac disease; common presenting features include fatigue and pale mucosa. Other symptoms of gluten-sensitive enteropathy include **postprandial diarrhea** and steatorrhea (eg, pale, loose stools), **abdominal cramps**, bloating, flatulence, and weight loss. Celiac disease is not associated with elevated systemic inflammatory markers (eg, C-reactive protein, erythrocyte sedimentation rate), and unlike gastrointestinal disorders that cause chronic blood loss (eg, inflammatory bowel disease, colon cancer), in celiac disease, fecal occult blood testing is negative.

(Choice B) Pernicious anemia is characterized by antibody-mediated destruction of intrinsic factor and gastric parietal cells. This can lead to decreased vitamin B_{12} absorption, with macrocytic (not microcytic) anemia, glossitis, and, sometimes, subacute combined degeneration of the dorsolateral spinal cord.

(Choice C) Ulcerative colitis causes chronic inflammatory changes of the colonic mucosa and submucosa. Iron deficiency anemia is common but is due to blood loss rather than malabsorption; a positive fecal occult blood test would be expected, and inflammatory markers are typically elevated.

(Choice D) Giardiasis is usually diagnosed on stool testing, although *Giardia lamblia* trophozoites are readily visible on small-bowel biopsy. Giardiasis is a common cause of diarrhea and may cause steatorrhea due to impairment of brush border enzymes. However, iron malabsorption with microcytic anemia is uncommon.

(Choice E) Collagenous colitis is characterized by subepithelial collagen deposition in the colon. It often causes watery diarrhea but does not affect iron absorption in the small intestine, so microcytic anemia would be unexpected.

Educational objective:

https://t.me/USMLEWorldStep1

manifestation of celiac disease; common presenting features include fatigue and pale mucosa. Other symptoms of gluten-sensitive enteropathy include **postprandial diarrhea** and steatorrhea (eg, pale, loose stools), **abdominal cramps**, bloating, flatulence, and weight loss. Celiac disease is not associated with elevated systemic inflammatory markers (eg, C-reactive protein, erythrocyte sedimentation rate), and unlike gastrointestinal disorders that cause chronic blood loss (eg, inflammatory bowel disease, colon cancer), in celiac disease, fecal occult blood testing is negative.

(Choice B) Pernicious anemia is characterized by antibody-mediated destruction of intrinsic factor and gastric parietal cells. This can lead to decreased vitamin B_{12} absorption, with macrocytic (not microcytic) anemia, glossitis, and, sometimes, subacute combined degeneration of the dorsolateral spinal cord.

(Choice C) Ulcerative colitis causes chronic inflammatory changes of the colonic mucosa and submucosa. Iron deficiency anemia is common but is due to blood loss rather than malabsorption; a positive fecal occult blood test would be expected, and inflammatory markers are typically elevated.

(Choice D) Giardiasis is usually diagnosed on stool testing, although *Giardia lamblia* trophozoites are readily visible on small-bowel biopsy. Giardiasis is a common cause of diarrhea and may cause steatorrhea due to impairment of brush border enzymes. However, iron malabsorption with microcytic anemia is uncommon.

(Choice E) Collagenous colitis is characterized by subepithelial collagen deposition in the colon. It often causes watery diarrhea but does not affect iron absorption in the small intestine, so microcytic anemia would be unexpected.

Educational objective:
Celiac disease is an immune-mediated disorder triggered by dietary gluten that causes small-bowel malabsorption. Because the proximal small bowel is primarily affected, iron deficiency leading to microcytic anemia is common. Histopathology is characterized by intraepithelial lymphocytosis, loss of intestinal villi, and mucosal atrophy.

Pathophysiology	Gastrointestinal & Nutrition	Celiac disease
Subject	System	Topic

Copyright © UWorld. All rights reserved.

https://t.me/USMLEWorldStep1

Exhibit Display

This p
immun
respon
This is
small-
small

Becau
manife
gluten
cramp
inflam
that ca
testing

(Choi
parieta
and, s

(Choi
deficie
would

(Choi
visible
impair

(Choice E) Collagenous colitis is characterized by subepithelial collagen deposition in the colon. It often causes watery diarrhea but does not affect iron absorption in the small intestine, so microcytic anemia would be

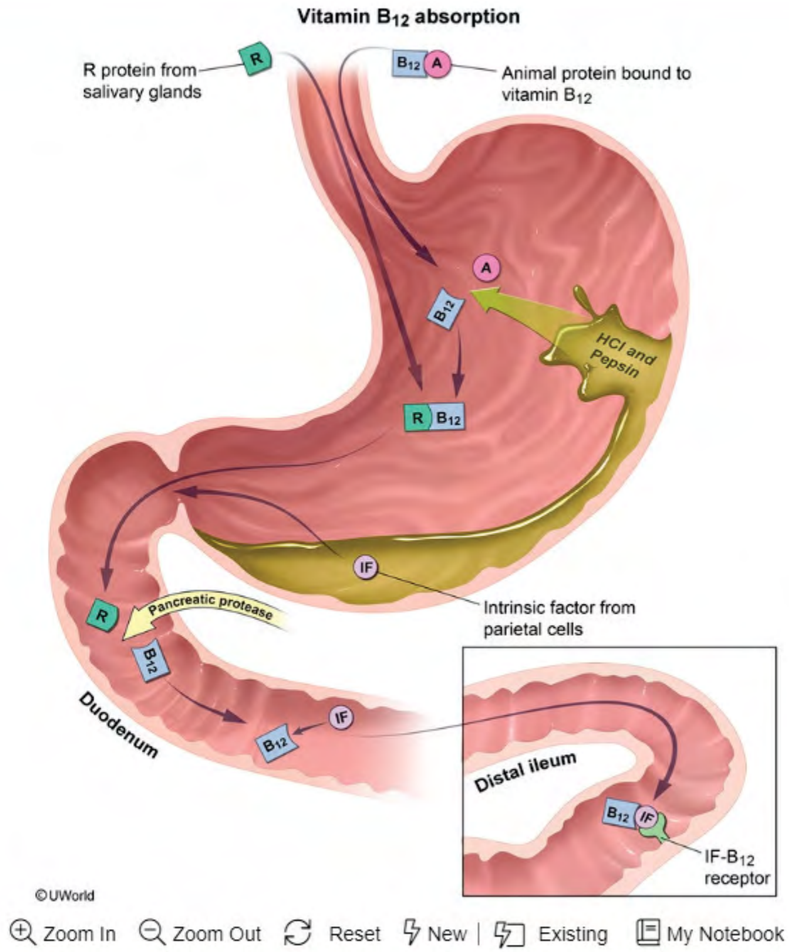

Zoom In | Zoom Out | Reset | New | Existing | My Notebook

https://t.me/USMLEWorldStep1

Exhibit Display

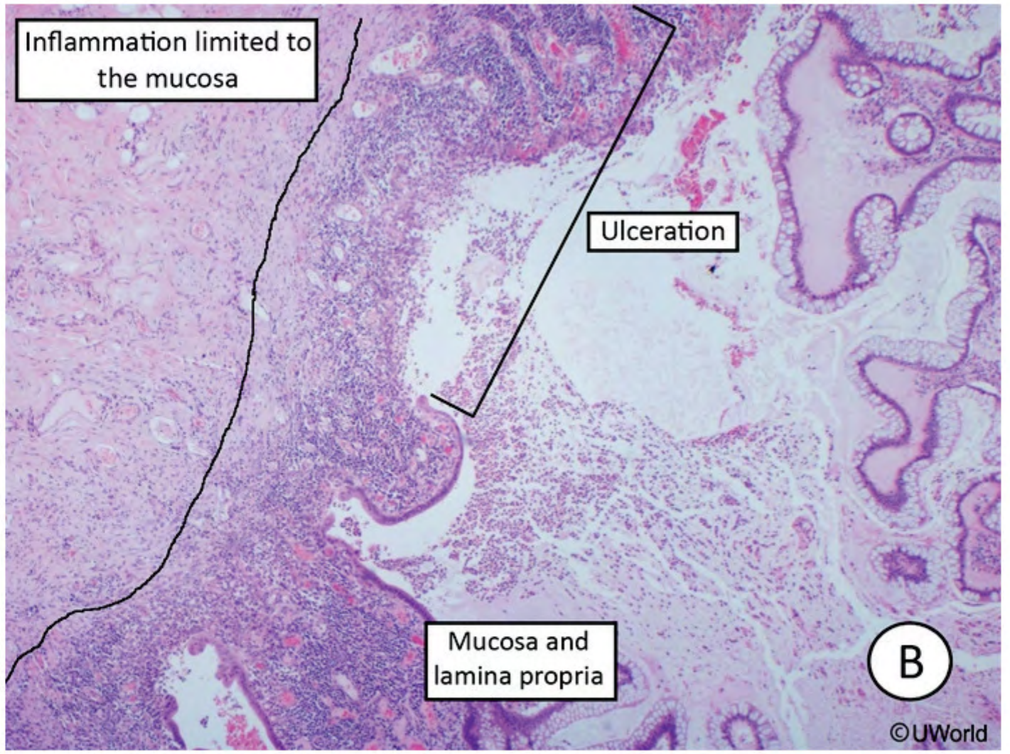

Zoom In | Zoom Out | Reset | New | Existing | My Notebook

This p
immur
respor
This is
small-
small

Becau
manife
gluten
cramp
inflam
that ca
testing

(Choi
parieta
and, s

(Choi
deficie
would

(Choi
visible
impair

(Choice E) Collagenous colitis is characterized by subepithelial collagen deposition in the colon. It often causes watery diarrhea but does not affect iron absorption in the small intestine, so microcytic anemia would be

https://t.me/USMLEWorldStep1

Brunner glands

Brunner glands

Exhibit Display

Zoom In | Zoom Out | Reset | New | Existing | My Notebook

This p
immur
respor
This is
small-
small

Becau
manife
gluten
cramp
inflam
that ca
testing

(Choi
parieta
and, s

(Choi
deficie
would

(Choi
visible
impair

(Choice E) Collagenous colitis is characterized by subepithelial collagen deposition in the colon. It often causes watery diarrhea but does not affect iron absorption in the small intestine, so microcytic anemia would be

https://t.me/USMLEWorldStep1

This patient's loose stools, abdominal cramps, and microcytic anemia are most likely due to **celiac disease**, an immune-mediated disorder of the small bowel caused by dietary gluten. Gliadin, a component of gluten, is respor
This is
small-
small

Becau
manife
gluten
cramp
inflam
that ca
testing

(Choi
parieta
and, s

(Choi
deficie
would

(Choi
visible
impair

(Choi
watery
unexpected.

Exhibit Display

Collagenous colitis

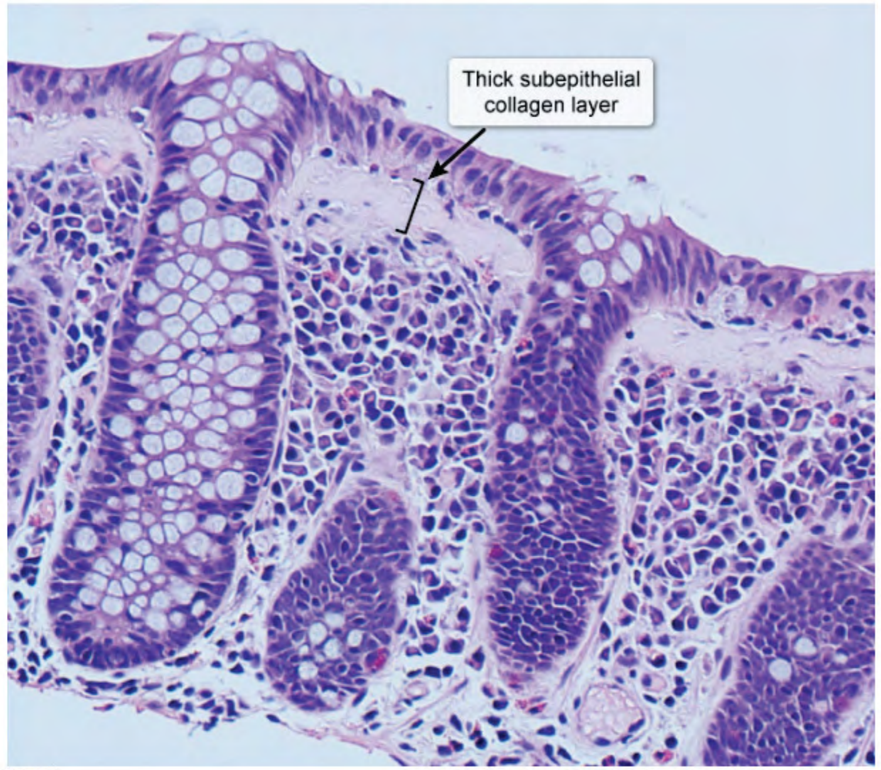

©UWorld

Zoom In Zoom Out Reset New | Existing My Notebook

Educational objective:

Celiac disease is an immune-mediated disorder triggered by dietary gluten that causes small-bowel

https://t.me/USMLEWorldStep1

A 47-year-old morbidly obese woman comes to the physician seeking advice regarding weight loss. She has tried diet and exercise a number of times without success. Her other medical problems include type 2 diabetes mellitus and obstructive sleep apnea. Her body mass index is 43 kg/m^2. After a discussion about available surgical options, she expresses interest in the adjustable gastric band, an inflatable silicone device that is placed around the cardiac part of the stomach. In order to encircle the stomach, the band must pass through which of the following structures?

- A. Falciform ligament
- B. Gastrocolic ligament
- C. Greater omentum
- D. Lesser omentum
- E. Splenorenal ligament

Submit

https://t.me/USMLEWorldStep1

A 47-year-old morbidly obese woman comes to the physician seeking advice regarding weight loss. She has tried diet and exercise a number of times without success. Her other medical problems include type 2 diabetes mellitus and obstructive sleep apnea. Her body mass index is 43 kg/m^2. After a discussion about available surgical options, she expresses interest in the adjustable gastric band, an inflatable silicone device that is placed around the cardiac part of the stomach. In order to encircle the stomach, the band must pass through which of the following structures?

- ✗ A. Falciform ligament (4%)
- B. Gastrocolic ligament (14%)
- C. Greater omentum (18%)
- ✓ D. Lesser omentum (60%)
- E. Splenorenal ligament (2%)

Incorrect
Correct answer
D

60%
Answered correctly

03 secs
Time Spent

2023
Version

Explanation

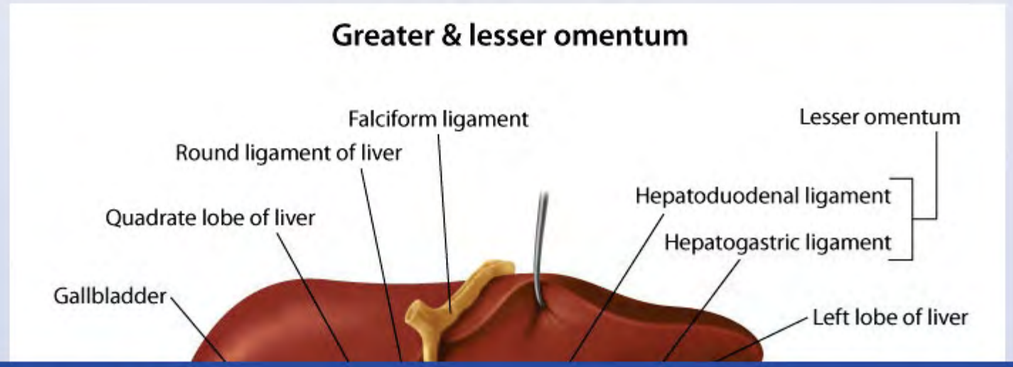

https://t.me/USMLEWorldStep1

A 47-year-old morbidly obese woman comes to the physician seeking advice regarding weight loss. She has tried diet ar
and ob
option
the ca
followi

Exhibit Display

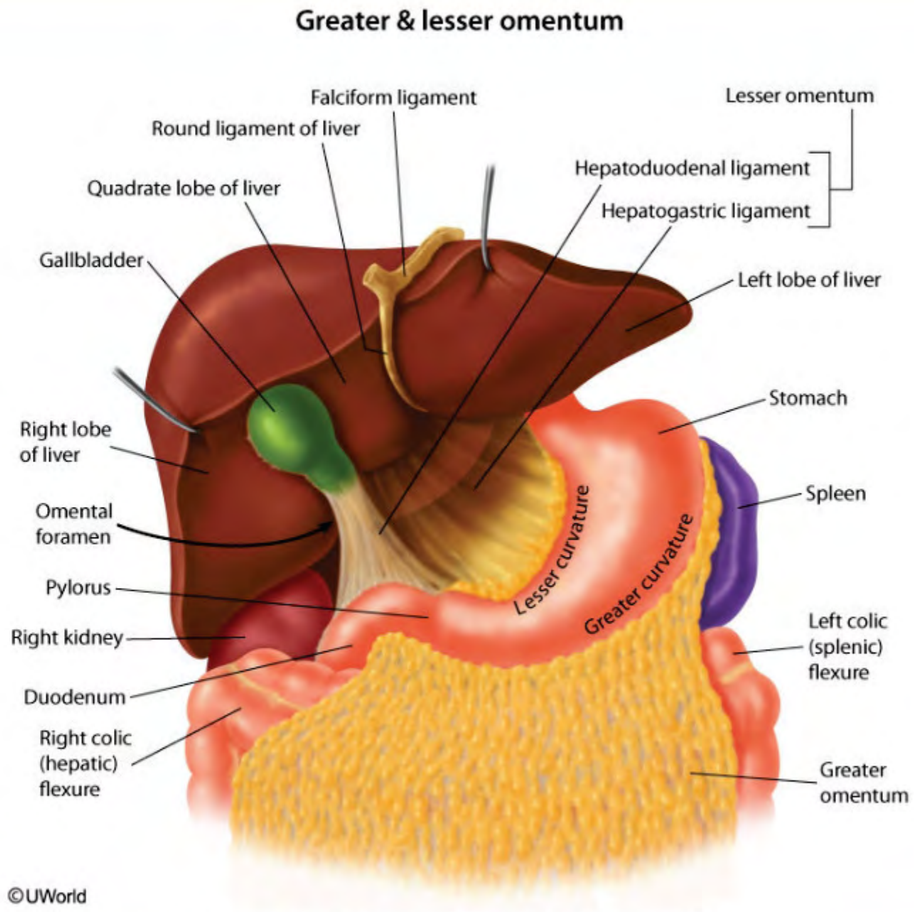

Zoom In | Zoom Out | Reset | New | Existing | My Notebook

https://t.me/USMLEWorldStep1

Adjustable gastric banding is a type of restrictive bariatric surgery designed for obese patients. The adjustable gastric band is an inflatable silicone device placed around the gastric cardia. It is intended to slow the passage of food, increasing satiety and limiting the amount of food consumed. To encircle the upper stomach, the gastric band must pass through the lesser omentum.

The lesser omentum is a double layer of peritoneum that extends from the liver to the lesser curvature of the stomach and the beginning of the duodenum. Anatomically, the lesser omentum is divided into 2 ligaments:

1. Hepatogastric ligament: the portion connecting to the lesser curvature of the stomach
2. Hepatoduodenal ligament: the portion connecting to the duodenum

Between the 2 layers of the lesser omentum, close to the right-sided free margin, lie the hepatic artery, common bile duct, portal vein, lymphatics, and hepatic plexus. The right and left gastric arteries and gastric veins also lie between the 2 layers, near where the lesser omentum attaches to the stomach.

(Choice A) The falciform ligament attaches the liver to the anterior body wall. It is a derivative of the embryonic ventral mesentery and contains the round ligament, the remnant of the fetal umbilical vein.

(Choices B and C) The greater omentum is a large fold of visceral peritoneum that extends from the greater curvature of the stomach, travels inferiorly over the small intestine, and then reflects on itself and ascends to encompass the transverse colon before reaching the posterior abdominal wall. The gastrocolic ligament is the section that stretches from the greater curvature of the stomach to the transverse colon. It forms part of the anterior wall of the lesser sac and is often divided during surgery to provide access to the anterior pancreas and posterior wall of the stomach.

(Choice E) The splenorenal ligament is derived from the peritoneum and lies between the left kidney and the spleen. It contains the splenic vessels and the tail of the pancreas.

Educational objective:
The lesser omentum is a double layer of peritoneum that extends from the liver to the lesser curvature of the stomach and the beginning of the duodenum. It is divided into the hepatogastric and hepatoduodenal ligaments.

Anatomy Gastrointestinal & Nutrition Obesity

https://t.me/USMLEWorldStep1

Adjustable gastric banding is a type of restrictive bariatric surgery designed for obese patients. The adjustable gastric
food, i
must p

The le
stoma

1. H
2. H

Betwe
bile du
betwe

(Choi
ventra

(Choi
curvat
encom
sectio
anteri
poster

(Choi
spleen

Educa
The le
stoma

Exhibit Display

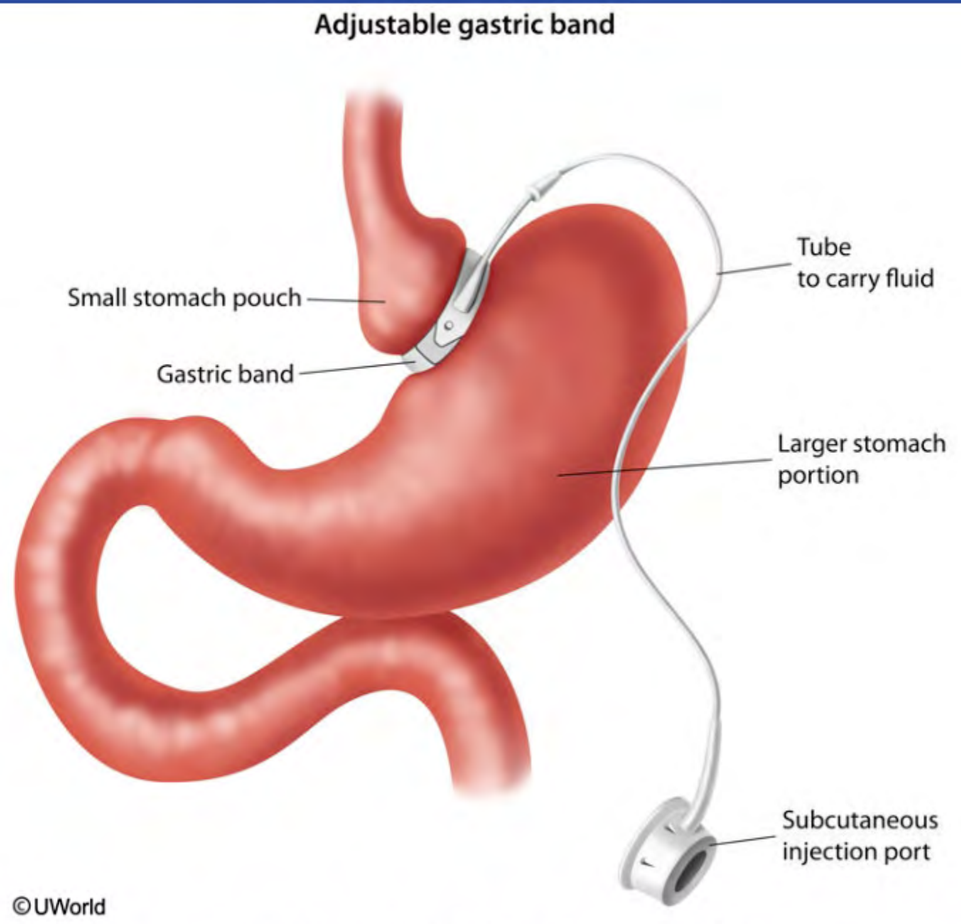

Zoom In | Zoom Out | Reset | New | Existing | My Notebook

Anatomy | Gastrointestinal & Nutrition | Obesity

https://t.me/USMLEWorldStep1

A 34-year-old man is found to have dyslipidemia. His other medical problems include a myocardial infarction 1 week ago. His father died of myocardial infarction at the age of 48 years. Several other family members have had myocardial infarctions and hypertension. The patient smoked cigarettes and drank alcohol occasionally but quit after his myocardial infarction. He is started on simvastatin and cholestyramine. Which of the following best describes the independent effects of simvastatin and cholestyramine, respectively, on hepatic cholesterol synthesis?

- A. Increase and increase
- B. Increase and decrease
- C. Decrease and increase
- D. Decrease and decrease
- E. Increase and no change

Submit

https://t.me/USMLEWorldStep1

A 34-year-old man is found to have dyslipidemia. His other medical problems include a myocardial infarction 1 week ago. His father died of myocardial infarction at the age of 48 years. Several other family members have had myocardial infarctions and hypertension. The patient smoked cigarettes and drank alcohol occasionally but quit after his myocardial infarction. He is started on simvastatin and cholestyramine. Which of the following best describes the independent effects of simvastatin and cholestyramine, respectively, on hepatic cholesterol synthesis?

- ✗ A. Increase and increase (2%)
- B. Increase and decrease (2%)
- ✓ C. Decrease and increase (72%)
- D. Decrease and decrease (19%)
- E. Increase and no change (3%)

Incorrect
Correct answer
C

72%
Answered correctly

05 secs
Time Spent

2023
Version

Explanation

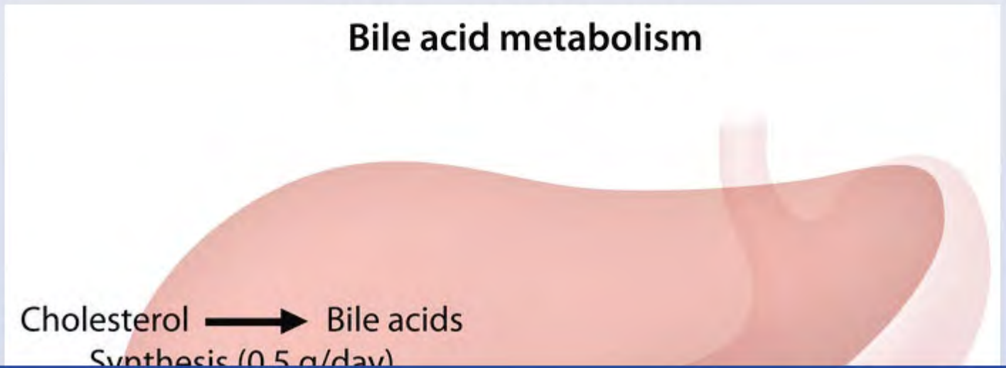

https://t.me/USMLEWorldStep1

A 34-year-old man is found to have dyslipidemia. His other medical problems include a myocardial infarction 1 week a
myoca
after h
descri
synthe

Exhibit Display

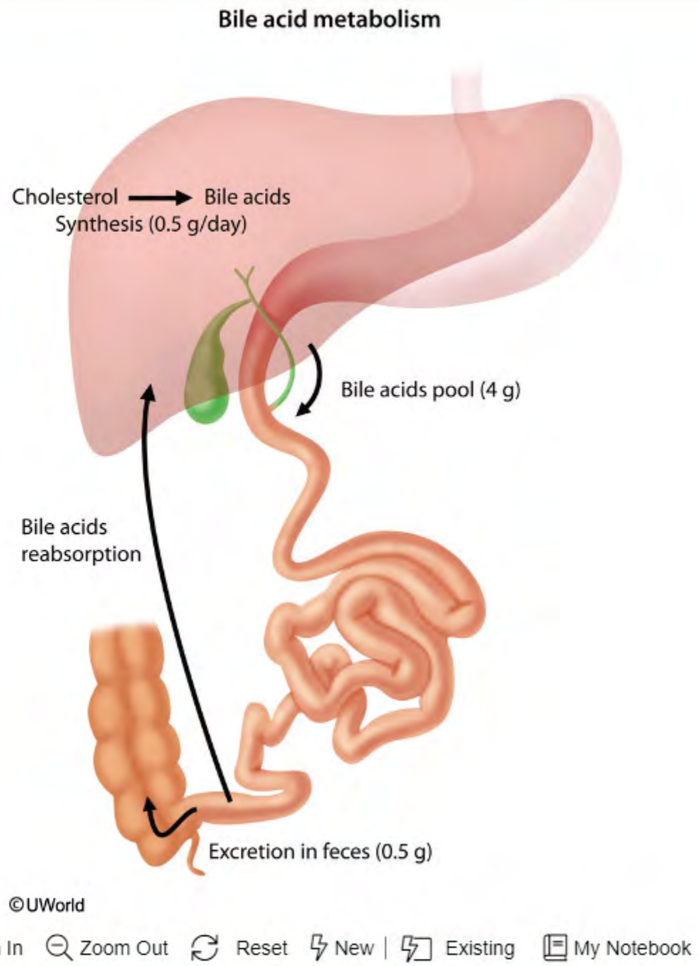

Zoom In | Zoom Out | Reset | New | Existing | My Notebook

Cholesterol → Bile acids
Synthesis (0.5 g/day)

https://t.me/USMLEWorldStep1

©UWorld

Bile acids are synthesized in the liver from cholesterol catabolism. Bile enters the duodenum through gallbladder contraction. Bile acids are primarily absorbed in the terminal ileum, with the small amount that remains unabsorbed being excreted in the stool (this amount is matched by bile acid synthesis).

Statins are the first-line therapy for most patients with hypercholesterolemia. These drugs competitively **inhibit HMG CoA reductase**, the enzyme responsible for the conversion of HMG CoA to mevalonate (ie, the rate-limiting step in hepatic cholesterol synthesis). This inhibition **decreases hepatic cholesterol synthesis**. The resulting upregulation of LDL receptors causes increased uptake of LDL from the circulation. Statins are very effective in reducing LDL cholesterol. Statins' effects on triglyceride and HDL levels are comparatively modest.

Bile acid–binding resins (ie, bile acid sequestrants) work by binding bile acids in the gastrointestinal tract, thereby interfering with the enterohepatic circulation of bile acids and causing increased bile acid excretion. This results in hepatic **synthesis of new bile acids**, a process that consumes liver cholesterol stores. Hepatic uptake of LDL from the circulation is increased for continued bile acid synthesis. Bile acid production and secretion are increased by 10-fold due to this interruption of the enterohepatic circulation of bile acids. Hepatic cholesterol reduction is an activating factor for HMG CoA reductase and subsequently results in **increased hepatic cholesterol synthesis**. This effect can be blocked with the addition of a statin drug to the treatment regimen, leading to a greater reduction in LDL levels than with use of either drug alone (synergistic action).

Educational objective:
Simvastatin decreases hepatic cholesterol production, while cholestyramine increases hepatic cholesterol and bile acid synthesis. Combination therapy results in a synergistic reduction in plasma LDL level.

References

- Overview of pharmacologic therapy for the treatment of dyslipidemia.

Pharmacology	Gastrointestinal & Nutrition	Dyslipidemia
Subject	System	Topic

Copyright © UWorld. All rights reserved.

https://t.me/USMLEWorldStep1

A 28-year-old man comes to the emergency department due to progressive abdominal pain. Although he has had mild abdominal cramps in the past, he has never before experienced anything this severe. The patient has 8-10 watery stools a day, weight loss, fatigue, and lethargy. Temperature is 38.3 C (100.9 F), blood pressure is 125/82 mm Hg, pulse is 95/min, and respirations are 14/min. The abdomen is tender to palpation without rebound or guarding. Abdominal CT scan reveals inflammatory changes affecting the ascending colon, sigmoid colon, and terminal ileum. Intestinal biopsy reveals the following:

Effective treatment of this patient's condition could be achieved by targeting which of the following molecules?

- A. BCR-ABL protein tyrosine kinase
- B. CD20 lymphocyte antigen
- C. mTOR protein kinase
- D. Programmed cell death-1 protein
- E. Tumor necrosis factor-alpha

Submit

https://t.me/USMLEWorldStep1

A 28-year-old man comes to the emergency department due to progressive abdominal pain. Although he has had
mild al
watery
mm Hg
guardi
termin

Exhibit Display

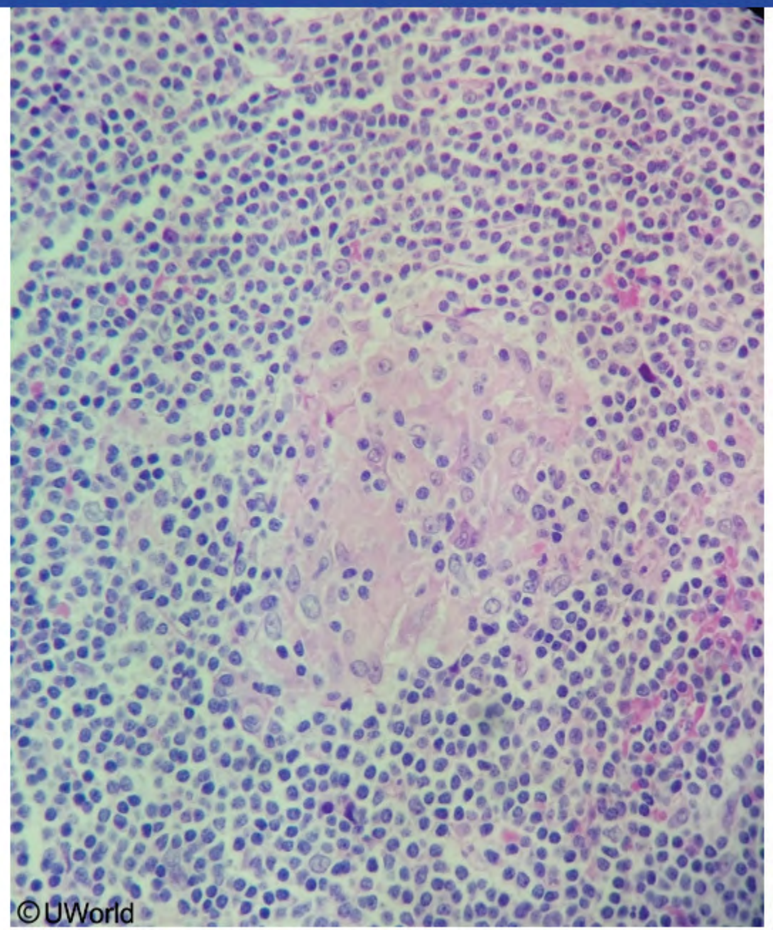

Zoom In Zoom Out Reset New | Existing My Notebook

https://t.me/USMLEWorldStep1

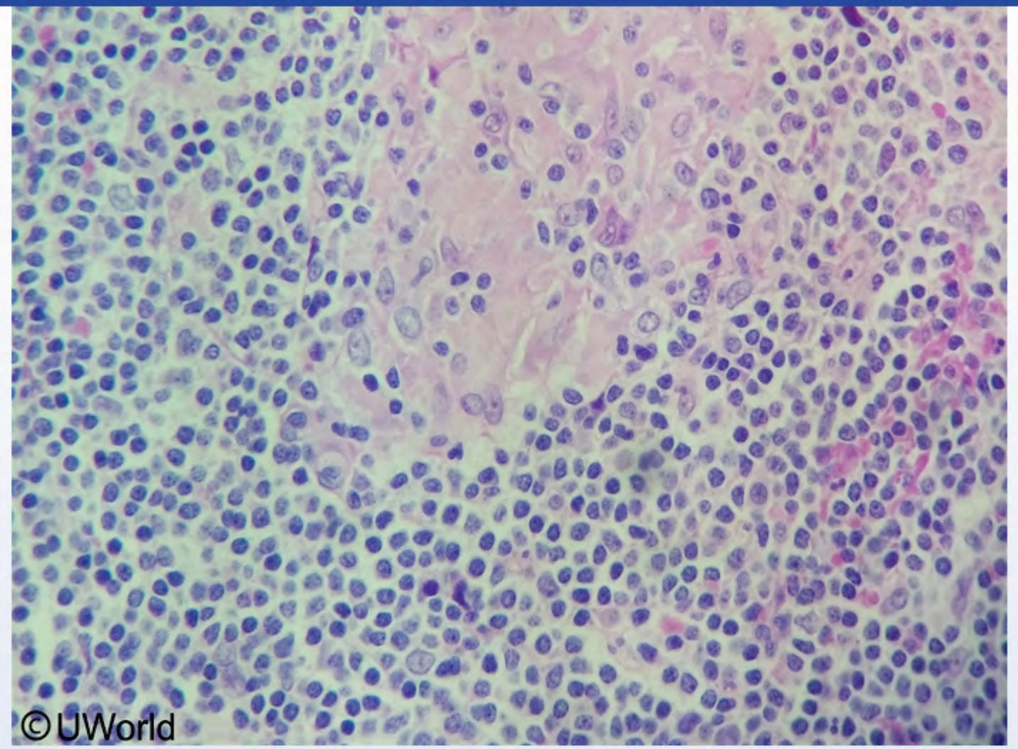

Effective treatment of this patient's condition could be achieved by targeting which of the following molecules?

- A. BCR-ABL protein tyrosine kinase
- B. CD20 lymphocyte antigen
- C. mTOR protein kinase
- D. Programmed cell death-1 protein
- E. Tumor necrosis factor-alpha

Submit

https://t.me/USMLEWorldStep1

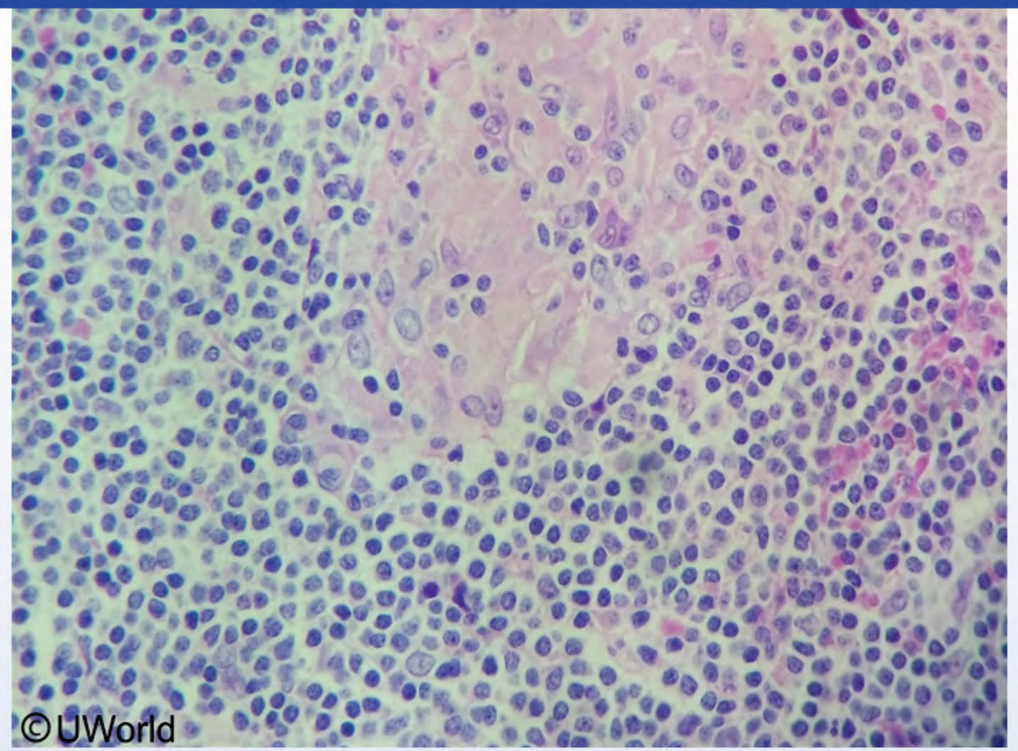

Effective treatment of this patient's condition could be achieved by targeting which of the following molecules?

- A. BCR-ABL protein tyrosine kinase (3%)
- ✕ B. CD20 lymphocyte antigen (9%)
- C. mTOR protein kinase (6%)
- D. Programmed cell death-1 protein (3%)
- ✓ E. Tumor necrosis factor-alpha (77%)

Incorrect
Correct answer
E

77%
Answered correctly

10 secs
Time Spent

2023
Version

https://t.me/USMLEWorldStep1

Explanation

Crohn disease	
Involvement	• Extending from the mouth to the anus (mostly ileum & colon) • Rectum spared • Perianal disease • Skip lesions
Microscopy	• Noncaseating granulomas
Gross findings	• Transmural inflammation • Linear mucosal ulcerations • Cobblestoning • Creeping fat
Clinical manifestations	• Diarrhea (bloody if colitis)
Intestinal complications	• Fistulae • Strictures (bowel obstruction) • Abscesses

This patient with recurrent abdominal pain, diarrhea, weight loss, and low-grade fevers has inflammatory changes of the colon and terminal ileum. In association with the characteristic intestinal biopsy findings, this presentation is consistent with **Crohn disease** (CD). CD is an inflammatory bowel disease that causes **patchy inflammation** throughout the gastrointestinal (GI) tract but spares the rectum; patients typically have segments of normal bowel interspersed with areas of disease (skip lesions).

The presence of noncaseating granulomas on intestinal biopsy is highly suggestive of CD. These lesions are characterized by the accumulation of epithelioid macrophages that fuse to form multinucleated cells surrounded by a band of lymphocytes. Other characteristic histopathologic findings in CD include inflammation involving the entire thickness of the intestinal wall (transmural inflammation), distortion of normal mucosal architecture, and

https://t.me/USMLEWorldStep1

Intestinal complications	• Strictures (bowel obstruction) • Abscesses

This patient with recurrent abdominal pain, diarrhea, weight loss, and low-grade fevers has inflammatory changes of the colon and terminal ileum. In association with the characteristic intestinal biopsy findings, this presentation is consistent with **Crohn disease** (CD). CD is an inflammatory bowel disease that causes **patchy inflammation** throughout the gastrointestinal (GI) tract but spares the rectum; patients typically have segments of normal bowel interspersed with areas of disease (skip lesions).

The presence of noncaseating granulomas on intestinal biopsy is highly suggestive of CD. These lesions are characterized by the accumulation of epithelioid macrophages that fuse to form multinucleated cells surrounded by a band of lymphocytes. Other characteristic histopathologic findings in CD include inflammation involving the entire thickness of the intestinal wall (transmural inflammation), distortion of normal mucosal architecture, and Paneth cell metaplasia.

Tumor necrosis factor-alpha (TNF-α), an inflammatory cytokine produced by macrophages, plays a central role in the pathogenesis of CD. It **promotes intestinal inflammation** by inducing lymphocyte proliferation, enhancing migration of neutrophils into the GI tract, and stimulating macrophage activity. Several TNF-α inhibitors (eg, infliximab, adalimumab) are used as first-line therapy in the treatment of CD.

(Choice A) Chronic myeloid leukemia (CML) occurs from a translocation between chromosomes 9 and 22, leading to creation of the BCR-ABL (fusion) protein tyrosine kinase. Imatinib, a direct inhibitor of BCR-ABL, is effective for CML but not for CD.

(Choice B) CD20 antigen is specific to B lymphocytes. Rituximab, a monoclonal antibody directed at CD20, results in B cell depletion. It is used in multiple autoimmune disorders (eg, rheumatoid arthritis) but not CD.

(Choice C) mTOR (mammalian target of rapamycin) is a stimulator of cell growth and proliferation. Sirolimus, an mTOR inhibitor, is used in patients with solid organ transplants to prevent allograft rejection.

(Choice D) Programmed cell death-1 (PD-1) is an immune checkpoint molecule that downregulates the immune response. PD-1 inhibitors (eg, nivolumab, pembrolizumab) are cancer immunotherapy drugs used to stimulate the immune response against malignant cells.

https://t.me/USMLEWorldStep1

interspersed with areas of disease (skip lesions).

The presence of noncaseating granulomas on intestinal biopsy is highly suggestive of CD. These lesions are characterized by the accumulation of epithelioid macrophages that fuse to form multinucleated cells surrounded by a band of lymphocytes. Other characteristic histopathologic findings in CD include inflammation involving the entire thickness of the intestinal wall (transmural inflammation), distortion of normal mucosal architecture, and Paneth cell metaplasia.

Tumor necrosis factor-alpha (TNF-α), an inflammatory cytokine produced by macrophages, plays a central role in the pathogenesis of CD. It **promotes intestinal inflammation** by inducing lymphocyte proliferation, enhancing migration of neutrophils into the GI tract, and stimulating macrophage activity. Several TNF-α inhibitors (eg, infliximab, adalimumab) are used as first-line therapy in the treatment of CD.

(Choice A) Chronic myeloid leukemia (CML) occurs from a translocation between chromosomes 9 and 22, leading to creation of the BCR-ABL (fusion) protein tyrosine kinase. Imatinib, a direct inhibitor of BCR-ABL, is effective for CML but not for CD.

(Choice B) CD20 antigen is specific to B lymphocytes. Rituximab, a monoclonal antibody directed at CD20, results in B cell depletion. It is used in multiple autoimmune disorders (eg, rheumatoid arthritis) but not CD.

(Choice C) mTOR (mammalian target of rapamycin) is a stimulator of cell growth and proliferation. Sirolimus, an mTOR inhibitor, is used in patients with solid organ transplants to prevent allograft rejection.

(Choice D) Programmed cell death-1 (PD-1) is an immune checkpoint molecule that downregulates the immune response. PD-1 inhibitors (eg, nivolumab, pembrolizumab) are cancer immunotherapy drugs used to stimulate the immune response against malignant cells.

Educational objective:
Crohn disease is an inflammatory bowel disorder that causes patchy inflammation throughout the gastrointestinal tract. Characteristic histopathologic findings include noncaseating granulomas, transmural inflammation, and Paneth cell metaplasia. Tumor necrosis factor-alpha (TNF-α), a cytokine produced by macrophages, plays a central role in the pathogenesis of CD; anti–TNF-α agents (eg, infliximab, adalimumab) are often used as first-line therapy.

References

https://t.me/USMLEWorldStep1

Clinical manifestations	• Diarrhea (bloody if colitis)

Exhibit Display

Crohn disease

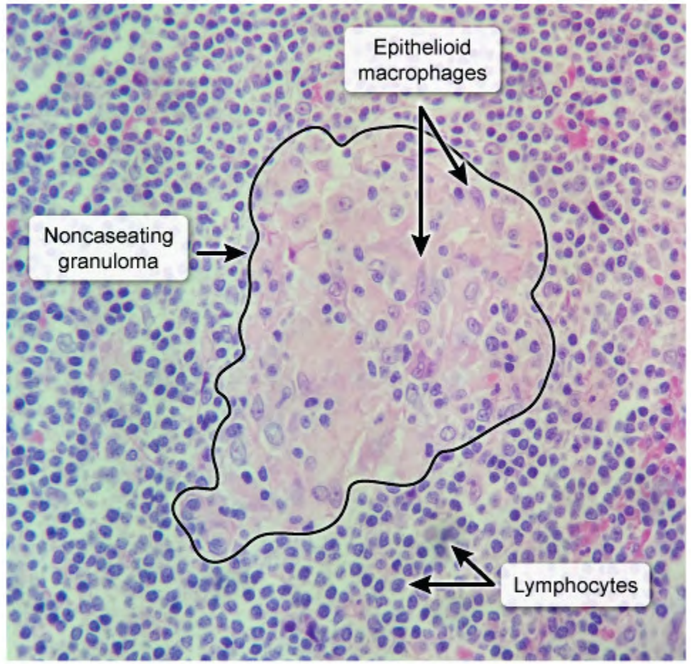

©UWorld

Zoom In | Zoom Out | Reset | New | Existing | My Notebook

This p
of the
consis
throug
intersp

The pr
charac
a banc
entire
Panetl

Tumor
in the
migrat
inflixim

(Choic
to crea
CML b

(Choic
results

(Choic
mTOR inhibitor, is used in patients with solid organ transplants to prevent allograft rejection.

https://t.me/USMLEWorldStep1

A 55-year-old woman comes to the emergency department with nausea, fever, fatigue, and anorexia. She returned a week ago from a trip to Mexico, where she underwent an emergency cholecystectomy without complications. Her temperature is 38.3 C (101 F), blood pressure is 100/60 mm Hg, pulse is 90/min, and respirations are 12/min. The patient is alert and answers questions but appears extremely weak and slightly icteric. She has no other medical problems and takes no medications. She does not use tobacco, alcohol, or illicit drugs. The patient is admitted to the hospital, but her condition worsens and she dies 2 days later. Postmortem viral serologies are negative. Gross examination of the liver on autopsy is shown in the image below.

Displayed with permission from Springer Healthcare Ltd. © Copyright 2006 by Current Medicine

Which of the following additional findings would have most likely been found in this patient?

- A. Decreased serum albumin level
- B. Distended abdominal veins and ascites
- C. Normal alanine aminotransferase level
- D. Palmar erythema
- E. Prolonged prothrombin time
- F. Splenomegaly

Submit

https://t.me/USMLEWorldStep1

A 55-year-old woman comes to the emergency department with nausea, fever, fatigue, and anorexia. She returned
a week
Her te
The pa
medica
admitt
negati

Which

Submit

Exhibit Display

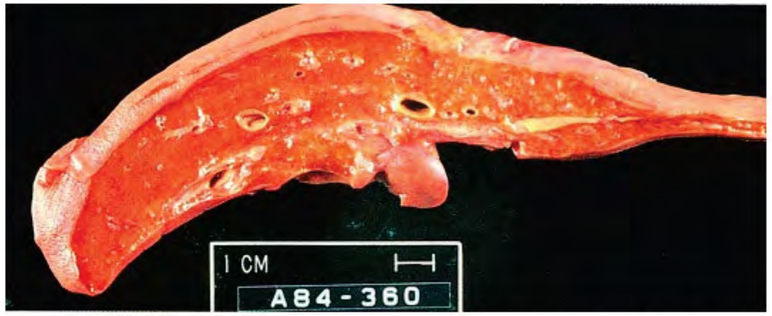

Displayed with permission from Springer Healthcare Ltd. © Copyright 2006 by Current Medicine

Zoom In Zoom Out Reset New | Existing My Notebook

https://t.me/USMLEWorldStep1

A 55-year-old woman comes to the emergency department with nausea, fever, fatigue, and anorexia. She returned a week ago from a trip to Mexico, where she underwent an emergency cholecystectomy without complications. Her temperature is 38.3 C (101 F), blood pressure is 100/60 mm Hg, pulse is 90/min, and respirations are 12/min. The patient is alert and answers questions but appears extremely weak and slightly icteric. She has no other medical problems and takes no medications. She does not use tobacco, alcohol, or illicit drugs. The patient is admitted to the hospital, but her condition worsens and she dies 2 days later. Postmortem viral serologies are negative. Gross examination of the liver on autopsy is shown in the image below.

Displayed with permission from Springer Healthcare Ltd. © Copyright 2006 by Current Medicine

Which of the following additional findings would have most likely been found in this patient?

- A. Decreased serum albumin level (17%)
- B. Distended abdominal veins and ascites (15%)
- ✗ C. Normal alanine aminotransferase level (15%)
- D. Palmar erythema (6%)
- ✓ E. Prolonged prothrombin time (32%)
- F. Splenomegaly (12%)

Incorrect
Correct answer

32%
Answered correctly

12 secs
Time Spent

2023
Version

https://t.me/USMLEWorldStep1

Explanation

This patient presents after a recent surgery with signs and symptoms consistent with **drug-induced liver injury**, most likely due to inhaled anesthetic use. **Inhaled anesthetic hepatotoxicity** is most frequently associated with halothane, which remains one of the most commonly used inhaled anesthetics worldwide. In the United States, halothane has been largely replaced with other halogenated anesthetics, such as enflurane, isoflurane, desflurane, and sevoflurane. Although these agents are safer than halothane, there have been reports of associated hepatotoxicity.

Halogenated inhaled anesthetics predominantly cause a **hepatocellular pattern** of liver injury. This can range from mild asymptomatic aminotransferase elevation to **fulminant hepatitis** with a 50% fatality rate. In severe cases, extensive hepatocellular damage causes the liver to rapidly atrophy and appear **shrunken** on autopsy. Histologically, widespread centrilobular necrosis and inflammation of the portal tracts and parenchyma are observed, making the condition indistinguishable from fulminant viral hepatitis. The underlying mechanism is thought to be a hypersensitivity reaction to the drug that causes an immune-mediated attack against hepatocytes.

Patients suffering from inhaled-anesthetic hepatotoxicity typically have fever, anorexia, nausea, myalgias, arthralgias, and rash. Tender hepatomegaly (reflecting widespread liver inflammation) and jaundice can be present on physical examination. Laboratory findings typically include markedly **elevated serum aminotransferase levels, prolonged prothrombin time**, leukocytosis, and eosinophilia. The prolonged prothrombin time is due to failure of hepatic synthetic function and deficiency of factor VII (which has the shortest half-life of all the procoagulant factors).

(Choice A) Decreased serum albumin levels are commonly seen in patients with chronic, end-stage liver disease as the remaining hepatocytes have reduced functionality. However, acute liver injury presents with normal albumin levels due to the long half-life of albumin (~20 days).

(Choices B and D) Distended abdominal veins with ascites and palmar erythema are usually seen in patients with end-stage liver disease (eg, cirrhosis). These findings are not associated with acute hepatic failure.

(Choice C) A markedly elevated alanine aminotransferase level would be expected with fulminant hepatic failure.

https://t.me/USMLEWorldStep1

and sevoflurane. Although these agents are safer than halothane, there have been reports of associated hepatotoxicity.

Halogenated inhaled anesthetics predominantly cause a **hepatocellular pattern** of liver injury. This can range from mild asymptomatic aminotransferase elevation to **fulminant hepatitis** with a 50% fatality rate. In severe cases, extensive hepatocellular damage causes the liver to rapidly atrophy and appear **shrunken** on autopsy. Histologically, widespread centrilobular necrosis and inflammation of the portal tracts and parenchyma are observed, making the condition indistinguishable from fulminant viral hepatitis. The underlying mechanism is thought to be a hypersensitivity reaction to the drug that causes an immune-mediated attack against hepatocytes.

Patients suffering from inhaled-anesthetic hepatotoxicity typically have fever, anorexia, nausea, myalgias, arthralgias, and rash. Tender hepatomegaly (reflecting widespread liver inflammation) and jaundice can be present on physical examination. Laboratory findings typically include markedly **elevated serum aminotransferase levels, prolonged prothrombin time**, leukocytosis, and eosinophilia. The prolonged prothrombin time is due to failure of hepatic synthetic function and deficiency of factor VII (which has the shortest half-life of all the procoagulant factors).

(Choice A) Decreased serum albumin levels are commonly seen in patients with chronic, end-stage liver disease as the remaining hepatocytes have reduced functionality. However, acute liver injury presents with normal albumin levels due to the long half-life of albumin (~20 days).

(Choices B and D) Distended abdominal veins with ascites and palmar erythema are usually seen in patients with end-stage liver disease (eg, cirrhosis). These findings are not associated with acute hepatic failure.

(Choice C) A markedly elevated alanine aminotransferase level would be expected with fulminant hepatic failure.

(Choice F) Splenomegaly develops secondary to portal hypertension and can be seen in cirrhotic patients. It is not associated with acute hepatitis.

Educational objective:
Inhaled anesthetics, such as halothane, can be associated with a highly lethal fulminant hepatitis that cannot be distinguished histologically from acute viral hepatitis. Patients have significantly elevated aminotransferase levels due to massive hepatocellular injury and a prolonged prothrombin time due to failure of hepatic synthetic function.

References

https://t.me/USMLEWorldStep1

A 53-year-old man comes to the physician with progressively worsening anorexia and abdominal discomfort. He has lost 14 kg (31 lb) since the onset of his symptoms about 4 months ago. Physical examination demonstrates nontender hepatomegaly. Laboratory studies show an elevated serum alkaline phosphatase level and a marginally elevated alanine aminotransferase level. A CT scan of the abdomen with oral and intravenous contrast is shown below.

Which of the following is the most likely diagnosis?

- A. Hepatic adenoma
- B. Hepatic angiosarcoma
- C. Hepatoblastoma
- D. Hepatocellular carcinoma
- E. Intrahepatic cholangiocarcinoma
- F. Metastatic liver disease

Submit

https://t.me/USMLEWorldStep1

A 53-year-old man comes to the physician with progressively worsening anorexia and abdominal discomfort. He has lo
nonter
elevat
below.

Exhibit Display

Zoom In | Zoom Out | Reset | New | Existing | My Notebook

Which

F. Metastatic liver disease

https://t.me/USMLEWorldStep1

nontender hepatomegaly. Laboratory studies show an elevated serum alkaline phosphatase level and a marginally elevated alanine aminotransferase level. A CT scan of the abdomen with oral and intravenous contrast is shown below.

Which of the following is the most likely diagnosis?

- A. Hepatic adenoma (1%)
- ✗ B. Hepatic angiosarcoma (3%)
- C. Hepatoblastoma (0%)
- D. Hepatocellular carcinoma (9%)
- E. Intrahepatic cholangiocarcinoma (13%)
- ✓ F. Metastatic liver disease (71%)

Incorrect
Correct answer
F

71%
Answered correctly

14 secs
Time Spent

2023
Version

https://t.me/USMLEWorldStep1

Incorrect
Correct answer
F

71%
Answered correctly

14 secs
Time Spent

2023
Version

Exhibit Display

Expl

Liver metastases

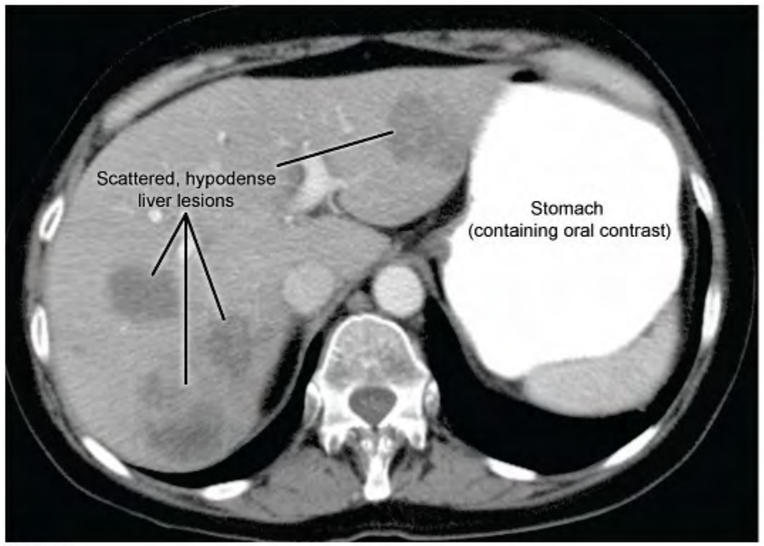

©UWorld

Zoom In | Zoom Out | Reset | New | Existing | My Notebook

The pa
metas
times
spread
functio

Patien
of the hepatic parenchyma, often resulting in marked **hepatomegaly**. The nodules frequently outgrow their
vascular supply and become centrally necrotic and umbilicated. Even with significant metastatic involvement

https://t.me/USMLEWorldStep1

The patient's contrast-enhanced CT scan shows **multiple hypodense masses** in the liver (arrows) consistent with **metastatic liver disease**. Metastases are the most common malignant neoplasms of the adult liver and are 20 times more common than hepatocellular carcinoma. The liver is the second most common site of metastatic spread (after the lymph nodes) because of its large size, dual blood supply, high perfusion rate, and the filtration function of Kupffer cells.

Patients with liver metastases typically have multiple nodules throughout the liver that may replace more than 80% of the hepatic parenchyma, often resulting in marked **hepatomegaly**. The nodules frequently outgrow their vascular supply and become centrally necrotic and umbilicated. Even with significant metastatic involvement, patients may have no clinical or laboratory signs suggestive of hepatic insufficiency. However, once the majority of the liver parenchyma is destroyed or the major bile ducts become obstructed with tumor, patients tend to present with jaundice or **abnormal hepatic enzymes** (eg, elevated aminotransferases, alkaline phosphatase).

(Choice A) Hepatic adenomas are uncommon, benign epithelial tumors of the liver that usually arise as a solitary mass in the right hepatic lobe. They are strongly associated with the use of oral contraceptives and anabolic steroids and are usually diagnosed in patients with upper abdominal pain or detected incidentally on imaging studies. They may rupture and cause intraabdominal hemorrhage.

(Choice B) Hepatic angiosarcomas are associated with recent or remote exposure to vinyl chloride, arsenic, or Thorotrast. This tumor is extremely aggressive and is associated with a poor prognosis, as most patients die within a year.

(Choice C) Hepatoblastoma is the most common liver neoplasm of children and is associated with familial adenomatous polyposis and Beckwith-Wiedemann syndromes. This neoplasm is usually fatal within a few years if not surgically resected.

(Choice D) Hepatocellular carcinoma can present unifocally, multifocally, or as a diffusely infiltrative cancer. It is more common in older patients with a history of cirrhosis or infection with hepatitis B or C.

(Choice E) Cholangiocarcinoma is a rare malignancy that arises from the intra- and extrahepatic bile ducts. Intrahepatic cholangiocarcinoma appears grossly as a treelike mass that grows along the biliary system, typically resulting in extensive intrahepatic metastasis. Risk factors include primary sclerosing cholangitis, fibropolycystic

https://t.me/USMLEWorldStep1

of the hepatic parenchyma, often resulting in marked **hepatomegaly**. The nodules frequently outgrow their vascular supply and become centrally necrotic and umbilicated. Even with significant metastatic involvement, patients may have no clinical or laboratory signs suggestive of hepatic insufficiency. However, once the majority of the liver parenchyma is destroyed or the major bile ducts become obstructed with tumor, patients tend to present with jaundice or **abnormal hepatic enzymes** (eg, elevated aminotransferases, alkaline phosphatase).

(Choice A) Hepatic adenomas are uncommon, benign epithelial tumors of the liver that usually arise as a solitary mass in the right hepatic lobe. They are strongly associated with the use of oral contraceptives and anabolic steroids and are usually diagnosed in patients with upper abdominal pain or detected incidentally on imaging studies. They may rupture and cause intraabdominal hemorrhage.

(Choice B) Hepatic angiosarcomas are associated with recent or remote exposure to vinyl chloride, arsenic, or Thorotrast. This tumor is extremely aggressive and is associated with a poor prognosis, as most patients die within a year.

(Choice C) Hepatoblastoma is the most common liver neoplasm of children and is associated with familial adenomatous polyposis and Beckwith-Wiedemann syndromes. This neoplasm is usually fatal within a few years if not surgically resected.

(Choice D) Hepatocellular carcinoma can present unifocally, multifocally, or as a diffusely infiltrative cancer. It is more common in older patients with a history of cirrhosis or infection with hepatitis B or C.

(Choice E) Cholangiocarcinoma is a rare malignancy that arises from the intra- and extrahepatic bile ducts. Intrahepatic cholangiocarcinoma appears grossly as a treelike mass that grows along the biliary system, typically resulting in extensive intrahepatic metastasis. Risk factors include primary sclerosing cholangitis, fibropolycystic liver disease, and infection with liver flukes in endemic areas. The prognosis is very poor.

Educational objective:
Malignant hepatic lesions most often represent metastasis from another primary site (eg, breast, lung, colon); primary liver neoplasms (eg, hepatocellular carcinoma) are much less common.

Pathology	Gastrointestinal & Nutrition	Metastatic liver disease
Subject	System	Topic

https://t.me/USMLEWorldStep1

A 3-hour-old girl is being evaluated in the neonatal intensive care unit due to respiratory distress and an episode of cyanosis. Endotracheal and orogastric tubes are inserted. An umbilical venous catheter is placed. Chest radiograph is shown in the image below:

Which of the following is most likely present in this patient?

- A. Bilateral obstruction of nares
- B. Blind-ending esophageal pouch
- C. Defect in the diaphragm
- D. Parallel pulmonary and systemic circulations
- E. Right ventricular outflow tract obstruction

Submit

https://t.me/USMLEWorldStep1

A 3-hour-old girl is being evaluated in the neonatal intensive care unit due to respiratory distress and an episode of cyano
radiog

Which

Sub

Exhibit Display

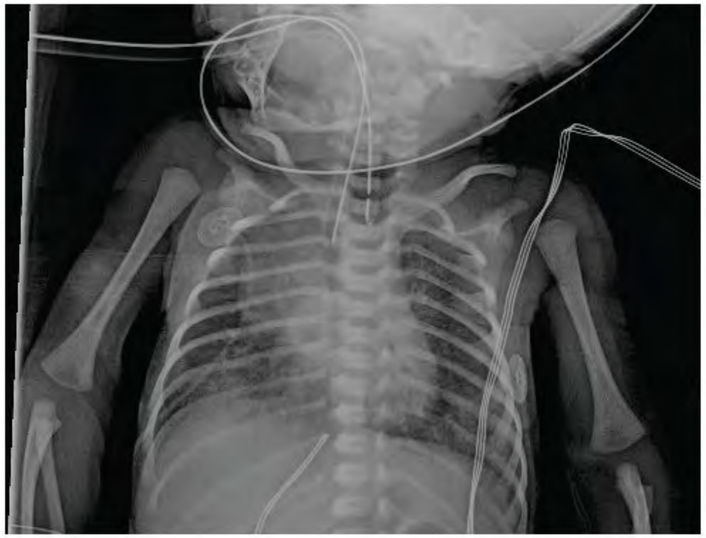

Zoom In Zoom Out Reset New | Existing My Notebook

https://t.me/USMLEWorldStep1

A 3-hour-old girl is being evaluated in the neonatal intensive care unit due to respiratory distress and an episode of cyanosis. Endotracheal and orogastric tubes are inserted. An umbilical venous catheter is placed. Chest radiograph is shown in the image below:

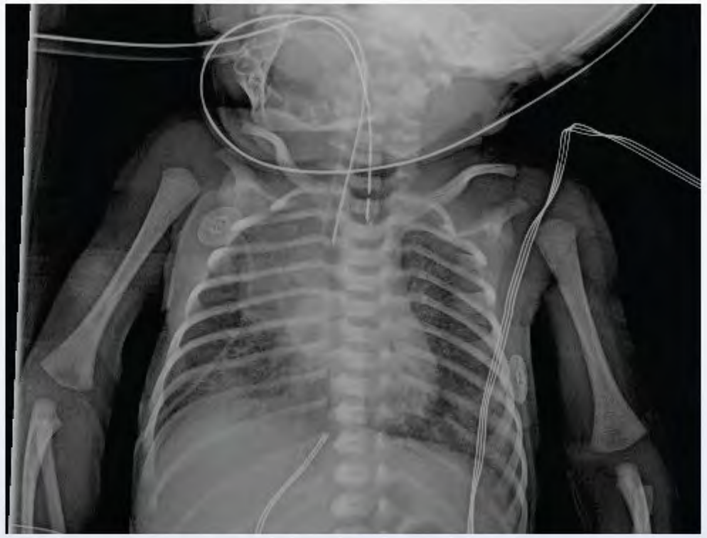

Which of the following is most likely present in this patient?

- ✗ A. Bilateral obstruction of nares (1%)
- ✓ B. Blind-ending esophageal pouch (65%)
- C. Defect in the diaphragm (15%)
- D. Parallel pulmonary and systemic circulations (7%)
- E. Right ventricular outflow tract obstruction (9%)

Incorrect
Correct answer
B

65%
Answered correctly

07 secs
Time Spent

2023
Version

https://t.me/USMLEWorldStep1

Exhibit Display

Tracheoesophageal fistula

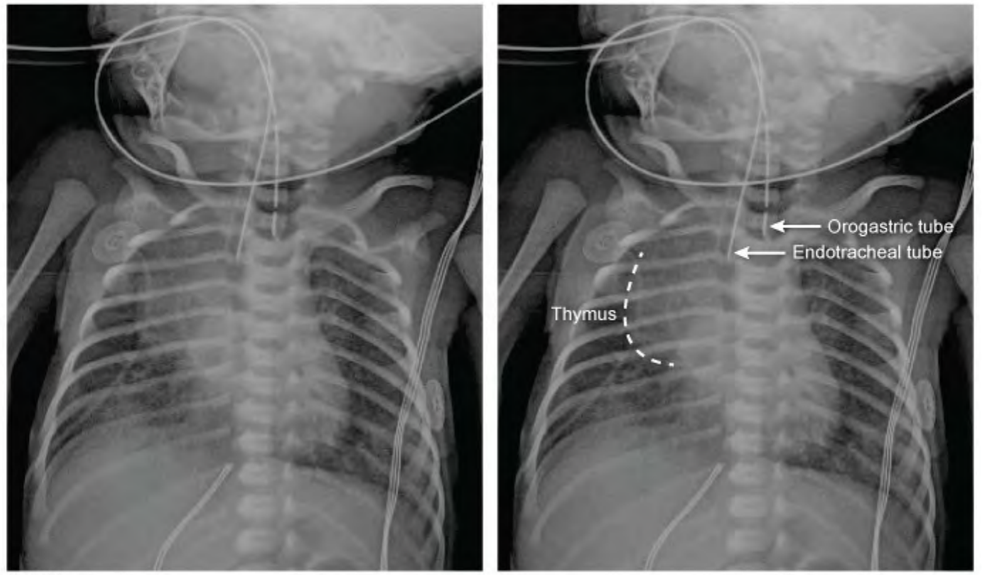

©UWorld

Zoom In | Zoom Out | Reset | New | Existing | My Notebook

This p
consis

Almos
resulti
arrang
distal e
VACTE

Prenat
Immed

attempts due to aspiration of breast milk/formula from the esophageal pouch into the proximal trachea. In addition, refluxed digestive fluids from the stomach can enter the trachea through the fistula, resulting in **respiratory**

https://t.me/USMLEWorldStep1

This patient's x-ray shows the distal end of the orogastric tube at the level of the proximal esophagus, a finding consistent with **esophageal atresia**, or a blind-ending esophageal pouch.

Almost all cases of esophageal atresia are associated with a tracheoesophageal fistula, a congenital anomaly resulting from improper division of the foregut during early gestation. These defects can present in various arrangements, the most common of which is proximal esophageal atresia with a fistula between the trachea and distal esophagus. The condition is often isolated, but up to half of patients have associated anomalies (eg, VACTERL association).

Prenatal ultrasonography usually reveals **polyhydramnios** because the fetus cannot swallow amniotic fluid. Immediately after birth, neonates exhibit excessive drooling as well as coughing and **regurgitation with feeding** attempts due to aspiration of breast milk/formula from the esophageal pouch into the proximal trachea. In addition, refluxed digestive fluids from the stomach can enter the trachea through the fistula, resulting in **respiratory distress** and episodic cyanosis.

Inability to pass a feeding tube into the stomach and the presence of the **enteric tube** tip in the **proximal esophagus** on x-ray are diagnostic.

(Choice A) Bilateral choanal atresia, or bony/membranous obstruction of the posterior nasal cavity, presents with cyanosis during feeding that improves with crying. Inability to pass a catheter through the nares (eg, nasogastric tube) is characteristic, but an orogastric tube would pass from the mouth through the esophagus and into the stomach.

(Choice C) Congenital diaphragmatic hernia presents with cyanosis and respiratory distress immediately after birth. However, characteristic x-ray findings include bowel in the thorax, a displaced cardiac silhouette, and a gasless abdomen.

(Choices D and E) Tetralogy of Fallot (TOF), a defect that includes right ventricular outflow tract obstruction, and transposition of the great arteries (TGA), or parallel pulmonary and systemic circulations, often present with neonatal cyanosis. However, an enteric tube would pass into the stomach with either condition.

Educational objective:
Tracheoesophageal fistula with esophageal atresia typically presents in the immediate newborn period with

https://t.me/USMLEWorldStep1

Almost all cases of esophageal atresia are associated with a tracheoesophageal fistula, a congenital anomaly resulting from improper division of the foregut during early gestation. These defects can present in various arrangements, the most common of which is proximal esophageal atresia with a fistula between the trachea and distal esophagus. The condition is often isolated, but up to half of patients have associated anomalies (eg, VACTERL association).

Prenatal ultrasonography usually reveals **polyhydramnios** because the fetus cannot swallow amniotic fluid. Immediately after birth, neonates exhibit excessive drooling as well as coughing and **regurgitation with feeding** attempts due to aspiration of breast milk/formula from the esophageal pouch into the proximal trachea. In addition, refluxed digestive fluids from the stomach can enter the trachea through the fistula, resulting in **respiratory distress** and episodic cyanosis.

Inability to pass a feeding tube into the stomach and the presence of the **enteric tube** tip in the **proximal esophagus** on x-ray are diagnostic.

(Choice A) Bilateral choanal atresia, or bony/membranous obstruction of the posterior nasal cavity, presents with cyanosis during feeding that improves with crying. Inability to pass a catheter through the nares (eg, nasogastric tube) is characteristic, but an orogastric tube would pass from the mouth through the esophagus and into the stomach.

(Choice C) Congenital diaphragmatic hernia presents with cyanosis and respiratory distress immediately after birth. However, characteristic x-ray findings include bowel in the thorax, a displaced cardiac silhouette, and a gasless abdomen.

(Choices D and E) Tetralogy of Fallot (TOF), a defect that includes right ventricular outflow tract obstruction, and transposition of the great arteries (TGA), or parallel pulmonary and systemic circulations, often present with neonatal cyanosis. However, an enteric tube would pass into the stomach with either condition.

Educational objective:
Tracheoesophageal fistula with esophageal atresia typically presents in the immediate newborn period with choking/coughing with feeding. A feeding tube cannot be passed into the stomach; curling of the distal end of the enteric tube in the proximal esophagus on x-ray is diagnostic.

References

https://t.me/USMLEWorldStep1

Exhibit Display

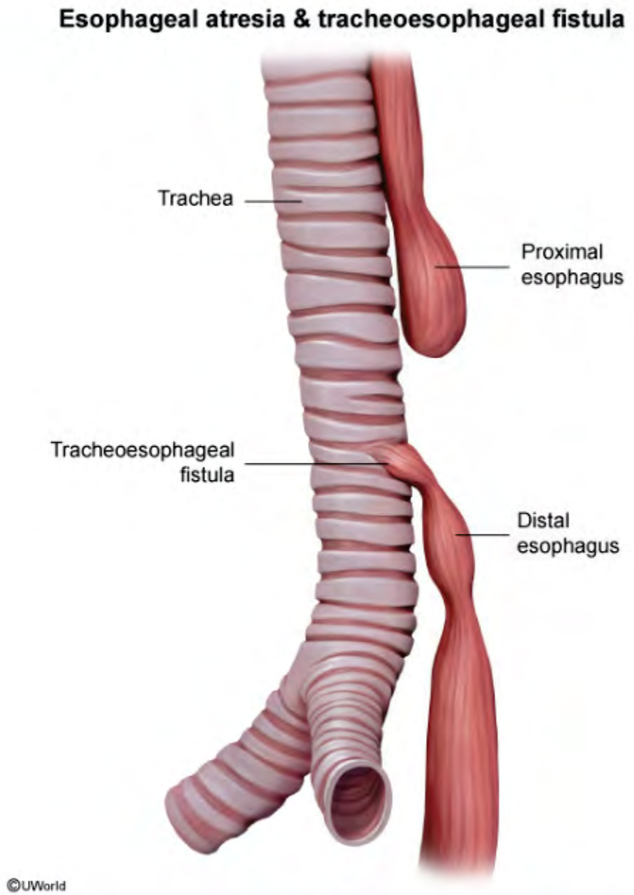

Zoom In | Zoom Out | Reset | New | Existing | My Notebook

This p
consis

Almos
resulti
arrang
distal
VACT

Prenat
Immed
attemp
refluxe
distre

Inabili
esoph

(Choi
cyanos
tube) i
stoma

(Choi
birth.
gasles

(Choices D and E) Tetralogy of Fallot (TOF), a defect that includes right ventricular outflow tract obstruction, and transposition of the great arteries (TGA), or parallel pulmonary and systemic circulations, often present with

https://t.me/USMLEWorldStep1

Exhibit Display

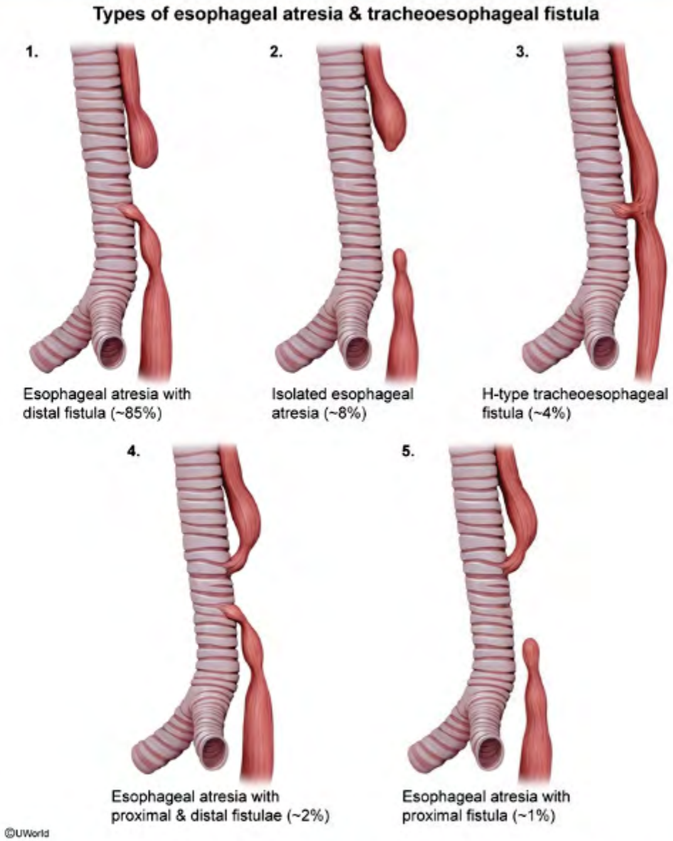

Zoom In | Zoom Out | Reset | New | Existing | My Notebook

This p
consis

Almos
resulti
arrang
distal
VACTI

Prenat
Immed
attemp
refluxe
distre

Inabili
esoph

(Choi
cyanos
tube) i
stoma

(Choi
birth.
gasless abdomen.

(Choices D and E) Tetralogy of Fallot (TOF), a defect that includes right ventricular outflow tract obstruction, and transposition of the great arteries (TGA), or parallel pulmonary and systemic circulations, often present with

https://t.me/USMLEWorldStep1

Exhibit Display

VACTERL association
V: vertebral anomaly
A: anorectal malformation
C: cardiovascular anomaly
T: tracheoesophageal fistula
E: **e**sophageal atresia
R: renal &/or radial anomaly
L: limb defect

New | Existing | My Notebook

This p
consis

Almos
resulti
arrang
distal
VACT

Prenat
Immed
attemp
refluxe
distre

Inabili
esoph

(Choi
cyanos
tube) i
stoma

(Choi
birth.
gasles

(Choices D and E) Tetralogy of Fallot (TOF), a defect that includes right ventricular outflow tract obstruction, and transposition of the great arteries (TGA), or parallel pulmonary and systemic circulations, often present with

https://t.me/USMLEWorldStep1

Exhibit Display

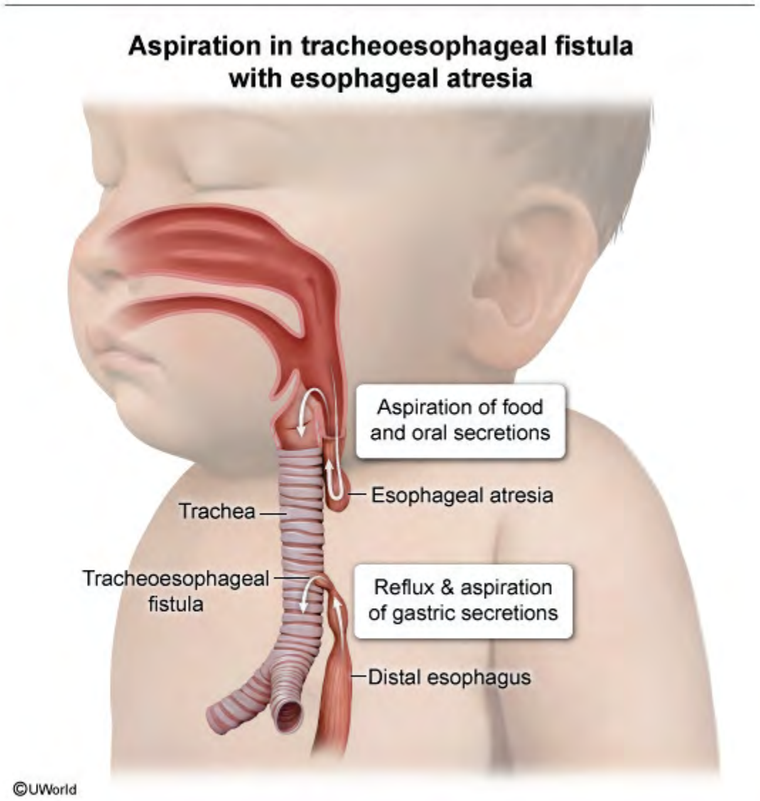

Zoom In | Zoom Out | Reset | New | Existing | My Notebook

This p
consis

Almos
resulti
arrang
distal
VACTI

Prenat
Immed
attemp
refluxe
distre

Inabili
esoph

(Choi
cyanos
tube) i
stoma

(Choi
birth.
gasles

(Choices D and E) Tetralogy of Fallot (TOF), a defect that includes right ventricular outflow tract obstruction, and transposition of the great arteries (TGA), or parallel pulmonary and systemic circulations, often present with

https://t.me/USMLEWorldStep1

Exhibit Display

Choanal atresia

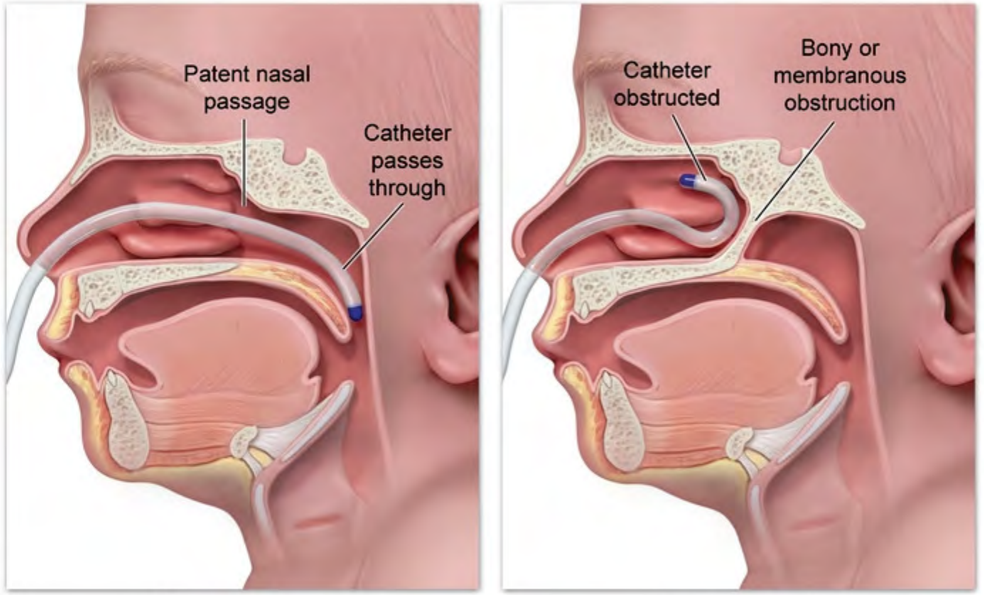

Normal anatomy **Choanal atresia**

©UWorld

Zoom In Zoom Out Reset New | Existing My Notebook

This p
consis

Almos
resulti
arrang
distal
VACTI

Prenat
Immed
attemp
refluxe
distre

Inabili
esoph

(Choi
cyanos
tube) i
stoma

(Choi
birth.
gasles

(Choices D and E) Tetralogy of Fallot (TOF), a defect that includes right ventricular outflow tract obstruction, and transposition of the great arteries (TGA), or parallel pulmonary and systemic circulations, often present with

https://t.me/USMLEWorldStep1

Exhibit Display

Congenital diaphragmatic hernia

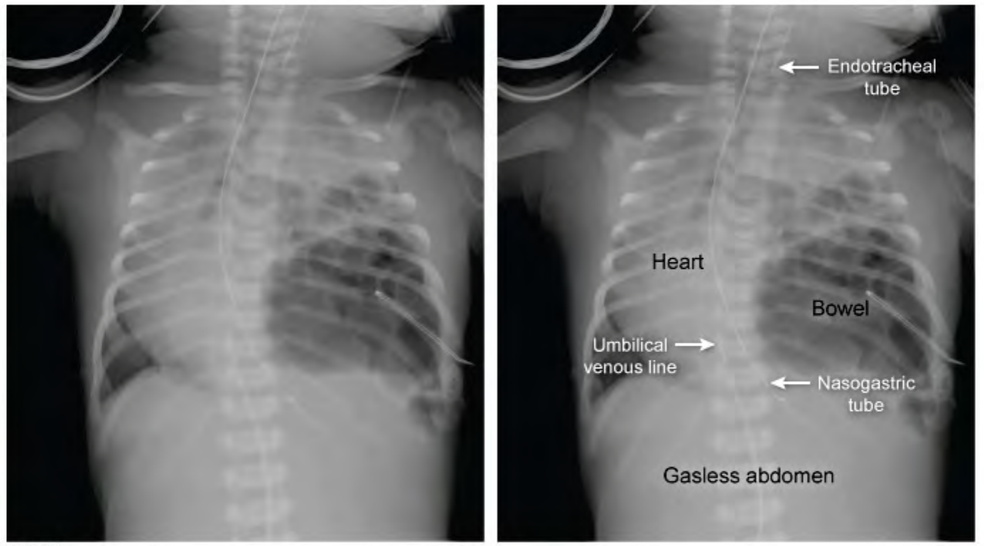

©UWorld

Zoom In | Zoom Out | Reset | New | Existing | My Notebook

This p
consis

Almos
resulti
arrang
distal
VACTI

Prenat
Immed
attemp
refluxe
distre

Inabili
esoph

(Choi
cyanos
tube) i
stoma

(Choi
birth.
gasles

(Choices D and E) Tetralogy of Fallot (TOF), a defect that includes right ventricular outflow tract obstruction, and transposition of the great arteries (TGA), or parallel pulmonary and systemic circulations, often present with

https://t.me/USMLEWorldStep1

A 40-year-old woman comes to the office due to a 6-month history of abdominal cramping and bloating associated with diarrhea. She experiences a strong urge to defecate shortly after meals and passes a small amount of stool and mucus 3 or 4 times daily, after which her cramping resolves. The patient has seen no blood in her stool and has had intermittent mild heartburn. She has had no fevers, chills, or weight loss. Medical history is significant for seasonal allergic rhinitis. Medications include only a multivitamin supplement. Vital signs and physical examination are normal. After a normal laboratory evaluation, the patient is prescribed a trial of loperamide therapy. Which of the following is the most likely primary target of this medication?

- A. Enteric secretomotor neurons
- B. Enteric serotonin receptors
- C. Enterocyte chloride channels
- D. Intestinal brush border cells
- E. Intestinal luminal bile salts
- F. Spinal mu-opioid receptors

Submit

https://t.me/USMLEWorldStep1

A 40-year-old woman comes to the office due to a 6-month history of abdominal cramping and bloating associated with diarrhea. She experiences a strong urge to defecate shortly after meals and passes a small amount of stool and mucus 3 or 4 times daily, after which her cramping resolves. The patient has seen no blood in her stool and has had intermittent mild heartburn. She has had no fevers, chills, or weight loss. Medical history is significant for seasonal allergic rhinitis. Medications include only a multivitamin supplement. Vital signs and physical examination are normal. After a normal laboratory evaluation, the patient is prescribed a trial of loperamide therapy. Which of the following is the most likely primary target of this medication?

- ✓ A. Enteric secretomotor neurons
- B. Enteric serotonin receptors
- ✗ C. Enterocyte chloride channels
- D. Intestinal brush border cells
- E. Intestinal luminal bile salts
- F. Spinal mu-opioid receptors

Incorrect
Correct answer
A

Collecting Statistics

03 secs
Time Spent

2023
Version

Explanation

This patient has chronic abdominal pain that subsides with bowel movements associated with changes in stool frequency and form (eg, diarrhea, mucus). Her normal laboratory evaluation and physical examination with no alarm symptoms (eg, weight loss, rectal bleeding) indicate that her symptoms are likely due to **diarrhea-predominant** irritable bowel syndrome (**IBS**).

For symptomatic relief of diarrhea in IBS, **loperamide** can be used. Loperamide is an **opioid agonist** that binds mu-opioid receptors on the **gastrointestinal secretomotor neurons** (ie, myenteric plexus, submucosal plexus).

https://t.me/USMLEWorldStep1

Explanation

This patient has chronic abdominal pain that subsides with bowel movements associated with changes in stool frequency and form (eg, diarrhea, mucus). Her normal laboratory evaluation and physical examination with no alarm symptoms (eg, weight loss, rectal bleeding) indicate that her symptoms are likely due to **diarrhea-predominant** irritable bowel syndrome (**IBS**).

For symptomatic relief of diarrhea in IBS, **loperamide** can be used. Loperamide is an **opioid agonist** that binds mu-opioid receptors on the **gastrointestinal secretomotor neurons** (ie, myenteric plexus, submucosal plexus). Loperamide decreases peristalsis, lengthens intestinal transit times, and reduces intestinal fluid and electrolyte secretions. It does not cross the blood-brain barrier; therefore, CNS effects are minimal **(Choice F)**.

Diphenoxylate-atropine is also used to treat diarrhea. Diphenoxylate also binds to the mu-opioid receptors of the gastrointestinal tract; however, unlike loperamide, diphenoxylate crosses the blood-brain barrier and can produce opiate-like euphoria and physical dependence. Therefore, diphenoxylate is combined with atropine, which produces adverse symptoms (eg, dry mouth, blurry vision, nausea) to prevent use in high doses.

(Choice B) Several types of serotonin receptors are present in myenteric and submucosal neurons of the gastrointestinal tract. Serotonin-3 receptor antagonists (eg, ondansetron, alosetron) exert antiemetic and antidiarrheal effects, whereas serotonin-4 receptor agonists increase colonic motility and attenuate visceral pain.

(Choice C) Lubiprostone activates chloride channels on the apical membranes of enterocytes to increase fluid secretion and intestinal transit. It is used to treat constipation-predominant IBS.

(Choice D) Lactase enzyme replacement is used to treat lactose intolerance and facilitates hydrolysis of lactose to glucose and galactose at the brush border cells of the small intestine.

(Choice E) Cholestyramine and colestipol bind bile salts in the intestinal lumen, thereby decreasing enterohepatic reuptake of bile salts. These agents are used to treat postcholecystectomy diarrhea due to excess bile salt in the colon.

Educational objective:
Loperamide is an antidiarrheal agent that acts as an agonist of mu-opioid receptors on gastrointestinal

https://t.me/USMLEWorldStep1

frequency and form (eg, diarrhea, mucus). Her normal laboratory evaluation and physical examination with no alarm symptoms (eg, weight loss, rectal bleeding) indicate that her symptoms are likely due to **diarrhea-predominant** irritable bowel syndrome (**IBS**).

For symptomatic relief of diarrhea in IBS, **loperamide** can be used. Loperamide is an **opioid agonist** that binds mu-opioid receptors on the **gastrointestinal secretomotor neurons** (ie, myenteric plexus, submucosal plexus). Loperamide decreases peristalsis, lengthens intestinal transit times, and reduces intestinal fluid and electrolyte secretions. It does not cross the blood-brain barrier; therefore, CNS effects are minimal **(Choice F)**.

Diphenoxylate-atropine is also used to treat diarrhea. Diphenoxylate also binds to the mu-opioid receptors of the gastrointestinal tract; however, unlike loperamide, diphenoxylate crosses the blood-brain barrier and can produce opiate-like euphoria and physical dependence. Therefore, diphenoxylate is combined with atropine, which produces adverse symptoms (eg, dry mouth, blurry vision, nausea) to prevent use in high doses.

(Choice B) Several types of serotonin receptors are present in myenteric and submucosal neurons of the gastrointestinal tract. Serotonin-3 receptor antagonists (eg, ondansetron, alosetron) exert antiemetic and antidiarrheal effects, whereas serotonin-4 receptor agonists increase colonic motility and attenuate visceral pain.

(Choice C) Lubiprostone activates chloride channels on the apical membranes of enterocytes to increase fluid secretion and intestinal transit. It is used to treat constipation-predominant IBS.

(Choice D) Lactase enzyme replacement is used to treat lactose intolerance and facilitates hydrolysis of lactose to glucose and galactose at the brush border cells of the small intestine.

(Choice E) Cholestyramine and colestipol bind bile salts in the intestinal lumen, thereby decreasing enterohepatic reuptake of bile salts. These agents are used to treat postcholecystectomy diarrhea due to excess bile salt in the colon.

Educational objective:
Loperamide is an antidiarrheal agent that acts as an agonist of mu-opioid receptors on gastrointestinal secretomotor neurons, resulting in decreased peristalsis, longer intestinal transit times, and reduced intestinal fluid and electrolyte secretions. It does not cross the blood-brain barrier; therefore, CNS effects are minimal.

References

https://t.me/USMLEWorldStep1

A 55-year-old man with a history of chronic pancreatitis and alcohol abuse is investigated for recent onset weight loss, decreased appetite, and worsening of chronic abdominal pain. Physical examination is significant for diffuse muscle atrophy, temporal wasting, and a mildly enlarged liver without ascites. Serum lipase and amylase are normal, and aspartate aminotransferase (AST) is mildly elevated. Abdominal imaging shows a malignant mass in the pancreas. The patient subsequently undergoes an uncomplicated subtotal pancreatectomy and returns for a postoperative nutritional assessment following hospital discharge. Which of the following tests will most likely be normal in this patient after surgery?

- A. Duodenal lipase levels after cholecystokinin stimulation
- B. Duodenal trypsin levels after cholecystokinin stimulation
- C. Intestinal D-xylose absorption
- D. Serum trypsinogen
- E. Stool neutral fat content

Submit

https://t.me/USMLEWorldStep1

A 55-year-old man with a history of chronic pancreatitis and alcohol abuse is investigated for recent onset weight loss, decreased appetite, and worsening of chronic abdominal pain. Physical examination is significant for diffuse muscle atrophy, temporal wasting, and a mildly enlarged liver without ascites. Serum lipase and amylase are normal, and aspartate aminotransferase (AST) is mildly elevated. Abdominal imaging shows a malignant mass in the pancreas. The patient subsequently undergoes an uncomplicated subtotal pancreatectomy and returns for a postoperative nutritional assessment following hospital discharge. Which of the following tests will most likely be normal in this patient after surgery?

- ✗ A. Duodenal lipase levels after cholecystokinin stimulation (6%)
- B. Duodenal trypsin levels after cholecystokinin stimulation (7%)
- ✓ C. Intestinal D-xylose absorption (68%)
- D. Serum trypsinogen (10%)
- E. Stool neutral fat content (6%)

Incorrect
Correct answer
C

68%
Answered correctly

03 secs
Time Spent

2023
Version

Explanation

The exocrine pancreas has a significant **secretory reserve**, and ≥90% of the glandular tissue must be destroyed before a patient will develop clinical malabsorption. However, this patient likely has significant loss of pancreatic tissue at baseline due to chronic pancreatitis and is at increased risk for **exocrine insufficiency**. Following partial pancreatic resection, he may develop clinically significant deficiency in any of the pancreatic digestive enzymes normally secreted into the duodenum.

Pancreatic amylases, along with salivary and brush border amylases, are required for the degradation of polysaccharides into monosaccharides, as polysaccharides cannot be absorbed by the intestinal mucosa. In

https://t.me/USMLEWorldStep1

The exocrine pancreas has a significant **secretory reserve**, and ≥90% of the glandular tissue must be destroyed before a patient will develop clinical malabsorption. However, this patient likely has significant loss of pancreatic tissue at baseline due to chronic pancreatitis and is at increased risk for **exocrine insufficiency**. Following partial pancreatic resection, he may develop clinically significant deficiency in any of the pancreatic digestive enzymes normally secreted into the duodenum.

Pancreatic amylases, along with salivary and brush border amylases, are required for the degradation of polysaccharides into monosaccharides, as polysaccharides cannot be absorbed by the intestinal mucosa. In contrast, **monosaccharides** (eg, glucose, galactose) are taken up directly by the epithelial cells of the small intestine through either sodium-dependent cotransport or facilitated diffusion. **D-xylose** is a monosaccharide that is absorbed directly without the action of pancreatic enzymes, and can be used to test for brush border absorptive function independent of pancreatic function. Intestinal D-xylose absorption can also decrease with bacterial overgrowth of the small intestine.

(Choices A and B) Patients with exocrine pancreatic insufficiency will have decreased secretion of trypsin and lipase into the duodenum following cholecystokinin (CCK) stimulation.

(Choice D) Trypsinogen is a proenzyme secreted by the exocrine pancreas into the small intestine. Small quantities are also detectable in serum. Serum trypsinogen levels are increased in acute pancreatitis but often decreased in patients with chronic pancreatitis or other forms of chronic pancreatic insufficiency.

(Choice E) The stool neutral fat (triglyceride) content is increased after pancreatic resection due to deficiency of pancreatic lipase.

Educational objective:
Polysaccharides must be degraded to monosaccharides by pancreatic and brush border amylases before they can be absorbed. Monosaccharides can be absorbed directly. D-xylose is a monosaccharide whose absorption is not affected by exocrine pancreatic insufficiency, and can be used to differentiate between pancreatic versus mucosal causes of malabsorption.

Pathophysiology Gastrointestinal & Nutrition Malabsorption

https://t.me/USMLEWorldStep1

Experimental gastric function monitoring in healthy subjects before, during and after a meal shows an initial rise, peak, and then decline in gastric acid production. Which of the following helps most to down-regulate gastric secretion after a meal?

- A. Basal secretion
- B. Cephalic phase
- C. Gastrin release
- D. Intestinal influences
- E. Receptive relaxation
- F. Postprandial alkaline tide

Submit

https://t.me/USMLEWorldStep1

Experimental gastric function monitoring in healthy subjects before, during and after a meal shows an initial rise, peak, and then decline in gastric acid production. Which of the following helps most to down-regulate gastric secretion after a meal?

- ✗ A. Basal secretion (3%)
- B. Cephalic phase (4%)
- C. Gastrin release (10%)
- ✓ D. Intestinal influences (60%)
- E. Receptive relaxation (5%)
- F. Postprandial alkaline tide (15%)

Incorrect
Correct answer
D

60%
Answered correctly

03 secs
Time Spent

2023
Version

Explanation

Classically, the stimulation of acid secretion within the stomach is separated into three phases: cephalic, gastric, and intestinal. The cephalic phase is mediated primarily by cholinergic and vagal mechanisms, and is triggered by the thought, sight, smell, and taste of food. The gastric phase is mediated by the presence of gastrin (which stimulates histamine secretion and therefore, indirectly, acid secretion), and is triggered by the chemical stimulus of food and distension of the stomach. The intestinal phase is initiated when protein-containing food enters the duodenum, but this phase plays only a minor role in stimulating gastric acid secretion.

In fact, intestinal influences are effective in down-regulating gastric acid secretion after a meal. The ileum and colon release peptide YY, which binds to receptors on the endocrine, histamine-containing cells described as enterochromaffin-like (ECLs). Such binding counteracts the cephalic and gastric phases of acid secretion by inhibiting gastrin-stimulated histamine release from ECLs. Other factors that inhibit acid secretion include

https://t.me/USMLEWorldStep1

Explanation

Classically, the stimulation of acid secretion within the stomach is separated into three phases: cephalic, gastric, and intestinal. The cephalic phase is mediated primarily by cholinergic and vagal mechanisms, and is triggered by the thought, sight, smell, and taste of food. The gastric phase is mediated by the presence of gastrin (which stimulates histamine secretion and therefore, indirectly, acid secretion), and is triggered by the chemical stimulus of food and distension of the stomach. The intestinal phase is initiated when protein-containing food enters the duodenum, but this phase plays only a minor role in stimulating gastric acid secretion.

In fact, intestinal influences are effective in down-regulating gastric acid secretion after a meal. The ileum and colon release peptide YY, which binds to receptors on the endocrine, histamine-containing cells described as enterochromaffin-like (ECLs). Such binding counteracts the cephalic and gastric phases of acid secretion by inhibiting gastrin-stimulated histamine release from ECLs. Other factors that inhibit acid secretion include somatostatin and prostaglandins.

(Choice A) Basal gastric secretion has been defined as the gastric juices secreted in the absence of intentional or avoidable stimuli (essentially, the "baseline" gastric acid secretion). Basal gastric secretion is not an important factor in the down-regulation of postprandial gastric secretion.

(Choices B and C) The cephalic and gastric phases both stimulate gastric acid secretion, not down-regulate it.

(Choice E) Receptive relaxation is a reflex that allows the gastric fundus to dilate in anticipation of food passing through the pharynx and esophagus. It is not an important factor in the down-regulation of postprandial gastric secretion.

(Choice F) Postprandial alkaline tide is defined as an increase in plasma HCO_3^- and decrease in plasma Cl^- secondary to the surge of acid within the gastric lumen. It is not an important factor in the down-regulation of postprandial gastric secretion.

Educational Objective:
The cephalic and gastric phases stimulate gastric acid secretion, while intestinal influences tend to reduce gastric acid secretion.

https://t.me/USMLEWorldStep1

A 25-year-old man comes to the hospital due to worsening abdominal pain, distension, and nausea and vomiting for 3 days. He has a 4-year history of recurrent abdominal pain associated with diarrhea, low-grade fever, and easy fatigability. The symptoms usually occur after stress and resolve spontaneously in a few days. However, this time, the patient's symptoms persisted and worsened. He has no other medical problems and takes no medications on a regular basis. Temperature is 38.2 C (100.8 F), blood pressure is 110/70 mm Hg, pulse is 104/min, and respirations are 16/min. BMI is 19 kg/m^2. Examination shows a tender mass in the right lower quadrant of the abdomen. Imaging is consistent with small-bowel obstruction. Laparotomy reveals that the abdominal mass is composed of inflamed small bowel, adherent and indurated mesentery, and enlarged abdominal lymph nodes. The affected region of the small bowel is resected. Which of the following is most likely to be seen on histologic examination of this patient's intestine?

- A. Caseating granulomas in all layers of the intestine
- B. Flask-shaped ulcers with narrow necks and broad bases
- C. Inflammation limited to the mucosa and submucosa
- D. Pseudomembranes of fibrin and inflammatory debris
- E. Thickening of the muscularis mucosae

Submit

https://t.me/USMLEWorldStep1

A 25-year-old man comes to the hospital due to worsening abdominal pain, distension, and nausea and vomiting for 3 days. He has a 4-year history of recurrent abdominal pain associated with diarrhea, low-grade fever, and easy fatigability. The symptoms usually occur after stress and resolve spontaneously in a few days. However, this time, the patient's symptoms persisted and worsened. He has no other medical problems and takes no medications on a regular basis. Temperature is 38.2 C (100.8 F), blood pressure is 110/70 mm Hg, pulse is 104/min, and respirations are 16/min. BMI is 19 kg/m^2. Examination shows a tender mass in the right lower quadrant of the abdomen. Imaging is consistent with small-bowel obstruction. Laparotomy reveals that the abdominal mass is composed of inflamed small bowel, adherent and indurated mesentery, and enlarged abdominal lymph nodes. The affected region of the small bowel is resected. Which of the following is most likely to be seen on histologic examination of this patient's intestine?

- A. Caseating granulomas in all layers of the intestine (45%)
- ✗ B. Flask-shaped ulcers with narrow necks and broad bases (11%)
- C. Inflammation limited to the mucosa and submucosa (17%)
- D. Pseudomembranes of fibrin and inflammatory debris (8%)
- ✓ E. Thickening of the muscularis mucosae (17%)

Incorrect
Correct answer
E

17%
Answered correctly

03 secs
Time Spent

2023
Version

Explanation

Crohn disease vs ulcerative colitis

Normal	Crohn disease	Ulcerative colitis

https://t.me/USMLEWorldStep1

A 25-year-old man comes to the hospital due to worsening abdominal pain, distension, and nausea and vomiting for 3 d
easy f
time, t
medic
104/m
quadra
abdom
lymph
on hist

Exhibit Display

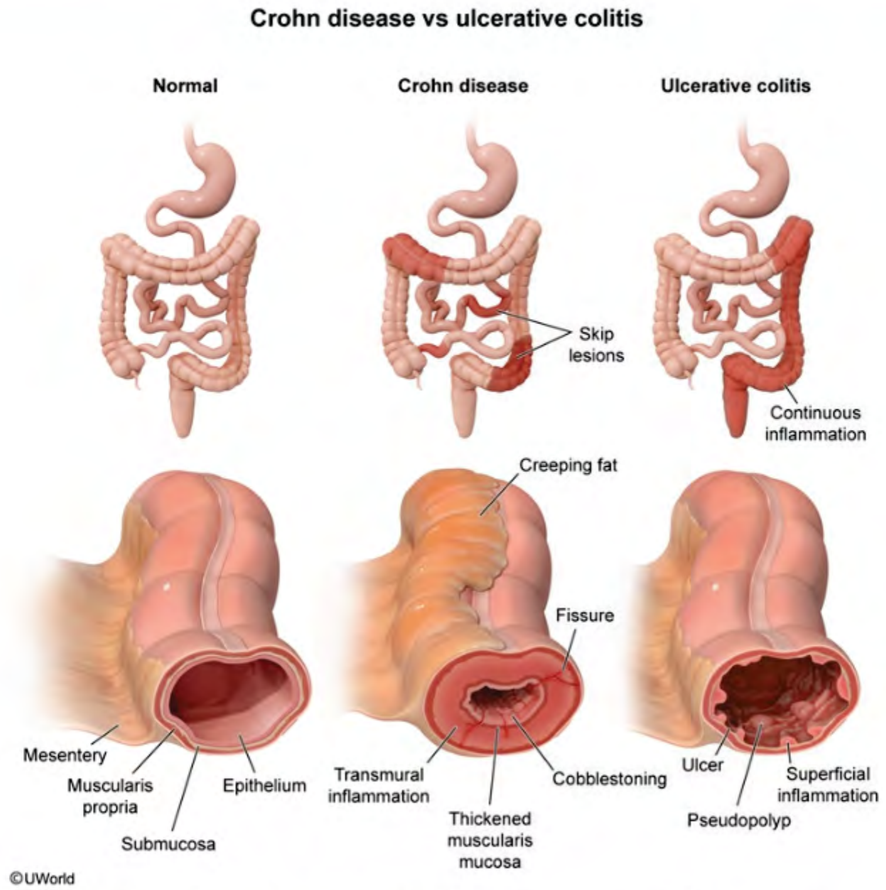

Zoom In | Zoom Out | Reset | New | Existing | My Notebook

Normal Crohn disease Ulcerative colitis

Inco
Corre
E

Expl

https://t.me/USMLEWorldStep1

©UWorld

This patient with recurrent abdominal pain and diarrhea likely has **Crohn disease** (CD) complicated by small-bowel obstruction. CD is an inflammatory bowel disease that occurs most commonly in young adults. It typically presents as recurrent episodes of abdominal pain associated with diarrhea, low-grade fevers, and fatigue; symptoms may worsen during periods of stress. The inflammation can affect any part of the gastrointestinal tract from the mouth to the anus and is typically patchy with interspersed areas of normal bowel (skip lesions). CD is characterized by **transmural inflammation** (all layers of the bowel wall are involved), which predisposes to several complications:

- **Strictures** occur as a result of bowel wall edema, fibrosis, and **hypertrophy (thickening)** of the muscularis mucosae, which narrows the intestinal lumen. This can progress to **bowel obstruction**.
- Fistulas occur when ulcers penetrate the entire thickness of the intestinal wall, leading to a sinus tract that communicates between multiple organs (eg, enterovesicular, enterovaginal, enteroenteric).
- Abscesses form when sinus tracts become walled off. They can also perforate, leading to diffuse peritonitis.

(Choice A) Caseating granulomas are typically seen in multiple infectious processes, most notably tuberculosis (TB). Abdominal TB can present with abdominal pain, fevers, and occasional obstruction; however, symptoms are unlikely to spontaneously wax and wane, and evidence of TB is often present in other sites (eg, hemoptysis with pulmonary TB). CD is associated with noncaseating, rather than caseating, granulomas.

(Choice B) Flask-shaped ulcers in the cecum and colon are seen in *Entamoeba histolytica* infection, which occurs more commonly in developing countries and presents with bloody diarrhea. Severe cases can cause fulminant colitis with bowel necrosis, but obstruction is uncommon.

(Choice C) Ulcerative colitis is an inflammatory bowel disease that involves only the mucosa and submucosa. Inflammation involves contiguous areas of the colon only, and the small bowel is not involved. Due to the superficial nature of the inflammation, strictures and fistulas are not seen.

(Choice D) Pseudomembranes composed of fibrin and inflammatory debris are seen with *Clostridium difficile* infection, which is typically associated with antibiotic use. Complications include toxic megacolon; however, *C*

https://t.me/USMLEWorldStep1

from the mouth to the anus and is typically patchy with interspersed areas of normal bowel (skip lesions). CD is characterized by **transmural inflammation** (all layers of the bowel wall are involved), which predisposes to several complications:

- **Strictures** occur as a result of bowel wall edema, fibrosis, and **hypertrophy (thickening)** of the muscularis mucosae, which narrows the intestinal lumen. This can progress to **bowel obstruction**.
- Fistulas occur when ulcers penetrate the entire thickness of the intestinal wall, leading to a sinus tract that communicates between multiple organs (eg, enterovesicular, enterovaginal, enteroenteric).
- Abscesses form when sinus tracts become walled off. They can also perforate, leading to diffuse peritonitis.

(Choice A) Caseating granulomas are typically seen in multiple infectious processes, most notably tuberculosis (TB). Abdominal TB can present with abdominal pain, fevers, and occasional obstruction; however, symptoms are unlikely to spontaneously wax and wane, and evidence of TB is often present in other sites (eg, hemoptysis with pulmonary TB). CD is associated with noncaseating, rather than caseating, granulomas.

(Choice B) Flask-shaped ulcers in the cecum and colon are seen in *Entamoeba histolytica* infection, which occurs more commonly in developing countries and presents with bloody diarrhea. Severe cases can cause fulminant colitis with bowel necrosis, but obstruction is uncommon.

(Choice C) Ulcerative colitis is an inflammatory bowel disease that involves only the mucosa and submucosa. Inflammation involves contiguous areas of the colon only, and the small bowel is not involved. Due to the superficial nature of the inflammation, strictures and fistulas are not seen.

(Choice D) Pseudomembranes composed of fibrin and inflammatory debris are seen with *Clostridium difficile* infection, which is typically associated with antibiotic use. Complications include toxic megacolon; however, *C difficile* does not cause obstruction and the small bowel is not typically involved.

Educational objective:
Crohn disease is characterized by patchy, transmural inflammation of the gastrointestinal tract. It can affect any part of the tract from the mouth to the anus. Complications include strictures (due to bowel wall edema, fibrosis, and thickening of the muscularis mucosae), fistulas (due to penetration of ulcers through the intestinal wall), and abscesses.

https://t.me/USMLEWorldStep1

obstruction. CD is an inflammatory bowel disease that occurs most commonly in young adults. It typically presents as recurrent episodes of abdominal pain associated with diarrhea, low-grade fevers, and fatigue; sympt
from th
charac
compli

- S
- F
- A

(Choi
(TB).
unlikel
pulmo

(Choi
more
colitis

(Choi
Inflam
superf

(Choi
infecti
difficile

Educational objective:
Crohn disease is characterized by patchy, transmural inflammation of the gastrointestinal tract. It can affect any

Exhibit Display

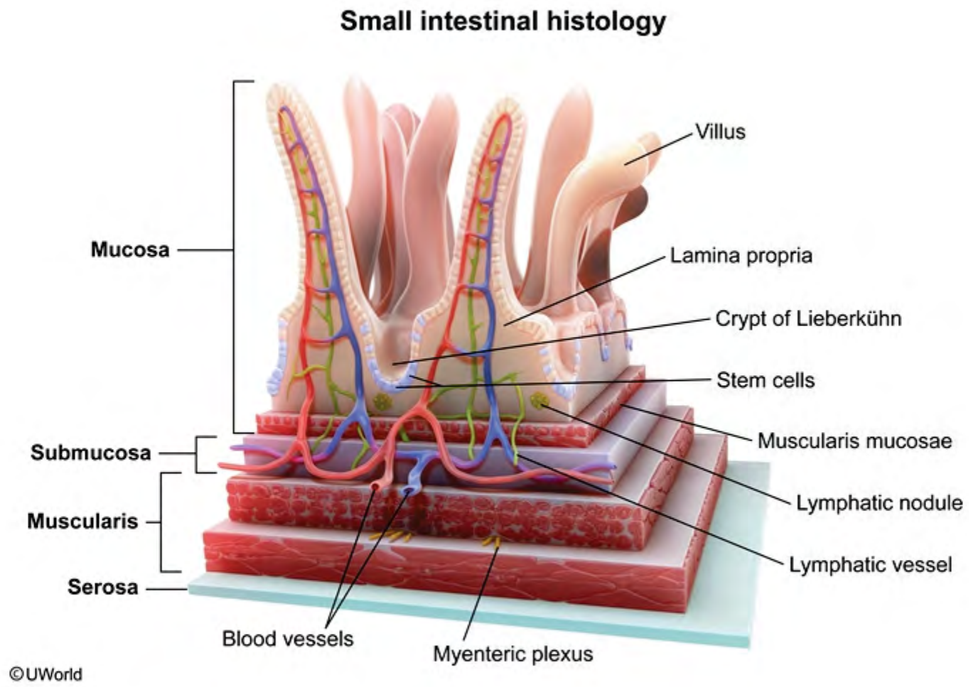

Zoom In Zoom Out Reset New | Existing My Notebook

https://t.me/USMLEWorldStep1

obstruction. CD is an inflammatory bowel disease that occurs most commonly in young adults. It typically
presents as recurrent episodes of abdominal pain associated with diarrhea, low-grade fevers, and fatigue;
sympt
from th
charac
compli

- S
- F
- A

(Choi
(TB).
unlikel
pulmo

(Choi
more
colitis

(Choi
Inflam
superf

(Choi
infecti
difficile does not cause obstruction and the small bowel is not typically involved.

Educational objective:
Crohn disease is characterized by patchy, transmural inflammation of the gastrointestinal tract. It can affect any

Exhibit Display

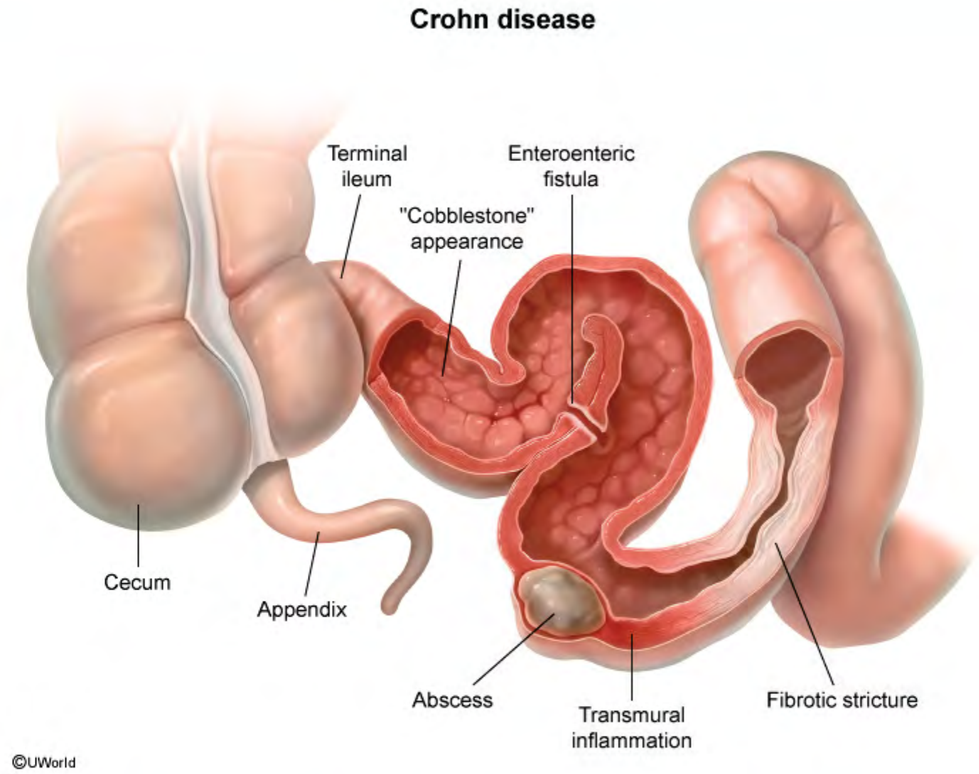

Zoom In | Zoom Out | Reset | New | Existing | My Notebook

https://t.me/USMLEWorldStep1

obstruction. CD is an inflammatory bowel disease that occurs most commonly in young adults. It typically
presents as recurrent episodes of abdominal pain associated with diarrhea, low-grade fevers, and fatigue;
sympt
from th
charac
compli

- S
- F
- A

(Choi
(TB).
unlikel
pulmo

(Choi
more
colitis

(Choi
Inflam
superf

(Choi
infecti
difficile does not cause obstruction and the small bowel is not typically involved.

Educational objective:
Crohn disease is characterized by patchy, transmural inflammation of the gastrointestinal tract. It can affect any

Exhibit Display

Pseudomembranous colitis

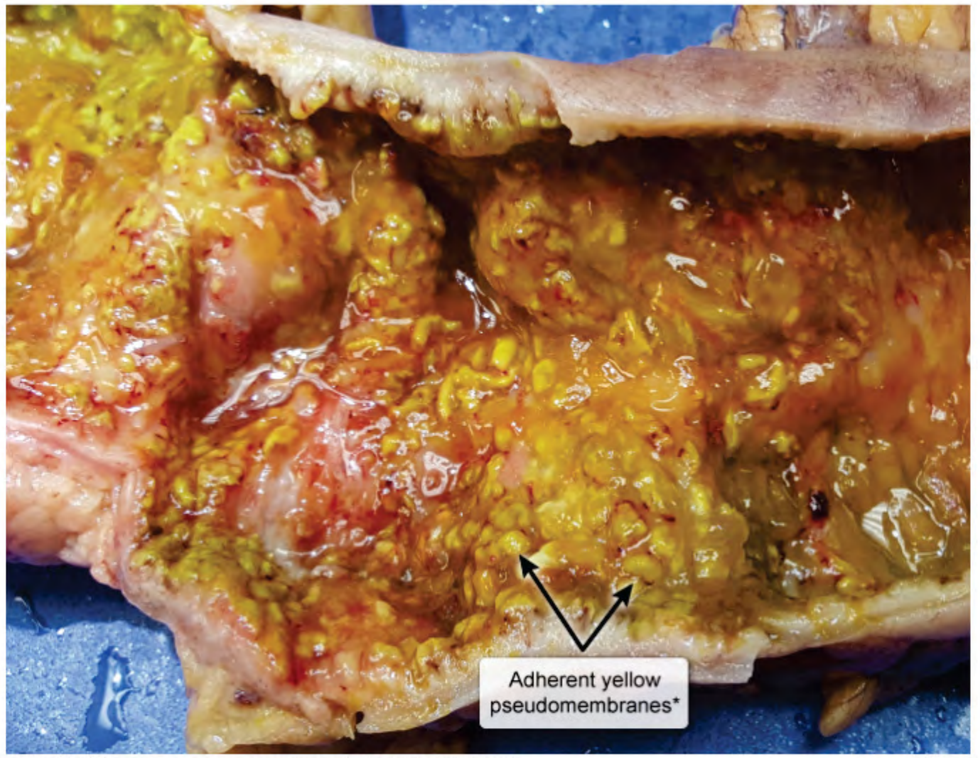

*Fibrin and inflammatory debris associated with *Clostridioides difficile*.

©UWorld

Zoom In Zoom Out Reset New | Existing My Notebook

https://t.me/USMLEWorldStep1

A 32-year-old man is being evaluated due to mild abdominal discomfort and anorexia. He recently consumed large amounts of alcohol at a holiday party. A liver biopsy is performed, and light microscopy findings are shown in the image below:

Which of the following metabolic changes most likely contributed to the development of this patient's biopsy findings?

- A. Decreased free fatty acid oxidation
- B. Decreased triglyceride synthesis
- C. Enhanced lipoprotein assembly
- D. Increased gluconeogenesis
- E. Increased glucose uptake into cells
- F. Increased phospholipid catabolism

Submit

https://t.me/USMLEWorldStep1

A 32-year-old man is being evaluated due to mild abdominal discomfort and anorexia. He recently consumed large amoun
image

Exhibit Display

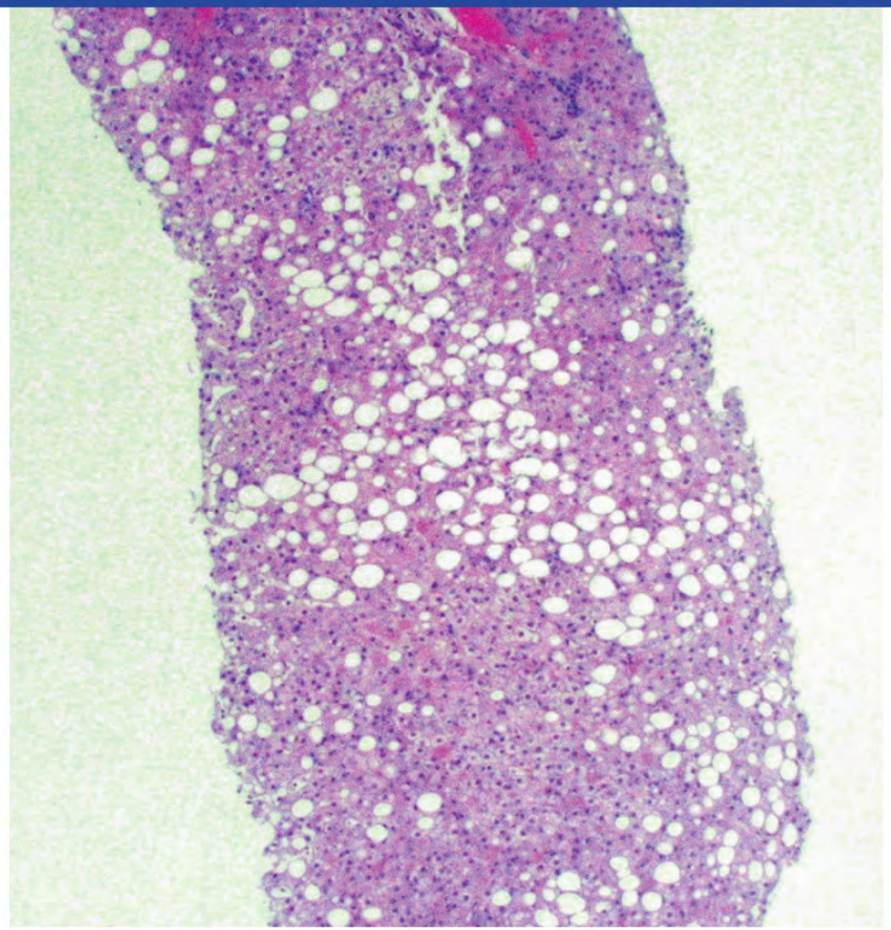

Zoom In Zoom Out Reset New | Existing My Notebook

https://t.me/USMLEWorldStep1

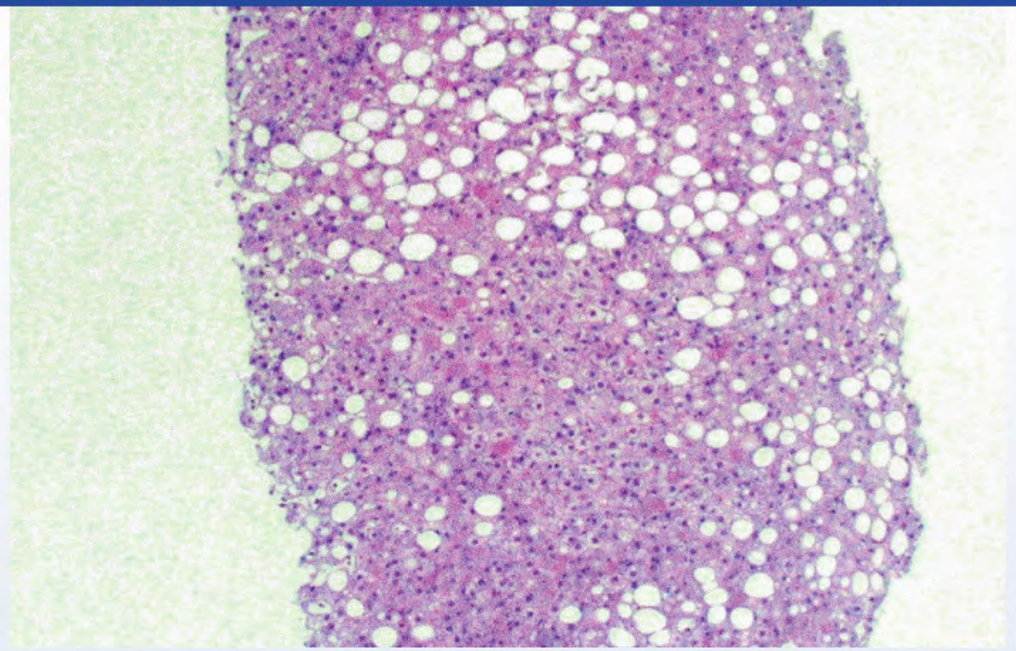

Which of the following metabolic changes most likely contributed to the development of this patient's biopsy findings?

- A. Decreased free fatty acid oxidation
- B. Decreased triglyceride synthesis
- C. Enhanced lipoprotein assembly
- D. Increased gluconeogenesis
- E. Increased glucose uptake into cells
- F. Increased phospholipid catabolism

Submit

https://t.me/USMLEWorldStep1

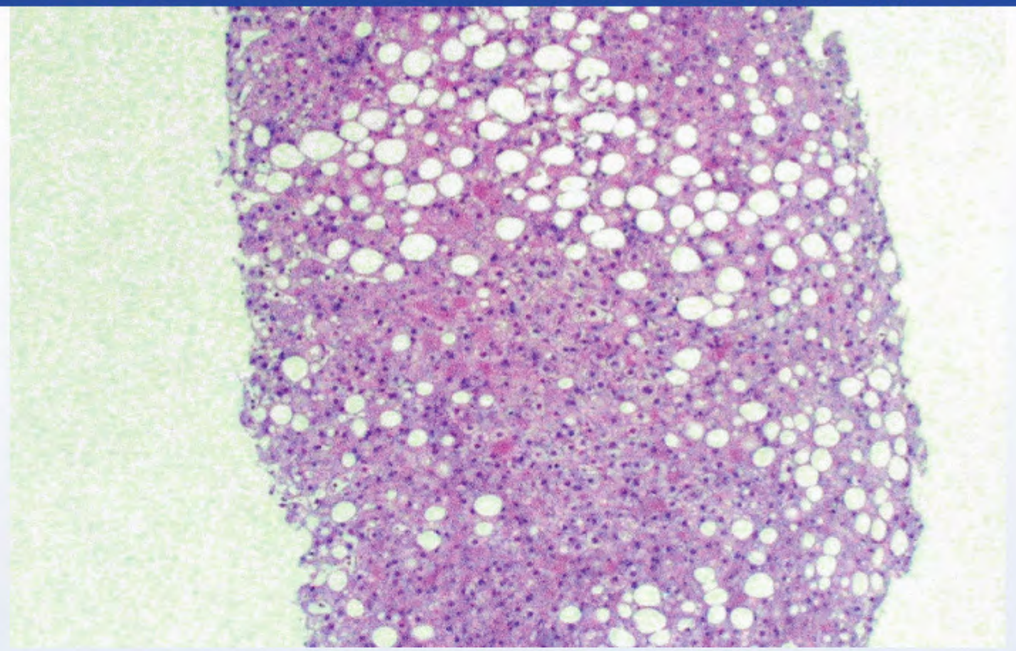

Which of the following metabolic changes most likely contributed to the development of this patient's biopsy findings?

- ✓ A. Decreased free fatty acid oxidation (68%)
- B. Decreased triglyceride synthesis (4%)
- C. Enhanced lipoprotein assembly (14%)
- D. Increased gluconeogenesis (2%)
- E. Increased glucose uptake into cells (3%)
- F. Increased phospholipid catabolism (6%)

Correct

68% Answered correctly

10 secs Time Spent

2023 Version

https://t.me/USMLEWorldStep1

Correct

68%
Answered correctly

10 secs
Time Spent

2023
Version

Exhibit Display

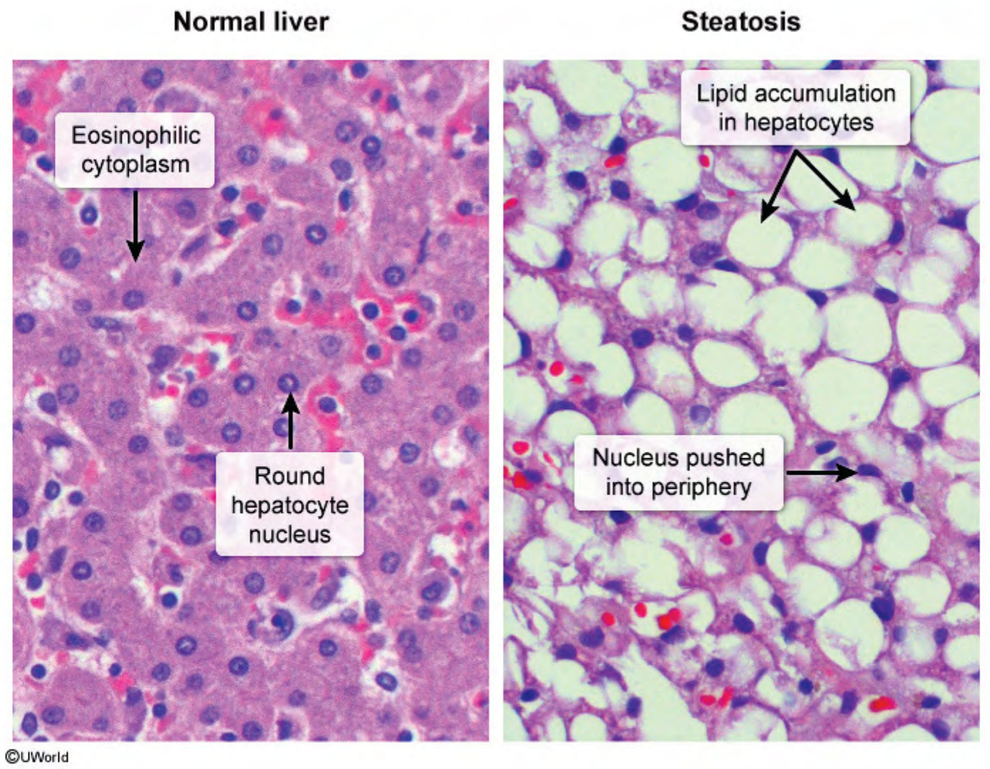

Zoom In | Zoom Out | Reset | New | Existing | My Notebook

producing NADH and an **increased NADH/NAD⁺ ratio**. Excess NADH production contributes to the pathogenesis

https://t.me/USMLEWorldStep1

©UWorld

This patient's liver biopsy shows **steatosis**, a nonspecific condition characterized by **triglyceride accumulation** within the hepatocellular cytoplasm, which is likely related to his recent **alcohol consumption**.

Ethanol is metabolized in the liver by alcohol dehydrogenase and acetaldehyde dehydrogenase enzymes, producing NADH and an **increased NADH/NAD$^+$ ratio**. Excess NADH production contributes to the pathogenesis of hepatic steatosis primarily by **inhibiting free fatty acid oxidation**. It also enhances fatty acid formation and glycerol-3-phosphate production, thus promoting triglyceride synthesis **(Choice B)**. Additional contributing pathogenetic factors include increased peripheral fat catabolism and impaired lipoprotein assembly and secretion **(Choice C)**.

On microscopic examination, fat accumulation appears as **clear cytoplasmic vacuoles** (lipids frequently dissolve during histologic processing) that often displace the hepatocyte nucleus. The lipids can also be highlighted by specialized staining with oil red O or Sudan black.

(Choice D) An increased hepatic NADH/NAD$^+$ ratio due to alcohol consumption inhibits gluconeogenesis reactions that require NAD$^+$ (eg, conversion of malate to oxaloacetate and lactate to pyruvate).

(Choice E) Increased cellular glucose uptake occurs with high circulating insulin levels; however, hyperinsulinemia does not significantly contribute to the pathogenesis of alcohol-induced hepatic steatosis. In contrast, insulin resistance and hyperinsulinemia play a key role in development of nonalcoholic fatty liver disease.

(Choice F) Alcohol use increases peripheral fat (not phospholipid) catabolism. The resulting increase in circulating free fatty acids contributes to alcohol-induced hepatic steatosis by increasing hepatocellular triglyceride synthesis.

Educational objective:
The pathogenesis of alcohol-induced hepatic steatosis involves excess NADH production (via ethanol metabolism), which inhibits free fatty acid oxidation and promotes lipogenesis. Steatosis is microscopically characterized by clear cytoplasmic vacuoles within hepatocytes.

Pathology	Gastrointestinal & Nutrition	Alcoholic liver disease
Subject	System	Topic

https://t.me/USMLEWorldStep1

A 53-year-old man with nocturnal cough undergoes an upper endoscopy with esophageal biopsy. Light microscopy of the tissue specimen shows elongation of the lamina propria papillae with several eosinophils and neutrophils scattered within the squamous epithelium. The patient takes metformin and enalapril for diabetes mellitus and hypertension, respectively. He is started on pantoprazole, and after 2 weeks his cough symptoms resolve. Which of the following was the most likely cause of his symptoms?

- A. Absent esophageal peristaltic movements
- B. Allergen-mediated esophageal disease
- C. Gastroesophageal junction incompetence
- D. Mucosal disruption from fungal infection
- E. Mucosal disruption from viral infection
- F. Pill-induced esophageal mucosa damage

Submit

https://t.me/USMLEWorldStep1

A 53-year-old man with nocturnal cough undergoes an upper endoscopy with esophageal biopsy. Light microscopy of the tissue specimen shows elongation of the lamina propria papillae with several eosinophils and neutrophils scattered within the squamous epithelium. The patient takes metformin and enalapril for diabetes mellitus and hypertension, respectively. He is started on pantoprazole, and after 2 weeks his cough symptoms resolve. Which of the following was the most likely cause of his symptoms?

- ✗ A. Absent esophageal peristaltic movements (1%)
- B. Allergen-mediated esophageal disease (18%)
- ✓ C. Gastroesophageal junction incompetence (67%)
- D. Mucosal disruption from fungal infection (3%)
- E. Mucosal disruption from viral infection (1%)
- F. Pill-induced esophageal mucosa damage (8%)

Incorrect
Correct answer
C

67%
Answered correctly

03 secs
Time Spent

2023
Version

Explanation

Gastroesophageal reflux disease	
Pathophysiology	• Decreased tone or excessive transient relaxation of LES • Anatomic disruption to gastroesophageal junction (eg, hiatal hernia) • ↑ Risk with obesity, pregnancy, smoking, alcohol intake
Manifestations	• Regurgitation of acidic material in mouth • Heartburn • Odynophagia (often indicates reflux esophagitis)

https://t.me/USMLEWorldStep1

Gastroesophageal reflux disease	
Pathophysiology	• Decreased tone or excessive transient relaxation of LES • Anatomic disruption to gastroesophageal junction (eg, hiatal hernia) • ↑ Risk with obesity, pregnancy, smoking, alcohol intake
Manifestations	• Regurgitation of acidic material in mouth • Heartburn • Odynophagia (often indicates reflux esophagitis) • Extraesophageal symptoms (eg, cough, laryngitis, wheezing)
Complications	• Erosive esophagitis • Strictures • Barrett esophagus → adenocarcinoma
Initial treatment	• Lifestyle (eg, weight loss) & dietary changes • H2R blocker or proton pump inhibitor
H2R = histamine 2 receptor; **LES** = lower esophageal sphincter.	

Gastroesophageal reflux disease (GERD) is a very common condition that usually manifests with heartburn, regurgitation, and dysphagia. However, patients can have **extraesophageal symptoms** (eg, nocturnal **cough**, hoarseness) in the absence of heartburn ("silent GERD").

Gastroesophageal junction incompetence is the primary pathophysiologic mechanism responsible for GERD. This incompetence is most commonly caused by excessive relaxation of the lower esophageal sphincter, resulting in the reflux of acidic gastric contents back into the esophagus. Irritation of the esophageal mucosa leads to an inflammatory reaction with mucosal erythema and edema; erosions/ulcerations may develop in severe cases. Characteristic histologic findings include basal zone hyperplasia, elongation of the lamina propria papillae, and scattered eosinophils and neutrophils.

(Choice A) Absent esophageal peristaltic movements can be seen with achalasia and systemic sclerosis. The distinctive histopathologic findings of systemic sclerosis involving the esophagus include atrophy of the muscularis

https://t.me/USMLEWorldStep1

Gastroesophageal reflux disease (GERD) is a very common condition that usually manifests with heartburn, regurgitation, and dysphagia. However, patients can have **extraesophageal symptoms** (eg, nocturnal **cough**, hoarseness) in the absence of heartburn ("silent GERD").

Gastroesophageal junction incompetence is the primary pathophysiologic mechanism responsible for GERD. This incompetence is most commonly caused by excessive relaxation of the lower esophageal sphincter, resulting in the reflux of acidic gastric contents back into the esophagus. Irritation of the esophageal mucosa leads to an inflammatory reaction with mucosal erythema and edema; erosions/ulcerations may develop in severe cases. Characteristic histologic findings include basal zone hyperplasia, elongation of the lamina propria papillae, and scattered eosinophils and neutrophils.

(Choice A) Absent esophageal peristaltic movements can be seen with achalasia and systemic sclerosis. The distinctive histopathologic findings of systemic sclerosis involving the esophagus include atrophy of the muscularis with collagenous fibrosis.

(Choice B) Eosinophilic esophagitis is an immune/antigen-mediated disease that typically presents with dysphagia and food impaction in atopic adults. It is characterized histologically by *numerous* superficially located intraepithelial eosinophils, which can help differentiate it from reflux esophagitis.

(Choice D) *Candida albicans* is the most common cause of infectious esophagitis in HIV and immunocompromised patients. Endoscopy typically shows white plaques on an erythematous mucosa, and light microscopy demonstrates pseudohyphae and budding spores embedded in necrotic debris.

(Choice E) Herpes simplex virus (HSV) and cytomegalovirus (CMV) are other common causes of infectious esophagitis in immunocompromised patients. HSV usually shows punched-out ulcers on endoscopy with eosinophilic nuclear inclusions on biopsy. In contrast, CMV produces shallow/linear ulcers with nuclear/cytoplasmic viral inclusions.

(Choice F) Pill-induced esophagitis is commonly seen with tetracycline antibiotics, potassium chloride, and bisphosphonates. Metformin and enalapril do not cause esophagitis.

Educational objective:
Gastroesophageal reflux disease is caused primarily by gastroesophageal junction incompetence and can be

https://t.me/USMLEWorldStep1

Gastroesophageal junction incompetence is the primary pathophysiologic mechanism responsible for GERD. This incompetence is most commonly caused by excessive relaxation of the lower esophageal sphincter, resulting in the reflux of acidic gastric contents back into the esophagus. Irritation of the esophageal mucosa leads to an inflammatory reaction with mucosal erythema and edema; erosions/ulcerations may develop in severe cases. Characteristic histologic findings include basal zone hyperplasia, elongation of the lamina propria papillae, and scattered eosinophils and neutrophils.

(Choice A) Absent esophageal peristaltic movements can be seen with achalasia and systemic sclerosis. The distinctive histopathologic findings of systemic sclerosis involving the esophagus include atrophy of the muscularis with collagenous fibrosis.

(Choice B) Eosinophilic esophagitis is an immune/antigen-mediated disease that typically presents with dysphagia and food impaction in atopic adults. It is characterized histologically by *numerous* superficially located intraepithelial eosinophils, which can help differentiate it from reflux esophagitis.

(Choice D) *Candida albicans* is the most common cause of infectious esophagitis in HIV and immunocompromised patients. Endoscopy typically shows white plaques on an erythematous mucosa, and light microscopy demonstrates pseudohyphae and budding spores embedded in necrotic debris.

(Choice E) Herpes simplex virus (HSV) and cytomegalovirus (CMV) are other common causes of infectious esophagitis in immunocompromised patients. HSV usually shows punched-out ulcers on endoscopy with eosinophilic nuclear inclusions on biopsy. In contrast, CMV produces shallow/linear ulcers with nuclear/cytoplasmic viral inclusions.

(Choice F) Pill-induced esophagitis is commonly seen with tetracycline antibiotics, potassium chloride, and bisphosphonates. Metformin and enalapril do not cause esophagitis.

Educational objective:
Gastroesophageal reflux disease is caused primarily by gastroesophageal junction incompetence and can be associated with extraesophageal symptoms (eg, nocturnal cough) in the absence of heartburn ("silent GERD"). Acidic gastric contents irritate the esophageal mucosa, leading to characteristic histologic findings that include basal zone hyperplasia, elongation of the lamina propria papillae, and scattered eosinophils.

https://t.me/USMLEWorldStep1

Initial treatment	• Lifestyle (eg, weight loss) & dietary changes H2R blocker or proton pump inhibitor

Exhibit Display

Reflux esophagitis

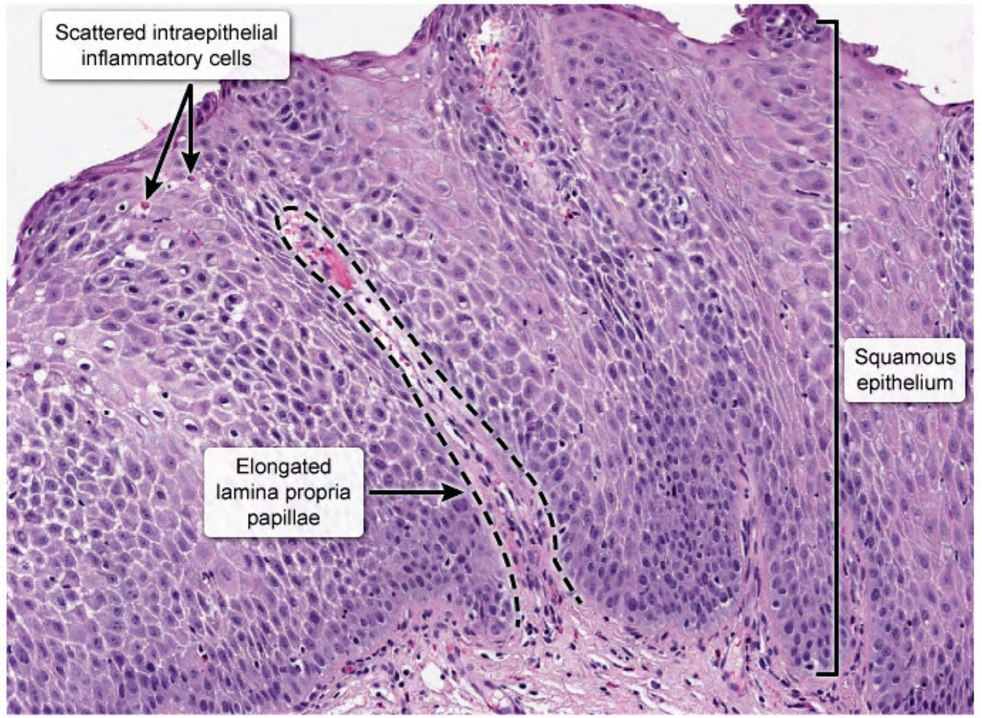

©UWorld

Zoom In | Zoom Out | Reset | New | Existing | My Notebook

Gastr
regurg
hoarse

Gastr
This in
in the
inflam
Chara
scatte

(Choi
distinc
with c

(Choi
dysph
intraep

(Choi
immur
micros

(Choi
esoph
eosinc
nuclea

(Choice F) Pill-induced esophagitis is commonly seen with tetracycline antibiotics, potassium chloride, and

https://t.me/USMLEWorldStep1

Initial treatment	• Lifestyle (eg, weight loss) & dietary changes H2R blocker or proton pump inhibitor

Exhibit Display

Eosinophilic esophagitis

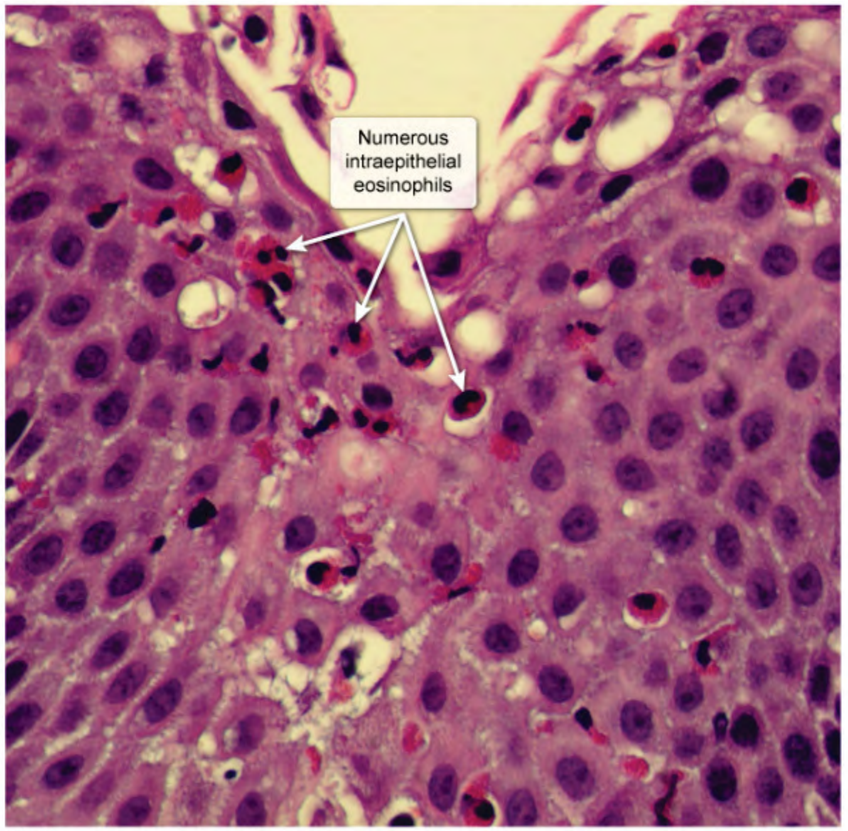

Zoom In | Zoom Out | Reset | New | Existing | My Notebook

Gastr
regurg
hoarse

Gastr
This in
in the
inflam
Chara
scatte

(Choi
distinc
with c

(Choi
dysph
intraep

(Choi
immur
micros

(Choi
esoph
eosinc
nuclea

(Choice F) Pill-induced esophagitis is commonly seen with tetracycline antibiotics, potassium chloride, and

https://t.me/USMLEWorldStep1

Initial treatment	• Lifestyle (eg, weight loss) & dietary changes H2R blocker or proton pump inhibitor

Exhibit Display

Gastr
regurg
hoarse

Gastr
This in
in the
inflam
Chara
scatte

(Choi
distinc
with c

(Choi
dysph
intraep

(Choi
immur
micros

(Choi
esoph
eosinc
nuclear/cytoplasmic viral inclusions.

(Choice F) Pill-induced esophagitis is commonly seen with tetracycline antibiotics, potassium chloride, and

***Candida* esophagitis**

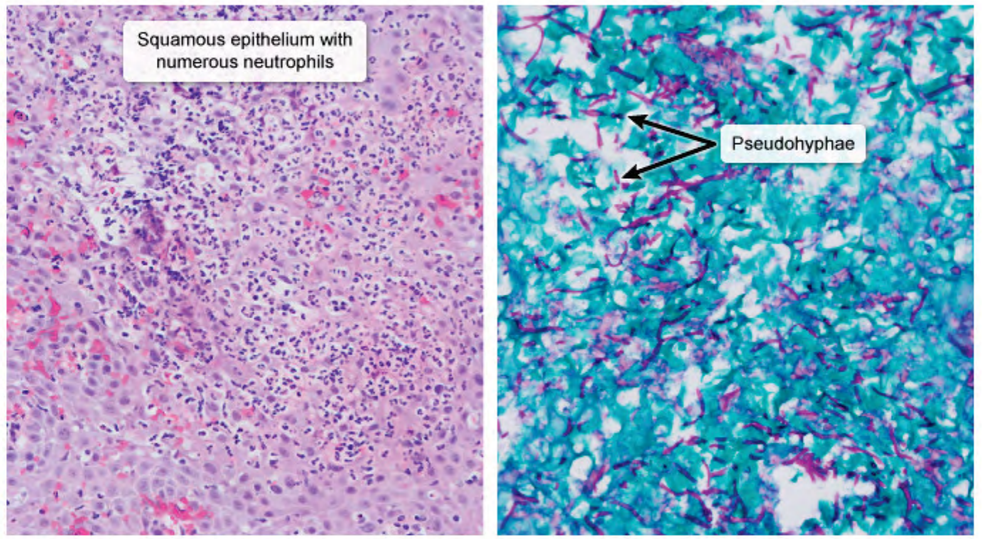

©UWorld

H&E stain

Periodic acid-Schiff stain

Zoom In | Zoom Out | Reset | New | Existing | My Notebook

https://t.me/USMLEWorldStep1

Initial treatment	• Lifestyle (eg, weight loss) & dietary changes H2R blocker or proton pump inhibitor

Exhibit Display

***Candida* esophagitis**

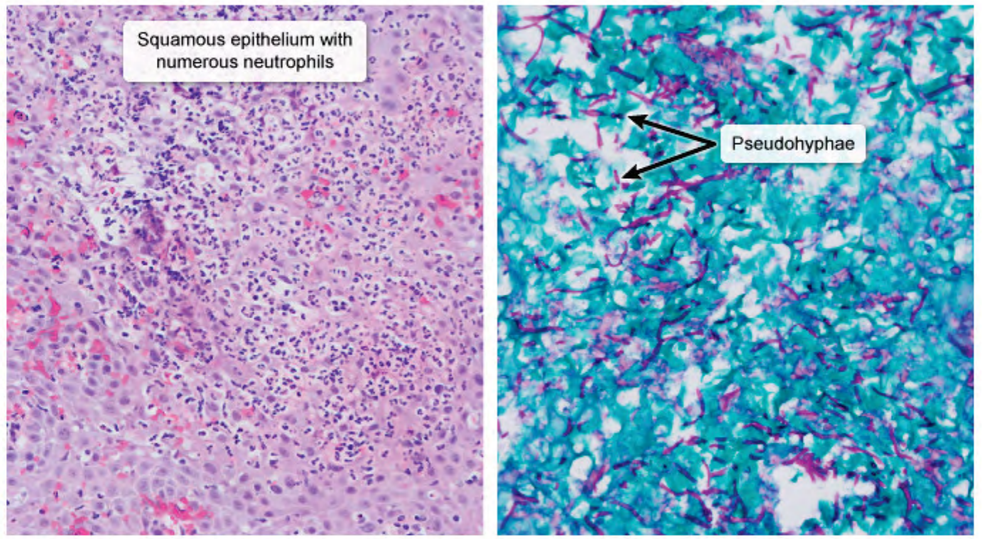

©UWorld

H&E stain

Periodic acid-Schiff stain

Zoom In Zoom Out Reset New | Existing My Notebook

Gastr
regurg
hoarse

Gastr
This in
in the
inflam
Chara
scatte

(Choi
distinc
with c

(Choi
dysph
intraep

(Choi
immur
micros

(Choi
esoph
eosinc
nuclea

(Choice F) Pill-induced esophagitis is commonly seen with tetracycline antibiotics, potassium chloride, and

https://t.me/USMLEWorldStep1

Initial treatment	• Lifestyle (eg, weight loss) & dietary changes H2R blocker or proton pump inhibitor

Exhibit Display

Herpes esophagitis

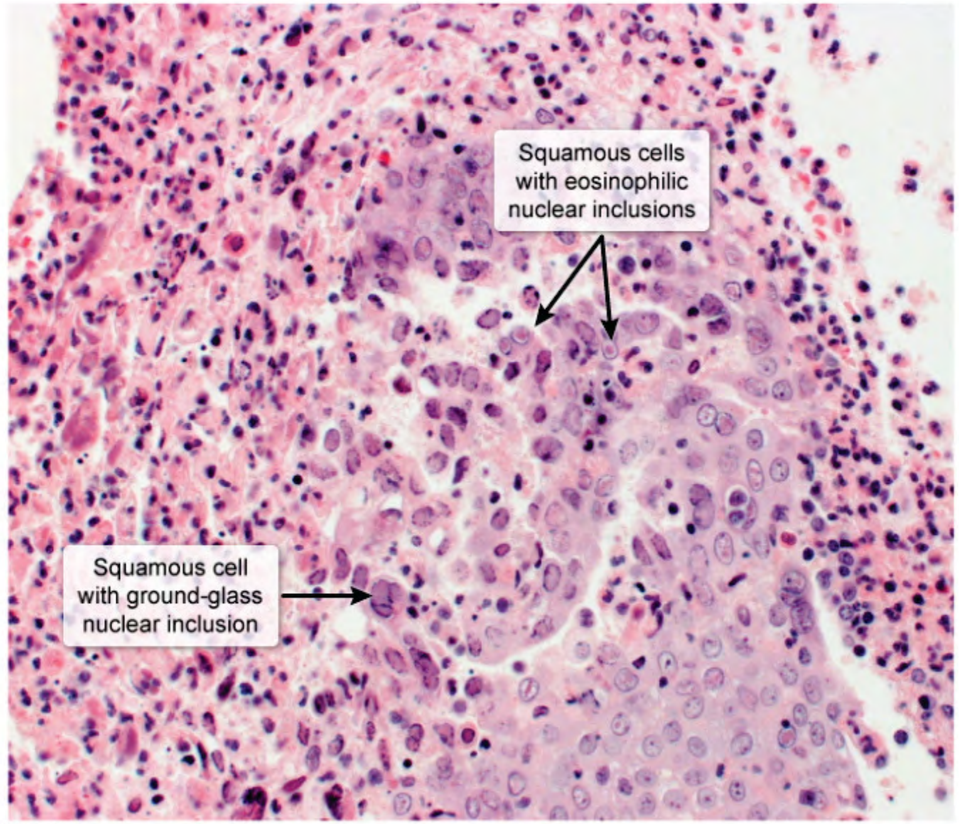

Zoom In | Zoom Out | Reset | New | Existing | My Notebook

Gastr
regurg
hoarse

Gastr
This in
in the
inflam
Chara
scatte

(Choi
distinc
with c

(Choi
dysph
intraep

(Choi
immur
micros

(Choi
esoph
eosinc
nuclea

(Choice F) Pill-induced esophagitis is commonly seen with tetracycline antibiotics, potassium chloride, and

https://t.me/USMLEWorldStep1

inflammatory reaction with mucosal erythema and edema; erosions/ulcerations may develop in severe cases.

Chara
scatte

(Choi
distinc
with c

(Choi
dysph
intraep

(Choi
immur
micros

(Choi
esoph
eosinc
nuclea

(Choi
bispho

Educa
Gastro
associ
Acidic
basal

Exhibit Display

Cytomegalovirus

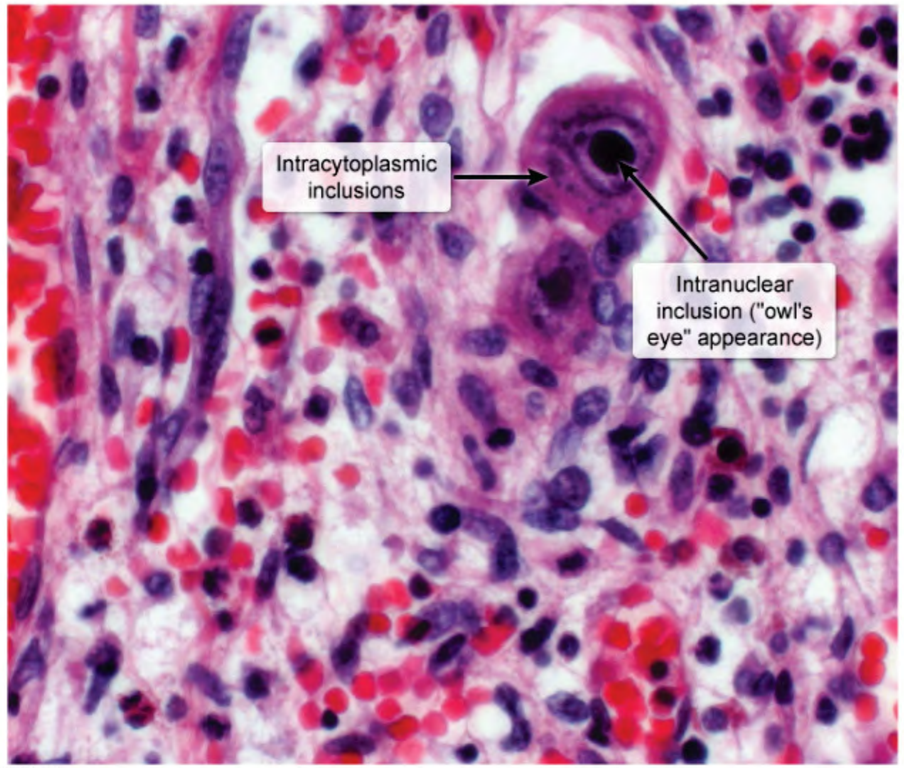

Zoom In | Zoom Out | Reset | New | Existing | My Notebook

Pathology
Subject

Gastrointestinal & Nutrition
System

Gastroesophageal reflux disease
Topic

Copyright © UWorld. All rights reserved.

https://t.me/USMLEWorldStep1

A 30-year-old man comes to the emergency department due to severe abdominal pain. The patient first developed the pain yesterday, and it has become increasingly worse. Over the last few hours, he has also developed bilious emesis. The patient has had no previous surgeries. Temperature is 37.8 C (100 F) and pulse is 110/min. Physical examination shows diffuse abdominal tenderness with guarding during palpation. Abdominal imaging reveals bowel wall thickening within a blind pouch connected to the ileum. A laparotomy is performed. During the procedure, a fibrous band is seen attaching the end of the pouch to the umbilicus. The walls of this pouch are most likely composed of which of the following?

- A. Fibrous scar tissue
- B. Granulation tissue and peritoneum
- C. Mucosa and submucosa layers
- D. Omentum and adipose tissue
- E. Submucosa, mucosa, and muscular layers

Submit

https://t.me/USMLEWorldStep1

A 30-year-old man comes to the emergency department due to severe abdominal pain. The patient first developed the pain yesterday, and it has become increasingly worse. Over the last few hours, he has also developed bilious emesis. The patient has had no previous surgeries. Temperature is 37.8 C (100 F) and pulse is 110/min. Physical examination shows diffuse abdominal tenderness with guarding during palpation. Abdominal imaging reveals bowel wall thickening within a blind pouch connected to the ileum. A laparotomy is performed. During the procedure, a fibrous band is seen attaching the end of the pouch to the umbilicus. The walls of this pouch are most likely composed of which of the following?

- A. Fibrous scar tissue (9%)
- B. Granulation tissue and peritoneum (5%)
- ✗ C. Mucosa and submucosa layers (20%)
- D. Omentum and adipose tissue (4%)
- ✓ E. Submucosa, mucosa, and muscular layers (60%)

Incorrect
Correct answer
E

60%
Answered correctly

04 secs
Time Spent

2023
Version

Explanation

https://t.me/USMLEWorldStep1

A 30-year-old man comes to the emergency department due to severe abdominal pain. The patient first developed
the pa
emesi
exami
bowel
proce
most li

Inco
Corre
E

Expl

Exhibit Display

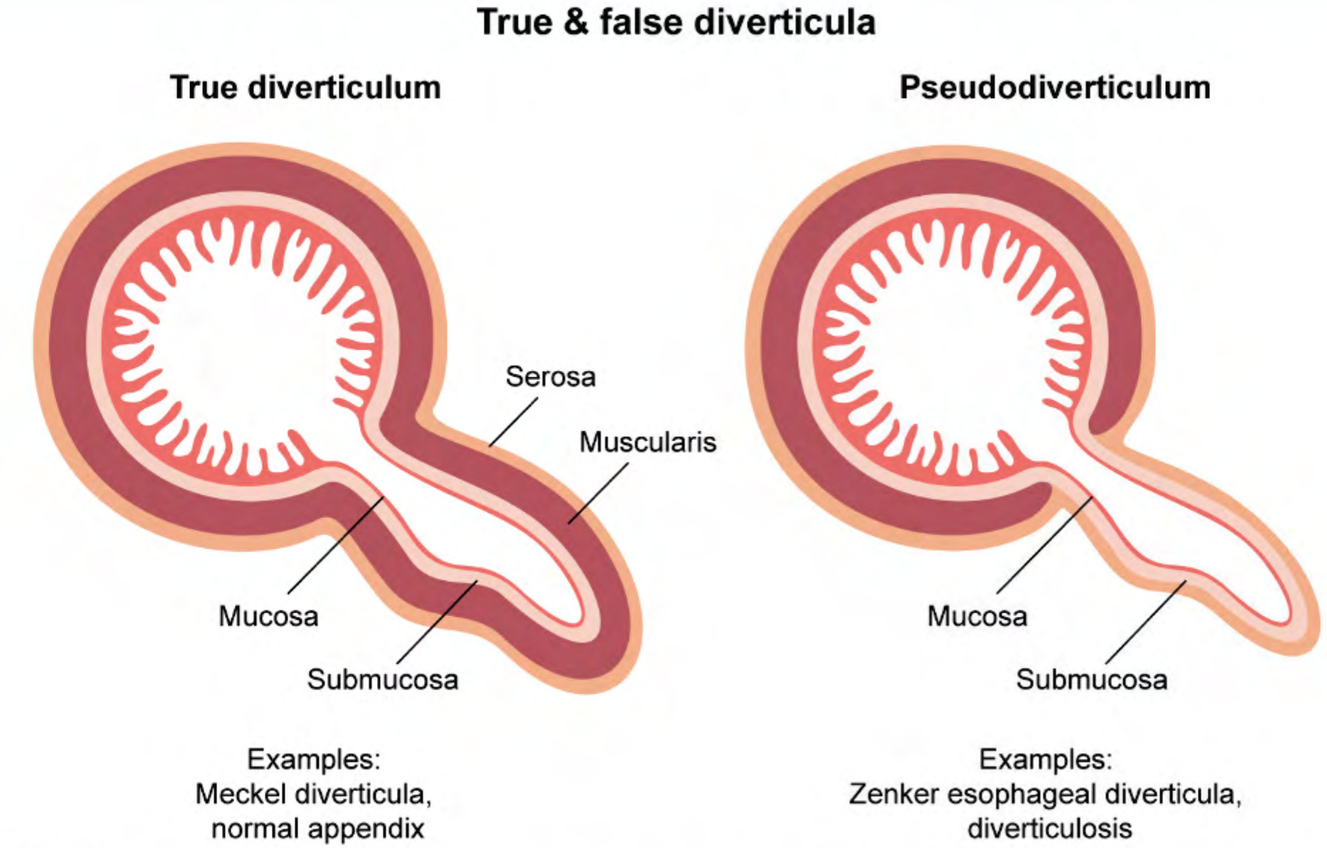

Zoom In | Zoom Out | Reset | New | Existing | My Notebook

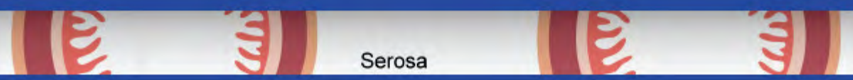

https://t.me/USMLEWorldStep1

©UWorld

This patient's outpouching from the **ileum** with a fibrous band connected to the **umbilicus** is characteristic of a **Meckel diverticulum**.

This congenital anomaly is due to **incomplete obliteration of the vitelline** (omphalomesenteric) duct in utero; the duct normally serves as a communication between the yolk sac and the primitive midgut in early gestation. Meckel diverticulum is typically located in the small bowel 2 feet from the ileocecal valve and, if symptomatic, often presents by age 2 (ie, rule of 2s); however, it can cause complications at any age.

Meckel diverticulum is a **true diverticulum**, consisting of all 3 layers of the intestinal wall: **mucosa, submucosa, and muscularis**. It often contains heterotopic gastric mucosa, which secretes hydrochloric acid and leads to the classic presentation of painless lower gastrointestinal bleeding (**hematochezia**) due to the ulceration of adjacent intestine. Patients may also develop **diverticular inflammation** with signs of acute intestinal obstruction (eg, abdominal pain, guarding, bilious emesis), as seen in this patient. Other complications of a Meckel diverticulum can include intussusception, volvulus, and bowel perforation.

(Choice A) Fibrous scar tissue, which can be present postoperatively or due to chronic inflammation, can cause intestinal obstruction with severe abdominal pain, bilious emesis, and guarding. However, a blind pouch connected to the ileum with an attachment to the umbilicus would not be present.

(Choice B) Granulation tissue is new connective tissue that forms in response to wound healing, and the peritoneum is the lining of the abdominal cavity. These tissues are not contained in a Meckel diverticulum.

(Choice C) False diverticula contain only mucosa and submucosa. These layers herniate through defects in the muscular layer. Colonic and Zenker (upper esophageal) diverticula are examples of false diverticula.

(Choice D) Tumors of the omentum (ie, adipose tissue covering the abdominal organs) are a rare cause of abdominal pain and vomiting but are not associated with an outpouching of the ileum.

Educational objective:
Meckel diverticulum, which classically causes painless hematochezia but can present with acute abdominal pain if inflamed (ie, diverticulitis), is an anatomic connection between the ileum and umbilicus resulting from incomplete obliteration of the vitelline duct. This congenital anomaly is a true diverticulum, consisting of all 3 layers of the intestinal wall (mucosa, submucosa, and muscularis).

https://t.me/USMLEWorldStep1

This congenital anomaly is due to **incomplete obliteration of the vitelline** (omphalomesenteric) duct in utero; the duct normally serves as a communication between the yolk sac and the primitive midgut in early gestation. Meckel diverticulum is typically located in the small bowel 2 feet from the ileocecal valve and, if symptomatic, often presents by age 2 (ie, rule of 2s); however, it can cause complications at any age.

Meckel diverticulum is a **true diverticulum**, consisting of all 3 layers of the intestinal wall: **mucosa, submucosa, and muscularis**. It often contains heterotopic gastric mucosa, which secretes hydrochloric acid and leads to the classic presentation of painless lower gastrointestinal bleeding (**hematochezia**) due to the ulceration of adjacent intestine. Patients may also develop **diverticular inflammation** with signs of acute intestinal obstruction (eg, abdominal pain, guarding, bilious emesis), as seen in this patient. Other complications of a Meckel diverticulum can include intussusception, volvulus, and bowel perforation.

(Choice A) Fibrous scar tissue, which can be present postoperatively or due to chronic inflammation, can cause intestinal obstruction with severe abdominal pain, bilious emesis, and guarding. However, a blind pouch connected to the ileum with an attachment to the umbilicus would not be present.

(Choice B) Granulation tissue is new connective tissue that forms in response to wound healing, and the peritoneum is the lining of the abdominal cavity. These tissues are not contained in a Meckel diverticulum.

(Choice C) False diverticula contain only mucosa and submucosa. These layers herniate through defects in the muscular layer. Colonic and Zenker (upper esophageal) diverticula are examples of false diverticula.

(Choice D) Tumors of the omentum (ie, adipose tissue covering the abdominal organs) are a rare cause of abdominal pain and vomiting but are not associated with an outpouching of the ileum.

Educational objective:
Meckel diverticulum, which classically causes painless hematochezia but can present with acute abdominal pain if inflamed (ie, diverticulitis), is an anatomic connection between the ileum and umbilicus resulting from incomplete obliteration of the vitelline duct. This congenital anomaly is a true diverticulum, consisting of all 3 layers of the intestinal wall (mucosa, submucosa, and muscularis).

Embryology	Gastrointestinal & Nutrition	Meckel diverticulum
Subject	System	Topic

https://t.me/USMLEWorldStep1

A 60-year-old woman comes to the office with persistent, profuse mucoid diarrhea. Despite not eating much for the past 2 days, her diarrhea has not decreased, but she has no other symptoms. The patient has not had age-appropriate colon cancer screening. Family history is unremarkable. She does not use tobacco, alcohol, or illicit drugs. Vital signs and cardiopulmonary examination are normal. The abdomen is soft and nondistended. There is no hepatosplenomegaly. Laboratory studies show hypokalemia and microcytic anemia. Colonoscopy reveals a 2.5-cm, cauliflower-like mass in the sigmoid colon. The mass is resected and the histopathology of the lesion is shown in the exhibit. Which of the following is the most likely diagnosis in this patient?

- A. Carcinoid tumor
- B. Hamartomatous polyp
- C. Hyperplastic polyp
- D. Signet ring cell carcinoma
- E. Villous adenoma

Submit

https://t.me/USMLEWorldStep1

A 60-year-old woman comes to the office with persistent, profuse mucoid diarrhea. Despite not eating much for the past 2
approp
drugs.
no hep
2.5-cm
shown

Sub

Exhibit Display

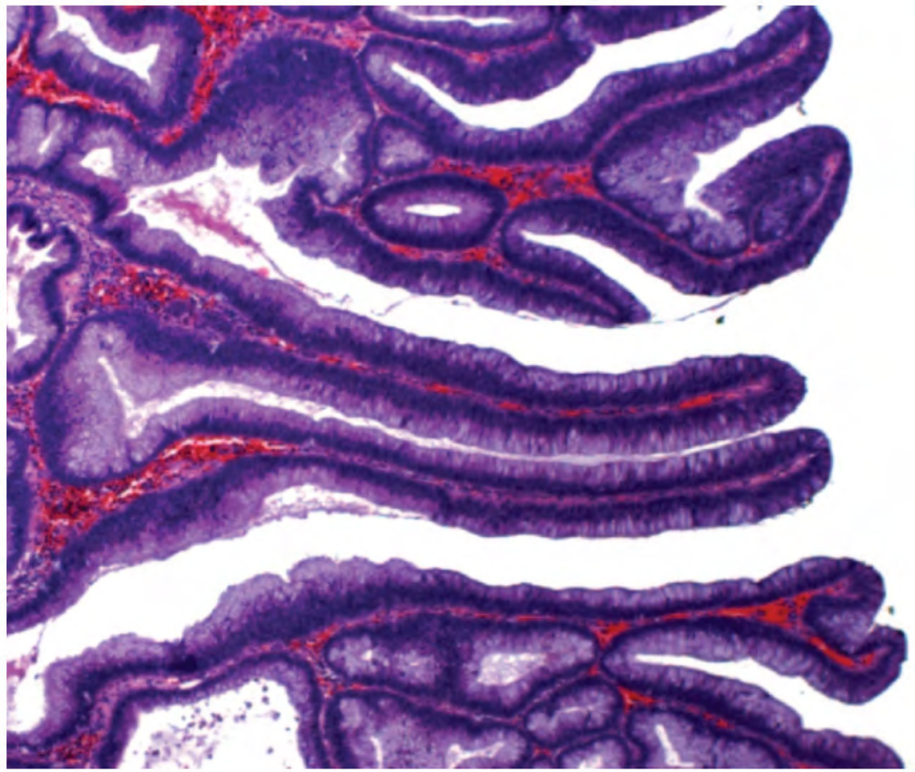

Zoom In Zoom Out Reset New | Existing My Notebook

https://t.me/USMLEWorldStep1

A 60-year-old woman comes to the office with persistent, profuse mucoid diarrhea. Despite not eating much for the past 2 days, her diarrhea has not decreased, but she has no other symptoms. The patient has not had age-appropriate colon cancer screening. Family history is unremarkable. She does not use tobacco, alcohol, or illicit drugs. Vital signs and cardiopulmonary examination are normal. The abdomen is soft and nondistended. There is no hepatosplenomegaly. Laboratory studies show hypokalemia and microcytic anemia. Colonoscopy reveals a 2.5-cm, cauliflower-like mass in the sigmoid colon. The mass is resected and the histopathology of the lesion is shown in the exhibit. Which of the following is the most likely diagnosis in this patient?

- ✗ A. Carcinoid tumor (7%)
- B. Hamartomatous polyp (7%)
- C. Hyperplastic polyp (7%)
- D. Signet ring cell carcinoma (1%)
- ✓ E. Villous adenoma (75%)

Incorrect
Correct answer
E

75%
Answered correctly

16 secs
Time Spent

2023
Version

Explanation

Villous adenoma

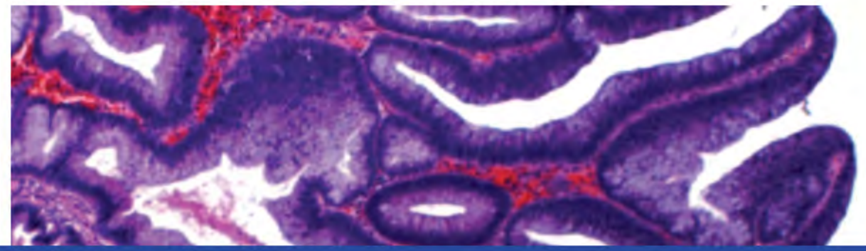

https://t.me/USMLEWorldStep1

✓ ○ E. Villous adenoma (75%)

Inco
Corre
E

Expl

Exhibit Display

Villous adenoma

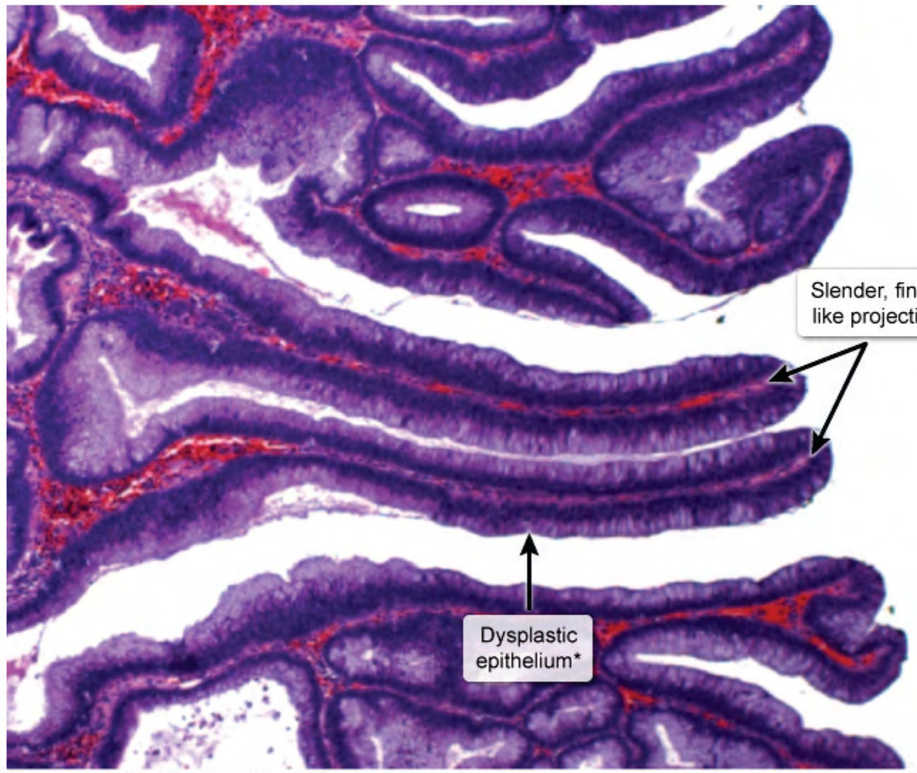

*Crowded cells with dark, elongated nuclei.

©UWorld

Zoom In | Zoom Out | Reset | New | Existing | My Notebook

*Crowded cells with dark, elongated nuclei.
©UWorld

https://t.me/USMLEWorldStep1

*Crowded cells with dark, elongated nuclei.

©UWorld

Biopsy of this patient's mass demonstrates long glands with finger-like (villous) projections extending from the surface as well as dysplastic epithelium, which are characteristic of a **villous adenoma**. A villous adenoma is often large and sessile and can have velvety or cauliflower-like projections. By contrast, a tubular adenoma is composed of dysplastic colonic mucosal cells that form tube-shaped glands and tends to be smaller and pedunculated. A mixture of these 2 types indicates a tubulovillous adenoma. Of these, villous adenomas are the most likely to undergo **malignant transformation**.

Adenomas in the colon can cause occult or visible bleeding, leading to iron-deficiency anemia. Large polyps may occasionally cause partial obstruction with pain, constipation, and abdominal distension. In addition, villous adenomas can produce large quantities of prostaglandin E2, which results in **increased mucin** production and a **secretory diarrhea** characterized by watery, mucinous stools. Mucin is a potassium-rich glycoprotein; excessive production can result in **hypoproteinemia** and **hypokalemia**.

(Choice A) Intestinal carcinoids can cause diarrhea and are often associated with additional symptoms such as flushing, wheezing, and vascular telangiectasia when they metastasize. Histopathology is typified by insular (nesting) masses of small, round cells with peripheral palisading, granular cytoplasm, small nucleoli, and salt-and-pepper chromatin.

(Choice B) Hamartomatous polyps consist of disorganized mucosal glands, smooth muscle, and connective tissue. They may occur sporadically or in Peutz-Jeghers syndrome or juvenile polyposis. These polyps can cause bleeding and intussusception, but not secretory diarrhea.

(Choice C) Hyperplastic polyps are characterized by a proliferation of nondysplastic epithelial cells resulting in a serrated or "sawtoothed" architecture seen in the upper parts of the crypts. They are typically small lesions and almost always asymptomatic.

(Choice D) Signet ring cell carcinoma can occur in different locations, such as the stomach, breast, ovary, and colorectal area. Tumor cells contain abundant mucins that push the nuclei to the periphery and give the tumor cells their characteristic appearance.

Educational objective:

https://t.me/USMLEWorldStep1

most likely to undergo **malignant transformation**.

Adenomas in the colon can cause occult or visible bleeding, leading to iron-deficiency anemia. Large polyps may occasionally cause partial obstruction with pain, constipation, and abdominal distension. In addition, villous adenomas can produce large quantities of prostaglandin E2, which results in **increased mucin** production and a **secretory diarrhea** characterized by watery, mucinous stools. Mucin is a potassium-rich glycoprotein; excessive production can result in **hypoproteinemia** and **hypokalemia**.

(Choice A) Intestinal carcinoids can cause diarrhea and are often associated with additional symptoms such as flushing, wheezing, and vascular telangiectasia when they metastasize. Histopathology is typified by insular (nesting) masses of small, round cells with peripheral palisading, granular cytoplasm, small nucleoli, and salt-and-pepper chromatin.

(Choice B) Hamartomatous polyps consist of disorganized mucosal glands, smooth muscle, and connective tissue. They may occur sporadically or in Peutz-Jeghers syndrome or juvenile polyposis. These polyps can cause bleeding and intussusception, but not secretory diarrhea.

(Choice C) Hyperplastic polyps are characterized by a proliferation of nondysplastic epithelial cells resulting in a serrated or "sawtoothed" architecture seen in the upper parts of the crypts. They are typically small lesions and almost always asymptomatic.

(Choice D) Signet ring cell carcinoma can occur in different locations, such as the stomach, breast, ovary, and colorectal area. Tumor cells contain abundant mucins that push the nuclei to the periphery and give the tumor cells their characteristic appearance.

Educational objective:
Adenomatous polyps are either tubular, villous, or tubulovillous, depending on their histologic appearance. Villous adenomas tend to be larger, sessile, and more severely dysplastic than tubular adenomas. Villous adenomas can cause a secretory diarrhea from increased mucin production; patients may develop hypoproteinemia and hypokalemia.

Pathology	Gastrointestinal & Nutrition	Colorectal polyps and cancer
Subject	System	Topic

https://t.me/USMLEWorldStep1

Dysplastic

Exhibit Display

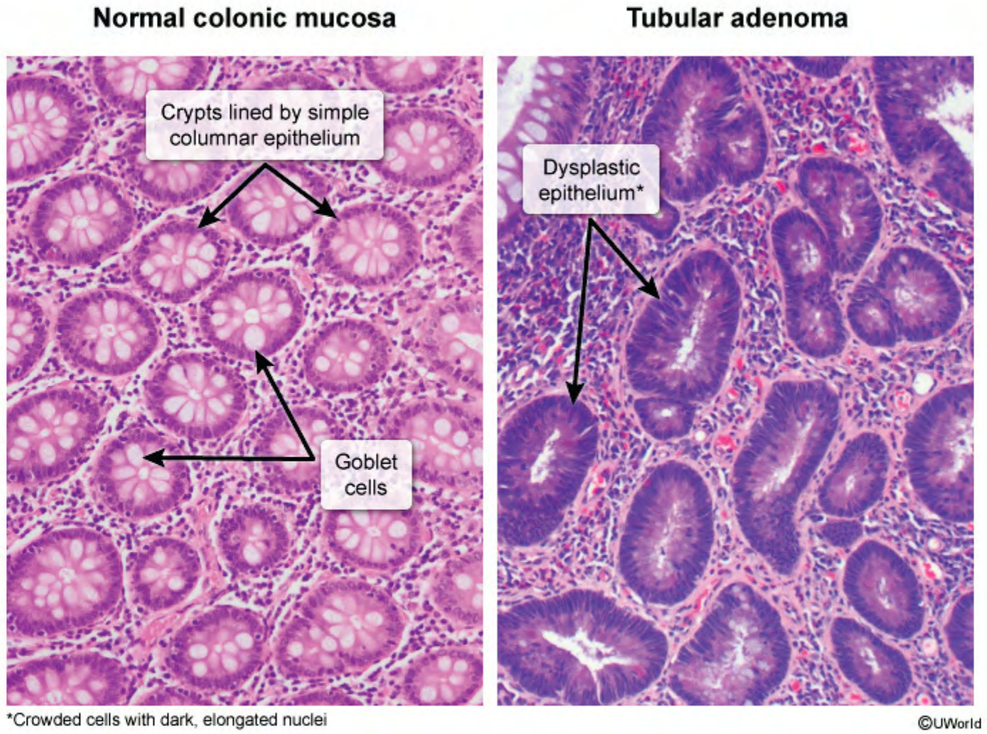

Zoom In | Zoom Out | Reset | New | Existing | My Notebook

Biopsy
surfac
often l
compo
pedun
most li

Adeno
occasi
adeno
secret
produc

(Choic
flushin
(nestir
peppe

(Choic
tissue.
bleedi

(Choic
serrate
almost

(Choice D) Signet ring cell carcinoma can occur in different locations, such as the stomach, breast, ovary, and

https://t.me/USMLEWorldStep1

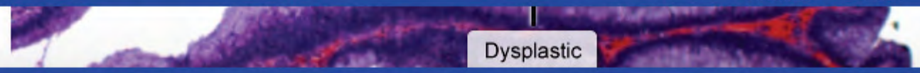

Exhibit Display

Gastric well-differentiated neuroendocrine (carcinoid) tumor

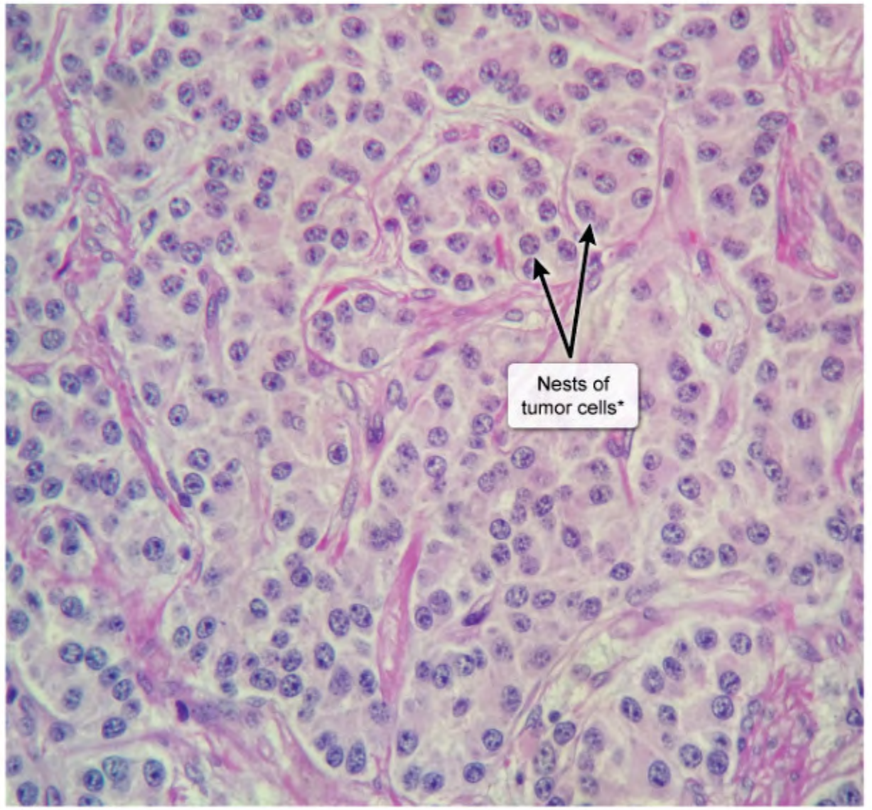

*Round nuclei, eosinophilic cytoplasm, and "salt and pepper" chromatin

©UWorld

Zoom In | Zoom Out | Reset | New | Existing | My Notebook

Biopsy
surfac
often l
compo
pedun
most li

Adeno
occasi
adeno
secret
produc

(Choi
flushin
(nestin
peppe

(Choi
tissue.
bleedi

(Choi
serrate
almost

(Choice D) Signet ring cell carcinoma can occur in different locations, such as the stomach, breast, ovary, and

https://t.me/USMLEWorldStep1

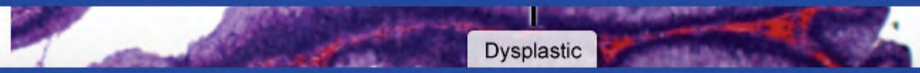

Exhibit Display

Hamartomatous polyp of Peutz-Jeghers syndrome

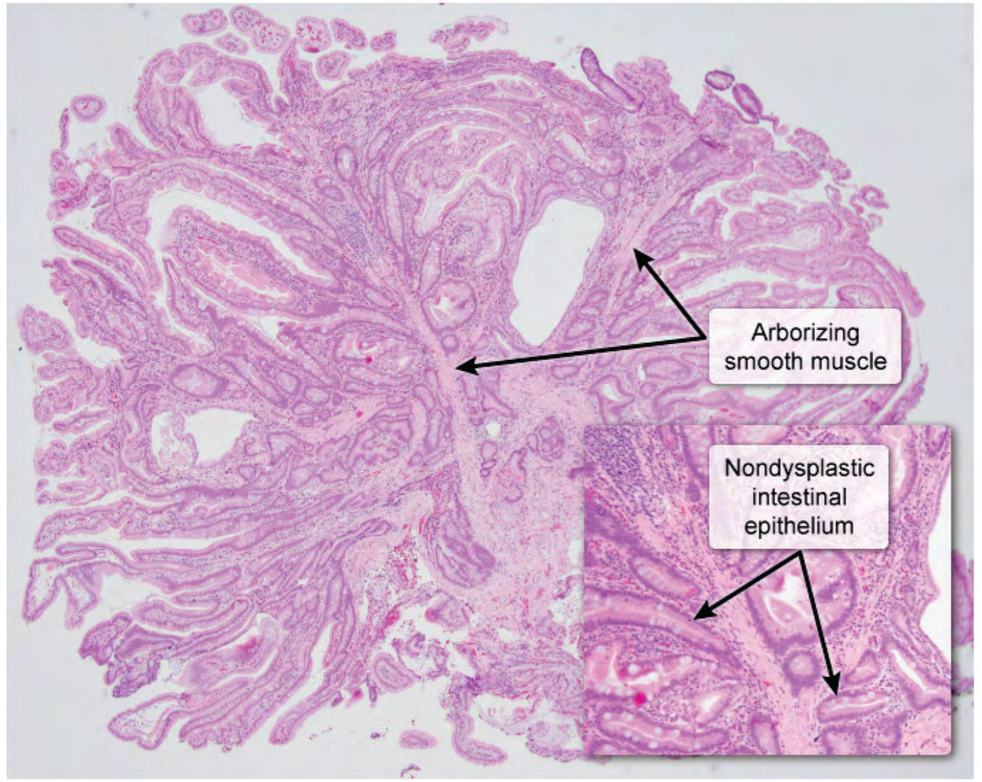

©UWorld

Zoom In | Zoom Out | Reset | New | Existing | My Notebook

Biopsy
surfac
often l
compo
pedun
most li

Adeno
occasi
adeno
secret
produc

(Choi
flushin
(nestin
peppe

(Choi
tissue.
bleedi

(Choi
serrate
almost

(Choice D) Signet ring cell carcinoma can occur in different locations, such as the stomach, breast, ovary, and

https://t.me/USMLEWorldStep1

*Crowded cells with dark, elongated nuclei.

©UWorld

Biopsy
surfac
often l
compo
pedun
most li

Adeno
occasi
adeno
secret
produc

(Choi
flushin
(nestin
peppe

(Choi
tissue.
bleedi

(Choi
serrate
almost

(Choi
colore
cells th

Educational objective:

Exhibit Display

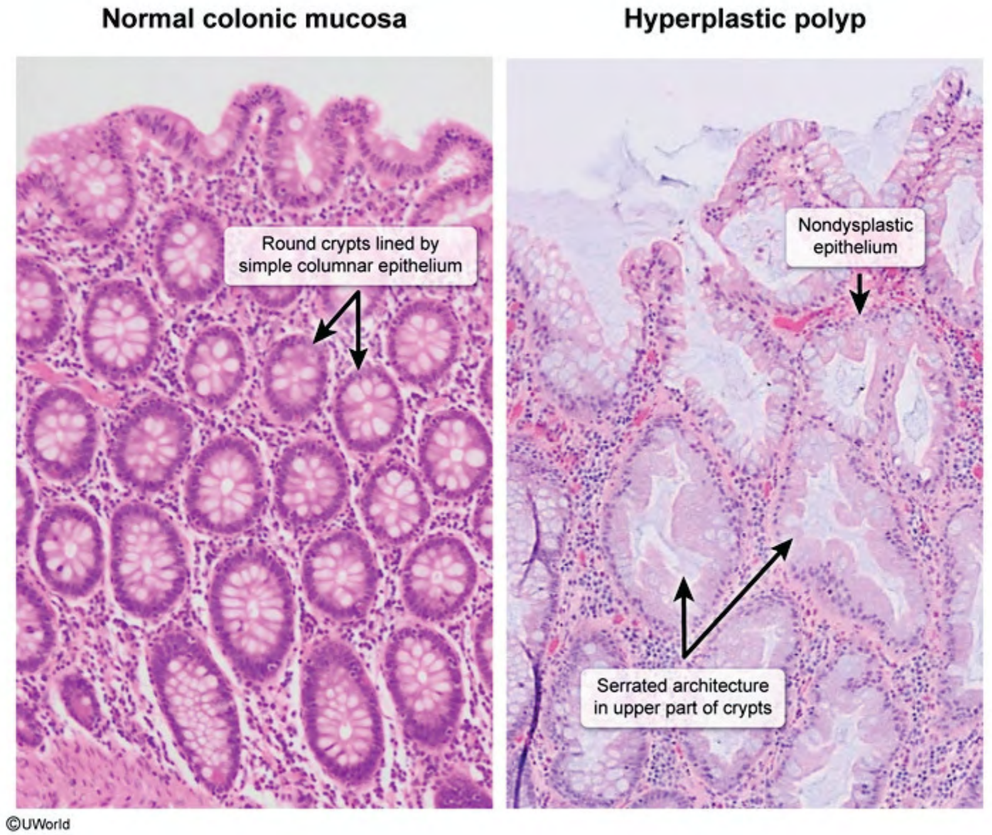

Zoom In | Zoom Out | Reset | New | Existing | My Notebook

https://t.me/USMLEWorldStep1

A 45-year-old man comes to the office due to several months of diarrhea. The patient experiences watery diarrhea shortly after eating, occasional abdominal discomfort, easy fatigability, and unintentional weight loss. He has a history of Crohn disease for which he takes mesalamine. The patient also takes prednisone intermittently for disease exacerbations, and 6 months ago he was treated with metronidazole for a perianal abscess. Surgical history includes several intestinal resections due to complications of Crohn disease. He does not use tobacco or illicit drugs but drinks alcohol occasionally. Physical examination shows conjunctival pallor. The abdomen is nondistended, soft, and nontender. Vibratory and position sense are decreased in the lower extremities. Stool guaiac test is negative. Laboratory studies show macrocytic anemia and a low vitamin B_{12} level. Which of the following is the most likely cause of this patient's presenting symptoms?

- A. Hormone-induced luminal secretion
- B. Infection with a protozoan parasite
- C. Infection with gram-positive, PAS-positive bacilli
- D. Loss of intestinal absorptive area
- E. Medication adverse effect
- F. Pancreatic enzyme deficiency
- G. Postprandial rapid fluid shifts

Submit

https://t.me/USMLEWorldStep1

A 45-year-old man comes to the office due to several months of diarrhea. The patient experiences watery diarrhea shortly after eating, occasional abdominal discomfort, easy fatigability, and unintentional weight loss. He has a history of Crohn disease for which he takes mesalamine. The patient also takes prednisone intermittently for disease exacerbations, and 6 months ago he was treated with metronidazole for a perianal abscess. Surgical history includes several intestinal resections due to complications of Crohn disease. He does not use tobacco or illicit drugs but drinks alcohol occasionally. Physical examination shows conjunctival pallor. The abdomen is nondistended, soft, and nontender. Vibratory and position sense are decreased in the lower extremities. Stool guaiac test is negative. Laboratory studies show macrocytic anemia and a low vitamin B_{12} level. Which of the following is the most likely cause of this patient's presenting symptoms?

- A. Hormone-induced luminal secretion (0%)
- ✗ B. Infection with a protozoan parasite (2%)
- C. Infection with gram-positive, PAS-positive bacilli (2%)
- ✓ D. Loss of intestinal absorptive area (87%)
- E. Medication adverse effect (2%)
- F. Pancreatic enzyme deficiency (2%)
- G. Postprandial rapid fluid shifts (1%)

Incorrect
Correct answer
D

87%
Answered correctly

03 secs
Time Spent

2023
Version

Explanation

This patient likely has **short bowel syndrome**, a malabsorptive condition that typically occurs in patients with massive **small bowel resection** and/or **Crohn disease**. Extensive intestinal disease or resection results in loss of absorptive surface area and a decrease in intestinal transit time, leading to postprandial voluminous diarrhea and

https://t.me/USMLEWorldStep1

Explanation

This patient likely has **short bowel syndrome**, a malabsorptive condition that typically occurs in patients with massive **small bowel resection** and/or **Crohn disease**. Extensive intestinal disease or resection results in loss of absorptive surface area and a decrease in intestinal transit time, leading to postprandial voluminous diarrhea and weight loss due to **malabsorption** of macro- and micronutrients.

Loss of functional distal ileum may specifically result in **vitamin B_{12} deficiency** with macrocytic anemia, peripheral neuropathy, and subacute combined degeneration of the spinal cord (eg, impaired vibration and position sense).

(Choice A) VIPoma is a pancreatic neuroendocrine tumor that secretes vasoactive intestinal polypeptide, resulting in secretory watery diarrhea (persists with fasting) and flushing. Malabsorption of macro- and micronutrients is not characteristic.

(Choice B) Giardia is a protozoan parasite that may cause chronic diarrhea and malabsorption; however, infection typically occurs in high-risk individuals such infants, campers/hikers drinking from mountain streams, those who are immunocompromised, and travelers to resource-limited areas.

(Choice C) Whipple disease is a rare multisystemic disorder caused by *Tropheryma whipplei*, a gram-positive, periodic acid-Schiff (PAS)-positive bacilli. Patients typically present with migratory polyarthritis followed by abdominal pain and malabsorptive diarrhea. Neurologic symptoms (eg, cognitive dysfunction, myoclonus) and cardiac disease (eg, endocarditis) are also characteristic.

(Choice E) Numerous medications can cause diarrhea as an adverse effect; however, this is unlikely in this patient with malabsorption, vitamin B_{12} deficiency, and weight loss in the setting of Crohn disease and intestinal resection.

(Choice F) Chronic pancreatitis is most commonly caused by alcohol abuse and typically presents with abdominal pain and pancreatic insufficiency. Patients often have chronic diarrhea/malabsorption due to lack of digestive enzymes (exocrine insufficiency) and diabetes mellitus due to endocrine insufficiency.

(Choice G) Dumping syndrome may occur after gastric bypass surgery or damage to the pyloric sphincter. Emptying of hyperosmolar chyme into the small intestine causes a rapid shift of fluid from the serum to the

https://t.me/USMLEWorldStep1

in secretory watery diarrhea (persists with fasting) and flushing. Malabsorption of macro- and micronutrients is not characteristic.

(Choice B) Giardia is a protozoan parasite that may cause chronic diarrhea and malabsorption; however, infection typically occurs in high-risk individuals such infants, campers/hikers drinking from mountain streams, those who are immunocompromised, and travelers to resource-limited areas.

(Choice C) Whipple disease is a rare multisystemic disorder caused by *Tropheryma whipplei*, a gram-positive, periodic acid-Schiff (PAS)-positive bacilli. Patients typically present with migratory polyarthritis followed by abdominal pain and malabsorptive diarrhea. Neurologic symptoms (eg, cognitive dysfunction, myoclonus) and cardiac disease (eg, endocarditis) are also characteristic.

(Choice E) Numerous medications can cause diarrhea as an adverse effect; however, this is unlikely in this patient with malabsorption, vitamin B_{12} deficiency, and weight loss in the setting of Crohn disease and intestinal resection.

(Choice F) Chronic pancreatitis is most commonly caused by alcohol abuse and typically presents with abdominal pain and pancreatic insufficiency. Patients often have chronic diarrhea/malabsorption due to lack of digestive enzymes (exocrine insufficiency) and diabetes mellitus due to endocrine insufficiency.

(Choice G) Dumping syndrome may occur after gastric bypass surgery or damage to the pyloric sphincter. Emptying of hyperosmolar chyme into the small intestine causes a rapid shift of fluid from the serum to the intestine, resulting in postprandial gastrointestinal (eg, nausea/vomiting, cramps, diarrhea) and vasomotor symptoms (eg, diaphoresis, flushing).

Educational objective:
Short bowel syndrome typically occurs in patients with massive small bowel resection and/or Crohn disease due to loss of intestinal absorptive surface area and a decrease in intestinal transit time. Patients usually present with postprandial voluminous diarrhea and weight loss due to malabsorption. Loss of functional distal ileum may result in vitamin B_{12} deficiency.

References

- Short bowel syndrome: a review of management options.

https://t.me/USMLEWorldStep1

A 39-year-old woman comes to the emergency department due to several episodes of severe upper abdominal pain. Her pain is triggered by fatty foods and resolves spontaneously. The symptoms first began a few months earlier after an uncomplicated pregnancy. Past medical history is notable for hypertension, for which the patient takes a calcium channel blocker, and hypertriglyceridemia, which is treated with a fibrate. Temperature is 37.2 C (98.9 F) and blood pressure is 143/76 mm Hg. The patient weighs 95 kg (210 lb) and is 173 cm (5 ft 8 in) tall. Ultrasound reveals thickening of the gallbladder wall, with tenderness elicited by the ultrasound probe directly over the gallbladder. She undergoes a laparoscopic cholecystectomy, with multiple stones noted in the contents of the gallbladder. Decreased activity of which of the following enzymes would most likely have contributed to this patient's condition?

- A. Aromatase
- B. β-glucuronidase
- C. Cholesterol 7α-hydroxylase
- D. HMG-CoA reductase
- E. Thiolase

Submit

https://t.me/USMLEWorldStep1

A 39-year-old woman comes to the emergency department due to several episodes of severe upper abdominal pain. Her pain is triggered by fatty foods and resolves spontaneously. The symptoms first began a few months earlier after an uncomplicated pregnancy. Past medical history is notable for hypertension, for which the patient takes a calcium channel blocker, and hypertriglyceridemia, which is treated with a fibrate. Temperature is 37.2 C (98.9 F) and blood pressure is 143/76 mm Hg. The patient weighs 95 kg (210 lb) and is 173 cm (5 ft 8 in) tall. Ultrasound reveals thickening of the gallbladder wall, with tenderness elicited by the ultrasound probe directly over the gallbladder. She undergoes a laparoscopic cholecystectomy, with multiple stones noted in the contents of the gallbladder. Decreased activity of which of the following enzymes would most likely have contributed to this patient's condition?

- A. Aromatase (3%)
- ✗ B. β-glucuronidase (14%)
- ✓ C. Cholesterol 7α-hydroxylase (65%)
- D. HMG-CoA reductase (14%)
- E. Thiolase (2%)

Incorrect
Correct answer
C

65%
Answered correctly

03 secs
Time Spent

2023
Version

Explanation

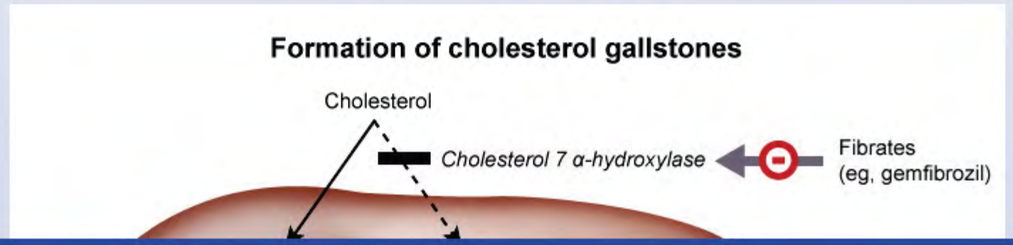

https://t.me/USMLEWorldStep1

C. Cholesterol 7α-hydroxylase (65%)

D. HMG-CoA reductase (14%)

Incc
Corre
C

Expl

Exhibit Display

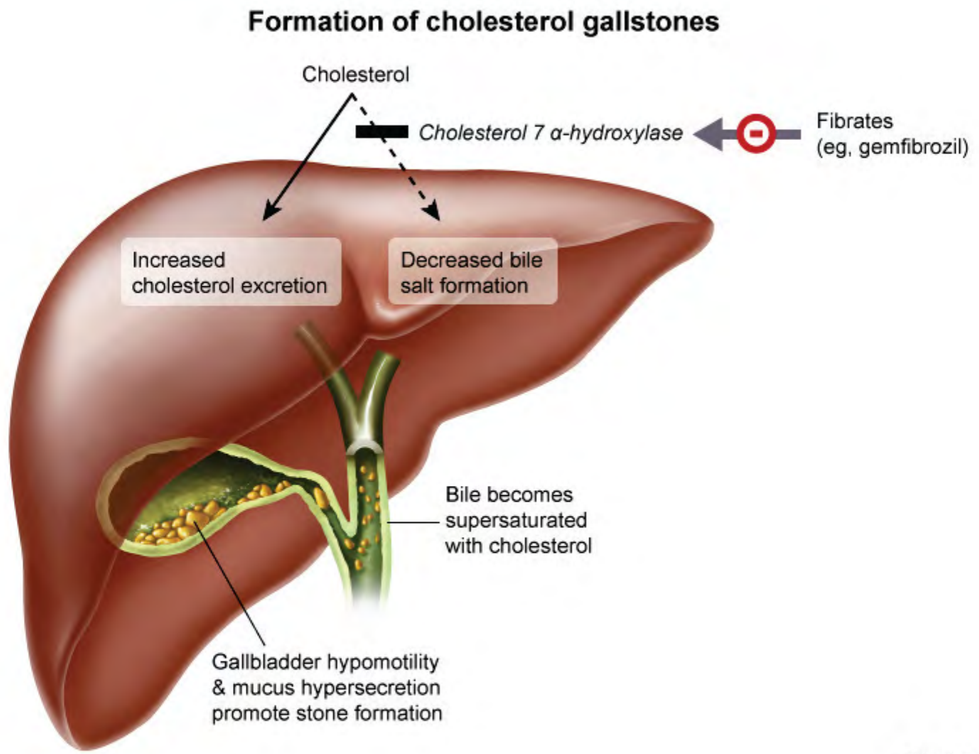

Zoom In | Zoom Out | Reset | New | Existing | My Notebook

promote stone formation

©UWorld

https://t.me/USMLEWorldStep1

promote stone formation

©UWorld

This patient, with recurring abdominal pain, a positive "sonographic Murphy sign," and multiple cholesterol **gallstones**, has acute cholecystitis. Water-insoluble **cholesterol** is secreted in bile, where it is solubilized by detergent-like bile salts and phosphatidylcholine. If there is more cholesterol than can be dissolved by the bile salts, it will precipitate into insoluble crystals, leading to formation of gallstones. Risk factors for gallstone formation include obesity or rapid weight loss, female sex, glucose intolerance, and hypomotility of the gallbladder (eg, pregnancy, prolonged fasting).

Fibrate medications (eg, fenofibrate, gemfibrozil) upregulate lipoprotein lipase, resulting in increased oxidation of fatty acids. In addition, fibrates inhibit **cholesterol 7α-hydroxylase**, which catalyzes the rate-limiting step in the synthesis of bile acids. The reduced bile acid production results in decreased cholesterol solubility in bile and favors the formation of cholesterol stones.

(Choice A) Estrogens increase the biosynthesis of cholesterol by upregulating hepatic HMG-CoA reductase activity. Estrogenic medications (eg, estrogen replacement therapy, combined oral contraceptives) increase the amount of cholesterol secreted in bile and contribute to formation of gallstones. Aromatase catalyzes the conversion of androgens to estrogen; inhibition would lead to reduced gallstone formation.

(Choice B) β-glucuronidase is released by damaged hepatocytes and bacteria in infected bile. It deconjugates bilirubin, and the resulting free bilirubin precipitates with calcium in the bile to form pigmented gallstones. Decreased activity of this enzyme would reduce the formation of pigmented stones but would not affect the formation of cholesterol gallstones.

(Choices D and E) The first step in cholesterol synthesis is the condensation of 2 molecules of acetyl-CoA by acetyl-CoA acetyl transferase (thiolase) to form acetoacetyl-CoA. Condensation with a third molecule of acetyl-CoA yields β-hydroxy-β-methylglutaryl-CoA (HMG-CoA). HMG-CoA reductase then catalyzes the conversion of HMG-CoA to mevalonate, the rate-limiting step in cholesterol synthesis. Decreased activity of these enzymes would reduce cholesterol synthesis and the amount of cholesterol secreted in bile, discouraging cholesterol stone formation.

Educational objective:

https://t.me/USMLEWorldStep1

formation include obesity or rapid weight loss, female sex, glucose intolerance, and hypomotility of the gallbladder (eg, pregnancy, prolonged fasting).

Fibrate medications (eg, fenofibrate, gemfibrozil) upregulate lipoprotein lipase, resulting in increased oxidation of fatty acids. In addition, fibrates inhibit **cholesterol 7α-hydroxylase**, which catalyzes the rate-limiting step in the synthesis of bile acids. The reduced bile acid production results in decreased cholesterol solubility in bile and favors the formation of cholesterol stones.

(Choice A) Estrogens increase the biosynthesis of cholesterol by upregulating hepatic HMG-CoA reductase activity. Estrogenic medications (eg, estrogen replacement therapy, combined oral contraceptives) increase the amount of cholesterol secreted in bile and contribute to formation of gallstones. Aromatase catalyzes the conversion of androgens to estrogen; inhibition would lead to reduced gallstone formation.

(Choice B) β-glucuronidase is released by damaged hepatocytes and bacteria in infected bile. It deconjugates bilirubin, and the resulting free bilirubin precipitates with calcium in the bile to form pigmented gallstones. Decreased activity of this enzyme would reduce the formation of pigmented stones but would not affect the formation of cholesterol gallstones.

(Choices D and E) The first step in cholesterol synthesis is the condensation of 2 molecules of acetyl-CoA by acetyl-CoA acetyl transferase (thiolase) to form acetoacetyl-CoA. Condensation with a third molecule of acetyl-CoA yields β-hydroxy-β-methylglutaryl-CoA (HMG-CoA). HMG-CoA reductase then catalyzes the conversion of HMG-CoA to mevalonate, the rate-limiting step in cholesterol synthesis. Decreased activity of these enzymes would reduce cholesterol synthesis and the amount of cholesterol secreted in bile, discouraging cholesterol stone formation.

Educational objective:
Fibrate medications (eg, fenofibrate, gemfibrozil) inhibit cholesterol 7α-hydroxylase, which catalyzes the rate-limiting step in the synthesis of bile acids. The reduced bile acid production results in decreased cholesterol solubility in bile and favors the formation of cholesterol gallstones.

References

- Safety considerations with fibrate therapy.

https://t.me/USMLEWorldStep1

promote stone formation

This p
gallst
deterg
salts, i
format
(eg, pr
Fibrat
fatty a
synthe
favors
(Choi
activity
amour
conver
(Choi
bilirubi
Decre
format
(Choi
acetyl-
CoA yi
HMG-
would
format

Educational objective:

Exhibit Display

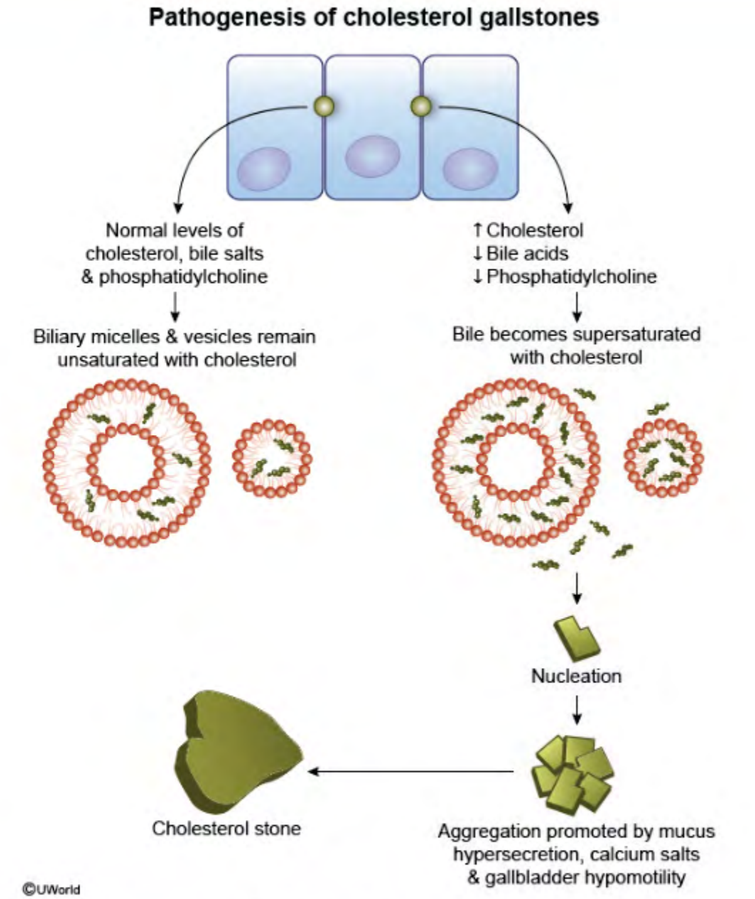

Zoom In | Zoom Out | Reset | New | Existing | My Notebook

https://t.me/USMLEWorldStep1

A 45-year-old man comes to the office due to a 1 year history of abdominal pain and greasy stools. He has also noticed a 7-kg (15.4-lb) weight loss over the past 6 months. Medical history is significant for several years of joint pain in his knees and wrists but is otherwise unremarkable. The patient does not use tobacco or alcohol. After an initial workup, a duodenal biopsy is performed. Microscopic examination shows numerous macrophages in the lamina propria filled with inclusions positive for periodic acid–Schiff stain. Which of the following is the most appropriate treatment for this patient?

- A. Aminosalicylic acid derivatives
- B. Antibiotics
- C. Enzyme supplementation
- D. Modified diet
- E. Surgical resection

Submit

https://t.me/USMLEWorldStep1

A 45-year-old man comes to the office due to a 1 year history of abdominal pain and greasy stools. He has also noticed a 7-kg (15.4-lb) weight loss over the past 6 months. Medical history is significant for several years of joint pain in his knees and wrists but is otherwise unremarkable. The patient does not use tobacco or alcohol. After an initial workup, a duodenal biopsy is performed. Microscopic examination shows numerous macrophages in the lamina propria filled with inclusions positive for periodic acid–Schiff stain. Which of the following is the most appropriate treatment for this patient?

- A. Aminosalicylic acid derivatives (5%)
- ✓ B. Antibiotics (67%)
- C. Enzyme supplementation (8%)
- D. Modified diet (14%)
- E. Surgical resection (4%)

Correct | 67% Answered correctly | 03 secs Time Spent | 2023 Version

Explanation

This patient with joint pain and malabsorption (eg, greasy stools, weight loss) has biopsy findings consistent with **Whipple disease**, a rare, systemic disease caused by chronic infection with the gram-positive bacillus ***Tropheryma whipplei***. It usually presents in middle-aged men (age 40-60) and often affects multiple organ systems, most commonly the small intestine (eg, **abdominal pain**, **diarrhea**, steatorrhea, weight loss), joints (eg, **arthralgia**), and CNS (eg, dementia). *T whipplei* **proliferates within the macrophages** of affected tissues and provokes minimal inflammatory response, allowing persistent infection.

Diagnosis can be confirmed with biopsy of the small intestine, which shows numerous **foamy macrophages** distended by bacilli in the lamina propria. The bacilli are characteristically positive for **periodic acid–Schiff** (PAS),

https://t.me/USMLEWorldStep1

This patient with joint pain and malabsorption (eg, greasy stools, weight loss) has biopsy findings consistent with **Whipple disease**, a rare, systemic disease caused by chronic infection with the gram-positive bacillus ***Tropheryma whipplei***. It usually presents in middle-aged men (age 40-60) and often affects multiple organ systems, most commonly the small intestine (eg, **abdominal pain**, **diarrhea**, steatorrhea, weight loss), joints (eg, **arthralgia**), and CNS (eg, dementia). *T whipplei* **proliferates within the macrophages** of affected tissues and provokes minimal inflammatory response, allowing persistent infection.

Diagnosis can be confirmed with biopsy of the small intestine, which shows numerous **foamy macrophages** distended by bacilli in the lamina propria. The bacilli are characteristically positive for **periodic acid–Schiff** (PAS), which stains polysaccharides in the *T whipplei* membrane. Long-term (ie, ≥12 months) **antibiotic therapy** is usually successful in resolving the symptoms, although relapses can occur.

(Choice A) Aminosalicylic acid derivatives are appropriate treatment for ulcerative colitis (UC). Although UC can present with gastrointestinal symptoms, weight loss, and joint pain, microscopic examination of the intestine typically shows diffuse mucosal inflammation, including crypt abscesses and ulceration.

(Choice C) Digestive enzyme supplementation is appropriate treatment for patients with diminished exocrine pancreatic function (eg, chronic pancreatitis). Patients with chronic pancreatitis may have abdominal discomfort, greasy stools, and weight loss. However, PAS-positive macrophages would not be expected.

(Choice D) A modified diet is indicated for patients with celiac disease or other food-sensitive conditions. Celiac disease can present with abdominal discomfort, greasy stools, and weight loss, but histologic findings typically include duodenal villous blunting, increased intraepithelial lymphocytes, and crypt hyperplasia.

(Choice E) Surgery is appropriate for patients with bowel conditions unresponsive to medical treatment (eg, ischemic infarction). Intestinal infarction typically presents with severe abdominal pain, and microscopic examination may show coagulative necrosis.

Educational objective:
Whipple disease, caused by the gram-positive actinomycete *Tropheryma whipplei,* is a rare systemic illness that often involves the small intestine, joints, and CNS. Classic intestinal histologic findings include foamy macrophages in the lamina propria filled with bacilli positive for periodic acid–Schiff stain. Treatment is with antibiotics.

https://t.me/USMLEWorldStep1

systems, most commonly the small intestine (eg, **abdominal pain**, **diarrhea**, steatorrhea, weight loss), joints (eg, **arthralgia**), and CNS (eg, dementia). *T whipplei* **proliferates within the macrophages** of affected tissues and provokes minimal inflammatory response, allowing persistent infection.

Diagnosis can be confirmed with biopsy of the small intestine, which shows numerous **foamy macrophages** distended by bacilli in the lamina propria. The bacilli are characteristically positive for **periodic acid–Schiff** (PAS), which stains polysaccharides in the *T whipplei* membrane. Long-term (ie, ≥12 months) **antibiotic therapy** is usually successful in resolving the symptoms, although relapses can occur.

(Choice A) Aminosalicylic acid derivatives are appropriate treatment for ulcerative colitis (UC). Although UC can present with gastrointestinal symptoms, weight loss, and joint pain, microscopic examination of the intestine typically shows diffuse mucosal inflammation, including crypt abscesses and ulceration.

(Choice C) Digestive enzyme supplementation is appropriate treatment for patients with diminished exocrine pancreatic function (eg, chronic pancreatitis). Patients with chronic pancreatitis may have abdominal discomfort, greasy stools, and weight loss. However, PAS-positive macrophages would not be expected.

(Choice D) A modified diet is indicated for patients with celiac disease or other food-sensitive conditions. Celiac disease can present with abdominal discomfort, greasy stools, and weight loss, but histologic findings typically include duodenal villous blunting, increased intraepithelial lymphocytes, and crypt hyperplasia.

(Choice E) Surgery is appropriate for patients with bowel conditions unresponsive to medical treatment (eg, ischemic infarction). Intestinal infarction typically presents with severe abdominal pain, and microscopic examination may show coagulative necrosis.

Educational objective:
Whipple disease, caused by the gram-positive actinomycete *Tropheryma whipplei,* is a rare systemic illness that often involves the small intestine, joints, and CNS. Classic intestinal histologic findings include foamy macrophages in the lamina propria filled with bacilli positive for periodic acid–Schiff stain. Treatment is with antibiotics.

References

- Clinical manifestations, treatment, and diagnosis of Tropheryma whipplei infections

https://t.me/USMLEWorldStep1

This patient with joint pain and malabsorption (eg, greasy stools, weight loss) has biopsy findings consistent with

Whipp

Troph

systen

arthra

provok

Diagn

disten

which

usuall

(Choi

preser

typical

(Choi

pancre

greasy

(Choi

diseas

includ

(Choi

ischen

exami

Educa

Whipp

often i

macrophages in the lamina propria filled with bacilli positive for periodic acid–Schiff stain. Treatment is with antibiotics.

Exhibit Display

Whipple disease

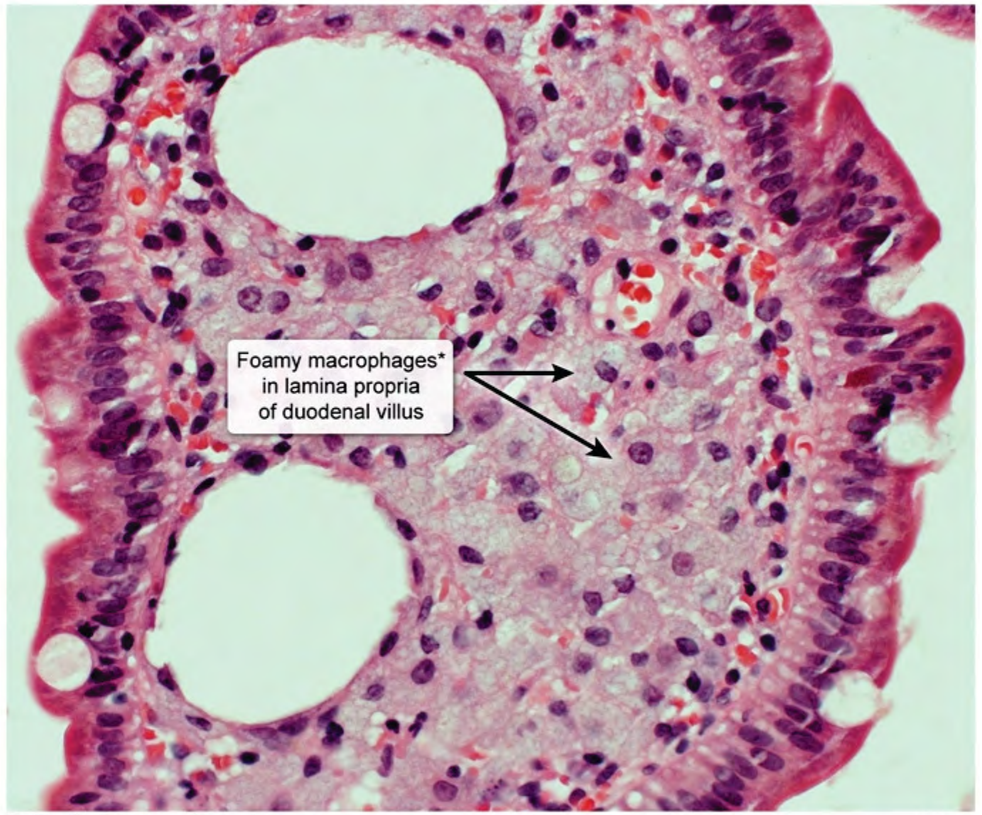

*Contain *Tropheryma whipplei*

©UWorld

Zoom In | Zoom Out | Reset | New | Existing | My Notebook

https://t.me/USMLEWorldStep1

This patient with joint pain and malabsorption (eg, greasy stools, weight loss) has biopsy findings consistent with

Whipp

Troph

systen

arthra

provok

Diagn

disten

which

usuall

(Choi

preser

typical

(Choi

pancre

greasy

(Choi

diseas

includ

(Choi

ischen

exami

Educa

Whipp

often i

macrophages in the lamina propria filled with bacilli positive for periodic acid–Schiff stain. Treatment is with antibiotics.

Exhibit Display

Ulcerative colitis

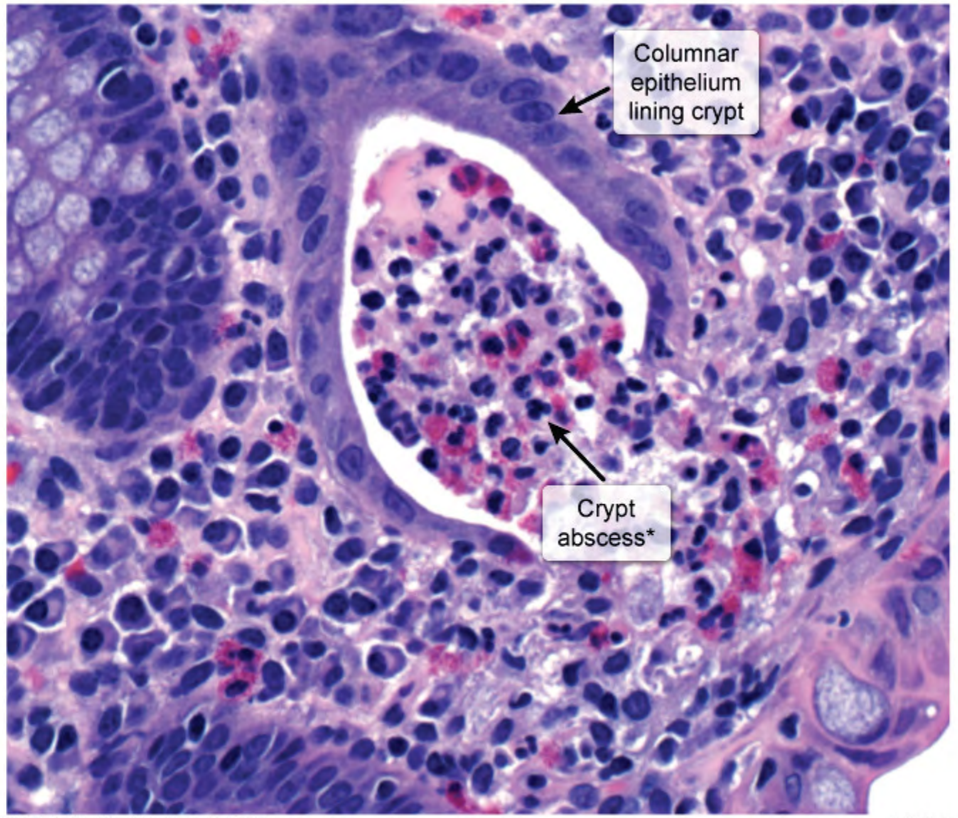

*Neutrophil collection in crypt lumen

©UWorld

Zoom In | Zoom Out | Reset | New | Existing | My Notebook

https://t.me/USMLEWorldStep1

Diagnosis can be confirmed with biopsy of the small intestine, which shows numerous **foamy macrophages** distended by bacilli in the lamina propria. The bacilli are characteristically positive for **periodic acid–Schiff** (PAS), which

usuall

(Choi

preser

typical

(Choi

pancre

greasy

(Choi

diseas

include

(Choi

ischen

exami

Educa

Whipp

often i

macro

antibio

Refere

- Clin

Pathol

Subject

Exhibit Display

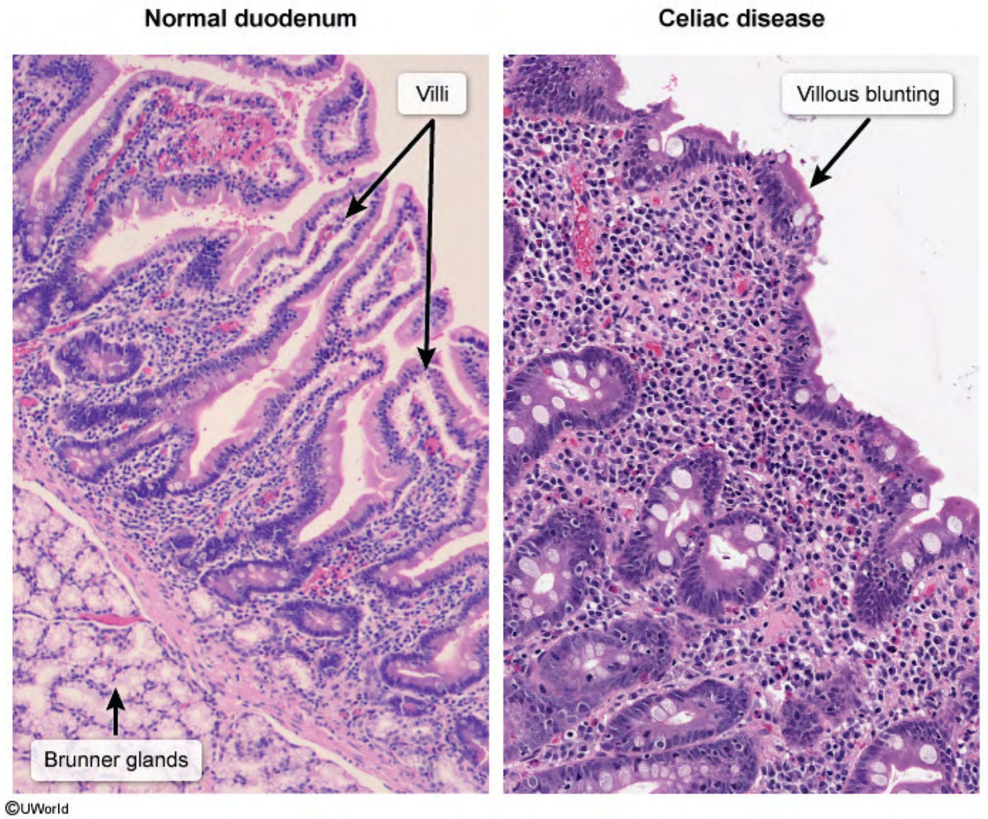

Zoom In | Zoom Out | Reset | New | Existing | My Notebook

Copyright © UWorld. All rights reserved.

https://t.me/USMLEWorldStep1

A 42-year-old man comes to the office due to progressive fatigue, nausea, and itchiness. On review of systems, the patient admits that he occasionally has bloody stools. Medical history is unremarkable. Examination shows scleral icterus. Percutaneous liver biopsy is performed, and histologic analysis of the tissue sample reveals fibrous obliteration of intrahepatic bile ducts with concentric replacement by connective tissue. Which of the following is the most likely diagnosis?

- A. Autoimmune hepatitis
- B. Cytomegalovirus infection
- C. Hemochromatosis
- D. Primary biliary cholangitis
- E. Primary sclerosing cholangitis

Submit

https://t.me/USMLEWorldStep1

A 42-year-old man comes to the office due to progressive fatigue, nausea, and itchiness. On review of systems, the patient admits that he occasionally has bloody stools. Medical history is unremarkable. Examination shows scleral icterus. Percutaneous liver biopsy is performed, and histologic analysis of the tissue sample reveals fibrous obliteration of intrahepatic bile ducts with concentric replacement by connective tissue. Which of the following is the most likely diagnosis?

- ✗ A. Autoimmune hepatitis (3%)
- B. Cytomegalovirus infection (0%)
- C. Hemochromatosis (1%)
- D. Primary biliary cholangitis (19%)
- ✓ E. Primary sclerosing cholangitis (75%)

Incorrect
Correct answer
E

75%
Answered correctly

04 secs
Time Spent

2023
Version

Explanation

Autoimmune liver disease

	Autoimmune hepatitis	Primary biliary cholangitis	Primary sclerosing cholangitis
Epidemiology	• Female > male	• Female >> male	• Male > female
Associations	• Other autoimmune disorders	• Other autoimmune disorders	• IBD (particularly UC)
Liver injury pattern	• Hepatocellular (↑ transaminases)	• Cholestatic (↑ alkaline phosphatase)	• Cholestatic (↑ alkaline phosphatase)

https://t.me/USMLEWorldStep1

Explanation

Autoimmune liver disease			
	Autoimmune hepatitis	**Primary biliary cholangitis**	**Primary sclerosing cholangitis**
Epidemiology	• Female > male	• Female >> male	• Male > female
Associations	• Other autoimmune disorders	• Other autoimmune disorders	• IBD (particularly UC)
Liver injury pattern	• Hepatocellular (↑ transaminases)	• Cholestatic (↑ alkaline phosphatase)	• Cholestatic (↑ alkaline phosphatase)
Antibodies	• Anti–smooth muscle • Antinuclear*	• Antimitochondrial • Antinuclear*	• ± p-ANCA*
Histology	• Interface hepatitis (portal & periportal lymphoplasmacytic infiltrate)	• Florid duct lesion (granulomatous destruction of small bile ducts)	• Fibrous obliteration of bile ducts with concentric periductal deposition of connective tissue (onion skin–like pattern)

*Nonspecific.

IBD = inflammatory bowel disease; **p-ANCA** = perinuclear antineutrophil cytoplasmic antibodies; **UC** = ulcerative colitis.

This patient with fatigue, nausea, pruritus, and scleral icterus has characteristic biopsy findings associated with **primary sclerosing cholangitis** (PSC), a chronic disorder characterized by inflammation, fibrosis, and stricture of the intrahepatic and extrahepatic bile ducts. Histologic features include **fibrous obliteration of the bile ducts** as well as **concentric periductal connective tissue** deposition, which resembles an onion skin–like pattern. PSC affects men disproportionately and has a strong association with **ulcerative colitis**, likely explaining this patient's bloody stools.

https://t.me/USMLEWorldStep1

*Nonspecific.

IBD = inflammatory bowel disease; **p-ANCA** = perinuclear antineutrophil cytoplasmic antibodies; **UC** = ulcerative colitis.

This patient with fatigue, nausea, pruritus, and scleral icterus has characteristic biopsy findings associated with **primary sclerosing cholangitis** (PSC), a chronic disorder characterized by inflammation, fibrosis, and stricture of the intrahepatic and extrahepatic bile ducts. Histologic features include **fibrous obliteration of the bile ducts** as well as **concentric periductal connective tissue** deposition, which resembles an onion skin–like pattern. PSC affects men disproportionately and has a strong association with **ulcerative colitis**, likely explaining this patient's bloody stools.

Manifestations of PSC are related to cholestasis and include **pruritus**, jaundice, and fatigue. Laboratory findings also reflect a **cholestatic pattern** of liver injury and include elevated alkaline phosphatase levels, direct hyperbilirubinemia, and normal to mildly elevated aminotransferases. The diagnosis is typically confirmed with cholangiography (eg, MR or endoscopic retrograde cholangiopancreatography) demonstrating multifocal bile duct stricture with segmental dilations.

(Choice A) Autoimmune hepatitis can cause fatigue, pruritus, and jaundice but is characterized histologically by portal and periportal lymphoplasmacytic infiltration. It is usually diagnosed in women with other autoimmune conditions (eg, celiac disease).

(Choice B) Cytomegalovirus infection can cause hepatitis; however, microscopy typically reveals large cells with basophilic intracytoplasmic and intranuclear inclusions (eg, owl's eye appearance). In addition, it typically occurs in immunocompromised individuals (eg, transplant patients).

(Choice C) Hemochromatosis leads to excessive hepatic iron storage, which results in visible iron deposits within hepatocytes. It is typically associated with diabetes, skin hyperpigmentation, arthralgias, and cardiomyopathy.

(Choice D) Primary biliary cholangitis also causes cholestasis with jaundice and pruritus; however, it is characterized histologically by inflammation and granulomatous destruction of the small bile ducts (eg, florid duct lesions). In addition, it is much more common in women and is not usually associated with inflammatory bowel disease.

Educational objective:

https://t.me/USMLEWorldStep1

affects men disproportionately and has a strong association with **ulcerative colitis**, likely explaining this patient's bloody stools.

Manifestations of PSC are related to cholestasis and include **pruritus**, jaundice, and fatigue. Laboratory findings also reflect a **cholestatic pattern** of liver injury and include elevated alkaline phosphatase levels, direct hyperbilirubinemia, and normal to mildly elevated aminotransferases. The diagnosis is typically confirmed with cholangiography (eg, MR or endoscopic retrograde cholangiopancreatography) demonstrating multifocal bile duct stricture with segmental dilations.

(Choice A) Autoimmune hepatitis can cause fatigue, pruritus, and jaundice but is characterized histologically by portal and periportal lymphoplasmacytic infiltration. It is usually diagnosed in women with other autoimmune conditions (eg, celiac disease).

(Choice B) Cytomegalovirus infection can cause hepatitis; however, microscopy typically reveals large cells with basophilic intracytoplasmic and intranuclear inclusions (eg, owl's eye appearance). In addition, it typically occurs in immunocompromised individuals (eg, transplant patients).

(Choice C) Hemochromatosis leads to excessive hepatic iron storage, which results in visible iron deposits within hepatocytes. It is typically associated with diabetes, skin hyperpigmentation, arthralgias, and cardiomyopathy.

(Choice D) Primary biliary cholangitis also causes cholestasis with jaundice and pruritus; however, it is characterized histologically by inflammation and granulomatous destruction of the small bile ducts (eg, florid duct lesions). In addition, it is much more common in women and is not usually associated with inflammatory bowel disease.

Educational objective:
Primary sclerosing cholangitis is characterized by inflammation, fibrosis, and stricture of intrahepatic and extrahepatic bile ducts. Histologic findings include fibrous obliteration of bile ducts and concentric periductal connective tissue deposition (eg, onion skin–like pattern). Manifestations reflect cholestasis and include jaundice, pruritus, fatigue, and a cholestatic injury pattern (ie, elevated alkaline phosphatase, direct hyperbilirubinemia).

Pathology	Gastrointestinal & Nutrition	Primary Sclerosing Cholangitis
Subject	System	Topic

https://t.me/USMLEWorldStep1

Histology	(portal & periportal	• Florid duct lesion (granulomatous destruction	with concentric periductal

Exhibit Display

Primary sclerosing cholangitis

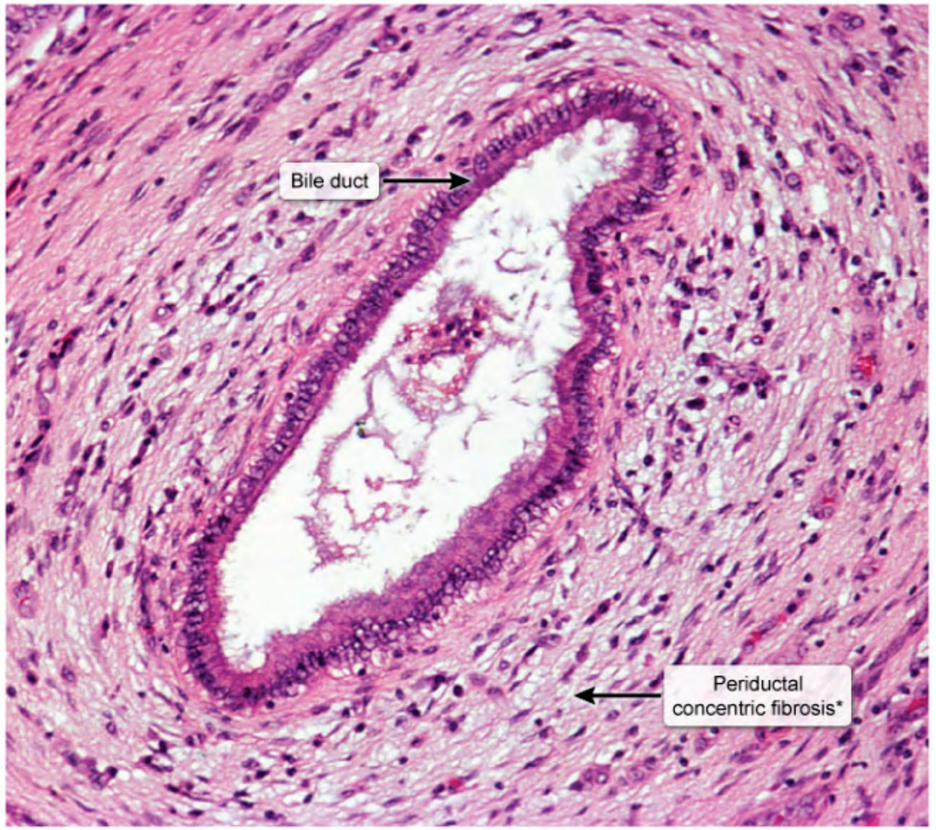

*"Onion-skin" appearance

©UWorld

Zoom In | Zoom Out | Reset | New | Existing | My Notebook

This p
prima
the int
well as
affects
bloody

Manife
also re
hyperb
cholan
strictu

(Choi
portal
conditi

(Choi
basop
immun

(Choi
hepato

(Choice D) Primary biliary cholangitis also causes cholestasis with jaundice and pruritus; however, it is characterized histologically by inflammation and granulomatous destruction of the small bile ducts (eg, florid duct

https://t.me/USMLEWorldStep1

Histology	(portal & periportal	• Florid duct lesion (granulomatous destruction	with concentric periductal

Exhibit Display

Autoimmune hepatitis

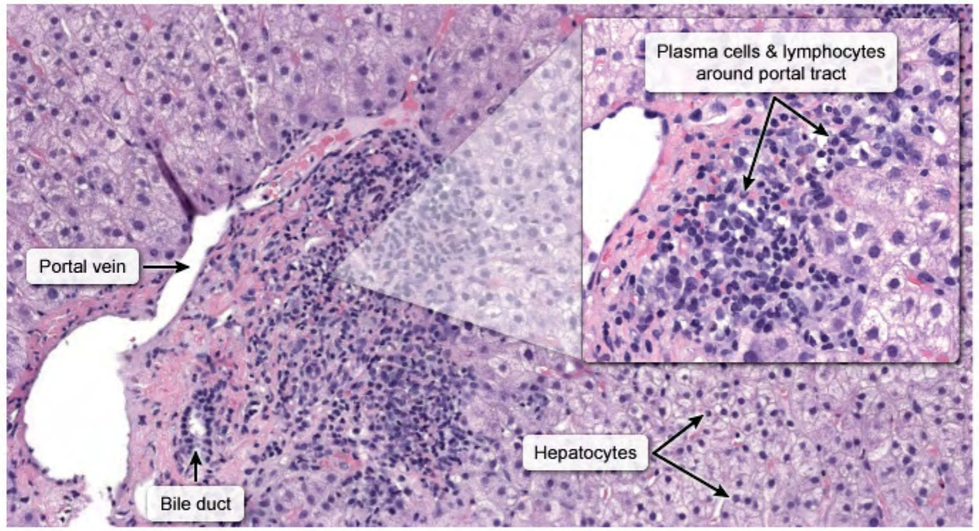

©UWorld

Zoom In | Zoom Out | Reset | New | Existing | My Notebook

This p
prima
the int
well as
affects
bloody

Manife
also re
hyperb
cholan
strictu

(Choi
portal
conditi

(Choi
basop
immun

(Choi
hepato

(Choice D) Primary biliary cholangitis also causes cholestasis with jaundice and pruritus; however, it is characterized histologically by inflammation and granulomatous destruction of the small bile ducts (eg, florid duct

https://t.me/USMLEWorldStep1

Histology	(portal & periportal	• Florid duct lesion (granulomatous destruction	with concentric periductal

Exhibit Display

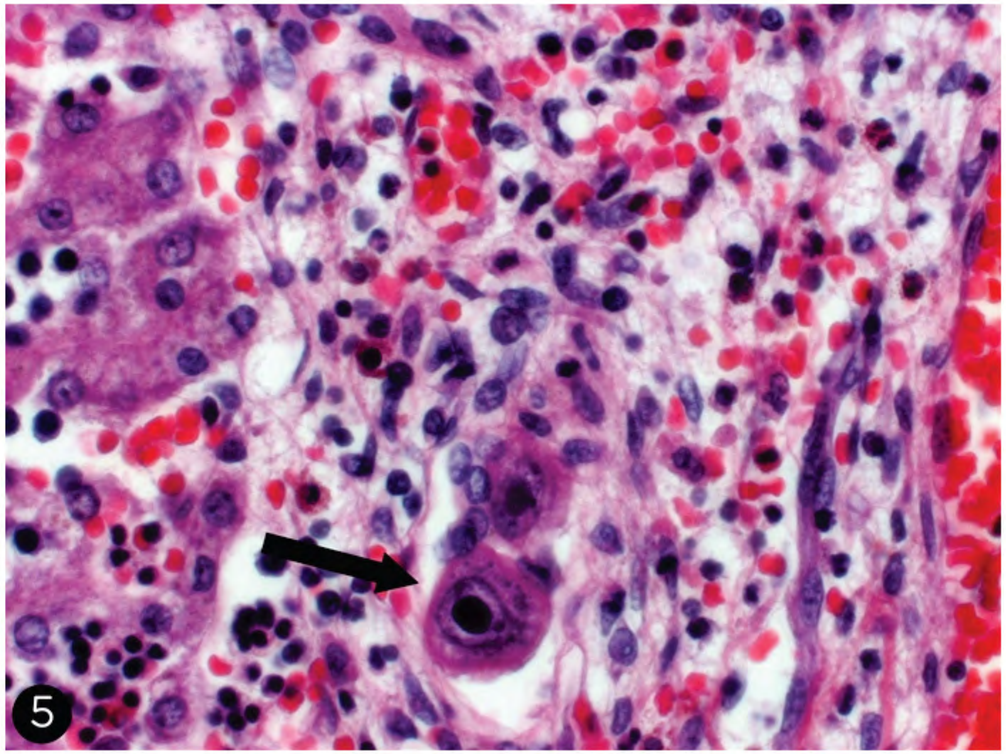

Zoom In Zoom Out Reset New | Existing My Notebook

*N
IBD

This p
prima
the int
well as
affects
bloody

Manife
also re
hyperb
cholan
strictu

(Choi
portal
conditi

(Choi
basop
immun

(Choi
hepato

(Choice D) Primary biliary cholangitis also causes cholestasis with jaundice and pruritus; however, it is characterized histologically by inflammation and granulomatous destruction of the small bile ducts (eg, florid duct

https://t.me/USMLEWorldStep1

bloody stools.

Manife
also re
hyperb
cholan
strictu

(Choi
portal
conditi

(Choi
basop
immur

(Choi
hepato

(Choi
charac
lesions
diseas

Educa
Primar
extrah
conne
pruritu

Pathol
Subject

Exhibit Display

Hemochromatosis

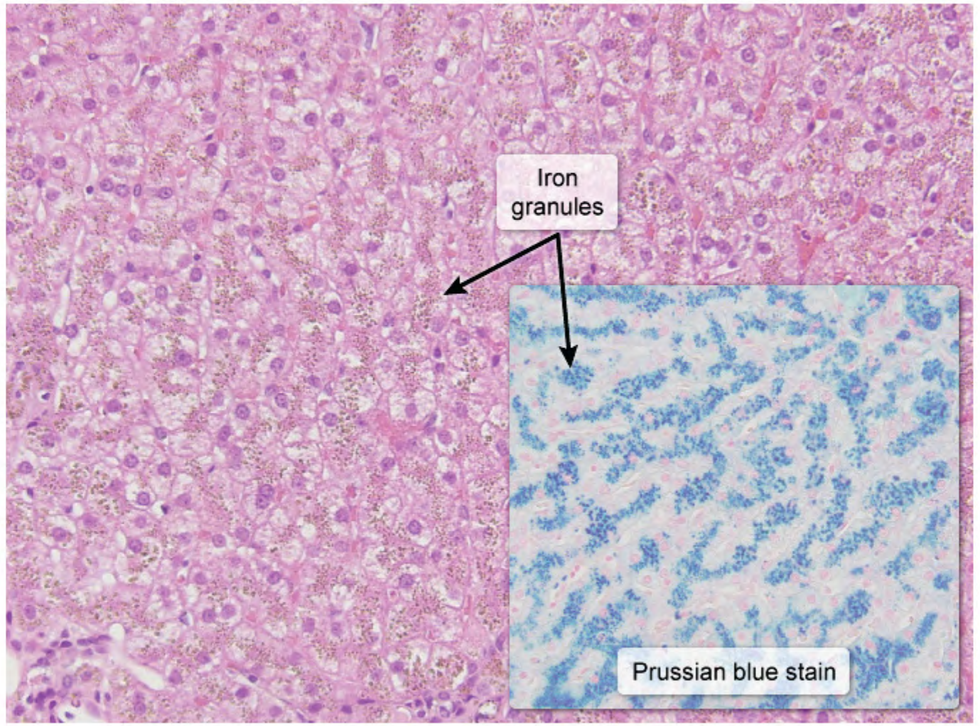

Liver

Zoom In | Zoom Out | Reset | New | Existing | My Notebook

Copyright © UWorld. All rights reserved.

https://t.me/USMLEWorldStep1

bloody stools.

Manife
also re
hyperb
cholan
strictu

(Choi
portal
conditi

(Choi
basop
immun

(Choi
hepato

(Choi
charac
lesions
diseas

Educa
Primar
extrah
conne
pruritu

Patholog
Subject

Exhibit Display

Primary biliary cholangitis

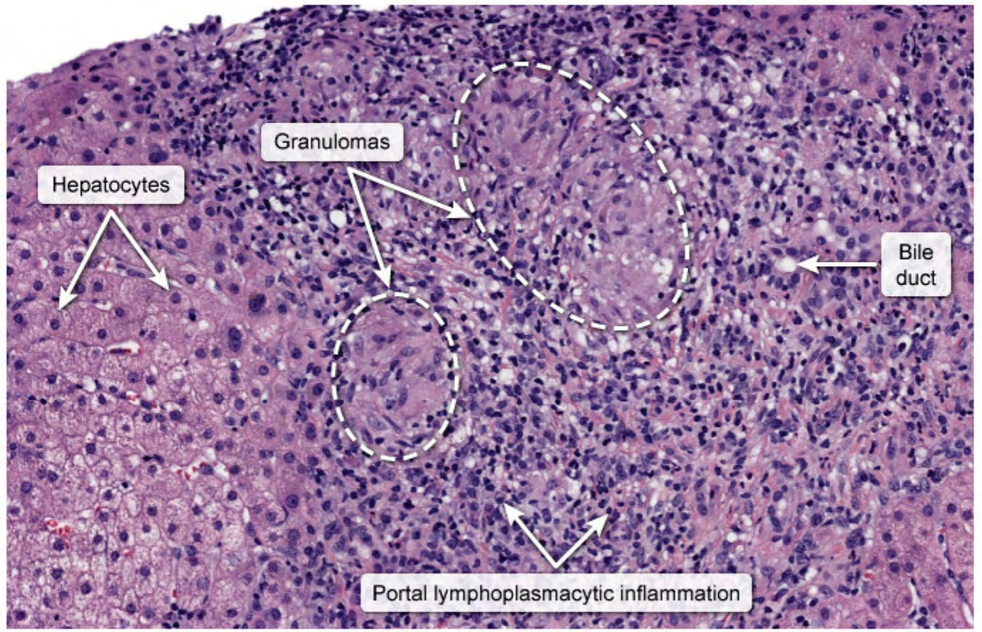

©UWorld

Zoom In | Zoom Out | Reset | New | Existing | My Notebook

Copyright © UWorld. All rights reserved.

https://t.me/USMLEWorldStep1

bloody stools.

Manife
also re
hyperb
cholan
strictu

(Choi
portal
conditi

(Choi
basop
immun

(Choi
hepato

(Choi
charac
lesions
diseas

Educa
Primar
extrah
conne
pruritu

Pathol
Subject

Exhibit Display

Autoimmune hepatitis

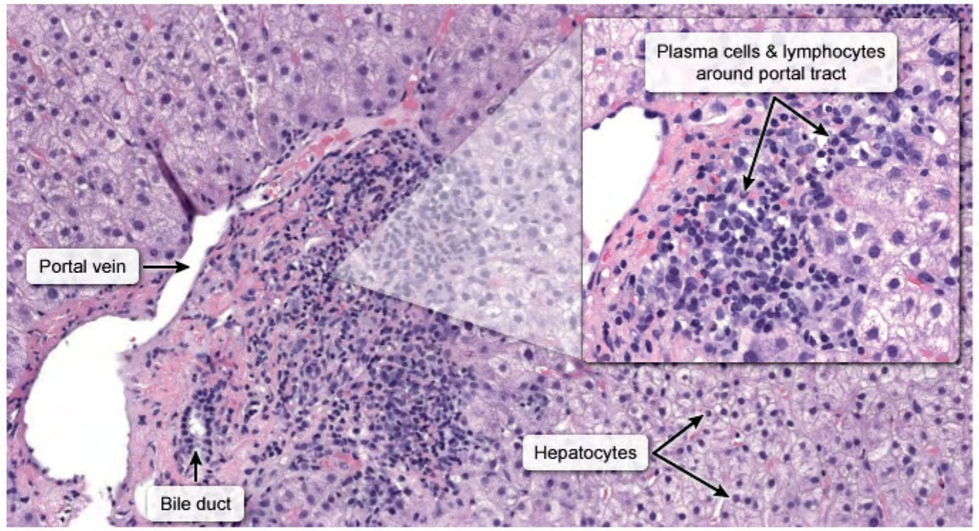

©UWorld

Zoom In | Zoom Out | Reset | New | Existing | My Notebook

Copyright © UWorld. All rights reserved.

https://t.me/USMLEWorldStep1

A 49-year-old man comes to the office for evaluation of a dry cough that occurs mainly at night. His symptoms have been present on and off for several years, but he has not been previously evaluated. The patient also reports a frequent sore throat and occasional epigastric discomfort. He has tried a variety of antihistamines and over-the-counter cough medications without relief. Past medical history is notable for obesity and diet-controlled type 2 diabetes mellitus. He does not smoke or drink alcohol. Cardiopulmonary and abdominal examinations are unremarkable. Chest x-ray reveals no abnormalities, and pulmonary function testing is normal. The patient undergoes upper gastrointestinal endoscopy with mucosal biopsies. Microscopic findings on lower esophageal biopsy are shown in the image below.

This patient is at highest risk of which of the following complications?

- A. Achalasia
- B. Adenocarcinoma
- C. Crohn disease
- D. Squamous cell carcinoma
- E. Variceal bleeding

Submit

https://t.me/USMLEWorldStep1

A 49-year-old man comes to the office for evaluation of a dry cough that occurs mainly at night. His symptoms have b
a frequ
counte
diabet
unrem
underg
biopsy

Exhibit Display

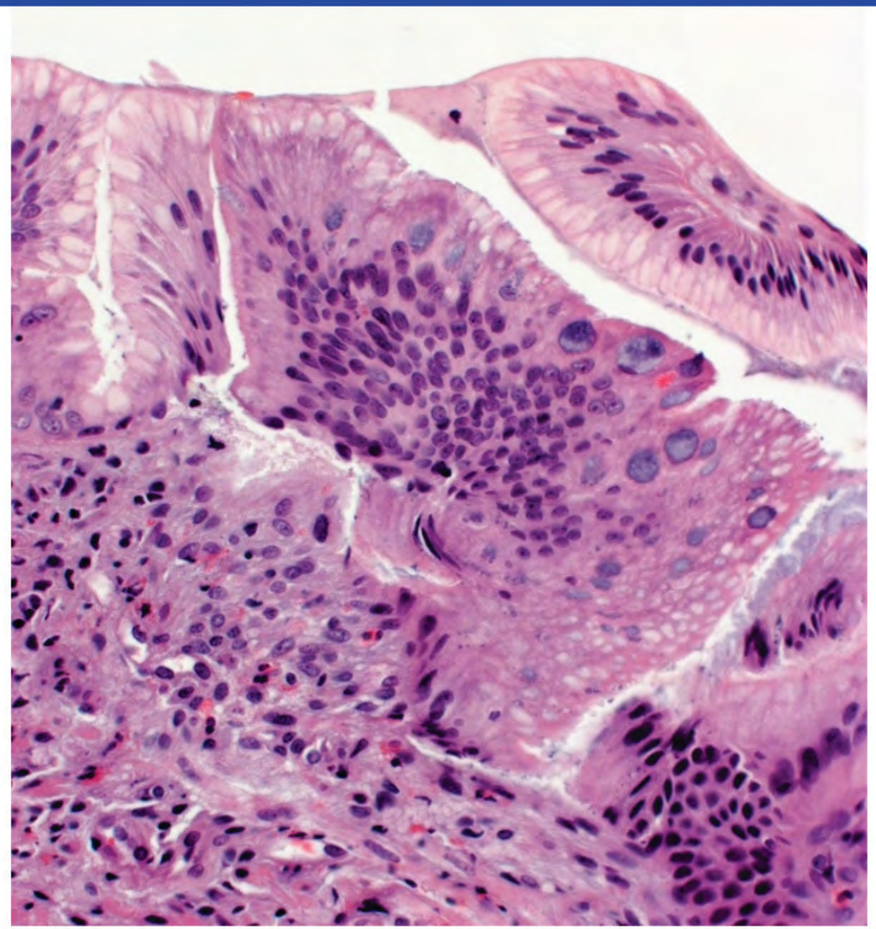

Zoom In Zoom Out Reset New | Existing My Notebook

https://t.me/USMLEWorldStep1

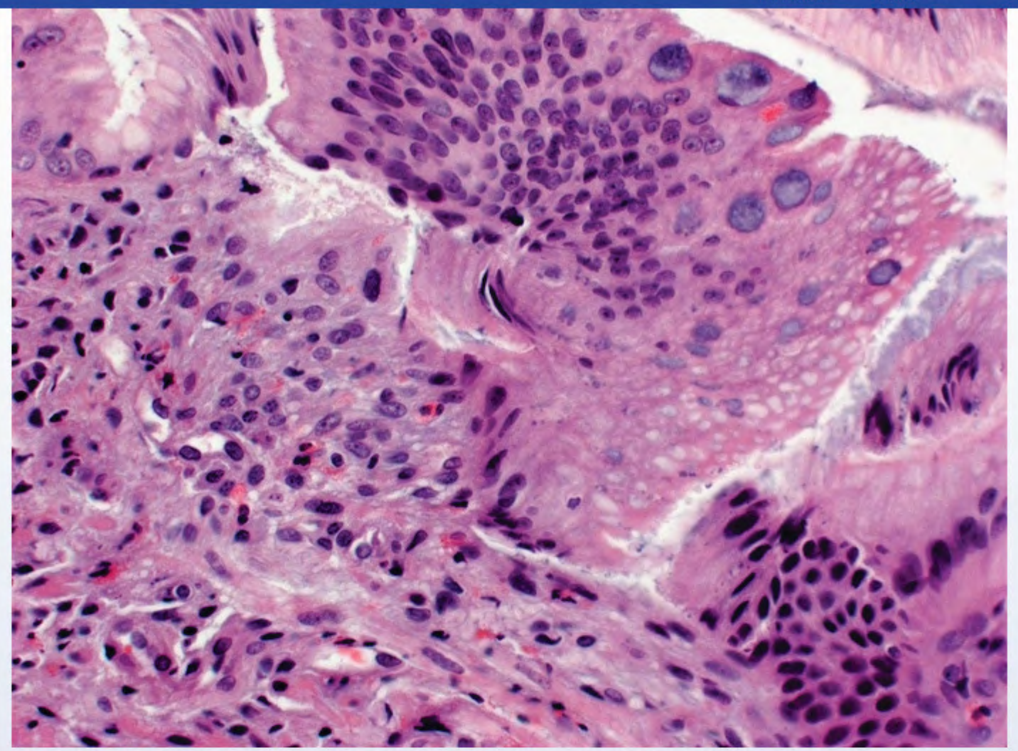

This patient is at highest risk of which of the following complications?

- A. Achalasia
- B. Adenocarcinoma
- C. Crohn disease
- D. Squamous cell carcinoma
- E. Variceal bleeding

Submit

https://t.me/USMLEWorldStep1

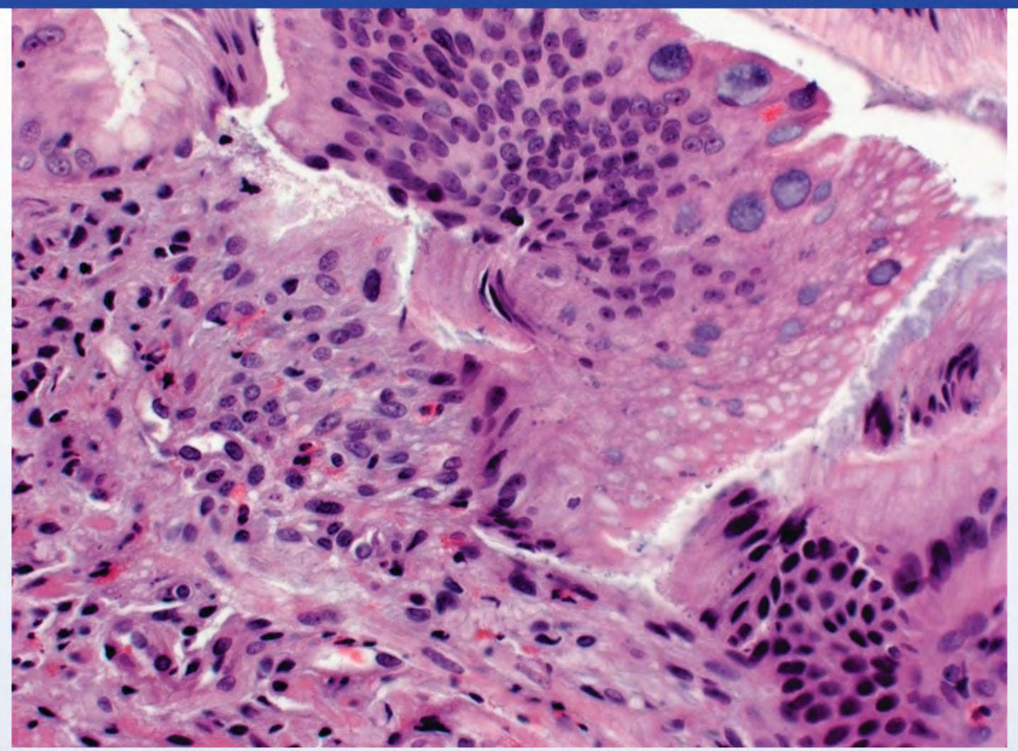

This patient is at highest risk of which of the following complications?

- A. Achalasia (1%)
- ✓ B. Adenocarcinoma (88%)
- C. Crohn disease (0%)
- D. Squamous cell carcinoma (7%)
- E. Variceal bleeding (0%)

Correct

88%
Answered correctly

13 secs
Time Spent

2023
Version

https://t.me/USMLEWorldStep1

D. Squamous cell carcinoma (7%)

Exhibit Display

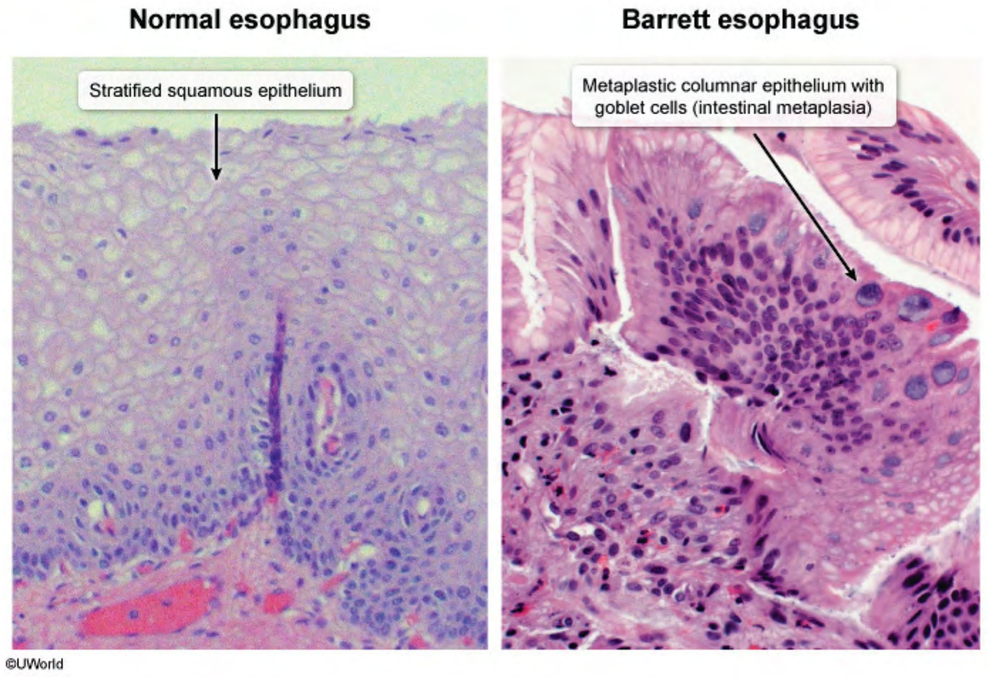

Zoom In | Zoom Out | Reset | New | Existing | My Notebook

This p
reflux
esophagus would be lined by stratified squamous epithelium. This finding is diagnostic of **Barrett esophagus**,

https://t.me/USMLEWorldStep1

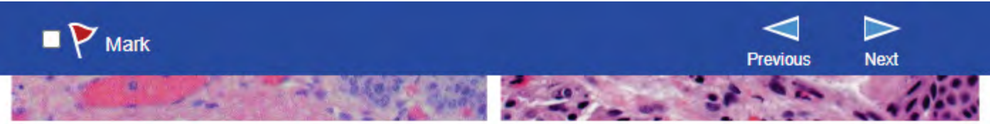

©UWorld

This patient's persistent dry cough, sore throat, and epigastric discomfort is suggestive of **gastroesophageal reflux disease**. His esophageal biopsy shows intestinal-type columnar epithelium with goblet cells where a normal esophagus would be lined by stratified squamous epithelium. This finding is diagnostic of **Barrett esophagus**, which is seen when acidic gastric contents enter the esophagus, causing inflammation and subsequent epithelial necrosis.

Sustained epithelial damage promotes metaplastic replacement of the normal stratified squamous epithelium with **intestinal-type columnar cells**. The transition to columnar epithelium may be seen grossly on endoscopy as tongues of beefy red mucosa extending above the lower esophageal sphincter into areas of normal pale pink squamous mucosa.

People with severe and **long-standing acid reflux** are most prone to Barrett esophagus. This metaplasia is hypothesized to be adaptive at first, as intestinal-type epithelium is more resistant to gastric acid. However, it is a major risk factor for **esophageal adenocarcinoma**, which typically develops from the metaplastic intestinal epithelium in the distal part of the esophagus.

(Choices A and D) The major risk factors for squamous cell carcinoma of the esophagus are cigarette smoking and alcohol use. Achalasia, an esophageal motility disorder caused by the loss of ganglion cells in the lower esophagus, also carries an increased risk of squamous carcinoma.

(Choices C and E) Crohn disease can affect the esophagus, typically causing patchy inflammation, erosions, ulcers, strictures, and fistulas. Esophageal varices develop in the context of high portal venous pressure, most often due to alcohol-induced or post-viral liver cirrhosis. These conditions are not associated with Barrett esophagus.

Educational objective:
Barrett esophagus is a metaplastic condition in which the normal squamous epithelium of the distal esophagus is replaced by intestinal-type columnar epithelium. It occurs most often in longstanding acid reflux and is associated with an increased risk of adenocarcinoma.

https://t.me/USMLEWorldStep1

A 28-year-old woman at 32 weeks gestation is seen in the office for a routine prenatal visit. The patient has had burning, squeezing pain in the middle of her chest that lasts for minutes to hours at a time and usually occurs after meals. The pain is occasionally accompanied by small amounts of sour-tasting material in the back of her throat. The patient does not have any abdominal pain, emesis, or visible blood in the stool. Her pregnancy has been complicated by gestational diabetes mellitus, which has been well controlled with nutritional therapy and exercise. She does not use alcohol, tobacco, or illicit drugs. Vital signs are normal. Fundal height is 32 cm and fetal heart tones are normal. Which of the following is the most likely cause of the patient's symptoms?

- A. Decreased lower esophageal sphincter tone
- B. Delayed gastric emptying
- C. Diffuse spasm of the esophageal smooth muscle
- D. *Helicobacter pylori* infection
- E. Increased gastric acid production

Submit

https://t.me/USMLEWorldStep1

A 28-year-old woman at 32 weeks gestation is seen in the office for a routine prenatal visit. The patient has had burning, squeezing pain in the middle of her chest that lasts for minutes to hours at a time and usually occurs after meals. The pain is occasionally accompanied by small amounts of sour-tasting material in the back of her throat. The patient does not have any abdominal pain, emesis, or visible blood in the stool. Her pregnancy has been complicated by gestational diabetes mellitus, which has been well controlled with nutritional therapy and exercise. She does not use alcohol, tobacco, or illicit drugs. Vital signs are normal. Fundal height is 32 cm and fetal heart tones are normal. Which of the following is the most likely cause of the patient's symptoms?

- ✓ A. Decreased lower esophageal sphincter tone (71%)
- ✗ B. Delayed gastric emptying (18%)
- C. Diffuse spasm of the esophageal smooth muscle (3%)
- D. *Helicobacter pylori* infection (1%)
- E. Increased gastric acid production (4%)

Incorrect
Correct answer
A

71%
Answered correctly

03 secs
Time Spent

2023
Version

Explanation

Gastroesophageal reflux is characterized by the retrograde movement of acidic stomach contents through the lower esophageal sphincter (LES) into the esophagus. Manifestations are most common in the minutes or hours after eating and typically include burning, squeezing pain in the retrosternal area, and the regurgitation of acidic (sour-tasting) stomach contents into the mouth.

Reflux occurs in most **pregnant women** and is common in all trimesters. The major underlying cause is **elevated estrogen and progesterone levels**, which relax the smooth muscle of the LES leading to **decreased LES tone** and reduced sensitivity to contractile stimuli (eg, high-protein meal). Later in pregnancy, reflux can also occur

https://t.me/USMLEWorldStep1

Gastroesophageal reflux is characterized by the retrograde movement of acidic stomach contents through the lower esophageal sphincter (LES) into the esophagus. Manifestations are most common in the minutes or hours after eating and typically include burning, squeezing pain in the retrosternal area, and the regurgitation of acidic (sour-tasting) stomach contents into the mouth.

Reflux occurs in most **pregnant women** and is common in all trimesters. The major underlying cause is **elevated estrogen and progesterone levels**, which relax the smooth muscle of the LES leading to **decreased LES tone** and reduced sensitivity to contractile stimuli (eg, high-protein meal). Later in pregnancy, reflux can also occur when the gravid uterus compresses the stomach and results in an altered LES angle or increased gastric pressure.

(Choice B) Delayed gastric emptying is common in those with poorly controlled diabetes mellitus due to autonomic neuropathy. It usually presents with nausea, vomiting, early satiety, and a sensation of postprandial fullness. Patients who have short periods of diabetes mellitus (eg, gestational diabetes) are unlikely to develop the autonomic damage that leads to delayed gastric emptying.

(Choice C) Diffuse esophageal spasm presents with difficulty swallowing solids and liquids and a sensation of food getting "stuck" in the esophagus. Pregnancy does not increase the risk of esophageal spasm.

(Choice D) *Helicobacter pylori* infection can cause gastritis and peptic ulcer disease, which typically present with epigastric or abdominal pain 2–5 hours after eating (when acid is in the stomach with no food buffer). *H pylori* is not considered a predominant cause of reflux.

(Choice E) Increased gastric acid production is seen in Zollinger-Ellison syndrome, which is caused by the secretion of gastrin from a pancreatic or duodenal neuroendocrine tumor. Patients usually have abdominal pain (from peptic ulcers) and diarrhea. Gastric acid levels are not increased in pregnancy.

Educational objective:
Pregnant women often develop gastroesophageal reflux disease (GERD) due to elevated levels of estrogen and progesterone, which relax the smooth muscle of the lower esophageal sphincter (LES). Later in pregnancy, GERD can also develop when the gravid uterus presses on the stomach and leads to an altered LES angle or increased gastric pressure.

https://t.me/USMLEWorldStep1

An 80-year-old man participates in a study designed to evaluate the effects of aging on the liver. He has undergone a liver biopsy every 10 years since age 40 so that researchers can identify age-related histologic changes. The subject is healthy and has no relevant family history. He does not use alcohol or illicit drugs. BMI is 21.5 kg/m^2. Physical examination is unremarkable; laboratory studies, including complete blood count, liver function tests, cholesterol levels, and hemoglobin A1c, are within normal limits. Which of the following histologic changes has most likely developed over time in this individual?

- A. Extracellular amyloid deposition
- B. Hemosiderin collections within hepatocytes
- C. Hepatocyte intracytoplasmic hyaline inclusions
- D. Lipofuscin deposition within hepatocytes
- E. Stellate cell collagen production

Submit

https://t.me/USMLEWorldStep1

An 80-year-old man participates in a study designed to evaluate the effects of aging on the liver. He has undergone a liver biopsy every 10 years since age 40 so that researchers can identify age-related histologic changes. The subject is healthy and has no relevant family history. He does not use alcohol or illicit drugs. BMI is 21.5 kg/m^2. Physical examination is unremarkable; laboratory studies, including complete blood count, liver function tests, cholesterol levels, and hemoglobin A1c, are within normal limits. Which of the following histologic changes has most likely developed over time in this individual?

- A. Extracellular amyloid deposition (7%)
- ✗ B. Hemosiderin collections within hepatocytes (3%)
- C. Hepatocyte intracytoplasmic hyaline inclusions (4%)
- ✓ D. Lipofuscin deposition within hepatocytes (77%)
- E. Stellate cell collagen production (7%)

Incorrect
Correct answer
D

77%
Answered correctly

04 secs
Time Spent

2023
Version

Explanation

Effect of aging on the liver	
Anatomic changes	• Decreased liver size/mass ◦ Due to decreased hepatic perfusion
Physiologic changes	• Decreased regenerative capacity • Decreased activity of cytochrome P-450 system • Decreased protein (eg, albumin, clotting factors) synthesis
	• Increased hepatocyte size

https://t.me/USMLEWorldStep1

Effect of aging on the liver	
Anatomic changes	• Decreased liver size/mass ◦ Due to decreased hepatic perfusion
Physiologic changes	• Decreased regenerative capacity • Decreased activity of cytochrome P-450 system • Decreased protein (eg, albumin, clotting factors) synthesis
Histologic changes	• Increased hepatocyte size • Increased polyploidy • Accumulation of lipofuscin (brown atrophy)

Several important **age-related changes** develop in the liver over time. The size of the liver **shrinks**, associated with a **decrease in perfusion**. In addition, the **regenerative capabilities** of the liver slow, increasing susceptibility to toxic and ischemic injury.

At the cellular level, the overall number of hepatocytes decreases, and the remaining hepatocytes usually increase in size, associated with polyploidy and enlarged mitochondria. Their ability to clear intracellular debris decreases, allowing a lysosomal degradation product called **lipofuscin** to accumulate over time; the presence of these **yellowish-brown inclusions** within hepatocytes is sometimes referred to as brown atrophy. Other cellular changes of aging include a decrease in size and number of fenestrations within endothelial cells, formation of lipid droplets within stellate cells, and decreased phagocytic activity of Kupffer cells.

(Choice A) Senile (eg, age-related) systemic amyloidosis is characterized by transthyretin deposition in the extracellular space. Although amyloidosis can involve the liver, affected patients frequently have hepatomegaly and elevated alkaline phosphatase levels.

(Choice B) Hereditary hemochromatosis is an autosomal recessive disorder characterized by excessive iron absorption and hemosiderin deposition in hepatocytes and other tissues. This patient has no family history of hemochromatosis, and abnormalities in liver transaminases (eg, AST, ALT) would be expected.

(Choice C) Mallory-Denk bodies are intracytoplasmic hyaline inclusions found within damaged hepatocytes in the

https://t.me/USMLEWorldStep1

	• Accumulation of lipofuscin (brown atrophy)

Several important **age-related changes** develop in the liver over time. The size of the liver **shrinks**, associated with a **decrease in perfusion**. In addition, the **regenerative capabilities** of the liver slow, increasing susceptibility to toxic and ischemic injury.

At the cellular level, the overall number of hepatocytes decreases, and the remaining hepatocytes usually increase in size, associated with polyploidy and enlarged mitochondria. Their ability to clear intracellular debris decreases, allowing a lysosomal degradation product called **lipofuscin** to accumulate over time; the presence of these **yellowish-brown inclusions** within hepatocytes is sometimes referred to as brown atrophy. Other cellular changes of aging include a decrease in size and number of fenestrations within endothelial cells, formation of lipid droplets within stellate cells, and decreased phagocytic activity of Kupffer cells.

(Choice A) Senile (eg, age-related) systemic amyloidosis is characterized by transthyretin deposition in the extracellular space. Although amyloidosis can involve the liver, affected patients frequently have hepatomegaly and elevated alkaline phosphatase levels.

(Choice B) Hereditary hemochromatosis is an autosomal recessive disorder characterized by excessive iron absorption and hemosiderin deposition in hepatocytes and other tissues. This patient has no family history of hemochromatosis, and abnormalities in liver transaminases (eg, AST, ALT) would be expected.

(Choice C) Mallory-Denk bodies are intracytoplasmic hyaline inclusions found within damaged hepatocytes in the setting of alcoholic hepatitis and other liver diseases (eg, nonalcoholic steatohepatitis). This patient has no medical conditions that predispose to their formation.

(Choice E) Chronic hepatic injury activates stellate cells, leading to collagen production and ultimately cirrhosis. This would not occur in a healthy individual.

Educational objective:
Normal age-related changes in the liver include decreased size, decreased perfusion, slower regenerative capability, and the development of yellowish-brown lipofuscin inclusions within hepatocytes.

References

- Hallmarks of aging in the liver.

https://t.me/USMLEWorldStep1

- Accumulation of lipofuscin (brown atrophy)

Exhibit Display

Amyloid

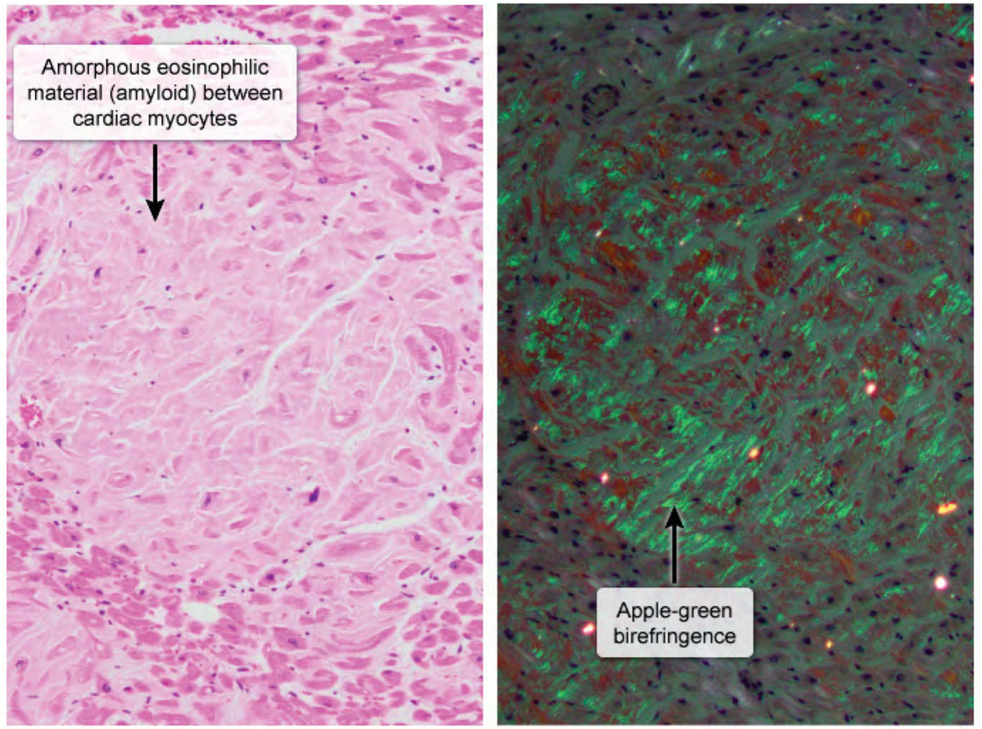

©UWorld

Hematoxylin & eosin stain

Congo red stain under polarized light

Zoom In | Zoom Out | Reset | New | Existing | My Notebook

- Hallmarks of aging in the liver.

https://t.me/USMLEWorldStep1

- Accumulation of lipofuscin (brown atrophy)

Exhibit Display

Hereditary hemochromatosis

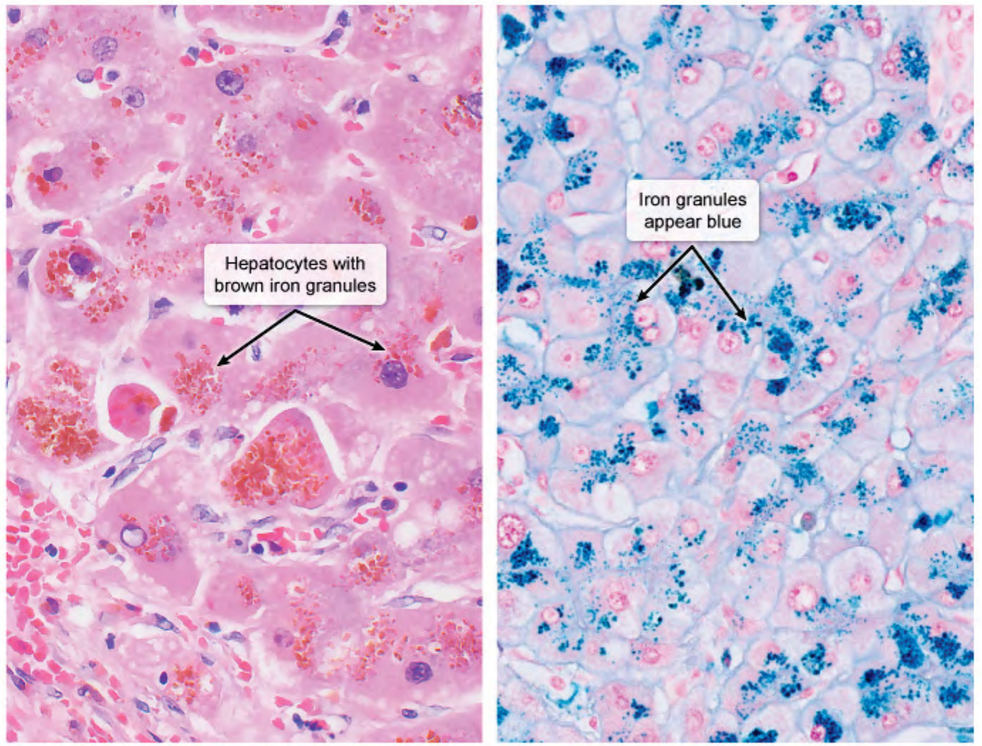

Hematoxylin & eosin stain

Prussian blue stain

©UWorld

Zoom In | Zoom Out | Reset | New | Existing | My Notebook

- Hallmarks of aging in the liver.

https://t.me/USMLEWorldStep1

	• Accumulation of lipofuscin (brown atrophy)

Exhibit Display

Mallory bodies

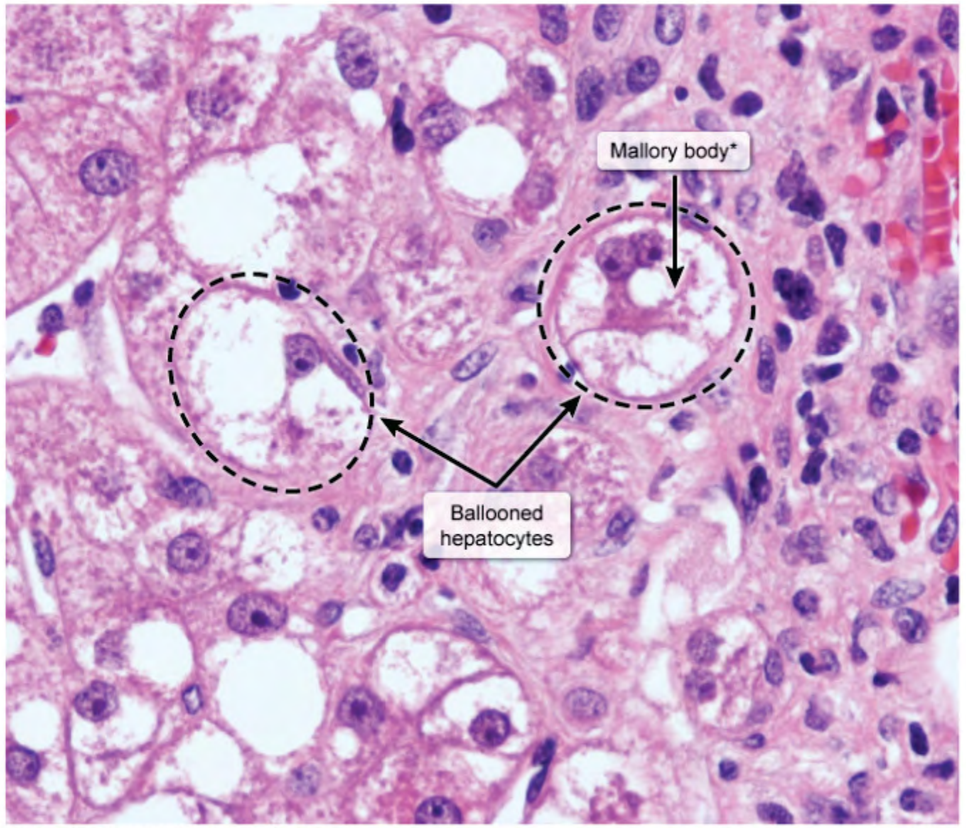

*Eosinophilic clumped intermediate filaments.

©UWorld

Zoom In | Zoom Out | Reset | New | Existing | My Notebook

Sever
with a
to toxi

At the
in size
allowir
yellow
chang
droplet

(Choi
extrac
and el

(Choi
absorp
hemoc

(Choi
setting
medica

(Choi
This w

Educa
Norma
capab

Refere

- Hallmarks of aging in the liver.

https://t.me/USMLEWorldStep1

A 22-year-old man is brought to the emergency department with abdominal pain that started around his belly button, then moved to the right lower abdominal quadrant. After initial evaluation, laparotomy is performed, and the surgical specimen is shown in the image below:

Which of the following most likely initiated this patient's condition?

- A. Arterial spasm
- B. Bacterial proliferation
- C. Lumen obstruction
- D. Peptic ulceration
- E. Venous thrombosis

Submit

https://t.me/USMLEWorldStep1

A 22-year-old man is brought to the emergency department with abdominal pain that started around his belly button, then moved to the right lower abdominal quadrant. After initial evaluation, laparotomy is performed, and the surgical specimen is shown in the image below:

Which of the following most likely initiated this patient's condition?

- ✗ A. Arterial spasm (2%)
- B. Bacterial proliferation (18%)
- ✓ C. Lumen obstruction (72%)
- D. Peptic ulceration (0%)
- E. Venous thrombosis (5%)

Incorrect
Correct answer
C

72%
Answered correctly

18 secs
Time Spent

2023
Version

https://t.me/USMLEWorldStep1

D. Peptic ulceration (0%)

Exhibit Display

Acute appendicitis

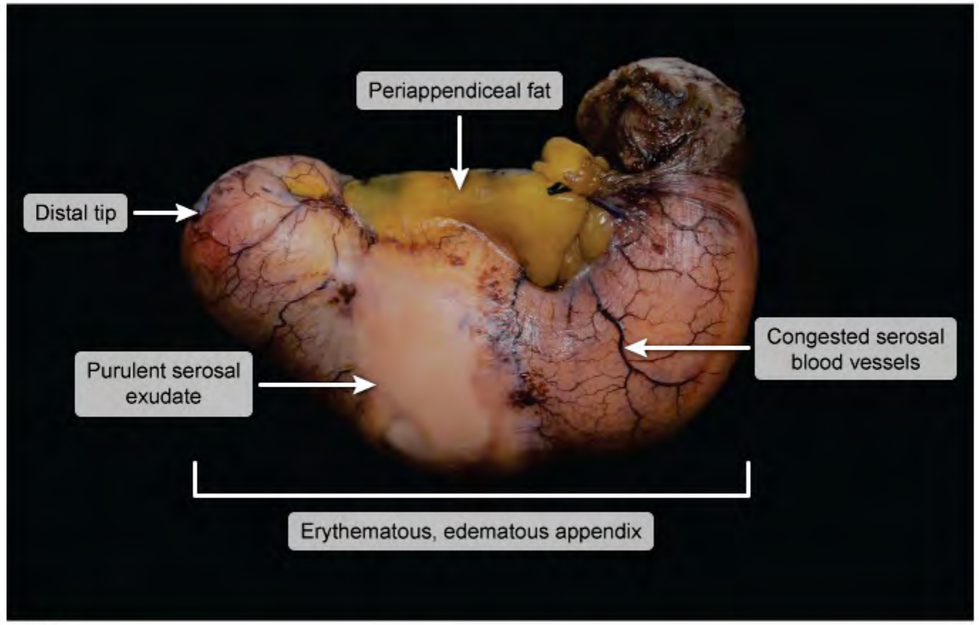

©UWorld

Zoom In | Zoom Out | Reset | New | Existing | My Notebook

This p

appendicitis typically occurs in children and young adults and is often initiated by **obstruction** of the **appendiceal lumen**. The most common obstructing agents are fecaliths, hyperplastic lymphoid follicles (eg, following infection).

https://t.me/USMLEWorldStep1

©UWorld

This patient with abdominal pain has gross pathologic findings consistent with acute appendicitis. **Acute appendicitis** typically occurs in children and young adults and is often initiated by **obstruction** of the **appendiceal lumen**. The most common obstructing agents are fecaliths, hyperplastic lymphoid follicles (eg, following infection), tumors (eg, carcinoid), and nematodes.

Mucus accumulates in the lumen of the obstructed appendix, which causes **increased pressure**, appendiceal wall distension, and impaired venous outflow. The resulting **ischemia** and associated **bacterial proliferation (Choice B)** lead to **inflammation** of the appendiceal wall, causing **edema** (with further distension), serosal **erythema**, and purulent **exudate**. Necrosis of the wall with rupture may follow, and inflammatory fluid and bacterial contents may spill into the peritoneal cavity, causing peritonitis.

Patients typically experience **abdominal pain**, which may migrate over time. Distension of the appendix triggers afferent pain fibers that enter at the T10 level in the spinal cord, producing vague, referred pain at the **umbilicus**. As the inflammatory reaction advances, the appendix irritates the parietal peritoneum, causing more severe somatic pain that **shifts** to the **right lower quadrant**.

(Choices A and E) Both arterial spasm and venous thrombosis can cause mesenteric ischemia, which often presents with severe, diffuse abdominal pain. Gross examination of the affected bowel segment would show dusky red serosa, edema, and hemorrhagic mucosa.

(Choice D) Meckel diverticula often contain ectopic gastric mucosa, which may lead to peptic ulceration of the surrounding small intestinal tissue and subsequent lower intestinal bleeding. Gross examination would show an intestinal outpouching within 2 feet of the ileocecal valve.

Educational objective:
Obstruction of the appendiceal lumen (eg, fecalith, lymphoid hyperplasia) is frequently the inciting event in pathogenesis of acute appendicitis, which typically presents with periumbilical pain that shifts to the right lower quadrant. Gross pathologic examination often shows an edematous, erythematous appendix with purulent exudate.

https://t.me/USMLEWorldStep1

A 70-year-old man comes to the office due to abdominal pain that began 1 month ago. He has also experienced fatigue and weight loss. He has no chronic medical conditions and takes no daily medications. The patient worked in a factory that produced polyvinyl chloride for several decades and is now retired. Physical examination shows hepatomegaly. Imaging demonstrates a liver mass, which is subsequently resected. Immunohistochemical staining of the tumor cells is positive for CD31. Which of the following is the most likely diagnosis?

- A. Cavernous hemangioma
- B. Cholangiocarcinoma
- C. Hepatic angiosarcoma
- D. Hepatoblastoma
- E. Hepatocellular adenoma
- F. Kaposi sarcoma

Submit

https://t.me/USMLEWorldStep1

A 70-year-old man comes to the office due to abdominal pain that began 1 month ago. He has also experienced fatigue and weight loss. He has no chronic medical conditions and takes no daily medications. The patient worked in a factory that produced polyvinyl chloride for several decades and is now retired. Physical examination shows hepatomegaly. Imaging demonstrates a liver mass, which is subsequently resected. Immunohistochemical staining of the tumor cells is positive for CD31. Which of the following is the most likely diagnosis?

- A. Cavernous hemangioma (2%)
- ✗ B. Cholangiocarcinoma (6%)
- ✓ C. Hepatic angiosarcoma (71%)
- D. Hepatoblastoma (5%)
- E. Hepatocellular adenoma (13%)
- F. Kaposi sarcoma (2%)

Incorrect
Correct answer
C

71%
Answered correctly

03 secs
Time Spent

2023
Version

Explanation

Hepatic angiosarcoma is a rare, **aggressive vascular malignancy**. It usually presents in **older men** (age >60) and is associated with carcinogen exposure. Implicated chemicals include **vinyl chloride** (eg, exposure during production of polyvinyl chloride, a widely used plastic), arsenic (eg, exposure to pesticides), and Thorotrast (formerly used radioactive contrast medium). Clinical manifestations can include abdominal pain, fatigue, weight loss, and hepatomegaly, as well as intraabdominal hemorrhage (caused by tumor rupture).

Angiosarcomas are derived from **endothelial cells**. In the liver, they appear grossly as poorly circumscribed, hemorrhagic lesions. Microscopic examination typically shows vascular structures lined by atypical (eg, hyperchromatic, pleomorphic) cells that express **CD31** (ie, platelet endothelial cell adhesion molecule [PECAM1]).

https://t.me/USMLEWorldStep1

Hepatic angiosarcoma is a rare, **aggressive vascular malignancy**. It usually presents in **older men** (age >60) and is associated with carcinogen exposure. Implicated chemicals include **vinyl chloride** (eg, exposure during production of polyvinyl chloride, a widely used plastic), arsenic (eg, exposure to pesticides), and Thorotrast (formerly used radioactive contrast medium). Clinical manifestations can include abdominal pain, fatigue, weight loss, and hepatomegaly, as well as intraabdominal hemorrhage (caused by tumor rupture).

Angiosarcomas are derived from **endothelial cells**. In the liver, they appear grossly as poorly circumscribed, hemorrhagic lesions. Microscopic examination typically shows vascular structures lined by atypical (eg, hyperchromatic, pleomorphic) cells that express **CD31** (ie, platelet endothelial cell adhesion molecule [PECAM1]). **PECAM1** is expressed on the surface of endothelial cells and functions in leukocyte migration through the endothelium.

(Choice A) Hepatic cavernous hemangiomas are common benign vascular lesions. Microscopy shows a well-circumscribed proliferation of dilated vascular structures that are lined by endothelial cells lacking atypia. Although cavernous hemangiomas express CD31, patients are typically asymptomatic (eg, lesion incidentally found on imaging).

(Choice B) Cholangiocarcinomas are rare, malignant tumors derived from bile duct epithelium. They may present with abdominal pain and weight loss, but CD31 expression would not be expected.

(Choice D) Hepatoblastomas are malignant liver tumors derived from immature, multipotent cells. Most cases occur in children age <5.

(Choice E) Hepatocellular adenomas are benign liver tumors derived from hepatocytes. Although clinical manifestations may include abdominal pain, they typically present in young women (ie, reproductive years) and are associated with oral contraceptives or anabolic steroid use.

(Choice F) Kaposi sarcoma is a vascular neoplasm associated with human herpesvirus 8 that can involve the liver. Microscopy typically shows proliferation of spindle-shaped endothelial cells (ie, CD31 positive) with slit-like vascular spaces. However, it typically presents in immunocompromised patients (eg, those with AIDS) and often initially involves the skin (eg, purple papules on the lower extremities).

Educational objective:

https://t.me/USMLEWorldStep1

(formerly used radioactive contrast medium). Clinical manifestations can include abdominal pain, fatigue, weight loss, and hepatomegaly, as well as intraabdominal hemorrhage (caused by tumor rupture).

Angiosarcomas are derived from **endothelial cells**. In the liver, they appear grossly as poorly circumscribed, hemorrhagic lesions. Microscopic examination typically shows vascular structures lined by atypical (eg, hyperchromatic, pleomorphic) cells that express **CD31** (ie, platelet endothelial cell adhesion molecule [PECAM1]). **PECAM1** is expressed on the surface of endothelial cells and functions in leukocyte migration through the endothelium.

(Choice A) Hepatic cavernous hemangiomas are common benign vascular lesions. Microscopy shows a well-circumscribed proliferation of dilated vascular structures that are lined by endothelial cells lacking atypia. Although cavernous hemangiomas express CD31, patients are typically asymptomatic (eg, lesion incidentally found on imaging).

(Choice B) Cholangiocarcinomas are rare, malignant tumors derived from bile duct epithelium. They may present with abdominal pain and weight loss, but CD31 expression would not be expected.

(Choice D) Hepatoblastomas are malignant liver tumors derived from immature, multipotent cells. Most cases occur in children age <5.

(Choice E) Hepatocellular adenomas are benign liver tumors derived from hepatocytes. Although clinical manifestations may include abdominal pain, they typically present in young women (ie, reproductive years) and are associated with oral contraceptives or anabolic steroid use.

(Choice F) Kaposi sarcoma is a vascular neoplasm associated with human herpesvirus 8 that can involve the liver. Microscopy typically shows proliferation of spindle-shaped endothelial cells (ie, CD31 positive) with slit-like vascular spaces. However, it typically presents in immunocompromised patients (eg, those with AIDS) and often initially involves the skin (eg, purple papules on the lower extremities).

Educational objective:
Hepatic angiosarcoma is an aggressive vascular malignancy associated with exposure to carcinogens (eg, vinyl chloride). The tumor cells express CD31 (ie, platelet endothelial cell adhesion molecule [PECAM1]), an endothelial cell marker important for leukocyte transmigration.

https://t.me/USMLEWorldStep1

Hepatic angiosarcoma is a rare, **aggressive vascular malignancy**. It usually presents in **older men** (age >60)

and is
produ
(forme
loss, a

Angios
hemor
hyperc
PECA
endoth

(Choi
circum
caverr
imagir

(Choi
with al

(Choi
occur

(Choi
manife
associ

(Choi
liver.
vascul
initially

Educational objective:

Exhibit Display

Hepatic angiosarcoma

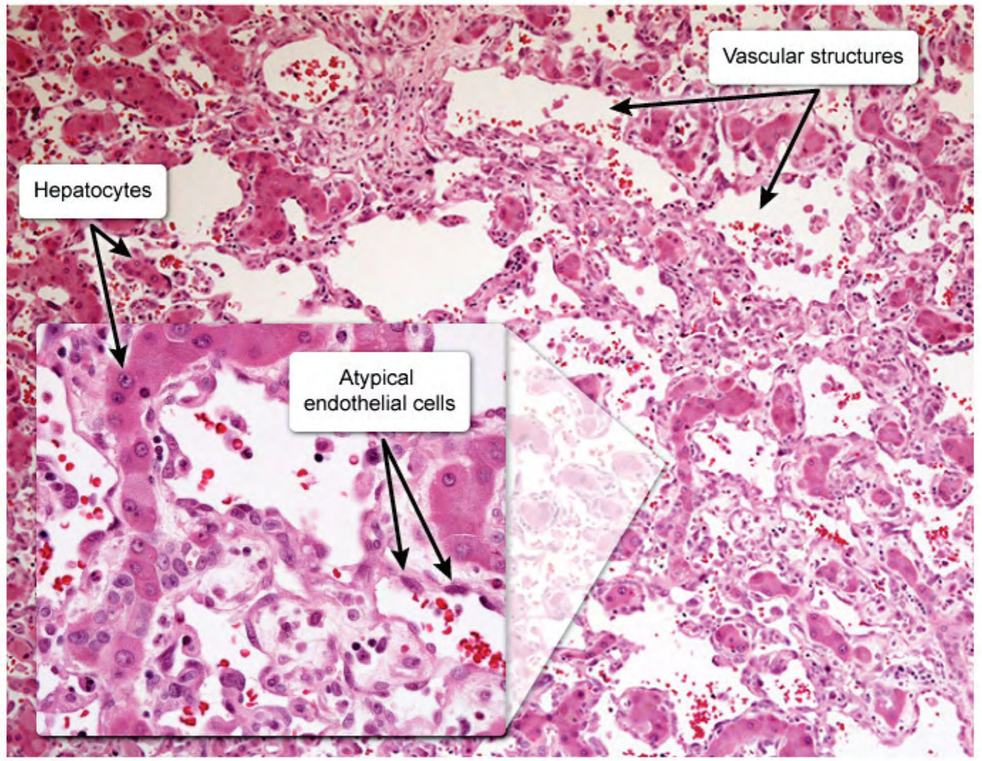

©UWorld

Zoom In | Zoom Out | Reset | New | Existing | My Notebook

https://t.me/USMLEWorldStep1

Hepatic angiosarcoma is a rare, **aggressive vascular malignancy**. It usually presents in **older men** (age >60)

and is
produ
(forme
loss, a

Angios
hemor
hyperc
PECA
endoth

(Choi
circum
caverr
imagir

(Choi
with al

(Choi
occur

(Choi
manife
associ

(Choi
liver.
vascul
initially

Educational objective:

Exhibit Display

Hepatic cavernous hemangioma

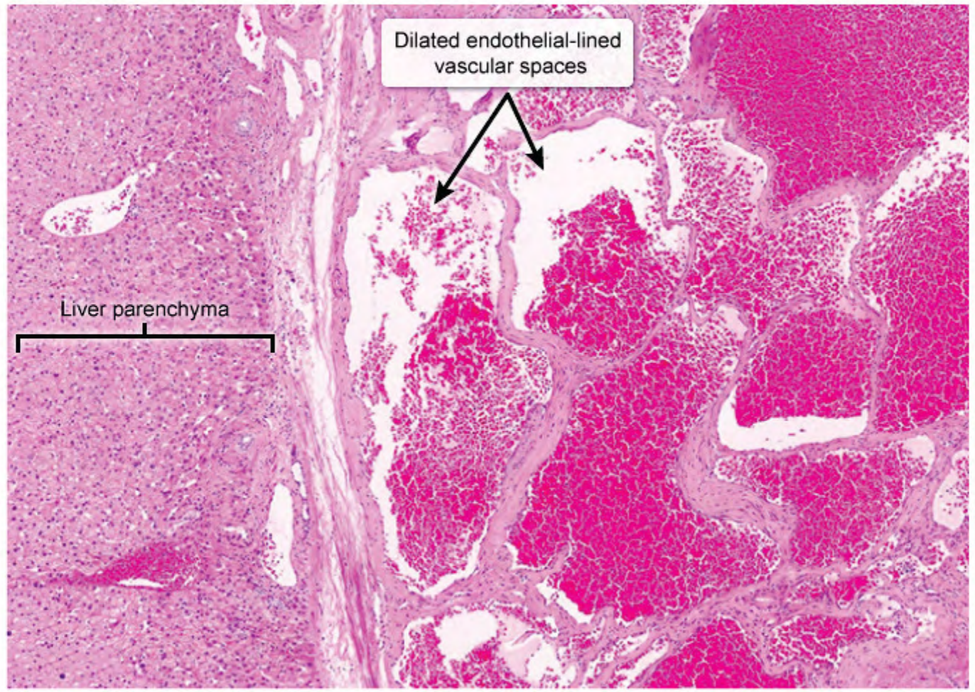

©UWorld

Zoom In | Zoom Out | Reset | New | Existing | My Notebook

https://t.me/USMLEWorldStep1

Hepatic angiosarcoma is a rare, **aggressive vascular malignancy**. It usually presents in **older men** (age >60)

and is
produc
(forme
loss, a

Angios
hemor
hyperc
PECA
endoth

(Choic
circum
caverr
imagir

(Choic
with al

(Choic
occur

(Choic
manife
associ

(Choic
liver.
vascul
initially

Educational objective:

Exhibit Display

Intrahepatic cholangiocarcinoma

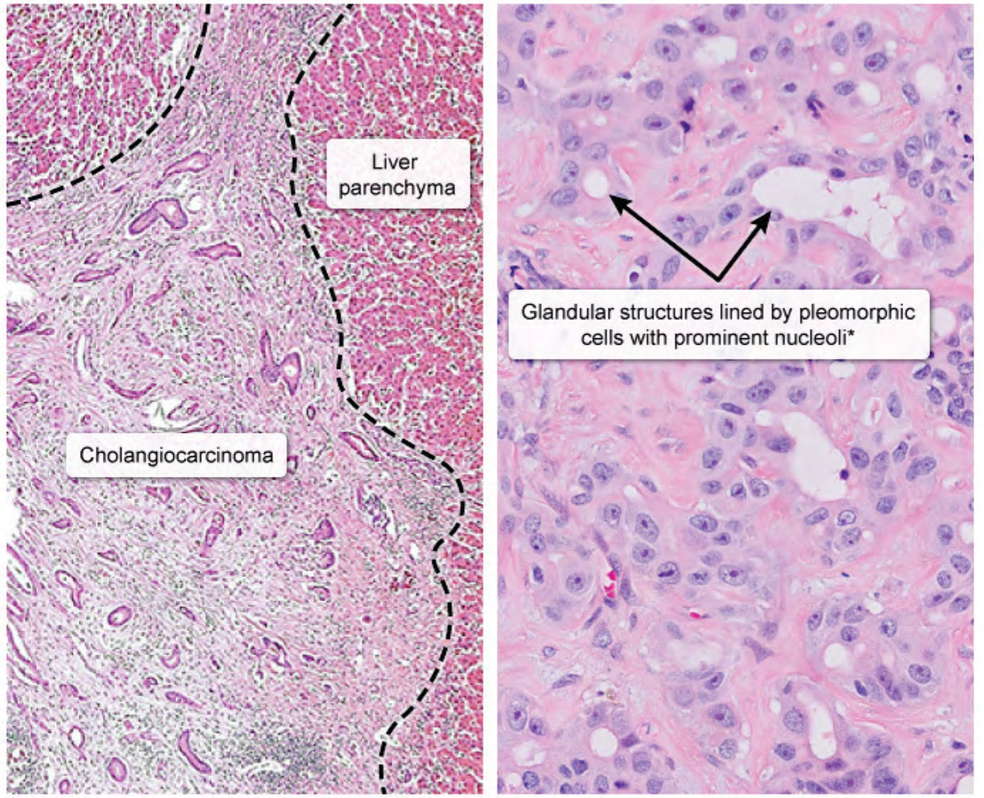

*Derived from bile duct epithelium

©UWorld

Zoom In | Zoom Out | Reset | New | Existing | My Notebook

https://t.me/USMLEWorldStep1

Hepatic angiosarcoma is a rare, **aggressive vascular malignancy**. It usually presents in **older men** (age >60)

and is
produc
(forme
loss, a

Angios
hemor
hyperc
PECA
endoth

(Choic
circum
caverr
imagir

(Choic
with al

(Choic
occur

(Choic
manife
associ

(Choic
liver.
vascul
initially

Educational objective:

Exhibit Display

Kaposi sarcoma

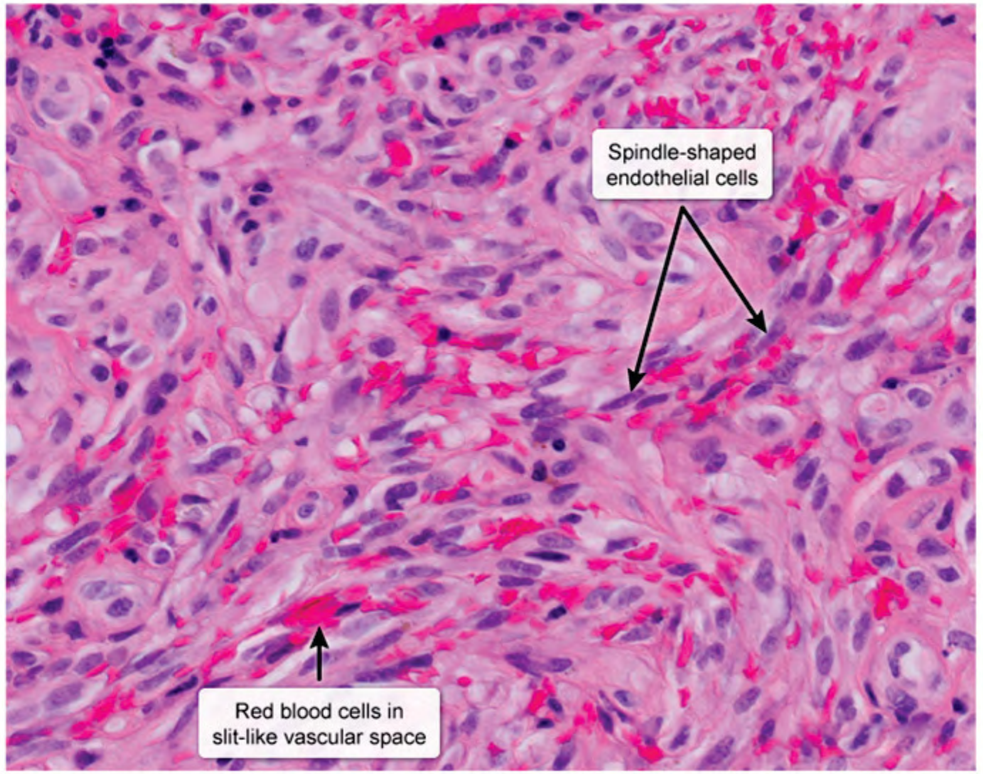

©UWorld

Zoom In | Zoom Out | Reset | New | Existing | My Notebook

https://t.me/USMLEWorldStep1

A 32-year-old woman comes to the office due to a 2-month history of dull pain in the right upper quadrant. The pain is worse with deep inspiration. The patient has no fever or weight loss. She drinks alcohol socially but does not use tobacco or recreational drugs. The patient has no significant family history of cancer. Temperature is 37.1 C (98.8 F), blood pressure is 130/78 mm Hg, pulse is 82/min, and respirations are 16/min. BMI is 36 kg/m^2. There is no jaundice. On examination, mild hepatomegaly is noted; no ascites is present. Abdominal ultrasonography reveals a solitary 4.5-cm mass in the right lobe of the liver. The patient undergoes surgical resection. On gross examination, the mass is soft and smooth with a tan appearance. On cut surface, areas of hemorrhage and necrosis are noted. Microscopic examination shows cells that are larger than normal hepatocytes and have small, regular nuclei without mitoses. There are scattered prominent arteries; no portal tracts or interlobular bile ducts are present. Which of the following is the most likely diagnosis?

- A. Focal nodular hyperplasia
- B. Hepatocellular adenoma
- C. Hepatocellular carcinoma
- D. Pyogenic abscess
- E. Solitary liver metastasis

Submit

https://t.me/USMLEWorldStep1

A 32-year-old woman comes to the office due to a 2-month history of dull pain in the right upper quadrant. The pain is worse with deep inspiration. The patient has no fever or weight loss. She drinks alcohol socially but does not use tobacco or recreational drugs. The patient has no significant family history of cancer. Temperature is 37.1 C (98.8 F), blood pressure is 130/78 mm Hg, pulse is 82/min, and respirations are 16/min. BMI is 36 kg/m^2. There is no jaundice. On examination, mild hepatomegaly is noted; no ascites is present. Abdominal ultrasonography reveals a solitary 4.5-cm mass in the right lobe of the liver. The patient undergoes surgical resection. On gross examination, the mass is soft and smooth with a tan appearance. On cut surface, areas of hemorrhage and necrosis are noted. Microscopic examination shows cells that are larger than normal hepatocytes and have small, regular nuclei without mitoses. There are scattered prominent arteries; no portal tracts or interlobular bile ducts are present. Which of the following is the most likely diagnosis?

- ✗ A. Focal nodular hyperplasia (36%)
- ✓ B. Hepatocellular adenoma (47%)
- C. Hepatocellular carcinoma (7%)
- D. Pyogenic abscess (4%)
- E. Solitary liver metastasis (4%)

Incorrect
Correct answer
B

47%
Answered correctly

04 secs
Time Spent

2023
Version

Explanation

Hepatocellular adenoma	
Epidemiology	• Uncommon, benign liver tumor • Young women • Associated with estrogen exposure (eg, OCPs) & anabolic steroid use

https://t.me/USMLEWorldStep1

Hepatocellular adenoma	
Epidemiology	• Uncommon, benign liver tumor • Young women • Associated with estrogen exposure (eg, OCPs) & anabolic steroid use
Clinical	• Often asymptomatic • Abdominal pain (due to hepatomegaly, bleeding, or necrosis) • Life-threatening intraabdominal bleeding (due to tumor rupture)
Pathology	• Solitary, well-circumscribed, unencapsulated liver mass • Sheets or plates of benign hepatocytes • Prominent arteries without portal tracts or interlobular bile ducts • Hemorrhage & necrosis
OCPs = oral contraceptive pills.	

This patient's pathologic features are consistent with **hepatocellular adenoma** (HCA), an uncommon benign liver tumor found predominantly in **young women**. It is associated with **estrogen** exposure (eg, oral contraceptive pills), anabolic steroid use, and obesity. Pathogenesis is thought to be hormonally mediated but is not fully understood.

Macroscopically, HCA is typically a well-circumscribed, solid, **solitary, unencapsulated** mass arising in the right lobe. The cut surface is often soft and tan with areas of hemorrhage and necrosis. Histologically, HCA is composed of sheets or plates of **benign hepatocytes**. Cells may be larger than normal hepatocytes but have small, uniform nuclei (ie, no cytologic atypia) and rare mitoses. Normal hepatic architecture is absent; instead, there are prominent arteries without normal portal tracts or interlobular bile ducts. The uninvolved liver is usually noncirrhotic.

Patients may be asymptomatic (ie, diagnosed incidentally by imaging) or have epigastric or **right upper quadrant pain** (due to hepatomegaly or intralesional bleeding or necrosis). Because HCA is an unencapsulated and vascular lesion, there is **risk for rupture** with life-threatening intraabdominal bleeding (eg, severe abdominal pain,

https://t.me/USMLEWorldStep1

OCPs = oral contraceptive pills.

This patient's pathologic features are consistent with **hepatocellular adenoma** (HCA), an uncommon benign liver tumor found predominantly in **young women**. It is associated with **estrogen** exposure (eg, oral contraceptive pills), anabolic steroid use, and obesity. Pathogenesis is thought to be hormonally mediated but is not fully understood.

Macroscopically, HCA is typically a well-circumscribed, solid, **solitary, unencapsulated** mass arising in the right lobe. The cut surface is often soft and tan with areas of hemorrhage and necrosis. Histologically, HCA is composed of sheets or plates of **benign hepatocytes**. Cells may be larger than normal hepatocytes but have small, uniform nuclei (ie, no cytologic atypia) and rare mitoses. Normal hepatic architecture is absent; instead, there are prominent arteries without normal portal tracts or interlobular bile ducts. The uninvolved liver is usually noncirrhotic.

Patients may be asymptomatic (ie, diagnosed incidentally by imaging) or have epigastric or **right upper quadrant pain** (due to hepatomegaly or intralesional bleeding or necrosis). Because HCA is an unencapsulated and vascular lesion, there is **risk for rupture** with life-threatening intraabdominal bleeding (eg, severe abdominal pain, hypotension). For this reason, large or symptomatic HCAs are usually surgically resected.

(Choice A) Focal nodular hyperplasia, a nonneoplastic liver lesion, occurs primarily in young women. Although typically a well-circumscribed, solitary mass, it characteristically has a central stellate scar.

(Choice C) Hepatocellular carcinoma (HCC) typically arises in older patients with underlying liver disease and cirrhosis. The macroscopic appearance can vary, but histopathology often shows atypical hepatocytes with increased mitoses. Although malignant transformation of HCA occasionally occurs, this patient's histopathology is not suggestive of HCC.

(Choice D) Pyogenic hepatic abscess commonly results from biliary tract infection or portal vein pyemia (eg, bowel leakage). Although it causes abdominal pain, patients are typically febrile. Pathologic examination often shows a soft, yellow-green, necrotic lesion composed of neutrophils and debris.

(Choice E) The liver is a common site of metastasis in patients with a history of malignancy (eg, colorectal). Histopathology of metastases may resemble that of the primary tumor (eg, atypical epithelial cells forming

https://t.me/USMLEWorldStep1

Macroscopically, HCA is typically a well-circumscribed, solid, **solitary, unencapsulated** mass arising in the right lobe. The cut surface is often soft and tan with areas of hemorrhage and necrosis. Histologically, HCA is composed of sheets or plates of **benign hepatocytes**. Cells may be larger than normal hepatocytes but have small, uniform nuclei (ie, no cytologic atypia) and rare mitoses. Normal hepatic architecture is absent; instead, there are prominent arteries without normal portal tracts or interlobular bile ducts. The uninvolved liver is usually noncirrhotic.

Patients may be asymptomatic (ie, diagnosed incidentally by imaging) or have epigastric or **right upper quadrant pain** (due to hepatomegaly or intralesional bleeding or necrosis). Because HCA is an unencapsulated and vascular lesion, there is **risk for rupture** with life-threatening intraabdominal bleeding (eg, severe abdominal pain, hypotension). For this reason, large or symptomatic HCAs are usually surgically resected.

(Choice A) Focal nodular hyperplasia, a nonneoplastic liver lesion, occurs primarily in young women. Although typically a well-circumscribed, solitary mass, it characteristically has a central stellate scar.

(Choice C) Hepatocellular carcinoma (HCC) typically arises in older patients with underlying liver disease and cirrhosis. The macroscopic appearance can vary, but histopathology often shows atypical hepatocytes with increased mitoses. Although malignant transformation of HCA occasionally occurs, this patient's histopathology is not suggestive of HCC.

(Choice D) Pyogenic hepatic abscess commonly results from biliary tract infection or portal vein pyemia (eg, bowel leakage). Although it causes abdominal pain, patients are typically febrile. Pathologic examination often shows a soft, yellow-green, necrotic lesion composed of neutrophils and debris.

(Choice E) The liver is a common site of metastasis in patients with a history of malignancy (eg, colorectal). Histopathology of metastases may resemble that of the primary tumor (eg, atypical epithelial cells forming infiltrative glands); mitoses are common.

Educational objective:
Hepatocellular adenomas are benign liver tumors found predominantly in young women with a history of oral contraceptive use. They are typically solitary, unencapsulated masses composed of benign hepatocytes and prominent arteries without normal portal tracts. Patients may be asymptomatic, have abdominal pain, or have intraabdominal bleeding due to tumor rupture.

https://t.me/USMLEWorldStep1

Pathology

- Sheets or plates of benign hepatocytes

Exhibit Display

Hepatocellular adenoma

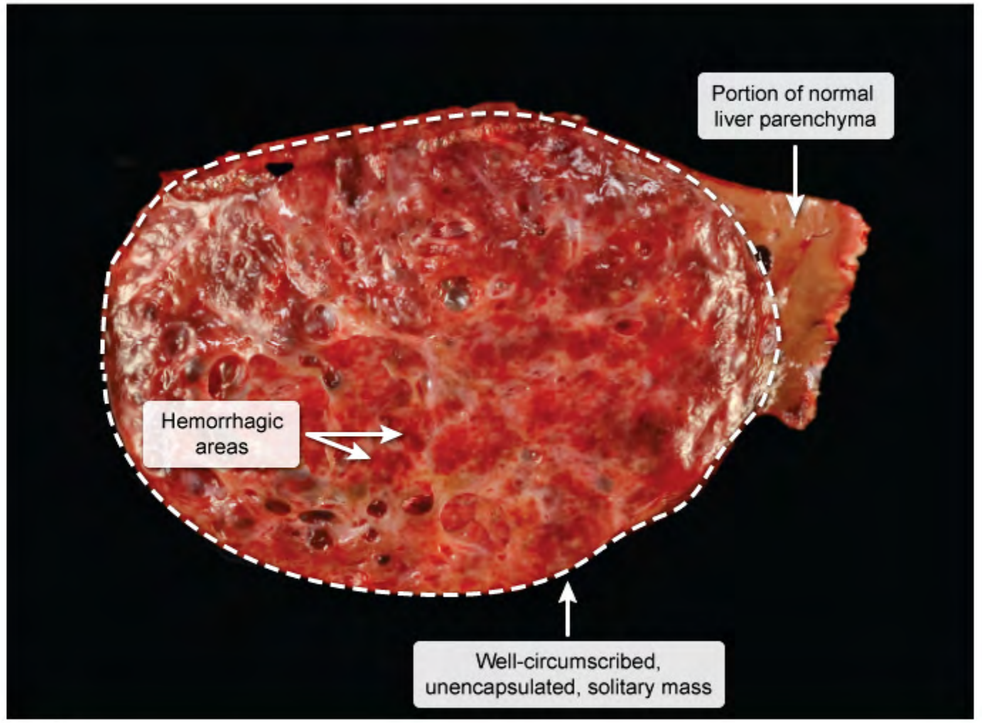

©UWorld

Zoom In | Zoom Out | Reset | New | Existing | My Notebook

This p
tumor
pills), a
unders

Macro
lobe.
compo
small,
there a
noncir

Patien
pain (
vascul
hypote

(Choi
typical

(Choi
cirrhos
increa
not su

(Choice D) Pyogenic hepatic abscess commonly results from biliary tract infection or portal vein pyemia (eg, bowel leakage). Although it causes abdominal pain, patients are typically febrile. Pathologic examination often

https://t.me/USMLEWorldStep1

Pathology	• Sheets or plates of benign hepatocytes

Exhibit Display

Hepatocellular adenoma

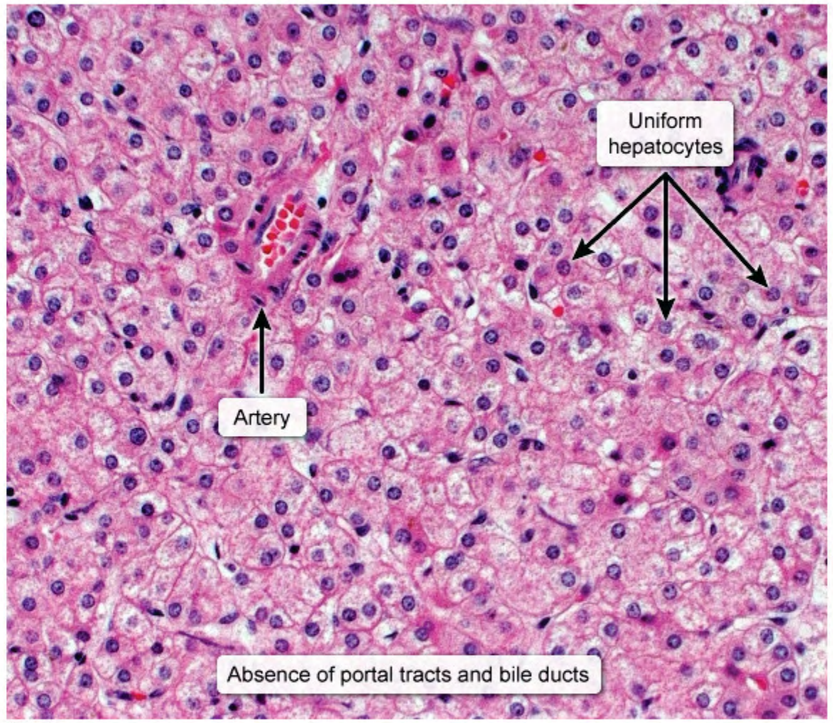

Zoom In | Zoom Out | Reset | New | Existing | My Notebook

This p
tumor
pills), a
unders

Macro
lobe.
compo
small,
there a
noncir

Patien
pain (
vascul
hypote

(Choi
typical

(Choi
cirrhos
increa
not su

(Choice D) Pyogenic hepatic abscess commonly results from biliary tract infection or portal vein pyemia (eg, bowel leakage). Although it causes abdominal pain, patients are typically febrile. Pathologic examination often

https://t.me/USMLEWorldStep1

Pathology	• Sheets or plates of benign hepatocytes

Exhibit Display

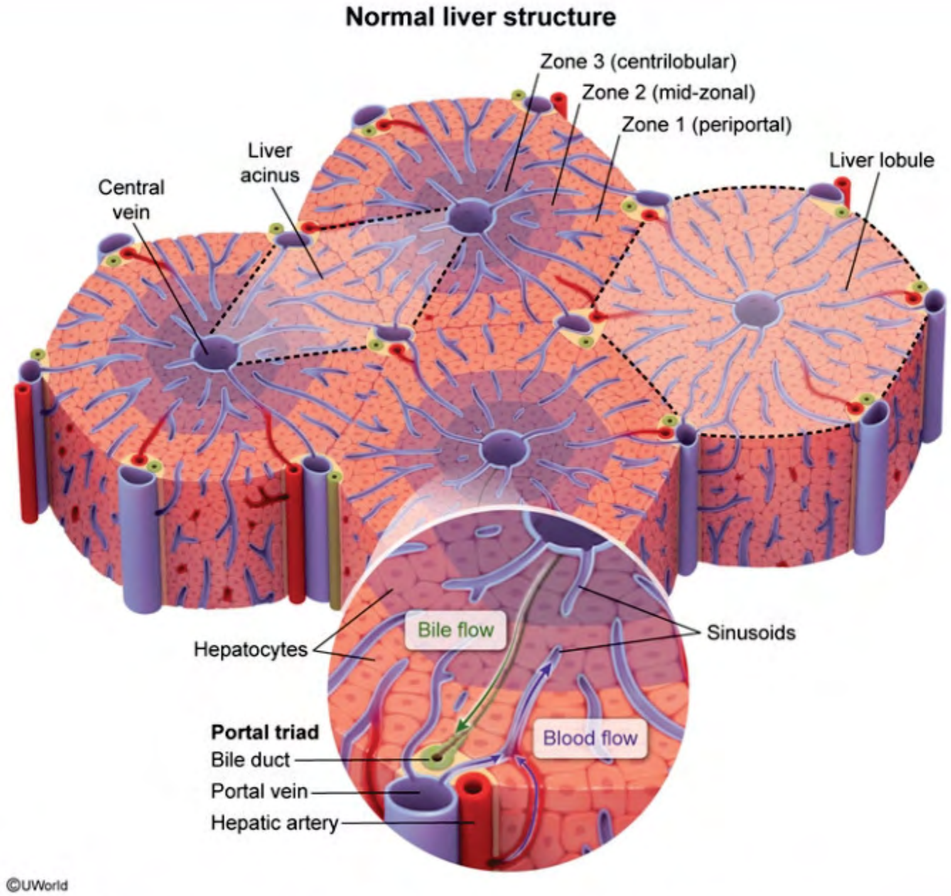

Zoom In | Zoom Out | Reset | New | Existing | My Notebook

This p
tumor
pills), a
unders

Macro
lobe.
compo
small,
there a
noncir

Patien
pain (
vascul
hypote

(Choi
typical

(Choi
cirrhos
increa
not su

(Choice D) Pyogenic hepatic abscess commonly results from biliary tract infection or portal vein pyemia (eg, bowel leakage). Although it causes abdominal pain, patients are typically febrile. Pathologic examination often

https://t.me/USMLEWorldStep1

Pathology

- Sheets or plates of benign hepatocytes

Exhibit Display

Focal nodular hyperplasia

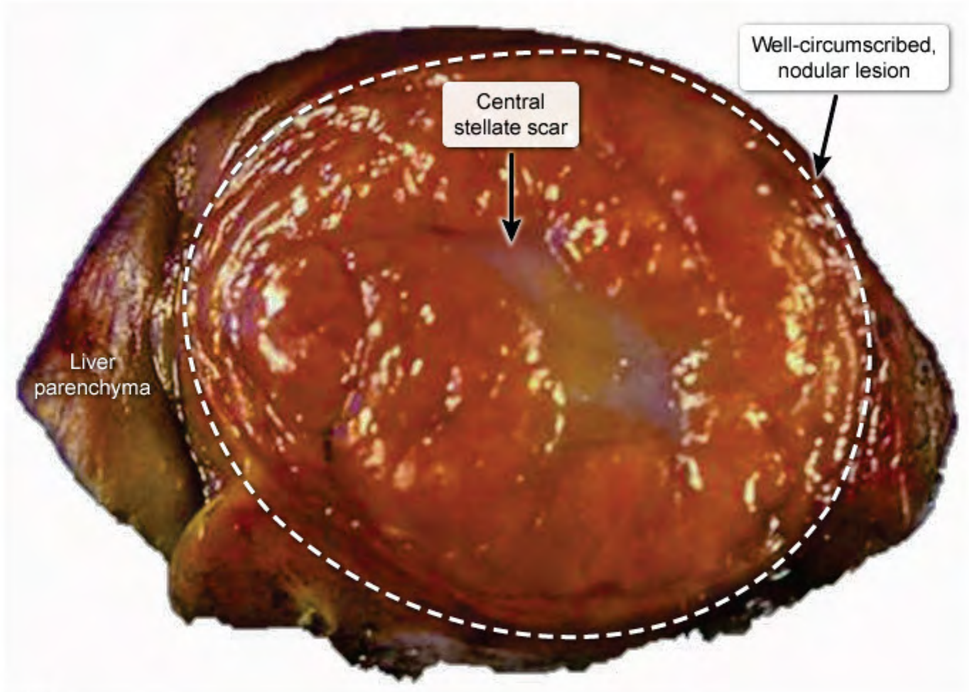

©UWorld

Zoom In | Zoom Out | Reset | New | Existing | My Notebook

This p
tumor
pills), a
unders

Macro
lobe.
compo
small,
there a
noncir

Patien
pain (
vascul
hypote

(Choi
typical

(Choi
cirrhos
increa
not su

(Choice D) Pyogenic hepatic abscess commonly results from biliary tract infection or portal vein pyemia (eg, bowel leakage). Although it causes abdominal pain, patients are typically febrile. Pathologic examination often

https://t.me/USMLEWorldStep1

Pathology	• Sheets or plates of benign hepatocytes

Exhibit Display

Hepatocellular carcinoma



©UWorld

Zoom In | Zoom Out | Reset | New | Existing | My Notebook

This p
tumor
pills), a
unders

Macro
lobe.
compo
small,
there a
noncir

Patien
pain (
vascul
hypote

(Choi
typical

(Choi
cirrhos
increa
not su

(Choice D) Pyogenic hepatic abscess commonly results from biliary tract infection or portal vein pyemia (eg, bowel leakage). Although it causes abdominal pain, patients are typically febrile. Pathologic examination often

https://t.me/USMLEWorldStep1

OCPs = oral contraceptive pills.

This p
tumor
pills), a
unders

Macro
lobe.
compo
small,
there a
noncir

Patien
pain (
vascul
hypote

(Choi
typical

(Choi
cirrhos
increa
not su

(Choi
bowel
shows

(Choice E) The liver is a common site of metastasis in patients with a history of malignancy (eg, colorectal). Histopathology of metastases may resemble that of the primary tumor (eg, atypical epithelial cells forming

Exhibit Display

Hepatocellular carcinoma

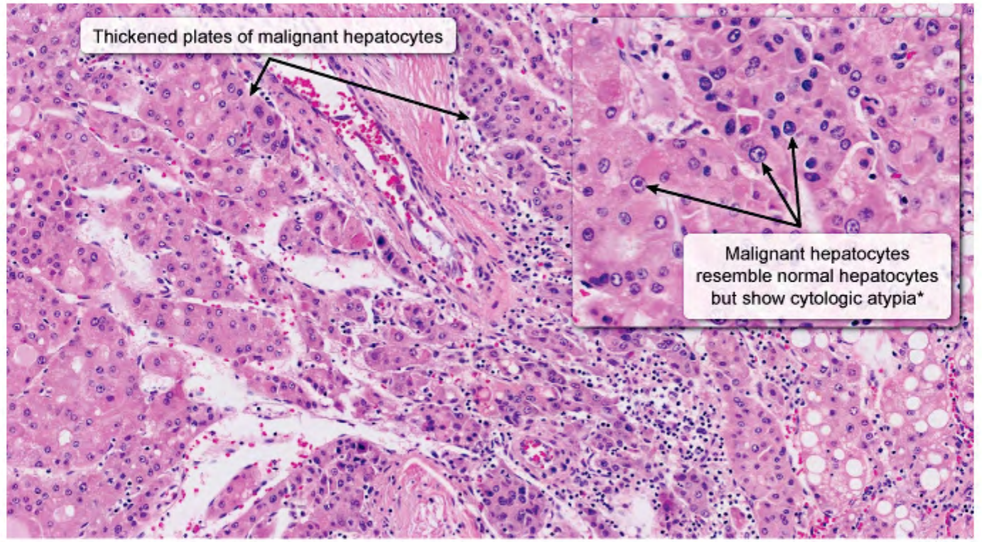

*Eg, large, irregular, hyperchromatic nuclei; prominent nucleoli.

©UWorld

Zoom In | Zoom Out | Reset | New | Existing | My Notebook

https://t.me/USMLEWorldStep1

tumor found predominantly in **young women**. It is associated with **estrogen** exposure (eg, oral contraceptive pills), anabolic steroid use, and obesity. Pathogenesis is thought to be hormonally mediated but is not fully unders

Macro
lobe.
compo
small,
there
noncir

Patien
pain (
vascul
hypote

(Choi
typical

(Choi
cirrhos
increa
not su

(Choi
bowel
shows

(Choi
Histop
infiltra

Educational objective:
Hepatocellular adenomas are benign liver tumors found predominantly in young women with a history of oral

Exhibit Display

Pyogenic hepatic abscess

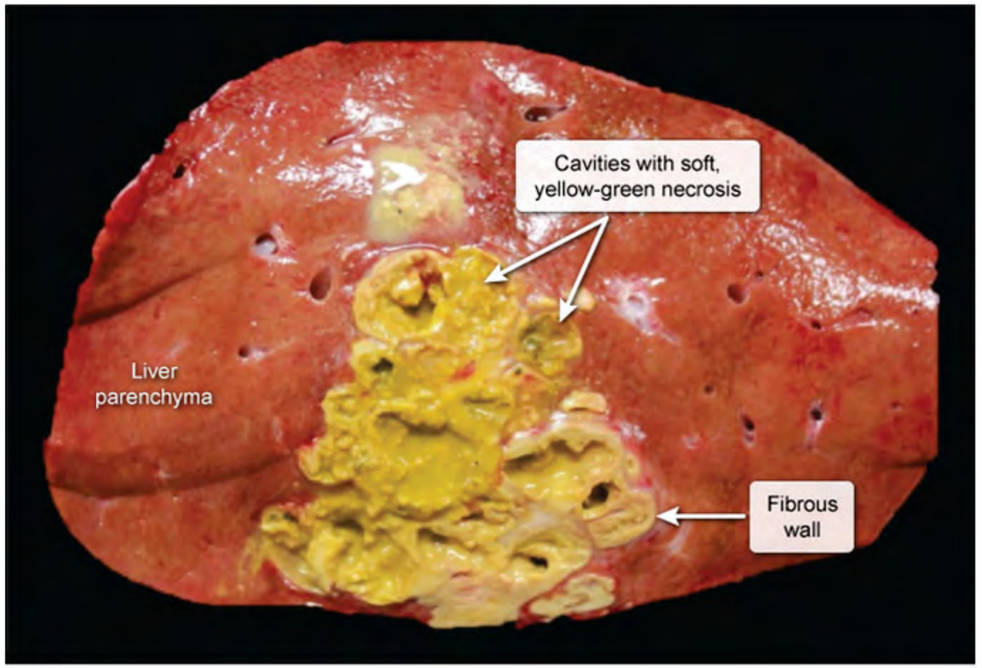

©UWorld

Zoom In | Zoom Out | Reset | New | Existing | My Notebook

https://t.me/USMLEWorldStep1

tumor found predominantly in **young women**. It is associated with **estrogen** exposure (eg, oral contraceptive pills), anabolic steroid use, and obesity. Pathogenesis is thought to be hormonally mediated but is not fully unders

Macro
lobe.
compo
small,
there
noncir

Patien
pain (
vascul
hypote

(Choi
typical

(Choi
cirrhos
increa
not su

(Choi
bowel
shows

(Choi
Histop
infiltra

Educational objective:
Hepatocellular adenomas are benign liver tumors found predominantly in young women with a history of oral

Exhibit Display

Hepatocellular carcinoma

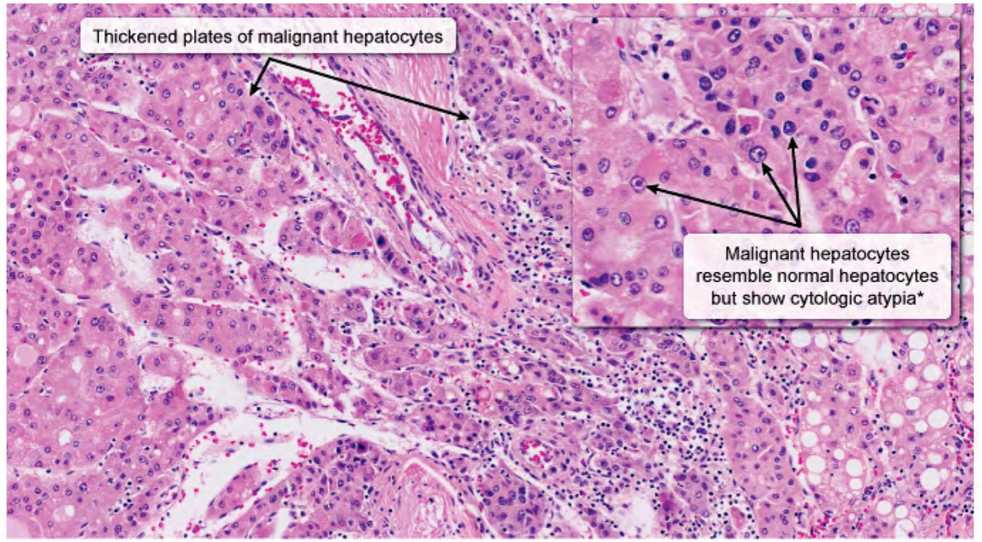

*Eg, large, irregular, hyperchromatic nuclei; prominent nucleoli.

©UWorld

Zoom In | Zoom Out | Reset | New | Existing | My Notebook

https://t.me/USMLEWorldStep1

Macroscopically, HCA is typically a well-circumscribed, solid, **solitary, unencapsulated** mass arising in the right lobe. The cut surface is often soft and tan with areas of hemorrhage and necrosis. Histologically, HCA is compo
small,
there a
noncir

Patien
pain (
vascul
hypote

(Choi
typical

(Choi
cirrhos
increa
not su

(Choi
bowel
shows

(Choi
Histop
infiltrat

Educa
Hepat
contra
promin
intraabdominal bleeding due to tumor rupture.

Exhibit Display

Metastatic colonic adenocarcinoma to liver

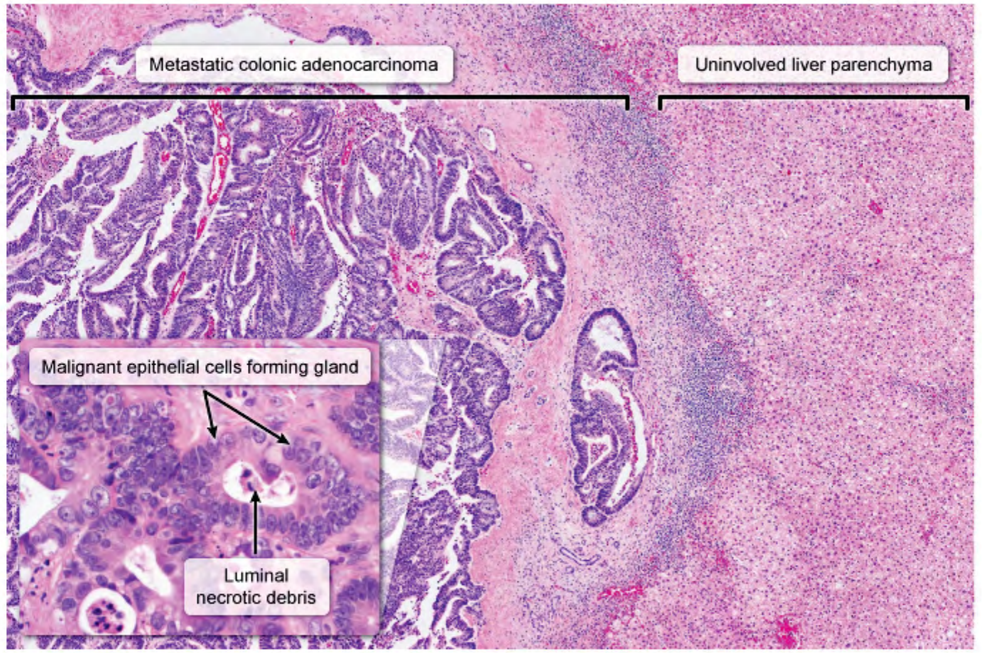

©UWorld

Zoom In | Zoom Out | Reset | New | Existing | My Notebook

https://t.me/USMLEWorldStep1

A 34-year-old man comes to the office due to anorexia, nausea, and dark-colored urine for the last 2 days. He travels frequently for business and recently returned from a trip to Mexico. The patient has a history of asthma and occasionally uses inhaled albuterol for symptom management. Temperature is 37.8 C (100.2 F), blood pressure is 125/70 mm Hg, and pulse is 94/min. Cardiopulmonary examination is normal. There is mild right upper quadrant abdominal tenderness with no guarding or rebound. Serologic testing for *Entamoeba histolytica* is negative. Which of the following histologic findings is most likely to be found within this patient's liver?

- A. Fibrinoid necrosis
- B. Hepatocyte swelling
- C. Liquefactive necrosis
- D. Malignant cells
- E. Regenerative nodules

Submit

https://t.me/USMLEWorldStep1

A 34-year-old man comes to the office due to anorexia, nausea, and dark-colored urine for the last 2 days. He travels frequently for business and recently returned from a trip to Mexico. The patient has a history of asthma and occasionally uses inhaled albuterol for symptom management. Temperature is 37.8 C (100.2 F), blood pressure is 125/70 mm Hg, and pulse is 94/min. Cardiopulmonary examination is normal. There is mild right upper quadrant abdominal tenderness with no guarding or rebound. Serologic testing for *Entamoeba histolytica* is negative. Which of the following histologic findings is most likely to be found within this patient's liver?

- ✗ A. Fibrinoid necrosis (8%)
- ✓ B. Hepatocyte swelling (74%)
- C. Liquefactive necrosis (8%)
- D. Malignant cells (1%)
- E. Regenerative nodules (6%)

Incorrect
Correct answer
B

74%
Answered correctly

04 secs
Time Spent

2023
Version

Explanation

This patient's low-grade fever, anorexia/nausea, dark-colored urine, and right upper quadrant abdominal tenderness is suggestive of **acute viral hepatitis**. Hepatitis A virus (HAV) is most likely responsible because it is the most common cause of acute viral hepatitis in young adults, and this patient has just returned from an endemic region.

Although liver biopsy is not required to make the diagnosis, the hallmark histologic findings of acute viral hepatitis include hepatocyte damage with mononuclear infiltration. Ballooning degeneration, characterized by **cellular swelling** and **cytoplasmic emptying**, is a form of hepatocyte injury caused by ATP depletion and disruption of the intermediate filament network that often progresses to cell rupture and death (eg, **necrosis**). Hepatocytes may

https://t.me/USMLEWorldStep1

This patient's low-grade fever, anorexia/nausea, dark-colored urine, and right upper quadrant abdominal tenderness is suggestive of **acute viral hepatitis**. Hepatitis A virus (HAV) is most likely responsible because it is the most common cause of acute viral hepatitis in young adults, and this patient has just returned from an endemic region.

Although liver biopsy is not required to make the diagnosis, the hallmark histologic findings of acute viral hepatitis include hepatocyte damage with mononuclear infiltration. Ballooning degeneration, characterized by **cellular swelling** and **cytoplasmic emptying**, is a form of hepatocyte injury caused by ATP depletion and disruption of the intermediate filament network that often progresses to cell rupture and death (eg, **necrosis**). Hepatocytes may also undergo apoptosis, which is characterized by cellular shrinkage and nuclear fragmentation with intensely eosinophilic cytoplasm (eg, Councilman bodies) and is likely caused by mitochondrial oxidative damage.

In severe cases, swaths of dead hepatocytes may span across the lobules (eg, bridging necrosis). The presence of virally infected and dying hepatocytes promotes **mononuclear inflammation** (eg, lymphocytes) throughout the lobule and around the portal tracts.

(Choice A) Fibrinoid necrosis is characterized by the deposition of amorphous, proteinaceous material in the walls of blood vessels affected by immune vasculitis or malignant hypertension.

(Choice C) Severe viral hepatitis can cause coagulative necrosis of hepatocytes. However, liquefactive necrosis classically occurs in the CNS due to enzymatic degradation of tissue. Amebic liver abscesses caused by *Entamoeba histolytica* infection may also produce liquefactive necrosis, but this is unlikely in the setting of negative serologic testing.

(Choice D) HAV is not associated with an increased risk of hepatocellular cancer. However, hepatitis B and C infections, aflatoxin B exposure, and all other forms of chronic hepatocyte injury are associated with increased incidence of hepatocellular carcinoma.

(Choice E) Nodular regeneration of hepatocytes is generally found in patients with cirrhosis, which can be caused by chronic viral hepatitis. Hepatitis B and hepatitis C viruses (not HAV) are associated with chronic hepatitis.

Educational objective:
Acute hepatitis due to most hepatotropic viruses causes hepatocyte injury (eg, ballooning degeneration) and cell

https://t.me/USMLEWorldStep1

region.

Although liver biopsy is not required to make the diagnosis, the hallmark histologic findings of acute viral hepatitis include hepatocyte damage with mononuclear infiltration. Ballooning degeneration, characterized by **cellular swelling** and **cytoplasmic emptying**, is a form of hepatocyte injury caused by ATP depletion and disruption of the intermediate filament network that often progresses to cell rupture and death (eg, **necrosis**). Hepatocytes may also undergo apoptosis, which is characterized by cellular shrinkage and nuclear fragmentation with intensely eosinophilic cytoplasm (eg, Councilman bodies) and is likely caused by mitochondrial oxidative damage.

In severe cases, swaths of dead hepatocytes may span across the lobules (eg, bridging necrosis). The presence of virally infected and dying hepatocytes promotes **mononuclear inflammation** (eg, lymphocytes) throughout the lobule and around the portal tracts.

(Choice A) Fibrinoid necrosis is characterized by the deposition of amorphous, proteinaceous material in the walls of blood vessels affected by immune vasculitis or malignant hypertension.

(Choice C) Severe viral hepatitis can cause coagulative necrosis of hepatocytes. However, liquefactive necrosis classically occurs in the CNS due to enzymatic degradation of tissue. Amebic liver abscesses caused by *Entamoeba histolytica* infection may also produce liquefactive necrosis, but this is unlikely in the setting of negative serologic testing.

(Choice D) HAV is not associated with an increased risk of hepatocellular cancer. However, hepatitis B and C infections, aflatoxin B exposure, and all other forms of chronic hepatocyte injury are associated with increased incidence of hepatocellular carcinoma.

(Choice E) Nodular regeneration of hepatocytes is generally found in patients with cirrhosis, which can be caused by chronic viral hepatitis. Hepatitis B and hepatitis C viruses (not HAV) are associated with chronic hepatitis.

Educational objective:
Acute hepatitis due to most hepatotropic viruses causes hepatocyte injury (eg, ballooning degeneration) and cell death with mononuclear cell infiltration.

Pathology	Gastrointestinal & Nutrition	Hepatitis a
Subject	System	Topic

https://t.me/USMLEWorldStep1

This patient's low-grade fever, anorexia/nausea, dark-colored urine, and right upper quadrant abdominal tender
the mo
region

Althou
include
swelli
interm
also u
eosinc

In sev
of vira
lobule

(Choi
of bloc

(Choi
classic
Entam
serolo

(Choi
infecti
incide

(Choi
by chr

Educa

Acute hepatitis due to most hepatotropic viruses causes hepatocyte injury (eg, ballooning degeneration) and cell

Exhibit Display

Ballooning degeneration

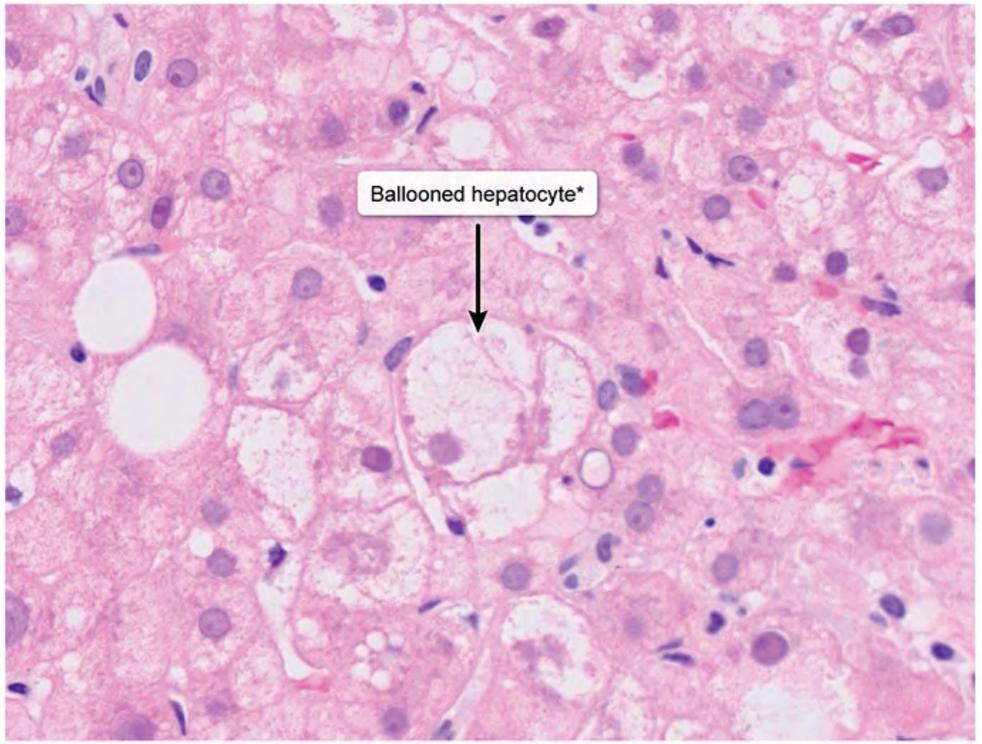

*Hepatocyte injury characterized by cell swelling and cytoplasmic clearing.

©UWorld

Zoom In Zoom Out Reset New | Existing My Notebook

https://t.me/USMLEWorldStep1

This patient's low-grade fever, anorexia/nausea, dark-colored urine, and right upper quadrant abdominal tender
the mo
region

Althou
include
swelli
interm
also u
eosinc

In sev
of vira
lobule

(Choi
of bloc

(Choi
classic
Entam
serolo

(Choi
infecti
incide

(Choi
by chr

Exhibit Display

Apoptotic hepatocyte

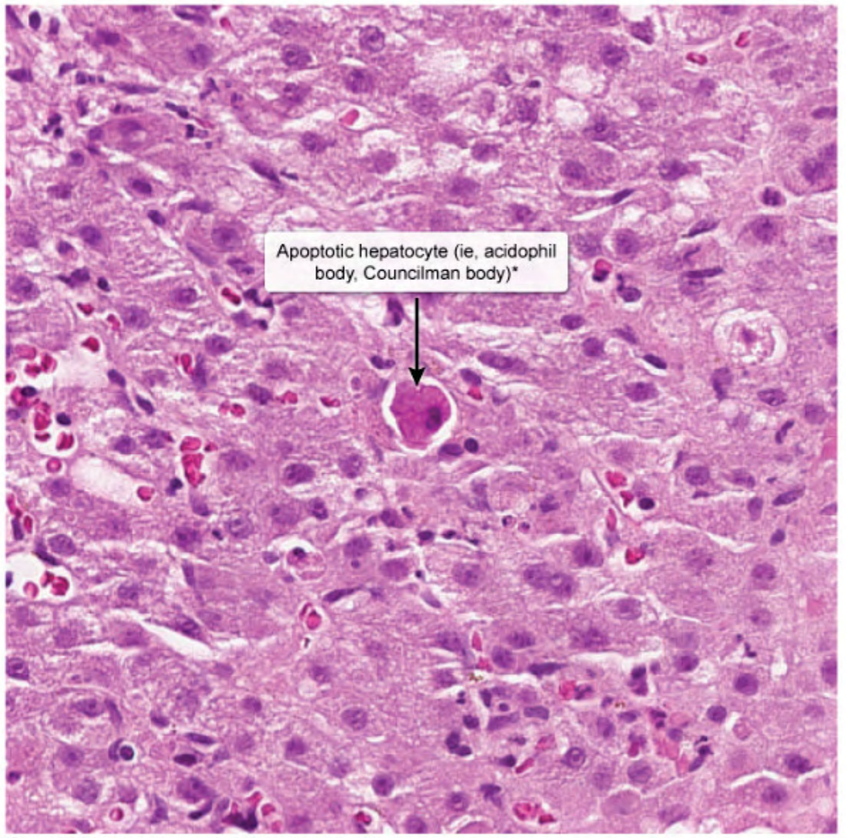

*Dense pink cytoplasm and small, dark (ie, pyknotic) nucleus.

©UWorld

Zoom In | Zoom Out | Reset | New | Existing | My Notebook

https://t.me/USMLEWorldStep1

This patient's low-grade fever, anorexia/nausea, dark-colored urine, and right upper quadrant abdominal tender
the mo
region

Althou
include
swelli
interm
also u
eosinc

In sev
of vira
lobule

(Choi
of bloc

(Choi
classic
Entam
serolo

(Choi
infecti
incide

(Choi
by chr

Exhibit Display

Acute viral hepatitis

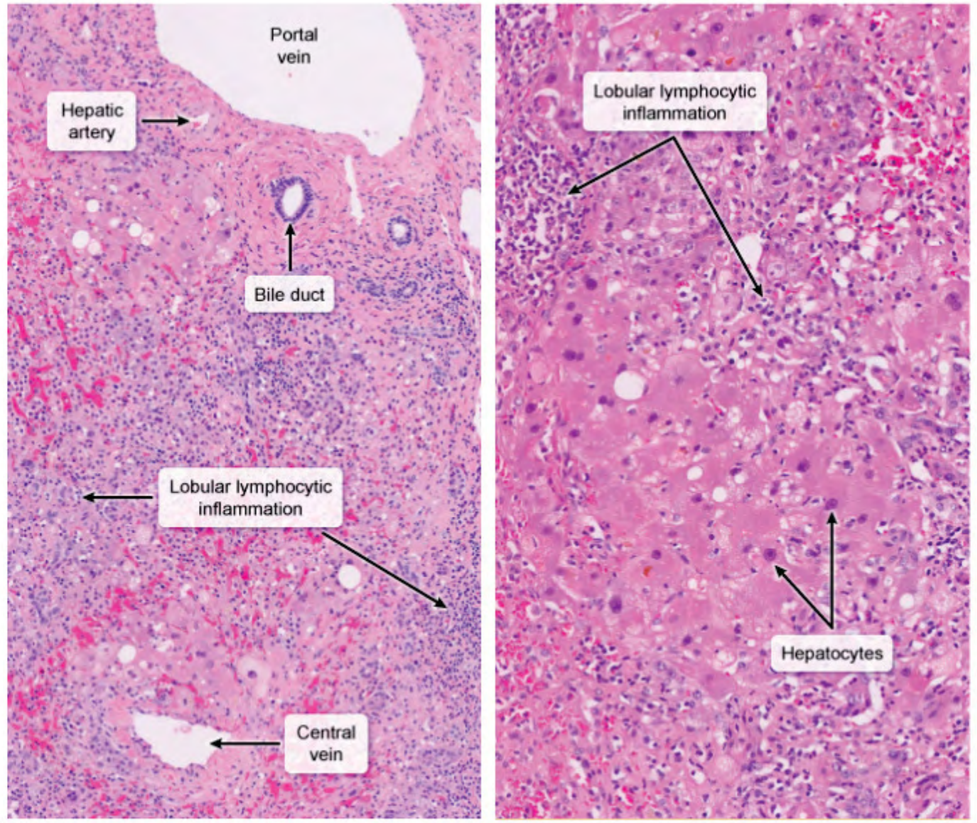

©UWorld

Zoom In | Zoom Out | Reset | New | Existing | My Notebook

https://t.me/USMLEWorldStep1
Show all

This patient's low-grade fever, anorexia/nausea, dark-colored urine, and right upper quadrant abdominal tender
the mo
region

Althou
include
swelli
interm
also u
eosinc

In sev
of vira
lobule

(Choi
of bloc

(Choi
classic
Entam
serolo

(Choi
infecti
incide

(Choi
by chronic viral hepatitis. Hepatitis B and hepatitis C viruses (not HAV) are associated with chronic hepatitis.

Exhibit Display

Fibrinoid necrosis

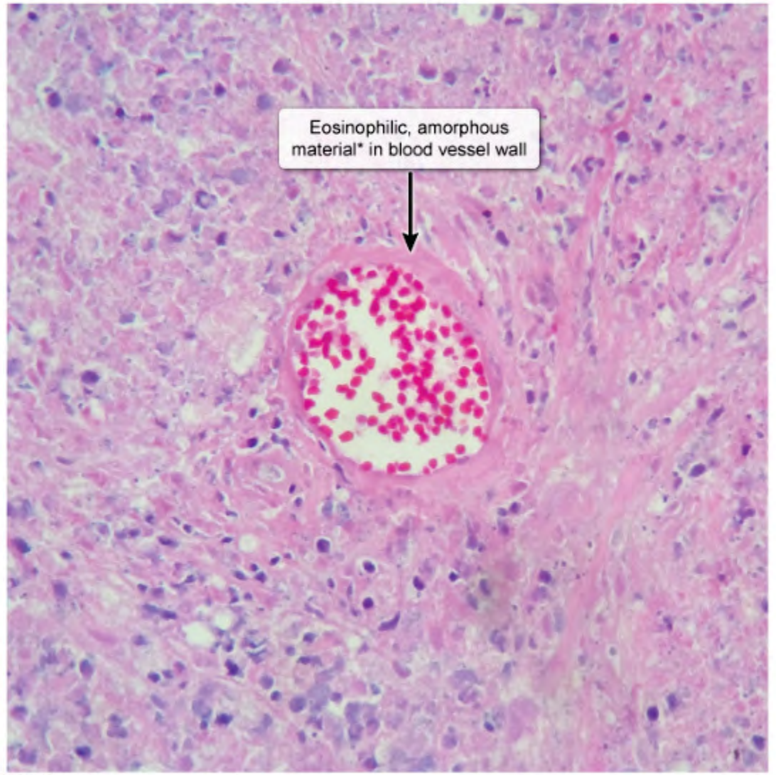

*Fibrin deposition.

©UWorld

Zoom In | Zoom Out | Reset | New | Existing | My Notebook

https://t.me/USMLEWorldStep1

swelling and **cytoplasmic emptying**, is a form of hepatocyte injury caused by ATP depletion and disruption of the

interm
also u
eosinc

In sev
of vira
lobule

(Choi
of bloc

(Choi
classic
Entam
serolo

(Choi
infecti
incide

(Choi
by chr

Educa
Acute
death

Pathol
Subject

Exhibit Display

Cirrhosis

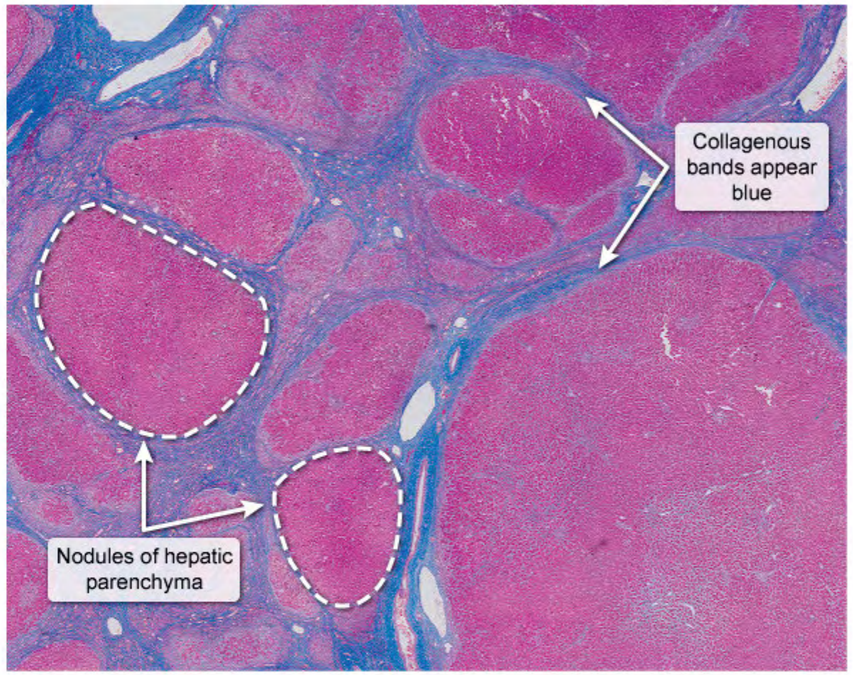

Trichrome stain

©UWorld

Zoom In | Zoom Out | Reset | New | Existing | My Notebook

Copyright © UWorld. All rights reserved.

https://t.me/USMLEWorldStep1

swelling and **cytoplasmic emptying**, is a form of hepatocyte injury caused by ATP depletion and disruption of the

Exhibit Display

Acute viral hepatitis

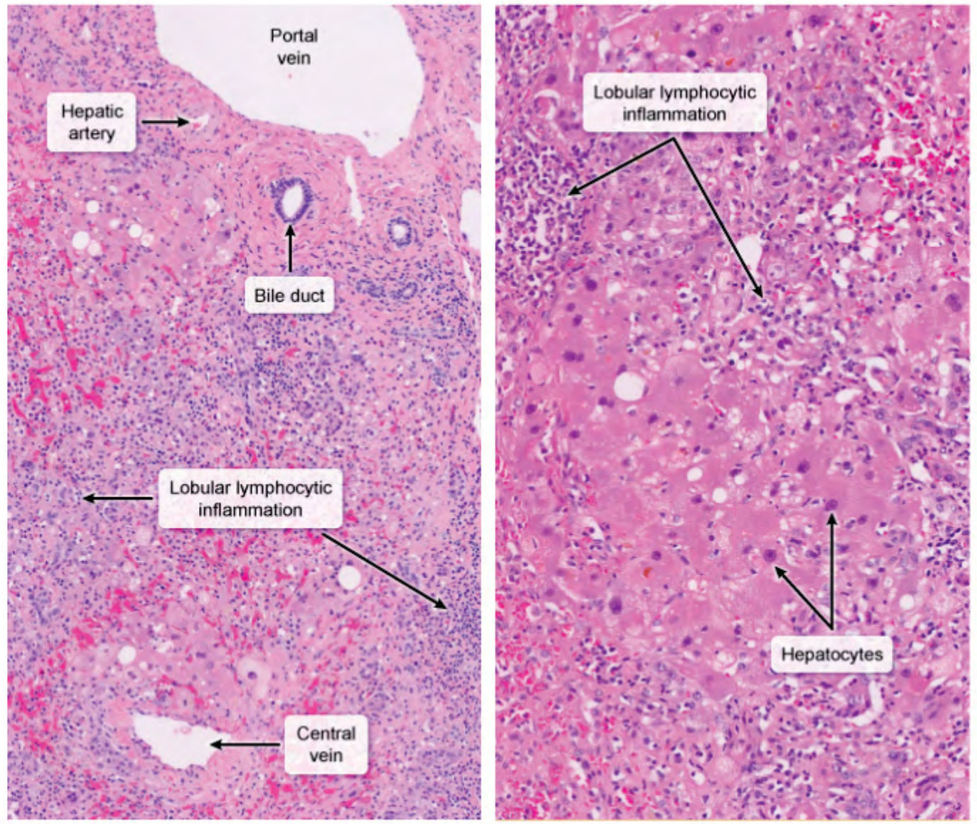

©UWorld

Zoom In | Zoom Out | Reset | New | Existing | My Notebook

https://t.me/USMLEWorldStep1

A 69-year-old man is evaluated for abdominal pain. Upper gastrointestinal endoscopy shows a single shallow, 1-cm ulcer in the duodenal bulb and mild gastric erythema. Biopsy specimens from the gastric antrum do not show *Helicobacter pylori*, and stool testing for *H pylori* antigen is negative. Which of the following parts of the history is most likely to reveal the cause of this patient's current condition?

- A. Family history
- B. Food diary
- C. Medication use
- D. Recent travel
- E. Seasonal allergies

Submit

https://t.me/USMLEWorldStep1

A 69-year-old man is evaluated for abdominal pain. Upper gastrointestinal endoscopy shows a single shallow, 1-cm ulcer in the duodenal bulb and mild gastric erythema. Biopsy specimens from the gastric antrum do not show *Helicobacter pylori*, and stool testing for *H pylori* antigen is negative. Which of the following parts of the history is most likely to reveal the cause of this patient's current condition?

- ✗ A. Family history (13%)
- B. Food diary (6%)
- ✓ C. Medication use (76%)
- D. Recent travel (2%)
- E. Seasonal allergies (0%)

Incorrect
Correct answer
C

76%
Answered correctly

16 secs
Time Spent

2023
Version

Explanation

NSAID-induced gastrointestinal bleeding

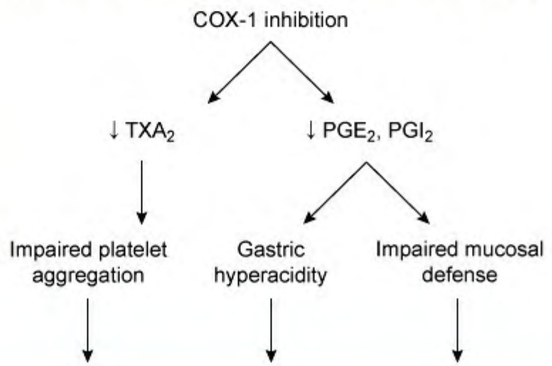

https://t.me/USMLEWorldStep1

A 69-year-old man is evaluated for abdominal pain. Upper gastrointestinal endoscopy shows a single shallow, 1-cm ulc
Helico
most li

Inco
Corre
C

Expl

Exhibit Display

NSAID-induced gastrointestinal bleeding

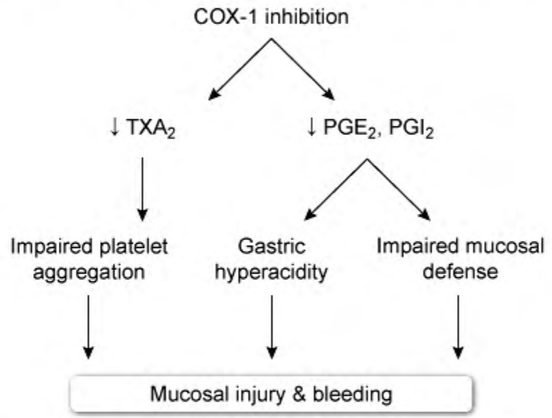

COX-1 = cyclooxygenase 1; **NSAID** = nonsteroidal anti-inflammatory drug;
PGE_2 = prostaglandin E_2; **PGI_2** = prostaglandin I_2 (prostacyclin);
TXA_2 = thromboxane A_2.

©UWorld

Zoom In | Zoom Out | Reset | New | Existing | My Notebook

https://t.me/USMLEWorldStep1

COX-1 = cyclooxygenase 1; **NSAID** = nonsteroidal anti-inflammatory drug; **PGE_2** = prostaglandin E_2; **PGI_2** = prostaglandin I_2 (prostacyclin); **TXA_2** = thromboxane A_2.

©UWorld

Peptic ulcers (defects in the stomach or duodenal mucosa) are most commonly due to *Helicobacter pylori* infection or **nonsteroidal anti-inflammatory drug (NSAID) use**. The majority of duodenal ulcers are associated with *H pylori* infection, but the prevalence is decreasing in the United States due to improved hygienic practices. *H pylori* has been adequately ruled out in this patient; therefore, he most likely has an NSAID-related duodenal ulcer.

Nonselective NSAIDs (eg, ibuprofen, naproxen, aspirin) exert analgesic, anti-inflammatory, and antipyretic effects through the inhibition of both forms of the cyclo-oxygenase (COX) enzyme. In the gastrointestinal tract, the COX-1 subtype is responsible for the synthesis of prostaglandins, which are critical for the maintenance of intestinal mucosa. **Inhibition of COX-1** leads to increased gastric acid formation, decreased mucosal bicarbonate production, and decreased mucosal blood flow, which can increase the risk for gastritis and peptic ulcer formation. Patients who are age >65 or those on long-term or high-dose NSAID therapy are at the highest risk.

(Choice A) Multiple endocrine neoplasia type 1 is a rare hereditary disorder that presents with pituitary, parathyroid, and pancreatic tumors, including gastrinomas. Gastrinomas manifest as peptic ulcer disease, but patients typically develop multiple ulcers and often have evidence of other neoplasias (eg, hypercalcemia from hyperparathyroidism, visual field defects from pituitary adenomas).

(Choices B and E) Diet and seasonal allergies are not associated with peptic ulcer disease, although certain foods (eg, spicy) may exacerbate ulcer-related dyspepsia and abdominal pain.

(Choice D) Travel to a resource-limited country increases the risk of *H pylori* infection; however, *H pylori was* ruled out in this patient.

Educational objective:
Peptic ulcers are most commonly caused by *Helicobacter pylori* infection or nonsteroidal anti-inflammatory drug (NSAID) use. NSAIDs inhibit cyclo-oxygenase-1, leading to increased gastric acid formation, decreased mucosal bicarbonate production, and decreased mucosal blood flow, which promote mucosal injury and ulcer formation.

Pathology	Gastrointestinal & Nutrition	Peptic ulcer disease
Subject	System	Topic

https://t.me/USMLEWorldStep1

A 65-year-old man comes to the office after his wife insisted he get a checkup. The patient feels well and has no chronic medical conditions but has not seen a physician in many years. He received blood transfusions after a motor vehicle trauma in his 20s. The patient does not use tobacco or illicit drugs but drinks 2 or 3 alcoholic beverages daily. Physical examination reveals no hepatomegaly, ascites, or dilation of the superficial abdominal veins. The remainder of the examination shows no abnormalities. Serology is positive for hepatitis C antibodies. Chronic hepatitis C infection is confirmed with positive HCV RNA testing. After appropriate counseling is provided, combination therapy with sofosbuvir and ledipasvir is planned. This treatment is most likely to help clear the infection through which of the following mechanisms?

- A. Blocking reverse transcription of viral RNA
- B. Enhancing antiviral host immune response
- C. Impairing viral entry into host cells
- D. Inhibiting viral genome replication and assembly
- E. Preventing new virion release from infected host cells

Submit

https://t.me/USMLEWorldStep1

A 65-year-old man comes to the office after his wife insisted he get a checkup. The patient feels well and has no chronic medical conditions but has not seen a physician in many years. He received blood transfusions after a motor vehicle trauma in his 20s. The patient does not use tobacco or illicit drugs but drinks 2 or 3 alcoholic beverages daily. Physical examination reveals no hepatomegaly, ascites, or dilation of the superficial abdominal veins. The remainder of the examination shows no abnormalities. Serology is positive for hepatitis C antibodies. Chronic hepatitis C infection is confirmed with positive HCV RNA testing. After appropriate counseling is provided, combination therapy with sofosbuvir and ledipasvir is planned. This treatment is most likely to help clear the infection through which of the following mechanisms?

- ✗ A. Blocking reverse transcription of viral RNA (16%)
- B. Enhancing antiviral host immune response (3%)
- C. Impairing viral entry into host cells (3%)
- ✓ D. Inhibiting viral genome replication and assembly (66%)
- E. Preventing new virion release from infected host cells (10%)

Incorrect
Correct answer
D

66%
Answered correctly

03 secs
Time Spent

2023
Version

Explanation

Hepatitis C virus (HCV) is a blood-borne pathogen that is primarily transmitted via injection drug use or transfusion of blood products (prior to widespread screening in 1992). Chronic infection develops in most individuals and increases the risk for cirrhosis and hepatocellular carcinoma. Because chronic HCV infection is often asymptomatic for decades, patients are often unaware that they have contracted the virus until they receive HCV screening.

Treatment of chronic HCV infection is with direct-acting antiviral (DAA) agents, which target specific enzymes in the

https://t.me/USMLEWorldStep1

Explanation

Hepatitis C virus (HCV) is a blood-borne pathogen that is primarily transmitted via injection drug use or transfusion of blood products (prior to widespread screening in 1992). Chronic infection develops in most individuals and increases the risk for cirrhosis and hepatocellular carcinoma. Because chronic HCV infection is often asymptomatic for decades, patients are often unaware that they have contracted the virus until they receive HCV screening.

Treatment of chronic HCV infection is with direct-acting antiviral (DAA) agents, which target specific enzymes in the HCV life cycle to **inhibit viral replication and assembly**, as follows:

- **RNA-dependent RNA polymerase inhibitors** – HCV binds to and enters host cells, uncoats, and subsequently replicates its genome using HCV-encoded RNA-dependent RNA polymerase. Nucleotide/non-nucleoside RNA polymerase inhibitors such as **sofosbuvir** target this step.
- **Protease inhibitors** – HCV mRNA is translated by host ribosomes into a polyprotein, which is cleaved by HCV protease into the individual proteins that compose the virus. HCV protease inhibitors such as simeprevir target this step.
- **NS5A inhibitors** – The HCV protein NS5A is crucial for viral replication and assembly (through unclear mechanisms) and is targeted by HCV medications such as **ledipasvir**.

DAA treatment results in a sustained virologic response (complete elimination of virus) in >97% of treated individuals.

(Choice A) HCV does not contain a reverse transcriptase enzyme so it does not integrate its genome into the host cell. Therefore, there are no reverse transcriptase inhibitors for HCV. Reverse transcriptase inhibitors are a mainstay of therapy for HIV.

(Choice B) Interferon-alpha was previously used in the treatment of chronic HCV (in combination with ribavirin) to trigger a broad antiviral immune response. However, interferon therapy has a lower cure rate (50%-80%) and a much higher incidence of side effects (eg, flu-like symptoms). Therefore, DAAs are now used preferentially.

(Choice C) HIV fusion inhibitors (eg, enfuvirtide) and CCR5 inhibitors (eg, maraviroc) inhibit the ability of HIV to

https://t.me/USMLEWorldStep1

- **RNA-dependent RNA polymerase inhibitors** – HCV binds to and enters host cells, uncoats, and subsequently replicates its genome using HCV-encoded RNA-dependent RNA polymerase. Nucleotide/non-nucleoside RNA polymerase inhibitors such as **sofosbuvir** target this step.
- **Protease inhibitors** – HCV mRNA is translated by host ribosomes into a polyprotein, which is cleaved by HCV protease into the individual proteins that compose the virus. HCV protease inhibitors such as simeprevir target this step.
- **NS5A inhibitors** – The HCV protein NS5A is crucial for viral replication and assembly (through unclear mechanisms) and is targeted by HCV medications such as **ledipasvir**.

DAA treatment results in a sustained virologic response (complete elimination of virus) in >97% of treated individuals.

(Choice A) HCV does not contain a reverse transcriptase enzyme so it does not integrate its genome into the host cell. Therefore, there are no reverse transcriptase inhibitors for HCV. Reverse transcriptase inhibitors are a mainstay of therapy for HIV.

(Choice B) Interferon-alpha was previously used in the treatment of chronic HCV (in combination with ribavirin) to trigger a broad antiviral immune response. However, interferon therapy has a lower cure rate (50%-80%) and a much higher incidence of side effects (eg, flu-like symptoms). Therefore, DAAs are now used preferentially.

(Choice C) HIV fusion inhibitors (eg, enfuvirtide) and CCR5 inhibitors (eg, maraviroc) inhibit the ability of HIV to enter cells. DAAs do not target viral entry.

(Choice E) Although HCV virion release could be a target for DAAs, there are currently no approved medications that target this step. Virion release (budding) is targeted by neuraminidase inhibitors in the treatment of influenza.

Educational objective:
Chronic hepatitis C virus infection is treated with direct-acting antiviral (DAAs) medications such as ledipasvir and sofosbuvir. These medications target specific HCV enzymes (eg, protease, NS5A, RNA polymerase), which inhibits viral replication and assembly. Treatment with DAAs results in cure in >97% of patients.

References

- HCV NS5A replication complex inhibitors.

https://t.me/USMLEWorldStep1

- **RNA-dependent RNA polymerase inhibitors** – HCV binds to and enters host cells, uncoats, and subsequently replicates its genome using HCV-encoded RNA-dependent RNA polymerase. Nucleotide/non-n
- **P** H ta
- **N** m

DAA tr individ

(Choi cell. T mainst

(Choi trigger much

(Choi enter

(Choi that ta

Educa Chron sofosb inhibits

References

- HCV NS5A replication complex inhibitors.

Exhibit Display

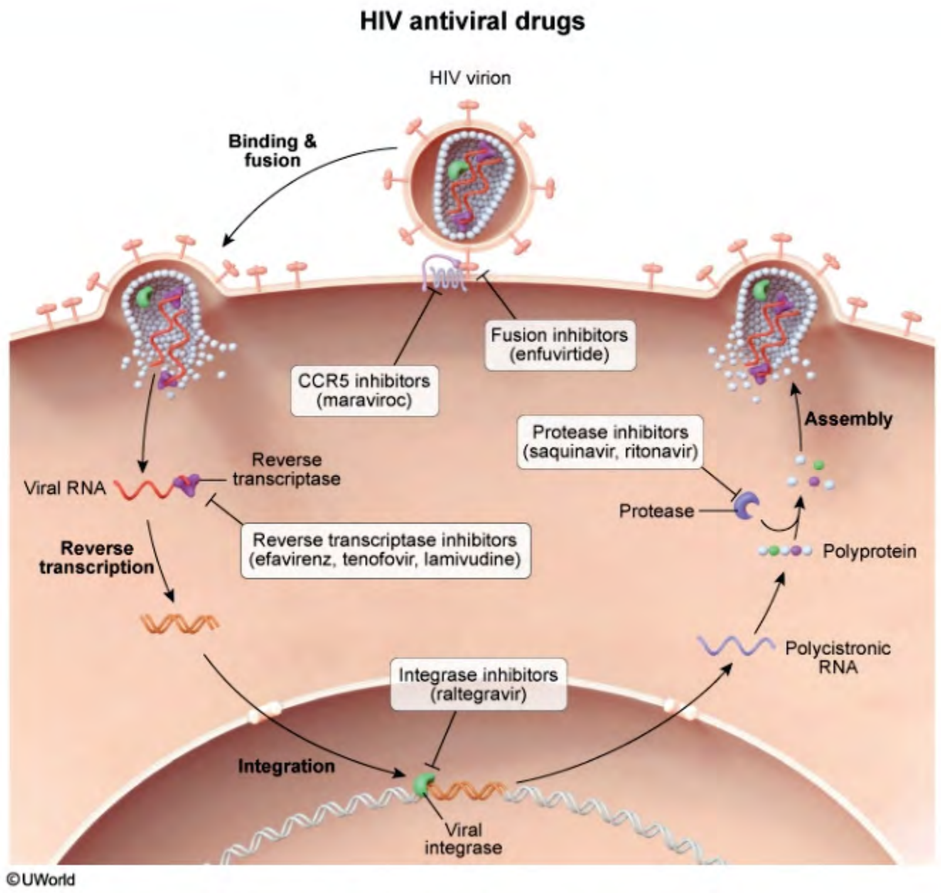

Zoom In | Zoom Out | Reset | New | Existing | My Notebook

https://t.me/USMLEWorldStep1

A 35-year-old man is admitted to the hospital with a 2-day history of abdominal pain. The patient's condition deteriorates throughout the course of hospitalization, and he dies 5 days after admission. Autopsy reveals chalky white lesions in the mesentery. Histologic evaluation of the lesions reveals adipose cell destruction and calcium deposition. Which of the following is the most likely cause of this patient's autopsy findings?

- A. Acute pancreatitis
- B. Bacterial peritonitis
- C. Celiac disease
- D. Crohn disease
- E. Intestinal perforation
- F. Mesenteric ischemia

Submit

https://t.me/USMLEWorldStep1

A 35-year-old man is admitted to the hospital with a 2-day history of abdominal pain. The patient's condition deteriorates throughout the course of hospitalization, and he dies 5 days after admission. Autopsy reveals chalky white lesions in the mesentery. Histologic evaluation of the lesions reveals adipose cell destruction and calcium deposition. Which of the following is the most likely cause of this patient's autopsy findings?

- ✓ A. Acute pancreatitis (74%)
- ✗ B. Bacterial peritonitis (4%)
- C. Celiac disease (0%)
- D. Crohn disease (4%)
- E. Intestinal perforation (2%)
- F. Mesenteric ischemia (13%)

Incorrect
Correct answer
A

74%
Answered correctly

04 secs
Time Spent

2023
Version

Explanation

This patient with abdominal pain and chalky white mesenteric lesions likely had **acute pancreatitis**. To prevent autodigestion, most pancreatic digestive enzymes (except for amylase and lipase) are secreted in an inactive form and are activated on arrival in the duodenum. In acute pancreatitis, intrapancreatic activation of enzymes result in acinar cell damage and pancreatic inflammation.

The release of **lipase** and other digestive enzymes from the inflamed pancreas damages nearby adipose cells. Liberated fatty acids bind calcium ions, precipitating as **insoluble calcium salts** (ie, saponification) that have a **chalky white** appearance grossly. Microscopically, **necrotic adipocytes** (ie, anucleate adipocytes with necrotic debris) and blue calcium deposits are seen (compared to a normal pancreas).

In mild cases, small areas of fat necrosis may be found within and around the pancreas, along with an edematous

https://t.me/USMLEWorldStep1

Explanation

This patient with abdominal pain and chalky white mesenteric lesions likely had **acute pancreatitis**. To prevent autodigestion, most pancreatic digestive enzymes (except for amylase and lipase) are secreted in an inactive form and are activated on arrival in the duodenum. In acute pancreatitis, intrapancreatic activation of enzymes result in acinar cell damage and pancreatic inflammation.

The release of **lipase** and other digestive enzymes from the inflamed pancreas damages nearby adipose cells. Liberated fatty acids bind calcium ions, precipitating as **insoluble calcium salts** (ie, saponification) that have a **chalky white** appearance grossly. Microscopically, **necrotic adipocytes** (ie, anucleate adipocytes with necrotic debris) and blue calcium deposits are seen (compared to a normal pancreas).

In mild cases, small areas of fat necrosis may be found within and around the pancreas, along with an edematous and inflamed pancreatic parenchyma. If the inflammatory process continues, acute necrotic pancreatitis develops. This is characterized by **parenchymal necrosis** and more **extensive fat necrosis**, which can spread to involve the **mesentery**, omentum, and other parts of the abdominal cavity (due to widespread lipase activity). Elastase-mediated destruction of blood vessel walls can cause hemorrhage into the necrotic areas (ie, hemorrhagic pancreatitis), and black hemorrhage may be seen grossly.

(Choice B) Bacterial peritonitis is characterized by a dull-appearing peritoneal surface with areas of viscous white-yellow suppurative exudate. Microscopic examination of the ascitic fluid shows numerous neutrophils.

(Choice C) In celiac disease, gross examination of an involved bowel segment would show normal-appearing serosa and mesentery.

(Choice D) Crohn disease often shows mesenteric fat grossly extending around the serosa of an affected intestinal segment (ie, "creeping fat"). The serosa looks dull-gray, edematous, and granular. The mesentery of an involved segment may become fibrotic due to chronic inflammation.

(Choice E) With intestinal perforation, a full-thickness defect in the intestinal wall is seen on gross examination.

(Choice F) With mesenteric ischemia, gross examination of an affected bowel segment would show dusky red serosa, edema, and hemorrhagic mucosa. Microscopically, areas of coagulative necrosis may be present

https://t.me/USMLEWorldStep1

The release of **lipase** and other digestive enzymes from the inflamed pancreas damages nearby adipose cells. Liberated fatty acids bind calcium ions, precipitating as **insoluble calcium salts** (ie, saponification) that have a **chalky white** appearance grossly. Microscopically, **necrotic adipocytes** (ie, anucleate adipocytes with necrotic debris) and blue calcium deposits are seen (compared to a normal pancreas).

In mild cases, small areas of fat necrosis may be found within and around the pancreas, along with an edematous and inflamed pancreatic parenchyma. If the inflammatory process continues, acute necrotic pancreatitis develops. This is characterized by **parenchymal necrosis** and more **extensive fat necrosis**, which can spread to involve the **mesentery**, omentum, and other parts of the abdominal cavity (due to widespread lipase activity). Elastase-mediated destruction of blood vessel walls can cause hemorrhage into the necrotic areas (ie, hemorrhagic pancreatitis), and black hemorrhage may be seen grossly.

(Choice B) Bacterial peritonitis is characterized by a dull-appearing peritoneal surface with areas of viscous white-yellow suppurative exudate. Microscopic examination of the ascitic fluid shows numerous neutrophils.

(Choice C) In celiac disease, gross examination of an involved bowel segment would show normal-appearing serosa and mesentery.

(Choice D) Crohn disease often shows mesenteric fat grossly extending around the serosa of an affected intestinal segment (ie, "creeping fat"). The serosa looks dull-gray, edematous, and granular. The mesentery of an involved segment may become fibrotic due to chronic inflammation.

(Choice E) With intestinal perforation, a full-thickness defect in the intestinal wall is seen on gross examination.

(Choice F) With mesenteric ischemia, gross examination of an affected bowel segment would show dusky red serosa, edema, and hemorrhagic mucosa. Microscopically, areas of coagulative necrosis may be present.

Educational objective:
In acute pancreatitis, release of lipase and other digestive enzymes causes fat necrosis with precipitation of insoluble calcium salts (ie, saponification), imparting a chalky white gross appearance. Microscopically, necrotic fat cells with calcium deposits are seen. In severe cases, fat necrosis can involve the mesentery, omentum, and other parts of the abdominal cavity.

https://t.me/USMLEWorldStep1

Explanation

Exhibit Display

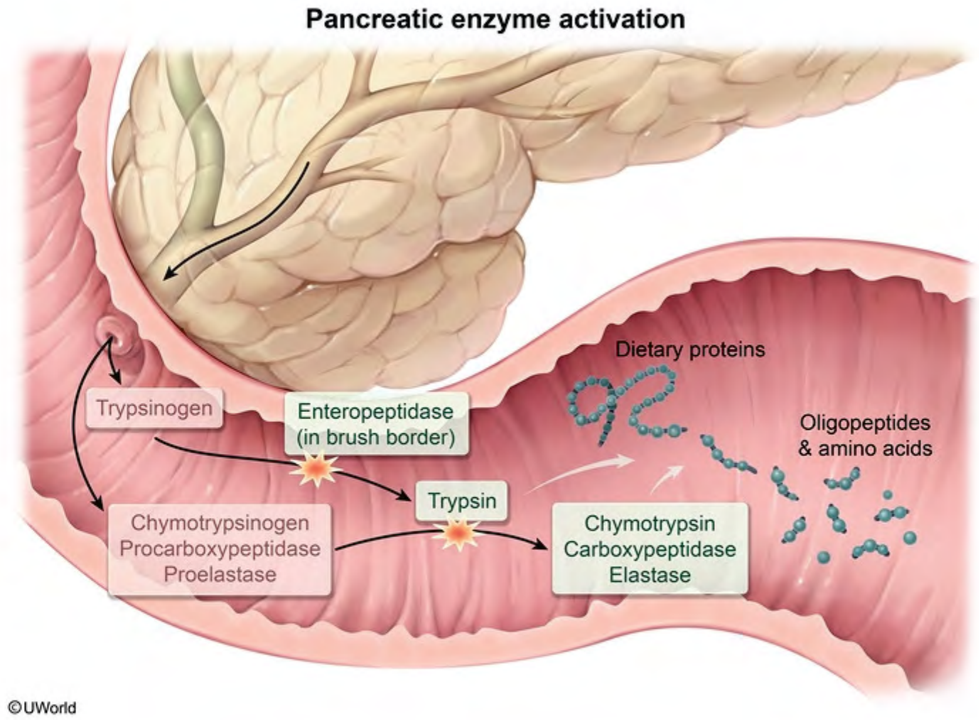

Zoom In | Zoom Out | Reset | New | Existing | My Notebook

This p
autodi
and ar
acinar

The re
Libera
chalk
debris

In milc
and in
This is
the **me**
media
pancre

(Choi
yellow

(Choi
serosa

(Choi
intesti
involve

(Choice E) With intestinal perforation, a full-thickness defect in the intestinal wall is seen on gross examination.

(Choice F) With mesenteric ischemia, gross examination of an affected bowel segment would show dusky red serosa, edema, and hemorrhagic mucosa. Microscopically, areas of coagulative necrosis may be present.

https://t.me/USMLEWorldStep1

Explanation

Exhibit Display

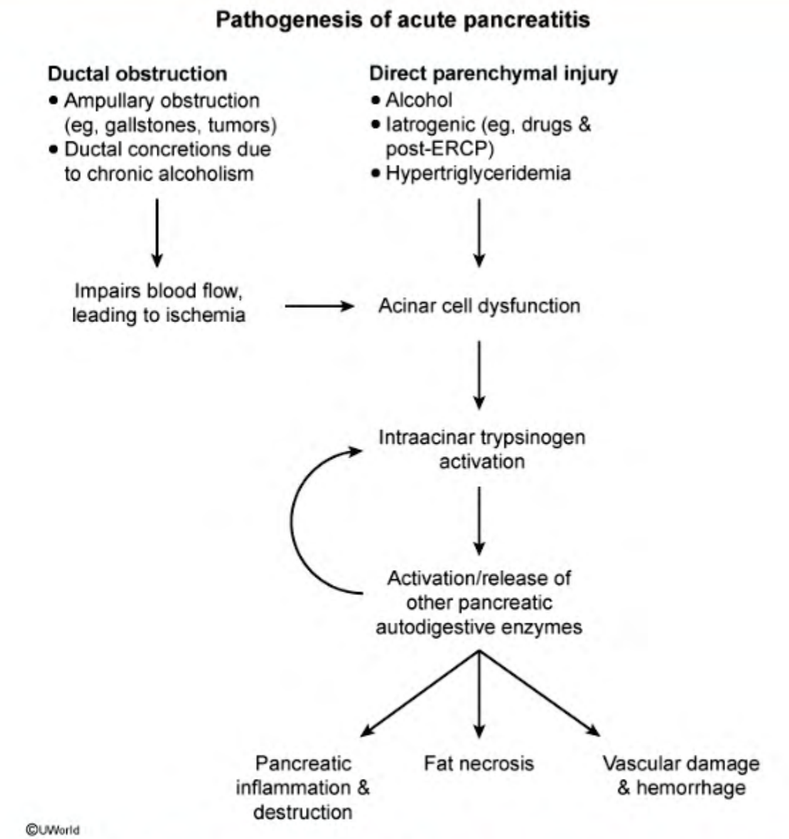

Zoom In | Zoom Out | Reset | New | Existing | My Notebook

This p
autodi
and ar
acinar

The re
Libera
chalk
debris

In mild
and in
This is
the **me**
media
pancre

(Choi
yellow

(Choi
serosa

(Choi
intesti
involve

(Choice E) With intestinal perforation, a full-thickness defect in the intestinal wall is seen on gross examination.

(Choice F) With mesenteric ischemia, gross examination of an affected bowel segment would show dusky red serosa, edema, and hemorrhagic mucosa. Microscopically, areas of coagulative necrosis may be present

https://t.me/USMLEWorldStep1

Explanation

Exhibit Display

This p
autodi
and ar
acinar

The re
Libera
chalky
debris

In milc
and in
This is
the **me**
media
pancre

(Choi
yellow

(Choi
serosa

(Choi
intesti
involve

(Choi

(Choice F) With mesenteric ischemia, gross examination of an affected bowel segment would show dusky red serosa, edema, and hemorrhagic mucosa. Microscopically, areas of coagulative necrosis may be present

Acute pancreatitis

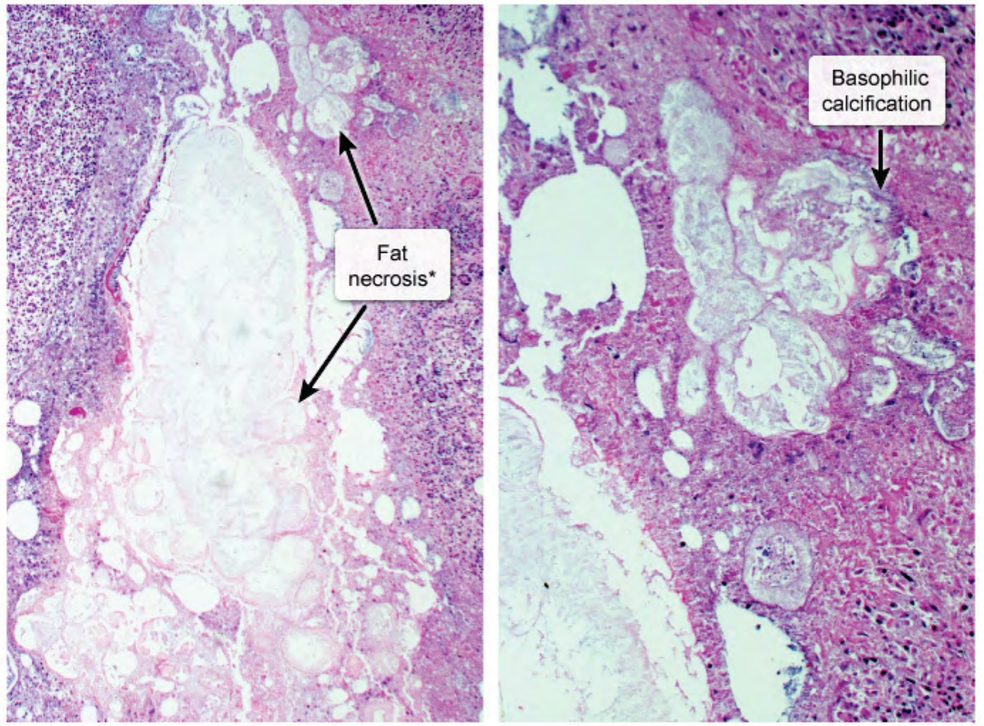

*Anucleate adipocytes with necrotic debris.

©UWorld

Zoom In | Zoom Out | Reset | New | Existing | My Notebook

https://t.me/USMLEWorldStep1

Explanation

Exhibit Display

This p
autodi
and ar
acinar

The re
Libera
chalk
debris

In milc
and in
This is
the **me**
media
pancre

(Choi
yellow

(Choi
serosa

(Choi
intesti
involve

(Choi

(Choice F) With mesenteric ischemia, gross examination of an affected bowel segment would show dusky red serosa, edema, and hemorrhagic mucosa. Microscopically, areas of coagulative necrosis may be present

Normal pancreas

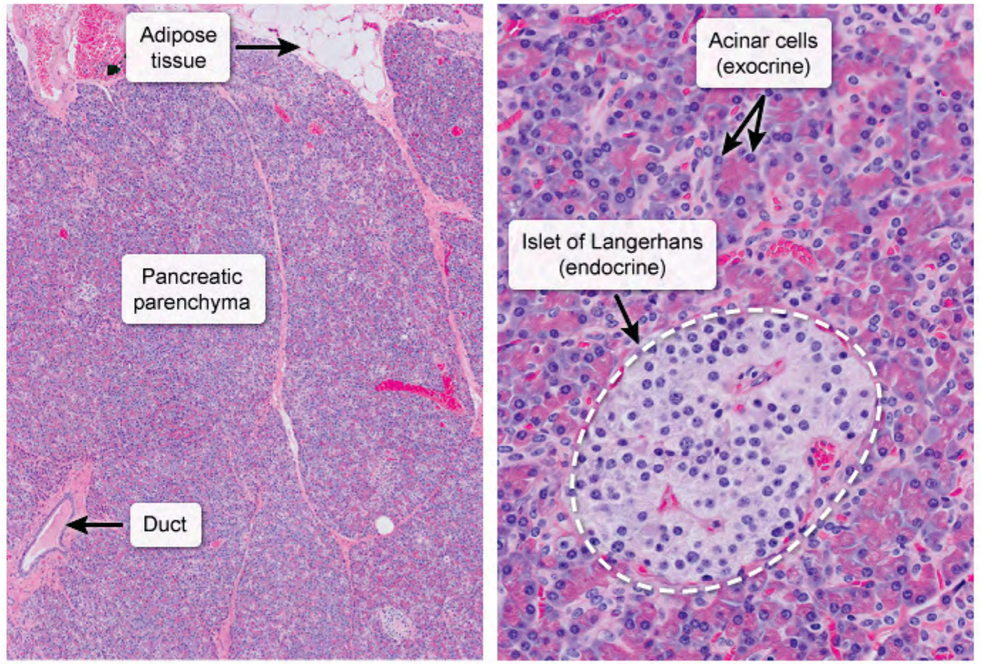

©UWorld

Zoom In | Zoom Out | Reset | New | Existing | My Notebook

https://t.me/USMLEWorldStep1

Explanation

Exhibit Display

This p
autodi
and ar
acinar

The re
Libera
chalk
debris

In milc
and in
This is
the **me**
media
pancre

(Choi
yellow

(Choi
serosa

(Choi
intesti
involve

(Choi

(Choice F) With mesenteric ischemia, gross examination of an affected bowel segment would show dusky red serosa, edema, and hemorrhagic mucosa. Microscopically, areas of coagulative necrosis may be present

Acute pancreatitis

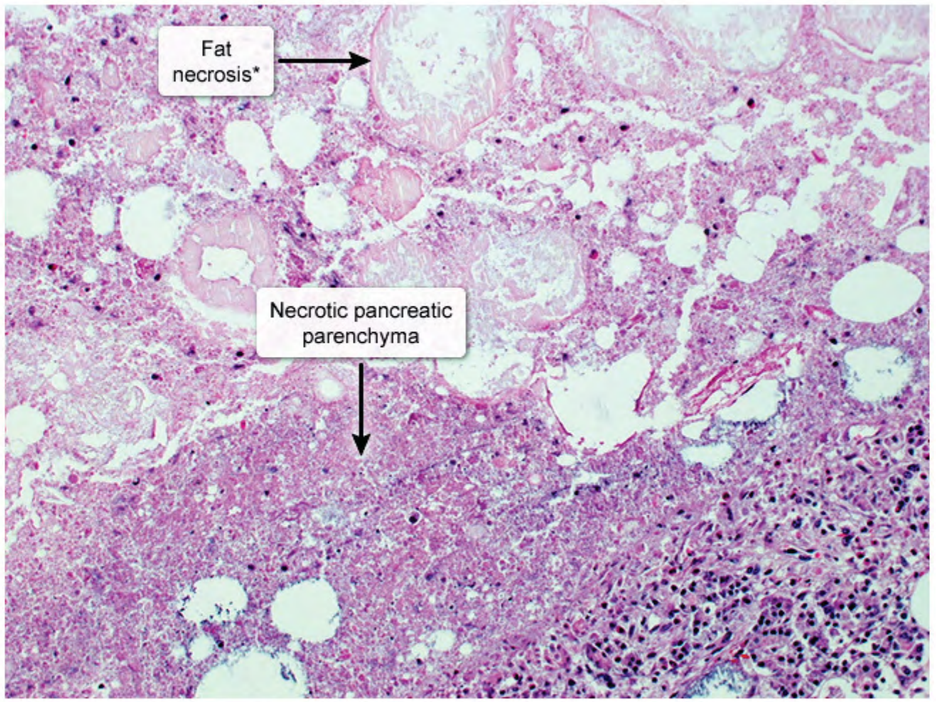

*Anucleate adipocytes with necrotic debris

©UWorld

Zoom In | Zoom Out | Reset | New | Existing | My Notebook

https://t.me/USMLEWorldStep1

A 32-year-old woman comes to the office due to 6 months of persistent diarrhea. She has had 8-10 episodes a day of tea-colored, odorless, watery stools. The symptoms have persisted despite a lactose-free diet and a fasting trial. The patient has had no abdominal pain, fever, or vomiting. Temperature is 36.7 C (98 F). Abdominal examination is unremarkable. Sampling of her gastric contents shows a total lack of gastric acid secretion. Somatostatin treatment promptly relieves the symptoms. An excess of which of the following hormones is most likely responsible for this patient's symptoms?

- A. Cholecystokinin
- B. Gastrin
- C. Ghrelin
- D. Glucagon
- E. Motilin
- F. Vasoactive intestinal peptide

Submit

https://t.me/USMLEWorldStep1

A 32-year-old woman comes to the office due to 6 months of persistent diarrhea. She has had 8-10 episodes a day of tea-colored, odorless, watery stools. The symptoms have persisted despite a lactose-free diet and a fasting trial. The patient has had no abdominal pain, fever, or vomiting. Temperature is 36.7 C (98 F). Abdominal examination is unremarkable. Sampling of her gastric contents shows a total lack of gastric acid secretion. Somatostatin treatment promptly relieves the symptoms. An excess of which of the following hormones is most likely responsible for this patient's symptoms?

- ✗ A. Cholecystokinin (15%)
- B. Gastrin (8%)
- C. Ghrelin (2%)
- D. Glucagon (3%)
- E. Motilin (7%)
- ✓ F. Vasoactive intestinal peptide (63%)

Incorrect
Correct answer
F

63%
Answered correctly

04 secs
Time Spent

2023
Version

Explanation

This patient has secretory diarrhea, distinguished from inflammatory diarrhea by the absence of blood or pus and from osmotic diarrhea (eg, due to lactose intolerance) by its failure to improve with dietary modification. Excess **vasoactive intestinal peptide** (VIP) secretion due to a pancreatic islet cell tumor called VIPoma can result in **watery diarrhea, hypokalemia, and achlorhydria** (WDHA) syndrome (**pancreatic cholera**). VIP stimulates pancreatic bicarbonate and chloride secretion, and its binding to intestinal epithelial cells leads to adenylate cyclase activation and increased cyclic AMP production, causing sodium, chloride, and water secretion into the bowel (**secretory** watery **diarrhea**, often >3 L/day).

https://t.me/USMLEWorldStep1

This patient has secretory diarrhea, distinguished from inflammatory diarrhea by the absence of blood or pus and from osmotic diarrhea (eg, due to lactose intolerance) by its failure to improve with dietary modification. Excess **vasoactive intestinal peptide** (VIP) secretion due to a pancreatic islet cell tumor called VIPoma can result in **watery diarrhea, hypokalemia, and achlorhydria** (WDHA) syndrome (**pancreatic cholera**). VIP stimulates pancreatic bicarbonate and chloride secretion, and its binding to intestinal epithelial cells leads to adenylate cyclase activation and increased cyclic AMP production, causing sodium, chloride, and water secretion into the bowel (**secretory** watery **diarrhea**, often >3 L/day).

Somatostatin (octreotide) decreases the production of many gastrointestinal (GI) hormones (eg, VIP, gastrin, glucagon, cholecystokinin [CCK]). Its inhibition of VIP production by this VIPoma is responsible for the resolution of this patient's symptoms.

(Choice A) CCK causes increased secretion of pancreatic enzymes and bicarbonate, gallbladder contraction, and inhibition of gastric emptying. It does not cause WDHA syndrome. CCK is produced by I cells of the proximal small bowel mucosa in response to fatty acids and amino acids.

(Choice B) Gastrin is produced by G cells in the stomach mucosa. It stimulates gastric acid production and growth of the gastric mucosa. Gastrinomas classically cause intractable peptic ulcer disease (Zollinger-Ellison syndrome), not WDHA syndrome.

(Choice C) Ghrelin is produced in the stomach and regulates food intake. Levels increase in fasting states and fall after eating. Ghrelin antagonists are being investigated as drug targets.

(Choice D) A glucagonoma is a pancreatic alpha cell tumor that hypersecretes glucagon and can cause secondary diabetes mellitus and necrolytic migratory erythema of the skin.

(Choice E) Motilin is produced by the duodenal mucosa and stimulates smooth muscle contraction in the upper GI tract. The antibiotic erythromycin acts as an agonist at motilin receptors in the stomach and duodenum, contributing to the drug's GI side effects.

Educational objective:
VIPomas are pancreatic islet cell tumors that hypersecrete vasoactive intestinal peptide (VIP), which increases

https://t.me/USMLEWorldStep1

vasoactive intestinal peptide (VIP) secretion due to a pancreatic islet cell tumor called VIPoma can result in **watery diarrhea, hypokalemia, and achlorhydria** (WDHA) syndrome (**pancreatic cholera**). VIP stimulates pancreatic bicarbonate and chloride secretion, and its binding to intestinal epithelial cells leads to adenylate cyclase activation and increased cyclic AMP production, causing sodium, chloride, and water secretion into the bowel (**secretory** watery **diarrhea**, often >3 L/day).

Somatostatin (octreotide) decreases the production of many gastrointestinal (GI) hormones (eg, VIP, gastrin, glucagon, cholecystokinin [CCK]). Its inhibition of VIP production by this VIPoma is responsible for the resolution of this patient's symptoms.

(Choice A) CCK causes increased secretion of pancreatic enzymes and bicarbonate, gallbladder contraction, and inhibition of gastric emptying. It does not cause WDHA syndrome. CCK is produced by I cells of the proximal small bowel mucosa in response to fatty acids and amino acids.

(Choice B) Gastrin is produced by G cells in the stomach mucosa. It stimulates gastric acid production and growth of the gastric mucosa. Gastrinomas classically cause intractable peptic ulcer disease (Zollinger-Ellison syndrome), not WDHA syndrome.

(Choice C) Ghrelin is produced in the stomach and regulates food intake. Levels increase in fasting states and fall after eating. Ghrelin antagonists are being investigated as drug targets.

(Choice D) A glucagonoma is a pancreatic alpha cell tumor that hypersecretes glucagon and can cause secondary diabetes mellitus and necrolytic migratory erythema of the skin.

(Choice E) Motilin is produced by the duodenal mucosa and stimulates smooth muscle contraction in the upper GI tract. The antibiotic erythromycin acts as an agonist at motilin receptors in the stomach and duodenum, contributing to the drug's GI side effects.

Educational objective:
VIPomas are pancreatic islet cell tumors that hypersecrete vasoactive intestinal peptide (VIP), which increases intestinal chloride loss into the stool and causes excess losses of the accompanying water, sodium, and potassium. VIP also inhibits gastric acid secretion. Somatostatin inhibits the secretion of VIP and is used to treat the symptoms of VIPoma.

https://t.me/USMLEWorldStep1

A 19-month-old boy is brought to the emergency department with severe abdominal pain and vomiting. On initial evaluation, rebound and guarding are present. Laparotomy is performed, and a portion of the intestine is resected; the gross specimen is shown in the image below:

Which of the following best describes the underlying pathologic process that led to this patient's condition?

- A. Eosinophilic infiltration of the lamina propria
- B. Hypertrophy of intestinal lymphoid follicles
- C. Intraluminal bacterial overgrowth
- D. Neutrophilic infiltration in response to bacterial toxins
- E. Smooth muscle hypertrophy

Submit

https://t.me/USMLEWorldStep1

A 19-month-old boy is brought to the emergency department with severe abdominal pain and vomiting. On initial
evalua
the gr

Which

Sub

Exhibit Display

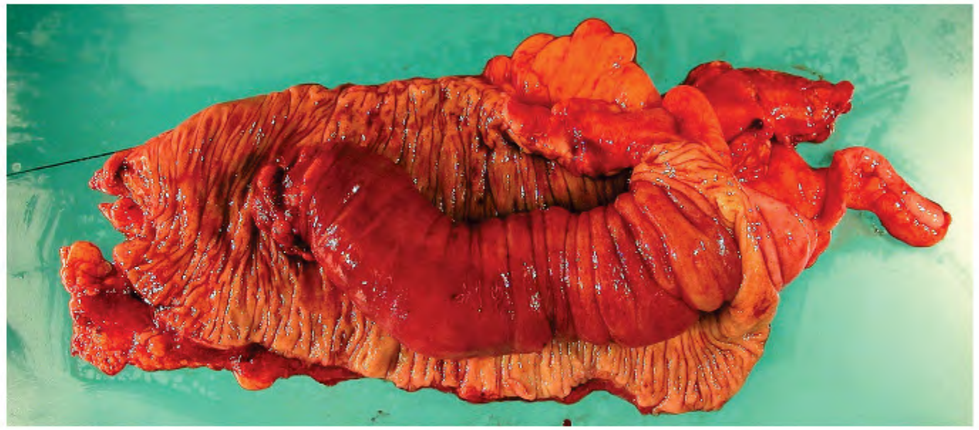

Zoom In Zoom Out Reset New | Existing My Notebook

https://t.me/USMLEWorldStep1

A 19-month-old boy is brought to the emergency department with severe abdominal pain and vomiting. On initial evaluation, rebound and guarding are present. Laparotomy is performed, and a portion of the intestine is resected; the gross specimen is shown in the image below:

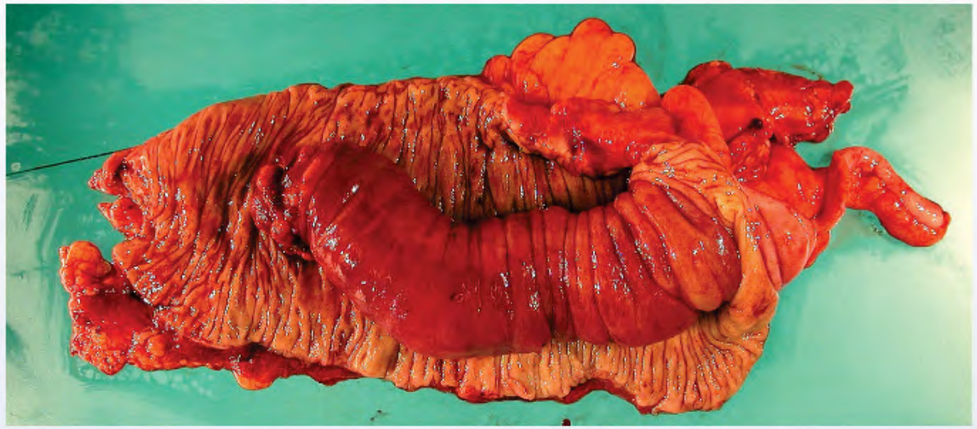

Which of the following best describes the underlying pathologic process that led to this patient's condition?

- A. Eosinophilic infiltration of the lamina propria
- B. Hypertrophy of intestinal lymphoid follicles
- C. Intraluminal bacterial overgrowth
- D. Neutrophilic infiltration in response to bacterial toxins
- E. Smooth muscle hypertrophy

Submit

https://t.me/USMLEWorldStep1

A 19-month-old boy is brought to the emergency department with severe abdominal pain and vomiting. On initial evaluation, rebound and guarding are present. Laparotomy is performed, and a portion of the intestine is resected; the gross specimen is shown in the image below:

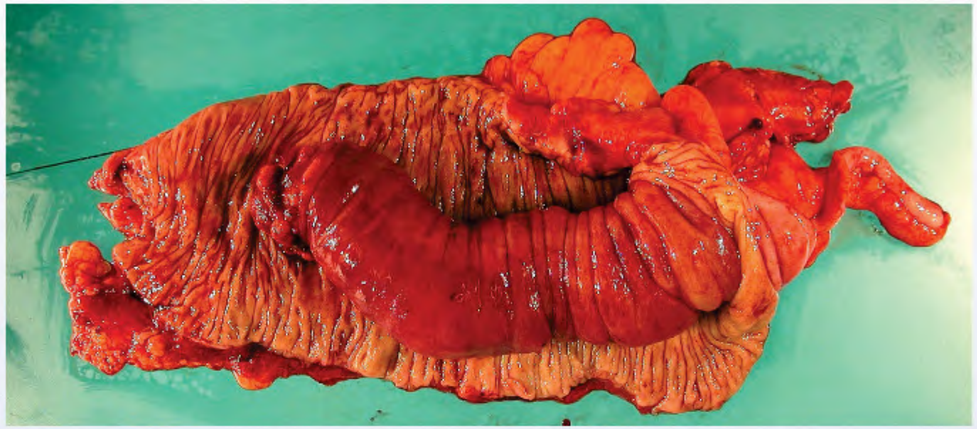

Which of the following best describes the underlying pathologic process that led to this patient's condition?

- A. Eosinophilic infiltration of the lamina propria (6%)
- ✓ B. Hypertrophy of intestinal lymphoid follicles (56%)
- C. Intraluminal bacterial overgrowth (7%)
- D. Neutrophilic infiltration in response to bacterial toxins (9%)
- E. Smooth muscle hypertrophy (20%)

Correct

56% Answered correctly

09 secs Time Spent

2023 Version

Explanation

https://t.me/USMLEWorldStep1

Explanation

Exhibit Display

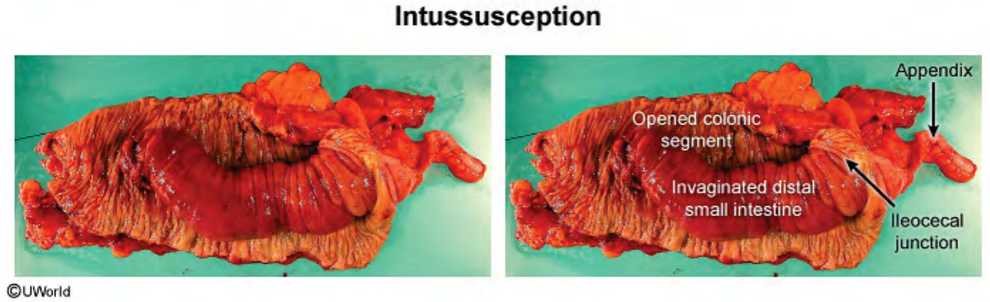

Zoom In Zoom Out Reset New | Existing My Notebook

In this
has ar
intuss

Intuss
stimul
areas,
the int
dense

Classi
waves
venou
correl
(eg, se

(Choi
of eos
perito

(Choice C) Intraluminal bacterial overgrowth occurs when the small intestine is colonized by excessive microbes

https://t.me/USMLEWorldStep1

In this surgical specimen, a longitudinally opened portion of the intestine (identified by the luminal transverse folds) has another intestinal segment that is ischemic (ie, dusky appearance) within its lumen. This is diagnostic of **intussusception**, an invagination of a portion of the intestine into an adjacent segment.

Intussusception classically occurs in children age 6 months to 3 years, often following a viral infection. Viral stimulation of **lymphoid follicles** within the small intestine **(Peyer patches)** can lead to hypertrophy of those areas, which can then act as **lead points** that become trapped by peristalsis and dragged into a distal portion of the intestine. The most common location is at the **ileocecal junction**, as in this patient, and is likely due to a dense concentration of Peyer patches in the terminal ileum.

Classic presentation is characterized by periods of inconsolability with colicky **abdominal pain** correlating with waves of peristalsis at the affected site; **air enema** usually reduces the intussusception. If untreated, impaired venous return of the invaginated segment can lead to ischemia and necrosis of the intestinal wall. Late findings correlating to bowel ischemia include currant jelly stools (ie, containing blood and mucus) and signs of peritonitis (eg, severe pain, rebound tenderness) warranting urgent surgical intervention, as in this patient.

(Choice A) Eosinophilic infiltration of the lamina propria within the mucosal layer of the intestines is characteristic of eosinophilic gastroenteritis. This typically presents with chronic abdominal pain, nausea/vomiting, or diarrhea; peritoneal signs and invaginated intestinal segments would not be seen.

(Choice C) Intraluminal bacterial overgrowth occurs when the small intestine is colonized by excessive microbes normally found in the colon. However, most patients are older adults with a history of motility disorders or pancreatitis, and symptoms include bloating and diarrhea.

(Choice D) *Clostridioides difficile* infection causes neutrophilic infiltration of the colonic wall and may be complicated by peritonitis due to toxic megacolon. Invagination of the intestine would not occur.

(Choice E) Pyloric stenosis is caused by smooth muscle hypertrophy at the gastric outlet and presents with vomiting in infants age 3-6 weeks. This patient's age and intestinal findings are inconsistent with this diagnosis.

Educational objective:
Intussusception, which presents with colicky abdominal pain, is characterized by telescoping of one intestinal segment into an adjacent one, most commonly at the ileocecal junction. Pathophysiology usually involves

https://t.me/USMLEWorldStep1

Intussusception classically occurs in children age 6 months to 3 years, often following a viral infection. Viral stimulation of **lymphoid follicles** within the small intestine **(Peyer patches)** can lead to hypertrophy of those areas, which can then act as **lead points** that become trapped by peristalsis and dragged into a distal portion of the intestine. The most common location is at the **ileocecal junction**, as in this patient, and is likely due to a dense concentration of Peyer patches in the terminal ileum.

Classic presentation is characterized by periods of inconsolability with colicky **abdominal pain** correlating with waves of peristalsis at the affected site; **air enema** usually reduces the intussusception. If untreated, impaired venous return of the invaginated segment can lead to ischemia and necrosis of the intestinal wall. Late findings correlating to bowel ischemia include currant jelly stools (ie, containing blood and mucus) and signs of peritonitis (eg, severe pain, rebound tenderness) warranting urgent surgical intervention, as in this patient.

(Choice A) Eosinophilic infiltration of the lamina propria within the mucosal layer of the intestines is characteristic of eosinophilic gastroenteritis. This typically presents with chronic abdominal pain, nausea/vomiting, or diarrhea; peritoneal signs and invaginated intestinal segments would not be seen.

(Choice C) Intraluminal bacterial overgrowth occurs when the small intestine is colonized by excessive microbes normally found in the colon. However, most patients are older adults with a history of motility disorders or pancreatitis, and symptoms include bloating and diarrhea.

(Choice D) *Clostridioides difficile* infection causes neutrophilic infiltration of the colonic wall and may be complicated by peritonitis due to toxic megacolon. Invagination of the intestine would not occur.

(Choice E) Pyloric stenosis is caused by smooth muscle hypertrophy at the gastric outlet and presents with vomiting in infants age 3-6 weeks. This patient's age and intestinal findings are inconsistent with this diagnosis.

Educational objective:
Intussusception, which presents with colicky abdominal pain, is characterized by telescoping of one intestinal segment into an adjacent one, most commonly at the ileocecal junction. Pathophysiology usually involves hypertrophy of intestinal lymphoid follicles (Peyer patches), which can act as lead points of the invaginated bowel.

References

- Intestinal intussusception: etiology, diagnosis, and treatment.

https://t.me/USMLEWorldStep1

Intussusception classically occurs in children age 6 months to 3 years, often following a viral infection. Viral stimula… areas, the int… dense…

Classi… waves… venou… correla… (eg, se…

(Choi… of eos… peritor…

(Choi… norma… pancre…

(Choi… compli…

(Choi… vomiti…

Educa… Intuss… segme… hypert…

Refere…

- Intestinal intussusception: etiology, diagnosis, and treatment.

Exhibit Display

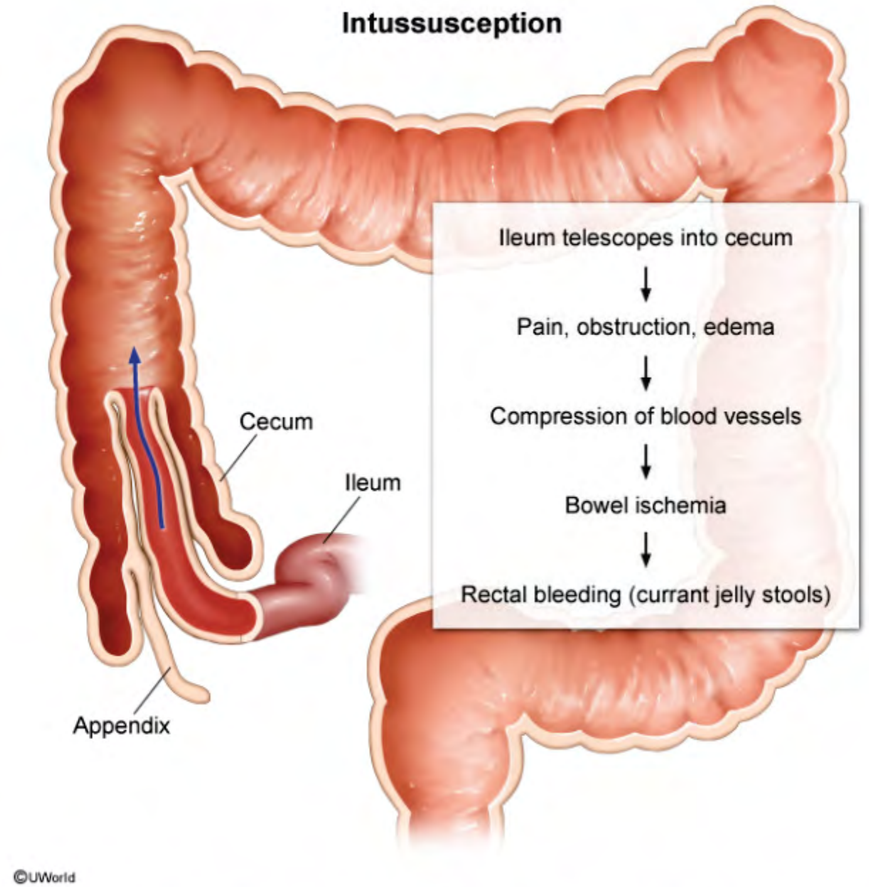

Zoom In | Zoom Out | Reset | New | Existing | My Notebook

https://t.me/USMLEWorldStep1

A 42-year-old man comes to the office with rectal bleeding. He used to have occasional streaks of blood on the tissue after wiping, but for the past several days he has seen blood dripping into the toilet at the end of defecation. The patient reports chronic constipation and has to strain while having a bowel movement but has no rectal or abdominal pain. He works as a truck driver, and his diet consists mainly of hamburgers and French fries. Abdominal examination is unremarkable. There is no mass or tenderness on digital rectal examination, but anoscopy shows bulging purplish-blue mucosal lesions above the dentate line. Rubber band ligation of the lesions is most likely to involve which of the following?

- A. Deep external pudendal artery branches
- B. External iliac vein tributaries
- C. Inferior mesenteric vein tributaries
- D. Internal pudendal vein tributaries
- E. Left colic artery branches
- F. Superior vesical artery branches

Submit

https://t.me/USMLEWorldStep1

A 42-year-old man comes to the office with rectal bleeding. He used to have occasional streaks of blood on the tissue after wiping, but for the past several days he has seen blood dripping into the toilet at the end of defecation. The patient reports chronic constipation and has to strain while having a bowel movement but has no rectal or abdominal pain. He works as a truck driver, and his diet consists mainly of hamburgers and French fries. Abdominal examination is unremarkable. There is no mass or tenderness on digital rectal examination, but anoscopy shows bulging purplish-blue mucosal lesions above the dentate line. Rubber band ligation of the lesions is most likely to involve which of the following?

- ✗ A. Deep external pudendal artery branches (3%)
- B. External iliac vein tributaries (4%)
- ✓ C. Inferior mesenteric vein tributaries (62%)
- D. Internal pudendal vein tributaries (24%)
- E. Left colic artery branches (2%)
- F. Superior vesical artery branches (2%)

Incorrect
Correct answer
C

62%
Answered correctly

04 secs
Time Spent

2023
Version

Explanation

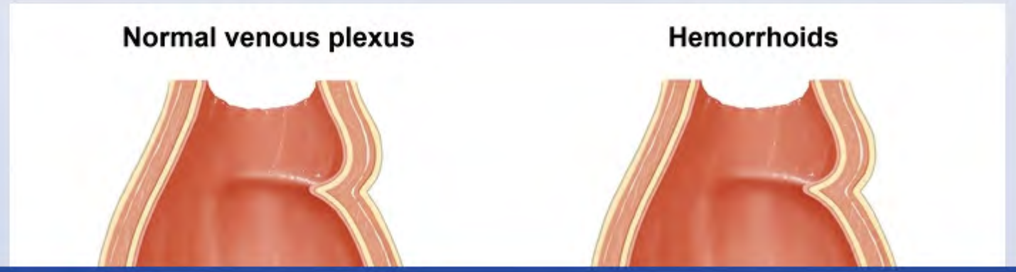

https://t.me/USMLEWorldStep1

A 42-year-old man comes to the office with rectal bleeding. He used to have occasional streaks of blood on the tissue
The pa
abdom
Abdon
anosc
is mos

Inco
Corre
C

Expl

Exhibit Display

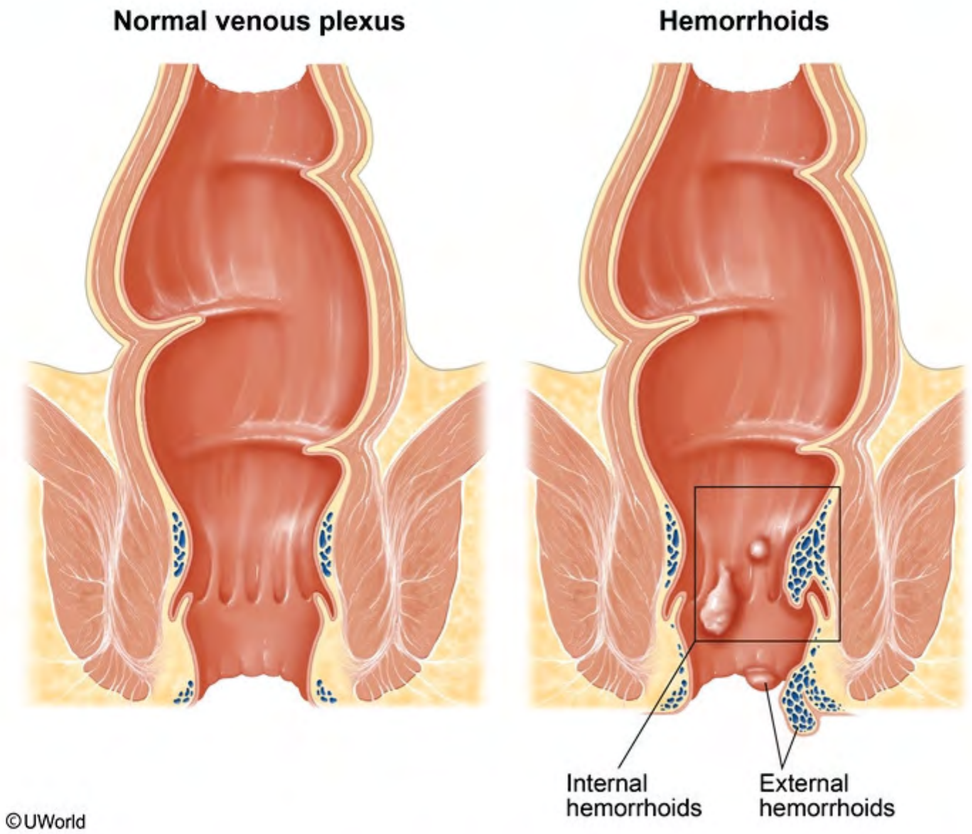

Zoom In Zoom Out Reset New | Existing My Notebook

https://t.me/USMLEWorldStep1

©UWorld

Hemorrhoids are classified based on their relation to the dentate line in the anal canal, with **internal hemorrhoids** originating **above the line** and external hemorrhoids below. They result from abnormal distension of the anal arteriovenous plexus, which normally forms the anal cushions (composed of venous sinusoids and connective tissue) that are important for maintaining fecal continence. Chronically increased venous pressure due to prolonged straining or breakdown of supporting tissue due to advancing age can cause the cushions to bulge into the anal canal, where they can become inflamed, thrombose, or prolapse.

Hemorrhoids can be treated with rubber band ligation, which cuts off the blood supply to the lesions and causes them to degenerate. The venous components of internal hemorrhoids drain into the **superior rectal vein**, which communicates with the **inferior mesenteric vein**. External hemorrhoids drain via the inferior rectal vein into the internal pudendal vein, which communicates with the internal iliac veins **(Choice D)**. Internal hemorrhoids have no somatic sensory innervation and cannot cause pain; however, external hemorrhoids are innervated by the same nerves that cover the perianal area and can be very sensitive to pain.

(Choice A) Branches of the deep external pudendal artery supply the scrotum (labia majora in females) and the perineum.

(Choice B) The external iliac vein receives drainage from the inferior epigastric and deep circumflex iliac veins, which serve the anterior abdominal wall and iliac crest, respectively.

(Choice E) The left colic artery branches off the inferior mesenteric artery to supply the transverse and descending colon.

(Choice F) The superior vesical artery and its branches supply portions of the urinary bladder and ductus deferens.

Educational objective:
Hemorrhoids result from abnormal distension of a portion of the anal arteriovenous plexus. The vascular components of internal hemorrhoids drain into the superior rectal vein, which subsequently drains into the inferior mesenteric vein. Band ligation of hemorrhoids cuts off their blood supply, causing them to degenerate.

https://t.me/USMLEWorldStep1

Internal External

Exhibit Display

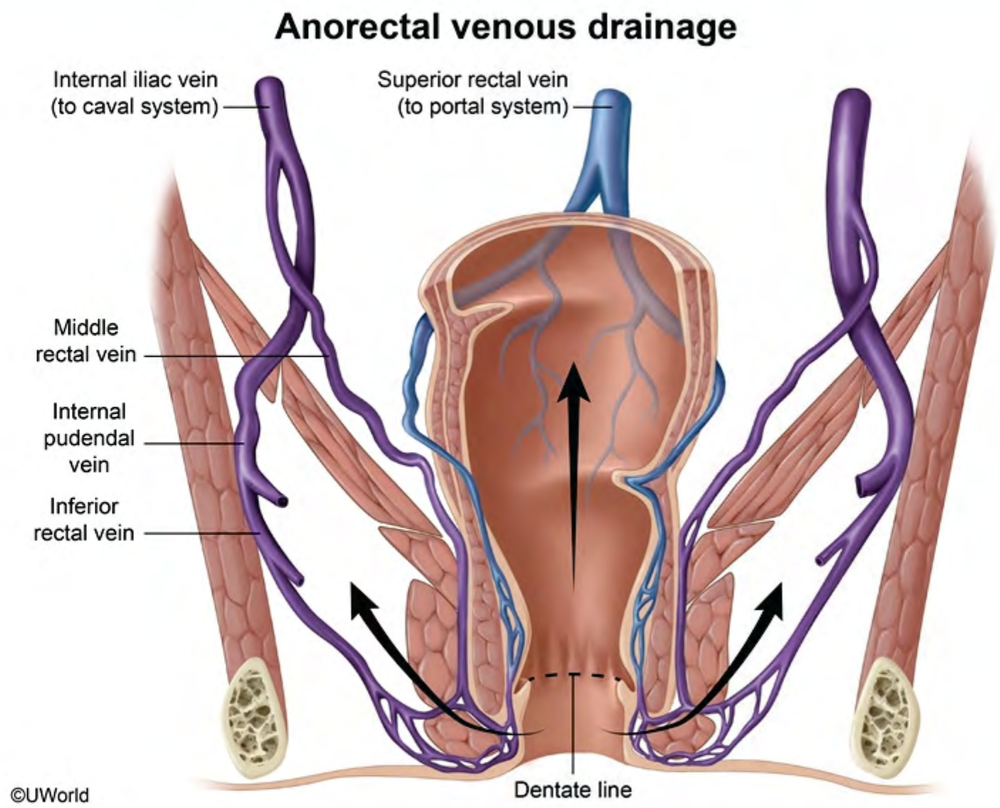

Zoom In Zoom Out Reset New | Existing My Notebook

Hemo
origina
arterio
tissue)
prolon
the an

Hemo
them t
comm
interna
somat
nerves

(Choi
perine

(Choi
which

(Choi
descer

(Choi
defere

Educa
Hemo
compo
mesenteric vein. Band ligation of hemorrhoids cuts off their blood supply, causing them to degenerate.

https://t.me/USMLEWorldStep1

A 63-year-old man comes to the office due to intermittent rectal bleeding. The bleeding worsens with defecation and is associated with itchiness. Ten years ago, he had a kidney transplant for diabetic nephropathy and reports compliance with posttransplant immunosuppression medications. Vital signs are normal. Physical examination reveals a 2-cm ulcerated mass extending from the anal verge into the rectum. Biopsy shows large, eosinophilic squamous epithelial cells arranged in islands; cells have hyperchromatic, irregular nuclei, and scant cytoplasm. Significant keratinization is present. Which of the following factors is most likely responsible for the development of this patient's anal lesion?

- A. *BRAF* mutation
- B. Human herpesvirus 8
- C. Human papillomavirus
- D. Mismatch repair gene mutation
- E. Poxvirus
- F. *Treponema pallidum*

Submit

https://t.me/USMLEWorldStep1

A 63-year-old man comes to the office due to intermittent rectal bleeding. The bleeding worsens with defecation and is associated with itchiness. Ten years ago, he had a kidney transplant for diabetic nephropathy and reports compliance with posttransplant immunosuppression medications. Vital signs are normal. Physical examination reveals a 2-cm ulcerated mass extending from the anal verge into the rectum. Biopsy shows large, eosinophilic squamous epithelial cells arranged in islands; cells have hyperchromatic, irregular nuclei, and scant cytoplasm. Significant keratinization is present. Which of the following factors is most likely responsible for the development of this patient's anal lesion?

- A. *BRAF* mutation (5%)
- ✗ B. Human herpesvirus 8 (6%)
- ✓ C. Human papillomavirus (82%)
- D. Mismatch repair gene mutation (4%)
- E. Poxvirus (0%)
- F. *Treponema pallidum* (0%)

Incorrect
Correct answer
C

82%
Answered correctly

03 secs
Time Spent

2023
Version

Explanation

Anal squamous cell carcinoma	
Risk factors	• Human papillomavirus (types 16 & 18) • Receptive anal intercourse • Immunocompromised state (eg, HIV, organ transplant) • Female sex

https://t.me/USMLEWorldStep1

Explanation

Anal squamous cell carcinoma	
Risk factors	• Human papillomavirus (types 16 & 18) • Receptive anal intercourse • Immunocompromised state (eg, HIV, organ transplant) • Female sex • Smoking
Manifestations	• Rectal bleeding/pain, pruritus, mass sensation • Ulcerated or nodular anal mass
Histology	• Islands of large, eosinophilic, hyperchromatic squamous cells with scant cytoplasm & nuclear atypia • Prominent keratinization &/or keratin pearls

This patient with a history of chronic immunosuppression has perianal bleeding and an ulcerated anal mass. In association with the classic histologic findings, this presentation suggests **anal squamous cell carcinoma** (SCC). Most patients have **rectal bleeding**, pain, or pruritus, and examination demonstrates an **ulcerated** or a nodular, exophytic anal lesion. On histology, SCCs are characterized by **large, eosinophilic, hyperchromatic squamous cells** with scant cytoplasm arranged in islands. Nuclear atypia and prominent **keratinization** and/or keratin pearls are usually observed.

Anal SCC, as well as multiple other anogenital (eg, cervical, penile, vaginal) and oropharyngeal SCCs, is strongly associated with **human papillomavirus** (HPV). HPV is a nonenveloped, double-stranded DNA virus that infects cutaneous and mucosal tissues. HPV types 16 and 18 are particularly associated with the development of malignancies. Immunocompromised states (eg, HIV, **organ transplant**) increase susceptibility to HPV infection and malignant transformation. Other risk factors include smoking, receptive anal intercourse, and female sex.

(Choice A) *BRAF* is a protoonocogene, and mutations are associated with multiple malignancies (eg, melanoma,

https://t.me/USMLEWorldStep1

associated with **human papillomavirus** (HPV). HPV is a nonenveloped, double-stranded DNA virus that infects cutaneous and mucosal tissues. HPV types 16 and 18 are particularly associated with the development of malignancies. Immunocompromised states (eg, HIV, **organ transplant**) increase susceptibility to HPV infection and malignant transformation. Other risk factors include smoking, receptive anal intercourse, and female sex.

(Choice A) *BRAF* is a protoonocogene, and mutations are associated with multiple malignancies (eg, melanoma, colon cancer, papillary thyroid cancer) but are not typically associated with anal SCC.

(Choice B) Human herpesvirus 8 causes Kaposi sarcoma, an angiogenic tumor that typically occurs in patients with severe immunosuppression (usually AIDS) but can occur in organ transplant recipients. However, it typically involves the extremities, face, or genitalia and results in painless purple or brown lesions. Histologic evaluation demonstrates whorls of spindle cells and neovascularization.

(Choice D) Mutations of DNA mismatch repair genes are associated with hereditary nonpolyposis colon cancer (ie, Lynch syndrome), an autosomal dominant disease that results in colonic, endometrial, and ovarian cancer. It is not associated with anal SCC.

(Choice E) Poxvirus causes molluscum contagiosum, which is characterized by umbilicated, flesh-colored papules with histologic findings of epidermal hyperplasia and eosinophilic, intracytoplasmic viral inclusions. Although immunocompromised patients are at increased risk of larger lesions, molluscum contagiosum is not associated with malignant transformation.

(Choice F) Primary syphilis (caused by *Treponema pallidum*) can result in a painless, ulcerated anogenital lesion (eg, chancre); however, bleeding is atypical, and dark-field microscopy is used to reveal the presence of spirochetes.

Educational objective:
Anal squamous cell carcinoma is strongly associated with human papillomavirus and typically presents with rectal bleeding, pruritus, and/or pain; examination demonstrates an ulcerated or nodular, exophytic anal lesion. Histology reveals large, eosinophilic, hyperchromatic squamous cells arranged in islands with nuclear atypia and prominent keratinization.

References

- Pathology of anal cancer.

https://t.me/USMLEWorldStep1

A 62-year-old man comes to the office due to worsening dysphagia. Three months ago, the patient started having difficulty swallowing large bites of solid food, and now he can swallow only liquids and mashed food. He has lost 9.1 kg (20 lb) since the onset of his symptoms. Medical history is significant for type 2 diabetes mellitus, hypercholesterolemia, and hypertension. The patient recently reduced the doses of his diabetic medications due to weight loss and lower blood glucose levels. He has no recent travel outside of the United States. Vital signs are normal. BMI is 29 kg/m^2. Physical examination is normal. A barium swallow study reveals an esophageal mass that significantly narrows the lumen. Endoscopic biopsy reveals moderately differentiated tumor cells with keratin nests and pearls. This patient's condition is most likely related to which of the following risk factors?

- A. Alcohol consumption and tobacco smoking
- B. Cold beverage consumption
- C. Gastroesophageal reflux disease and esophagitis
- D. *Helicobacter pylori* infection
- E. Obesity and metabolic syndrome

Submit

https://t.me/USMLEWorldStep1

A 62-year-old man comes to the office due to worsening dysphagia. Three months ago, the patient started having difficulty swallowing large bites of solid food, and now he can swallow only liquids and mashed food. He has lost 9.1 kg (20 lb) since the onset of his symptoms. Medical history is significant for type 2 diabetes mellitus, hypercholesterolemia, and hypertension. The patient recently reduced the doses of his diabetic medications due to weight loss and lower blood glucose levels. He has no recent travel outside of the United States. Vital signs are normal. BMI is 29 kg/m^2. Physical examination is normal. A barium swallow study reveals an esophageal mass that significantly narrows the lumen. Endoscopic biopsy reveals moderately differentiated tumor cells with keratin nests and pearls. This patient's condition is most likely related to which of the following risk factors?

- ✓ A. Alcohol consumption and tobacco smoking (86%)
- ✗ B. Cold beverage consumption (0%)
- C. Gastroesophageal reflux disease and esophagitis (9%)
- D. *Helicobacter pylori* infection (0%)
- E. Obesity and metabolic syndrome (3%)

Incorrect
Correct answer
A

86%
Answered correctly

03 secs
Time Spent

2023
Version

Explanation

Risk factors for esophageal cancer	
Squamous cell carcinoma	**Adenocarcinoma**
• Alcohol use • Tobacco smoking • N-nitroso–containing foods	• Barrett esophagus • Gastroesophageal reflux disease • Obesity

https://t.me/USMLEWorldStep1

Explanation

Risk factors for esophageal cancer	
Squamous cell carcinoma	**Adenocarcinoma**
• Alcohol use • Tobacco smoking • N-nitroso–containing foods • Underlying esophageal disease (achalasia, prior injury)	• Barrett esophagus • Gastroesophageal reflux disease • Obesity • Tobacco use

This patient has **squamous cell carcinoma** (SCC), which is characterized by flattened polyhedral or ovoid epithelial cells with eosinophilic cytoplasm, keratin nests or pearls within or between cells, and intercellular bridging. **Esophageal SCC** typically presents with progressive solid-food dysphagia and weight loss. Chronic gastrointestinal blood loss may result in iron deficiency anemia.

The incidence of esophageal SCC is decreasing in the United States, with the highest incidence occurring in middle-aged and older individuals (age >50). The most significant risk factors for SCC in the United States include **cigarette smoking** and **alcohol intake**. In Asia, the chewing of betel nuts and consumption of foods containing N-nitroso compounds (often found in preserved or pickled vegetables) are commonly associated with SCC. Other risk factors include preexisting esophageal disease (eg, achalasia, caustic injury) and ingestion of high-temperature liquids **(Choice B)**.

(Choice C) Chronic gastroesophageal reflux disease and esophagitis can lead to Barrett metaplasia and can increase the risk for esophageal adenocarcinoma.

(Choice D) *Helicobacter pylori* infection, a common cause of gastritis, is associated with an increased risk of gastric adenocarcinoma. However, it is not associated with increased risk of the development of Barrett esophagus, esophageal adenocarcinoma, or esophageal SCC.

(Choice E) Obesity and metabolic syndrome are associated with increased risk of esophageal adenocarcinoma, likely because of increased acid reflux into the esophagus due to anatomic abnormalities.

https://t.me/USMLEWorldStep1

Squamous cell carcinoma	Adenocarcinoma
• Alcohol use • Tobacco smoking • N-nitroso–containing foods • Underlying esophageal disease (achalasia, prior injury)	• Barrett esophagus • Gastroesophageal reflux disease • Obesity • Tobacco use

This patient has **squamous cell carcinoma** (SCC), which is characterized by flattened polyhedral or ovoid epithelial cells with eosinophilic cytoplasm, keratin nests or pearls within or between cells, and intercellular bridging. **Esophageal SCC** typically presents with progressive solid-food dysphagia and weight loss. Chronic gastrointestinal blood loss may result in iron deficiency anemia.

The incidence of esophageal SCC is decreasing in the United States, with the highest incidence occurring in middle-aged and older individuals (age >50). The most significant risk factors for SCC in the United States include **cigarette smoking** and **alcohol intake**. In Asia, the chewing of betel nuts and consumption of foods containing N-nitroso compounds (often found in preserved or pickled vegetables) are commonly associated with SCC. Other risk factors include preexisting esophageal disease (eg, achalasia, caustic injury) and ingestion of high-temperature liquids **(Choice B)**.

(Choice C) Chronic gastroesophageal reflux disease and esophagitis can lead to Barrett metaplasia and can increase the risk for esophageal adenocarcinoma.

(Choice D) *Helicobacter pylori* infection, a common cause of gastritis, is associated with an increased risk of gastric adenocarcinoma. However, it is not associated with increased risk of the development of Barrett esophagus, esophageal adenocarcinoma, or esophageal SCC.

(Choice E) Obesity and metabolic syndrome are associated with increased risk of esophageal adenocarcinoma, likely because of increased acid reflux into the esophagus due to anatomic abnormalities.

Educational objective:
Major risk factors for esophageal squamous cell carcinoma include smoking, excessive alcohol consumption, and intake of foods containing N-nitroso compounds.

https://t.me/USMLEWorldStep1

Squamous cell carcinoma	Adenocarcinoma

Exhibit Display

Squamous cell carcinoma

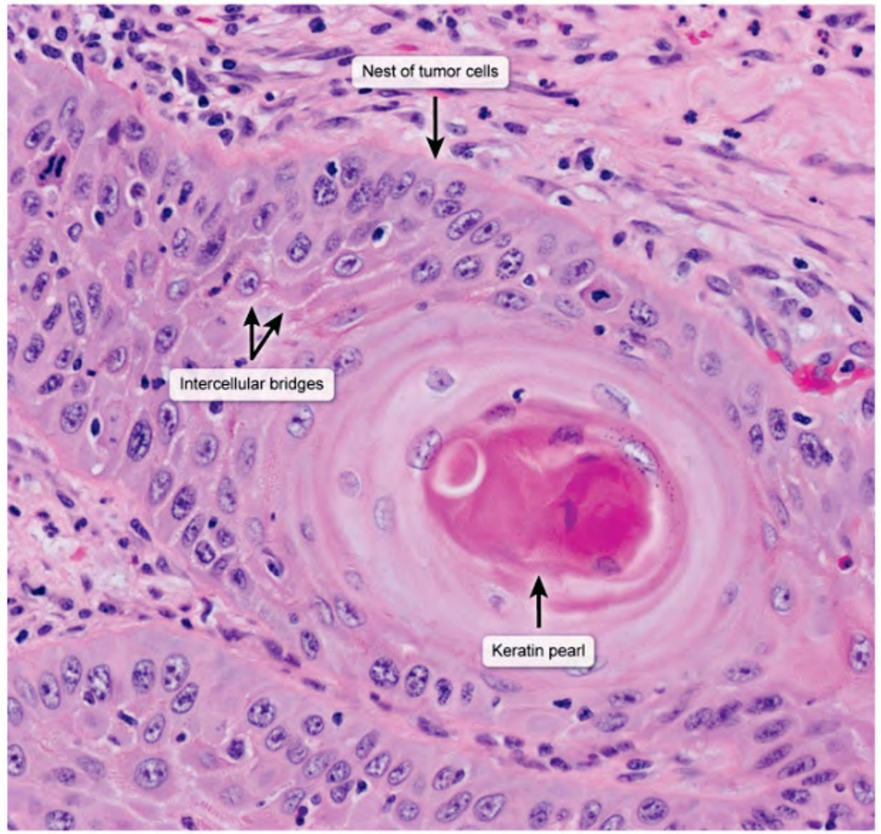

Zoom In | Zoom Out | Reset | New | Existing | My Notebook

This p
epithe
bridgi
gastro

The in
middle
cigare
nitroso
risk fa
tempe

(Choi
increa

(Choi
gastric
esoph

(Choi
likely b

Educa
Major
intake of foods containing N-nitroso compounds.

https://t.me/USMLEWorldStep1

Squamous cell carcinoma	Adenocarcinoma

Exhibit Display

Barrett esophagus

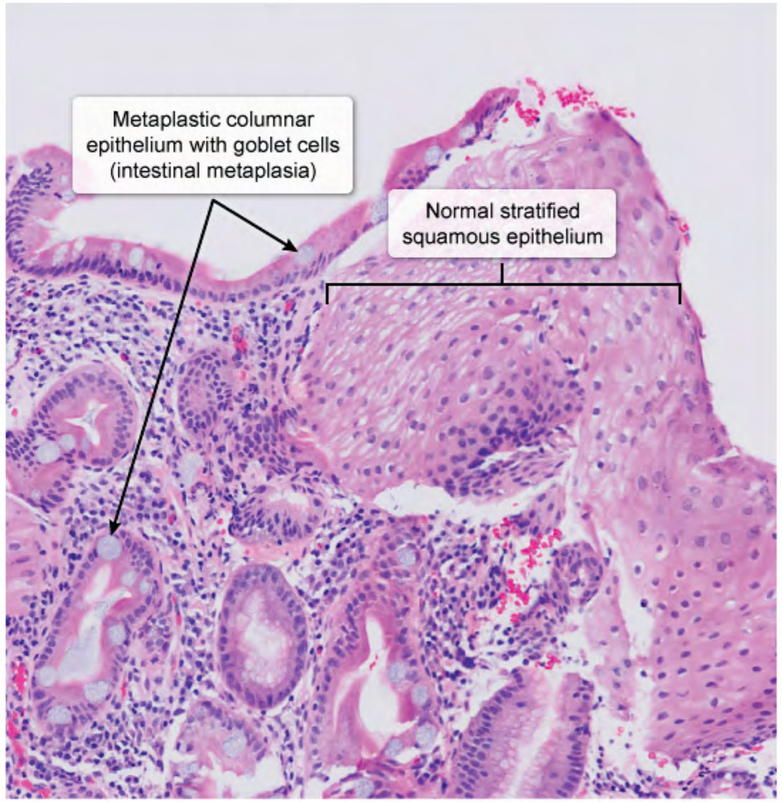

©UWorld

Zoom In | Zoom Out | Reset | New | Existing | My Notebook

This p
epithe
bridgi
gastro

The in
middle
cigare
nitroso
risk fa
tempe

(Choi
increa

(Choi
gastric
esoph

(Choi
likely b

Educa
Major
intake of foods containing N-nitroso compounds.

https://t.me/USMLEWorldStep1

Squamous cell carcinoma	Adenocarcinoma

Exhibit Display

Esophageal adenocarcinoma

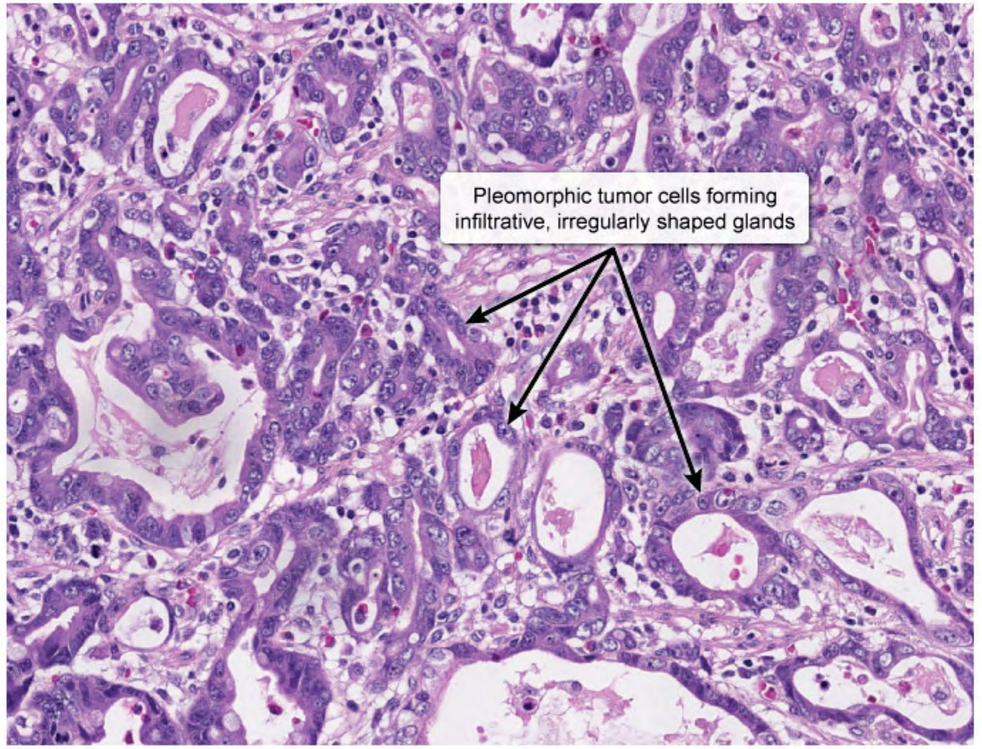

Zoom In | Zoom Out | Reset | New | Existing | My Notebook

This p
epithe
bridgi
gastro

The in
middle
cigare
nitroso
risk fa
tempe

(Choi
increa

(Choi
gastric
esoph

(Choi
likely b

Educational objective:
Major risk factors for esophageal squamous cell carcinoma include smoking, excessive alcohol consumption, and intake of foods containing N-nitroso compounds.

https://t.me/USMLEWorldStep1

An 80-year-old man comes to the office for evaluation of persistent dry mouth and difficulty chewing food. He has had no dry eyes or joint pains. The patient has no chronic medical conditions and takes no medications. On examination, there is decreased saliva production but no tenderness or swelling of the salivary glands. Extensive dental caries are present. Laboratory results show negative anti-Ro/SSA and anti-La/SSB antibodies. Which of the following age-related changes is most likely responsible for this patient's symptoms?

- A. Acinar atrophy and fatty infiltration of salivary glands
- B. Acinar atrophy due to extracellular amyloid deposition
- C. Focal lymphocytic infiltration of the salivary glands
- D. Granulomatous inflammation of the salivary glands
- E. Neutrophilic inflammation of the salivary glands

Submit

https://t.me/USMLEWorldStep1

An 80-year-old man comes to the office for evaluation of persistent dry mouth and difficulty chewing food. He has had no dry eyes or joint pains. The patient has no chronic medical conditions and takes no medications. On examination, there is decreased saliva production but no tenderness or swelling of the salivary glands. Extensive dental caries are present. Laboratory results show negative anti-Ro/SSA and anti-La/SSB antibodies. Which of the following age-related changes is most likely responsible for this patient's symptoms?

- ✓ A. Acinar atrophy and fatty infiltration of salivary glands (63%)
- ✗ B. Acinar atrophy due to extracellular amyloid deposition (28%)
- C. Focal lymphocytic infiltration of the salivary glands (5%)
- D. Granulomatous inflammation of the salivary glands (1%)
- E. Neutrophilic inflammation of the salivary glands (1%)

Incorrect
Correct answer
A

63%
Answered correctly

03 secs
Time Spent

2023
Version

Explanation

Age-related changes to the upper aerodigestive tract	
Salivary glands	• Acinar atrophy, fatty infiltration • Reduced saliva production • Xerostomia, dental caries
Oral/oropharyngeal muscles	• Decreased muscle mass & tissue elasticity • Weakness & dyscoordination of masticatory, tongue & pharyngeal muscles • Increased transit time, decreased coordination

https://t.me/USMLEWorldStep1

Explanation

Age-related changes to the upper aerodigestive tract	
Salivary glands	• Acinar atrophy, fatty infiltration • Reduced saliva production • Xerostomia, dental caries
Oral/oropharyngeal muscles	• Decreased muscle mass & tissue elasticity • Weakness & dyscoordination of masticatory, tongue & pharyngeal muscles • Increased transit time, decreased coordination
Other effects	• Mucosal atrophy • Decreased taste & smell • Impaired airway protective reflexes

Elderly patients are at increased risk of dysphagia due to age-related physiologic changes in the upper aerodigestive tract. **Acinar atrophy and fatty infiltration** affecting the parotid **salivary glands** result in a dramatic reduction (~50%) in saliva production, which frequently leads to xerostomia. This **decrease in saliva** is often accompanied by age-related mucosal atrophy, which manifests as receding gums with increased exposure of tooth roots; these changes increase the risk of **tooth decay** in elderly patients.

Elderly patients also commonly have a **decrease in muscle mass** and **loss of connective tissue elasticity**, which can impact the muscles of mastication, intrinsic and extrinsic tongue muscles, and pharyngeal constrictors. These alterations can lead to difficulty forming food into a bolus and propelling food from the oral cavity into the oropharynx and then into the esophagus.

In addition, elderly patients have a **decreased sense of taste and smell** and impaired airway protective reflexes. They also are more likely to have comorbid neurologic diseases (eg, stroke, Parkinson disease) that further increase the risk of dysphagia. Dysphagia can lead to **malnutrition** and **aspiration**, both of which cause

https://t.me/USMLEWorldStep1

tooth roots, these changes increase the risk of **tooth decay** in elderly patients.

Elderly patients also commonly have a **decrease in muscle mass** and **loss of connective tissue elasticity**, which can impact the muscles of mastication, intrinsic and extrinsic tongue muscles, and pharyngeal constrictors. These alterations can lead to difficulty forming food into a bolus and propelling food from the oral cavity into the oropharynx and then into the esophagus.

In addition, elderly patients have a **decreased sense of taste and smell** and impaired airway protective reflexes. They also are more likely to have comorbid neurologic diseases (eg, stroke, Parkinson disease) that further increase the risk of dysphagia. Dysphagia can lead to **malnutrition** and **aspiration**, both of which cause significant morbidity and mortality in the elderly.

(Choice B) Involvement of the salivary glands by systemic amyloidosis is common, but amyloid deposition significant enough to lead to dysphagia is very rare; normal age-related physiologic changes are much more likely in this patient.

(Choice C) Fibrosis and focal lymphocytic infiltration into the salivary glands are seen in Sjögren syndrome, an autoimmune disease impacting exocrine glands (eg, salivary, lacrimal, vaginal). Although patients often have dry mouth, they also typically have dry eyes and positive anti-Ro/SSA and/or anti-La/SSB antibodies.

(Choice D) Granulomatous inflammation of the salivary glands is seen in uveoparotid fever (ie, Heerfordt syndrome), an uncommon manifestation of sarcoidosis characterized by acute fever, parotitis, and anterior uveitis.

(Choice E) Elderly patients with xerostomia are at risk of acute sialadenitis, an infection of the salivary glands caused by retrograde seeding of bacteria from the oral cavity. Patients have acute, typically unilateral salivary gland swelling, exquisite pain, and fever.

Educational objective:
Elderly patients have decreased saliva production due to acinar atrophy and fatty infiltration of the salivary glands. Other age-related changes include oral mucosal atrophy; weakening of the muscles of mastication, tongue muscles, and pharyngeal constrictors; and a decreased sense of taste and smell. As a result, elderly patients are at increased risk of dysphagia, malnutrition, and pneumonia.

Physiology Gastrointestinal & Nutrition Aging

https://t.me/USMLEWorldStep1

tooth roots, these changes increase the risk of **tooth decay** in elderly patients.

Elderly [illegible] decrease in muscle mass [illegible] loss of connective tissue elasticity, which [illegible] These [illegible] oropha[illegible]

In add[illegible] They a[illegible] increa[illegible] signifi[illegible]

(Choi[illegible] signifi[illegible] in this [illegible]

(Choi[illegible] autoim[illegible] mouth[illegible]

(Choi[illegible] syndro[illegible]

(Choi[illegible] cause[illegible] gland [illegible]

Educa[illegible]
Elderly [illegible]
Other [illegible]
muscles, and pharyngeal constrictors, and a decreased sense of taste and smell. As a result, elderly patients are at increased risk of dysphagia, malnutrition, and pneumonia.

Exhibit Display

Sjogren syndrome

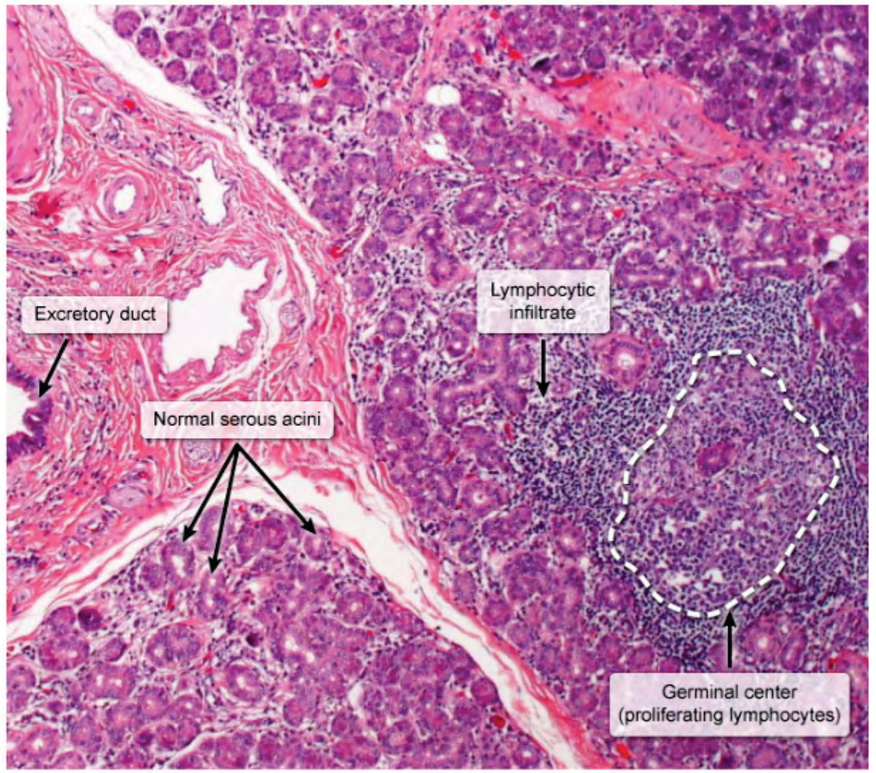

©UWorld

Zoom In | Zoom Out | Reset | New | Existing | My Notebook

https://t.me/USMLEWorldStep1

tooth roots, these changes increase the risk of **tooth decay** in elderly patients.

Elderly [illegible] which These oropha

In add They a increa signifi

(Choi signifi in this

(Choi autoim mouth

(Choi syndro

(Choi cause gland

Educa Elderly Other

muscles, and pharyngeal sphincters, and a decreased sense of taste and smell. As a result, elderly patients are at increased risk of dysphagia, malnutrition, and pneumonia.

Exhibit Display

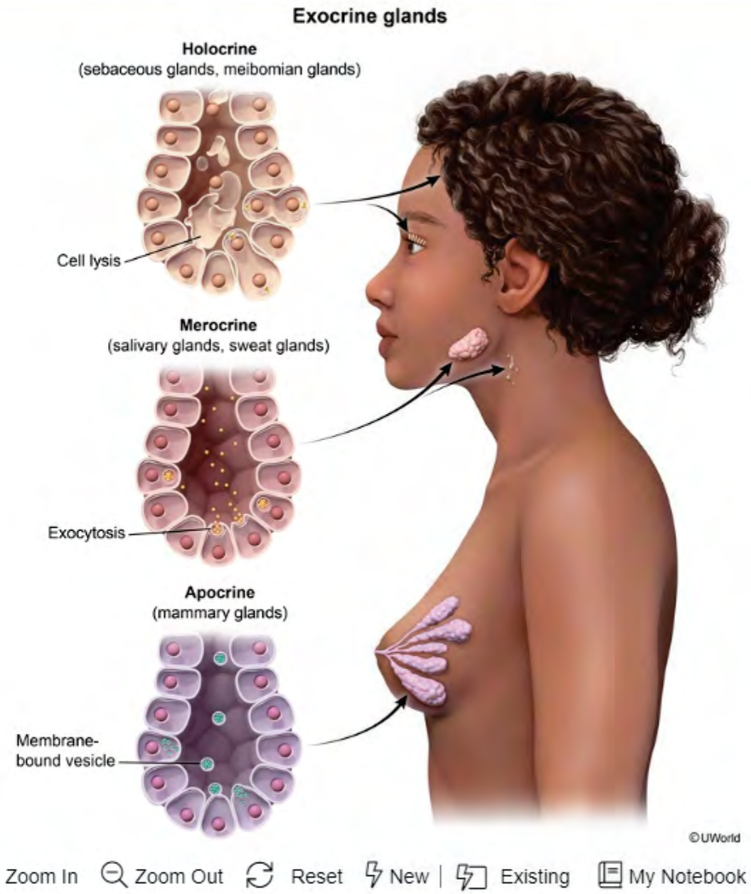

Zoom In Zoom Out Reset New | Existing My Notebook

https://t.me/USMLEWorldStep1

A 34-year-old man comes to the emergency department due to 5 days of progressive anorexia, nausea, and abdominal pain. The patient is a known hepatitis B carrier. He admits to using IV drugs and has shared needles with other drug users on several occasions. His temperature is 37.7 C (99.9 F). Examination shows scleral icterus and mild, tender hepatomegaly. Laboratory studies are notable for highly elevated levels of liver aminotransferases and serum bilirubin and also show the following results:

Hepatitis B surface antigen	positive
Hepatitis C virus antibody	negative
HIV-1 antibody	negative
Hepatitis D RNA	positive

This patient's chronic infection assists which of the following life cycle aspects of the current infectious agent?

- A. Coating of viral particles
- B. Integration into host genome
- C. Intracellular survival
- D. Replication of viral RNA
- E. Translation of viral transcripts

Submit

https://t.me/USMLEWorldStep1
Show all

A 34-year-old man comes to the emergency department due to 5 days of progressive anorexia, nausea, and abdominal pain. The patient is a known hepatitis B carrier. He admits to using IV drugs and has shared needles with other drug users on several occasions. His temperature is 37.7 C (99.9 F). Examination shows scleral icterus and mild, tender hepatomegaly. Laboratory studies are notable for highly elevated levels of liver aminotransferases and serum bilirubin and also show the following results:

Hepatitis B surface antigen	positive
Hepatitis C virus antibody	negative
HIV-1 antibody	negative
Hepatitis D RNA	positive

This patient's chronic infection assists which of the following life cycle aspects of the current infectious agent?

- ✓ A. Coating of viral particles (39%)
- ✗ B. Integration into host genome (17%)
- C. Intracellular survival (11%)
- D. Replication of viral RNA (25%)
- E. Translation of viral transcripts (6%)

Incorrect
Correct answer
A

39%
Answered correctly

04 secs
Time Spent

2023
Version

Explanation

https://t.me/USMLEWorldStep1
Show all

D. Replication of viral RNA (25%)

E. Translation of viral transcripts (6%)

Incorrect
Correct answer
A

39%
Answered correctly

04 secs
Time Spent

2023
Version

Explanation

Often referred to as the delta agent, **hepatitis D virus** (HDV) is a 35-nm, double-shelled particle that resembles the Dane particle of hepatitis B virus (HBV). The internal polypeptide assembly of HDV is designated **hepatitis D antigen (HDAg)**. Associated with this antigen is a very short, circular molecule of single-stranded RNA. HDAg is considered **replication defective** as it must be coated by the external coat **hepatitis B surface antigen (HBsAg)** of HBV to penetrate the hepatocyte. HDV infection can arise either as an acute coinfection with HBV or as a superinfection of a chronic HBV carrier.

(Choices B, C, D, and E) Once coated with HBsAg, HDV is able to penetrate the hepatocyte, survive within the cell, integrate into the host genome, replicate its viral RNA, and translate its genome into protein.

Educational objective:
The hepatitis B surface antigen of hepatitis B virus must coat the hepatitis D antigen of hepatitis D virus before it can infect hepatocytes and multiply.

References

- Life cycle and pathogenesis of hepatitis D virus: A review.

Microbiology
Subject

Gastrointestinal & Nutrition
System

Hepatitis d
Topic

Copyright © UWorld. All rights reserved.

https://t.me/USMLEWorldStep1
Show all

An 18-year-old man comes to the clinic for evaluation of fatigue that began several months ago and has progressively worsened. The patient takes no medications. He does not use alcohol or recreational drugs but smokes a pack of cigarettes daily. Examination shows conjunctival pallor. The abdomen is soft and nontender with no organomegaly. Laboratory evaluation shows hemoglobin is 8.5 g/dL, and stool testing for blood is positive. Further work-up reveals mild hemorrhaging within the ileum; just proximal to the site of hemorrhage is a 5-cm outpouching of intestine. The pouch is surgically resected and microscopic findings are shown in the image below.

This patient's condition is most likely the result of which of the following pathological processes?

- A. Anaplasia
- B. Dysplasia
- C. Ectopia
- D. Hypertrophy
- E. Metaplasia

Submit

https://t.me/USMLEWorldStep1
Show all

An 18-year-old man comes to the clinic for evaluation of fatigue that began several months ago and has
progre
smoke
with n
Furthe
outpou

Exhibit Display

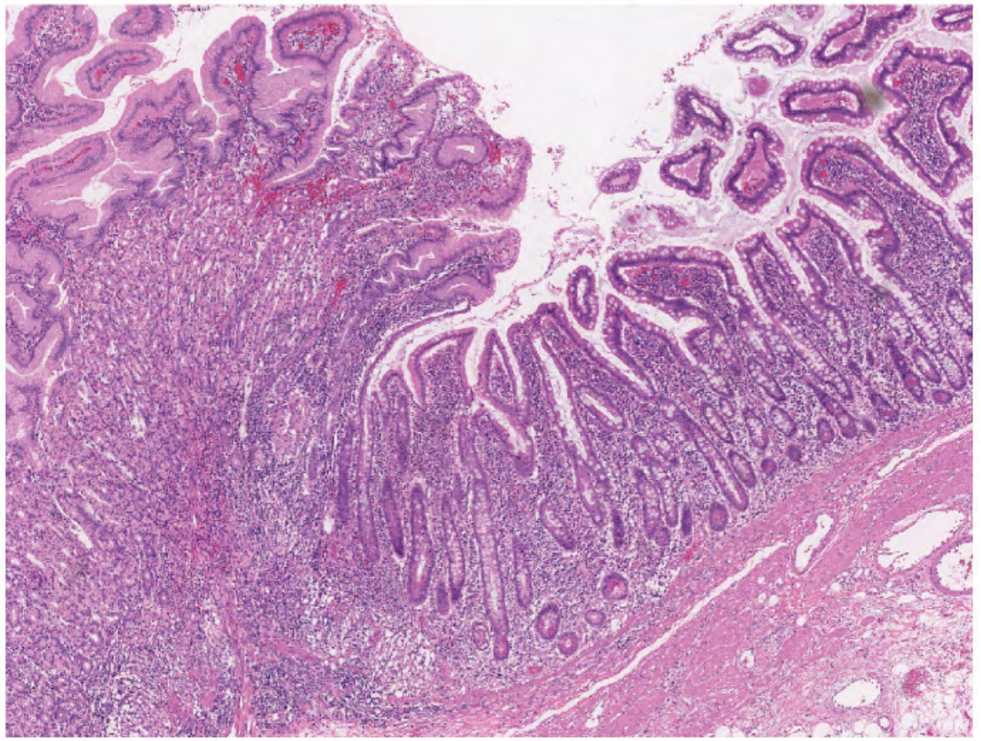

Zoom In | Zoom Out | Reset | New | Existing | My Notebook

This p

https://t.me/USMLEWorldStep1

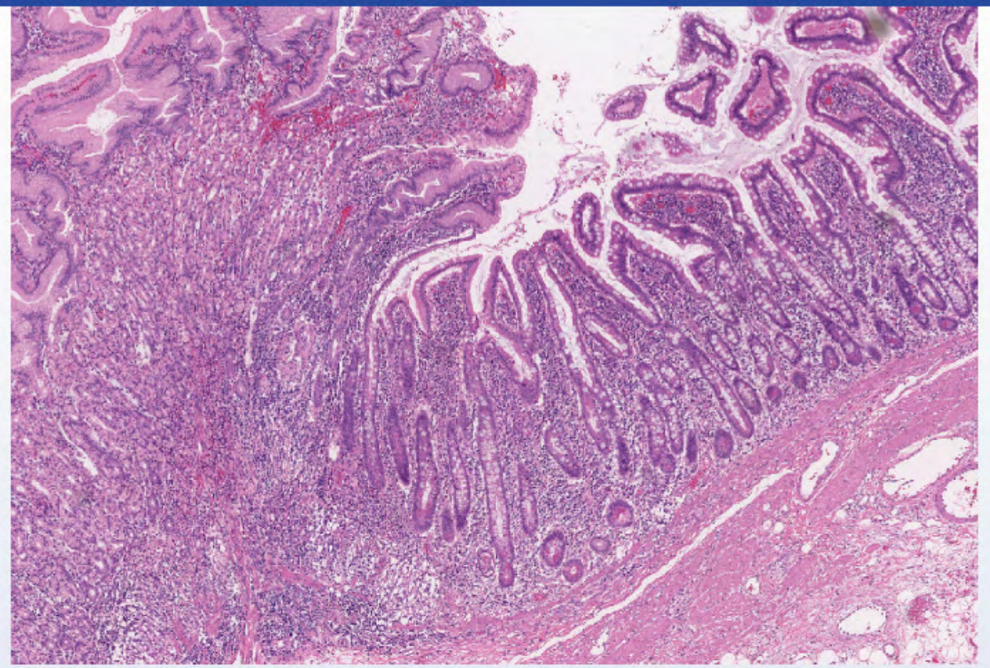

This patient's condition is most likely the result of which of the following pathological processes?

- A. Anaplasia
- B. Dysplasia
- C. Ectopia
- D. Hypertrophy
- E. Metaplasia

Submit

https://t.me/USMLEWorldStep1
Show all

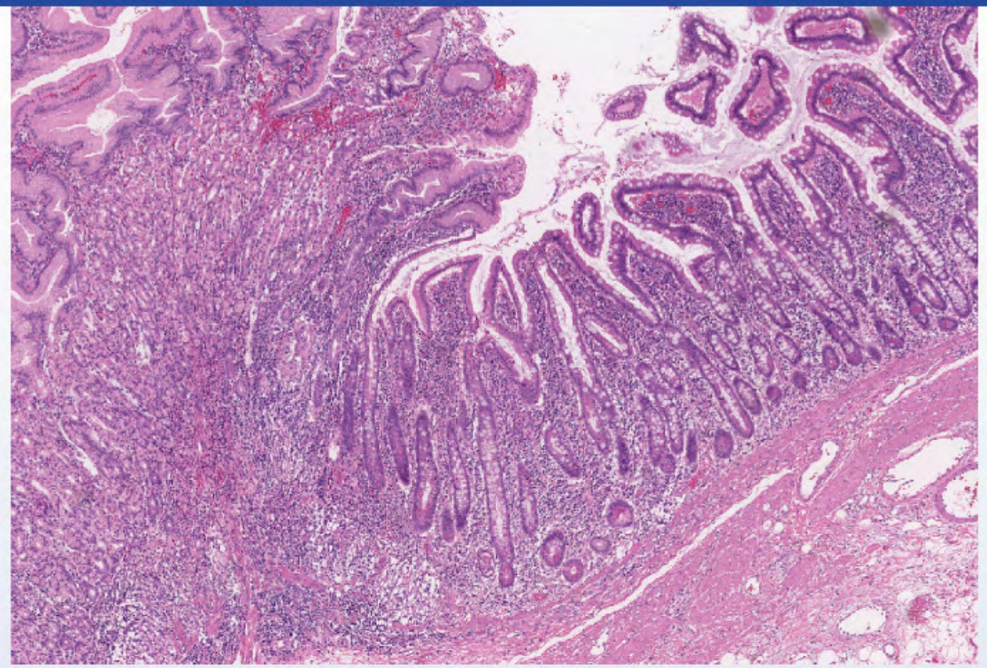

This patient's condition is most likely the result of which of the following pathological processes?

- A. Anaplasia (4%)
- ✗ B. Dysplasia (25%)
- ✓ C. Ectopia (38%)
- D. Hypertrophy (9%)
- E. Metaplasia (20%)

Incorrect
Correct answer
C

38%
Answered correctly

11 secs
Time Spent

2023
Version

https://t.me/USMLEWorldStep1
Show all

Expl

Exhibit Display

Meckel diverticulum

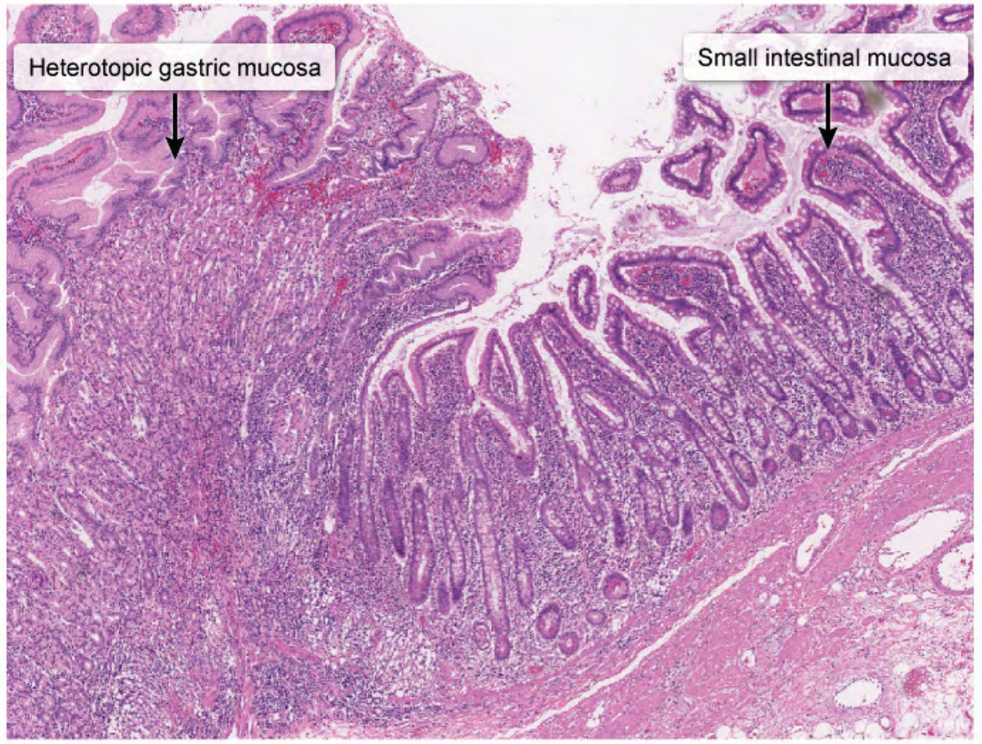

©UWorld

Zoom In | Zoom Out | Reset | New | Existing | My Notebook

Histolo
with a

In utero, the midgut lumen and yolk sac cavity normally are connected via the vitelline (omphalomesenteric) duct,

https://t.me/USMLEWorldStep1

Histologic examination of this patient's **intestinal outpouching** shows **gastric mucosa**. This finding is consistent with a **Meckel diverticulum**, the most common congenital anomaly of the small intestine.

In utero, the midgut lumen and yolk sac cavity normally are connected via the vitelline (omphalomesenteric) duct, which is obliterated in the first trimester. Failure of vitelline duct obliteration results in a Meckel diverticulum, which is usually located in the ileum within 2 feet of the ileocecal valve. If symptomatic, a Meckel diverticulum often presents by age 2 (ie, rule of 2s); however, it can cause complications at any age.

Various **ectopic (heterotopic)** tissues (ie, misplaced but functionally normal cells) can be present within a Meckel diverticulum, including gastric, pancreatic, or colonic mucosa. The most common is gastric tissue, as seen in this patient. Because **hydrochloric acid** secreted by gastric parietal cells causes ulceration and erosion of adjacent intestinal mucosa, Meckel diverticulum most commonly presents with brisk but painless lower **gastrointestinal bleeding** and **anemia** (eg, fatigue, pallor).

(Choices A and B) Anaplasia refers to poorly differentiated cells that have lost the characteristics of mature tissue, whereas dysplasia refers to disordered growth with loss of cell uniformity. Dysplasia can occur with benign and precancerous lesions, whereas anaplasia is indicative of malignant transformation.

(Choice D) Hypertrophy is an increase in the size of the cells in a tissue or organ. It can be physiologic (eg, exercise-induced skeletal muscle growth) or pathologic (eg, hypertrophic cardiomyopathy).

(Choice E) Metaplasia is an *acquired transformation* (ie, not present at birth) of one differentiated cell type to another differentiated cell type not typical for the location. For example, chronic reflux esophagitis can trigger the replacement of normal squamous epithelium in the distal esophagus with metaplastic columnar epithelium (ie, Barrett esophagus). In contrast, Meckel diverticulum is a congenital lesion.

Educational objective:
Meckel diverticulum is a congenital outpouching of the intestine that commonly contains ectopic (heterotopic) gastric mucosa. Hydrochloric acid production by gastric epithelium can lead to intestinal ulceration and subsequent lower gastrointestinal bleeding and anemia.

https://t.me/USMLEWorldStep1
Show all

Histologic examination of this patient's **intestinal outpouching** shows **gastric mucosa**. This finding is consistent with a

In uter
which
is usu
preser

Variou
diverti
patien
intesti
bleedi

(Choi
tissue,
and pr

(Choi
exerci

(Choi
anothe
replac
Barret

Educa
Mecke
gastric
subse

Exhibit Display

Vitelline duct abnormalities

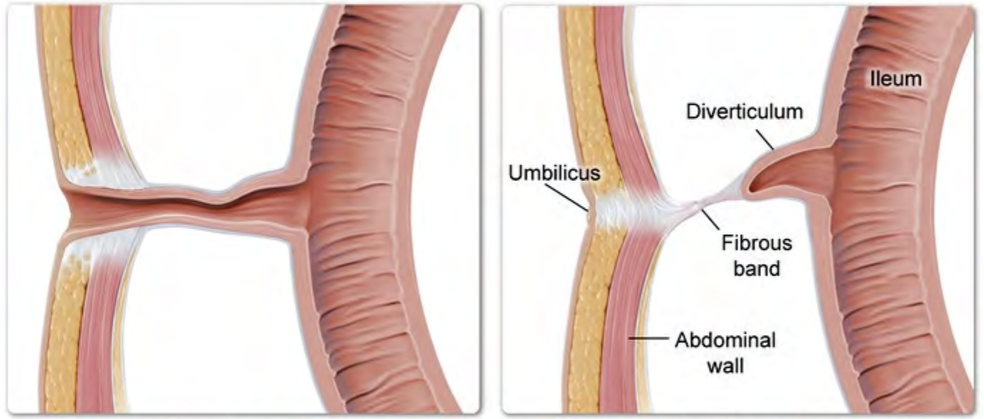

Persistent vitelline duct

Meckel diverticulum (most common)

©UWorld

Zoom In | Zoom Out | Reset | New | Existing | My Notebook

https://t.me/USMLEWorldStep1
Show all

Histologic examination of this patient's **intestinal outpouching** shows **gastric mucosa**. This finding is consistent with a

In uter
which
is usu
preser

Variou
diverti
patien
intesti
bleedi

(Choi
tissue,
and pr

(Choi
exerci

(Choi
anothe
replac
Barret

Educa
Mecke
gastric
subsequent lower gastrointestinal bleeding and anemia.

Exhibit Display

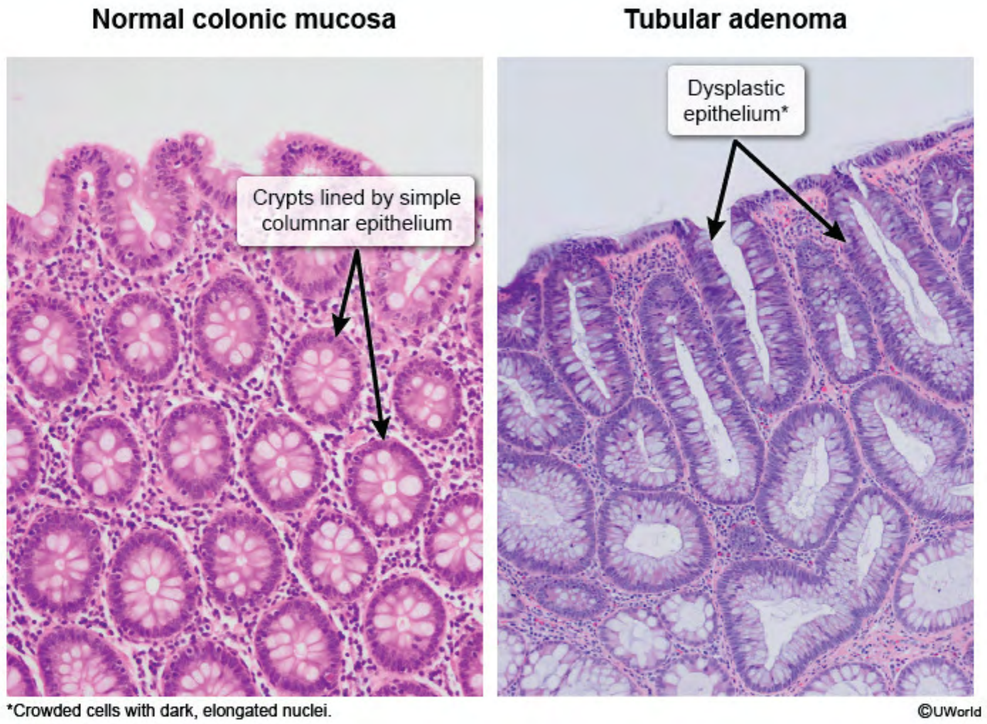

Zoom In Zoom Out Reset New | Existing My Notebook

https://t.me/USMLEWorldStep1

Histologic examination of this patient's **intestinal outpouching** shows **gastric mucosa**. This finding is consistent with a

In uter
which
is usu
preser

Variou
diverti
patien
intesti
bleedi

(Choi
tissue,
and pr

(Choi
exerci

(Choi
anothe
replac
Barret

Educa
Mecke
gastric
subsequent lower gastrointestinal bleeding and anemia.

Exhibit Display

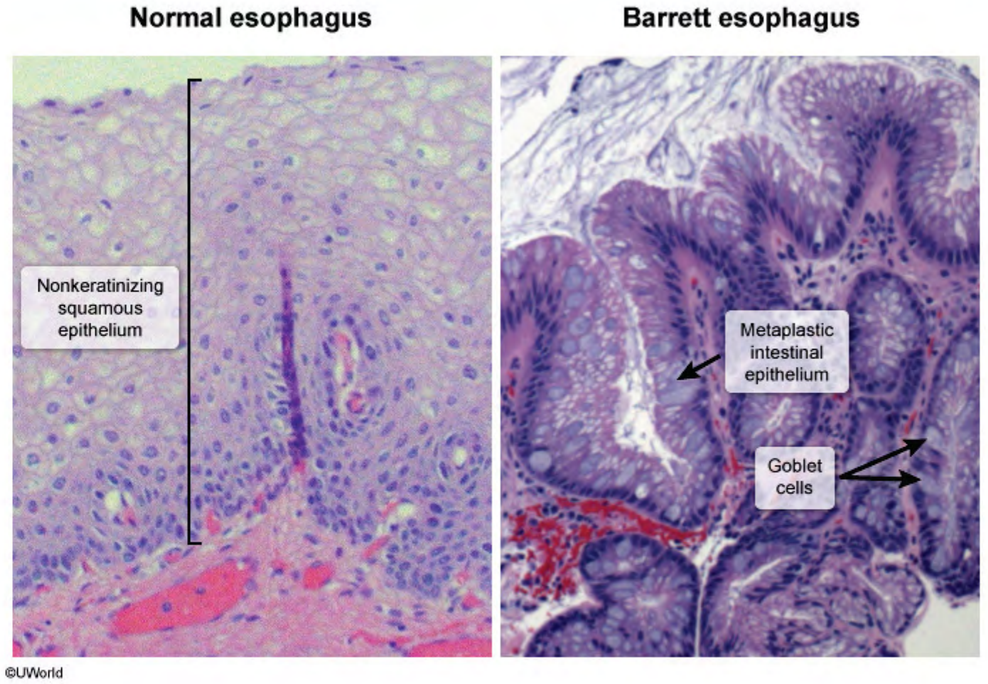

Zoom In Zoom Out Reset New | Existing My Notebook

https://t.me/USMLEWorldStep1

A 13-year-old boy is brought to the emergency department for evaluation of a rash and difficulty walking. A couple of weeks ago, the patient's mother noticed that he was walking with a slight limp. There were also a few red spots on his legs at that time. Over the past couple of days, the rash has progressed, and he now seems to have pain in both legs. The patient has autism and is nonverbal. He is a picky eater and takes no medications. Examination shows tenderness to palpation of his bilateral lower extremities. The patient requires assistance to stand. Reflexes are intact. Skin examination is shown in the exhibit. Oropharyngeal examination shows poor dentition with swollen, tender gums. Imaging studies reveal subperiosteal hematomas affecting the bilateral tibias. A deficiency of which of the following is the most likely cause of this patient's clinical findings?

- A. Vitamin B_2 (riboflavin)
- B. Vitamin B_3 (niacin)
- C. Vitamin B_6 (pyridoxine)
- D. Vitamin B_7 (biotin)
- E. Vitamin B_{12} (cobalamin)
- F. Vitamin C (ascorbic acid)
- G. Vitamin D
- H. Vitamin K

Submit

https://t.me/USMLEWorldStep1
Show all

A 13-year-old boy is brought to the emergency department for evaluation of a rash and difficulty walking. A couple of wee
on his
both le
shows
Reflex
with s
deficie

Sub

Exhibit Display

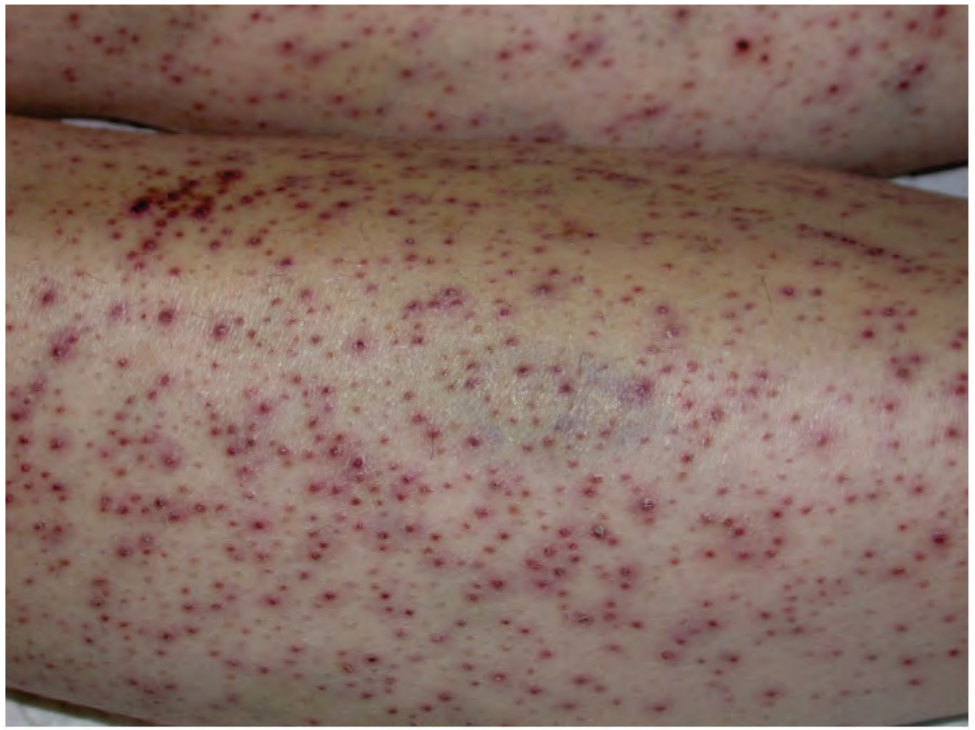

Zoom In Zoom Out Reset New | Existing My Notebook

https://t.me/USMLEWorldStep1

A 13-year-old boy is brought to the emergency department for evaluation of a rash and difficulty walking. A couple of weeks ago, the patient's mother noticed that he was walking with a slight limp. There were also a few red spots on his legs at that time. Over the past couple of days, the rash has progressed, and he now seems to have pain in both legs. The patient has autism and is nonverbal. He is a picky eater and takes no medications. Examination shows tenderness to palpation of his bilateral lower extremities. The patient requires assistance to stand. Reflexes are intact. Skin examination is shown in the exhibit. Oropharyngeal examination shows poor dentition with swollen, tender gums. Imaging studies reveal subperiosteal hematomas affecting the bilateral tibias. A deficiency of which of the following is the most likely cause of this patient's clinical findings?

- A. Vitamin B_2 (riboflavin) (1%)
- ✗ B. Vitamin B_3 (niacin) (3%)
- C. Vitamin B_6 (pyridoxine) (3%)
- D. Vitamin B_7 (biotin) (1%)
- E. Vitamin B_{12} (cobalamin) (3%)
- ✓ F. Vitamin C (ascorbic acid) (68%)
- G. Vitamin D (2%)
- H. Vitamin K (16%)

Incorrect
Correct answer
F

68%
Answered correctly

43 secs
Time Spent

2023
Version

Explanation

https://t.me/USMLEWorldStep1

Explanation

Water-soluble vitamins		
Vitamin	**Primary function**	**Deficiency**
Thiamine (B_1)	Decarboxylation of α-keto acids (carbohydrate metabolism)	• Beriberi (peripheral neuropathy, heart failure) • Wernicke-Korsakoff syndrome
Riboflavin (B_2)	Mitochondrial redox reactions (FMN, FAD)	• Cheilosis, stomatitis, glossitis • Normocytic anemia
Niacin (B_3)	Redox reactions (NAD/NADP)	• Pellagra (dermatitis, dementia, diarrhea)
Pantothenic acid (B_5)	Acetylation reactions (CoA)	• Distal paresthesia (rare)
Pyridoxine (B_6)	Transamination of amino acids (amino acid synthesis)	• Peripheral neuropathy • Cheilosis, stomatitis, glossitis
Biotin (B_7)	Carboxylase reactions (CO_2 carrier)	• Dermatitis, conjunctivitis, alopecia, neurologic changes
Folate (B_9)	Hydroxymethyl/formyl carrier (purine & thymine synthesis)	• Megaloblastic anemia • Neural tube defects (fetus)
Cobalamin (B_{12})	Isomerase & methyltransferase cofactor (DNA & methionine synthesis)	• Megaloblastic anemia • Neurologic deficits
	Hydroxylation of proline & lysine	• Scurvy (perifollicular hemorrhage

https://t.me/USMLEWorldStep1
Show all

Water-soluble vitamins		
Vitamin	**Primary function**	**Deficiency**
Thiamine (B_1)	Decarboxylation of α-keto acids (carbohydrate metabolism)	• Beriberi (peripheral neuropathy, heart failure) • Wernicke-Korsakoff syndrome
Riboflavin (B_2)	Mitochondrial redox reactions (FMN, FAD)	• Cheilosis, stomatitis, glossitis • Normocytic anemia
Niacin (B_3)	Redox reactions (NAD/NADP)	• Pellagra (dermatitis, dementia, diarrhea)
Pantothenic acid (B_5)	Acetylation reactions (CoA)	• Distal paresthesia (rare)
Pyridoxine (B_6)	Transamination of amino acids (amino acid synthesis)	• Peripheral neuropathy • Cheilosis, stomatitis, glossitis
Biotin (B_7)	Carboxylase reactions (CO_2 carrier)	• Dermatitis, conjunctivitis, alopecia, neurologic changes
Folate (B_9)	Hydroxymethyl/formyl carrier (purine & thymine synthesis)	• Megaloblastic anemia • Neural tube defects (fetus)
Cobalamin (B_{12})	Isomerase & methyltransferase cofactor (DNA & methionine synthesis)	• Megaloblastic anemia • Neurologic deficits
Ascorbic acid (C)	Hydroxylation of proline & lysine (collagen synthesis)	• Scurvy (perifollicular hemorrhage, gingivitis, muscle pain)

This patient with perifollicular hemorrhages, gingivitis, and subperiosteal hematomas likely has **vitamin C**

https://t.me/USMLEWorldStep1
Show all

Ascorbic acid (C)	Hydroxylation of proline & lysine (collagen synthesis)	• Scurvy (perifollicular hemorrhage, gingivitis, muscle pain)

This patient with perifollicular hemorrhages, gingivitis, and subperiosteal hematomas likely has **vitamin C deficiency (scurvy)**. This condition is rare in resource-rich countries but can occur in patients who are malnourished; children with autism, as in this case, are at increased risk due to a higher likelihood of self-**restrictive diets** that lack vitamin C–rich foods (eg, vegetables, citrus fruits).

Vitamin C is a cofactor for the hydroxylation of proline and lysine during collagen synthesis. Hydroxyproline and hydroxylysine are essential for the spontaneous cross-linking of collagen molecules. Vitamin C deficiency impairs collagen cross-linking, compromising tensile strength, particularly in the skin and vascular walls. Increased **vascular wall fragility** leads to:

- Perifollicular hemorrhages
- Petechiae/ecchymoses
- **Periodontal disease** (gingival erythema/edema/bleeding)
- Intramuscular or **subperiosteal hemorrhages**, especially in the lower extremities due to increased hydrostatic pressure. This results in **pain** and **difficulty with ambulation**, which may be the presenting symptoms in children.

Other features associated with defective collagen production in vitamin C deficiency include poor wound healing, follicular hyperkeratosis, and corkscrew hairs.

(Choice A) Vitamin B_2 (riboflavin) deficiency is characterized by stomatitis, cheilosis, and glossitis but not perifollicular/subperiosteal hemorrhage.

(Choice B) Vitamin B_3 (niacin) deficiency, or pellagra, is characterized by dermatitis, dementia, and diarrhea. Bleeding symptoms are not seen.

(Choices C, E, and G) Vitamin B_6 (pyridoxine) and B_{12} (cobalamin) deficiencies may cause peripheral neuropathy

https://t.me/USMLEWorldStep1
Show all

symptoms in children.

Other features associated with defective collagen production in vitamin C deficiency include poor wound healing, follicular hyperkeratosis, and corkscrew hairs.

(Choice A) Vitamin B_2 (riboflavin) deficiency is characterized by stomatitis, cheilosis, and glossitis but not perifollicular/subperiosteal hemorrhage.

(Choice B) Vitamin B_3 (niacin) deficiency, or pellagra, is characterized by dermatitis, dementia, and diarrhea. Bleeding symptoms are not seen.

(Choices C, E, and G) Vitamin B_6 (pyridoxine) and B_{12} (cobalamin) deficiencies may cause peripheral neuropathy that leads to difficulty walking. Similarly, vitamin D deficiency can cause difficulty walking but due to osteomalacia and bone pain. None of these conditions are associated with the subperiosteal and perifollicular hemorrhages seen in this patient.

(Choice D) Vitamin B_7 (biotin) deficiency may cause difficulty walking that would be due to a neurologic deficit (eg, ataxia, paresthesias), not subperiosteal hematomas. Moreover, other typical findings include perioral dermatitis, conjunctivitis, and alopecia, none of which are seen in this patient.

(Choice H) Vitamin K deficiency leads to impaired synthesis of coagulation factors, most commonly causing easy bruising and mucosal bleeding. In contrast to this case, gingivitis (swollen, tender gums) would not be seen. Moreover, the perifollicular hemorrhages seen in this patient are more specific for scurvy because they represent capillary fragility, not impaired coagulation.

Educational objective:
Vitamin C is a cofactor for the hydroxylation of proline and lysine during collagen synthesis, which is essential for maximum tensile strength. Deficiency (scurvy) is characterized by periodontal disease, impaired wound healing, vascular wall fragility (eg, perifollicular, subperiosteal hemorrhage), follicular hyperkeratosis, and corkscrew hairs.

Biochemistry Gastrointestinal & Nutrition Vitamin C deficiency

https://t.me/USMLEWorldStep1
Show all

Ascorbic acid (C)	Hydroxylation of proline & lysine (collagen synthesis)	• Scurvy (perifollicular hemorrhage, gingivitis, muscle pain)

Exhibit Display

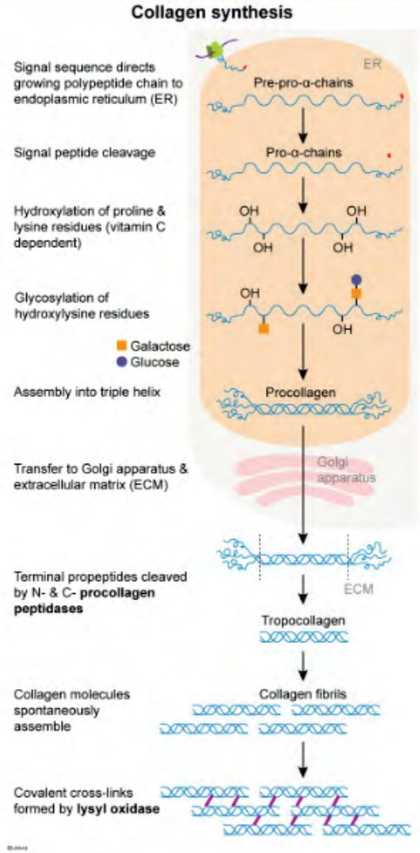

Zoom In | Zoom Out | Reset | New | Existing | My Notebook

This p
defici
malno
restri

Vitami
hydrox
collage
vascu

- P
- P
- **P**
- In
  h
  sy

Other
follicul

(Choi
perifol

(Choi
Bleedi

(Choices C, E, and G) Vitamin B_6 (pyridoxine) and B_{12} (cobalamin) deficiencies may cause peripheral neuropathy

https://t.me/USMLEWorldStep1
Show all

Ascorbic acid (C)	Hydroxylation of proline & lysine (collagen synthesis)	• Scurvy (perifollicular hemorrhage, gingivitis, muscle pain)

Exhibit Display

Vitamin C deficiency (scurvy)

©UWorld

Zoom In | Zoom Out | Reset | New | Existing | My Notebook

This p
defici
malno
restri

Vitami
hydrox
collage
vascu

- P
- P
- **P**
- In
  h
  sy

Other
follicul

(Choi
perifol

(Choi
Bleedi

(Choices C, E, and G) Vitamin B_6 (pyridoxine) and B_{12} (cobalamin) deficiencies may cause peripheral neuropathy

https://t.me/USMLEWorldStep1
Show all

Ascorbic acid (C)	Hydroxylation of proline & lysine (collagen synthesis)

- Scurvy (perifollicular hemorrhage, gingivitis, muscle pain)

Exhibit Display

Vitamin C deficiency (scurvy)

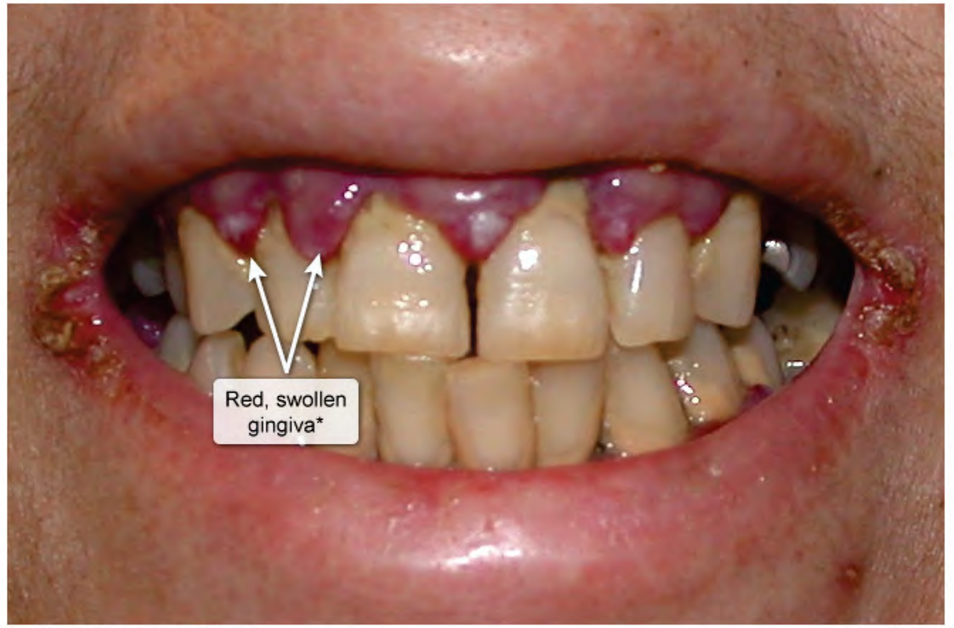

*Due to impaired collagen formation.

©UWorld

Zoom In | Zoom Out | Reset | New | Existing | My Notebook

This p
defici
malno
restri

Vitami
hydrox
collage
vascu

- P
- P
- **P**
- Ir
  h
  sy

Other
follicul

(Choi
perifol

(Choi
Bleedi

(Choices C, E, and G) Vitamin B_6 (pyridoxine) and B_{12} (cobalamin) deficiencies may cause peripheral neuropathy

https://t.me/USMLEWorldStep1

A 56-year-old man comes to the emergency department because of sudden onset of severe, diffuse abdominal pain. The patient has experienced 3 months of epigastric pain that has been refractive to proton-pump inhibitor therapy. Physical examination reveals an exquisitely tender, rigid abdomen with rebound tenderness. Abdominal radiographs reveal free air under the diaphragm. Supportive therapy is initiated. Exploratory laparotomy reveals a large, perforated gastric ulcer with features suggestive of malignancy. He undergoes partial gastrectomy with gastrojejunostomy. Long-term supplementation with which of the following is most important in this patient?

- A. Ascorbic acid
- B. Biotin
- C. Iron
- D. Pantothenic acid
- E. Pyridoxine

Submit

https://t.me/USMLEWorldStep1
Show all

A 56-year-old man comes to the emergency department because of sudden onset of severe, diffuse abdominal pain. The patient has experienced 3 months of epigastric pain that has been refractive to proton-pump inhibitor therapy. Physical examination reveals an exquisitely tender, rigid abdomen with rebound tenderness. Abdominal radiographs reveal free air under the diaphragm. Supportive therapy is initiated. Exploratory laparotomy reveals a large, perforated gastric ulcer with features suggestive of malignancy. He undergoes partial gastrectomy with gastrojejunostomy. Long-term supplementation with which of the following is most important in this patient?

- A. Ascorbic acid (4%)
- ✕ B. Biotin (4%)
- ✓ C. Iron (74%)
- D. Pantothenic acid (4%)
- E. Pyridoxine (12%)

Incorrect
Correct answer
C

74%
Answered correctly

41 secs
Time Spent

2023
Version

Explanation

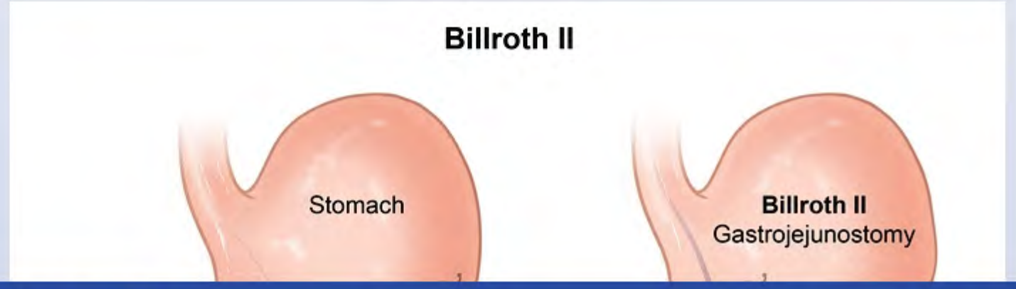

https://t.me/USMLEWorldStep1
Show all

A 56-year-old man comes to the emergency department because of sudden onset of severe, diffuse abdominal pain. [illegible] therap[illegible] radiog[illegible] large, [illegible] gastro[illegible]

Exhibit Display

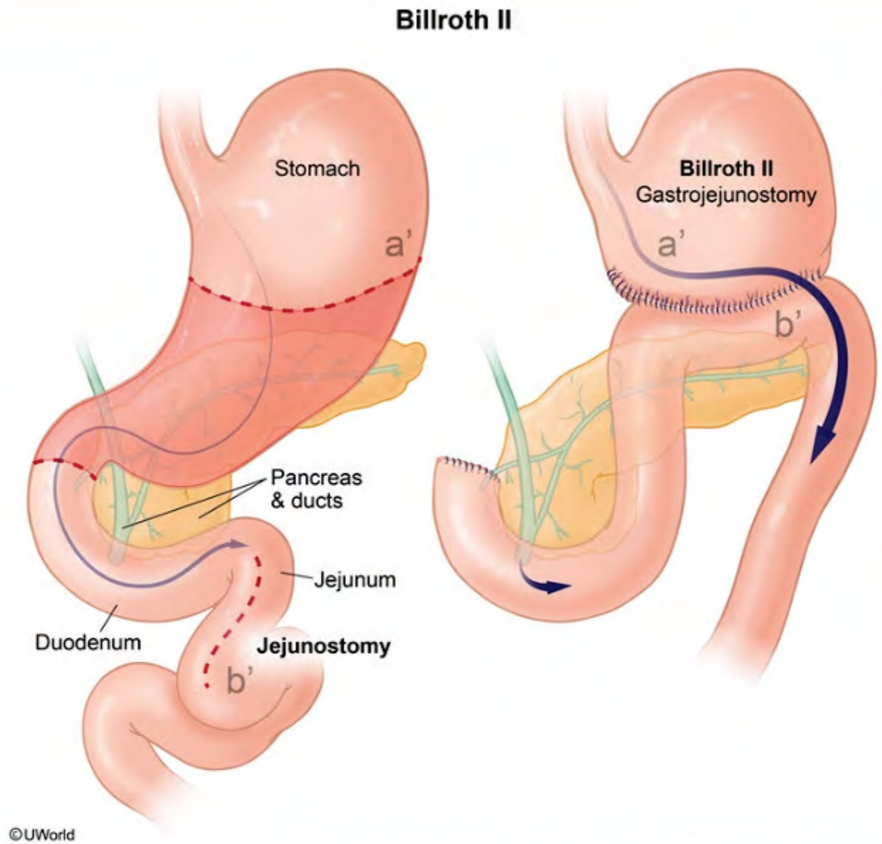

Zoom In | Zoom Out | Reset | New | Existing | My Notebook

Gastrojejunostomy

https://t.me/USMLEWorldStep1

Show all

©UWorld

Partial gastrectomy with **gastrojejunostomy** is most often performed to treat **complicated peptic ulcer disease** (eg, perforation, malignancy, gastric outlet obstruction) or ulcers refractory to medical management. In a Billroth II gastrojejunostomy, the gastric antrum is removed to decrease gastrin production and for histopathologic evaluation. A side-to-side anastomosis is then made between the jejunum and the gastric body, bypassing the duodenum and proximal jejunum.

Iron absorption occurs predominantly in the **duodenum and proximal jejunum**, and bypass of this segment of small bowel results in iron deficiency **anemia**. The post-surgical decrease in gastric acidity also diminishes iron absorption and may contribute to iron deficiency in these patients. Treatment is accomplished with pharmacologic **iron supplementation**, which allows for adequate iron absorption at secondary absorption sites in the distal small bowel.

Deficiency involving thiamine, folate, vitamin B_{12}, fat-soluble vitamins (especially vitamin D), and calcium is also common following gastrojejunostomy.

(Choice A) Although ascorbic acid (vitamin C) can increase the bioavailability of nonheme iron, vitamin C supplementation would not be enough to counteract the effect of decreased iron absorption post-gastrojejunostomy.

(Choices B and D) Biotin (vitamin B_7) and pantothenic acid (vitamin B_5) are absorbed in the small and large intestine via the sodium-dependent multivitamin transporter. Deficiency of either of these vitamins is rare and not associated with gastric bypass procedures.

(Choice E) Pyridoxine (vitamin B_6) absorption occurs in the jejunum and the ileum by passive diffusion and is not typically affected by gastrojejunostomy.

Educational objective:
Iron absorption occurs predominantly in the duodenum and proximal jejunum. Bypass of this segment of small

https://t.me/USMLEWorldStep1
Show all

Partial gastrectomy with **gastrojejunostomy** is most often performed to treat **complicated peptic ulcer disease** (eg, perforation, malignancy, gastric outlet obstruction) or ulcers refractory to medical management. In a Billroth II gastrojejunostomy, the gastric antrum is removed to decrease gastrin production and for histopathologic evaluation. A side-to-side anastomosis is then made between the jejunum and the gastric body, bypassing the duodenum and proximal jejunum.

Iron absorption occurs predominantly in the **duodenum and proximal jejunum**, and bypass of this segment of small bowel results in iron deficiency **anemia**. The post-surgical decrease in gastric acidity also diminishes iron absorption and may contribute to iron deficiency in these patients. Treatment is accomplished with pharmacologic **iron supplementation**, which allows for adequate iron absorption at secondary absorption sites in the distal small bowel.

Deficiency involving thiamine, folate, vitamin B_{12}, fat-soluble vitamins (especially vitamin D), and calcium is also common following gastrojejunostomy.

(Choice A) Although ascorbic acid (vitamin C) can increase the bioavailability of nonheme iron, vitamin C supplementation would not be enough to counteract the effect of decreased iron absorption post-gastrojejunostomy.

(Choices B and D) Biotin (vitamin B_7) and pantothenic acid (vitamin B_5) are absorbed in the small and large intestine via the sodium-dependent multivitamin transporter. Deficiency of either of these vitamins is rare and not associated with gastric bypass procedures.

(Choice E) Pyridoxine (vitamin B_6) absorption occurs in the jejunum and the ileum by passive diffusion and is not typically affected by gastrojejunostomy.

Educational objective:
Iron absorption occurs predominantly in the duodenum and proximal jejunum. Bypass of this segment of small bowel by gastrojejunostomy results in iron deficiency anemia that can be corrected with pharmacologic iron supplementation. Malabsorption of thiamine, folate, vitamin B_{12}, fat-soluble vitamins (especially vitamin D), and calcium is also common following gastric bypass procedures.

https://t.me/USMLEWorldStep1
Show all

A 72-year-old woman comes to the emergency department due to bloody bowel movements. One hour ago, the patient had a sudden urge to defecate and passed a large amount of bright red blood mixed with stool. Several minutes later, she had another episode with a small amount of blood. The patient reports no nausea, vomiting, abdominal pain, diarrhea, or fever and never had such symptoms before. She is hospitalized but has no further bleeding. Physical examination, including a digital rectal examination, is unremarkable. A colonoscopy performed after bowel preparation reveals the findings in the exhibit. There are no other abnormalities. Which of following is the most likely source of this patient's bleeding?

- A. Abnormal arteriovenous channel
- B. Diffusely eroded mucosal surface
- C. Dilated and tortuous venous plexus
- D. Disruption of vasa recta
- E. Sloughed off polypoidal mass

Submit

https://t.me/USMLEWorldStep1

A 72-year-old woman comes to the emergency department due to bloody bowel movements. One hour ago, the patien
minute
abdom
bleedi
after b
the mo

Sub

Exhibit Display

Zoom In | Zoom Out | Reset | New | Existing | My Notebook

https://t.me/USMLEWorldStep1

A 72-year-old woman comes to the emergency department due to bloody bowel movements. One hour ago, the patient had a sudden urge to defecate and passed a large amount of bright red blood mixed with stool. Several minutes later, she had another episode with a small amount of blood. The patient reports no nausea, vomiting, abdominal pain, diarrhea, or fever and never had such symptoms before. She is hospitalized but has no further bleeding. Physical examination, including a digital rectal examination, is unremarkable. A colonoscopy performed after bowel preparation reveals the findings in the exhibit. There are no other abnormalities. Which of following is the most likely source of this patient's bleeding?

- A. Abnormal arteriovenous channel (6%)
- B. Diffusely eroded mucosal surface (17%)
- C. Dilated and tortuous venous plexus (7%)
- ✓ D. Disruption of vasa recta (63%)
- E. Sloughed off polypoidal mass (4%)

Correct

63% Answered correctly

21 secs Time Spent

2023 Version

Explanation

Diverticular disease	
Etiology	• Diverticulosis: ↑ intraluminal pressure causing herniation through points of weakness (vasa recta penetration) • Diverticular bleeding: injury to exposed vasa recta • Diverticulitis: trapped food particles & ↑ intraluminal pressure

https://t.me/USMLEWorldStep1
Show all

Diverticular disease	
Etiology	• Diverticulosis: ↑ intraluminal pressure causing herniation through points of weakness (vasa recta penetration) • Diverticular bleeding: injury to exposed vasa recta • Diverticulitis: trapped food particles & ↑ intraluminal pressure causing microperforation
Symptoms	• Diverticulosis: none • Diverticular bleeding: painless hematochezia • Diverticulitis: left lower quadrant pain, nausea, vomiting, fever
Risk factors	• Diet high in red meat & fat & low in fiber • Obesity, physical inactivity, smoking

This patient with hematochezia had a colonoscopy revealing multiple outpouchings of the colonic mucosa, consistent with **colonic diverticulosis**. The incidence of diverticulosis increases with age and is seen typically in patients age >60. Risk factors include low-fiber, high-fat diet, obesity, and physical inactivity.

Diverticula tend to form in areas where the intraluminal colon wall lacks structural integrity. Typically, these weak points are located where the **vasa recta** (terminal vessels derived from the superior and inferior mesenteric arteries) penetrate through the smooth muscular layer of the colon. As the diverticula enlarge, the vessels are exposed to chronic injury, leading to thinning of the vascular media. Ultimately, the weakened **vessels can ulcerate and rupture**, leading to intraluminal hemorrhage and **painless hematochezia** that is often self-limited but can occasionally result in hemodynamic instability.

Management includes patient resuscitation (eg, intravenous fluids) and colonoscopy, which can diagnose diverticulosis and may identify and treat the source of any active bleeding; angiography or surgery may be required for persistent bleeding.

https://t.me/USMLEWorldStep1
Show all

arteries) penetrate through the smooth muscular layer of the colon. As the diverticula enlarge, the vessels are exposed to chronic injury, leading to thinning of the vascular media. Ultimately, the weakened **vessels can ulcerate and rupture**, leading to intraluminal hemorrhage and **painless hematochezia** that is often self-limited but can occasionally result in hemodynamic instability.

Management includes patient resuscitation (eg, intravenous fluids) and colonoscopy, which can diagnose diverticulosis and may identify and treat the source of any active bleeding; angiography or surgery may be required for persistent bleeding.

(Choice A) Angiodysplasias are abnormal arteriovenous channels that form from ectatic, thin-walled vessels within the gastrointestinal tract. Although they can also cause painless hematochezia, they are identified on colonoscopy as flat, red lesions with a fern-like or arborized appearance.

(Choice B) Diffuse, continuous mucosal inflammation and erosion extending from the rectum and into the proximal colon are consistent with ulcerative colitis (UC) and typically grossly visible on endoscopy. Although UC also causes hematochezia, it is typically associated with diarrhea, progressive abdominal pain, tenesmus, and fevers.

(Choice C) Hemorrhoids are characterized by dilation and tortuosity of the rectal venous plexuses. These appear as a purplish or bluish bulge at the anorectum and are identified easily on physical examination or during colonoscopy.

(Choice E) Colorectal adenocarcinoma, which arises typically from colonic polyps, can also cause hematochezia due to mucosal sloughing but is usually identified during a colonoscopy as an ulcerated polypoid mass. Patients also often have a history of unexplained weight loss, fatigue, or abnormal stool caliber (eg, pencil-thin stool).

Educational objective:
Colonic diverticula form at weak points in the colon wall, typically in areas where the vasa recta penetrate through the smooth muscle. As diverticula enlarge, the vasa recta are exposed and become vulnerable to chronic injury, which can lead to intraluminal hemorrhage and painless hematochezia.

https://t.me/USMLEWorldStep1
Show all

This p
consis
patien

Diverti
points
arterie
expos
ulcera
but ca

Manag
diverti
for per

(Choi
within
colonc

(Choi
proxim
also ca
fevers

(Choi
as a p
colonc

(Choice E) Colorectal adenocarcinoma, which arises typically from colonic polyps, can also cause hematochezia due to mucosal sloughing but is usually identified during a colonoscopy as an ulcerated polypoid mass. Patients

Exhibit Display

Zoom In | Zoom Out | Reset | New | Existing | My Notebook

https://t.me/USMLEWorldStep1

but can occasionally result in hemodynamic instability.

Manag
diverti
for per

(Choi
within
colonc

(Choi
proxim
also ca
fevers

(Choi
as a p
colonc

(Choi
due to
also of

Educa
Coloni
the sm
which

Pathol
Subject

Exhibit Display

Zoom In | Zoom Out | Reset | New | Existing | My Notebook

Copyright © UWorld. All rights reserved.

https://t.me/USMLEWorldStep1

A 45-year-old woman diagnosed with Crohn disease 3 years ago comes to the office due to recurrent right upper quadrant abdominal pain. The pain is graded 5/10 in intensity, is characterized as dull, and occasionally radiates to the right shoulder. It typically occurs after eating fatty meals and is associated with nausea. The patient has no fever, vomiting, melena, or hematochezia. She currently takes infliximab for Crohn disease and atorvastatin for hyperlipidemia. Vital signs and abdominal examination are normal. Abdominal ultrasonography reveals multiple mobile calculi within the gallbladder. Which of the following processes is most likely responsible for the development of gallstones in this patient?

- A. Gallbladder hypomobility
- B. Increased bile acid wasting
- C. Increased intestinal oxalate absorption
- D. Medication side effect
- E. Red blood cell destruction

Submit

https://t.me/USMLEWorldStep1
Show all

A 45-year-old woman diagnosed with Crohn disease 3 years ago comes to the office due to recurrent right upper quadrant abdominal pain. The pain is graded 5/10 in intensity, is characterized as dull, and occasionally radiates to the right shoulder. It typically occurs after eating fatty meals and is associated with nausea. The patient has no fever, vomiting, melena, or hematochezia. She currently takes infliximab for Crohn disease and atorvastatin for hyperlipidemia. Vital signs and abdominal examination are normal. Abdominal ultrasonography reveals multiple mobile calculi within the gallbladder. Which of the following processes is most likely responsible for the development of gallstones in this patient?

- A. Gallbladder hypomobility (18%)
- ✓ B. Increased bile acid wasting (45%)
- C. Increased intestinal oxalate absorption (16%)
- D. Medication side effect (18%)
- E. Red blood cell destruction (1%)

Correct

45% Answered correctly

03 secs Time Spent

2023 Version

Explanation

Pathogenesis of gallstones in Crohn disease

https://t.me/USMLEWorldStep1
Show all

E. Red blood cell destruction (1%)

Exhibit Display

Pathogenesis of gallstones in Crohn disease

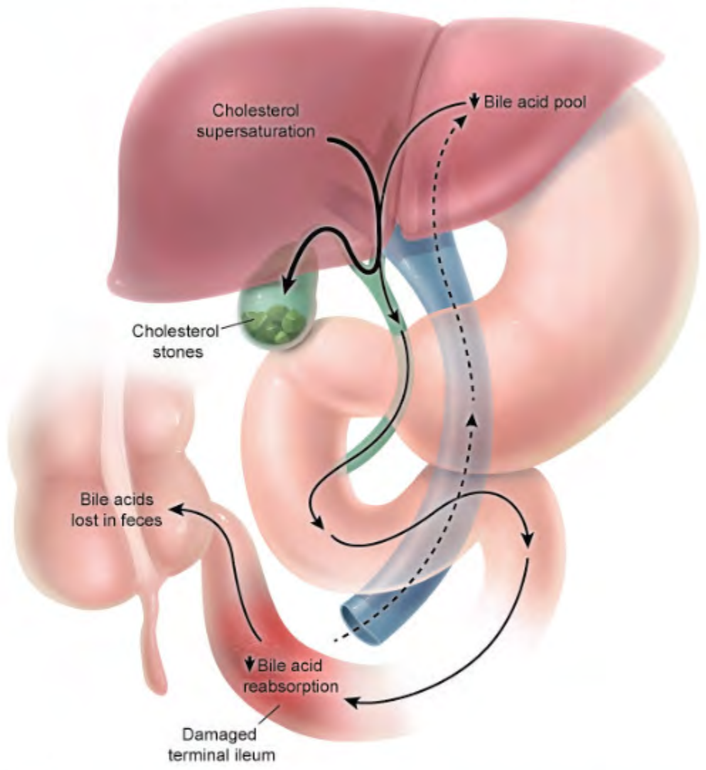

Zoom In | Zoom Out | Reset | New | Existing | My Notebook

https://t.me/USMLEWorldStep1

©UWorld

This patient with Crohn disease most likely developed gallstones due to inflammation of the terminal ileum causing decreased bile acid reabsorption.

Bile acids are produced in the liver and excreted with bile into the duodenum. There, they **emulsify fat droplets** to form water-soluble micelles that allow pancreatic lipase to efficiently hydrolyze triglycerides into fatty acids and monoglycerides. In the jejunum, these micelles come in close contact with the gut epithelium, which facilitates the passive absorption of fatty acids, monoglycerides, and cholesterol across the brush border into enterocytes. However, bile acids are ionized molecules that cannot passively cross the intestinal wall. The bile acids eventually reach the **terminal ileum**, where specialized transport proteins allow them to be **reabsorbed**.

The terminal ileum is a typical location of activity in **Crohn disease**. When the mucosa of the terminal ileum is inflamed, **bile acids are lost in the feces**. As a result, a lesser amount of bile acid is present in the bile, so the ratio of cholesterol/bile acids increases. Supersaturation of the bile with cholesterol then leads to formation of **gallstones**.

(Choice A) Gallbladder hypomobility may contribute to cholesterol gallstone formation in patients with spinal cord injury or those receiving total parenteral nutrition; however, this is not observed with Crohn disease.

(Choice C) Increased intestinal oxalate absorption can contribute to calcium oxalate **kidney** stone formation in patients with Crohn disease (enteric oxaluria). However, this process is not responsible for the development of gallstones.

(Choice D) Statins inhibit the rate-limiting step of cholesterol synthesis (HMG-CoA reductase), which reduces the risk of gallstone formation. Infliximab is a tumor necrosis factor-alpha inhibitor used to treat severe or refractory Crohn disease; it is associated with an increased risk of serious infections.

(Choice E) Chronic hemolytic anemias are associated with the development of pigment gallstones due to the increased secretion of bilirubin into bile. Crohn disease can cause anemia due to nutrient deficiency (eg, vitamin B_{12}, iron) and chronic inflammation (eg, anemia of chronic disease), but it does not typically cause hemolysis.

https://t.me/USMLEWorldStep1
Show all

passive absorption of fatty acids, monoglycerides, and cholesterol across the brush border into enterocytes. However, bile acids are ionized molecules that cannot passively cross the intestinal wall. The bile acids eventually reach the **terminal ileum**, where specialized transport proteins allow them to be **reabsorbed**.

The terminal ileum is a typical location of activity in **Crohn disease**. When the mucosa of the terminal ileum is inflamed, **bile acids are lost in the feces**. As a result, a lesser amount of bile acid is present in the bile, so the ratio of cholesterol/bile acids increases. Supersaturation of the bile with cholesterol then leads to formation of **gallstones**.

(Choice A) Gallbladder hypomobility may contribute to cholesterol gallstone formation in patients with spinal cord injury or those receiving total parenteral nutrition; however, this is not observed with Crohn disease.

(Choice C) Increased intestinal oxalate absorption can contribute to calcium oxalate **kidney** stone formation in patients with Crohn disease (enteric oxaluria). However, this process is not responsible for the development of gallstones.

(Choice D) Statins inhibit the rate-limiting step of cholesterol synthesis (HMG-CoA reductase), which reduces the risk of gallstone formation. Infliximab is a tumor necrosis factor-alpha inhibitor used to treat severe or refractory Crohn disease; it is associated with an increased risk of serious infections.

(Choice E) Chronic hemolytic anemias are associated with the development of pigment gallstones due to the increased secretion of bilirubin into bile. Crohn disease can cause anemia due to nutrient deficiency (eg, vitamin B_{12}, iron) and chronic inflammation (eg, anemia of chronic disease), but it does not typically cause hemolysis.

Educational objective:
Patients with Crohn disease affecting the terminal ileum (most common site of involvement) are prone to developing gallstones. Decreased bile acid reabsorption by the inflamed terminal ileum promotes cholesterol supersaturation of the bile, resulting in gallstone formation.

References

- Pathogenesis of gall stones in Crohn's disease: an alternative explanation.
- Gallbladder bile composition in patients with Crohn's disease.

https://t.me/USMLEWorldStep1
Show all

A term newborn boy is evaluated in the neonatal intensive care unit for respiratory distress. Apgar scores are 2 and 5 at 1 and 5 minutes, respectively. Respirations are 84/min. On examination, the patient has a barrel chest with a scaphoid abdomen and mild cyanosis of his extremities. Auscultation shows absent breath sounds on the left; right lung aeration is normal. Chest x-ray reveals multiple fluid-containing cystic areas on the left and a mediastinal shift to the right. Which of the following embryologic events most likely failed to occur in this patient?

- A. Closure of the pleuroperitoneal fold
- B. Closure of the ventral body wall
- C. Formation of the pleuropericardial membrane
- D. Rotation of the midgut
- E. Separation of the dorsal and ventral foregut

Submit

https://t.me/USMLEWorldStep1
Show all

A term newborn boy is evaluated in the neonatal intensive care unit for respiratory distress. Apgar scores are 2 and 5 at 1 and 5 minutes, respectively. Respirations are 84/min. On examination, the patient has a barrel chest with a scaphoid abdomen and mild cyanosis of his extremities. Auscultation shows absent breath sounds on the left; right lung aeration is normal. Chest x-ray reveals multiple fluid-containing cystic areas on the left and a mediastinal shift to the right. Which of the following embryologic events most likely failed to occur in this patient?

- ✓ A. Closure of the pleuroperitoneal fold (73%)
- ✗ B. Closure of the ventral body wall (3%)
- C. Formation of the pleuropericardial membrane (15%)
- D. Rotation of the midgut (4%)
- E. Separation of the dorsal and ventral foregut (4%)

Incorrect
Correct answer
A

73%
Answered correctly

03 secs
Time Spent

2023
Version

Explanation

Congenital diaphragmatic hernia

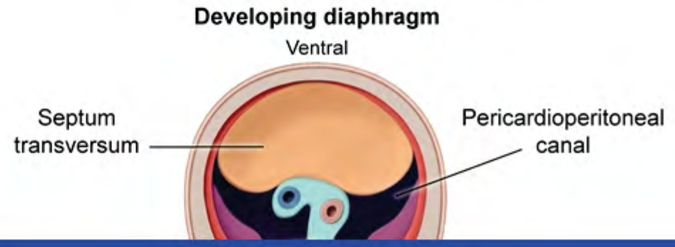

https://t.me/USMLEWorldStep1
Show all

A term newborn boy is evaluated in the neonatal intensive care unit for respiratory distress. Apgar scores are 2 and 5 with a left; rig media

Exhibit Display

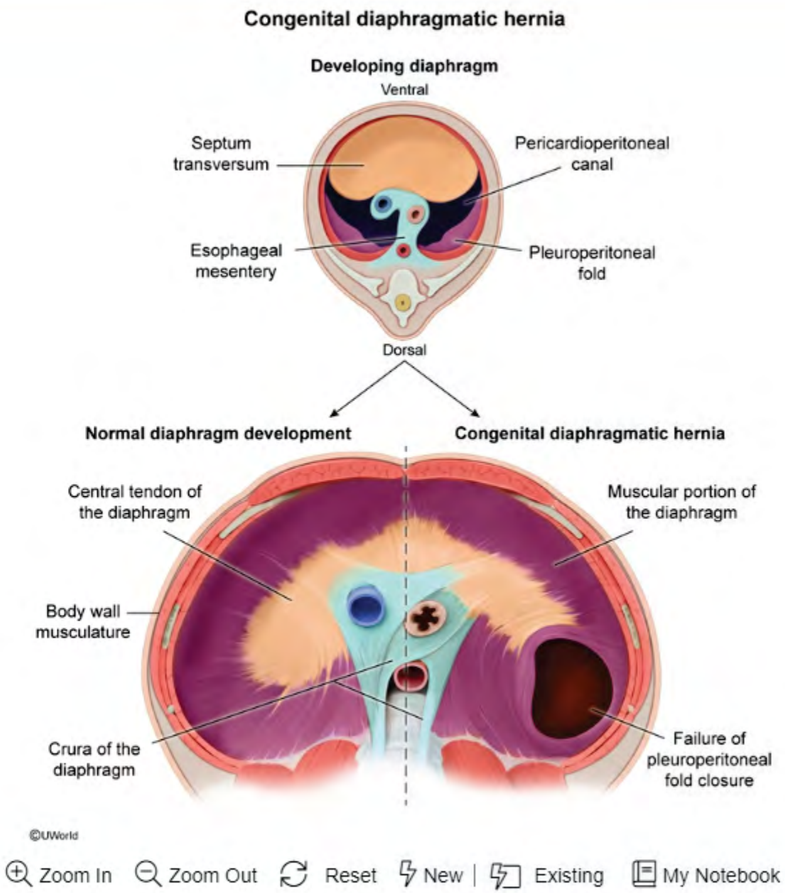

Zoom In | Zoom Out | Reset | New | Existing | My Notebook

Inco
Corre
A

Expl

https://t.me/USMLEWorldStep1

fold closure

©UWorld

This **newborn** with **respiratory distress** and **unilateral decreased breath sounds** has a **scaphoid abdomen** and chest x-ray revealing cystic structures. These findings are consistent with a **congenital diaphragmatic hernia** (CDH), a congenital malformation caused by failure of the pleuroperitoneal folds to close.

In general, the diaphragm forms from 4 distinct tissues: the septum transversum, esophageal mesentery, musculature from the body wall, and pleuroperitoneal folds. Extension of the **pleuroperitoneal folds** to these other structures ultimately leads to division of the pericardioperitoneal canal into the peritoneal cavity and thoracic cavity. **Failure of closure** results in an abnormal communication between the thorax and abdomen. This defect is usually located on the left posterolateral side, allowing bowel, stomach, spleen, and/or liver to herniate into the thorax. Because this malformation occurs during organogenesis in the first trimester, compression of the developing lung leads to **pulmonary hypoplasia**.

Affected newborns have respiratory distress at birth. Displacement of abdominal organs into the thorax causes the abdomen to appear scaphoid and the chest barrel shaped. Ipsilateral breath sounds are decreased or absent. Chest x-ray findings supportive of CDH include **mediastinal shift** and **thoracic bowel loops**, which may appear as cystic, fluid-filled structures.

(Choice B) Failure of ventral body wall closure results in gastroschisis, which is characterized by bowel evisceration without a protective membrane. A full-thickness abdominal wall defect is apparent on examination.

(Choice C) The pleuropericardial membranes, which become the fibrous pericardium, fuse to separate the pericardial and pleural cavities. Fusion defects are rare, often asymptomatic, and result in communication between these two thoracic cavities, not between the thorax and abdomen.

(Choice D) Malrotation, characterized by incomplete physiologic rotation of the bowel in utero, usually presents with bilious emesis in infancy due to duodenal obstruction from abnormally positioned peritoneal bands. Respiratory distress and thoracic bowel loops would not be seen.

(Choice E) Abnormal separation of the dorsal (gastrointestinal tract) and ventral (respiratory tract) foregut results

https://t.me/USMLEWorldStep1
Show all

usually located on the left posterolateral side, allowing bowel, stomach, spleen, and/or liver to herniate into the thorax. Because this malformation occurs during organogenesis in the first trimester, compression of the developing lung leads to **pulmonary hypoplasia**.

Affected newborns have respiratory distress at birth. Displacement of abdominal organs into the thorax causes the abdomen to appear scaphoid and the chest barrel shaped. Ipsilateral breath sounds are decreased or absent. Chest x-ray findings supportive of CDH include **mediastinal shift** and **thoracic bowel loops**, which may appear as cystic, fluid-filled structures.

(Choice B) Failure of ventral body wall closure results in gastroschisis, which is characterized by bowel evisceration without a protective membrane. A full-thickness abdominal wall defect is apparent on examination.

(Choice C) The pleuropericardial membranes, which become the fibrous pericardium, fuse to separate the pericardial and pleural cavities. Fusion defects are rare, often asymptomatic, and result in communication between these two thoracic cavities, not between the thorax and abdomen.

(Choice D) Malrotation, characterized by incomplete physiologic rotation of the bowel in utero, usually presents with bilious emesis in infancy due to duodenal obstruction from abnormally positioned peritoneal bands. Respiratory distress and thoracic bowel loops would not be seen.

(Choice E) Abnormal separation of the dorsal (gastrointestinal tract) and ventral (respiratory tract) foregut results in esophageal atresia with or without a tracheoesophageal fistula. Symptoms include respiratory distress and choking with feeds; chest x-ray would not show cystic thoracic structures.

Educational objective:
Congenital diaphragmatic hernia is caused by failure of the pleuroperitoneal folds to close. Immediately after birth, newborns have respiratory distress, unilateral decreased breath sounds, and a scaphoid abdomen, with imaging revealing thoracic bowel loops and mediastinal shift.

References

- Congenital diaphragmatic hernia.
- Congenital diaphragmatic hernia—a review.

https://t.me/USMLEWorldStep1
Show all

fold closure

This n
and ch
hernia

In gen
muscu
other s
cavity.
usually
thorax
develo

Affecte
abdom
Chest
as cys

(Choi
evisce

(Choi
perica
these

(Choi
with bi
Respir

Exhibit Display

Congenital diaphragmatic hernia

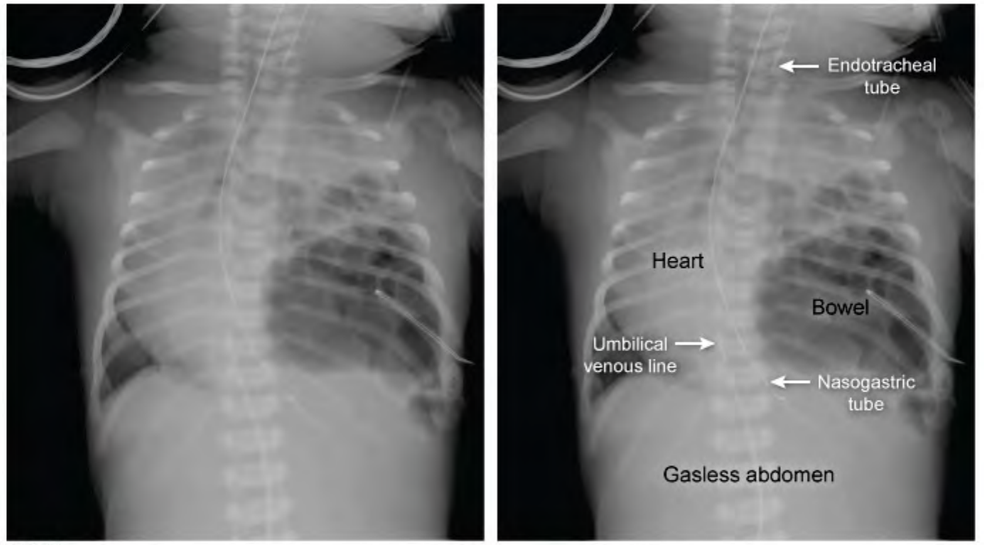

©UWorld

Zoom In | Zoom Out | Reset | New | Existing | My Notebook

https://t.me/USMLEWorldStep1
Show all

fold closure

Exhibit Display

This n
and ch
hernia

In gen
muscu
other s
cavity.
usually
thorax
develo

Affecte
abdom
Chest
as cys

(Choi
evisce

(Choi
perica
these

(Choi
with bi

Respiratory distress and thoracic bowel loops would not be seen.

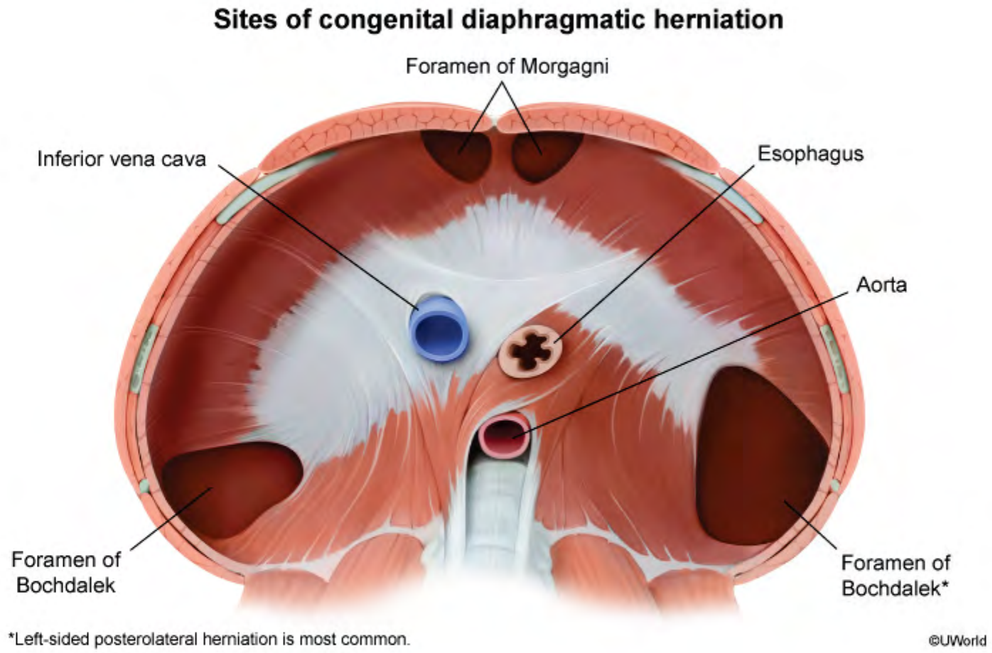

Zoom In Zoom Out Reset New | Existing My Notebook

https://t.me/USMLEWorldStep1

fold closure

Exhibit Display

Gastroschisis
Eviscerated bowel with no covering membrane

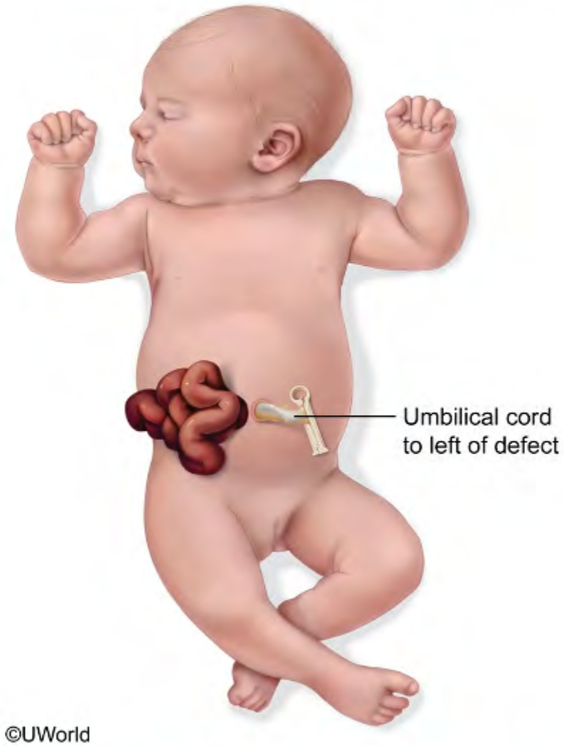

©UWorld

Zoom In | Zoom Out | Reset | New | Existing | My Notebook

This n
and ch
hernia

In gen
muscu
other s
cavity.
usually
thorax
develo

Affecte
abdom
Chest
as cys

(Choi
evisce

(Choi
perica
these

(Choi
with bi

Respiratory distress and thoracic bowel loops would not be seen.

https://t.me/USMLEWorldStep1

fold closure

This n
and ch
hernia

In gen
muscu
other s
cavity.
usually
thorax
develo

Affecte
abdom
Chest
as cys

(Choi
evisce

(Choi
perica
these

(Choi
with bi
Respir

Exhibit Display

Midgut malrotation

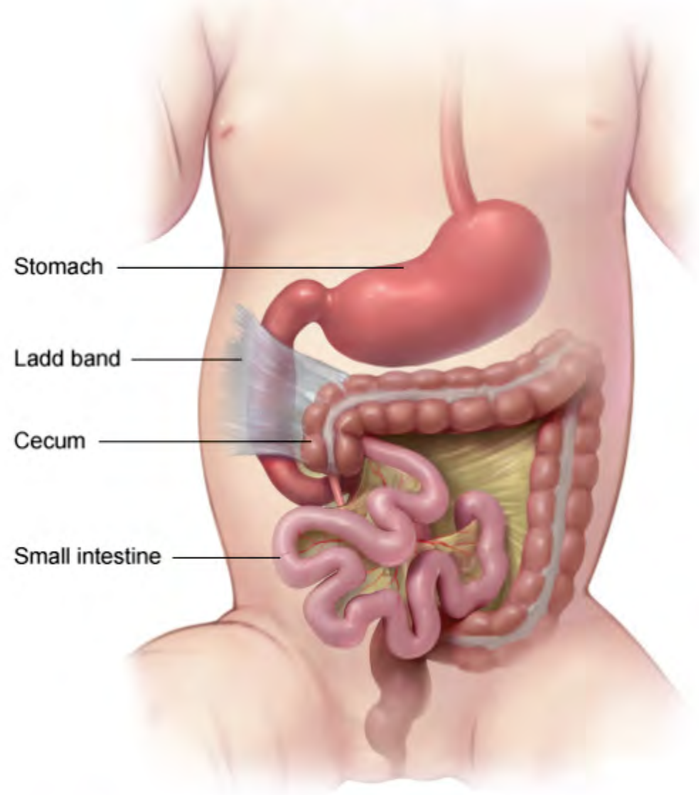

©UWorld

Zoom In | Zoom Out | Reset | New | Existing | My Notebook

https://t.me/USMLEWorldStep1

usually located on the left posterolateral side, allowing bowel, stomach, spleen, and/or liver to herniate into the thorax. Because this malformation occurs during organogenesis in the first trimester, compression of the develo

Affecte
abdom
Chest
as cys

(Choi
evisce

(Choi
perica
these

(Choi
with bi
Respir

(Choi
in eso
chokin

Educa
Conge
newbo
reveal

Refere

- Congenital diaphragmatic hernia.
- Congenital diaphragmatic hernia—a review.

Exhibit Display

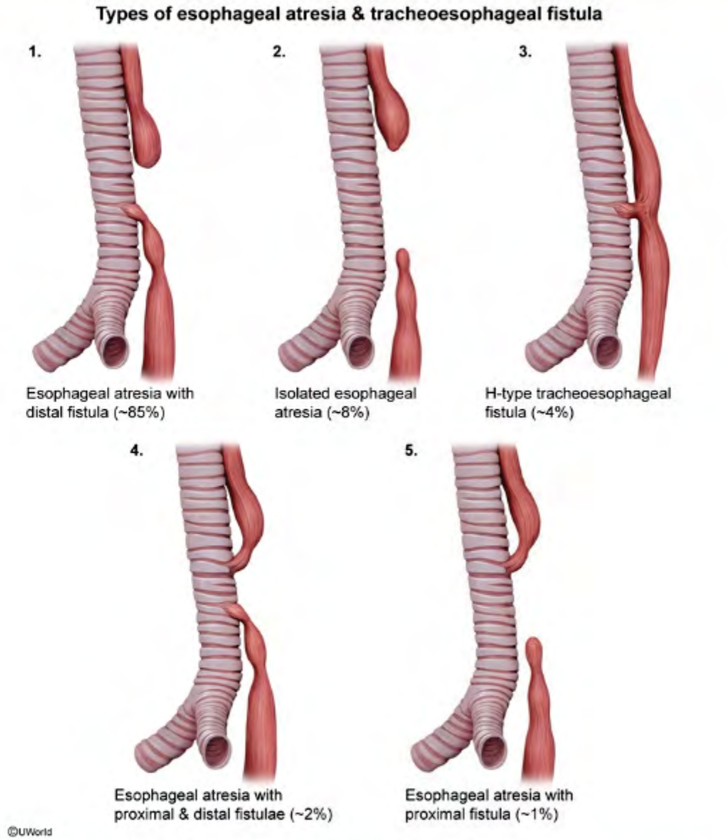

Zoom In | Zoom Out | Reset | New | Existing | My Notebook

https://t.me/USMLEWorldStep1

A 23-year-old woman comes to the physician due to acute nausea and vomiting. She recently returned from a vacation to Mexico and started to feel "queasy" on the last day of her trip. The patient then developed nausea with frequent vomiting and intermittent bouts of watery diarrhea. She has no visible blood in her stools. Her temperature is 36.8 C (98 F), blood pressure is 118/70 mm Hg, pulse is 86/min, and respirations are 12/min. Abdominal examination shows mild tenderness and increased bowel sounds. Improvement of this patient's vomiting would best be achieved by a medication targeting which of the following receptors?

- A. 5-HT_3 receptor
- B. μ-opioid receptor
- C. Dopamine receptor
- D. Histamine H_1 receptor
- E. Histamine H_2 receptor
- F. Muscarinic acetylcholine receptor
- G. Somatostatin receptor

Submit

https://t.me/USMLEWorldStep1
Show all

A 23-year-old woman comes to the physician due to acute nausea and vomiting. She recently returned from a vacation to Mexico and started to feel "queasy" on the last day of her trip. The patient then developed nausea with frequent vomiting and intermittent bouts of watery diarrhea. She has no visible blood in her stools. Her temperature is 36.8 C (98 F), blood pressure is 118/70 mm Hg, pulse is 86/min, and respirations are 12/min. Abdominal examination shows mild tenderness and increased bowel sounds. Improvement of this patient's vomiting would best be achieved by a medication targeting which of the following receptors?

- ✓ A. 5-HT_3 receptor (55%)
- ✗ B. μ-opioid receptor (9%)
- C. Dopamine receptor (11%)
- D. Histamine H_1 receptor (5%)
- E. Histamine H_2 receptor (3%)
- F. Muscarinic acetylcholine receptor (13%)
- G. Somatostatin receptor (2%)

Incorrect
Correct answer
A

55%
Answered correctly

03 secs
Time Spent

2023
Version

Explanation

https://t.me/USMLEWorldStep1
Show all

A 23-year-old woman comes to the physician due to acute nausea and vomiting. She recently returned from a
vacati
freque
tempe
Abdon
vomiti

Exhibit Display

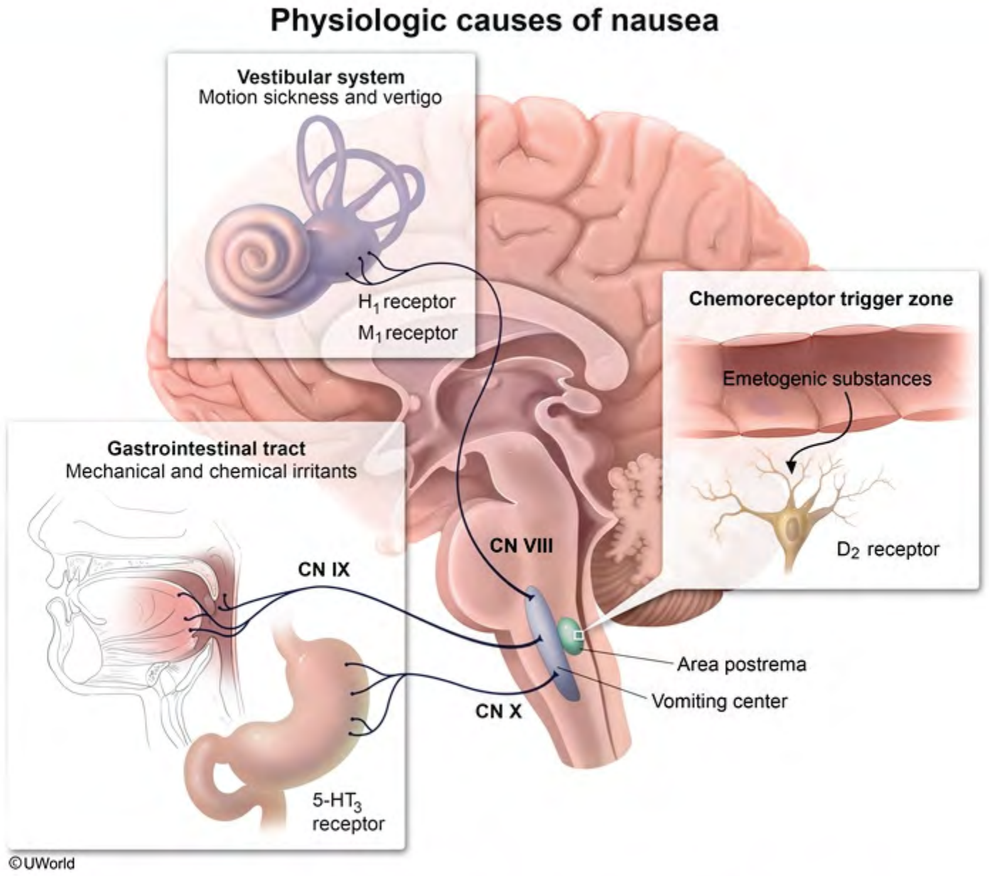

Zoom In | Zoom Out | Reset | New | Existing | My Notebook

Inco
Corre
A

Expl

https://t.me/USMLEWorldStep1

This patient's nausea, vomiting, and watery diarrhea are typical symptoms of classic **travelers' diarrhea (TD)**. TD can be caused by a variety of organisms, including bacteria (eg, *Escherichia coli*), viruses (eg, rotaviruses), or occasionally, parasites (eg, *Cryptosporidium parvum*). In most cases, the illness is self-limited and treatment is symptomatic.

The choice of antiemetic therapy depends on the source of the emetogenic stimulus. Conditions that cause **gastrointestinal irritation** (eg, infections, chemotherapy, distention) result in increased mucosal **serotonin** release and activation of 5-HT_3 receptors on vagal and spinal afferent nerves. These then relay their impulses to the medullary vomiting center, inducing emesis. **5-HT_3 receptor antagonists** (eg, ondansetron) are well-tolerated medications that are very effective at reducing nausea and vomiting caused by gastrointestinal upset.

(Choice B) Loperamide is a μ-opioid receptor agonist that functions as an antimotility agent. It is commonly used in TD to reduce diarrhea but can worsen nausea and vomiting due to colonic retention.

(Choice C) Dopamine receptor antagonists (eg, metoclopramide, prochlorperazine) are effective in treating central nausea (seen in acute migraines) and also reduce migraine headache pain. Dopamine antagonists have significant adverse effects including sedation and extrapyramidal symptoms; these are not the first-line treatment for nausea due to gastrointestinal upset.

(Choices D and F) First-generation H_1 receptor antagonists (eg, diphenhydramine, meclizine) and muscarinic acetylcholine receptor antagonists (eg, scopolamine) are frequently used to treat vestibular nausea (eg, motion sickness). Promethazine is a dopamine and H_1 receptor antagonist that can also treat vestibular nausea. All of these medications can cause significant sedation.

(Choice E) H_2 blockers (eg, famotidine) reduce gastric acid secretion and can alleviate symptoms of gastroesophageal reflux but do not treat nausea and vomiting.

(Choice G) Somatostatin receptor agonists (eg, octreotide) inhibit bioactive amine release and are used to treat diarrhea in patients with carcinoid syndrome and vasoactive intestinal peptide-secreting tumors (ie, VIPoma). They are also used for treatment of acute esophageal variceal hemorrhage.

https://t.me/USMLEWorldStep1
Show all

release and activation of 5-HT_3 receptors on vagal and spinal afferent nerves. These then relay their impulses to the medullary vomiting center, inducing emesis. **5-HT_3 receptor antagonists** (eg, ondansetron) are well-tolerated medications that are very effective at reducing nausea and vomiting caused by gastrointestinal upset.

(Choice B) Loperamide is a μ-opioid receptor agonist that functions as an antimotility agent. It is commonly used in TD to reduce diarrhea but can worsen nausea and vomiting due to colonic retention.

(Choice C) Dopamine receptor antagonists (eg, metoclopramide, prochlorperazine) are effective in treating central nausea (seen in acute migraines) and also reduce migraine headache pain. Dopamine antagonists have significant adverse effects including sedation and extrapyramidal symptoms; these are not the first-line treatment for nausea due to gastrointestinal upset.

(Choices D and F) First-generation H_1 receptor antagonists (eg, diphenhydramine, meclizine) and muscarinic acetylcholine receptor antagonists (eg, scopolamine) are frequently used to treat vestibular nausea (eg, motion sickness). Promethazine is a dopamine and H_1 receptor antagonist that can also treat vestibular nausea. All of these medications can cause significant sedation.

(Choice E) H_2 blockers (eg, famotidine) reduce gastric acid secretion and can alleviate symptoms of gastroesophageal reflux but do not treat nausea and vomiting.

(Choice G) Somatostatin receptor agonists (eg, octreotide) inhibit bioactive amine release and are used to treat diarrhea in patients with carcinoid syndrome and vasoactive intestinal peptide-secreting tumors (ie, VIPoma). They are also used for treatment of acute esophageal variceal hemorrhage.

Educational objective:
5-HT_3 receptor antagonists are useful for the treatment of visceral nausea due to gastrointestinal insults, such as gastroenteritis, chemotherapy, and general anesthesia. Antihistamines and anticholinergics are recommended for vestibular nausea. Dopamine antagonists are useful for nausea associated with migraine.

References

- Use of antiemetic agents in acute gastroenteritis: a systematic review and meta-analysis.

https://t.me/USMLEWorldStep1
Show all

A 40-year-old man comes to the office with pain on defecation. The pain is sharp and severe but subsides within minutes of passing the bowel movement. He often sees spots of bright red blood on the toilet paper. The patient has chronic constipation and has not taken laxatives or increased his fluid intake to compensate. He has no fever, night sweats, diarrhea, or unexpected weight loss. Past medical history is notable for chronic low back pain following a motor vehicle accident, for which he takes a scheduled dose of pain relievers. The patient has smoked a pack of cigarettes daily for the last 20 years but does not use alcohol or illicit drugs. He is married and has no outside sexual contacts. Vital signs are normal. The abdomen is soft and nontender with no hepatosplenomegaly. Rectal examination is likely to show a tear at which of the following locations?

- A. Anterior midline distal to the dentate line
- B. Anterior midline proximal to the dentate line
- C. Bilateral distal to the dentate line
- D. Lateral distal to the dentate line
- E. Lateral proximal to the dentate line
- F. Posterior midline distal to the dentate line

Submit

https://t.me/USMLEWorldStep1
Show all

A 40-year-old man comes to the office with pain on defecation. The pain is sharp and severe but subsides within minutes of passing the bowel movement. He often sees spots of bright red blood on the toilet paper. The patient has chronic constipation and has not taken laxatives or increased his fluid intake to compensate. He has no fever, night sweats, diarrhea, or unexpected weight loss. Past medical history is notable for chronic low back pain following a motor vehicle accident, for which he takes a scheduled dose of pain relievers. The patient has smoked a pack of cigarettes daily for the last 20 years but does not use alcohol or illicit drugs. He is married and has no outside sexual contacts. Vital signs are normal. The abdomen is soft and nontender with no hepatosplenomegaly. Rectal examination is likely to show a tear at which of the following locations?

- ✗ A. Anterior midline distal to the dentate line (12%)
- B. Anterior midline proximal to the dentate line (6%)
- C. Bilateral distal to the dentate line (5%)
- D. Lateral distal to the dentate line (11%)
- E. Lateral proximal to the dentate line (3%)
- ✓ F. Posterior midline distal to the dentate line (59%)

Incorrect
Correct answer
F

59%
Answered correctly

03 secs
Time Spent

2023
Version

Explanation

Anorectal arterial supply

https://t.me/USMLEWorldStep1
Show all

B. Anterior midline proximal to the dentate line (6%)

Exhibit Display

Anorectal arterial supply

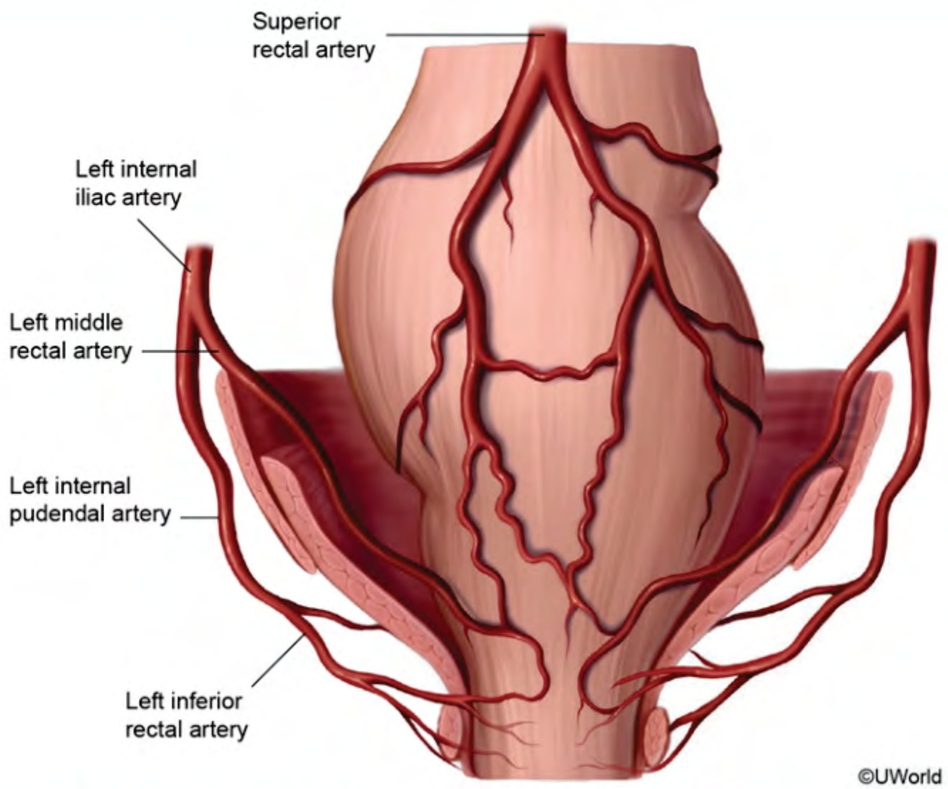

Zoom In | Zoom Out | Reset | New | Existing | My Notebook

https://t.me/USMLEWorldStep1

©UWorld

This patient has sharp pain and bright red rectal bleeding on defecation, suggesting an **anal fissure**. Anal fissures are due to stretching of the mucosa and are characterized by longitudinal tears in the anal canal distal to the dentate line **(Choice B)**. Spasm of the sphincter can contribute to the pain and create tension across the wound, leading to a chronic fissure. Most fissures are related to chronic constipation with high anal pressures and passage of hard stools. They can also be seen with frequent diarrhea or anal sexual intercourse. In some cases, the pain may be so severe that patients withhold bowel movements, thereby exacerbating the constipation.

The majority of fissures, especially those causing prolonged symptoms, occur at the **posterior midline** of the anal verge. This is likely due to the relatively poor perfusion of the posterior anal canal, which makes its mucosa sensitive to trauma and slows healing times. Anterior midline fissures are less common, but may occur due to mechanical stresses related to the alignment of muscular fibers in the external sphincter **(Choice A)**.

(Choice C) Bilateral anal fissures are uncommon.

(Choices D and E) Fissures not at the midline are more likely due to unusual causes (eg, inflammatory bowel disease, malignancy, infection) and may warrant more detailed investigation.

Educational objective:
Anal fissures are longitudinal tears in the mucosa. They are usually due to passage of hard stool in patients with chronic constipation. Most fissures occur at the posterior midline, likely due to decreased blood flow in this area. Fissures in other areas may be due to less common causes.

References

- Anorectal conditions: anal fissure and anorectal fistula.

Pathology	Gastrointestinal & Nutrition	Anal fissure
Subject	System	Topic

Copyright © UWorld. All rights reserved.

https://t.me/USMLEWorldStep1
Show all

A 48-year-old male is admitted to the hospital with severe epigastric abdominal pain and vomiting after an episode of binge-drinking. Four weeks later, he is found to have a palpable upper abdominal mass and a cystic lesion is visualized on computed tomography scanning (see image below, asterisk marks the lesion).

The inner walls of the lesion are most likely lined with:

- A. Glycogen-rich cuboidal epithelium
- B. Columnar mucinous epithelium
- C. Atypical cells forming papillary projections
- D. Fibrous and granulation tissue
- E. Endothelial cells

Submit

https://t.me/USMLEWorldStep1

A 48-year-old male is admitted to the hospital with severe epigastric abdominal pain and vomiting after an episode of bing
visuali

Exhibit Display

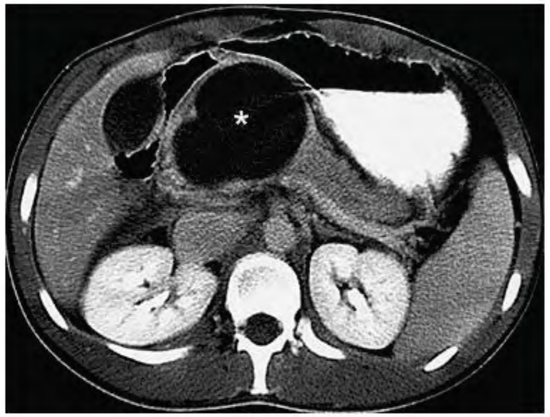

Zoom In Zoom Out Reset New | Existing My Notebook

The in

Sub

https://t.me/USMLEWorldStep1

A 48-year-old male is admitted to the hospital with severe epigastric abdominal pain and vomiting after an episode of binge-drinking. Four weeks later, he is found to have a palpable upper abdominal mass and a cystic lesion is visualized on computed tomography scanning (see image below, asterisk marks the lesion).

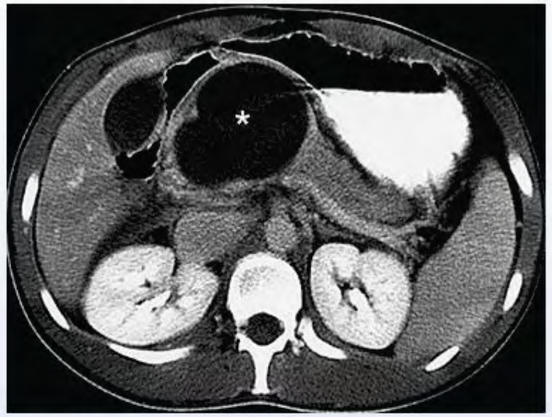

The inner walls of the lesion are most likely lined with:

- A. Glycogen-rich cuboidal epithelium
- B. Columnar mucinous epithelium
- C. Atypical cells forming papillary projections
- D. Fibrous and granulation tissue
- E. Endothelial cells

Submit

https://t.me/USMLEWorldStep1
Show all

A 48-year-old male is admitted to the hospital with severe epigastric abdominal pain and vomiting after an episode of binge-drinking. Four weeks later, he is found to have a palpable upper abdominal mass and a cystic lesion is visualized on computed tomography scanning (see image below, asterisk marks the lesion).

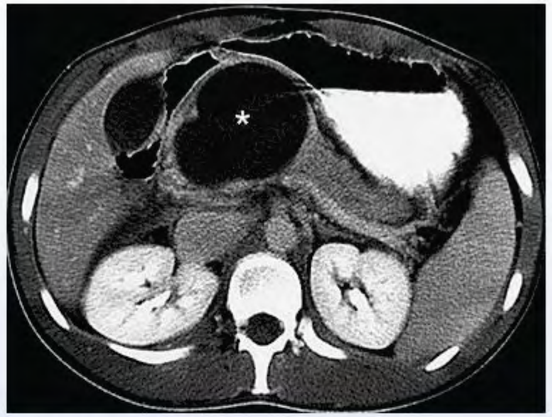

The inner walls of the lesion are most likely lined with:

- A. Glycogen-rich cuboidal epithelium (13%)
- B. Columnar mucinous epithelium (31%)
- ✗ C. Atypical cells forming papillary projections (5%)
- ✓ D. Fibrous and granulation tissue (42%)
- E. Endothelial cells (7%)

Incorrect
Correct answer
D

42%
Answered correctly

10 secs
Time Spent

2023
Version

Explanation

https://t.me/USMLEWorldStep1
Show all

Explanation

This CT image shows a pancreatic pseudocyst, a potential complication of pancreatitis. In acute pancreatitis, proteolytic enzymes may disrupt the walls of the pancreatic ducts and cause leakage of pancreatic secretions into the peripancreatic space. This fluid has a high pancreatic enzyme content and induces an inflammatory reaction in the walls of the surrounding organs. Granulation tissue forms, encapsulating the fluid collection and forming a pseudocyst.

In contrast to a true cyst with walls lined by epithelial cells, the walls of a pseudocyst consist of granulation tissue and no epithelial lining. Fibrosis, thickening and organization of the walls occur with time. The formation of firm fibrotic pseudocyst walls ("maturation" of the pseudocyst) takes about 4 to 6 weeks following the episode of acute pancreatitis.

The most common location for a pseudocyst is in the lesser peritoneal sac, bordered by the stomach, duodenum and transverse colon. The pseudocyst walls are closely adherent to the surrounding hollow organs. The pseudocyst in the CT image above is located in the lesser sac, posterior to the stomach.

(Choice A) Glycogen-rich cuboidal epithelium is seen in serous pancreatic neoplasms.

(Choice B) Columnar mucinous epithelium is typically found in mucinous cystic neoplasms of the pancreas.

(Choice C) Atypical cells forming papillary projections are seen in the papillary variant of pancreatic adenocarcinoma.

(Choice E) Endothelial cells are not found in the wall of the pseudocyst.

Educational Objective:
Pancreatic pseudocyst is a common complication of acute pancreatitis. It is a collection of fluid rich in enzymes and inflammatory debris. Its walls consist of granulation tissue and fibrosis. Unlike true cysts, pseudocysts are not lined by epithelium.

Pathology Gastrointestinal & Nutrition Acute pancreatitis

https://t.me/USMLEWorldStep1
Show all

A 59-year-old woman comes to the office due to fatigue and generalized itching that have developed slowly over the last year. She has not had a visible rash. The patient is reluctant to seek health care and has not seen a physician in years. She does not use tobacco, alcohol, or illicit drugs. Vital signs are normal. Examination shows mild hepatomegaly. Laboratory studies show a striking increase in serum alkaline phosphatase, with moderate elevations in bilirubin and hepatic transaminases. Liver biopsy reveals dilated bile canaliculi with green-brown plugs and yellowish-green accumulations of pigment within the hepatic parenchyma. The patient does not return for her scheduled follow-up appointment to discuss further management. This patient is at risk for developing which of the following complications?

- A. Cardiac dilation
- B. Choreoathetosis
- C. Fat-soluble vitamin deficiency
- D. Gastric atrophy
- E. Macrocytic anemia
- F. Seborrheic dermatitis

Submit

https://t.me/USMLEWorldStep1
Show all

A 59-year-old woman comes to the office due to fatigue and generalized itching that have developed slowly over the last year. She has not had a visible rash. The patient is reluctant to seek health care and has not seen a physician in years. She does not use tobacco, alcohol, or illicit drugs. Vital signs are normal. Examination shows mild hepatomegaly. Laboratory studies show a striking increase in serum alkaline phosphatase, with moderate elevations in bilirubin and hepatic transaminases. Liver biopsy reveals dilated bile canaliculi with green-brown plugs and yellowish-green accumulations of pigment within the hepatic parenchyma. The patient does not return for her scheduled follow-up appointment to discuss further management. This patient is at risk for developing which of the following complications?

- ✗ A. Cardiac dilation (3%)
- B. Choreoathetosis (8%)
- ✓ C. Fat-soluble vitamin deficiency (81%)
- D. Gastric atrophy (1%)
- E. Macrocytic anemia (3%)
- F. Seborrheic dermatitis (2%)

Incorrect
Correct answer
C

81%
Answered correctly

21 secs
Time Spent

2023
Version

Explanation

Causes of cholestasis

https://t.me/USMLEWorldStep1
Show all

Causes of cholestasis	
Intrahepatic	• Drug induced (eg, erythromycin, contraceptives) • Primary biliary cholangitis • Cholestasis of pregnancy • Primary sclerosing cholangitis (may also be extrahepatic)
Extrahepatic	• Choledocholithiasis • Malignancy (eg, pancreatic, gallbladder)

This patient has fatigue, pruritus, hepatomegaly, and an elevated alkaline phosphatase level suggesting cholestatic liver disease. **Cholestasis** can arise secondary to hepatocellular dysfunction or intrahepatic or extrahepatic biliary obstruction. Both obstructive and nonobstructive cholestasis are characterized by the deposition of bile pigment within the hepatic parenchyma, often with green-brown plugs in the dilated bile canaliculi. When it is prolonged, the reduction in bile flow causes intestinal **malabsorption** of fats and **fat-soluble vitamins** (A, D, E, and K), which require bile salts for digestion.

(Choice A) Cardiac dilation can result from deficiency of thiamine (vitamin B_1), a water-soluble vitamin. Deficiency is common in patients with alcohol use disorder, not cholestatic liver disease.

(Choice B) Wilson disease is an autosomal recessive disorder characterized by abnormal biliary handling of copper. Liver disease with eventual cirrhosis is common. Central nervous system involvement can cause dysarthria, ataxia, and movement disorders including chorea and athetosis. Hepatocellular markers (eg, transaminases) will be elevated more prominently than cholestatic markers.

(Choices D and E) Atrophic gastritis can be due to autoimmune causes (pernicious anemia), *Helicobacter pylori* infection, radiation, or granulomatous conditions. Loss of intrinsic factor production by parietal cells can lead to deficiency of vitamin B_{12} with resulting macrocytic anemia.

https://t.me/USMLEWorldStep1
Show all

	• Primary sclerosing cholangitis (may also be extrahepatic)
Extrahepatic	• Choledocholithiasis • Malignancy (eg, pancreatic, gallbladder)

This patient has fatigue, pruritus, hepatomegaly, and an elevated alkaline phosphatase level suggesting cholestatic liver disease. **Cholestasis** can arise secondary to hepatocellular dysfunction or intrahepatic or extrahepatic biliary obstruction. Both obstructive and nonobstructive cholestasis are characterized by the deposition of bile pigment within the hepatic parenchyma, often with green-brown plugs in the dilated bile canaliculi. When it is prolonged, the reduction in bile flow causes intestinal **malabsorption** of fats and **fat-soluble vitamins** (A, D, E, and K), which require bile salts for digestion.

(Choice A) Cardiac dilation can result from deficiency of thiamine (vitamin B_1), a water-soluble vitamin. Deficiency is common in patients with alcohol use disorder, not cholestatic liver disease.

(Choice B) Wilson disease is an autosomal recessive disorder characterized by abnormal biliary handling of copper. Liver disease with eventual cirrhosis is common. Central nervous system involvement can cause dysarthria, ataxia, and movement disorders including chorea and athetosis. Hepatocellular markers (eg, transaminases) will be elevated more prominently than cholestatic markers.

(Choices D and E) Atrophic gastritis can be due to autoimmune causes (pernicious anemia), *Helicobacter pylori* infection, radiation, or granulomatous conditions. Loss of intrinsic factor production by parietal cells can lead to deficiency of vitamin B_{12} with resulting macrocytic anemia.

(Choice F) Seborrheic dermatitis is a common inflammatory condition characterized by accumulation of scaly, greasy skin on the scalp, face, ears, eyelids, and eyebrows. Severe or widespread seborrhea is seen in HIV infection and Parkinson disease, but it is not associated with cholestatic liver disease.

Educational objective:
Cholestatic liver disease can cause malabsorption and nutritional deficiencies of fat-soluble vitamins.

Pathology Gastrointestinal & Nutrition Cholestasis

https://t.me/USMLEWorldStep1
Show all

- Primary sclerosing cholangitis (may also be extrahepatic)

Exhibit Display

Seborrheic dermatitis

*High concentration of sebaceous glands.

©UWorld

Zoom In | Zoom Out | Reset | New | Existing | My Notebook

This p
liver di
obstru
within
the rec
require

(Choi
is com

(Choi
coppe
dysart
transa

(Choi
infecti
deficie

(Choi
greasy
infecti

Educa
Choles

Pathology | Gastrointestinal & Nutrition | Cholestasis

https://t.me/USMLEWorldStep1

A 62-year-old woman comes to the office due to a change in bowel habits. For 2 months, she has had bowel movements once every 5 or 6 days. The patient describes her stools as hard and lumpy and of small volume; defecation is uncomfortable. She has no trouble passing gas and has no other symptoms, including no nausea, vomiting, or weight changes. The patient was admitted to the hospital 3 months ago for acute diverticulitis, and her hospital course was complicated by new-onset atrial fibrillation. Colonoscopy a month after hospitalization revealed sigmoid diverticulosis but no masses or polyps. The patient takes fiber supplements, diltiazem, and apixaban. She does not use tobacco or alcohol. Vital signs are within normal limits. Cardiac auscultation reveals an irregular heart rhythm but no murmurs. Abdominal examination is significant for mild distension. Which of the following best explains this patient's symptoms?

- A. Alterations in colonic microbiome
- B. Gastrocolic reflex impairment
- C. Inappropriate contraction of pelvic floor muscles
- D. Medication adverse effects
- E. Posterior vaginal wall prolapse
- F. Sigmoid volvulus

Submit

https://t.me/USMLEWorldStep1
Show all

A 62-year-old woman comes to the office due to a change in bowel habits. For 2 months, she has had bowel movements once every 5 or 6 days. The patient describes her stools as hard and lumpy and of small volume; defecation is uncomfortable. She has no trouble passing gas and has no other symptoms, including no nausea, vomiting, or weight changes. The patient was admitted to the hospital 3 months ago for acute diverticulitis, and her hospital course was complicated by new-onset atrial fibrillation. Colonoscopy a month after hospitalization revealed sigmoid diverticulosis but no masses or polyps. The patient takes fiber supplements, diltiazem, and apixaban. She does not use tobacco or alcohol. Vital signs are within normal limits. Cardiac auscultation reveals an irregular heart rhythm but no murmurs. Abdominal examination is significant for mild distension. Which of the following best explains this patient's symptoms?

- A. Alterations in colonic microbiome (6%)
- ✗ B. Gastrocolic reflex impairment (11%)
- C. Inappropriate contraction of pelvic floor muscles (2%)
- ✓ D. Medication adverse effects (66%)
- E. Posterior vaginal wall prolapse (3%)
- F. Sigmoid volvulus (9%)

Incorrect
Correct answer
D

66%
Answered correctly

04 secs
Time Spent

2023
Version

Explanation

Common medications associated with constipation

https://t.me/USMLEWorldStep1
Show all

Common medications associated with constipation	
Opioids	• Centrally acting (eg, oxycodone, morphine) • Peripherally acting (eg, loperamide)
Anticholinergic agents	• Antihistamines (eg, diphenhydramine) • Tricyclic antidepressants (eg, amitriptyline) • Antispasmodics (eg, dicyclomine) • 1st-generation antipsychotics (eg, haloperidol)
Cation-containing agents	• Iron tablets • Aluminum (eg, antacids)
Non–dihydropyridine calcium channel blockers	• Diltiazem, verapamil
5HT$_3$ antagonists	• Ondansetron, granisetron
5-HT$_3$ = 5-hydroxytryptamine type 3.	

Constipation is an exceedingly common gastrointestinal condition with a wide variety of underlying etiologies (eg, autonomic neuropathy, hypothyroidism, electrolyte abnormalities). In this patient who developed constipation after new-onset atrial fibrillation, the most likely etiology is a **drug effect** related to diltiazem.

Diltiazem and verapamil are **non–dihydropyridine calcium channel blockers** that decrease conduction velocity in the sinoatrial and atrioventricular nodes and are often used in the management of atrial fibrillation. Constipation, a common adverse effect, occurs due to inhibition of the colonic migrating motor complex, resulting in **slowed contractions of colonic smooth muscle**. This is not typically seen with dihydropyridine calcium channel blockers (eg, amlodipine, nifedipine).

Other common medications that cause constipation include opiates, serotonin 5-HT$_3$ antagonists (eg,

https://t.me/USMLEWorldStep1
Show all

contractions of colonic smooth muscle. This is not typically seen with dihydropyridine calcium channel blockers (eg, amlodipine, nifedipine).

Other common medications that cause constipation include opiates, serotonin 5-HT_3 antagonists (eg, ondansetron), iron tablets, aluminum-containing agents (eg, antacids), and medications with anticholinergic properties (eg, diphenhydramine, tricyclic antidepressants, first-generation antipsychotics).

(Choice A) Alterations in the colonic microbiome are common after antibiotic therapy but typically cause diarrhea (eg, *Clostridioides* [formerly *Clostridium*] *difficile* colitis), not constipation.

(Choice B) The gastrocolic reflex is a neurogenic reflex triggered by gastric distension from food, leading to colonic contractions; impairment of the reflex can cause constipation. However, this typically occurs in patients with diabetic neuropathy and gastroparesis.

(Choice C) Inappropriate contraction of pelvic floor muscles occurs with dyssenergic defecation, preventing the expulsion of stool from the rectum. Dyssenergic defecation is more common in the elderly and often associated with neurologic disorders (eg, Parkinson disease) or trauma. The development of symptoms after this patient started diltiazem is more consistent with medication-induced constipation.

(Choice E) A rectocele, which occurs when the rectum prolapses into the posterior vaginal wall, usually develops in elderly, multiparous women. Although constipation is common, patients usually describe pelvic pressure and the need to manually push on the vagina or rectum to defecate.

(Choice F) Sigmoid volvulus typically presents with progressive abdominal pain, nausea, and constipation and eventually results in bowel obstruction (eg, failure to pass gas, obstipation, possible perforation). Symptoms occur over the course of days, not months.

Educational objective:
Constipation is a common adverse effect of non–dihydropyridine calcium channel blockers (eg, diltiazem, verapamil). Other medications that cause constipation include opiates, 5-HT_3 antagonists, iron tablets, aluminum-containing antacids, and medications with anticholinergic properties.

https://t.me/USMLEWorldStep1
Show all

A 17-year-old girl is brought to the hospital due to abdominal pain, nausea, and vomiting. She began having periumbilical pain and nausea several hours ago and initially attributed her symptoms to some "bad food" she ate at a potluck lunch earlier in the day. However, her pain progressively worsened and became localized to the right lower quadrant. Temperature is 101 F (38.3 C), blood pressure is 124/78 mm Hg, pulse is 92/min, and respirations are 14/min. On examination, the patient has right lower quadrant tenderness with guarding. Laboratory evaluation shows leukocytosis. Surgical intervention is planned. During surgery, which of the following landmarks is most helpful in identifying the diseased organ?

- A. Greater omentum
- B. Haustra of the colon
- C. Lesser omentum
- D. Psoas major muscle
- E. Teniae coli

Submit

https://t.me/USMLEWorldStep1
Show all

A 17-year-old girl is brought to the hospital due to abdominal pain, nausea, and vomiting. She began having periumbilical pain and nausea several hours ago and initially attributed her symptoms to some "bad food" she ate at a potluck lunch earlier in the day. However, her pain progressively worsened and became localized to the right lower quadrant. Temperature is 101 F (38.3 C), blood pressure is 124/78 mm Hg, pulse is 92/min, and respirations are 14/min. On examination, the patient has right lower quadrant tenderness with guarding. Laboratory evaluation shows leukocytosis. Surgical intervention is planned. During surgery, which of the following landmarks is most helpful in identifying the diseased organ?

- ✗ A. Greater omentum (2%)
- B. Haustra of the colon (16%)
- C. Lesser omentum (2%)
- D. Psoas major muscle (30%)
- ✓ E. Teniae coli (48%)

Incorrect
Correct answer
E

48%
Answered correctly

03 secs
Time Spent

2023
Version

Explanation

https://t.me/USMLEWorldStep1
Show all

A 17-year-old girl is brought to the hospital due to abdominal pain, nausea, and vomiting. She began having
perium
at a pc
lower
are 14
shows
helpfu

Exhibit Display

Colon anatomy

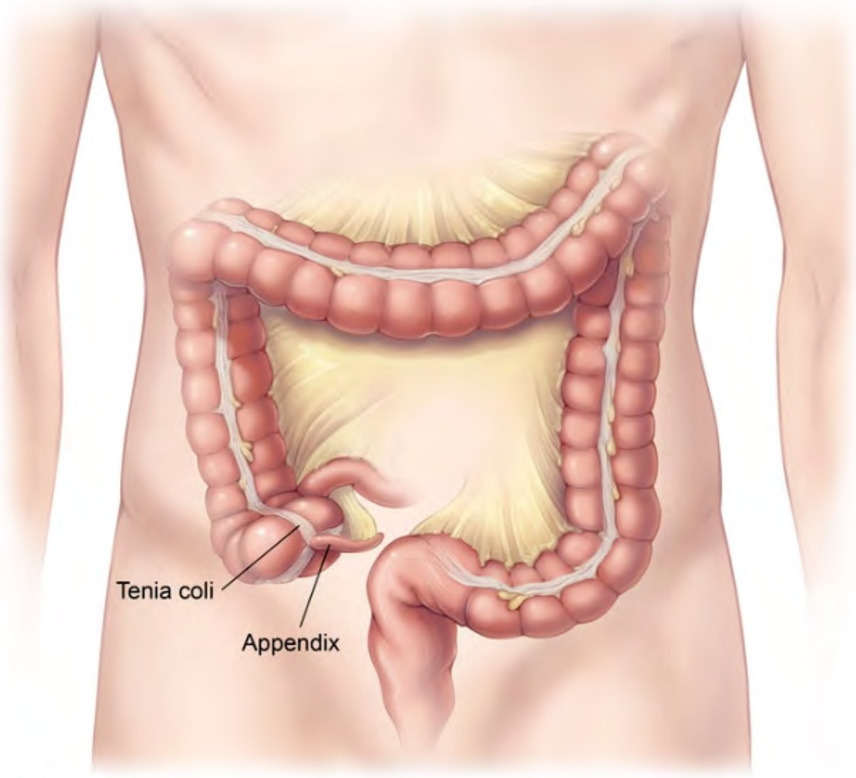

©UWorld

Zoom In Zoom Out Reset New | Existing My Notebook

https://t.me/USMLEWorldStep1

This patient most likely has **appendicitis**, which is usually treated by removing the appendix. During the procedure, the **teniae coli** can be used as a surgical landmark.

The teniae coli begin as a continuous layer of longitudinal muscle that surrounds the rectum just below the serosa. At the rectosigmoid junction, this layer condenses to form **3 distinct longitudinal bands** that travel on the outside of the entire colon before **converging** at the root of the vermiform **appendix**. The teniae coli have a similar function as the outer layer of the muscularis externa in other portions of the digestive tract. If the appendix cannot be identified by palpation during an appendectomy, it can be located by following the teniae coli to its origin at the cecal base.

(Choices A and C) The greater omentum extends from the greater curvature of the stomach in front of the small intestine. It then reflects on itself and ascends to encompass the transverse colon before reaching the posterior abdominal wall. The lesser omentum extends from the fissure of ligamentum venosum and porta hepatis to the lesser curvature of the stomach (hepatogastric ligament) and the start of the duodenum (hepatoduodenal ligament).

(Choice B) The teniae coli run the length of the colon and contract lengthwise to form haustra, colonic sacculations causing the colon's segmented appearance. Compared to the circumferential small intestinal folds, the distance between haustra is wider and they do not span the entire colonic circumference. These differences help distinguish the colon from the small intestine on abdominal x-ray.

(Choice D) Acute appendicitis due to a retrocecal appendix can irritate the iliopsoas group of hip flexors. Psoas sign is abdominal pain elicited by passive thigh extension, which causes friction against nearby inflamed tissues. However, psoas sign can be due to any retroperitoneal irritation and is not specific for appendicitis.

Educational objective:
The teniae coli are 3 separate smooth muscle ribbons that travel longitudinally on the outside of the colon and converge at the root of the vermiform appendix. If the appendix cannot be identified by palpation during an appendectomy, it can be located by following the teniae coli to their origin at the cecal base.

https://t.me/USMLEWorldStep1
Show all

This patient most likely has **appendicitis**, which is usually treated by removing the appendix. During the proced

The te
At the
of the
functio
be ide
cecal l

(Choi
intesti
abdom
lesser
ligame

(Choi
saccul
the dis
help d

(Choi
sign is
Howev

Educa
The te
conver
appen

Exhibit Display

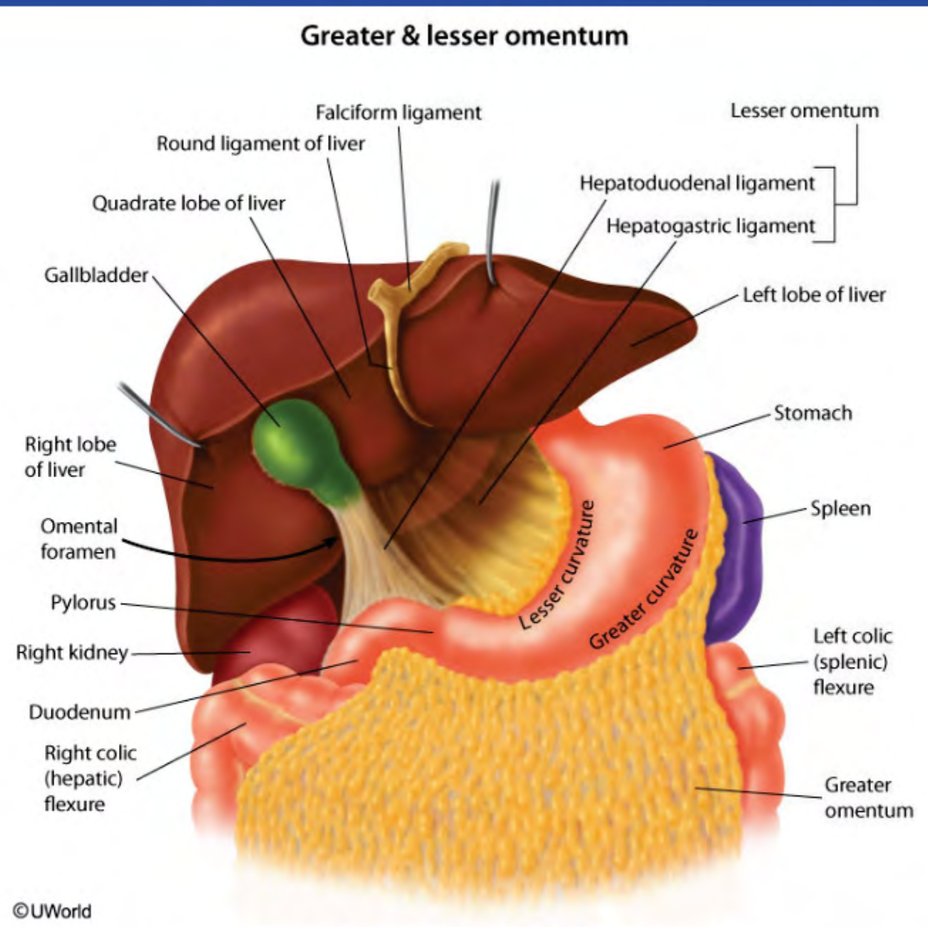

Zoom In | Zoom Out | Reset | New | Existing | My Notebook

https://t.me/USMLEWorldStep1

A 15-month-old boy is brought to the office by his parents for poor weight gain. The parents have also noticed frequent, large, foul-smelling stools. He was admitted to the hospital for a prolonged bout of bacterial pneumonia 6 months ago. Both parents are healthy and have no similar symptoms. The child was born at term at home. He is at the 20th percentile for length and 3rd percentile for weight. Vital signs are normal. On examination, the child appears thin and has a nontender, nondistended abdomen. Which of the following is most likely present in this patient?

- A. Decreased fecal calcium content
- B. Decreased fecal elastase
- C. Increased fecal calprotectin
- D. Increased fecal chymotrypsin
- E. Increased pancreatic bicarbonate secretion

Submit

https://t.me/USMLEWorldStep1
Show all

A 15-month-old boy is brought to the office by his parents for poor weight gain. The parents have also noticed frequent, large, foul-smelling stools. He was admitted to the hospital for a prolonged bout of bacterial pneumonia 6 months ago. Both parents are healthy and have no similar symptoms. The child was born at term at home. He is at the 20th percentile for length and 3rd percentile for weight. Vital signs are normal. On examination, the child appears thin and has a nontender, nondistended abdomen. Which of the following is most likely present in this patient?

- A. Decreased fecal calcium content (4%)
- ✓ B. Decreased fecal elastase (67%)
- C. Increased fecal calprotectin (4%)
- D. Increased fecal chymotrypsin (14%)
- E. Increased pancreatic bicarbonate secretion (9%)

Correct | 67% Answered correctly | 03 secs Time Spent | 2023 Version

Explanation

Features of cystic fibrosis	
Pathogenesis	• Autosomal recessive mutation (Δ**F508**) impairs CFTR function • Decreased water content causes **thick, viscous mucus**: ◦ Chronic airway obstruction

https://t.me/USMLEWorldStep1
Show all

Features of cystic fibrosis	
Pathogenesis	• Autosomal recessive mutation (**ΔF508**) impairs CFTR function • Decreased water content causes **thick, viscous mucus**: ◦ Chronic airway obstruction ◦ Gastrointestinal malabsorption
Clinical manifestations	• Chronic, productive cough • Recurrent **sinopulmonary infections** (eg, *Staphylococcus aureus*, *Pseudomonas aeruginosa*, & *Burkholderia cepacia* complex) • **Pancreatic insufficiency** • Male infertility (bilateral absence of vas deferens)
Diagnosis	• Elevated sweat chloride levels • Nasal potential difference measurements • Genetic testing for *CFTR* mutations
CFTR = cystic fibrosis transmembrane conductance regulator.	

This patient with failure to thrive, steatorrhea, and a hospitalization for pneumonia most likely has **cystic fibrosis** (CF). CF is an autosomal recessive disorder in which a defective chloride channel causes the accumulation of thick, dehydrated secretions in multiple organs.

In the **pancreas**, viscous mucus obstructs small ducts and acini, preventing **digestive enzymes** from reaching the intestinal lumen and leading to progressive pancreatic inflammation and fibrosis. This ultimately causes

https://t.me/USMLEWorldStep1
Show all

CFTR = cystic fibrosis transmembrane conductance regulator.

This patient with failure to thrive, steatorrhea, and a hospitalization for pneumonia most likely has **cystic fibrosis** (CF). CF is an autosomal recessive disorder in which a defective chloride channel causes the accumulation of thick, dehydrated secretions in multiple organs.

In the **pancreas**, viscous mucus obstructs small ducts and acini, preventing **digestive enzymes** from reaching the intestinal lumen and leading to progressive pancreatic inflammation and fibrosis. This ultimately causes **pancreatic insufficiency**, which may be present at birth in patients with CF and typically progresses throughout childhood. Signs of fat and protein malabsorption due to pancreatic insufficiency include **steatorrhea** (bulky, foul-smelling stools), **failure to thrive**, and fat-soluble vitamin deficiencies (A, D, E, and K).

Elastase is a pro-enzyme (ie, zymogen) produced by pancreatic acinar cells and activated by trypsin within the duodenal lumen. Because elastase production and secretion are decreased in patients with pancreatic insufficiency, fecal elastase levels are also decreased; the presence of **low fecal elastase** is an accurate and noninvasive method for diagnosing pancreatic insufficiency of any cause (eg, CF, chronic pancreatitis).

(Choice A) Dietary absorption of calcium is decreased in CF in part due to vitamin D deficiency, which leads to both hypocalcemia and increased calcium fecal concentration.

(Choice C) Calprotectin is a protein derived from neutrophils that is released into the stool of patients with inflammatory diarrhea (eg, ulcerative colitis, Crohn disease). Fecal calprotectin levels are not increased in CF.

(Choice D) Like elastase, chymotrypsin is a pancreatic digestive enzyme whose fecal concentration would be decreased (not increased) in patients with pancreatic insufficiency.

(Choice E) Bicarbonate is produced and secreted by the pancreas to neutralize gastric acid and raise duodenal pH. Because patients with pancreatic insufficiency have less bicarbonate secretion, duodenal pH will decrease. The low pH can inactivate digestive enzymes produced by the stomach and intestine, further impairing nutrient absorption.

Educational objective:

https://t.me/USMLEWorldStep1
Show all

thick, dehydrated secretions in multiple organs.

In the **pancreas**, viscous mucus obstructs small ducts and acini, preventing **digestive enzymes** from reaching the intestinal lumen and leading to progressive pancreatic inflammation and fibrosis. This ultimately causes **pancreatic insufficiency**, which may be present at birth in patients with CF and typically progresses throughout childhood. Signs of fat and protein malabsorption due to pancreatic insufficiency include **steatorrhea** (bulky, foul-smelling stools), **failure to thrive**, and fat-soluble vitamin deficiencies (A, D, E, and K).

Elastase is a pro-enzyme (ie, zymogen) produced by pancreatic acinar cells and activated by trypsin within the duodenal lumen. Because elastase production and secretion are decreased in patients with pancreatic insufficiency, fecal elastase levels are also decreased; the presence of **low fecal elastase** is an accurate and noninvasive method for diagnosing pancreatic insufficiency of any cause (eg, CF, chronic pancreatitis).

(Choice A) Dietary absorption of calcium is decreased in CF in part due to vitamin D deficiency, which leads to both hypocalcemia and increased calcium fecal concentration.

(Choice C) Calprotectin is a protein derived from neutrophils that is released into the stool of patients with inflammatory diarrhea (eg, ulcerative colitis, Crohn disease). Fecal calprotectin levels are not increased in CF.

(Choice D) Like elastase, chymotrypsin is a pancreatic digestive enzyme whose fecal concentration would be decreased (not increased) in patients with pancreatic insufficiency.

(Choice E) Bicarbonate is produced and secreted by the pancreas to neutralize gastric acid and raise duodenal pH. Because patients with pancreatic insufficiency have less bicarbonate secretion, duodenal pH will decrease. The low pH can inactivate digestive enzymes produced by the stomach and intestine, further impairing nutrient absorption.

Educational objective:
Pancreatic insufficiency is common in cystic fibrosis because thick, viscous secretions in the pancreas block digestive enzymes, leading to malabsorption (eg, steatorrhea, failure to thrive). The presence of low fecal elastase is an accurate and noninvasive method for diagnosing pancreatic insufficiency.

https://t.me/USMLEWorldStep1
Show all

- Elevated sweat chloride levels

Exhibit Display

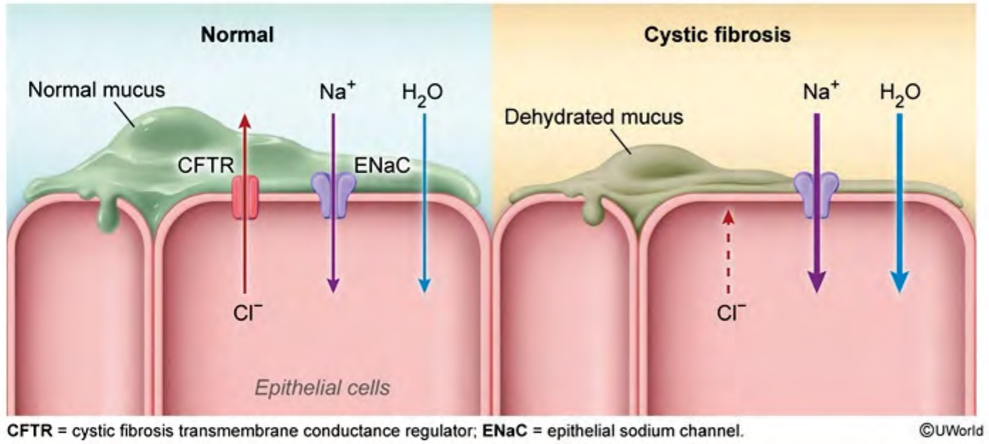

CFTR = cystic fibrosis transmembrane conductance regulator; **ENaC** = epithelial sodium channel. ©UWorld

Zoom In | Zoom Out | Reset | New | Existing | My Notebook

This p
(CF).
thick,

In the
intesti
pancr
childh
smelli

Elasta
duode
insuffi
noninv

(Choi
both h

(Choi
inflam

(Choi
decrea

(Choice E) Bicarbonate is produced and secreted by the pancreas to neutralize gastric acid and raise duodenal pH. Because patients with pancreatic insufficiency have less bicarbonate secretion, duodenal pH will decrease.

https://t.me/USMLEWorldStep1

- Elevated sweat chloride levels

Exhibit Display

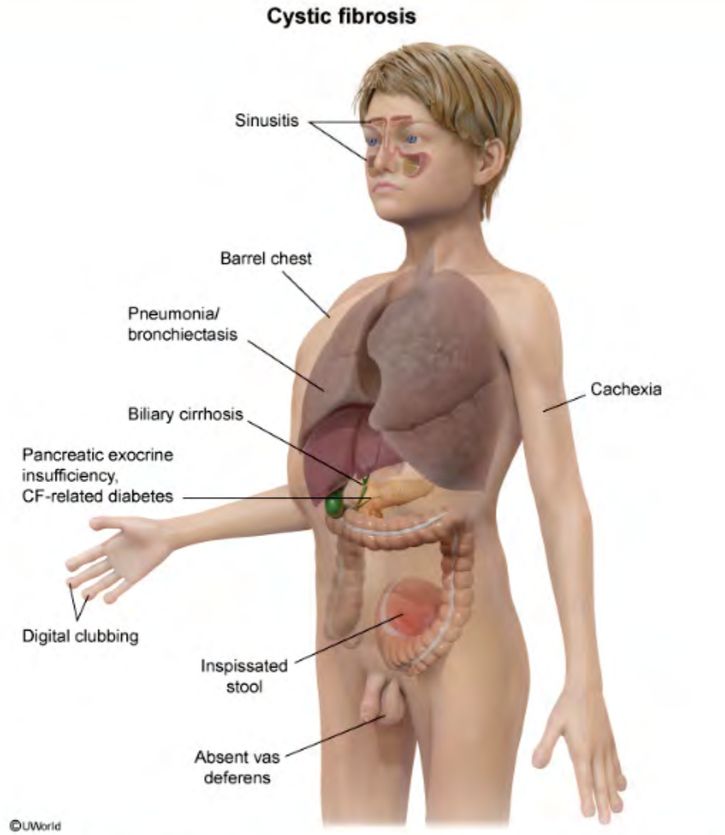

Zoom In | Zoom Out | Reset | New | Existing | My Notebook

This p
(CF).
thick,

In the
intesti
pancr
childh
smelli

Elasta
duode
insuffi
noninv

(Choi
both h

(Choi
inflam

(Choi
decrea

(Choice E) Bicarbonate is produced and secreted by the pancreas to neutralize gastric acid and raise duodenal pH. Because patients with pancreatic insufficiency have less bicarbonate secretion, duodenal pH will decrease.

https://t.me/USMLEWorldStep1
Show all

- Elevated sweat chloride levels

Exhibit Display

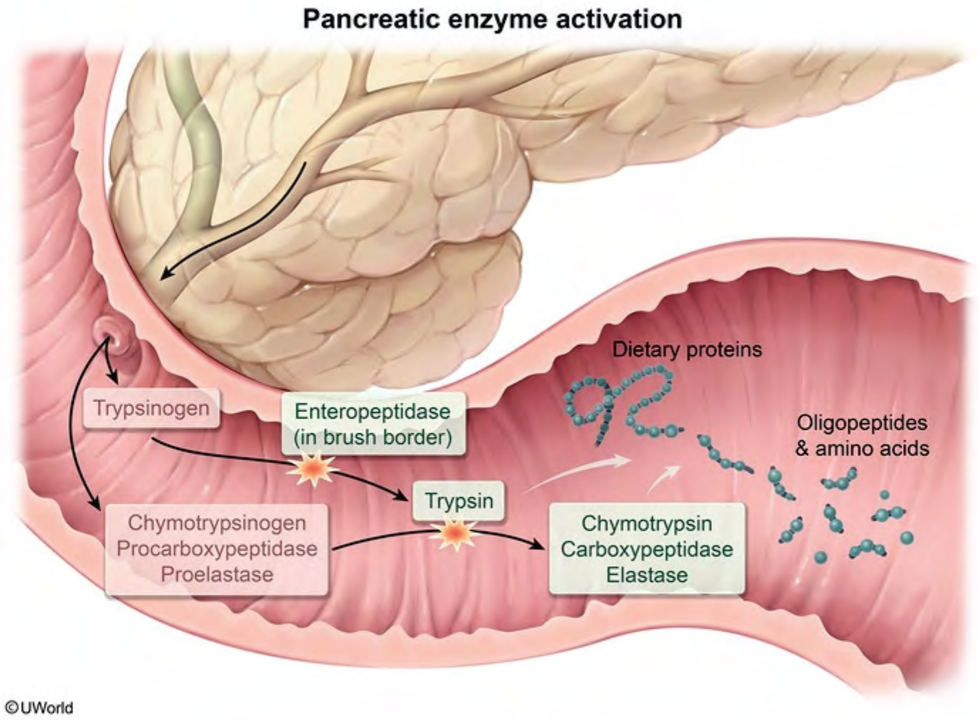

Zoom In | Zoom Out | Reset | New | Existing | My Notebook

This p
(CF).
thick,

In the
intesti
pancr
childh
smelli

Elasta
duode
insuffi
noninv

(Choi
both h

(Choi
inflam

(Choi
decrea

(Choice E) Bicarbonate is produced and secreted by the pancreas to neutralize gastric acid and raise duodenal pH. Because patients with pancreatic insufficiency have less bicarbonate secretion, duodenal pH will decrease.

https://t.me/USMLEWorldStep1
Show all

A 56-year-old man comes to the physician complaining of early satiety, nausea, and vague epigastric pain for the past 4 months. He has a 36-pack-year smoking history and admits to drinking alcohol daily for the past 15 years. On physical examination, the patient appears thin and cachectic. Palpation of his abdomen reveals splenomegaly. Abdominal CT scan shows a large irregular mass extending posteriorly from the greater curvature of the stomach, impinging on the splenic artery and vein as they pass below. Tissues supplied by which of the following arteries would most likely be affected by compression of the splenic artery?

- A. Gastroduodenal
- B. Left gastroepiploic
- C. Right gastric
- D. Right gastroepiploic
- E. Short gastric

Submit

https://t.me/USMLEWorldStep1
Show all

A 56-year-old man comes to the physician complaining of early satiety, nausea, and vague epigastric pain for the past 4 months. He has a 36-pack-year smoking history and admits to drinking alcohol daily for the past 15 years. On physical examination, the patient appears thin and cachectic. Palpation of his abdomen reveals splenomegaly. Abdominal CT scan shows a large irregular mass extending posteriorly from the greater curvature of the stomach, impinging on the splenic artery and vein as they pass below. Tissues supplied by which of the following arteries would most likely be affected by compression of the splenic artery?

- A. Gastroduodenal (4%)
- ✗ B. Left gastroepiploic (31%)
- C. Right gastric (4%)
- D. Right gastroepiploic (5%)
- ✓ E. Short gastric (54%)

Incorrect
Correct answer
E

54%
Answered correctly

03 secs
Time Spent

2023
Version

Explanation

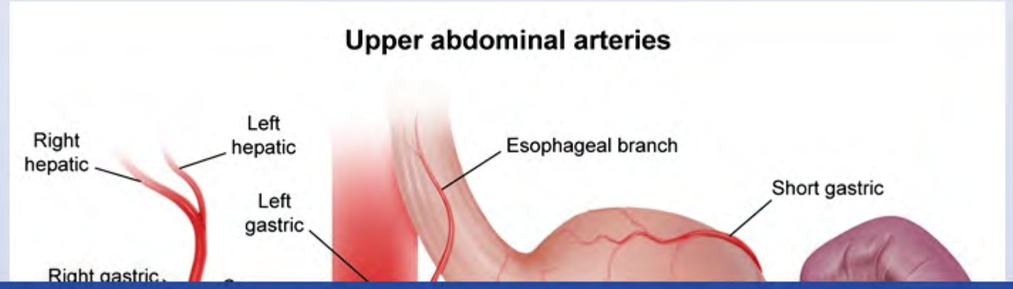

https://t.me/USMLEWorldStep1
Show all

A 56-year-old man comes to the physician complaining of early satiety, nausea, and vague epigastric pain for the past 4
On ph
splenc
of the
followi

Inco
Corre
E

Expl

Exhibit Display

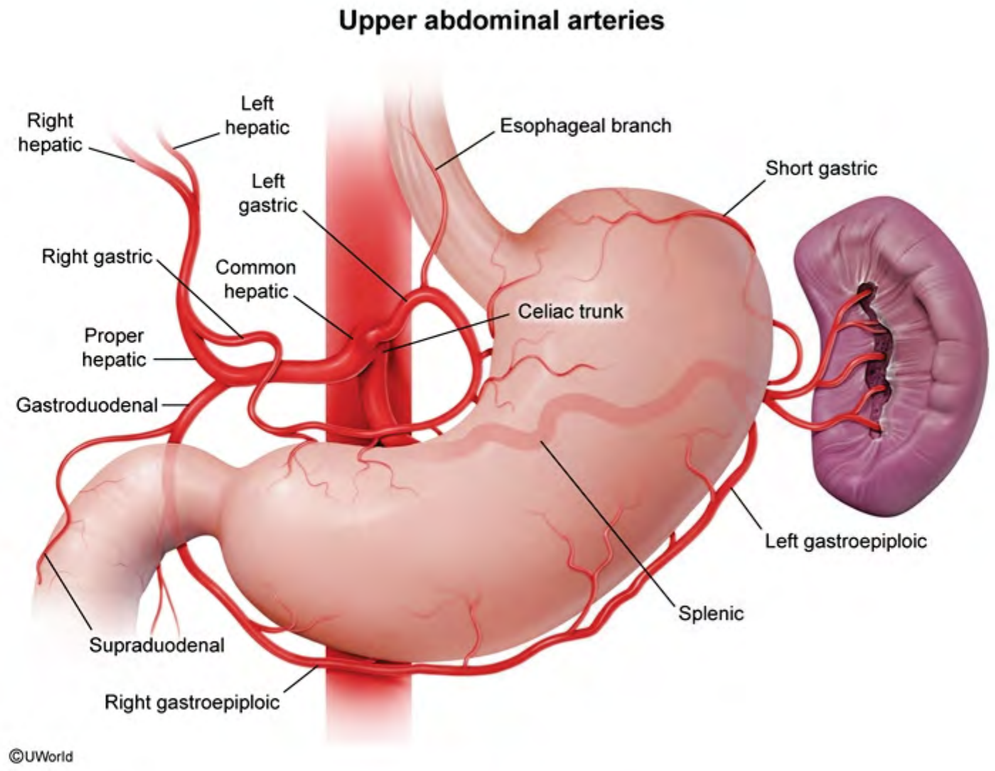

Zoom In | Zoom Out | Reset | New | Existing | My Notebook

https://t.me/USMLEWorldStep1

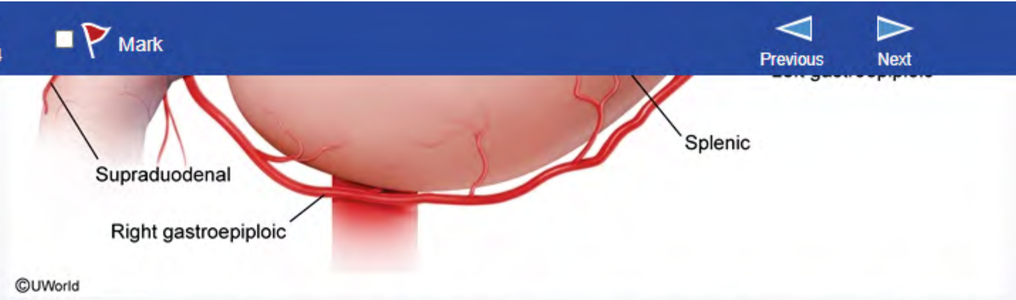

The splenic artery originates from the celiac artery and courses superior to the pancreas. Along its route, it gives off several branches to the stomach and pancreas before reaching the spleen. The short gastric arteries and the left gastroepiploic artery arise from the splenic artery immediately after it passes the greater curvature of the stomach. The short gastric arteries have very poor anastomoses, and the tissue supplied by them is vulnerable to ischemic injury following splenic artery blockage. In contrast, tissues supplied by the left gastroepiploic artery can be alternatively supplemented by its strong anastomotic connection with the right gastroepiploic artery **(Choice B)**.

(Choice A) The gastroduodenal artery supplies blood to the pylorus and the proximal part of the duodenum. It arises from the common hepatic artery.

(Choice C) The right gastric artery supplies blood to the distal lesser curvature of the stomach. It arises from the proper hepatic artery.

(Choice D) The right gastroepiploic artery arises from the gastroduodenal artery and perfuses the distal greater curvature of the stomach. It forms an anastomosis with the left gastroepiploic artery.

Educational objective:
The splenic artery originates from the **celiac artery** and gives off several branches to the stomach and pancreas (pancreatic, short gastric, and left gastroepiploic arteries) before finally reaching the spleen. Due to poor anastomoses, the gastric tissue supplied by the short gastric arteries is vulnerable to ischemic injury following splenic artery blockage.

Anatomy	Gastrointestinal & Nutrition	Gastrointestinal blood supply
Subject	System	Topic

https://t.me/USMLEWorldStep1
Show all

Exhibit Display

Splenic artery branches	
Branches	**Distribution**
Pancreatic branches	Run posterior to the upper border of the pancreas, supplying its body & tail
Short gastric branches	Supply the upper part of the greater curvature of the stomach
Left gastroepiploic artery	Supply the middle part of the greater curvature of the stomach

New | Existing | My Notebook

The sp
off sev
left ga
stoma
ischen
be alte

(Choi
arises

(Choi
proper

(Choi
curvat

Educa
The sp
(pancr
anasto
splenic

Anatomy
Subject System Topic

https://t.me/USMLEWorldStep1

A 74-year-old man comes to the office due to chronic constipation. Bowel movements occur once every 3 days and are hard and pellet-like. The patient frequently strains when he tries to defecate and never feels completely evacuated. The constipation is occasionally so severe that he uses his fingers to remove stool from the anorectal vault. Medical history is significant for Parkinson disease, for which he takes carbidopa-levodopa. Vital signs are unremarkable. A resting tremor is present on physical examination. The abdomen is distended but nontender to palpation. This patient's condition is most likely due to inadequate relaxation of which of the following muscles during defecation?

- A. Bulbospongiosus
- B. Obturator
- C. Piriformis
- D. Puborectalis
- E. Rectus abdominis

Submit

https://t.me/USMLEWorldStep1
Show all

A 74-year-old man comes to the office due to chronic constipation. Bowel movements occur once every 3 days and are hard and pellet-like. The patient frequently strains when he tries to defecate and never feels completely evacuated. The constipation is occasionally so severe that he uses his fingers to remove stool from the anorectal vault. Medical history is significant for Parkinson disease, for which he takes carbidopa-levodopa. Vital signs are unremarkable. A resting tremor is present on physical examination. The abdomen is distended but nontender to palpation. This patient's condition is most likely due to inadequate relaxation of which of the following muscles during defecation?

- A. Bulbospongiosus (6%)
- ✗ B. Obturator (2%)
- C. Piriformis (5%)
- ✓ D. Puborectalis (80%)
- E. Rectus abdominis (5%)

Incorrect
Correct answer
D

80%
Answered correctly

04 secs
Time Spent

2023
Version

Explanation

Stool continence is largely maintained by tonic contraction of the internal and external anal sphincter and the puborectalis muscle, which forms a muscular sling around the rectum and squeezes it into a narrow angle to prevent stool leakage. **Defecation** requires the coordinated relaxation of these muscles, which occurs as follows:

1. Distension of the rectal vault activates mechanoreceptors that cause involuntary relaxation of the internal anal sphincter (rectosphincteric reflex) and an urge to defecate.

https://t.me/USMLEWorldStep1
Show all

Stool continence is largely maintained by tonic contraction of the internal and external anal sphincter and the puborectalis muscle, which forms a muscular sling around the rectum and squeezes it into a narrow angle to prevent stool leakage. **Defecation** requires the coordinated relaxation of these muscles, which occurs as follows:

1. Distension of the rectal vault activates mechanoreceptors that cause involuntary relaxation of the internal anal sphincter (rectosphincteric reflex) and an urge to defecate.
2. The puborectalis muscle and external anal sphincter are under voluntary control; when defecation is desired, the muscles relax and the rectum contracts, expelling feces.
3. The abdominal muscles contract to increase the pressure gradient of the rectum and aid in the rapid expulsion of feces.

If the internal or external anal sphincter or, more commonly, the **puborectalis muscle fails to relax**, stool remains in the rectal vault despite attempts to initiate bowel movements **(dyssynergia)**, resulting in chronic **constipation**. Patients often strain for a long time only to pass small amounts of stool, and manual disimpaction may be required. Dyssynergic defecation is usually considered a functional disorder and occurs more commonly in the elderly; however, it can occur with certain neurologic disorders (eg, Parkinson disease, multiple sclerosis) or trauma.

(Choice A) The bulbospongiosus is a superficial perineal muscle that enables penile erection and ejaculation in men and facilitates both vaginal canal closure and orgasm in women. Its dysfunction would lead to sexual impairment but not defecatory dysfunction.

(Choices B and C) The obturator internus and externus and the piriformis contribute to lateral hip rotation. Dysfunction in these muscles would result in motor impairment and gait abnormalities, not defecatory dysfunction.

(Choice E) The rectus abdominis consists of 2 large, paired muscles that run vertically along the anterior abdominal wall. Contraction of abdominal muscles increases the pressure gradient of the rectum and aids in the rapid expulsion of feces; failure of this muscle to relax would not result in constipation.

https://t.me/USMLEWorldStep1
Show all

2. The puborectalis muscle and external anal sphincter are under voluntary control; when defecation is desired, the muscles relax and the rectum contracts, expelling feces.

3. The abdominal muscles contract to increase the pressure gradient of the rectum and aid in the rapid expulsion of feces.

If the internal or external anal sphincter or, more commonly, the **puborectalis muscle fails to relax**, stool remains in the rectal vault despite attempts to initiate bowel movements **(dyssynergia)**, resulting in chronic **constipation**. Patients often strain for a long time only to pass small amounts of stool, and manual disimpaction may be required. Dyssynergic defecation is usually considered a functional disorder and occurs more commonly in the elderly; however, it can occur with certain neurologic disorders (eg, Parkinson disease, multiple sclerosis) or trauma.

(Choice A) The bulbospongiosus is a superficial perineal muscle that enables penile erection and ejaculation in men and facilitates both vaginal canal closure and orgasm in women. Its dysfunction would lead to sexual impairment but not defecatory dysfunction.

(Choices B and C) The obturator internus and externus and the piriformis contribute to lateral hip rotation. Dysfunction in these muscles would result in motor impairment and gait abnormalities, not defecatory dysfunction.

(Choice E) The rectus abdominis consists of 2 large, paired muscles that run vertically along the anterior abdominal wall. Contraction of abdominal muscles increases the pressure gradient of the rectum and aids in the rapid expulsion of feces; failure of this muscle to relax would not result in constipation.

Educational objective:
Dyssynergic defecation occurs when the puborectalis muscle or the internal or external anal sphincter fails to relax during defecation, leading to chronic constipation. Dyssynergic defecation is usually considered a functional disorder and occurs more commonly in the elderly but may also occur with certain neurologic disorders (eg, Parkinson disease, multiple sclerosis) or trauma.

References

https://t.me/USMLEWorldStep1
Show all

A 2-year-old girl is brought to the emergency department with intermittent pain in the abdomen that began several hours ago. The patient also had a bowel movement that appeared tinged with blood. Ultrasound shows an area along the ileum in which the proximal small intestine is telescoped into the distal small intestine. Reduction via enema is unsuccessful, and the patient undergoes laparotomy with resultant resection of the involved intestine. The pathologic finding at the lead point is shown in the exhibit. Which of the following is the most likely underlying diagnosis in this patient?

- A. Burkitt lymphoma
- B. Henoch-Schönlein purpura
- C. Inflammatory bowel disease
- D. Meckel diverticulum
- E. Pseudomembranous colitis

Submit

https://t.me/USMLEWorldStep1
Show all

A 2-year-old girl is brought to the emergency department with intermittent pain in the abdomen that began several hours
along
enema
The pa
diagnc

Sub

Exhibit Display

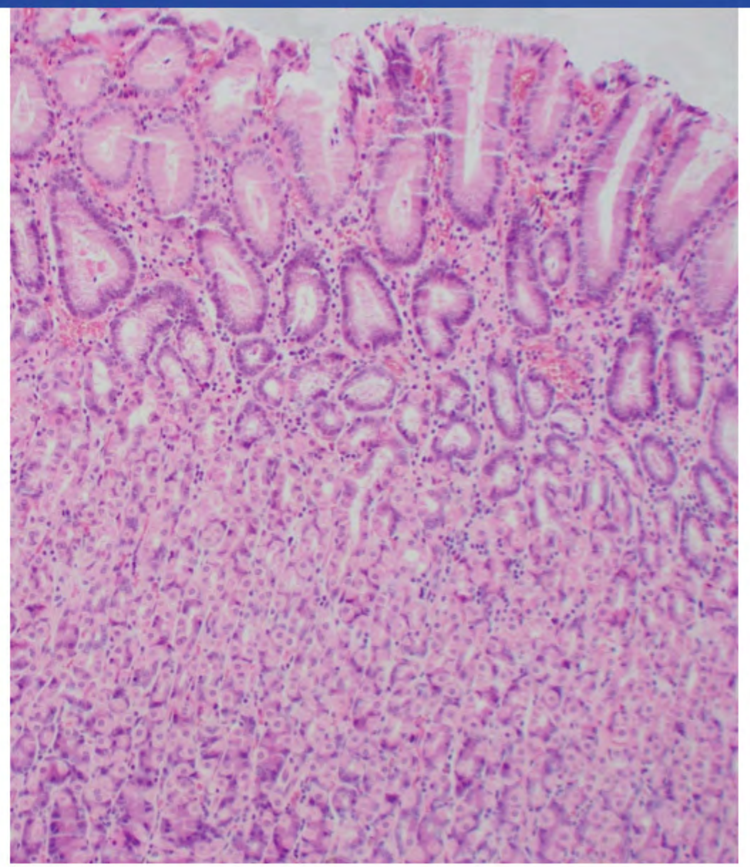

Zoom In Zoom Out Reset New | Existing My Notebook

https://t.me/USMLEWorldStep1

A 2-year-old girl is brought to the emergency department with intermittent pain in the abdomen that began several hours ago. The patient also had a bowel movement that appeared tinged with blood. Ultrasound shows an area along the ileum in which the proximal small intestine is telescoped into the distal small intestine. Reduction via enema is unsuccessful, and the patient undergoes laparotomy with resultant resection of the involved intestine. The pathologic finding at the lead point is shown in the exhibit. Which of the following is the most likely underlying diagnosis in this patient?

- A. Burkitt lymphoma (5%)
- B. Henoch-Schönlein purpura (10%)
- C. Inflammatory bowel disease (13%)
- ✓ D. Meckel diverticulum (64%)
- E. Pseudomembranous colitis (5%)

Correct

64% Answered correctly

25 secs Time Spent

2023 Version

Explanation

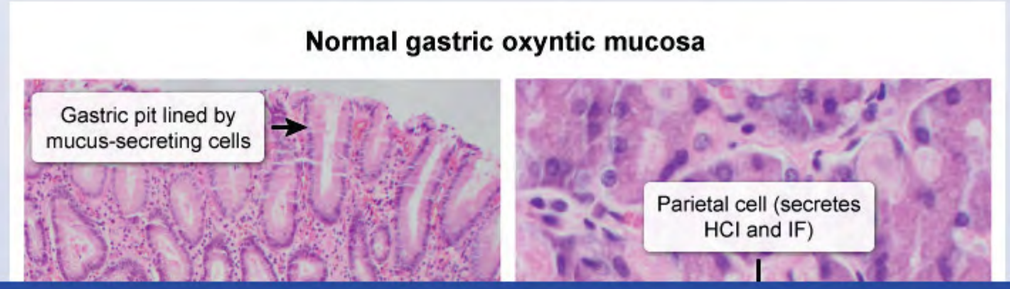

https://t.me/USMLEWorldStep1
Show all

A 2-year-old girl is brought to the emergency department with intermittent pain in the abdomen that began several hours along enema The pa diagnc

Cor

Expl

Exhibit Display

Normal gastric oxyntic mucosa

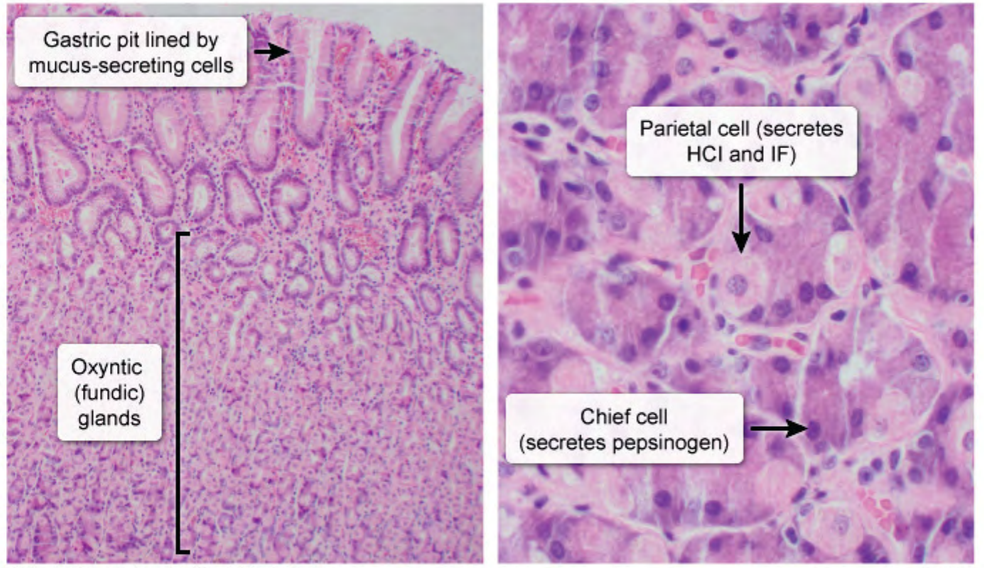

HCl = hydrochloric acid; **IF** = intrinsic factor.

©UWorld

Zoom In | Zoom Out | Reset | New | Existing | My Notebook

HCl and IF)

https://t.me/USMLEWorldStep1

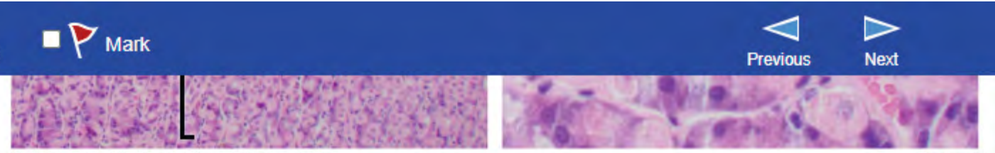

HCl = hydrochloric acid; **IF** = intrinsic factor.

©UWorld

Intussusception occurs when a proximal segment of intestine telescopes into a distal segment, causing episodes of severe abdominal pain. Progressive intestinal obstruction can also lead to bowel wall ischemia and bloody, currant jelly stools. Most cases are idiopathic in young children; however, 25% have a **pathologic lead point** for bowel invagination. The lead point is generally an anatomic abnormality (eg, polyp, mass) within the intestinal lumen that is entrapped during peristalsis and forced into distal bowel.

Meckel diverticulum is the **most common** pathologic lead point for intussusception and is a congenital anomaly of the gastrointestinal (GI) tract caused by incomplete obliteration of the vitelline duct. Most Meckel diverticula are clinically silent; symptomatic diverticula often contain **ectopic gastric mucosa**, which causes ulceration and painless lower GI bleeding. Patients can also have complications such as diverticulitis, bowel obstruction, perforation, and intussusception.

In some cases, Meckel diverticulum may be identified incidentally during laparotomy based on histologic evidence of gastric tissue within the small intestine. Distinct features of gastric mucosa include gastric pits and glands with chief cells and parietal cells. Meckel scan is a nuclear study that can be used to detect the presence of ectopic gastric mucosa and diagnose Meckel diverticulum.

(Choice A) Burkitt lymphoma can serve as a pathologic lead point for intussusception, but microscopy would show a lymphoid infiltrate in a starry sky pattern.

(Choice B) Intestinal edema and hemorrhage associated with Henoch-Schönlein purpura can trigger intussusception; however, leukocytoclastic vasculitis (perivascular neutrophils with fibrin deposits and nuclear debris) would be expected on microscopy.

(Choices C and E) Inflammatory bowel disease (eg, Crohn disease) and pseudomembranous colitis (ie, *Clostridioides difficile* infection) cause GI tract inflammation that could trigger intussusception, but the incidence is rare, particularly in a child age 2. In addition, microscopic findings of Crohn disease include transmural

https://t.me/USMLEWorldStep1
Show all

lumen that is entrapped during peristalsis and forced into distal bowel.

Meckel diverticulum is the **most common** pathologic lead point for intussusception and is a congenital anomaly of the gastrointestinal (GI) tract caused by incomplete obliteration of the vitelline duct. Most Meckel diverticula are clinically silent; symptomatic diverticula often contain **ectopic gastric mucosa**, which causes ulceration and painless lower GI bleeding. Patients can also have complications such as diverticulitis, bowel obstruction, perforation, and intussusception.

In some cases, Meckel diverticulum may be identified incidentally during laparotomy based on histologic evidence of gastric tissue within the small intestine. Distinct features of gastric mucosa include gastric pits and glands with chief cells and parietal cells. Meckel scan is a nuclear study that can be used to detect the presence of ectopic gastric mucosa and diagnose Meckel diverticulum.

(Choice A) Burkitt lymphoma can serve as a pathologic lead point for intussusception, but microscopy would show a lymphoid infiltrate in a starry sky pattern.

(Choice B) Intestinal edema and hemorrhage associated with Henoch-Schönlein purpura can trigger intussusception; however, leukocytoclastic vasculitis (perivascular neutrophils with fibrin deposits and nuclear debris) would be expected on microscopy.

(Choices C and E) Inflammatory bowel disease (eg, Crohn disease) and pseudomembranous colitis (ie, *Clostridioides difficile* infection) cause GI tract inflammation that could trigger intussusception, but the incidence is rare, particularly in a child age 2. In addition, microscopic findings of Crohn disease include transmural inflammation with noncaseating granulomas, and pseudomembranous colitis is characterized by pseudomembranes composed of fibrin, neutrophils, and cellular debris.

Educational objective:
Meckel diverticulum is the most common pathologic lead point for intussusception, a condition in which a portion of the intestine telescopes into itself. Meckel diverticula frequently contain ectopic gastric mucosa, which can aid in diagnosis.

https://t.me/USMLEWorldStep1
Show all

Exhibit Display

Intussusception

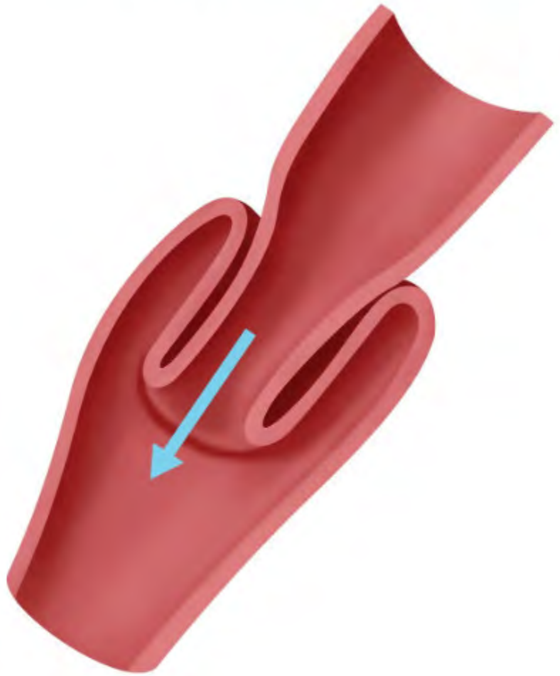

©UWorld

Zoom In | Zoom Out | Reset | New | Existing | My Notebook

Intuss
of sev
curran
bowel
lumen

Mecke
of the
clinica
painles
perfora

In som
of gas
chief c
gastric

(Choi
a lymp

(Choi
intussu
debris

(Choi
Clostri
rare, particularly in a child age 2. In addition, microscopic findings of Crohn disease include transmural

https://t.me/USMLEWorldStep1
Show all

Intuss
of sev
curran
bowel
lumen

Mecke
of the
clinica
painle
perfor

In som
of gas
chief c
gastric

(Choic
a lymp

(Choic
intussu
debris

(Choic
Clostri
rare, p

Exhibit Display

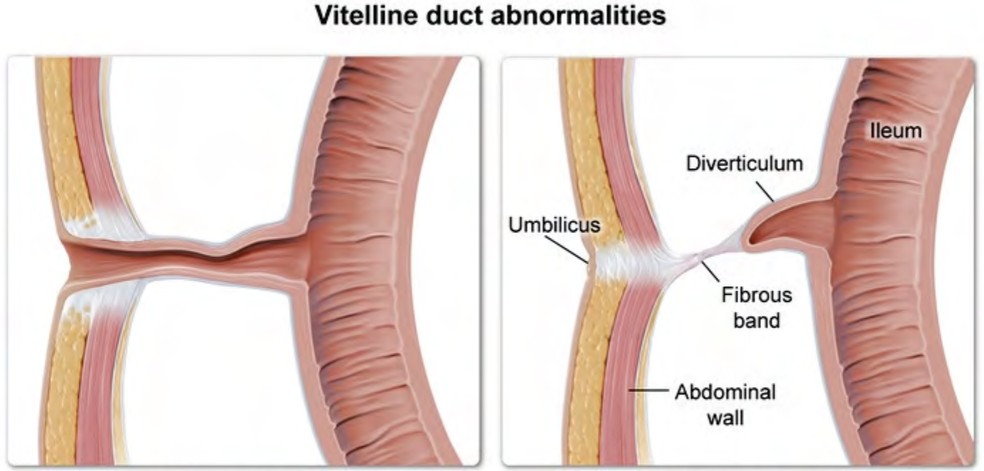

Zoom In | Zoom Out | Reset | New | Existing | My Notebook

https://t.me/USMLEWorldStep1

Exhibit Display

Normal small intestine

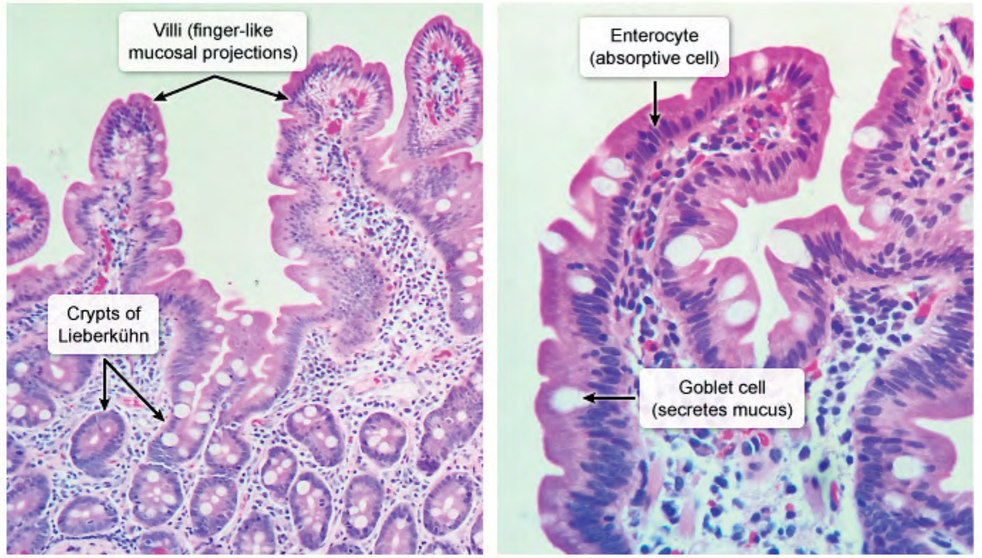

©UWorld

Zoom In Zoom Out Reset New | Existing My Notebook

Intuss
of sev
curran
bowel
lumen

Mecke
of the
clinica
painle
perfor

In som
of gas
chief c
gastric

(Choi
a lymp

(Choi
intussu
debris

(Choi
Clostri
rare, particularly in a child age 2. In addition, microscopic findings of Crohn disease include transmural

https://t.me/USMLEWorldStep1

Exhibit Display

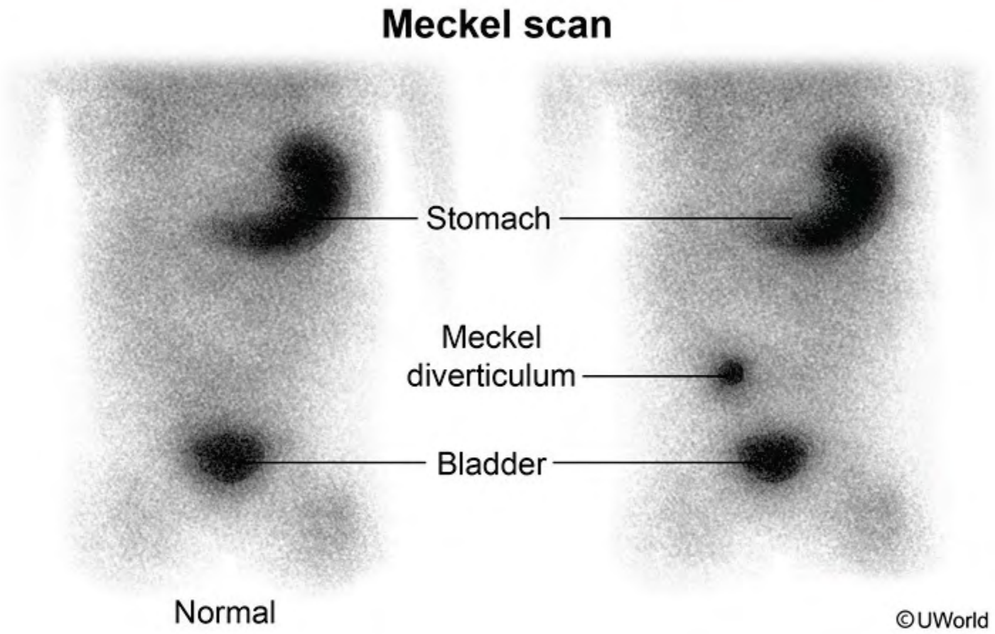

Zoom In | Zoom Out | Reset | New | Existing | My Notebook

Intuss
of sev
curran
bowel
lumen

Mecke
of the
clinica
painle
perfor

In som
of gas
chief c
gastric

(Choic
a lymp

(Choic
intussu
debris

(Choic
Clostri
rare, p

https://t.me/USMLEWorldStep1
Show all

Exhibit Display

Burkitt lymphoma

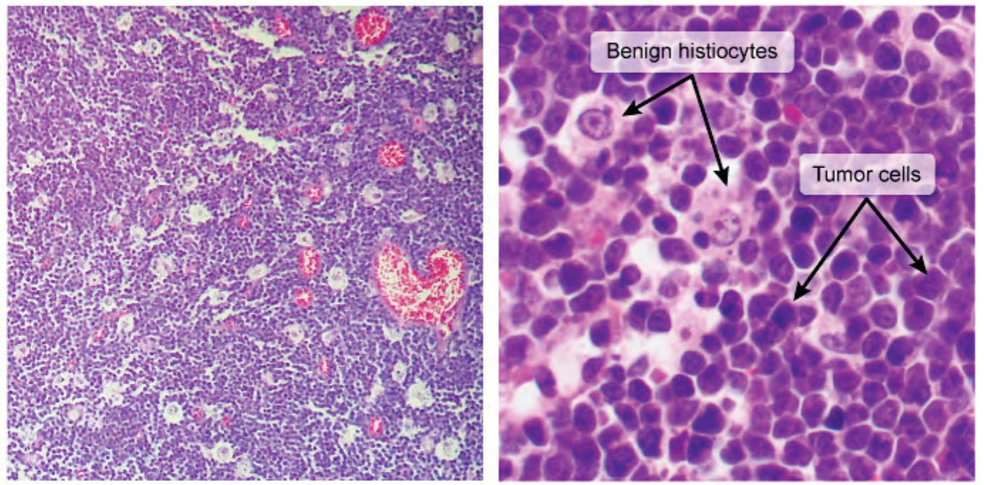

Lighter histiocytes in a field of darker tumor cells; "starry sky" appearance

©UWorld

Zoom In | Zoom Out | Reset | New | Existing | My Notebook

Intuss
of sev
curran
bowel
lumen

Mecke
of the
clinica
painle
perfor

In som
of gas
chief c
gastric

(Choi
a lymp

(Choi
intussu
debris

(Choi
Clostri
rare, particularly in a child age 2. In addition, microscopic findings of Crohn disease include transmural

https://t.me/USMLEWorldStep1

of severe abdominal pain. Progressive intestinal obstruction can also lead to bowel wall ischemia and bloody,

curran

bowel

lumen

Mecke

of the

clinica

painle

perfor

In som

of gas

chief c

gastric

(Choi

a lymp

(Choi

intussu

debris

(Choi

Clostri

rare, p

inflam

pseud

Educational objective:

Meckel diverticulum is the most common pathologic lead point for intussusception, a condition in which a portion of

Exhibit Display

Leukocytoclastic vasculitis

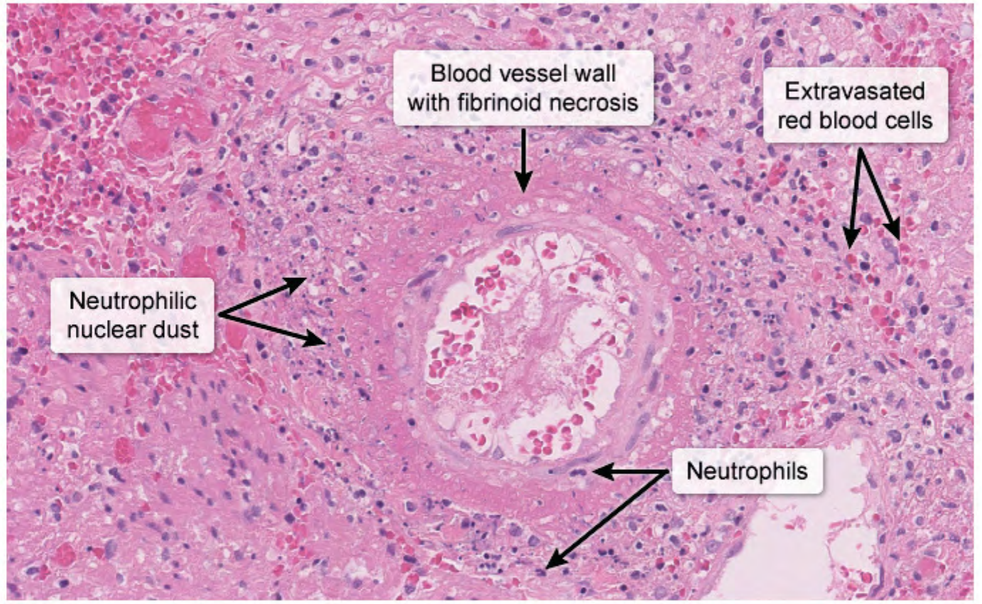

©UWorld

Zoom In Zoom Out Reset New | Existing My Notebook

https://t.me/USMLEWorldStep1

of severe abdominal pain. Progressive intestinal obstruction can also lead to bowel wall ischemia and bloody,

curran

bowel

lumen

Mecke

of the

clinica

painle

perfor

In som

of gas

chief c

gastric

(Choi

a lymp

(Choi

intussu

debris

(Choi

Clostri

rare, p

inflam

pseud

Educa

Exhibit Display

Crohn disease

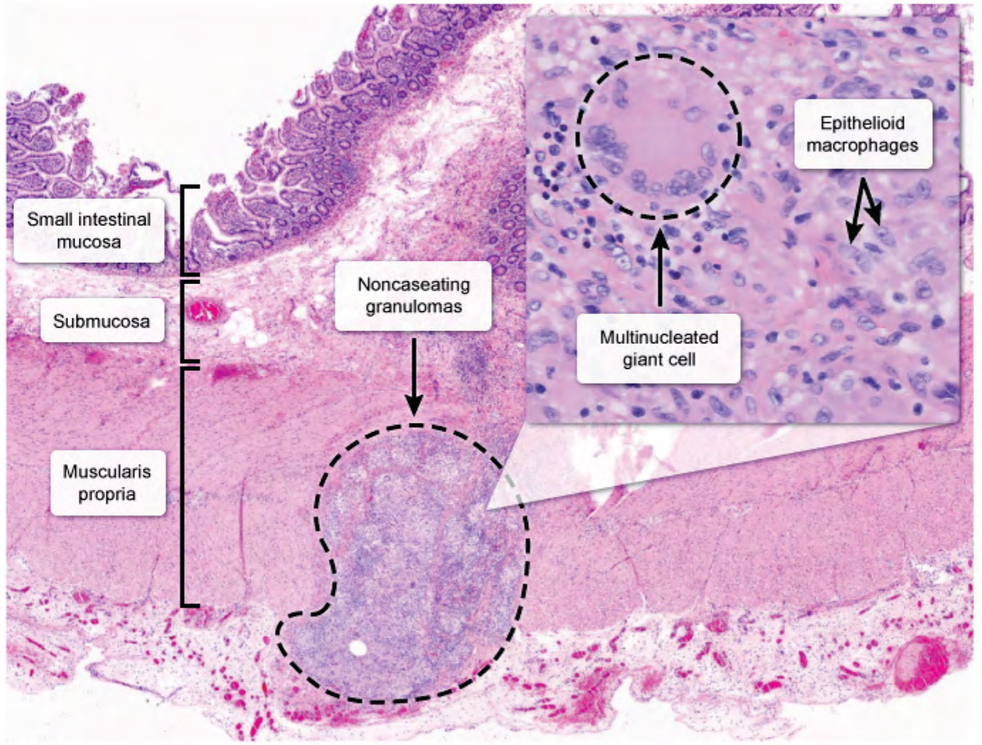

©UWorld

Zoom In | Zoom Out | Reset | New | Existing | My Notebook

https://t.me/USMLEWorldStep1

lumen that is entrapped during peristalsis and forced into distal bowel.

Mecke
of the
clinica
painle
perfor

In som
of gas
chief c
gastric

(Choic
a lymp

(Choic
intussu
debris

(Choic
Clostri
rare, p
inflam
pseud

Educa
Mecke
the int
diagnosis.

Exhibit Display

Pseudomembranous colitis

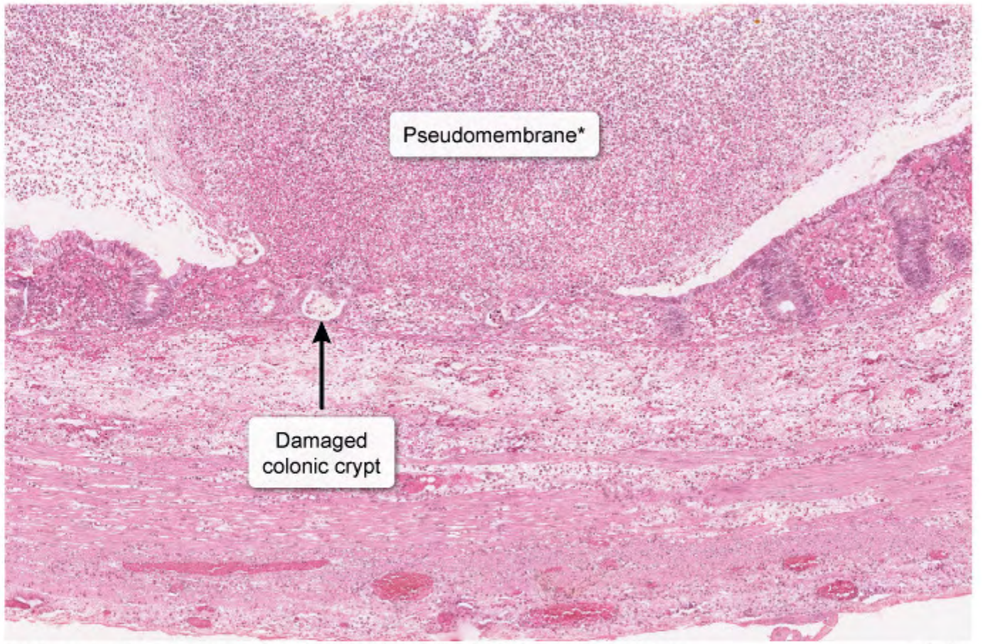

*Fibrin, neutrophils, and necrotic epithelium associated with *Clostridioidies difficile* infection.

©UWorld

Zoom In | Zoom Out | Reset | New | Existing | My Notebook

https://t.me/USMLEWorldStep1

A 34-year-old man is evaluated due to elevated liver aminotransferases. The patient has no chronic medical conditions but has a history of injection drug use. Family history is notable for liver cirrhosis in his mother. Ultrasonography-guided liver biopsy is performed. Histopathology demonstrates marked panlobular mononuclear cell infiltration that spans adjacent lobules. Intensely eosinophilic round bodies are occasionally seen scattered among the hepatic parenchyma. Which of the following is the most likely cause of the latter histopathologic finding in this patient?

- A. Coagulative necrosis due to a toxin
- B. Cytotoxic T-cell–mediated apoptosis
- C. Intracellular pigment accumulation
- D. Intracytoplasmic cytokeratin deposition
- E. Small foci of fibrinoid necrosis
- F. Stellate cell activation into myofibroblast

Submit

https://t.me/USMLEWorldStep1
Show all

A 34-year-old man is evaluated due to elevated liver aminotransferases. The patient has no chronic medical conditions but has a history of injection drug use. Family history is notable for liver cirrhosis in his mother. Ultrasonography-guided liver biopsy is performed. Histopathology demonstrates marked panlobular mononuclear cell infiltration that spans adjacent lobules. Intensely eosinophilic round bodies are occasionally seen scattered among the hepatic parenchyma. Which of the following is the most likely cause of the latter histopathologic finding in this patient?

- A. Coagulative necrosis due to a toxin (6%)
- ✓ B. Cytotoxic T-cell–mediated apoptosis (38%)
- C. Intracellular pigment accumulation (7%)
- D. Intracytoplasmic cytokeratin deposition (17%)
- E. Small foci of fibrinoid necrosis (9%)
- F. Stellate cell activation into myofibroblast (20%)

Correct | 38% Answered correctly | 03 secs Time Spent | 2023 Version

Explanation

This patient with a history of intravenous drug use likely has elevated aminotransferases due to **acute viral hepatitis**, which is characterized by hepatocyte damage (eg, cell injury, cell death) and inflammation.

Most cases are marked by significant **panlobular lymphocytic inflammation** (ie, involving the entire lobule), which develops in response to the viral antigens. To control the infection, **cytotoxic T cells** trigger apoptosis of infected hepatocytes by binding death receptors (eg, Fas) on the plasma membrane and by secreting cytotoxic

https://t.me/USMLEWorldStep1
Show all

This patient with a history of intravenous drug use likely has elevated aminotransferases due to **acute viral hepatitis**, which is characterized by hepatocyte damage (eg, cell injury, cell death) and inflammation.

Most cases are marked by significant **panlobular lymphocytic inflammation** (ie, involving the entire lobule), which develops in response to the viral antigens. To control the infection, **cytotoxic T cells** trigger apoptosis of infected hepatocytes by binding death receptors (eg, Fas) on the plasma membrane and by secreting cytotoxic mediators (eg, perforins, granzymes). As a result, a cascade of caspase enzymes breaks down hepatocyte proteins and DNA, leading to cell shrinkage, chromatin condensation and fragmentation, and budding apoptotic bodies (ie, membrane-bound cellular fragments).

In liver biopsy, these apoptotic hepatocytes (ie, **Councilman bodies**, acidophil bodies) have a small, round, intensely pink (ie, eosinophilic) appearance on hematoxylin and eosin staining and may contain pyknotic nuclei or nuclear fragments. They are typically promptly phagocytosed by Kupffer cells.

(Choice A) Toxin-mediated hepatic injury (eg, due to acetaminophen) often results in centrilobular hepatocyte necrosis (ie, centered around central veins) due to oxidative damage.

(Choice C) Hemochromatosis is characterized by the deposition of iron within hepatocytes, which appears as yellow to brown granules that can be highlighted with Prussian blue stain.

(Choice D) Mallory bodies, damaged cytokeratin filaments that appear as eosinophilic hepatocellular inclusions, often arise in alcoholic liver disease. Alcohol-mediated liver injury is associated with fat deposition in hepatocytes, particularly in the centrilobular region.

(Choice E) Aschoff bodies, seen in the myocardium of patients with rheumatic heart disease, are small areas of granulomatous inflammation that may contain central fibrinoid necrosis. They are not seen in the liver.

(Choice F) Stellate cells, which reside in the hepatic perisinusoidal space, can transdifferentiate into myofibroblasts in response to hepatocyte injury and deposit collagen, resulting in liver fibrosis. Fibrotic bands may develop in chronic viral hepatitis, which is characterized by persistent hepatocyte injury and predominantly portal

https://t.me/USMLEWorldStep1
Show all

mediators (eg, perforins, granzymes). As a result, a cascade of caspase enzymes breaks down hepatocyte proteins and DNA, leading to cell shrinkage, chromatin condensation and fragmentation, and budding apoptotic bodies (ie, membrane-bound cellular fragments).

In liver biopsy, these apoptotic hepatocytes (ie, **Councilman bodies**, acidophil bodies) have a small, round, intensely pink (ie, eosinophilic) appearance on hematoxylin and eosin staining and may contain pyknotic nuclei or nuclear fragments. They are typically promptly phagocytosed by Kupffer cells.

(Choice A) Toxin-mediated hepatic injury (eg, due to acetaminophen) often results in centrilobular hepatocyte necrosis (ie, centered around central veins) due to oxidative damage.

(Choice C) Hemochromatosis is characterized by the deposition of iron within hepatocytes, which appears as yellow to brown granules that can be highlighted with Prussian blue stain.

(Choice D) Mallory bodies, damaged cytokeratin filaments that appear as eosinophilic hepatocellular inclusions, often arise in alcoholic liver disease. Alcohol-mediated liver injury is associated with fat deposition in hepatocytes, particularly in the centrilobular region.

(Choice E) Aschoff bodies, seen in the myocardium of patients with rheumatic heart disease, are small areas of granulomatous inflammation that may contain central fibrinoid necrosis. They are not seen in the liver.

(Choice F) Stellate cells, which reside in the hepatic perisinusoidal space, can transdifferentiate into myofibroblasts in response to hepatocyte injury and deposit collagen, resulting in liver fibrosis. Fibrotic bands may develop in chronic viral hepatitis, which is characterized by persistent hepatocyte injury and predominantly portal tract–based lymphocytic inflammation.

Educational objective:
Intravenous drug use is a risk factor for acute viral hepatitis, which is marked by panlobular inflammation, hepatocyte injury, and cell death. To control the infection, cytotoxic T-cell–mediated signals cause hepatocyte apoptosis, which is characterized microscopically by Councilman bodies (ie, round, intensely eosinophilic bodies).

Pathology Gastrointestinal & Nutrition Hepatitis a

https://t.me/USMLEWorldStep1
Show all

This p
hepati

Most c
which
infecte
media
protein
bodies

In liver
intens
nuclea

(Choi
necros

(Choi
yellow

(Choi
often a
particu

(Choi
granul

(Choi
myofib
develo

Exhibit Display

Acute viral hepatitis

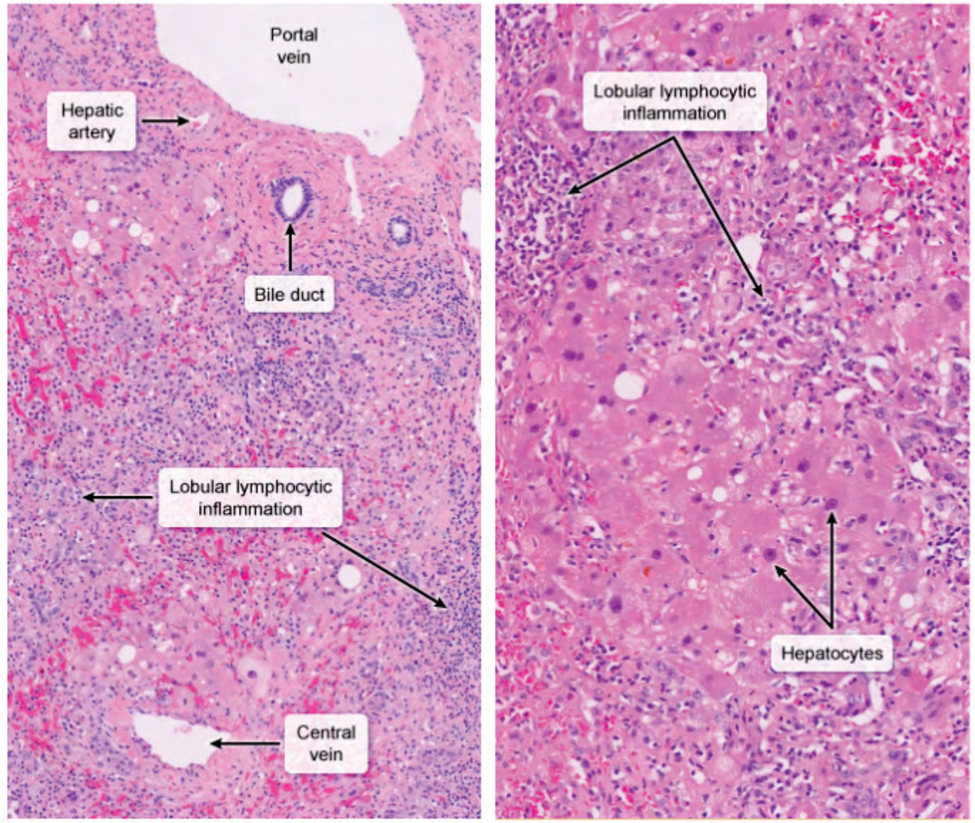

©UWorld

Zoom In | Zoom Out | Reset | New | Existing | My Notebook

https://t.me/USMLEWorldStep1

This p
hepati

Most c
which
infecte
media
protein
bodies

In liver
intens
nuclea

(Choi
necros

(Choi
yellow

(Choi
often a
particu

(Choi
granul

(Choi
myofib
develo

Exhibit Display

Apoptotic hepatocyte

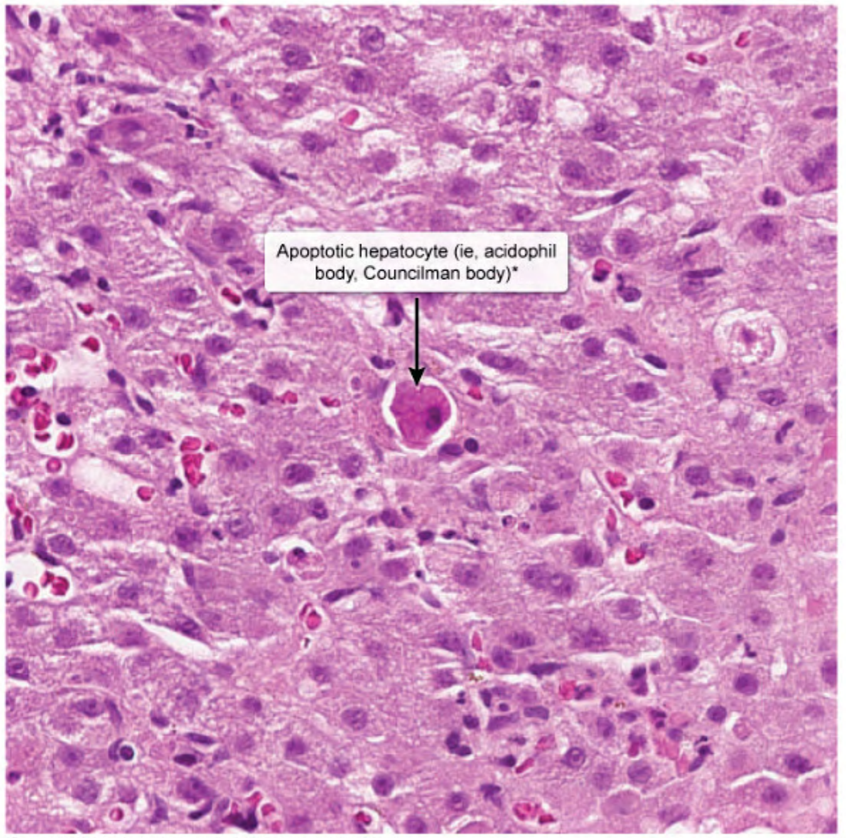

*Dense pink cytoplasm and small, dark (ie, pyknotic) nucleus.

©UWorld

Zoom In | Zoom Out | Reset | New | Existing | My Notebook

69213.mp4
https://t.me/USMLEWorldStep1
Show all

This p
hepati

Most c
which
infecte
media
protein
bodies

In liver
intens
nuclea

(Choi
necros

(Choi
yellow

(Choi
often a
particu

(Choi
granul

(Choi
myofib
develo

Exhibit Display

Hereditary hemochromatosis

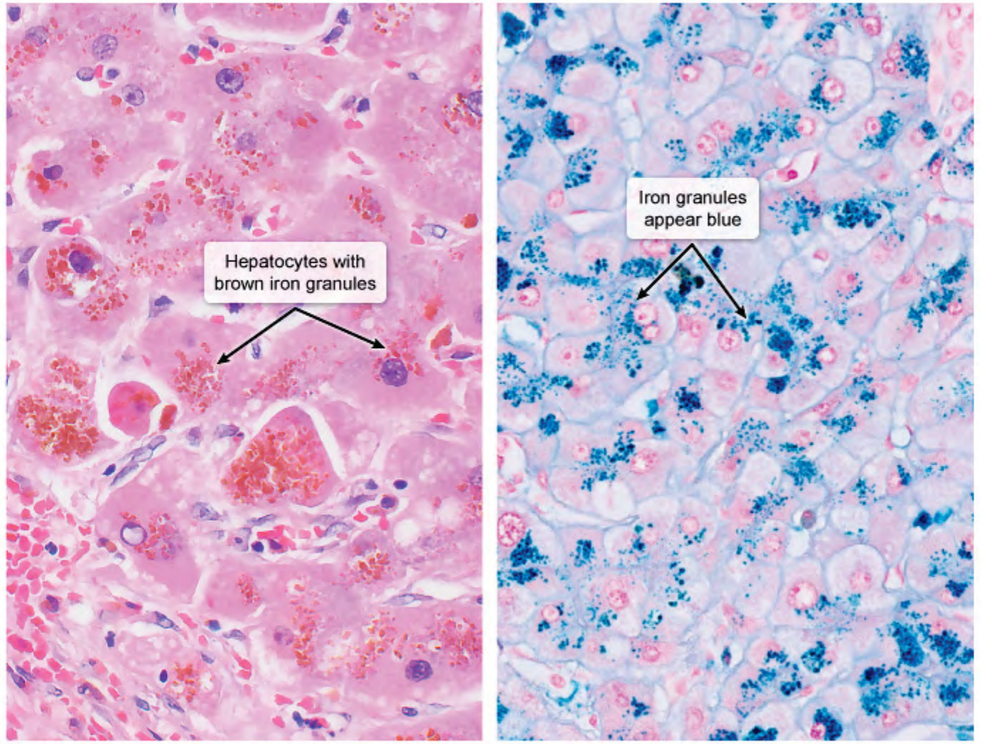

Hematoxylin & eosin stain

Prussian blue stain

©UWorld

Zoom In | Zoom Out | Reset | New | Existing | My Notebook

69213.mp4
https://t.me/USMLEWorldStep1
Show all

Most cases are marked by significant **panlobular lymphocytic inflammation** (ie, involving the entire lobule),

which
infecte
media
protei
bodies

In liver
intens
nuclea

(Choi
necros

(Choi
yellow

(Choi
often a
particu

(Choi
granul

(Choi
myofib
develo
tract–b

Educa
Intrave

Exhibit Display

Mallory bodies

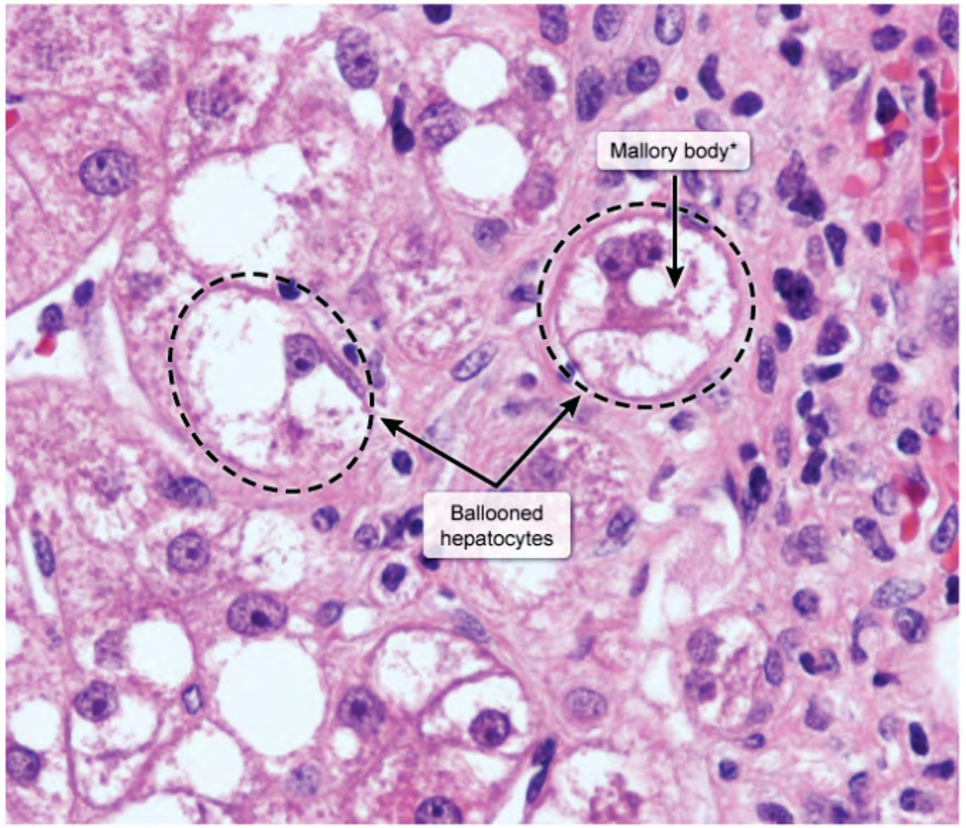

*Eosinophilic clumped intermediate filaments.

©UWorld

Zoom In | Zoom Out | Reset | New | Existing | My Notebook

69213.mp4
https://t.me/USMLEWorldStep1
Show all

Most cases are marked by significant **panlobular lymphocytic inflammation** (ie, involving the entire lobule),

which
infecte
media
protein
bodies

In liver
intens
nuclea

(Choi
necros

(Choi
yellow

(Choi
often a
particu

(Choi
granul

(Choi
myofib
develo
tract–b

Educa
Intrave

Exhibit Display

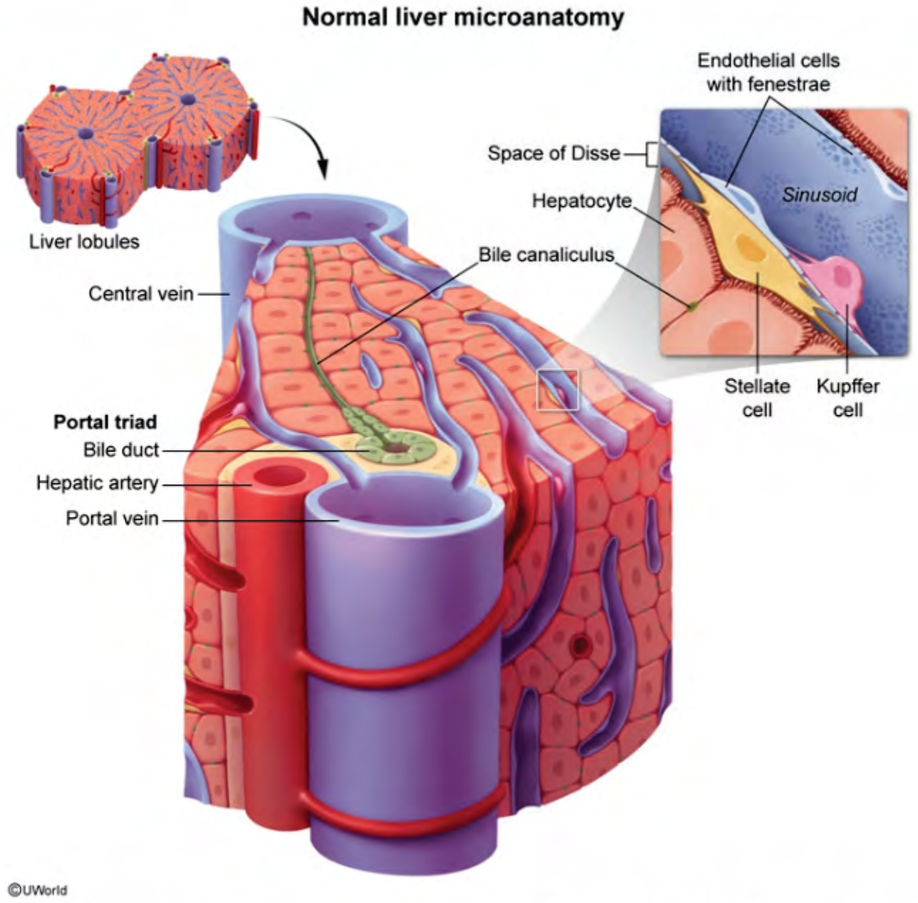

Zoom In | Zoom Out | Reset | New | Existing | My Notebook

69213.mp4
https://t.me/USMLEWorldStep1
Show all

A 6-year-old girl is brought to the office due to intermittent abdominal cramps, bloating, and diarrhea for 2 months. She also has excessive flatulence, which typically occurs after meals. The patient has had no fever or vomiting. She eats a well-balanced diet and takes no medications or vitamins. Vital signs are appropriate for age. Examination shows a mildly distended abdomen with no hepatosplenomegaly or tenderness. Laboratory evaluation reveals elevated tissue transglutaminase antibodies. Which of the following locations should be biopsied to confirm the diagnosis in this patient?

- A. Stomach
- B. Duodenum
- C. Distal jejunum
- D. Terminal ileum
- E. Colon

Submit

69213.mp4
https://t.me/USMLEWorldStep1
Show all

A 6-year-old girl is brought to the office due to intermittent abdominal cramps, bloating, and diarrhea for 2 months. She also has excessive flatulence, which typically occurs after meals. The patient has had no fever or vomiting. She eats a well-balanced diet and takes no medications or vitamins. Vital signs are appropriate for age. Examination shows a mildly distended abdomen with no hepatosplenomegaly or tenderness. Laboratory evaluation reveals elevated tissue transglutaminase antibodies. Which of the following locations should be biopsied to confirm the diagnosis in this patient?

- ✗ A. Stomach (1%)
- ✓ B. Duodenum (63%)
- C. Distal jejunum (17%)
- D. Terminal ileum (15%)
- E. Colon (2%)

Incorrect
Correct answer
B

63%
Answered correctly

04 secs
Time Spent

2023
Version

Explanation

Celiac disease	
Pathogenesis	• Gluten (gliadin) consumption → immune-mediated small intestine inflammation → chronic malabsorption
	• Abdominal pain • Diarrhea, flatulence & bloating

69213.mp4
https://t.me/USMLEWorldStep1
Show all

Celiac disease	
Pathogenesis	• Gluten (gliadin) consumption → immune-mediated small intestine inflammation → chronic malabsorption
Symptoms	• Abdominal pain • Diarrhea, flatulence & bloating • Failure to thrive (children) or weight loss • Iron deficiency anemia • Dermatitis herpetiformis
Diagnosis	• Serology: tissue transglutaminase IgA, antiendomysial antibodies • Duodenal biopsy: intraepithelial lymphocytes, villous atrophy, crypt hyperplasia
Associated conditions	• Autoimmune disorders (eg, type 1 diabetes) • Cancer risk: T-cell lymphoma

This patient with chronic gastrointestinal symptoms and elevated **tissue transglutaminase (TTG) antibodies** likely has **celiac disease**. This chronic, malabsorptive disorder is caused by an immune-mediated reaction to dietary gliadin (the major component of **gluten**) found in wheat, barley, and rye.

In patients with celiac disease, gliadin triggers an **inflammatory reaction** within the small intestine that leads to the classic symptoms of abdominal pain, distension, flatulence, and diarrhea. Laboratory evaluation usually reveals antibodies against TTG, a crosslinking enzyme that interacts with glutamine-rich proteins (including exogenous gliadin). Endoscopy with biopsy characteristically shows villus atrophy, lymphocytic infiltration of the intraepithelial cells, and crypt hyperplasia. Biopsy of the **duodenum** and **proximal jejunum** are most likely to confirm the diagnosis because these areas of the intestine are exposed to the **highest concentration of gliadin**.

(Choice A) *Helicobacter pylori* infection, which predisposes to gastritis and peptic ulcer disease, can cause abdominal pain (often postprandial) and bloating, and gastric biopsy can confirm the diagnosis. However, elevated TTG antibodies are not associated with *H pylori*.

69213.mp4
https://t.me/USMLEWorldStep1
Show all

Diagnosis	• Serology: tissue transglutaminase IgA, antiendomysial antibodies • Duodenal biopsy: intraepithelial lymphocytes, villous atrophy, crypt hyperplasia
Associated conditions	• Autoimmune disorders (eg, type 1 diabetes) • Cancer risk: T-cell lymphoma

This patient with chronic gastrointestinal symptoms and elevated **tissue transglutaminase (TTG) antibodies** likely has **celiac disease**. This chronic, malabsorptive disorder is caused by an immune-mediated reaction to dietary gliadin (the major component of **gluten**) found in wheat, barley, and rye.

In patients with celiac disease, gliadin triggers an **inflammatory reaction** within the small intestine that leads to the classic symptoms of abdominal pain, distension, flatulence, and diarrhea. Laboratory evaluation usually reveals antibodies against TTG, a crosslinking enzyme that interacts with glutamine-rich proteins (including exogenous gliadin). Endoscopy with biopsy characteristically shows villus atrophy, lymphocytic infiltration of the intraepithelial cells, and crypt hyperplasia. Biopsy of the **duodenum** and **proximal jejunum** are most likely to confirm the diagnosis because these areas of the intestine are exposed to the **highest concentration of gliadin**.

(Choice A) *Helicobacter pylori* infection, which predisposes to gastritis and peptic ulcer disease, can cause abdominal pain (often postprandial) and bloating, and gastric biopsy can confirm the diagnosis. However, elevated TTG antibodies are not associated with *H pylori*.

(Choices C, D, and E) Because celiac disease primarily involves the proximal small bowel, biopsies from the distal jejunum and terminal ileum may be normal in patients with celiac disease and are not recommended; the colon is not affected in celiac disease.

Educational objective:
Celiac disease is caused by an immune-mediated reaction to gluten and classically leads to chronic gastrointestinal symptoms. Diagnosis is confirmed by elevated tissue transglutaminase IgA antibody levels and duodenal biopsy showing villus flattening, intraepithelial lymphocyte infiltration, and crypt hyperplasia.

Pathology Gastrointestinal & Nutrition Celiac disease

69213.mp4
https://t.me/USMLEWorldStep1
Show all

A 43-year-old man is evaluated in the hospital for a medical illness. He has traveled to various countries on missionary trips and recently returned from South America. The patient has no prior medical history and takes no medications. His father has a history of alcohol dependence complicated by cirrhosis and portal hypertension. A liver biopsy is performed, and light microscopy of the tissue demonstrates spotty hepatocyte necrosis and inflammatory cell infiltration, as shown in the image below.

Which of the following is the most likely initial clinical presentation of this patient?

- A. Clay-colored stools and osteoporosis
- B. Fever, anorexia, and dark-colored urine
- C. Prolonged pruritus and fatigue
- D. Skin pigmentation and diabetes mellitus
- E. Upper gastrointestinal bleeding and ascites

Submit

69213.mp4
https://t.me/USMLEWorldStep1
Show all

A 43-year-old man is evaluated in the hospital for a medical illness. He has traveled to various countries on
missio
medica
liver bi
inflam

Exhibit Display

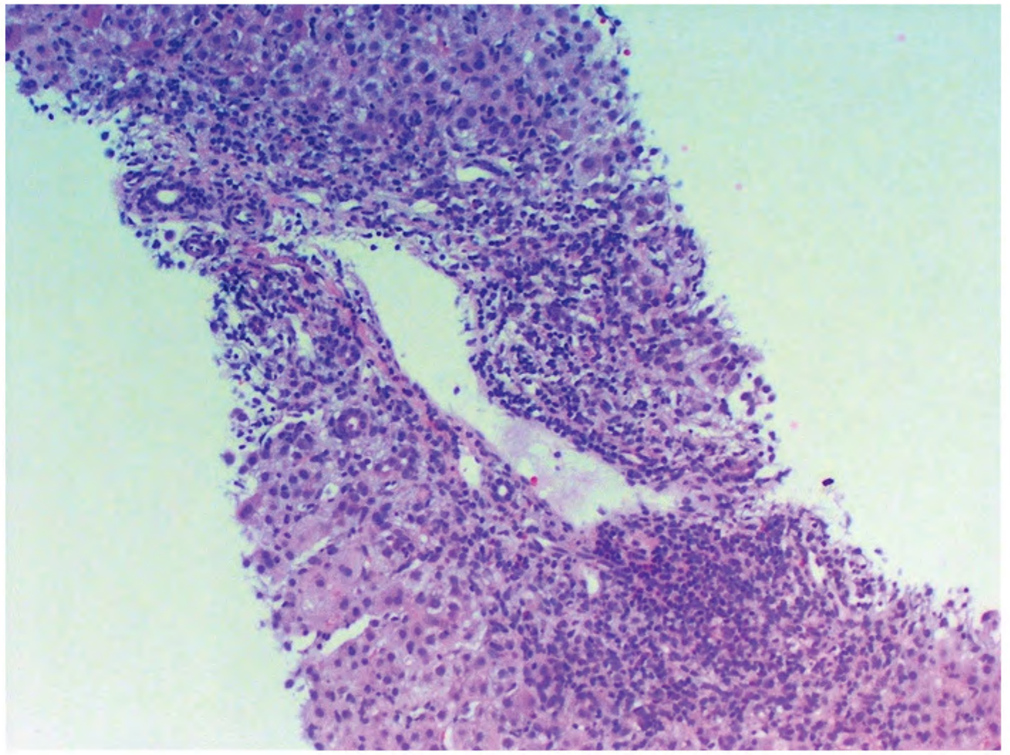

Zoom In | Zoom Out | Reset | New | Existing | My Notebook

Which

A. Clay-colored stools and osteoporosis

69213.mp4
https://t.me/USMLEWorldStep1
Show all

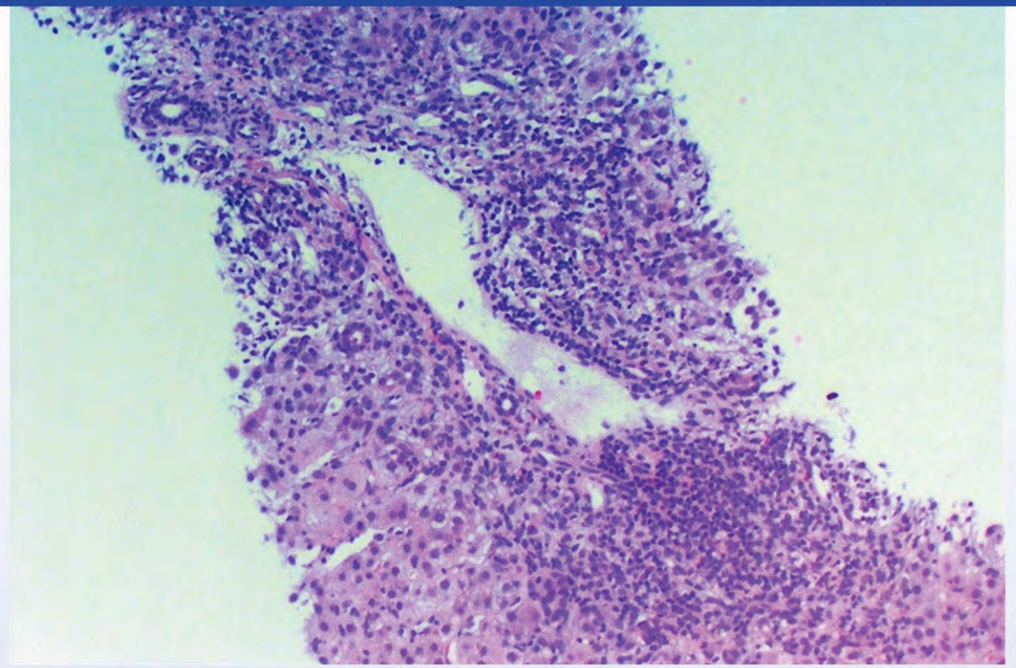

Which of the following is the most likely initial clinical presentation of this patient?

- A. Clay-colored stools and osteoporosis
- B. Fever, anorexia, and dark-colored urine
- C. Prolonged pruritus and fatigue
- D. Skin pigmentation and diabetes mellitus
- E. Upper gastrointestinal bleeding and ascites

Submit

69213.mp4
https://t.me/USMLEWorldStep1
Show all

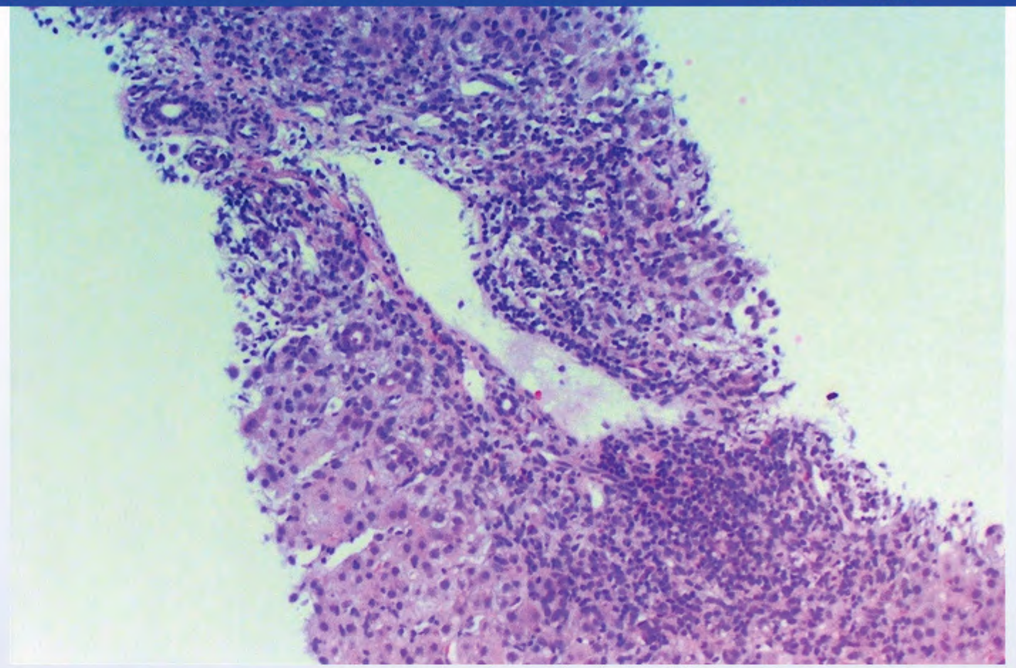

Which of the following is the most likely initial clinical presentation of this patient?

- A. Clay-colored stools and osteoporosis (3%)
- ✓ B. Fever, anorexia, and dark-colored urine (62%)
- C. Prolonged pruritus and fatigue (19%)
- D. Skin pigmentation and diabetes mellitus (5%)
- E. Upper gastrointestinal bleeding and ascites (8%)

Correct

62%
Answered correctly

10 secs
Time Spent

2023
Version

69213.mp4
https://t.me/USMLEWorldStep1
Show all

Explanation

This patient's liver biopsy findings and recent travel to an endemic region suggest **acute hepatitis A infection**. Acute viral hepatitis is characterized histologically by the presence of "spotty necrosis" with ballooning degeneration (hepatocyte swelling with wispy/clear cytoplasm), Councilman bodies (eosinophilic apoptotic hepatocytes), and mononuclear cell infiltrates.

Patients typically present acutely with a prodrome of **fever**, malaise, **anorexia**, nausea/vomiting, and right upper quadrant abdominal pain. After several days (up to 1 week), prodromal symptoms lessen as patients develop signs of cholestasis such as jaundice, pruritus, **dark-colored urine** (due to increased conjugated bilirubin levels), and acholic stool (lacks bilirubin pigment). The illness is self-limited and does not progress to chronic hepatitis, cirrhosis, or hepatocellular carcinoma.

(Choices A and C) Chronic cholestatic processes (eg, primary biliary cirrhosis, primary sclerosing cholangitis) may present initially with prolonged pruritus and fatigue. As these conditions progress, patients can develop acholic stools and malabsorption of fat-soluble vitamins (due to reduced bile flow to the small intestine). This can lead to vitamin D deficiency and metabolic bone disease (eg, osteoporosis, osteomalacia).

(Choice D) Skin pigmentation and diabetes mellitus are more suggestive of hemochromatosis, an inherited disease associated with iron overload in the liver, pancreas, heart, and other organs.

(Choice E) Upper gastrointestinal bleeding and ascites are more suggestive of portal hypertension, a condition that typically develops secondary to liver cirrhosis.

Educational objective:
Acute hepatitis A is a self-limited infection that typically presents acutely with prodromal symptoms (eg, fever, malaise, anorexia, nausea/vomiting, right upper quadrant pain) followed by signs of cholestasis (eg, jaundice, pruritus, dark-colored urine, clay-colored stool).

69213.mp4
https://t.me/USMLEWorldStep1
Show all

Expl

This p
Acute
degen
hepato

Patien
quadra
signs
and ac
cirrhos

(Choi
may p
acholi
lead to

(Choi
diseas

(Choi
that ty

Educa
Acute
malais
pruritus, dark-colored urine, clay-colored stool).

Exhibit Display

Ballooning degeneration

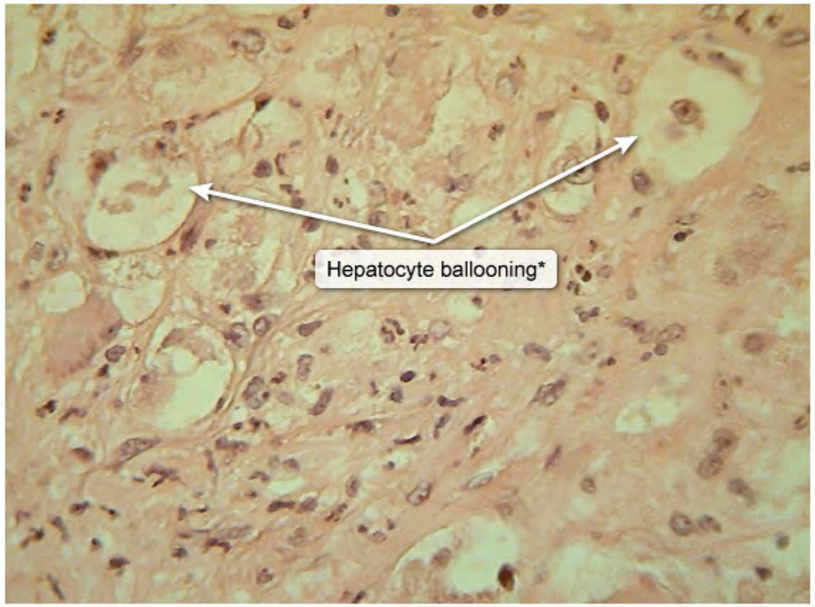

*Swollen cells with cytoplasmic clearing

©UWorld

Zoom In | Zoom Out | Reset | New | Existing | My Notebook

69213.mp4
https://t.me/USMLEWorldStep1
Show all

Expl

This p
Acute
degen
hepato

Patien
quadra
signs
and ac
cirrhos

(Choi
may p
acholi
lead to

(Choi
diseas

(Choi
that ty

Educa
Acute
malais
pruritus, dark-colored urine, clay-colored stool).

Exhibit Display

Acute hepatitis | Acute hepatitis

Acute viral hepatitis

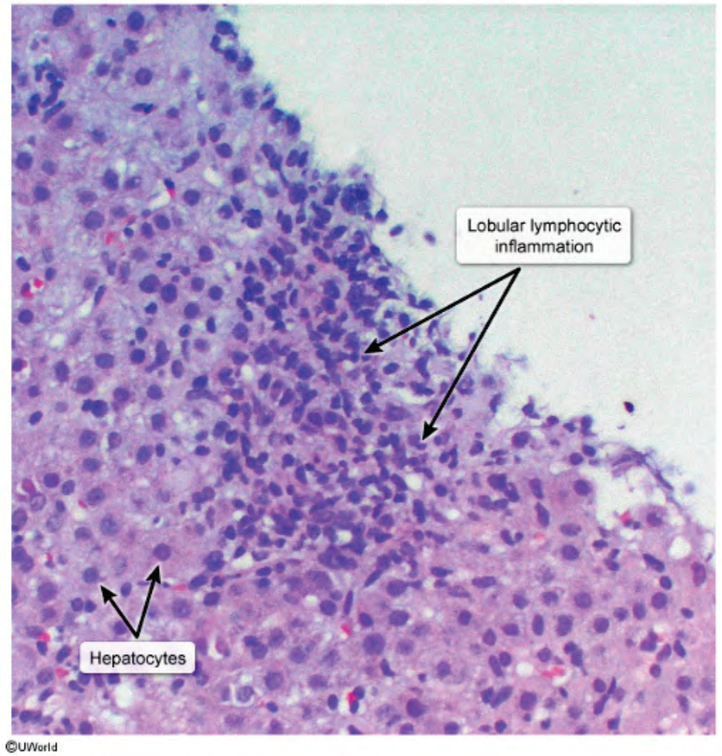

Zoom In | Zoom Out | Reset | New | Existing | My Notebook

69213.mp4
https://t.me/USMLEWorldStep1
Show all

Expl

This p
Acute
degen
hepato

Patien
quadra
signs
and ac
cirrhos

(Choi
may p
acholi
lead to

(Choi
diseas

(Choi
that ty

Educa
Acute
malais
pruritus, dark-colored urine, clay-colored stool).

Exhibit Display

Acute hepatitis | Acute hepatitis

Acute hepatitis

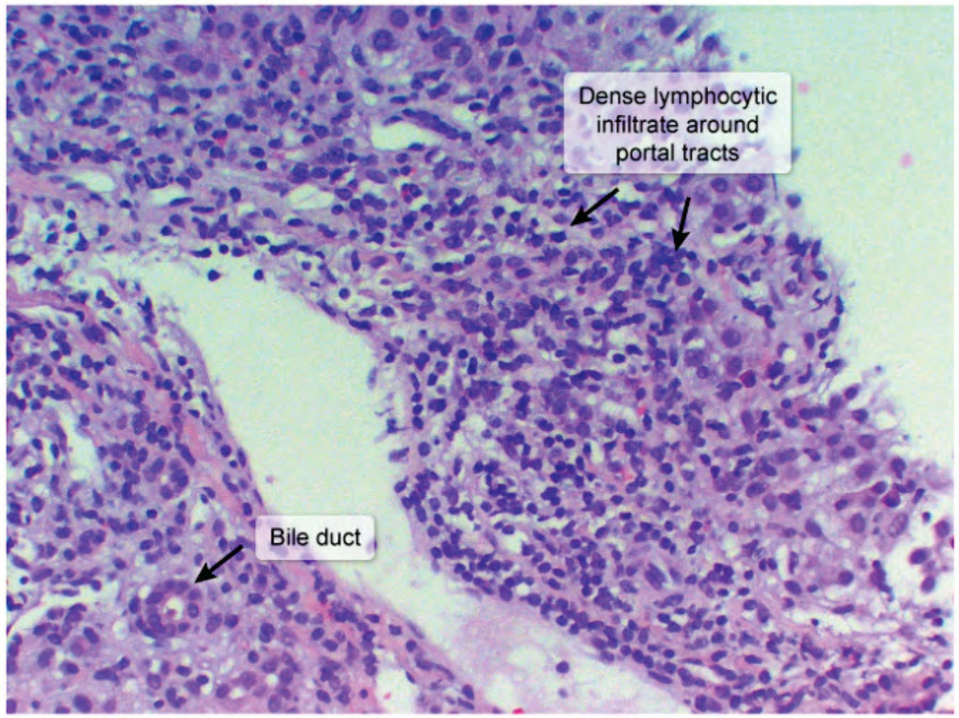

©UWorld

Zoom In | Zoom Out | Reset | New | Existing | My Notebook

69213.mp4
https://t.me/USMLEWorldStep1
Show all

An 8-month-old boy is brought to clinic due to abdominal distension. The patient has had excessive straining and irritability with bowel movements since birth. He had been exclusively breastfed, and his symptoms worsened after transitioning to pureed foods. Vital signs are normal. Abdominal examination shows distension with mild tenderness to palpation. Bowel sounds are present, and there is no hepatosplenomegaly. Barium enema shows a relatively narrow rectum and rectosigmoid area. The rest of the colon proximal to this segment is significantly dilated. Colorectal biopsy of which of the following areas is most likely to reveal the underlying cause of this patient's condition?

- A. Mucosa of the dilated segment
- B. Mucosa of the narrow segment
- C. Muscular layer of the dilated segment
- D. Submucosa of the dilated segment
- E. Submucosa of the narrow segment

Submit

69213.mp4
https://t.me/USMLEWorldStep1
Show all

An 8-month-old boy is brought to clinic due to abdominal distension. The patient has had excessive straining and irritability with bowel movements since birth. He had been exclusively breastfed, and his symptoms worsened after transitioning to pureed foods. Vital signs are normal. Abdominal examination shows distension with mild tenderness to palpation. Bowel sounds are present, and there is no hepatosplenomegaly. Barium enema shows a relatively narrow rectum and rectosigmoid area. The rest of the colon proximal to this segment is significantly dilated. Colorectal biopsy of which of the following areas is most likely to reveal the underlying cause of this patient's condition?

- A. Mucosa of the dilated segment (1%)
- ✗ B. Mucosa of the narrow segment (8%)
- C. Muscular layer of the dilated segment (11%)
- D. Submucosa of the dilated segment (8%)
- ✓ E. Submucosa of the narrow segment (70%)

Incorrect
Correct answer
E

70%
Answered correctly

04 secs
Time Spent

2023
Version

Explanation

Hirschsprung disease	
Pathophysiology	• Failure of neural crest cell migration caudally to distal colon • Absent parasympathetic ganglia in affected submucosal & myenteric plexus • Chronically contracted colonic segment

69213.mp4
https://t.me/USMLEWorldStep1
Show all

Hirschsprung disease	
Pathophysiology	• Failure of neural crest cell migration caudally to distal colon • Absent parasympathetic ganglia in affected submucosal & myenteric plexus • Chronically contracted colonic segment
Clinical features	• Delayed passage of meconium in neonates • Chronic constipation • Abdominal distension
Evaluation	• Contrast enema: narrow rectosigmoid area with dilated proximal colon • Rectal suction biopsy (diagnostic): absent submucosal ganglia

This infant with chronic constipation and abdominal distension has barium enema findings suggestive of **Hirschsprung disease** (HD). HD is a congenital disorder in which **neural crest cells** fail to migrate to the bowel wall during embryogenesis. These cells normally develop into ganglion cells of the **submucosal (Meissner) and myenteric (Auerbach) plexus**. In HD, the affected colon lacks parasympathetic ganglia and is therefore unable to relax. Because the neural crest cells migrate caudally along the bowel, the **rectosigmoid area** is most commonly involved.

Typical presentation is in the neonatal period with delayed passage of meconium and signs of bowel obstruction (eg, bilious emesis, abdominal distension). However, disease severity correlates with the length of nonfunctional bowel. Therefore, those with a short aganglionic segment may go undiagnosed with chronic, refractory **constipation** for months or years, as in this case. Characteristic findings on contrast enema include a narrowed rectosigmoid area (due to chronic contraction) and a dilated bowel proximal to the obstruction.

Rectal suction biopsy is the gold standard for the diagnosis of HD and should include the **submucosa** of the rectum (ie, **narrowed segment**), which is the most superficial layer that demonstrates the **absence of ganglion cells** (ie, submucosal plexus). Absence of ganglia between the longitudinal and circular layers of the muscularis

69213.mp4
https://t.me/USMLEWorldStep1
Show all

Clinical features	• Delayed passage of meconium in neonates • Chronic constipation • Abdominal distension
Evaluation	• Contrast enema: narrow rectosigmoid area with dilated proximal colon • Rectal suction biopsy (diagnostic): absent submucosal ganglia

This infant with chronic constipation and abdominal distension has barium enema findings suggestive of **Hirschsprung disease** (HD). HD is a congenital disorder in which **neural crest cells** fail to migrate to the bowel wall during embryogenesis. These cells normally develop into ganglion cells of the **submucosal (Meissner) and myenteric (Auerbach) plexus**. In HD, the affected colon lacks parasympathetic ganglia and is therefore unable to relax. Because the neural crest cells migrate caudally along the bowel, the **rectosigmoid area** is most commonly involved.

Typical presentation is in the neonatal period with delayed passage of meconium and signs of bowel obstruction (eg, bilious emesis, abdominal distension). However, disease severity correlates with the length of nonfunctional bowel. Therefore, those with a short aganglionic segment may go undiagnosed with chronic, refractory **constipation** for months or years, as in this case. Characteristic findings on contrast enema include a narrowed rectosigmoid area (due to chronic contraction) and a dilated bowel proximal to the obstruction.

Rectal suction biopsy is the gold standard for the diagnosis of HD and should include the **submucosa** of the rectum (ie, **narrowed segment**), which is the most superficial layer that demonstrates the **absence of ganglion cells** (ie, submucosal plexus). Absence of ganglia between the longitudinal and circular layers of the muscularis externa (ie, myenteric plexus) can also be seen on full-thickness biopsies.

Educational objective:
Absence of the submucosal (Meissner) and myenteric (Auerbach) plexuses in Hirschsprung disease causes the affected rectosigmoid region to become narrowed. The submucosa of the narrowed area is the most superficial layer where the absence of ganglion cells can be confirmed during biopsy procedures.

69213.mp4
https://t.me/USMLEWorldStep1
Show all

Evaluation	• Contrast enema: narrow rectosigmoid area with dilated proximal colon

This ir
Hirsch
wall du
myent
relax.
involve

Typica
(eg, bi
bowel.
consti
rectos

Rectal
rectum
cells (
extern

Educa
Absen
affecte
layer v

Pathol
Subject

Exhibit Display

Hirschsprung disease

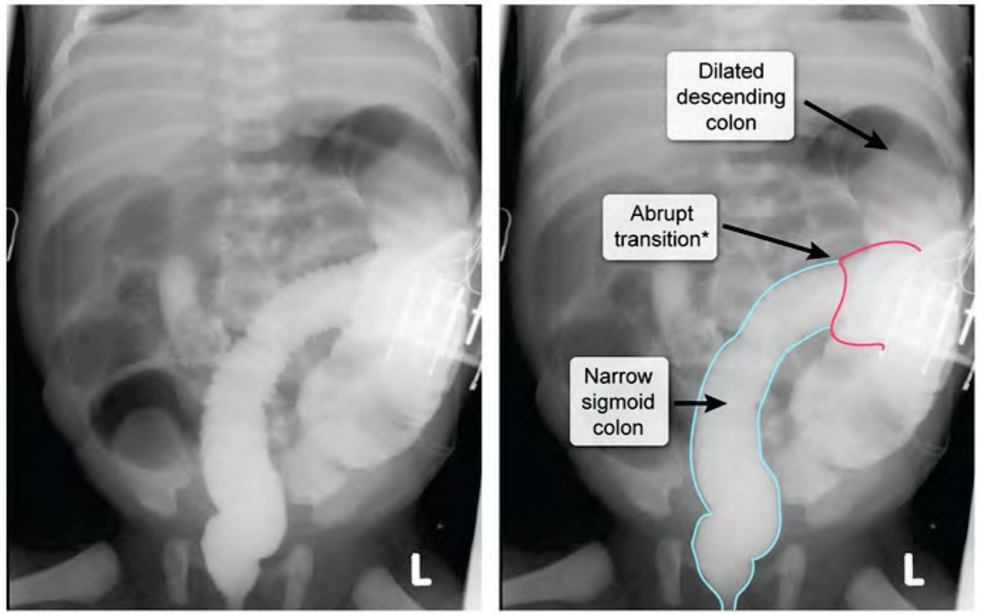

*Between narrow, aganglionic colon & dilated proximal colon.

©UWorld

Zoom In | Zoom Out | Reset | New | Existing | My Notebook

69213.mp4
https://t.me/USMLEWorldStep1
Show all

A 60-year-old woman comes to the office with intermittent flatulence, crampy abdominal pain, and watery diarrhea. Her symptoms started 2 months ago after she recovered from an episode of acute gastroenteritis associated with nausea, vomiting, and diarrhea. The patient's symptoms are worse after drinking "too much milk." She usually has 1 or 2 glasses of wine every evening with dinner. Physical examination is unremarkable. Initial laboratory evaluation, including serum chemistries, blood counts, stool cultures, and studies for ova and parasites, is negative. Which of the following is most likely decreased in this patient?

- A. Breath hydrogen content
- B. Fecal fat
- C. Pancreatic enzymes
- D. Stool osmolality
- E. Stool pH

Submit

69213.mp4
https://t.me/USMLEWorldStep1
Show all

A 60-year-old woman comes to the office with intermittent flatulence, crampy abdominal pain, and watery diarrhea. Her symptoms started 2 months ago after she recovered from an episode of acute gastroenteritis associated with nausea, vomiting, and diarrhea. The patient's symptoms are worse after drinking "too much milk." She usually has 1 or 2 glasses of wine every evening with dinner. Physical examination is unremarkable. Initial laboratory evaluation, including serum chemistries, blood counts, stool cultures, and studies for ova and parasites, is negative. Which of the following is most likely decreased in this patient?

- A. Breath hydrogen content (9%)
- ✗ B. Fecal fat (2%)
- C. Pancreatic enzymes (17%)
- D. Stool osmolality (23%)
- ✓ E. Stool pH (47%)

Incorrect
Correct answer
E

47%
Answered correctly

01 min, 08 secs
Time Spent

2023
Version

Explanation

This patient's presentation with flatulence, crampy abdominal pain, and watery diarrhea after consuming dairy products (eg, milk) is consistent with **lactose intolerance**. The most common cause of lactose intolerance is lactase nonpersistence, which is especially prevalent in Asian and African populations and is characterized by declining lactase expression in adulthood. This patient's lactose intolerance is most likely due to **secondary lactase deficiency**, an acquired condition resulting from inflammation/infection (eg, bacterial overgrowth, **infectious enteritis**, Crohn disease) that causes injury to the mucosal brush border of the small bowel where lactase is expressed

69213.mp4
https://t.me/USMLEWorldStep1
Show all

This patient's presentation with flatulence, crampy abdominal pain, and watery diarrhea after consuming dairy products (eg, milk) is consistent with **lactose intolerance**. The most common cause of lactose intolerance is lactase nonpersistence, which is especially prevalent in Asian and African populations and is characterized by declining lactase expression in adulthood. This patient's lactose intolerance is most likely due to **secondary lactase deficiency**, an acquired condition resulting from inflammation/infection (eg, bacterial overgrowth, **infectious enteritis**, Crohn disease) that causes injury to the mucosal brush border of the small bowel where lactase is expressed.

Lactase deficiency results in incomplete hydrolysis of lactose into the monosaccharides glucose and galactose. The fermentation of undigested lactose by gut bacteria leads to increased production of short-chain fatty acids (eg, acetate, butyrate, propionate) that acidify the stool (**decreased stool pH**). During this process, hydrogen gas is also produced, leading to **increased breath hydrogen content (Choice A)**. In addition, the high amounts of undigested lactose in the bowel lead to **elevated stool osmolality**, which attracts excess water in the bowel lumen, causing osmotic diarrhea **(Choice D)**.

(Choice B) Inflammation/infection of the small intestine may lead to fat malabsorption, resulting in steatorrhea (eg, greasy, malodorous stool that is difficult to flush), weight loss, and increased fecal fat content. Fat malabsorption does not typically occur in patients with lactase deficiency.

(Choice C) Reduced pancreatic enzyme production (exocrine insufficiency) can occur with chronic pancreatitis, which is seen frequently in individuals with chronic alcoholism. Pancreatic enzyme levels are not affected by secondary lactase deficiency.

Educational objective:
Lactose intolerance presents with flatulence, crampy abdominal pain, and watery diarrhea after dairy product consumption. It can be acquired by inflammatory/infectious conditions that injure the mucosal brush border of the small intestine where lactase is expressed. Studies can show increased breath hydrogen content, reduced stool pH, and elevated stool osmolality.

References

69213.mp4
https://t.me/USMLEWorldStep1
Show all

This patient's presentation with flatulence, crampy abdominal pain, and watery diarrhea after consuming dairy products (eg, milk) is consistent with **lactose intolerance**. The most common cause of lactose intolerance is lactase nonpersistence, which is especially prevalent in Asian and African populations and is characterized by declining lactase expression in adulthood. This patient's lactose intolerance is most likely due to **secondary lactase deficiency**, an acquired condition resulting from inflammation/infection (eg, bacterial overgrowth, **infectious enteritis**, Crohn disease) that causes injury to the mucosal brush border of the small bowel where lactase is expressed.

Lactase deficiency results in incomplete hydrolysis of lactose into the monosaccharides glucose and galactose. The fermentation of undigested lactose by gut bacteria leads to increased production of short-chain fatty acids (eg, acetate, butyrate, propionate) that acidify the stool (**decreased stool pH**). During this process, hydrogen gas is also produced, leading to **increased breath hydrogen content (Choice A)**. In addition, the high amounts of undigested lactose in the bowel lead to **elevated stool osmolality**, which attracts excess water in the bowel lumen, causing osmotic diarrhea **(Choice D)**.

(Choice B) Inflammation/infection of the small intestine may lead to fat malabsorption, resulting in steatorrhea (eg, greasy, malodorous stool that is difficult to flush), weight loss, and increased fecal fat content. Fat malabsorption does not typically occur in patients with lactase deficiency.

(Choice C) Reduced pancreatic enzyme production (exocrine insufficiency) can occur with chronic pancreatitis, which is seen frequently in individuals with chronic alcoholism. Pancreatic enzyme levels are not affected by secondary lactase deficiency.

Educational objective:
Lactose intolerance presents with flatulence, crampy abdominal pain, and watery diarrhea after dairy product consumption. It can be acquired by inflammatory/infectious conditions that injure the mucosal brush border of the small intestine where lactase is expressed. Studies can show increased breath hydrogen content, reduced stool pH, and elevated stool osmolality.

References

69213.mp4
https://t.me/USMLEWorldStep1
Show all

A 50-year-old woman comes to the physician due to periodic reddening of her skin that is starting to become bothersome. The redness involves mainly her face and neck and is accompanied by mild warmth. The episodes initially lasted only a few minutes, but now they sometimes exceed 20 minutes. The patient has also had persistent watery diarrhea and associated abdominal cramping for the last several months. Physical examination shows several, purple vascular lesions surrounding her nose. Urinary excretion of 5-hydroxyindoleacetic acid (5-HIAA) over 24 hours is increased. Abdominal imaging shows a tumor in the small intestine. Which of the following is most likely responsible for this patient's condition?

- A. Localized adenocarcinoma
- B. Localized carcinoid
- C. Metastatic carcinoid
- D. Metastatic lymphoma
- E. Secretory leiomyoma

Submit

69213.mp4
https://t.me/USMLEWorldStep1
Show all

A 50-year-old woman comes to the physician due to periodic reddening of her skin that is starting to become bothersome. The redness involves mainly her face and neck and is accompanied by mild warmth. The episodes initially lasted only a few minutes, but now they sometimes exceed 20 minutes. The patient has also had persistent watery diarrhea and associated abdominal cramping for the last several months. Physical examination shows several, purple vascular lesions surrounding her nose. Urinary excretion of 5-hydroxyindoleacetic acid (5-HIAA) over 24 hours is increased. Abdominal imaging shows a tumor in the small intestine. Which of the following is most likely responsible for this patient's condition?

- A. Localized adenocarcinoma (2%)
- ✗ B. Localized carcinoid (21%)
- ✓ C. Metastatic carcinoid (72%)
- D. Metastatic lymphoma (2%)
- E. Secretory leiomyoma (1%)

Incorrect
Correct answer
C

72%
Answered correctly

04 secs
Time Spent

2023
Version

Explanation

Features of carcinoid syndrome	
Clinical manifestations	• Skin: flushing, telangiectasias, cyanosis • Gastrointestinal: watery diarrhea, cramping • Pulmonary: bronchospasm, dyspnea, wheezing • Cardiac: valvular fibrous plaques (right > left)

69213.mp4
https://t.me/USMLEWorldStep1
Show all

Features of carcinoid syndrome	
Clinical manifestations	• Skin: flushing, telangiectasias, cyanosis • Gastrointestinal: watery diarrhea, cramping • Pulmonary: bronchospasm, dyspnea, wheezing • Cardiac: valvular fibrous plaques (right > left)
Diagnosis	• Elevated 24-hr urinary excretion of 5-HIAA • CT scan/MRI of abdomen & pelvis to localize tumor
Treatment	• Octreotide for symptomatic patients • Surgery for liver metastases
5-HIAA = 5-hydroxyindoleacetic acid.	

Carcinoid tumors most frequently arise from the enterochromaffin (endocrine) cells of the intestinal mucosa. These cells produce a number of vasoactive substances, such as serotonin (5-HT), bradykinin, and prostaglandins. When the tumor is confined to the intestine, these secretory products are metabolized by the liver and patients do not develop carcinoid syndrome. In contrast, if intestinal carcinoid **metastasizes to the liver**, these vasoactive substances bypass the liver and enter the systemic circulation, resulting in **carcinoid syndrome**. Extraintestinal carcinoid tumors (eg, bronchial carcinoid) can cause carcinoid syndrome without metastasizing as the vasoactive substances are secreted directly into systemic circulation (again bypassing hepatic metabolism).

Increased level of the serotonin metabolite **5-hydroxyindoleacetic acid (5-HIAA)** in a 24-hour urine sample is the most useful initial test for confirming carcinoid syndrome.

(Choices A, D, and E) Adenocarcinoma, lymphoma, and secretory leiomyoma would not result in carcinoid syndrome or elevated urinary 5-HIAA levels.

(Choice B) The vasoactive substances secreted by a localized intestinal carcinoid tumor are metabolized by the

69213.mp4
https://t.me/USMLEWorldStep1
Show all

Treatment	• Octreotide for symptomatic patients • Surgery for liver metastases

5-HIAA = 5-hydroxyindoleacetic acid.

Carcinoid tumors most frequently arise from the enterochromaffin (endocrine) cells of the intestinal mucosa. These cells produce a number of vasoactive substances, such as serotonin (5-HT), bradykinin, and prostaglandins. When the tumor is confined to the intestine, these secretory products are metabolized by the liver and patients do not develop carcinoid syndrome. In contrast, if intestinal carcinoid **metastasizes to the liver**, these vasoactive substances bypass the liver and enter the systemic circulation, resulting in **carcinoid syndrome**. Extraintestinal carcinoid tumors (eg, bronchial carcinoid) can cause carcinoid syndrome without metastasizing as the vasoactive substances are secreted directly into systemic circulation (again bypassing hepatic metabolism).

Increased level of the serotonin metabolite **5-hydroxyindoleacetic acid (5-HIAA)** in a 24-hour urine sample is the most useful initial test for confirming carcinoid syndrome.

(Choices A, D, and E) Adenocarcinoma, lymphoma, and secretory leiomyoma would not result in carcinoid syndrome or elevated urinary 5-HIAA levels.

(Choice B) The vasoactive substances secreted by a localized intestinal carcinoid tumor are metabolized by the liver via first-pass metabolism, preventing the development of carcinoid syndrome. Extraintestinal metastasis of intestinal carcinoid tumors is required to produce carcinoid symptoms.

Educational objective:
Carcinoid tumors confined to the intestine do not cause carcinoid syndrome as their secretory products are metabolized by the liver before entering the systemic circulation. In contrast, intestinal carcinoids that metastasize to the liver and extraintestinal (eg, bronchial) carcinoids release vasoactive substances that avoid first-pass metabolism, resulting in carcinoid syndrome (eg, flushing, diarrhea, bronchospasm).

Pathophysiology	Gastrointestinal & Nutrition	Carcinoid tumors
Subject	System	Topic

69213.mp4
https://t.me/USMLEWorldStep1
Show all

A 78-year-old man is brought to the emergency department from a nursing home due to abdominal pain and discomfort. The patient has advanced dementia and is only partially able to describe his symptoms. He has had intermittent abdominal discomfort for years with no other related symptoms. The patient is in bed most of the time and can participate in minimal activity with the help of nurses and physical therapists. Prior screening colonoscopies have shown only benign lesions. Abdominal examination is notable for fullness but does not show tenderness, masses, or hepatosplenomegaly. Polyethylene glycol is administered and produces a bowel movement 18 hours later. The mechanism of action of this medication most closely resembles the underlying cause of diarrhea in which of the following conditions?

- A. Carcinoid syndrome
- B. Crohn disease
- C. Irritable bowel syndrome
- D. Lactose intolerance
- E. Rectal prolapse

Submit

69213.mp4
https://t.me/USMLEWorldStep1
Show all

A 78-year-old man is brought to the emergency department from a nursing home due to abdominal pain and discomfort. The patient has advanced dementia and is only partially able to describe his symptoms. He has had intermittent abdominal discomfort for years with no other related symptoms. The patient is in bed most of the time and can participate in minimal activity with the help of nurses and physical therapists. Prior screening colonoscopies have shown only benign lesions. Abdominal examination is notable for fullness but does not show tenderness, masses, or hepatosplenomegaly. Polyethylene glycol is administered and produces a bowel movement 18 hours later. The mechanism of action of this medication most closely resembles the underlying cause of diarrhea in which of the following conditions?

- A. Carcinoid syndrome (10%)
- ✗ B. Crohn disease (3%)
- C. Irritable bowel syndrome (13%)
- ✓ D. Lactose intolerance (69%)
- E. Rectal prolapse (1%)

Incorrect
Correct answer
D

69%
Answered correctly

04 secs
Time Spent

2023
Version

Explanation

Pharmacologic treatment of chronic constipation*		
Class	**Agent**	**Mechanism**
Osmotic laxatives	Polyethylene glycol,	

69213.mp4
https://t.me/USMLEWorldStep1
Show all

Explanation

Pharmacologic treatment of chronic constipation*		
Class	**Agent**	**Mechanism**
Osmotic laxatives	Polyethylene glycol, lactulose	↑ Osmotic gradient for water → bowel distension → ↑ peristalsis
Saline laxatives	Magnesium salts	
Stimulant laxatives	Bisacodyl, senna (irritants)	Enteric neuron stimulation → ↑ peristalsis + ↑ fluid secretion
Chloride channel activators	Lubiprostone	CFTR chloride channel stimulation → ↑ fluid secretion
Opioid antagonists**	Methylnaltrexone	μ Opioid receptor antagonism → ↑ peristalsis
*<3 bowel movements/week with symptoms (eg, straining, hard stools) for at least 3-6 months. **For chronic constipation induced by opioids. **CFTR** = cystic fibrosis transmembrane conductance regulator.		

Chronic constipation is common in elderly persons with impaired mobility as well as those treated long term with opioids. Because lifestyle (eg, exercise) and dietary modifications (eg, increased fiber, fluid) are frequently difficult for these patients, constipation is often treated pharmacologically.

Osmotic laxatives (eg, polyethylene glycol) are poorly absorbable substances that draw water (and subsequently electrolytes) into the intestinal lumen. The **increased fluid load** distends the intestinal wall, stimulating intestinal **peristalsis** to create a bowel movement.

69213.mp4
https://t.me/USMLEWorldStep1
Show all

Chronic constipation is common in elderly persons with impaired mobility as well as those treated long term with opioids. Because lifestyle (eg, exercise) and dietary modifications (eg, increased fiber, fluid) are frequently difficult for these patients, constipation is often treated pharmacologically.

Osmotic laxatives (eg, polyethylene glycol) are poorly absorbable substances that draw water (and subsequently electrolytes) into the intestinal lumen. The **increased fluid load** distends the intestinal wall, stimulating intestinal **peristalsis** to create a bowel movement.

Osmotic substances can also accumulate in the intestinal lumen in patients with **lactose intolerance**. Undigested lactose is a nonabsorbable osmotic substance; accumulation in the small intestine leads to an increase in the secretion of water and electrolytes into the intestinal lumen, causing **osmotic diarrhea**. Bacteria in the distal intestine can also ferment the lactose, producing fatty acids and gasses that cause additional abdominal distension, pain, and flatulence. Symptoms resolve when milk-containing products are eliminated from the diet.

(Choice A) Diarrhea in carcinoid syndrome is secretory and high in electrolytes. High amounts of circulating serotonin stimulate 5-HT_4 receptors in the colon, increasing fluid secretion.

(Choice B) In Crohn disease, intestinal inflammation leads to dysregulated ion transport and impaired epithelial barrier function. Consequently, colonic fluid secretion outweighs fluid reabsorption, resulting in diarrhea that is secretory, bloody, and leukocytic (inflammatory diarrhea).

(Choice C) Irritable bowel syndrome is a functional intestinal disorder that presents with diarrhea alternating with constipation, abdominal pain, and distension without organic cause. Fecal water and electrolyte content are normal.

(Choice E) Rectal prolapse is a protrusion of rectal mucosa through the anus associated with pregnancy and constipation; the risk is also increased in patients with chronic diarrhea.

Educational objective:
Polyethylene glycol is an osmotic laxative. Primary lactose intolerance is associated with the inability to digest lactose. The high osmotic load from intraluminal accumulation of lactose can lead to watery diarrhea.

69213.mp4
https://t.me/USMLEWorldStep1
Show all

A 46-year-old woman comes to the office due to dysphagia. The patient has had difficulty swallowing both liquids and solid foods as well as frequent episodes of regurgitation and cough while eating. She has also had weakness in her extremities and a rash. The patient has no prior medical problems and takes no medications. Vital signs are within normal limits. Physical examination shows an erythematous eruption on the upper eyelids. The oropharynx is clear and cardiopulmonary and abdominal examinations are unremarkable. She has difficulty lifting her arms above her head and standing from a sitting position. Which of the following is the most likely cause of this patient's dysphagia?

- A. Atrophy and fibrous replacement of the distal esophageal muscularis propria
- B. Diffuse eosinophil-predominant inflammation of the esophageal mucosa
- C. Inflammation and degeneration of the esophageal myenteric plexus
- D. Outpouching of hypopharyngeal mucosa through weakened muscle
- E. Perifascicular atrophy of muscle fibers in the proximal esophageal muscularis propria

Submit

69213.mp4
https://t.me/USMLEWorldStep1
Show all

A 46-year-old woman comes to the office due to dysphagia. The patient has had difficulty swallowing both liquids and solid foods as well as frequent episodes of regurgitation and cough while eating. She has also had weakness in her extremities and a rash. The patient has no prior medical problems and takes no medications. Vital signs are within normal limits. Physical examination shows an erythematous eruption on the upper eyelids. The oropharynx is clear and cardiopulmonary and abdominal examinations are unremarkable. She has difficulty lifting her arms above her head and standing from a sitting position. Which of the following is the most likely cause of this patient's dysphagia?

- A. Atrophy and fibrous replacement of the distal esophageal muscularis propria (24%)
- ✗ B. Diffuse eosinophil-predominant inflammation of the esophageal mucosa (7%)
- C. Inflammation and degeneration of the esophageal myenteric plexus (18%)
- D. Outpouching of hypopharyngeal mucosa through weakened muscle (2%)
- ✓ E. Perifascicular atrophy of muscle fibers in the proximal esophageal muscularis propria (46%)

Incorrect
Correct answer
E

46%
Answered correctly

03 secs
Time Spent

2023
Version

Explanation

This patient has painless **proximal muscle weakness**; in association with the heliotrope **rash** on her eyelids, this presentation is consistent with **dermatomyositis**, an inflammatory myopathy that primarily affects **striated muscle** and skin. Diagnostic findings include elevated muscle enzymes (eg, creatinine kinase) and positive autoantibodies (ie, antinuclear antibody [high sensitivity, low specificity], anti–Jo-1 [low sensitivity, high specificity]). Muscle biopsy in dermatomyositis shows perimysial inflammatory infiltrates and atrophy involving the fibers around the periphery of muscle fascicles **(perifascicular atrophy)**.

69213.mp4
https://t.me/USMLEWorldStep1
Show all

This patient has painless **proximal muscle weakness**; in association with the heliotrope **rash** on her eyelids, this presentation is consistent with **dermatomyositis**, an inflammatory myopathy that primarily affects **striated muscle** and skin. Diagnostic findings include elevated muscle enzymes (eg, creatinine kinase) and positive autoantibodies (ie, antinuclear antibody [high sensitivity, low specificity], anti–Jo-1 [low sensitivity, high specificity]). Muscle biopsy in dermatomyositis shows perimysial inflammatory infiltrates and atrophy involving the fibers around the periphery of muscle fascicles **(perifascicular atrophy)**.

The **oropharynx and upper esophagus** also contain skeletal muscle that can be affected in dermatomyositis and polymyositis, leading to **dysphagia** and pulmonary aspiration. Other important complications of inflammatory myopathies include interstitial lung disease and **myocarditis** (due to involvement of striated cardiac muscle).

(Choice A) Progressive systemic sclerosis (scleroderma) commonly affects the esophagus, leading to atrophy and fibrous replacement of the distal esophageal muscularis propria. Clinical features include dysphagia, reflux esophagitis, and aspiration. However, the dermal manifestations include sclerodactyly, digital ulcers, and calcinosis cutis, rather than a heliotrope rash. Also, dermatomyositis affects only the striated muscle in the oropharynx and upper esophagus (eg, choking, aspiration), whereas scleroderma can affect the lower esophagus.

(Choice B) Eosinophilic esophagitis typically presents with dysphagia, epigastric pain, recurrent esophageal reflux, and food impaction. Skin rash and extremity weakness would be unexpected.

(Choice C) Achalasia is caused by inflammation and degeneration of the esophageal myenteric plexus, resulting in impaired relaxation of the smooth muscle in the distal esophagus and lower esophageal sphincter. It typically presents with dysphagia, regurgitation, and heartburn but is not associated with rash or skeletal muscle weakness.

(Choice D) Zenker diverticulum develops immediately above the upper esophageal sphincter, with posterior mucosal herniation between the fibers of the cricopharyngeus muscle. Although it presents with dysphagia, regurgitation, and aspiration, it is not associated with rash or muscular weakness.

Educational objective:
Dermatomyositis is characterized by proximal muscle weakness resembling polymyositis, with additional

69213.mp4
https://t.me/USMLEWorldStep1
Show all

and skin. Diagnostic findings include elevated muscle enzymes (eg, creatinine kinase) and positive autoantibodies (ie, antinuclear antibody [high sensitivity, low specificity], anti–Jo-1 [low sensitivity, high specificity]). Muscle biopsy in dermatomyositis shows perimysial inflammatory infiltrates and atrophy involving the fibers around the periphery of muscle fascicles **(perifascicular atrophy)**.

The **oropharynx and upper esophagus** also contain skeletal muscle that can be affected in dermatomyositis and polymyositis, leading to **dysphagia** and pulmonary aspiration. Other important complications of inflammatory myopathies include interstitial lung disease and **myocarditis** (due to involvement of striated cardiac muscle).

(Choice A) Progressive systemic sclerosis (scleroderma) commonly affects the esophagus, leading to atrophy and fibrous replacement of the distal esophageal muscularis propria. Clinical features include dysphagia, reflux esophagitis, and aspiration. However, the dermal manifestations include sclerodactyly, digital ulcers, and calcinosis cutis, rather than a heliotrope rash. Also, dermatomyositis affects only the striated muscle in the oropharynx and upper esophagus (eg, choking, aspiration), whereas scleroderma can affect the lower esophagus.

(Choice B) Eosinophilic esophagitis typically presents with dysphagia, epigastric pain, recurrent esophageal reflux, and food impaction. Skin rash and extremity weakness would be unexpected.

(Choice C) Achalasia is caused by inflammation and degeneration of the esophageal myenteric plexus, resulting in impaired relaxation of the smooth muscle in the distal esophagus and lower esophageal sphincter. It typically presents with dysphagia, regurgitation, and heartburn but is not associated with rash or skeletal muscle weakness.

(Choice D) Zenker diverticulum develops immediately above the upper esophageal sphincter, with posterior mucosal herniation between the fibers of the cricopharyngeus muscle. Although it presents with dysphagia, regurgitation, and aspiration, it is not associated with rash or muscular weakness.

Educational objective:
Dermatomyositis is characterized by proximal muscle weakness resembling polymyositis, with additional inflammatory features affecting the skin (eg, heliotrope rash, Gottron papules). In both conditions, involvement of striated muscle in the oropharynx and heart can lead to dysphagia, pulmonary aspiration, and myocarditis.

69213.mp4
https://t.me/USMLEWorldStep1
Show all

A 43-year-old man comes to the office due to yellowing of the skin over the past few weeks. He has had no fever or abdominal pain and has not traveled recently or received blood transfusions. The patient has also experienced increased shortness of breath with exercise over the last several months. He has no other medical conditions and takes no medications. The patient drinks 1 or 2 glasses of wine on social occasions and does not use tobacco or illicit drugs. His father died of liver cirrhosis attributed to heavy alcohol use. On physical examination, expiration is prolonged and there are scattered wheezes bilaterally. Laboratory results show total bilirubin of 4.1 mg/dL and alanine aminotransferase of 90 U/L. Viral hepatitis serology is negative. Chest x-ray shows hyperlucency of the lungs and flattening of the diaphragm. Abdominal ultrasound reveals increased liver span and echogenicity of the liver parenchyma but no masses. Which of the following is the most likely underlying cause of this patient's symptoms?

- A. Autoimmune injury of the intrahepatic bile ducts
- B. Decreased UDP-glucuronosyltransferase activity
- C. Defective chloride transport at epithelial surfaces
- D. Defective transport and accumulation of copper
- E. Inherited deficiency of a serine protease inhibitor
- F. Unregulated gastrointestinal iron absorption

Submit

69213.mp4
https://t.me/USMLEWorldStep1
Show all

A 43-year-old man comes to the office due to yellowing of the skin over the past few weeks. He has had no fever or abdominal pain and has not traveled recently or received blood transfusions. The patient has also experienced increased shortness of breath with exercise over the last several months. He has no other medical conditions and takes no medications. The patient drinks 1 or 2 glasses of wine on social occasions and does not use tobacco or illicit drugs. His father died of liver cirrhosis attributed to heavy alcohol use. On physical examination, expiration is prolonged and there are scattered wheezes bilaterally. Laboratory results show total bilirubin of 4.1 mg/dL and alanine aminotransferase of 90 U/L. Viral hepatitis serology is negative. Chest x-ray shows hyperlucency of the lungs and flattening of the diaphragm. Abdominal ultrasound reveals increased liver span and echogenicity of the liver parenchyma but no masses. Which of the following is the most likely underlying cause of this patient's symptoms?

- A. Autoimmune injury of the intrahepatic bile ducts (8%)
- ✗ B. Decreased UDP-glucuronosyltransferase activity (10%)
- C. Defective chloride transport at epithelial surfaces (5%)
- D. Defective transport and accumulation of copper (4%)
- ✓ E. Inherited deficiency of a serine protease inhibitor (64%)
- F. Unregulated gastrointestinal iron absorption (5%)

Incorrect
Correct answer
E

64%
Answered correctly

03 secs
Time Spent

2023
Version

Explanation

Alpha-1 antitrypsin deficiency

69213.mp4
https://t.me/USMLEWorldStep1
Show all

alanine aminotransferase of 90 U/L. Viral hepatitis serology is negative. Chest x-ray shows hyperlucency of the lungs
liver p
sympt

Exhibit Display

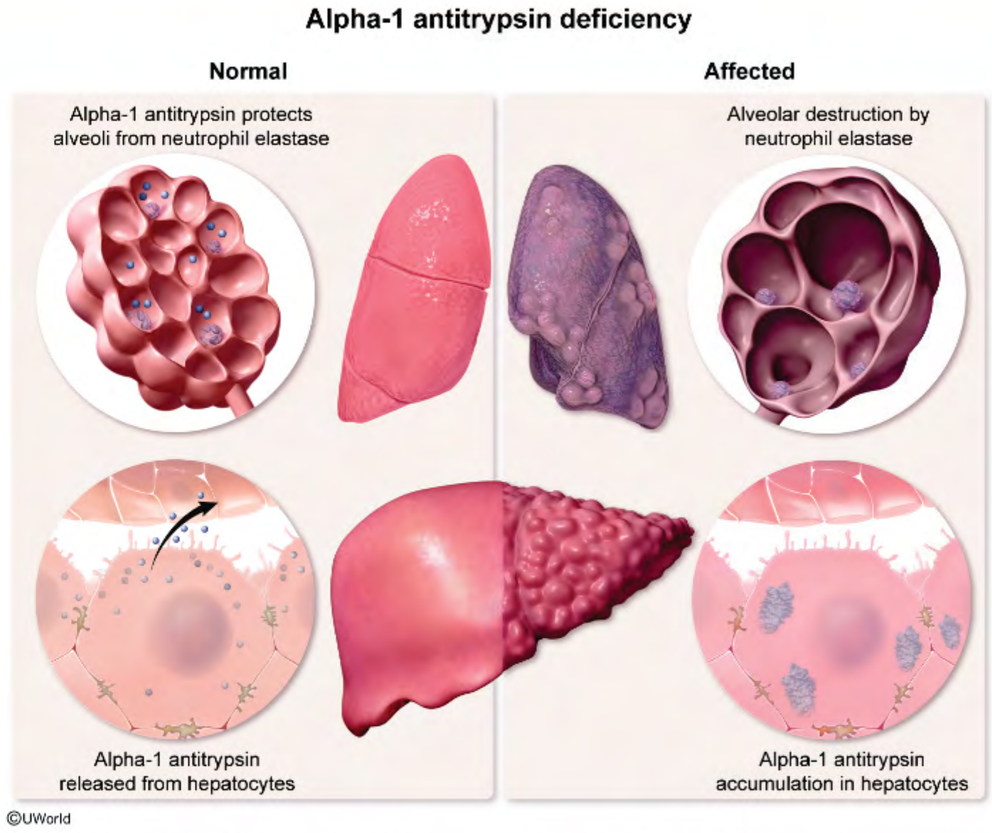

Zoom In Zoom Out Reset New | Existing My Notebook

Inco
Corre
E

Expl

69213.mp4

https://t.me/USMLEWorldStep1

Show all

Alpha-1 antitrypsin released from hepatocytes

Alpha-1 antitrypsin accumulation in hepatocytes

©UWorld

This patient with signs of liver dysfunction (ie, jaundice, transaminitis) and evidence of **emphysema** on chest x-ray (eg, hyperlucency, diaphragmatic flattening) likely has **alpha-1 antitrypsin deficiency** (AATD). Alpha-1 antitrypsin is a serine **protease inhibitor** that regulates the activity of a number of tissue-destructive proteases, most importantly neutrophil **elastase**. Deficiency is inherited in an autosomal codominant fashion.

AATD leads to unchecked elastase activity in the lungs, resulting in alveolar destruction and lung hyperinflation; the panacinar emphysema tends to favor the basilar lung regions and typically develops prior to age 50. In addition, some patients are at risk for developing **liver disease** due to accumulation of improperly folded alpha-1 antitrypsin proteins in hepatocytes. Liver disease is of greatest concern in the first 2 decades of life, but it can present at any age. Patients can experience hepatomegaly, hyperbilirubinemia, elevated transaminases, and eventual cirrhosis and end-stage liver disease. Hepatocellular carcinoma may also develop.

(Choice A) Autoimmune injury of intrahepatic bile ducts occurs in primary biliary cholangitis (PBC). PBC predominantly affects women and is characterized by positive antimitochondrial antibodies. It is not associated with emphysema.

(Choice B) UDP-glucuronosyltransferase is an enzyme that converts unconjugated bilirubin to its conjugated form, and inherited deficiency can exist in varying degrees. Mild deficiency results in benign elevations in unconjugated bilirubin during periods of stress (ie, Gilbert syndrome), while severe deficiency can be fatal during infancy (ie, Crigler-Najjar syndrome type I).

(Choice C) Defective epithelial chloride transport occurs in cystic fibrosis. Patients typically develop obstructive lung disease in the form of bronchiectasis and can have pancreatic insufficiency leading to malabsorption. Cirrhosis can sometimes occur due to chronic obstruction of the biliary ducts, but almost always develops during childhood.

(Choice D) Defective copper transport resulting in accumulation of intracellular copper occurs in Wilson disease. Patients can develop cirrhosis as well as brain degeneration leading to neurologic (eg, dysarthria, gait

69213.mp4
https://t.me/USMLEWorldStep1
Show all

proteins in hepatocytes. Liver disease is of greatest concern in the first 2 decades of life, but it can present at any age. Patients can experience hepatomegaly, hyperbilirubinemia, elevated transaminases, and eventual cirrhosis and end-stage liver disease. Hepatocellular carcinoma may also develop.

(Choice A) Autoimmune injury of intrahepatic bile ducts occurs in primary biliary cholangitis (PBC). PBC predominantly affects women and is characterized by positive antimitochondrial antibodies. It is not associated with emphysema.

(Choice B) UDP-glucuronosyltransferase is an enzyme that converts unconjugated bilirubin to its conjugated form, and inherited deficiency can exist in varying degrees. Mild deficiency results in benign elevations in unconjugated bilirubin during periods of stress (ie, Gilbert syndrome), while severe deficiency can be fatal during infancy (ie, Crigler-Najjar syndrome type I).

(Choice C) Defective epithelial chloride transport occurs in cystic fibrosis. Patients typically develop obstructive lung disease in the form of bronchiectasis and can have pancreatic insufficiency leading to malabsorption. Cirrhosis can sometimes occur due to chronic obstruction of the biliary ducts, but almost always develops during childhood.

(Choice D) Defective copper transport resulting in accumulation of intracellular copper occurs in Wilson disease. Patients can develop cirrhosis as well as brain degeneration leading to neurologic (eg, dysarthria, gait abnormalities) and psychiatric (eg, impulsivity) manifestations.

(Choice F) Unregulated gastrointestinal iron absorption occurs in hemochromatosis. Patients can develop cirrhosis due to iron overload. The joints (arthritis), pancreas (diabetes mellitus), and heart (cardiomyopathy) are also commonly affected, but lung involvement is not typical.

Educational objective:
Alpha-1 antitrypsin (AAT) is a serine protease inhibitor that regulates the activity of elastase in the lung. Inherited deficiency of AAT leads to alveolar destruction and panacinar emphysema; in addition, accumulation of improperly folded AAT proteins in hepatocytes can lead to liver dysfunction and cirrhosis in some patients.

References

69213.mp4
https://t.me/USMLEWorldStep1
Show all

Alpha-1 antitrypsin released from hepatocytes

Alpha-1 antitrypsin accumulation in hepatocytes

Exhibit Display

This p
(eg, hy
is a se
import

AATD
panac
some
protei
age. P
and er

(Choi
predor
with e

(Choi
form, a
uncon
infanc

(Choi
lung d
Cirrho
childh

(Choice D) Defective copper transport resulting in accumulation of intracellular copper occurs in Wilson disease. Patients can develop cirrhosis as well as brain degeneration leading to neurologic (eg, dysarthria, gait

Proteinase/antiproteinase balance

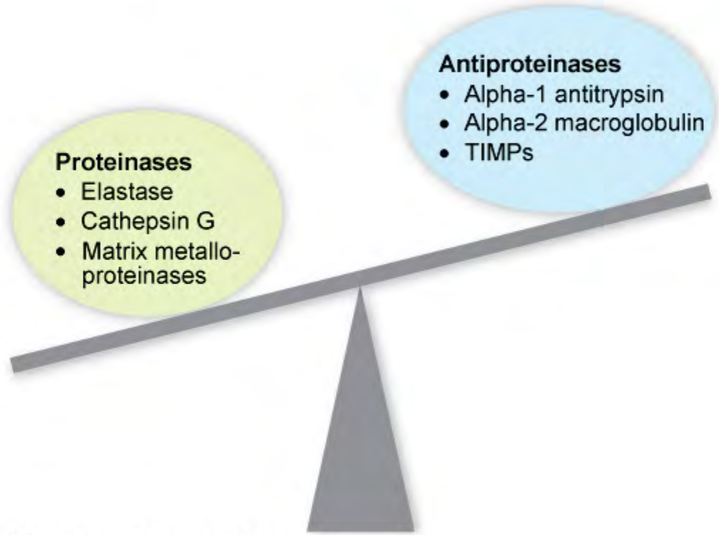

TIMPs = tissue inhibitors of metalloproteinase.
©UWorld

Zoom In | Zoom Out | Reset | New | Existing | My Notebook

69213.mp4
https://t.me/USMLEWorldStep1
Show all

Alpha-1 antitrypsin released from hepatocytes

Alpha-1 antitrypsin accumulation in hepatocytes

Exhibit Display

This p
(eg, hy
is a se
import

AATD
panac
some
protei
age. P
and er

(Choi
predor
with e

(Choi
form, a
uncon
infanc

(Choi
lung d
Cirrho
childh

(Choice D) Defective copper transport resulting in accumulation of intracellular copper occurs in Wilson disease. Patients can develop cirrhosis as well as brain degeneration leading to neurologic (eg, dysarthria, gait

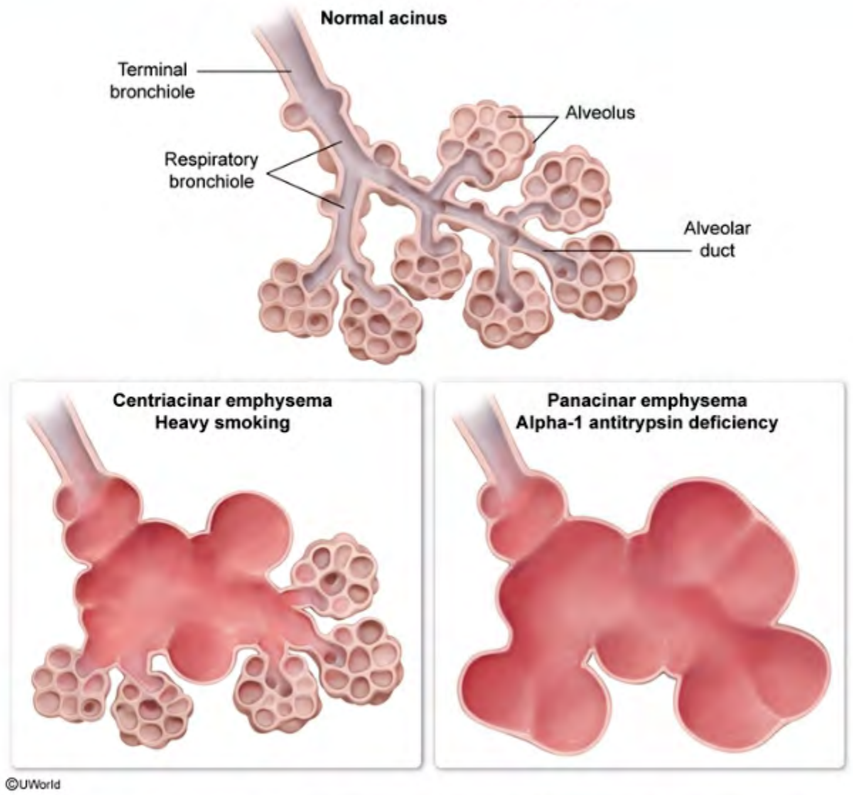

Zoom In Zoom Out Reset New | Existing My Notebook

69213.mp4
https://t.me/USMLEWorldStep1
Show all

Item 35 of 40
Question Id: 400
Mark
Previous Next
Full Screen Tutorial Lab Values Notes Calculator Reverse Color Text Zoom Settings

Alpha-1 antitrypsin released from hepatocytes

Alpha-1 antitrypsin accumulation in hepatocytes

This p
(eg, hy
is a se
import
AATD
panac
some
protein
age. F
and er
(Choi
predor
with er
(Choi
form, a
uncon
infancy
(Choi
lung d
Cirrho
childh
(Choi
Patien

Exhibit Display

Bilirubin metabolism

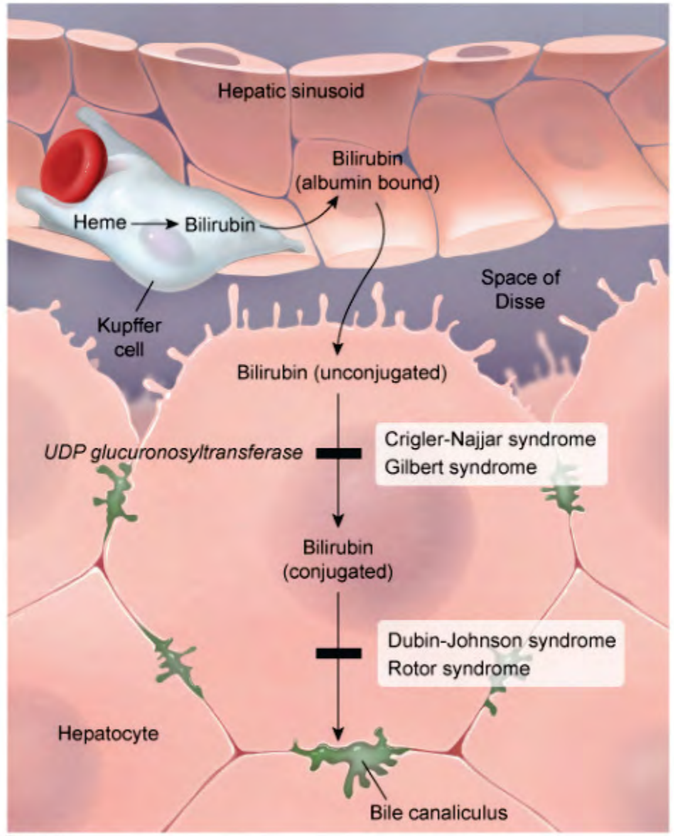

©UWorld

Zoom In Zoom Out Reset New | Existing My Notebook

https://t.me/USMLEWorldStep1

An 18-year-old man is admitted to the hospital with cough, fever, and hypoxemia. Despite multiple intravenous antibiotics and frequent chest physiotherapy, the patient decompensates and is transferred to the intensive care unit for mechanical ventilation. Sputum cultures grow >100,000 colony-forming units of a non-lactose-fermenting gram-negative rod. After several days, the patient dies of overwhelming pneumonia complicated by respiratory failure. Since age 1, he had been hospitalized for recurrent episodes of multi-lobar pneumonia, sinusitis, and poor growth. On autopsy, both vas deferens are absent. Which of the following findings is also likely to be present on autopsy?

- A. Distension and obstruction of pancreatic ducts
- B. Lobar sequestration
- C. Lymphocytic infiltrate of pancreatic islet cells
- D. Nodular lymphoid hyperplasia in the intestine
- E. Situs inversus

Submit

69213.mp4
https://t.me/USMLEWorldStep1
Show all

An 18-year-old man is admitted to the hospital with cough, fever, and hypoxemia. Despite multiple intravenous antibiotics and frequent chest physiotherapy, the patient decompensates and is transferred to the intensive care unit for mechanical ventilation. Sputum cultures grow >100,000 colony-forming units of a non-lactose-fermenting gram-negative rod. After several days, the patient dies of overwhelming pneumonia complicated by respiratory failure. Since age 1, he had been hospitalized for recurrent episodes of multi-lobar pneumonia, sinusitis, and poor growth. On autopsy, both vas deferens are absent. Which of the following findings is also likely to be present on autopsy?

- ✓ A. Distension and obstruction of pancreatic ducts (69%)
- ✗ B. Lobar sequestration (1%)
- C. Lymphocytic infiltrate of pancreatic islet cells (3%)
- D. Nodular lymphoid hyperplasia in the intestine (1%)
- E. Situs inversus (24%)

Incorrect
Correct answer
A

69%
Answered correctly

03 secs
Time Spent

2023
Version

Explanation

Clinical features of CF	
Respiratory	• Obstructive lung disease → bronchiectasis • Recurrent pneumonia • Chronic rhinosinusitis

69213.mp4
https://t.me/USMLEWorldStep1
Show all

Clinical features of CF	
Respiratory	• Obstructive lung disease → bronchiectasis • Recurrent pneumonia • Chronic rhinosinusitis

Gastrointestinal	• Obstruction (10%-20%)
	  ◦ Meconium ileus
	  ◦ Distal intestinal obstruction syndrome
	• Pancreatic disease
	  ◦ Exocrine pancreatic insufficiency
	  ◦ CF-related diabetes (~25%)
	• Biliary cirrhosis

Reproductive	• Infertility (>95% men, ~20% women)
Musculoskeletal	• Osteopenia → fractures • Kyphoscoliosis • Digital clubbing
CF = cystic fibrosis.	

Cystic fibrosis transmembrane conductance regulator (CFTR) normally allows for transport of chloride into gastrointestinal and respiratory lumens, followed by sodium and water, leading to thin mucus. In cystic fibrosis (CF), the dysfunctional or absent *CFTR* gene leads to decreased water within the lumen, resulting in **thick, dehydrated, and viscous mucus** within organs.

This patient's **recurrent sinopulmonary infections** and **congenital absence of the vas deferens** are consistent with CF. Pneumonia due to a non-lactose-fermenting, gram-negative rod (*Pseudomonas aeruginosa* or *Burkholderia cepacia*) is very common.

69213.mp4
https://t.me/USMLEWorldStep1
Show all

Cystic fibrosis transmembrane conductance regulator (CFTR) normally allows for transport of chloride into gastrointestinal and respiratory lumens, followed by sodium and water, leading to thin mucus. In cystic fibrosis (CF), the dysfunctional or absent *CFTR* gene leads to decreased water within the lumen, resulting in **thick, dehydrated, and viscous mucus** within organs.

This patient's **recurrent sinopulmonary infections** and **congenital absence of the vas deferens** are consistent with CF. Pneumonia due to a non-lactose-fermenting, gram-negative rod (*Pseudomonas aeruginosa* or *Burkholderia cepacia*) is very common.

The most common gastrointestinal manifestation of CF is **pancreatic insufficiency (PI)**. Pancreatic duct obstruction and distension due to viscous mucus and subsequent inflammation develop in utero, eventually leading to fibrosis. PI is present from birth in most patients with CF. The loss of pancreatic tissue prevents these patients from developing pancreatitis. PI results in inability to absorb fats and fat-soluble vitamins (ADEK), leading to **steatorrhea** and **failure to thrive**. Patients with PI require **pancreatic enzyme supplementation**.

(Choice B) Bronchopulmonary sequestration is a congenital malformation characterized by extra, nonfunctional lung tissue without communication to the tracheobronchial tree. The extra tissue can be within a lung lobe or outside of the lungs and can present as recurrent pneumonia in the same focal site.

(Choice C) Lymphocytic infiltration of pancreatic islet cells is seen in the pathogenesis of type 1 diabetes mellitus. One or more autoantigens within these cells serves as a target for autoimmune attack, eventually leading to destruction of insulin-producing pancreatic cells.

(Choice D) Nodular lymphoid hyperplasia of the intestine is classically seen in common variable immunodeficiency syndrome (CVID), a disorder of low immunoglobulin and B lymphocyte levels that predisposes to recurrent sinopulmonary and gastrointestinal infections. Congenital absence of the vas deferens is not associated with CVID.

(Choice E) Situs inversus refers to transposition of the major internal organs (eg, dextrocardia). It is associated with primary ciliary dyskinesia (or Kartagener syndrome), in which inefficient cilia in multiple organs fail to beat synchronously and clear mucus. Recurrent sinopulmonary infections and bronchiectasis result, but absence of the

69213.mp4
https://t.me/USMLEWorldStep1
Show all

Burkholderia cepacia) is very common.

The most common gastrointestinal manifestation of CF is **pancreatic insufficiency (PI)**. Pancreatic duct obstruction and distension due to viscous mucus and subsequent inflammation develop in utero, eventually leading to fibrosis. PI is present from birth in most patients with CF. The loss of pancreatic tissue prevents these patients from developing pancreatitis. PI results in inability to absorb fats and fat-soluble vitamins (ADEK), leading to **steatorrhea** and **failure to thrive**. Patients with PI require **pancreatic enzyme supplementation**.

(Choice B) Bronchopulmonary sequestration is a congenital malformation characterized by extra, nonfunctional lung tissue without communication to the tracheobronchial tree. The extra tissue can be within a lung lobe or outside of the lungs and can present as recurrent pneumonia in the same focal site.

(Choice C) Lymphocytic infiltration of pancreatic islet cells is seen in the pathogenesis of type 1 diabetes mellitus. One or more autoantigens within these cells serves as a target for autoimmune attack, eventually leading to destruction of insulin-producing pancreatic cells.

(Choice D) Nodular lymphoid hyperplasia of the intestine is classically seen in common variable immunodeficiency syndrome (CVID), a disorder of low immunoglobulin and B lymphocyte levels that predisposes to recurrent sinopulmonary and gastrointestinal infections. Congenital absence of the vas deferens is not associated with CVID.

(Choice E) Situs inversus refers to transposition of the major internal organs (eg, dextrocardia). It is associated with primary ciliary dyskinesia (or Kartagener syndrome), in which inefficient cilia in multiple organs fail to beat synchronously and clear mucus. Recurrent sinopulmonary infections and bronchiectasis result, but absence of the vas deferens does not occur.

Educational objective:
The most common gastrointestinal disorder in patients with cystic fibrosis is pancreatic insufficiency. Mutations in the cystic fibrosis transmembrane conductance regulator gene lead to thick, viscous secretions in the lumens of the pancreas, resulting in obstruction, inflammation, and subsequent fibrosis. Clinical manifestations include steatorrhea, failure to thrive, and deficiency of fat-soluble vitamins.

69213.mp4
https://t.me/USMLEWorldStep1
Show all

A 52-year-old woman comes to the office with a 2-month history of skin rash that worsens with sun exposure. Her family says that lately she has become irritable and hostile and has had episodes of disorientation. The patient does not use tobacco or recreational drugs but has been drinking a half bottle of gin daily. Further questioning reveals poor nutritional intake and intermittent diarrhea. The patient restricts her diet for weight control. BMI is 17 kg/m^2. On examination, she has a well-demarcated, hyperpigmented, scaly rash on the hands, forearms, and upper chest. It is determined that the patient is deficient in a vitamin that is used to synthesize the NAD^+ coenzyme. Which of the following substances can also be used as a precursor during production of this coenzyme?

- A. Arginine
- B. Carotene
- C. Cholesterol
- D. Orotic acid
- E. Phenylalanine
- F. Tryptophan

Submit

69213.mp4
https://t.me/USMLEWorldStep1
Show all

A 52-year-old woman comes to the office with a 2-month history of skin rash that worsens with sun exposure. Her family says that lately she has become irritable and hostile and has had episodes of disorientation. The patient does not use tobacco or recreational drugs but has been drinking a half bottle of gin daily. Further questioning reveals poor nutritional intake and intermittent diarrhea. The patient restricts her diet for weight control. BMI is 17 kg/m^2. On examination, she has a well-demarcated, hyperpigmented, scaly rash on the hands, forearms, and upper chest. It is determined that the patient is deficient in a vitamin that is used to synthesize the NAD^+ coenzyme. Which of the following substances can also be used as a precursor during production of this coenzyme?

- A. Arginine (16%)
- ✗ B. Carotene (8%)
- C. Cholesterol (2%)
- D. Orotic acid (7%)
- E. Phenylalanine (10%)
- ✓ F. Tryptophan (54%)

Incorrect
Correct answer
F

54%
Answered correctly

03 secs
Time Spent

2023
Version

Explanation

Niacin metabolism

Diet

69213.mp4
https://t.me/USMLEWorldStep1
Show all

Exhibit Display

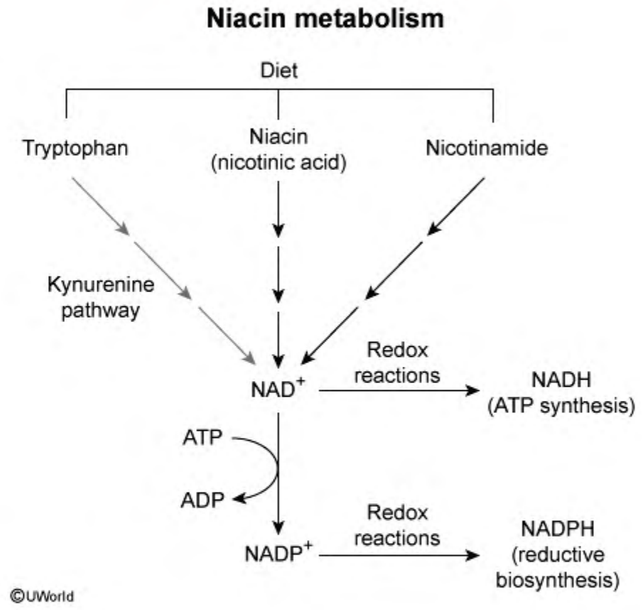

Zoom In Zoom Out Reset New | Existing My Notebook

scaly skin.

69213.mp4
https://t.me/USMLEWorldStep1
Show all



©UWorld

Pellagra ("rough skin" in Italian vernacular) is due to **niacin deficiency** and is characterized by 3 Ds: dermatitis, diarrhea, and dementia:

- Dermatitis is bilateral and symmetric on sun-exposed areas of the body and is characterized by rough, thick, scaly skin.
- **Diarrhea** is due to atrophy (and occasional ulceration) of columnar epithelium of the gastrointestinal tract.
- **Dementia** is due to neuronal degeneration in the brain and spinal cord, with lesions like those associated with pernicious anemia.

Niacin (nicotinic acid, or vitamin B_3) is an essential component of the **coenzymes NAD and NADP**, which participate in redox metabolism. Specifically, NAD functions as a coenzyme for dehydrogenases involved in the metabolism of fats, carbohydrates, and amino acids; NADP is crucial in the hexose-monophosphate shunt of glucose metabolism and for biosynthesis of cholesterol and fatty acids.

Niacin can be obtained through dietary intake or **synthesized endogenously** from **tryptophan**. In developing countries, niacin deficiency is seen in populations that subsist primarily on corn products (niacin in corn occurs in a bound, unabsorbable form). In developed countries, it is primarily seen in patients with impaired nutritional intake (eg, alcohol use disorder, chronic illness). Pellagra can also be seen occasionally in those with carcinoid syndrome, prolonged isoniazid therapy, or Hartnup disease.

(Choice A) Arginine is a nonessential amino acid and a precursor of nitric oxide, urea, ornithine, and agmatine. It is also necessary for the formation of creatine.

(Choice B) Carotene is the precursor to vitamin A. Carotene deficiency may result in night blindness and immune dysfunction.

(Choice C) Cholesterol is the precursor to steroid hormones.

(Choice D) Orotic acid is a precursor of pyrimidine. Hereditary orotic aciduria occurs due to impairment of the

69213.mp4
https://t.me/USMLEWorldStep1
Show all

Niacin (nicotinic acid, or vitamin B_3) is an essential component of the **coenzymes NAD and NADP**, which participate in redox metabolism. Specifically, NAD functions as a coenzyme for dehydrogenases involved in the metabolism of fats, carbohydrates, and amino acids; NADP is crucial in the hexose-monophosphate shunt of glucose metabolism and for biosynthesis of cholesterol and fatty acids.

Niacin can be obtained through dietary intake or **synthesized endogenously** from **tryptophan**. In developing countries, niacin deficiency is seen in populations that subsist primarily on corn products (niacin in corn occurs in a bound, unabsorbable form). In developed countries, it is primarily seen in patients with impaired nutritional intake (eg, alcohol use disorder, chronic illness). Pellagra can also be seen occasionally in those with carcinoid syndrome, prolonged isoniazid therapy, or Hartnup disease.

(Choice A) Arginine is a nonessential amino acid and a precursor of nitric oxide, urea, ornithine, and agmatine. It is also necessary for the formation of creatine.

(Choice B) Carotene is the precursor to vitamin A. Carotene deficiency may result in night blindness and immune dysfunction.

(Choice C) Cholesterol is the precursor to steroid hormones.

(Choice D) Orotic acid is a precursor of pyrimidine. Hereditary orotic aciduria occurs due to impairment of the enzyme uridine monophosphate synthetase, which synthesizes pyrimidines from orotic acid. The accumulation of orotic acid leads to megaloblastic anemia, developmental delay, and failure to thrive.

(Choice E) Phenylalanine is an essential amino acid and the precursor to tyrosine, an amino acid necessary for the formation of catecholamines. Phenylketonuria (PKU) occurs due to impairment of the enzyme phenylalanine hydroxylase, which synthesizes tyrosine from phenylalanine.

Educational objective:
Niacin (vitamin B_3) can be synthesized endogenously from tryptophan and is an essential component of NAD and NADP. A deficiency of this vitamin results in pellagra, which is characterized by dermatitis, diarrhea, and dementia.

References

69213.mp4
https://t.me/USMLEWorldStep1
Show all

(ATP synthesis)

ATP

Exhibit Display

Niacin deficiency (pellagra)

*Sun-exposed skin.

©UWorld

Zoom In | Zoom Out | Reset | New | Existing | My Notebook

Pellag
diarrhe

- D
- **D**
- **D**

Niacin
particip
metab
glucos

Niacin
countr
bound
(eg, al
syndro

(Choi
is also

(Choice B) Carotene is the precursor to vitamin A. Carotene deficiency may result in night blindness and immune

69213.mp4
https://t.me/USMLEWorldStep1
Show all

A 36-year-old woman comes to the office due to vague epigastric abdominal pain, occasional nausea, and bloating. She has no associated weight loss. Medical history is notable for moderate obesity and chronic allergic rhinitis. The patient takes no medications and does not use tobacco, alcohol, or illicit drugs. She was a vegetarian for several years but now consumes a wide variety of foods, including meat products. The patient has traveled abroad extensively in the past. Vital signs are normal. Examination shows mild epigastric tenderness to deep palpation. Laboratory results reveal mild anemia. Upper gastrointestinal endoscopy shows diffuse erythema of the antral mucosa. Biopsy reveals an inflammatory cell infiltrate involving the superficial mucosal layers. The underlying cause of this patient's current condition can also lead to which of the following?

- A. Gastric lymphoma
- B. Gastroparesis
- C. Gluten intolerance
- D. Ileal obstruction
- E. Pernicious anemia

Submit

69213.mp4
https://t.me/USMLEWorldStep1
Show all

A 36-year-old woman comes to the office due to vague epigastric abdominal pain, occasional nausea, and bloating. She has no associated weight loss. Medical history is notable for moderate obesity and chronic allergic rhinitis. The patient takes no medications and does not use tobacco, alcohol, or illicit drugs. She was a vegetarian for several years but now consumes a wide variety of foods, including meat products. The patient has traveled abroad extensively in the past. Vital signs are normal. Examination shows mild epigastric tenderness to deep palpation. Laboratory results reveal mild anemia. Upper gastrointestinal endoscopy shows diffuse erythema of the antral mucosa. Biopsy reveals an inflammatory cell infiltrate involving the superficial mucosal layers. The underlying cause of this patient's current condition can also lead to which of the following?

- ✓ A. Gastric lymphoma (55%)
- ✗ B. Gastroparesis (2%)
- C. Gluten intolerance (6%)
- D. Ileal obstruction (1%)
- E. Pernicious anemia (33%)

Incorrect
Correct answer
A

55%
Answered correctly

03 secs
Time Spent

2023
Version

Explanation

Atrophic gastritis		
	***Helicobacter pylori*–induced chronic gastritis**	**Autoimmune gastritis**

69213.mp4
https://t.me/USMLEWorldStep1
Show all

Explanation

Atrophic gastritis		
	***Helicobacter pylori*–induced chronic gastritis**	**Autoimmune gastritis**
Distribution	Multifocal; patchy	Corpus; diffuse (spares antrum)
Inflammatory cells	Neutrophils, plasma cells, lymphocytes	Lymphocytes, macrophages
Gastrin level	Normal or ↑	↑
Acid production	Normal or ↓	↓
Sequelae	Gastric ulcer*	Vitamin B_{12} deficiency/pernicious anemia
Associated malignancy	Adenocarcinoma, MALT lymphoma	Adenocarcinoma, carcinoid
Risk factors	Living in resource-limited area	Other autoimmune diseases
*Long-standing *H pylori* infection is more associated with gastric ulcers; initial infection is more associated with duodenal ulcers. **MALT** = mucosa-associated lymphoid tissue.		

69213.mp4
https://t.me/USMLEWorldStep1
Show all

This patient with **antral-predominant** gastritis likely has an **acute** *Helicobacter pylori* infection, which typically presents as nonatrophic gastritis. Destruction of somatostatin-producing cells in the antrum leads to **unchecked gastrin secretion** and results in excess production of stomach acid and an increased risk of **duodenal ulcers**.

If left untreated, **chronic** *H pylori* infection typically **spreads** to involve the corpus (body) and fundus of the stomach and is characterized by patchy, **multifocal gastric atrophy** with intestinal metaplasia. Patchy destruction of parietal and G cells results in **diminished acid secretion** and hypochlorhydria. Patients with chronic gastritis are less likely to develop duodenal ulcers but due to the associated **chronic inflammation**, they are at increased risk of **gastric ulcers** and malignancy, particularly **gastric lymphoma** (ie, mucosa-associated lymphoid tissue [MALT] lymphoma) and gastric adenocarcinoma.

(Choice B) *H pylori*–associated ulcers can cause gastric outlet obstruction, not gastroparesis, which is commonly due to uncontrolled diabetes or infiltrative diseases (eg, scleroderma).

(Choice C) Celiac disease is an immune-mediated response to a protein in gluten and can cause microcytic anemia due to iron malabsorption. Autoimmune diseases are associated with autoimmune gastritis, not *H pylori* infection.

(Choice D) Ileal obstruction can occur due to Crohn disease, which can also cause abdominal pain and blood-loss anemia. However, *H pylori* infects gastric mucosa; the ileum is typically unaffected.

(Choice E) Unlike chronic *H pylori*-associated atrophic gastritis, which causes patchy atrophy with sparing of some parietal cells (allowing for continued intrinsic factor production and B_{12} absorption), autoimmune gastritis is characterized by diffuse and more complete immune-mediated destruction of parietal cells and intrinsic factor. This results in impaired vitamin B_{12} absorption and pernicious anemia.

Educational objective:
Acute *Helicobacter pylori* infection initially causes nonatrophic antral gastritis and an increased risk for duodenal ulcers. Chronic infection results in patchy, multifocal, atrophic gastritis with loss of parietal cells and G cells in the gastric body; this is associated with decreased acid secretion and an increased risk of gastric ulcers, gastric adenocarcinoma, and MALT lymphoma.

69213.mp4
https://t.me/USMLEWorldStep1
Show all

anemia

Exhibit Display

***Helicobacter pylori* gastritis**

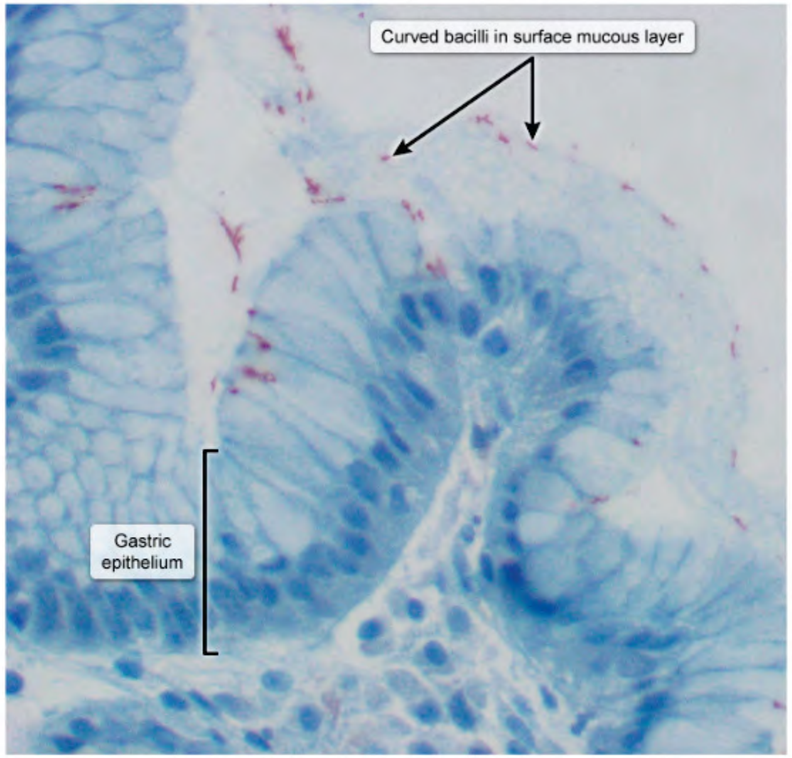

H pylori immunohistochemical stain

©UWorld

Zoom In | Zoom Out | Reset | New | Existing | My Notebook

This p
preser
gastri

If left u
stoma
of pari
are les
risk of
[MALT

(Choi
due to

(Choi
anemi
infecti

(Choice D) Ileal obstruction can occur due to Crohn disease, which can also cause abdominal pain and blood-loss anemia. However, *H pylori* infects gastric mucosa; the ileum is typically unaffected.

69213.mp4
https://t.me/USMLEWorldStep1
Show all

A 62-year-old woman comes to the office for diarrhea. She has had 4 or 5 watery, brown stools every day for the past 6 months. Although most episodes occur during the day, she wakes up at least once a night to defecate. There is no associated hematochezia, melena, vomiting, or unexpected weight loss. Medical history is significant for type 2 diabetes mellitus and hypertension. She takes lisinopril, insulin, and metformin. She has no recent travel or new medications. Family history is unremarkable. She does not drink alcohol. Temperature is 37.4 C (99.3 F), blood pressure is 125/80 mm Hg, and pulse is 80/min. The abdomen is nontender and nondistended. Complete blood count, serum chemistries, and stool studies are normal. Which of the following is the most likely cause of this patient's diarrhea?

- A. Decreased bacterial growth in the colon
- B. Disaccharidase deficiency
- C. Disordered motility of the small bowel and colon
- D. Exocrine pancreatic insufficiency
- E. Transmural intestinal inflammation

Submit

69213.mp4
https://t.me/USMLEWorldStep1
Show all

A 62-year-old woman comes to the office for diarrhea. She has had 4 or 5 watery, brown stools every day for the past 6 months. Although most episodes occur during the day, she wakes up at least once a night to defecate. There is no associated hematochezia, melena, vomiting, or unexpected weight loss. Medical history is significant for type 2 diabetes mellitus and hypertension. She takes lisinopril, insulin, and metformin. She has no recent travel or new medications. Family history is unremarkable. She does not drink alcohol. Temperature is 37.4 C (99.3 F), blood pressure is 125/80 mm Hg, and pulse is 80/min. The abdomen is nontender and nondistended. Complete blood count, serum chemistries, and stool studies are normal. Which of the following is the most likely cause of this patient's diarrhea?

- A. Decreased bacterial growth in the colon (7%)
- ✗ B. Disaccharidase deficiency (14%)
- ✓ C. Disordered motility of the small bowel and colon (55%)
- D. Exocrine pancreatic insufficiency (15%)
- E. Transmural intestinal inflammation (6%)

Incorrect
Correct answer
C

55%
Answered correctly

03 secs
Time Spent

2023
Version

Explanation

Diabetic diarrhea	
Etiology	• Long-standing hyperglycemia damages the autonomic nervous system, resulting in: ◦ Altered intestinal motility ◦ Increased intestinal secretions

69213.mp4
https://t.me/USMLEWorldStep1
Show all

Explanation

Diabetic diarrhea	
Etiology	• Long-standing hyperglycemia damages the autonomic nervous system, resulting in: ◦ Altered intestinal motility ◦ Increased intestinal secretions ◦ ± Fecal incontinence
Risk factors	• Poorly controlled diabetes mellitus • Vascular risk factors (eg, smoking, obesity, hyperlipidemia)
Manifestations	• Painless, watery diarrhea • Secretory-like (persists at night & while fasting) • Laboratory evaluation typically unremarkable

This patient with diabetes mellitus has several months of watery diarrhea that occurs both during the day and at night. In the setting of normal laboratory evaluation, this presentation suggests **diabetic diarrhea** due to **diabetic autonomic neuropathy** (DAN). Long-standing hyperglycemia results in the accumulation of cross-linked glycosylated serum proteins in the vasa nervorum, which causes inflammation and **damage to peripheral nerves**. Although this most commonly results in a distal, symmetric polyneuropathy of the feet, it can also result in damage to **sympathetic and parasympathetic nerves**, leading to autonomic dysfunction. Risk factors include poor glucose control and other vascular risk factors (eg, hypertension, obesity).

Loss of autonomic input to the gastrointestinal tract results in abnormal peristalsis, leading to **disordered small-bowel and colonic motility**, which can result in rapid intestinal transport. Furthermore, intestinal water and electrolyte secretion is increased. **Fecal incontinence** is particularly common in patients with long-standing diabetes, resulting from both a large volume of watery diarrhea and decreased anorectal sensation. Other common gastrointestinal manifestations of DAN include gastroparesis and gastroesophageal reflux.

69213.mp4
https://t.me/USMLEWorldStep1
Show all

This patient with diabetes mellitus has several months of watery diarrhea that occurs both during the day and at night. In the setting of normal laboratory evaluation, this presentation suggests **diabetic diarrhea** due to **diabetic autonomic neuropathy** (DAN). Long-standing hyperglycemia results in the accumulation of cross-linked glycosylated serum proteins in the vasa nervorum, which causes inflammation and **damage to peripheral nerves**. Although this most commonly results in a distal, symmetric polyneuropathy of the feet, it can also result in damage to **sympathetic and parasympathetic nerves**, leading to autonomic dysfunction. Risk factors include poor glucose control and other vascular risk factors (eg, hypertension, obesity).

Loss of autonomic input to the gastrointestinal tract results in abnormal peristalsis, leading to **disordered small-bowel and colonic motility**, which can result in rapid intestinal transport. Furthermore, intestinal water and electrolyte secretion is increased. **Fecal incontinence** is particularly common in patients with long-standing diabetes, resulting from both a large volume of watery diarrhea and decreased anorectal sensation. Other common gastrointestinal manifestations of DAN include gastroparesis and gastroesophageal reflux.

Patients with diabetic diarrhea typically have painless, secretory-like diarrhea that **persists with fasting** (eg, nocturnal diarrhea). Laboratory evaluation, including fecal leukocytes and fecal occult blood testing, is usually unremarkable.

(Choice A) Although altered small-bowel motility related to DAN can predispose to small intestinal bacterial overgrowth, this occurs due to an increase in small bowel bacteria, not a decrease in colonic bacterial burden. It typically causes abdominal bloating, discomfort, and gas. Nocturnal diarrhea is unexpected.

(Choice B) Lactase deficiency can cause osmotic diarrhea after lactose ingestion, leading to postprandial loose stools and bloating. However, unless patients are eating during the night, nocturnal bowel movements would not occur.

(Choice D) Exocrine pancreatic insufficiency (EPI), which is common in chronic pancreatitis or after pancreatic resection, leads to bulky, foul-smelling stool (eg, steatorrhea). Although insulin resistance can mildly impact pancreatic secretions, EPI leading to steatorrhea is rare in diabetes.

69213.mp4
https://t.me/USMLEWorldStep1
Show all

diabetes, resulting from both a large volume of watery diarrhea and decreased anorectal sensation. Other common gastrointestinal manifestations of DAN include gastroparesis and gastroesophageal reflux.

Patients with diabetic diarrhea typically have painless, secretory-like diarrhea that **persists with fasting** (eg, nocturnal diarrhea). Laboratory evaluation, including fecal leukocytes and fecal occult blood testing, is usually unremarkable.

(Choice A) Although altered small-bowel motility related to DAN can predispose to small intestinal bacterial overgrowth, this occurs due to an increase in small bowel bacteria, not a decrease in colonic bacterial burden. It typically causes abdominal bloating, discomfort, and gas. Nocturnal diarrhea is unexpected.

(Choice B) Lactase deficiency can cause osmotic diarrhea after lactose ingestion, leading to postprandial loose stools and bloating. However, unless patients are eating during the night, nocturnal bowel movements would not occur.

(Choice D) Exocrine pancreatic insufficiency (EPI), which is common in chronic pancreatitis or after pancreatic resection, leads to bulky, foul-smelling stool (eg, steatorrhea). Although insulin resistance can mildly impact pancreatic secretions, EPI leading to steatorrhea is rare in diabetes.

(Choice E) Crohn disease, which causes transmural gastrointestinal inflammation, can cause watery diarrhea. However, abdominal pain, anemia, abnormal stool studies (eg, fecal occult blood, fecal calprotectin), and possibly fever are expected.

Educational objective:
Prolonged hyperglycemia in diabetes mellitus can injure the parasympathetic and sympathetic nervous system, resulting in diabetic autonomic neuropathy. This can lead to disordered small-bowel and colonic motility and increased intestinal secretions, resulting in secretory-like diarrhea (eg, fasting bowel movements).

Pathophysiology	Gastrointestinal & Nutrition	Diabetic neuropathy
Subject	System	Topic

Copyright © UWorld. All rights reserved.

69213.mp4
https://t.me/USMLEWorldStep1
Show all

A 58-year-old man is being evaluated for constipation and weight loss over the last several months. During the past 2 weeks, he has had several episodes of rectal bleeding. The patient has never had a screening colonoscopy. Examination shows a soft and nontender abdomen without masses or organomegaly. Digital rectal examination reveals a firm palpable mass in the rectal vault. Flexible rectosigmoidoscopy shows a large ulcerative mass in the middle third of the rectum extending to the rectosigmoid junction. He undergoes surgical resection of the rectosigmoid colon. Frozen section analysis reveals clear margins of the colon specimen with metastases in the pararectal lymph nodes. Which of the following lymph node groups should be sampled in this patient for further assessment of metastatic disease?

- A. Celiac
- B. Internal iliac
- C. Left colic
- D. Right colic
- E. Superficial inguinal
- F. Superior mesenteric
- G. Supraclavicular

Submit

69213.mp4
https://t.me/USMLEWorldStep1
Show all

A 58-year-old man is being evaluated for constipation and weight loss over the last several months. During the past 2 weeks, he has had several episodes of rectal bleeding. The patient has never had a screening colonoscopy. Examination shows a soft and nontender abdomen without masses or organomegaly. Digital rectal examination reveals a firm palpable mass in the rectal vault. Flexible rectosigmoidoscopy shows a large ulcerative mass in the middle third of the rectum extending to the rectosigmoid junction. He undergoes surgical resection of the rectosigmoid colon. Frozen section analysis reveals clear margins of the colon specimen with metastases in the pararectal lymph nodes. Which of the following lymph node groups should be sampled in this patient for further assessment of metastatic disease?

- A. Celiac (1%)
- ✓ B. Internal iliac (53%)
- C. Left colic (18%)
- D. Right colic (1%)
- E. Superficial inguinal (13%)
- F. Superior mesenteric (7%)
- G. Supraclavicular (4%)

Correct

53% Answered correctly

03 secs Time Spent

2023 Version

Explanation

Lymph nodes & vessels of large intestine

69213.mp4
https://t.me/USMLEWorldStep1
Show all

G. Supraclavicular (4%)

Exhibit Display

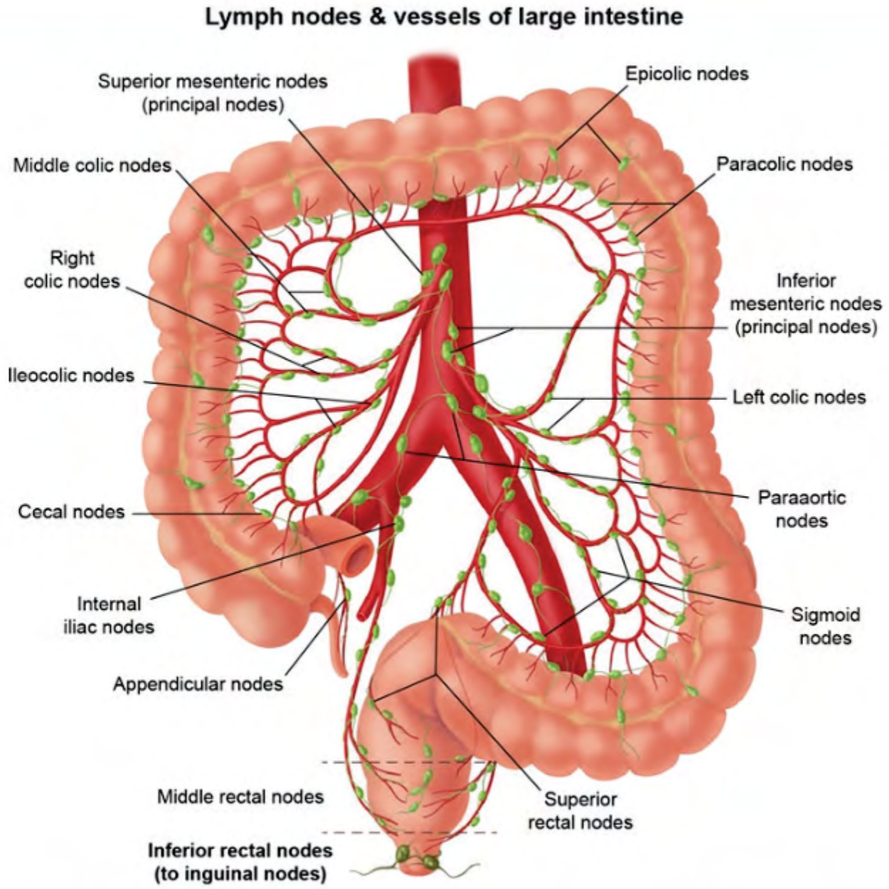

Zoom In | Zoom Out | Reset | New | Existing | My Notebook

69213.mp4

https://t.me/USMLEWorldStep1

Show all

Lymphatic drainage of the colon generally follows the arterial supply. Lymph nodes are located on the bowel wall (epicolic nodes), inner bowel margins along the arterial arcades (paracolic nodes), around the corresponding mesenteric vessels (intermediate nodes), and at the origin of the superior and inferior mesenteric arteries (principal nodes). The sentinel lymph nodes (first 1-4 lymph nodes draining a specific colonic segment) are usually the first site for colon cancer metastasis.

Lymphatic channels **proximal** to the anal **dentate line** drain into the **inferior mesenteric** and **internal iliac lymph nodes**. The upper rectum and superior part of the middle rectum follow the superior rectal nodes along the superior rectal artery into the inferior mesenteric lymph nodes. The middle to lower third of the rectum can drain upward into the inferior mesenteric nodes or follow the middle rectal nodes along the middle rectal artery to the internal iliac lymph nodes. Areas **distal** to the anal dentate line drain primarily into the **inguinal nodes**, although some lymph can also reach the inferior mesenteric and internal iliac nodes.

(Choice A) The celiac lymph nodes are located around the celiac trunk and drain lymph from the gastric, hepatic, and splenic nodes. These in turn drain their respective organ systems (not the colon).

(Choice C) The left colic lymph nodes and their branches are located along the left colic artery and drain the left colonic flexure and upper descending colon.

(Choice D) The right colic lymph nodes are found along the right colic artery and primarily drain the upper ascending colon.

(Choice E) The superficial inguinal lymph nodes lie below the inguinal ligament and are bordered by the sartorius and adductor longus muscles. They drain parts of the genitalia (eg, penis, scrotum, perineum, and vulva), buttocks, anus below the dentate line, and abdominal wall below the umbilicus.

(Choice F) The superior mesenteric lymph nodes (mesenteric, ileocolic, and mesocolic) mainly drain the ileum, jejunum, vermiform process, and parts of the ascending and transverse colon.

69213.mp4
https://t.me/USMLEWorldStep1
Show all

site for colon cancer metastasis.

Lymphatic channels **proximal** to the anal **dentate line** drain into the **inferior mesenteric** and **internal iliac lymph nodes**. The upper rectum and superior part of the middle rectum follow the superior rectal nodes along the superior rectal artery into the inferior mesenteric lymph nodes. The middle to lower third of the rectum can drain upward into the inferior mesenteric nodes or follow the middle rectal nodes along the middle rectal artery to the internal iliac lymph nodes. Areas **distal** to the anal dentate line drain primarily into the **inguinal nodes**, although some lymph can also reach the inferior mesenteric and internal iliac nodes.

(Choice A) The celiac lymph nodes are located around the celiac trunk and drain lymph from the gastric, hepatic, and splenic nodes. These in turn drain their respective organ systems (not the colon).

(Choice C) The left colic lymph nodes and their branches are located along the left colic artery and drain the left colonic flexure and upper descending colon.

(Choice D) The right colic lymph nodes are found along the right colic artery and primarily drain the upper ascending colon.

(Choice E) The superficial inguinal lymph nodes lie below the inguinal ligament and are bordered by the sartorius and adductor longus muscles. They drain parts of the genitalia (eg, penis, scrotum, perineum, and vulva), buttocks, anus below the dentate line, and abdominal wall below the umbilicus.

(Choice F) The superior mesenteric lymph nodes (mesenteric, ileocolic, and mesocolic) mainly drain the ileum, jejunum, vermiform process, and parts of the ascending and transverse colon.

(Choice G) Lymph node metastasis typically occurs sequentially through the epicolic/paracolic, intermediate, and paraaortic lymph nodes. Later in the disease course, the cancer can spread via the thoracic duct to the supraclavicular lymph node (Virchow node).

Educational objective:
Lymphatic drainage of the rectum proximal to the anal dentate line occurs via the inferior mesenteric and internal iliac lymph nodes. Areas distal to the dentate line drain primarily into the inguinal nodes.

69213.mp4
https://t.me/USMLEWorldStep1
Show all

A 68-year-old woman is evaluated after recurrent episodes of bright red blood per rectum. She has had no abdominal pain, nausea, vomiting, or hematemesis. Her medical conditions include hypertension and obesity. She is a smoker, has a sedentary lifestyle, and consumes processed food and red meat frequently. Abdominal examination shows no abnormalities. Colonoscopy reveals numerous mucosal outpouchings in the sigmoid colon, and sigmoid colectomy is performed. Histopathology of this patient's colonic lesions is most likely to reveal which of the following findings?

- A. Absence of muscularis propria
- B. Ectopic gastric mucosa
- C. Neoplastic mucosal growth
- D. Neural plexus lacking ganglion cells
- E. Normal colonic layers

Submit

https://cdnjs.cloudflare.com/ajax/libs/mathjax/2.7.3/extensions/MathML/mml3.js

https://t.me/USMLEWorldStep1

A 68-year-old woman is evaluated after recurrent episodes of bright red blood per rectum. She has had no abdominal pain, nausea, vomiting, or hematemesis. Her medical conditions include hypertension and obesity. She is a smoker, has a sedentary lifestyle, and consumes processed food and red meat frequently. Abdominal examination shows no abnormalities. Colonoscopy reveals numerous mucosal outpouchings in the sigmoid colon, and sigmoid colectomy is performed. Histopathology of this patient's colonic lesions is most likely to reveal which of the following findings?

- ✓ A. Absence of muscularis propria (47%)
- ✗ B. Ectopic gastric mucosa (3%)
- C. Neoplastic mucosal growth (25%)
- D. Neural plexus lacking ganglion cells (1%)
- E. Normal colonic layers (21%)

Incorrect
Correct answer
A

47%
Answered correctly

17 secs
Time Spent

2023
Version

Explanation

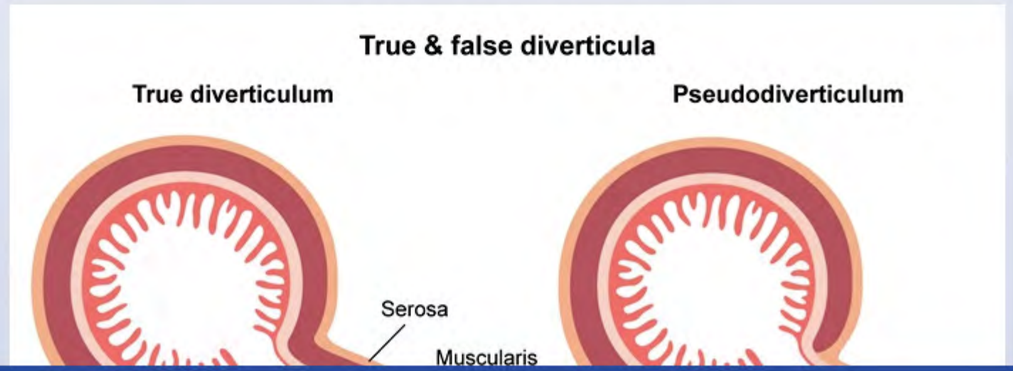

https://t.me/USMLEWorldStep1

A 68-year-old woman is evaluated after recurrent episodes of bright red blood per rectum. She has had no abdom
is a sn
exami
and si
of the

Inco
Corre
A

Expl

Exhibit Display

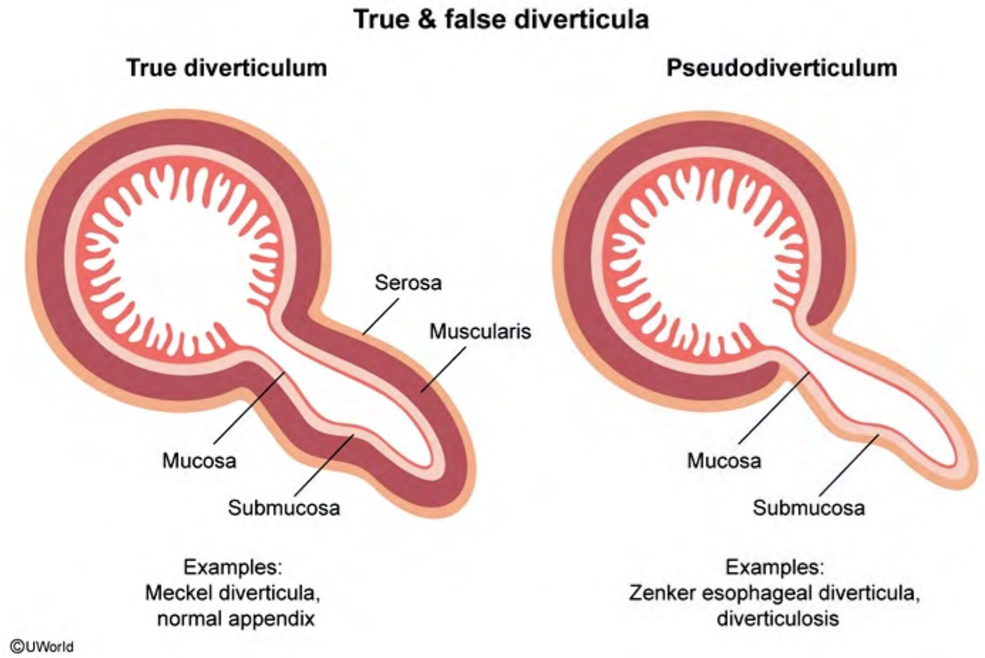

Zoom In | Zoom Out | Reset | New | Existing | My Notebook

Serosa
Muscularis

https://t.me/USMLEWorldStep1

This elderly patient with hematochezia and abnormal outpouchings from the colonic lumen has diverticulosis. **Diverticulosis** most commonly affects the sigmoid colon and is usually seen in individuals age >60. Most patients are asymptomatic, but some may present with **painless hematochezia** due to disruption of the arterioles (vasa recta) adjacent to the diverticula. Diverticula can also become inflamed (ie, diverticulitis), causing left lower quadrant abdominal pain, low-grade fever, and constipation or diarrhea.

Diverticula of the gastrointestinal tract may be classified according to morphology; true diverticula include all 3 layers of the gut wall and are often formed during embryologic development. **False diverticula** occur when the **mucosa and submucosa herniate** through areas of **focal weakness in the muscularis**. Exaggerated contractions of colonic smooth muscle segments are responsible for colonic diverticulosis; the resultant increased intraluminal pressure causes herniation and false diverticula formation. Most diverticula acquired during adult life are false (eg, Zenker diverticulum of the upper esophagus).

(Choices B and E) Congenital colonic diverticulosis and Meckel diverticula are formed during embryologic development and are true diverticula containing all three layers of the gut wall. Congenital colonic diverticula are extremely rare and typically occur as a single, large diverticulum. Meckel diverticula often contain heterotopic gastric or pancreatic mucosa, and may cause bleeding, but are located in the small intestine; symptoms (ie, pain, nausea, vomiting) typically present in early childhood.

(Choice C) Neoplastic mucosal growth causes colonic polyps, which are solid protuberances into the colonic lumen (rather than the outpouching away from the lumen seen in diverticulosis).

(Choice D) Congenital aganglionic megacolon (Hirschsprung disease) results from the failure of neural crest cells to migrate to the colon, resulting in an aganglionic segment and severe constipation. This disease manifests in infancy with failure to pass meconium.

Educational objective:
Colonic diverticula often involve the sigmoid colon and develop due to exaggerated contractions of colonic smooth muscle segments. This results in increased intraluminal pressure, causing outpouching of the mucosa and

https://t.me/USMLEWorldStep1

This elderly patient with hematochezia and abnormal outpouchings from the colonic lumen has diverticulosis.

Diverticulosis most commonly affects the sigmoid colon and is usually seen in individuals age >60. Most patients are asymptomatic, but some may present with **painless hematochezia** due to disruption of the arterioles (vasa recta) adjacent to the diverticula. Diverticula can also become inflamed (ie, diverticulitis), causing left lower quadrant abdominal pain, low-grade fever, and constipation or diarrhea.

Diverticula of the gastrointestinal tract may be classified according to morphology; true diverticula include all 3 layers of the gut wall and are often formed during embryologic development. **False diverticula** occur when the **mucosa and submucosa herniate** through areas of **focal weakness in the muscularis**. Exaggerated contractions of colonic smooth muscle segments are responsible for colonic diverticulosis; the resultant increased intraluminal pressure causes herniation and false diverticula formation. Most diverticula acquired during adult life are false (eg, Zenker diverticulum of the upper esophagus).

(Choices B and E) Congenital colonic diverticulosis and Meckel diverticula are formed during embryologic development and are true diverticula containing all three layers of the gut wall. Congenital colonic diverticula are extremely rare and typically occur as a single, large diverticulum. Meckel diverticula often contain heterotopic gastric or pancreatic mucosa, and may cause bleeding, but are located in the small intestine; symptoms (ie, pain, nausea, vomiting) typically present in early childhood.

(Choice C) Neoplastic mucosal growth causes colonic polyps, which are solid protuberances into the colonic lumen (rather than the outpouching away from the lumen seen in diverticulosis).

(Choice D) Congenital aganglionic megacolon (Hirschsprung disease) results from the failure of neural crest cells to migrate to the colon, resulting in an aganglionic segment and severe constipation. This disease manifests in infancy with failure to pass meconium.

Educational objective:
Colonic diverticula often involve the sigmoid colon and develop due to exaggerated contractions of colonic smooth muscle segments. This results in increased intraluminal pressure, causing outpouching of the mucosa and submucosa through the muscularis (false diverticula). Individuals (typically age >60) may be asymptomatic or have hematochezia or diverticulitis.

Pathology Gastrointestinal & Nutrition Diverticular disease

https://t.me/USMLEWorldStep1

Examples:
Meckel diverticula,

Examples:
Zenker esophageal diverticula,

Exhibit Display

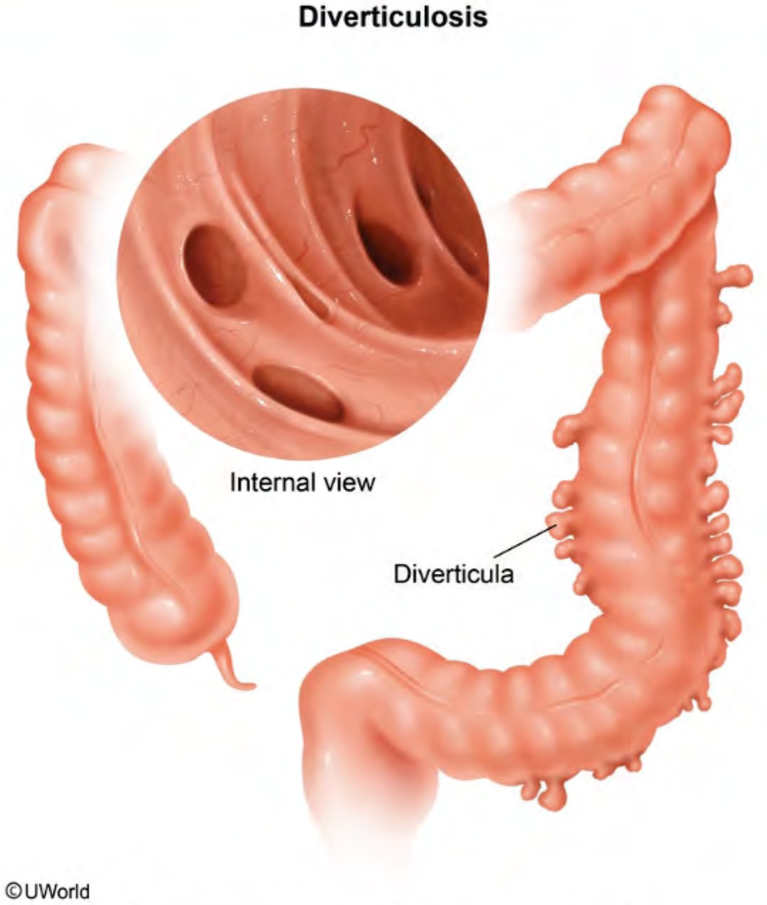

Zoom In | Zoom Out | Reset | New | Existing | My Notebook

This e
Divert
are as
recta)
quadra

Diverti
layers
mucos
contra
intralu
are fal

(Choi
develo
extrem
gastric
nause

(Choi
lumen

(Choi
to mig
infancy

Educa
Colonic diverticula often involve the sigmoid colon and develop due to exaggerated contractions of colonic smooth muscle segments. This results in increased intraluminal pressure, causing outpouching of the mucosa and

https://t.me/USMLEWorldStep1

A 1-month-old, full-term boy is brought to the office for a routine check-up. He is exclusively breastfed. The boy does not have any medical problems, and his hospital stay after birth was unremarkable. His mother consumes a well-balanced diet, takes no medications, and does not drink alcohol. The boy is at the 50th percentile for weight and the 60th percentile for height. His physical examination is normal. At this time, supplementation with which of the following should be recommended for this infant?

- A. Folic acid
- B. Iron
- C. Riboflavin
- D. Thiamine
- E. Vitamin A
- F. Vitamin D

Submit

https://t.me/USMLEWorldStep1

A 1-month-old, full-term boy is brought to the office for a routine check-up. He is exclusively breastfed. The boy does not have any medical problems, and his hospital stay after birth was unremarkable. His mother consumes a well-balanced diet, takes no medications, and does not drink alcohol. The boy is at the 50th percentile for weight and the 60th percentile for height. His physical examination is normal. At this time, supplementation with which of the following should be recommended for this infant?

- A. Folic acid (4%)
- ✕ B. Iron (15%)
- C. Riboflavin (2%)
- D. Thiamine (3%)
- E. Vitamin A (5%)
- ✓ F. Vitamin D (68%)

Incorrect
Correct answer
F

68%
Answered correctly

03 secs
Time Spent

2023
Version

Explanation

Supplementation for breastfed infants	
Supplement	**Risk factors**
Vitamin D	• Exclusive breastfeeding • Lack of sunlight exposure • Dark skin pigmentation
Iron	• Preterm/low-birthweight

https://t.me/USMLEWorldStep1

Supplementation for breastfed infants	
Supplement	**Risk factors**
Vitamin D	• Exclusive breastfeeding • Lack of sunlight exposure • Dark skin pigmentation
Iron	• Preterm/low-birthweight

Breast milk is the gold standard of infant nutrition; it contains proteins, carbohydrates, fats, vitamins, trace minerals, immunoglobulins, amino acids, and enzymes. All vitamins and trace minerals are present in adequate amounts **except vitamins D and K**. Vitamin K is supplemented by an intramuscular injection at delivery to prevent hemorrhagic disease in the newborn.

Regular **sunlight** exposure typically provides sufficient vitamin D. However, infants are generally shielded from direct sunlight due to sunburn risk. In addition, infants with dark skin pigmentation require more sunlight exposure to produce adequate vitamin D. Melanin is a natural sunblock and prevents ultraviolet rays from reaching the skin for vitamin D synthesis. Prolonged vitamin D insufficiency can lead to rickets (inadequate bone and cartilage mineralization). Therefore, all **exclusively breastfed** infants should receive **vitamin D supplementation** to **prevent rickets**. Formula-fed infants do not require supplementation as formula is fortified with adequate amounts of vitamin D.

(Choices A, C, and D) Human breast milk normally provides adequate amounts of folic acid, riboflavin, and thiamine for full-term infants.

(Choice B) Although breast milk has low iron content, the bioavailability of iron in breastmilk is considerably higher than supplemental iron and is sufficient for infants until age 4 months. Due to decreasing iron concentration in breast milk over time, supplementation is recommended for breastfed infants at age >4 months until solid food intake provides an adequate amount.

(Choice E) Vitamin A stores in the liver are low at birth but rapidly increase due to the large amount in colostrum and breast milk.

https://t.me/USMLEWorldStep1

Iron	• Preterm/low-birthweight

Breast milk is the gold standard of infant nutrition; it contains proteins, carbohydrates, fats, vitamins, trace minerals, immunoglobulins, amino acids, and enzymes. All vitamins and trace minerals are present in adequate amounts **except vitamins D and K**. Vitamin K is supplemented by an intramuscular injection at delivery to prevent hemorrhagic disease in the newborn.

Regular **sunlight** exposure typically provides sufficient vitamin D. However, infants are generally shielded from direct sunlight due to sunburn risk. In addition, infants with dark skin pigmentation require more sunlight exposure to produce adequate vitamin D. Melanin is a natural sunblock and prevents ultraviolet rays from reaching the skin for vitamin D synthesis. Prolonged vitamin D insufficiency can lead to rickets (inadequate bone and cartilage mineralization). Therefore, all **exclusively breastfed** infants should receive **vitamin D supplementation** to **prevent rickets**. Formula-fed infants do not require supplementation as formula is fortified with adequate amounts of vitamin D.

(Choices A, C, and D) Human breast milk normally provides adequate amounts of folic acid, riboflavin, and thiamine for full-term infants.

(Choice B) Although breast milk has low iron content, the bioavailability of iron in breastmilk is considerably higher than supplemental iron and is sufficient for infants until age 4 months. Due to decreasing iron concentration in breast milk over time, supplementation is recommended for breastfed infants at age >4 months until solid food intake provides an adequate amount.

(Choice E) Vitamin A stores in the liver are low at birth but rapidly increase due to the large amount in colostrum and breast milk.

Educational objective:
The breast milk content of vitamins D and K is typically insufficient for the nutritional needs of the newborn. Vitamin K is given parenterally to all newborns at birth to prevent hemorrhagic disease of the newborn. Exclusively breastfed infants require vitamin D supplementation due to lack of sunlight exposure and to prevent rickets.

References

• Is vitamin D supplementation necessary in healthy full-term breastfed infants? A follow-up study of bone

https://t.me/USMLEWorldStep1

- Exclusive breastfeeding

Exhibit Display

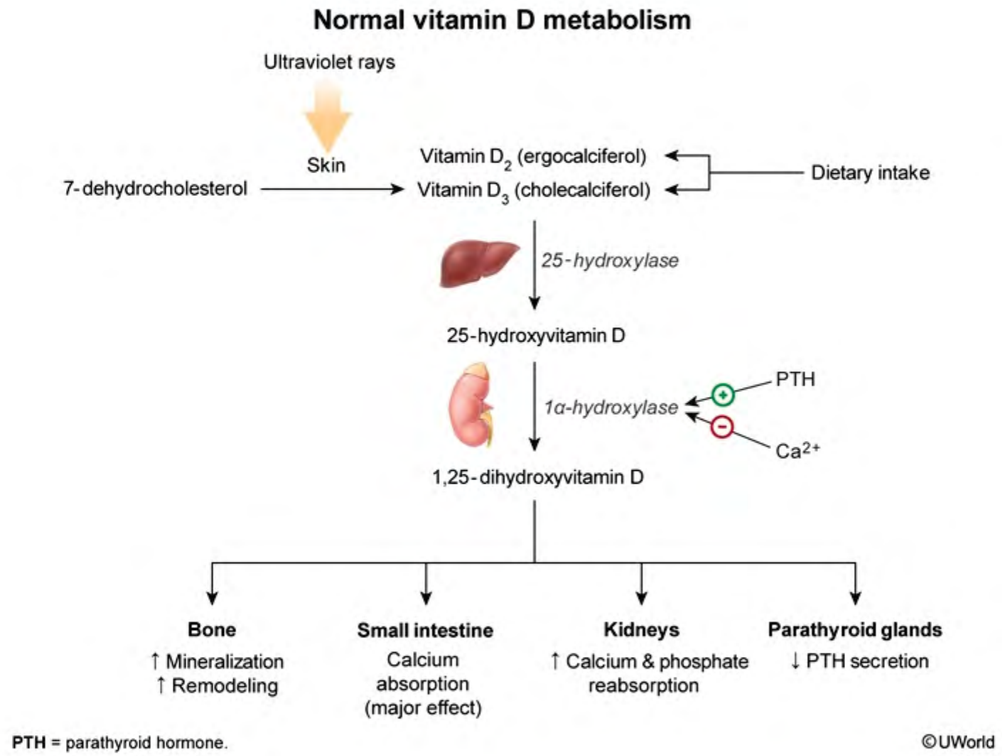

Zoom In | Zoom Out | Reset | New | Existing | My Notebook

Breas
minera
amour
hemor

Regula
direct
to proc
for vita
minera
preve
of vita

(Choi
thiami

(Choi
than s
breast
intake

(Choi
and br

Educa

The breast milk content of vitamins D and K is typically insufficient for the nutritional needs of the newborn.

Vitamin K is given parenterally to all newborns at birth to prevent hemorrhagic disease of the newborn. Exclusively

https://t.me/USMLEWorldStep1

A 54-year-old man comes to the office for evaluation of chronic diarrhea and weight loss. He has had bulky, foul-smelling stools for the past 8 months, which usually occur shortly after eating. There have been no nocturnal bowel movements, and he denies fecal incontinence. The patient also experiences dull, epigastric abdominal pain that is exacerbated by eating and unrelieved by antacids. He drinks 6 or 7 beers a day but denies tobacco or illicit drug use. Vital signs are within normal limits. The abdomen is tender to palpation in the epigastrium without distension, rebound, or guarding. Sudan staining of a fecal specimen is positive, and fecal occult blood testing is negative. Blood testing reveals normal hemoglobin. Which of the following pathophysiologic changes are most likely present in this patient?

- A. Decreased bile acid synthesis
- B. Decreased levels of fecal elastase
- C. Impaired production of intrinsic factor
- D. Increased pancreatic bicarbonate secretion
- E. Small bowel villous atrophy

Submit

https://t.me/USMLEWorldStep1

A 54-year-old man comes to the office for evaluation of chronic diarrhea and weight loss. He has had bulky, foul-smelling stools for the past 8 months, which usually occur shortly after eating. There have been no nocturnal bowel movements, and he denies fecal incontinence. The patient also experiences dull, epigastric abdominal pain that is exacerbated by eating and unrelieved by antacids. He drinks 6 or 7 beers a day but denies tobacco or illicit drug use. Vital signs are within normal limits. The abdomen is tender to palpation in the epigastrium without distension, rebound, or guarding. Sudan staining of a fecal specimen is positive, and fecal occult blood testing is negative. Blood testing reveals normal hemoglobin. Which of the following pathophysiologic changes are most likely present in this patient?

- A. Decreased bile acid synthesis (29%)
- ✓ B. Decreased levels of fecal elastase (40%)
- C. Impaired production of intrinsic factor (4%)
- D. Increased pancreatic bicarbonate secretion (7%)
- E. Small bowel villous atrophy (18%)

Correct | 40% Answered correctly | 03 secs Time Spent | 2023 Version

Explanation

This patient with a history of alcohol use disorder who has chronic epigastric pain, weight loss, and steatorrhea (ie, bulky, fatty stools) likely has **chronic pancreatitis**, a progressive inflammatory disease that ultimately leads to pancreatic fibrosis. Major risk factors include **alcohol abuse**, recurrent episodes of acute pancreatitis, and smoking.

Patients classically have **epigastric pain** that worsens with meals; pain is initially intermittent but may become constant in advanced disease. Other signs and symptoms of chronic pancreatitis are due to the following

https://t.me/USMLEWorldStep1

Explanation

This patient with a history of alcohol use disorder who has chronic epigastric pain, weight loss, and steatorrhea (ie, bulky, fatty stools) likely has **chronic pancreatitis**, a progressive inflammatory disease that ultimately leads to pancreatic fibrosis. Major risk factors include **alcohol abuse**, recurrent episodes of acute pancreatitis, and smoking.

Patients classically have **epigastric pain** that worsens with meals; pain is initially intermittent but may become constant in advanced disease. Other signs and symptoms of chronic pancreatitis are due to the following pathophysiologic changes:

- **Endocrine insufficiency**: Destruction of islet cells results in insulin-dependent diabetes mellitus.
- **Exocrine insufficiency**: Destruction of acinar cells results in lipase, elastase, amylase, trypsin, and chymotrypsin deficiency. This results in protein and fat malabsorption with **weight loss**, **steatorrhea**, and fat-soluble vitamin deficiencies.

Elastase is derived from a zymogen produced by pancreatic acinar cells and activated by trypsin in the duodenum; levels **correlate with pancreatic exocrine activity**. Therefore, **low fecal elastase** can help diagnose **pancreatic insufficiency** and supports a diagnosis of chronic pancreatitis. Other useful tests include Sudan staining (which identifies fecal fat) and hemoglobin A1c (which diagnoses diabetes mellitus).

(Choice A) Bile acid synthesis, which occurs in the liver, is not affected by chronic pancreatitis. Bile acids are necessary for proper biliary flow; therefore, bile acid synthesis disorders usually present with cholestasis, jaundice, and hepatic failure in neonates.

(Choice C) Autoimmune gastritis occurs due to autoantibodies directed at parietal cells and intrinsic factor, resulting in reduced intrinsic factor production. Although patients may have postprandial abdominal pain, they also typically have macrocytic anemia (due to vitamin B_{12} deficiency). Steatorrhea (due to fat malabsorption) is unexpected.

(Choice D) The pancreas normally produces a bicarbonate-rich fluid that neutralizes stomach acid. Chronic pancreatitis results in progressive pancreatic destruction, leading to decreased pancreatic bicarbonate production.

https://t.me/USMLEWorldStep1

- **Endocrine insufficiency**: Destruction of islet cells results in insulin-dependent diabetes mellitus.
- **Exocrine insufficiency**: Destruction of acinar cells results in lipase, elastase, amylase, trypsin, and chymotrypsin deficiency. This results in protein and fat malabsorption with **weight loss**, **steatorrhea**, and fat-soluble vitamin deficiencies.

Elastase is derived from a zymogen produced by pancreatic acinar cells and activated by trypsin in the duodenum; levels **correlate with pancreatic exocrine activity**. Therefore, **low fecal elastase** can help diagnose **pancreatic insufficiency** and supports a diagnosis of chronic pancreatitis. Other useful tests include Sudan staining (which identifies fecal fat) and hemoglobin A1c (which diagnoses diabetes mellitus).

(Choice A) Bile acid synthesis, which occurs in the liver, is not affected by chronic pancreatitis. Bile acids are necessary for proper biliary flow; therefore, bile acid synthesis disorders usually present with cholestasis, jaundice, and hepatic failure in neonates.

(Choice C) Autoimmune gastritis occurs due to autoantibodies directed at parietal cells and intrinsic factor, resulting in reduced intrinsic factor production. Although patients may have postprandial abdominal pain, they also typically have macrocytic anemia (due to vitamin B_{12} deficiency). Steatorrhea (due to fat malabsorption) is unexpected.

(Choice D) The pancreas normally produces a bicarbonate-rich fluid that neutralizes stomach acid. Chronic pancreatitis results in progressive pancreatic destruction, leading to decreased pancreatic bicarbonate production.

(Choice E) Villous atrophy of the small bowel is characteristic of celiac disease. Although patients can have steatorrhea and abdominal pain, celiac disease also usually causes iron deficiency anemia. In addition, chronic pancreatitis is more likely in this patient with heavy alcohol use.

Educational objective:
Chronic pancreatitis is an inflammatory disorder leading to pancreatic fibrosis and atrophy, resulting in endocrine (ie, insulin) and exocrine (eg, lipase, elastase, amylase, trypsin, chymotrypsin) insufficiencies. Patients typically have postprandial steatorrhea (ie, bulky diarrhea that is difficult to flush) and epigastric pain with meals. Low fecal elastase, positive Sudan staining, and elevated hemoglobin A1c support the diagnosis.

References

https://t.me/USMLEWorldStep1

A 43-year-old woman comes to the office with a 1-month history of dull abdominal pain that occurs mainly after eating. The pain is localized to the right upper quadrant and is especially severe after fatty meals. Physical examination is unremarkable. Ultrasound of the abdomen reveals several mobile echogenic foci within the gallbladder lumen. Which of the following sets of conditions is most likely present within this patient's gallbladder?

	Cholesterol	Bile acids	Phosphatidylcholine
A.	↓	↑	↑
B.	↓	↑	↓
C.	↓	↓	↑
D.	↑	↓	↓
E.	↑	↑	↓
F.	↑	↓	↑

Submit

https://t.me/USMLEWorldStep1

A 43-year-old woman comes to the office with a 1-month history of dull abdominal pain that occurs mainly after eating. The pain is localized to the right upper quadrant and is especially severe after fatty meals. Physical examination is unremarkable. Ultrasound of the abdomen reveals several mobile echogenic foci within the gallbladder lumen. Which of the following sets of conditions is most likely present within this patient's gallbladder?

	Cholesterol	Bile acids	Phosphatidylcholine	
✗	A. ↓	↑	↑	(2%)
	B. ↓	↑	↓	(2%)
	C. ↓	↓	↑	(1%)
✓	D. ↑	↓	↓	(51%)
	E. ↑	↑	↓	(20%)
	F. ↑	↓	↑	(22%)

Incorrect
Correct answer
D

51%
Answered correctly

04 secs
Time Spent

2023
Version

Explanation

Pathogenesis of cholesterol gallstones

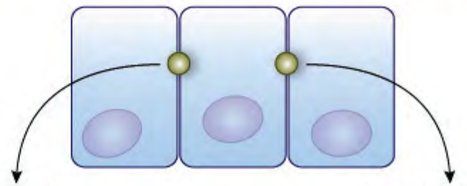

Normal levels of cholesterol, bile salts

↑ Cholesterol
↓ Bile acids

https://t.me/USMLEWorldStep1

A 43-year-old woman comes to the office with a 1-month history of dull abdominal pain that occurs mainly after eating
exami
gallbla

Exhibit Display

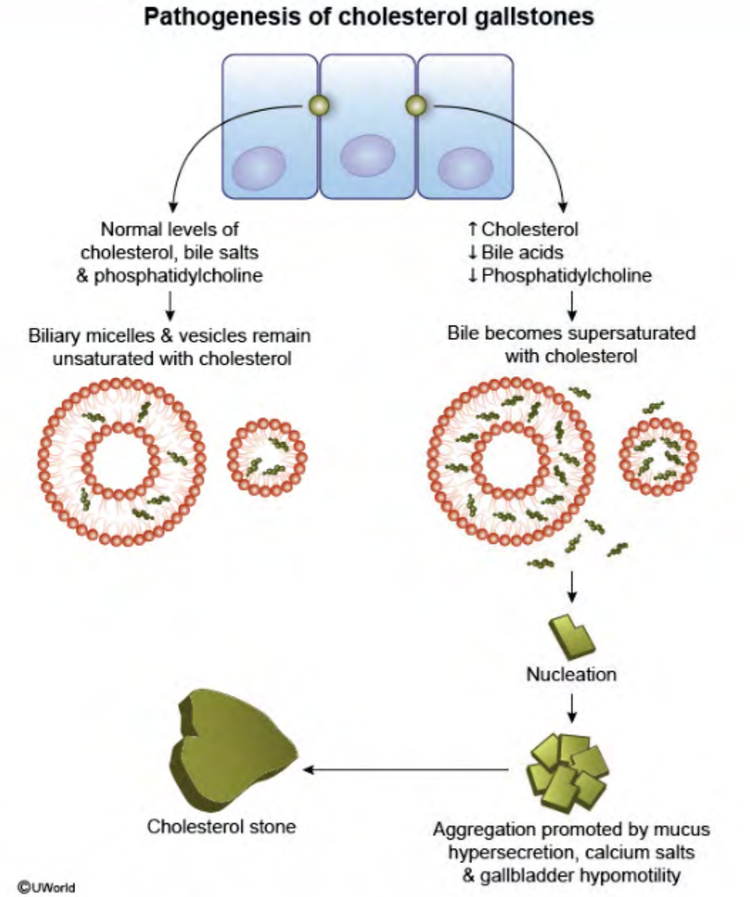

Zoom In | Zoom Out | Reset | New | Existing | My Notebook

Normal levels of cholesterol, bile salts
↑ Cholesterol
↓ Bile acids

https://t.me/USMLEWorldStep1

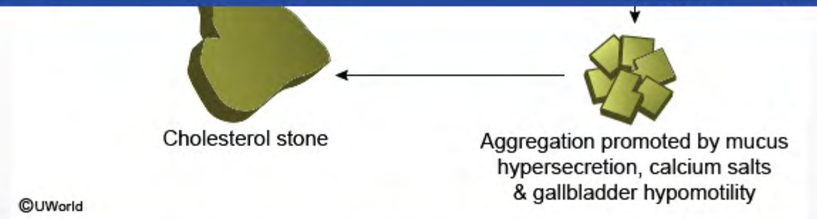

Removal of excess cholesterol from the body occurs via 2 mechanisms: excretion of **free cholesterol** into bile and conversion of cholesterol into **bile acids**.

In the liver, free cholesterol is converted into cholic and chenodeoxycholic acids through a series of chemical reactions beginning with cholesterol 7α-hydroxylase (rate-limiting step in bile acid synthesis). These bile acids are then conjugated to either glycine or taurine (improving solubility and emulsifying ability) to create the bile salts that are actively secreted into the bile canaliculi. As **water-insoluble cholesterol** is secreted in bile, it is rendered soluble in small amounts by the detergent action of these amphipathic (eg, hydrophobic and hydrophilic) bile salts and phosphatidylcholine (a phospholipid). When there is more cholesterol than can be made soluble, it **precipitates into crystals** that eventually grow and merge to form **gallstones**. Gallbladder hypomotility further promotes cholesterol nucleation and gallstone formation.

(Choices A, B, C, E, and F) These represent lower cholesterol concentrations related to total bile salt and phosphatidylcholine levels. Such conditions would decrease the likelihood of gallstone formation.

Educational objective:
Elevated cholesterol concentrations increase the likelihood of cholesterol precipitation and gallstone formation. High levels of bile salts and phosphatidylcholine increase cholesterol solubility and decrease the risk of gallstones.

References

- Pathogenesis of gallstones
- Pathogenesis of gallstones.

Pathophysiology	Gastrointestinal & Nutrition	Gallstone disease
Subject	System	Topic

Copyright © UWorld. All rights reserved.

https://t.me/USMLEWorldStep1

A 26-year-old woman comes to the office due to recurrent nausea and vomiting for the past several months. The patient experiences nausea and epigastric discomfort after meals and often feels full after eating only a small portion of food. On several occasions, she has had emesis containing particles of food that she ate several hours earlier. The patient has a 15-year history of type 1 diabetes mellitus complicated by diabetic nephropathy. Her medications include a basal-bolus insulin regimen and lisinopril. She does not use tobacco, alcohol, or illicit drugs. Vital signs are within normal limits. The abdomen is soft and nontender with no organomegaly. Bowel sounds are normal. Testing of stool for occult blood is negative. An upper gastrointestinal endoscopy is unremarkable. Which of the following mechanisms is most likely responsible for this patient's current symptoms?

- A. Decreased activity of vagus motor nucleus
- B. Disruption of lower esophageal sphincter
- C. Dysfunction of gastric enteric neurons
- D. Excessive production of cholecystokinin
- E. Hypertrophy of pyloric smooth muscles

Submit

https://t.me/USMLEWorldStep1

A 26-year-old woman comes to the office due to recurrent nausea and vomiting for the past several months. The patient experiences nausea and epigastric discomfort after meals and often feels full after eating only a small portion of food. On several occasions, she has had emesis containing particles of food that she ate several hours earlier. The patient has a 15-year history of type 1 diabetes mellitus complicated by diabetic nephropathy. Her medications include a basal-bolus insulin regimen and lisinopril. She does not use tobacco, alcohol, or illicit drugs. Vital signs are within normal limits. The abdomen is soft and nontender with no organomegaly. Bowel sounds are normal. Testing of stool for occult blood is negative. An upper gastrointestinal endoscopy is unremarkable. Which of the following mechanisms is most likely responsible for this patient's current symptoms?

- A. Decreased activity of vagus motor nucleus (15%)
- ✗ B. Disruption of lower esophageal sphincter (11%)
- ✓ C. Dysfunction of gastric enteric neurons (63%)
- D. Excessive production of cholecystokinin (3%)
- E. Hypertrophy of pyloric smooth muscles (6%)

Incorrect
Correct answer
C

63%
Answered correctly

03 secs
Time Spent

2023
Version

Explanation

Diabetic gastroparesis	
Pathogenesis	• Autonomic neuropathy • Destruction of enteric neurons • Failure of relaxation in fundus & uncoordinated peristalsis
	• Long-standing diabetes (especially type 1)

https://t.me/USMLEWorldStep1

Explanation

Diabetic gastroparesis	
Pathogenesis	• Autonomic neuropathy • Destruction of enteric neurons • Failure of relaxation in fundus & uncoordinated peristalsis
Risk factors	• Long-standing diabetes (especially type 1) • Chronic poor control • Labile blood glucose
Clinical presentation	• Postprandial bloating & vomiting • Early satiety • Impaired nutrition & weight loss
Diagnosis	• Nuclear gastric emptying study: delayed transit into duodenum
Treatment	• Promotility drugs: metoclopramide, erythromycin

This patient with diabetes has postprandial nausea, vomiting, early satiety, and regurgitation of undigested food particles, which is suggestive of **diabetic gastroparesis**. Gastroparesis is a type of **autonomic neuropathy** involving the gastrointestinal tract and is characterized by delayed gastric emptying not due to an obstruction.

Normal postprandial gastric activity is a multistep process that occurs in response to food ingestion. After food passes down the esophagus, vagally stimulated enteric neurons release nitric oxide to induce relaxation of the fundus of the stomach and accommodate the incoming food bolus. Specialized gastric pacemaker cells (interstitial cells of Cajal) initiate pacesetter potentials (slow waves), which generate circumferential contractions of the gastric smooth muscle (peristalsis). Peristalsis facilitates food mixing and propulsion toward the pylorus.

Chronic hyperglycemia in patients with diabetes can result in **destruction of the enteric neurons**. Loss of nitric oxide–containing neurons results in impaired fundal relaxation, and loss of the interstitial cells of Cajal results in uncoordinated smooth muscle contractions and ineffective peristalsis, both of which **delay gastric emptying**.

https://t.me/USMLEWorldStep1

This patient with diabetes has postprandial nausea, vomiting, early satiety, and regurgitation of undigested food particles, which is suggestive of **diabetic gastroparesis**. Gastroparesis is a type of **autonomic neuropathy** involving the gastrointestinal tract and is characterized by delayed gastric emptying not due to an obstruction.

Normal postprandial gastric activity is a multistep process that occurs in response to food ingestion. After food passes down the esophagus, vagally stimulated enteric neurons release nitric oxide to induce relaxation of the fundus of the stomach and accommodate the incoming food bolus. Specialized gastric pacemaker cells (interstitial cells of Cajal) initiate pacesetter potentials (slow waves), which generate circumferential contractions of the gastric smooth muscle (peristalsis). Peristalsis facilitates food mixing and propulsion toward the pylorus.

Chronic hyperglycemia in patients with diabetes can result in **destruction of the enteric neurons**. Loss of nitric oxide–containing neurons results in impaired fundal relaxation, and loss of the interstitial cells of Cajal results in uncoordinated smooth muscle contractions and ineffective peristalsis, both of which **delay gastric emptying**.

(Choice A) Chronic hyperglycemia can cause vagus nerve denervation with axonal damage, which can contribute to diabetic gastroparesis. However, the vagal motor nucleus is located in the brainstem and is typically unaffected by diabetes.

(Choice B) Disruption of the lower esophageal sphincter can cause symptoms of acid reflux. Although severe gastroesophageal reflux can cause regurgitation, a history of heartburn or epigastric pain would be expected. In addition, upper endoscopy typically shows evidence of esophagitis (eg, mucosal erythema, exudates).

(Choice D) Cholecystokinin is secreted in response to fat- or protein-rich meals and slows gastric emptying to improve digestion of these nutrients. Cholecystokinin secretion may actually be reduced in diabetes and is not thought to be a major cause of diabetic gastroparesis.

(Choice E) Hypertrophy of pyloric smooth muscles is seen in congenital pyloric stenosis, which causes projective vomiting and is typically diagnosed in infancy. The smooth muscle cells typically remain normal in diabetic gastroparesis.

Educational objective:
Diabetic gastroparesis results from the destruction of enteric neurons due to chronic hyperglycemia, leading to impaired relaxation and disordered and ineffective peristalsis. This causes delayed gastric emptying, which

https://t.me/USMLEWorldStep1

Normal postprandial gastric activity is a multistep process that occurs in response to food ingestion. After food passes down the esophagus, vagally stimulated enteric neurons release nitric oxide to induce relaxation of the fundus of the stomach and accommodate the incoming food bolus. Specialized gastric pacemaker cells (interstitial cells of Cajal) initiate pacesetter potentials (slow waves), which generate circumferential contractions of the gastric smooth muscle (peristalsis). Peristalsis facilitates food mixing and propulsion toward the pylorus.

Chronic hyperglycemia in patients with diabetes can result in **destruction of the enteric neurons**. Loss of nitric oxide–containing neurons results in impaired fundal relaxation, and loss of the interstitial cells of Cajal results in uncoordinated smooth muscle contractions and ineffective peristalsis, both of which **delay gastric emptying**.

(Choice A) Chronic hyperglycemia can cause vagus nerve denervation with axonal damage, which can contribute to diabetic gastroparesis. However, the vagal motor nucleus is located in the brainstem and is typically unaffected by diabetes.

(Choice B) Disruption of the lower esophageal sphincter can cause symptoms of acid reflux. Although severe gastroesophageal reflux can cause regurgitation, a history of heartburn or epigastric pain would be expected. In addition, upper endoscopy typically shows evidence of esophagitis (eg, mucosal erythema, exudates).

(Choice D) Cholecystokinin is secreted in response to fat- or protein-rich meals and slows gastric emptying to improve digestion of these nutrients. Cholecystokinin secretion may actually be reduced in diabetes and is not thought to be a major cause of diabetic gastroparesis.

(Choice E) Hypertrophy of pyloric smooth muscles is seen in congenital pyloric stenosis, which causes projective vomiting and is typically diagnosed in infancy. The smooth muscle cells typically remain normal in diabetic gastroparesis.

Educational objective:
Diabetic gastroparesis results from the destruction of enteric neurons due to chronic hyperglycemia, leading to impaired relaxation and disordered and ineffective peristalsis. This causes delayed gastric emptying, which presents as postprandial fullness, regurgitation of undigested food, nausea, and vomiting.

References

- Diabetic gastroparesis.

https://t.me/USMLEWorldStep1

A 46-year-old woman comes to the emergency department due to 3 days of persistent upper abdominal pain, nausea, and vomiting. The patient has had similar pain in the past, especially after fatty meals, which resolved spontaneously within several hours. Temperature is 38.6 C (101.5 F), blood pressure is 110/65 mm Hg, and pulse is 98/min. BMI is 33 kg/m^2. Physical examination is notable for severe right upper quadrant tenderness. Leukocyte count is 21,000/mm^3. Laparoscopic surgery is performed and reveals an erythematous, distended gallbladder with patchy necrosis. Which of the following events most likely initiated this patient's condition?

- A. Bacterial invasion of the gallbladder wall
- B. Cystic artery thrombosis
- C. Gallbladder outflow obstruction
- D. Ischemic disruption of the mucosal layer
- E. Lecithin hydrolysis and mucosal damage

Submit

https://t.me/USMLEWorldStep1

A 46-year-old woman comes to the emergency department due to 3 days of persistent upper abdominal pain, nausea, and vomiting. The patient has had similar pain in the past, especially after fatty meals, which resolved spontaneously within several hours. Temperature is 38.6 C (101.5 F), blood pressure is 110/65 mm Hg, and pulse is 98/min. BMI is 33 kg/m^2. Physical examination is notable for severe right upper quadrant tenderness. Leukocyte count is 21,000/mm^3. Laparoscopic surgery is performed and reveals an erythematous, distended gallbladder with patchy necrosis. Which of the following events most likely initiated this patient's condition?

- A. Bacterial invasion of the gallbladder wall (11%)
- ✗ B. Cystic artery thrombosis (1%)
- ✓ C. Gallbladder outflow obstruction (81%)
- D. Ischemic disruption of the mucosal layer (4%)
- E. Lecithin hydrolysis and mucosal damage (1%)

Incorrect
Correct answer
C

81%
Answered correctly

03 secs
Time Spent

2023
Version

Explanation

This patient likely has **acute calculous cholecystitis**, an acute inflammation of the gallbladder initiated by **gallstone obstruction** of the **cystic duct**. Patients typically present with persistent right upper quadrant pain, fever, and leukocytosis. Examination classically shows Murphy sign, an inspiratory pause elicited by pain during deep palpation of the right upper quadrant. Symptoms are often preceded by transient episodes of abdominal pain and nausea after fatty meals due to temporary cystic duct obstruction (biliary colic).

Persistent gallbladder outflow obstruction promotes hydrolysis of luminal lecithins to lysolecithins, which disrupts the protective mucus layer. The luminal epithelium is then exposed to the detergent action of the bile salts, resulting in chemical irritation and prostaglandin release. Inflammation of the mucosa and deeper tissues causes

https://t.me/USMLEWorldStep1

This patient likely has **acute calculous cholecystitis**, an acute inflammation of the gallbladder initiated by **gallstone obstruction** of the **cystic duct**. Patients typically present with persistent right upper quadrant pain, fever, and leukocytosis. Examination classically shows Murphy sign, an inspiratory pause elicited by pain during deep palpation of the right upper quadrant. Symptoms are often preceded by transient episodes of abdominal pain and nausea after fatty meals due to temporary cystic duct obstruction (biliary colic).

Persistent gallbladder outflow obstruction promotes hydrolysis of luminal lecithins to lysolecithins, which disrupts the protective mucus layer. The luminal epithelium is then exposed to the detergent action of the bile salts, resulting in chemical irritation and prostaglandin release. Inflammation of the mucosa and deeper tissues causes gallbladder hypomotility. The increasing distension and internal pressure within the gallbladder eventually result in ischemia. Finally, bacteria (eg, *Escherichia coli*, *Enterococcus*, *Klebsiella*, *Enterobacter*) invade the injured and necrotic gallbladder wall, causing an infection **(Choice A)**.

(Choices B and D) The gallbladder is vulnerable to ischemic injury as the cystic artery lacks collateral circulation. Although inflammation/edema of the gallbladder may compromise blood flow, ischemic disruption of the mucosal layer is usually the next to last step in the pathogenesis of acute calculous cholecystitis. Gallbladder ischemia is not typically caused by cystic artery thrombosis.

(Choice E) Lecithin hydrolysis and mucosal damage occur after gallbladder outflow obstruction in the pathogenesis of acute calculous cholecystitis.

Educational objective:
Acute calculous cholecystitis is an acute inflammation of the gallbladder initiated by gallstone obstruction of the cystic duct. Subsequent steps in pathogenesis include mucosal disruption by lysolecithins, bile salt irritation of the luminal epithelium, prostaglandin release with transmural inflammation, gallbladder hypomotility, increased intraluminal pressure causing ischemia, and bacterial invasion.

References

- Acute cholecystitis.

Pathology	Gastrointestinal & Nutrition	Cholecystitis
Subject	System	Topic

https://t.me/USMLEWorldStep1

A 26-year-old woman is evaluated for intermittent abdominal discomfort, diarrhea, and melena. The patient undergoes colonoscopy followed by total colectomy due to significant colonic abnormalities. Representative colon findings are shown in the image below.

Her sister, who has the same biological parents and has no symptoms, also undergoes screening colonoscopy and has similar findings. If left untreated, which of the following is the most likely lifetime risk of colon cancer in the patient's sister?

- A. About 25%
- B. About 50%
- C. About 75%
- D. Close to 100%
- E. Same as general population

Submit

https://t.me/USMLEWorldStep1

A 26-year-old woman is evaluated for intermittent abdominal discomfort, diarrhea, and melena. The patient
underg
finding

Her sis
has sir
patien

Exhibit Display

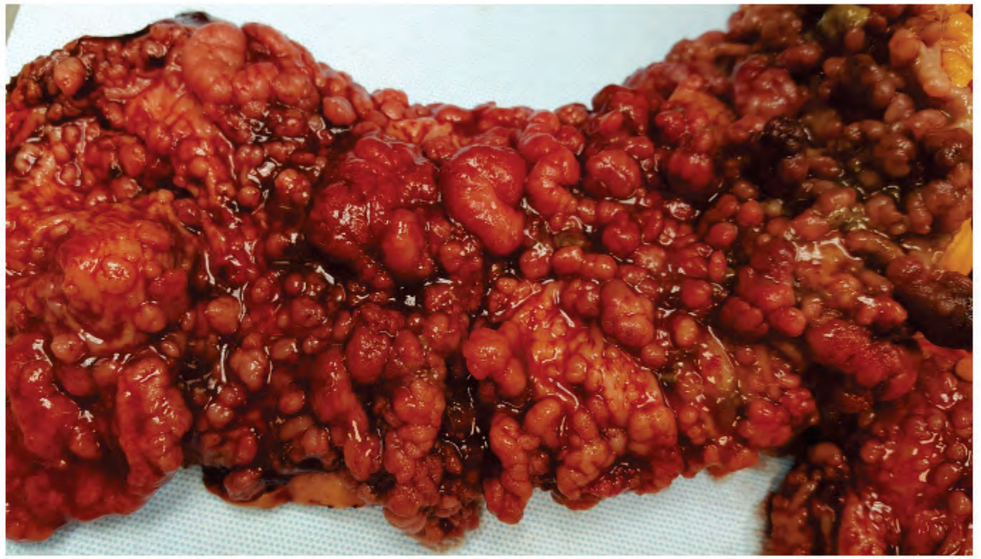

Zoom In Zoom Out Reset New | Existing My Notebook

https://t.me/USMLEWorldStep1

A 26-year-old woman is evaluated for intermittent abdominal discomfort, diarrhea, and melena. The patient undergoes colonoscopy followed by total colectomy due to significant colonic abnormalities. Representative colon findings are shown in the image below.

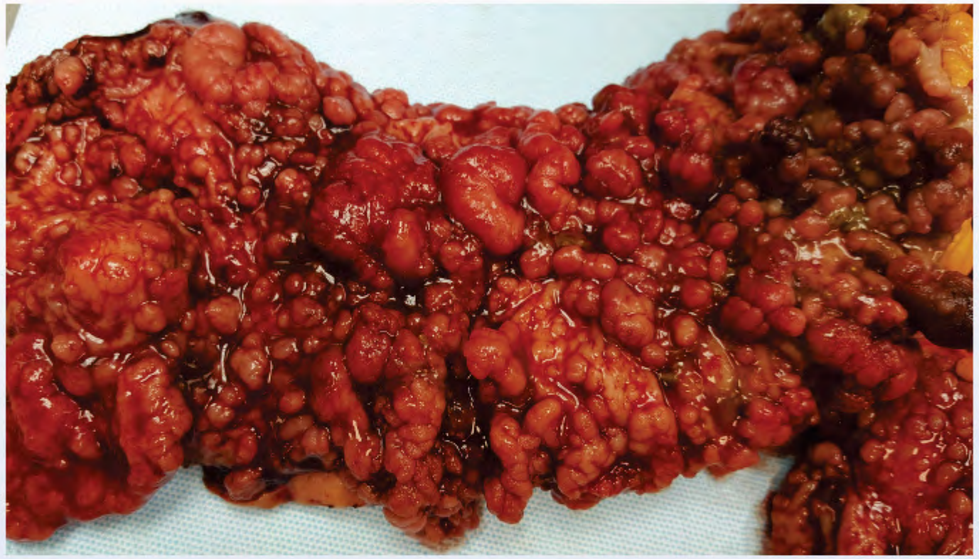

Her sister, who has the same biological parents and has no symptoms, also undergoes screening colonoscopy and has similar findings. If left untreated, which of the following is the most likely lifetime risk of colon cancer in the patient's sister?

- A. About 25%
- B. About 50%
- C. About 75%
- D. Close to 100%
- E. Same as general population

https://t.me/USMLEWorldStep1

undergoes colonoscopy followed by total colectomy due to significant colonic abnormalities. Representative colon findings are shown in the image below.

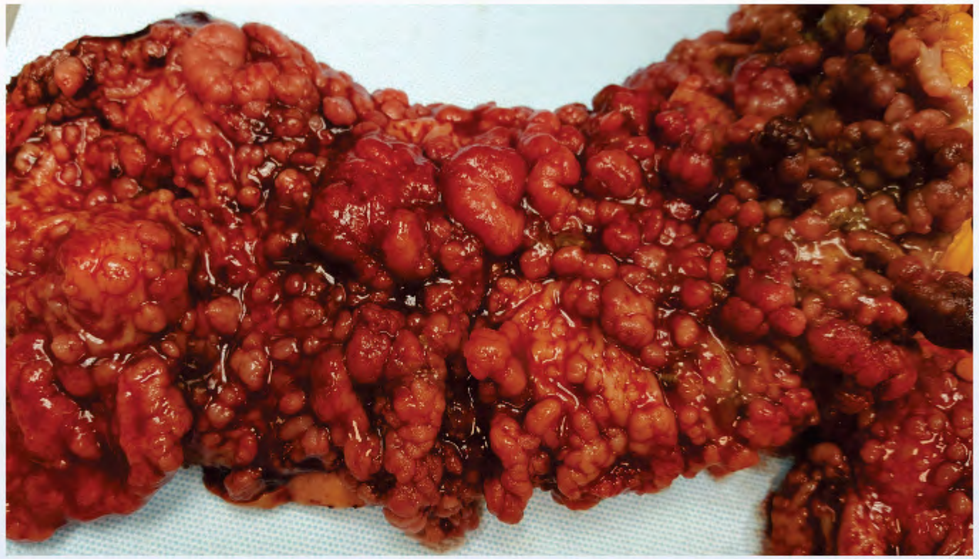

Her sister, who has the same biological parents and has no symptoms, also undergoes screening colonoscopy and has similar findings. If left untreated, which of the following is the most likely lifetime risk of colon cancer in the patient's sister?

- A. About 25% (3%)
- ✗ B. About 50% (6%)
- C. About 75% (4%)
- ✓ D. Close to 100% (83%)
- E. Same as general population (1%)

Incorrect
Correct answer
D

83%
Answered correctly

12 secs
Time Spent

2023
Version

https://t.me/USMLEWorldStep1

Explanation

Syndromes that increase colon cancer risk			
Syndrome	**Gene mutation**	**Colon cancer risk**	**Other associated neoplasms**
Familial adenomatous polyposis	*APC*	100%	Upper gastrointestinal Thyroid Desmoids/osteomas
Lynch syndrome	*MSH2/6*, *MLH1*	50%-80%	Endometrial Ovarian
Peutz-Jeghers syndrome	*STK11*	39%	Upper gastrointestinal Pancreatic Breast

This patient and her sister have innumerable colonic polyps, raising strong suspicion for the autosomal dominant hereditary disorder **familial adenomatous polyposis** (FAP). Patients with this disorder develop hundreds or thousands of **colonic polyps** in the second or third decade of life. These polyps behave similarly to colonic polyps that form in patients who do not have FAP (spontaneous polyps): they typically grow over time, do not regress, and are associated with a progressive risk for high-grade dysplasia and transformation to invasive cancer as they enlarge. Because patients with FAP have innumerable polyps, the risk that one or more will transform into invasive **colonic carcinoma is nearly 100%**. Therefore, colectomy is generally recommended.

FAP is caused by a germline mutation to the tumor suppressor gene ***adenomatous polyposis coli*** (*APC*). The *APC* gene encodes for a protein that destroys beta-catenin. Loss of the APC protein results in elevated beta-catenin levels, which stimulates a transcriptional activator that leads to proliferation of intestinal crypt cells (and the subsequent formation of polyps). Patients may also have extracolonic manifestations such as gastric or duodenal polyps, desmoid tumors, and brain cancer, but these manifestations have lower penetrance than colonic polyps.

Loss of control of the APC pathway is a crucial first step in the development of both hereditary and sporadic forms

https://t.me/USMLEWorldStep1

syndrome	*STK11*	39%	Pancreatic Breast

This patient and her sister have innumerable colonic polyps, raising strong suspicion for the autosomal dominant hereditary disorder **familial adenomatous polyposis** (FAP). Patients with this disorder develop hundreds or thousands of **colonic polyps** in the second or third decade of life. These polyps behave similarly to colonic polyps that form in patients who do not have FAP (spontaneous polyps): they typically grow over time, do not regress, and are associated with a progressive risk for high-grade dysplasia and transformation to invasive cancer as they enlarge. Because patients with FAP have innumerable polyps, the risk that one or more will transform into invasive **colonic carcinoma is nearly 100%**. Therefore, colectomy is generally recommended.

FAP is caused by a germline mutation to the tumor suppressor gene ***adenomatous polyposis coli*** (*APC*). The *APC* gene encodes for a protein that destroys beta-catenin. Loss of the APC protein results in elevated beta-catenin levels, which stimulates a transcriptional activator that leads to proliferation of intestinal crypt cells (and the subsequent formation of polyps). Patients may also have extracolonic manifestations such as gastric or duodenal polyps, desmoid tumors, and brain cancer, but these manifestations have lower penetrance than colonic polyps.

Loss of control of the APC pathway is a crucial first step in the development of both hereditary and sporadic forms of colon cancer. Nearly 80% of sporadic colon cancers have somatic mutations to both *APC* alleles; the remainder usually have activating mutations to the downstream products of this pathway.

Educational objective:
Familial adenomatous polyposis (FAP) is an autosomal dominant disorder caused by germline mutation to the tumor suppressor gene *adenomatous polyposis coli*. Patients with FAP develop hundreds or thousands of colonic polyps; lifetime risk of colon cancer is close to 100%.

References

- Hereditary and familial colon cancer.

Pathology	Gastrointestinal & Nutrition	Colorectal polyps and cancer
Subject	System	Topic

Copyright © UWorld. All rights reserved.

https://t.me/USMLEWorldStep1

syndrome	*STK11*	39%	Pancreatic Breast

This p
heredi
thousa
that fo
are as
enlarg
coloni

FAP is
APC g
cateni
subse
polyps

Loss o
of colo
usuall

Educa
Famili
tumor
polyps

Refere
- Her

Patholog
Subject

Copyright © UWorld. All rights reserved.

Exhibit Display

Familial adenomatous polyposis

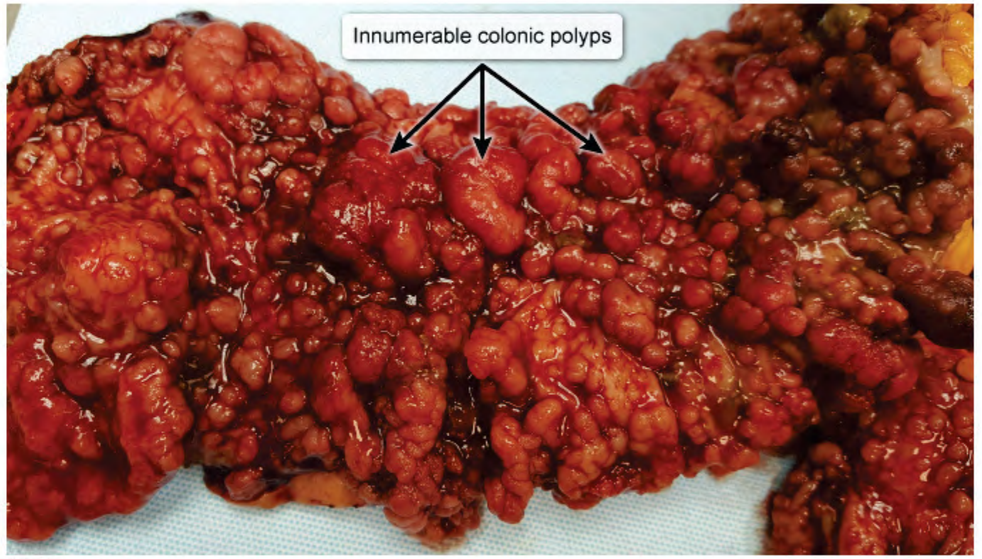

©UWorld

Zoom In | Zoom Out | Reset | New | Existing | My Notebook

https://t.me/USMLEWorldStep1

A 26-year-old previously healthy man is brought to the emergency department after a motor vehicle collision. The patient was driving while wearing a seatbelt when his car was hit on the left side by another vehicle. He has since had persistent left shoulder pain. He also has nausea and hiccups. The patient's blood pressure is 90/60 mm Hg and pulse is 115/min. On examination, he has a bruise on the left lower chest wall with tenderness to palpation along the area. Chest auscultation reveals normal heart sounds and bilaterally equal breath sounds. He has a rigid and tender abdomen. Which of the following is the most likely diagnosis?

- A. Aortic rupture
- B. Hemopericardium
- C. Humerus fracture
- D. Lung contusion
- E. Myocardial contusion
- F. Pneumothorax
- G. Splenic laceration

Submit

https://t.me/USMLEWorldStep1

A 26-year-old previously healthy man is brought to the emergency department after a motor vehicle collision. The patient was driving while wearing a seatbelt when his car was hit on the left side by another vehicle. He has since had persistent left shoulder pain. He also has nausea and hiccups. The patient's blood pressure is 90/60 mm Hg and pulse is 115/min. On examination, he has a bruise on the left lower chest wall with tenderness to palpation along the area. Chest auscultation reveals normal heart sounds and bilaterally equal breath sounds. He has a rigid and tender abdomen. Which of the following is the most likely diagnosis?

- A. Aortic rupture (3%)
- B. Hemopericardium (4%)
- ✗ C. Humerus fracture (0%)
- D. Lung contusion (3%)
- E. Myocardial contusion (1%)
- F. Pneumothorax (1%)
- ✓ G. Splenic laceration (85%)

Incorrect
Correct answer
G

85%
Answered correctly

03 secs
Time Spent

2023
Version

Explanation

This patient's rigid abdomen with associated left shoulder pain, hypotension, and tachycardia suggests a possible **splenic laceration** and hemoperitoneum. The shoulder pain likely represents referred pain due to peritoneal irritation (**Kehr sign**).

The phrenic nerves originate from C3-C5 and pass between the lung and heart to provide motor function to the diaphragm. The phrenic nerves also provide sensory fibers to the pericardium, mediastinal pleura, and diaphragmatic peritoneum. The supraclavicular nerves originate from C3-C4 and their branches innervate the

https://t.me/USMLEWorldStep1

Explanation

This patient's rigid abdomen with associated left shoulder pain, hypotension, and tachycardia suggests a possible **splenic laceration** and hemoperitoneum. The shoulder pain likely represents referred pain due to peritoneal irritation (**Kehr sign**).

The phrenic nerves originate from C3-C5 and pass between the lung and heart to provide motor function to the diaphragm. The phrenic nerves also provide sensory fibers to the pericardium, mediastinal pleura, and diaphragmatic peritoneum. The supraclavicular nerves originate from C3-C4 and their branches innervate the sternoclavicular joint, local muscles (eg, sternocleidomastoid), and the skin of the upper and posterior shoulder. Any abdominal process (eg, ruptured spleen, peritonitis, hemoperitoneum) irritating the sensory fibers around the diaphragm can cause **referred pain** via the phrenic nerve to the C3-C5 shoulder region. Phrenic nerve irritation can also cause **hiccups** due to spasmodic diaphragmatic contraction pulling air against a closed larynx.

(Choice A) Traumatic aortic rupture presents with chest wall contusions and hypotension, but it is not typically associated with persistent left shoulder pain or hiccups.

(Choices B and D) Hemopericardium (blood accumulation in the pericardial sac) typically presents with shortness of breath, tachycardia, jugular venous distention, and possible hypotension. Lung contusion usually presents gradually with shortness of breath, chest pain, and consolidation on lung imaging. However, persistent shoulder pain is not commonly associated with either condition.

(Choice C) Humerus fracture typically presents with acute shoulder pain that is increased with movement. Examination can show a deformed shoulder joint. This patient's rigid abdomen and absence of obvious shoulder abnormalities make this less likely.

(Choice E) Myocardial contusion after chest wall trauma typically presents with mid-anterior chest wall pain, shortness of breath, persistent tachycardia, and new conduction defects on ECG (eg, bundle branch block). It is not typically associated with persistent abdominal or shoulder pain.

(Choice F) Pneumothorax after chest trauma usually presents with tachypnea, shortness of breath, decreased or absent breath sounds, unilateral hyperresonance to percussion, and pleuritic chest pain. This patient's bilaterally

https://t.me/USMLEWorldStep1

diaphragm. The phrenic nerves also provide sensory fibers to the pericardium, mediastinal pleura, and diaphragmatic peritoneum. The supraclavicular nerves originate from C3-C4 and their branches innervate the sternoclavicular joint, local muscles (eg, sternocleidomastoid), and the skin of the upper and posterior shoulder. Any abdominal process (eg, ruptured spleen, peritonitis, hemoperitoneum) irritating the sensory fibers around the diaphragm can cause **referred pain** via the phrenic nerve to the C3-C5 shoulder region. Phrenic nerve irritation can also cause **hiccups** due to spasmodic diaphragmatic contraction pulling air against a closed larynx.

(Choice A) Traumatic aortic rupture presents with chest wall contusions and hypotension, but it is not typically associated with persistent left shoulder pain or hiccups.

(Choices B and D) Hemopericardium (blood accumulation in the pericardial sac) typically presents with shortness of breath, tachycardia, jugular venous distention, and possible hypotension. Lung contusion usually presents gradually with shortness of breath, chest pain, and consolidation on lung imaging. However, persistent shoulder pain is not commonly associated with either condition.

(Choice C) Humerus fracture typically presents with acute shoulder pain that is increased with movement. Examination can show a deformed shoulder joint. This patient's rigid abdomen and absence of obvious shoulder abnormalities make this less likely.

(Choice E) Myocardial contusion after chest wall trauma typically presents with mid-anterior chest wall pain, shortness of breath, persistent tachycardia, and new conduction defects on ECG (eg, bundle branch block). It is not typically associated with persistent abdominal or shoulder pain.

(Choice F) Pneumothorax after chest trauma usually presents with tachypnea, shortness of breath, decreased or absent breath sounds, unilateral hyperresonance to percussion, and pleuritic chest pain. This patient's bilaterally equal breath sounds make this unlikely.

Educational objective:
Any abdominal process (eg, ruptured spleen, peritonitis, hemoperitoneum) irritating the phrenic nerve sensory fibers around the diaphragm can cause referred pain to the C3-C5 shoulder region (Kehr sign).

References

- Traditional Kehr's sign: Left shoulder pain related to splenic abscess.

https://t.me/USMLEWorldStep1

A 6-hour-old boy is in the newborn nursery with feeding difficulties. The patient was born at 39 weeks gestation to a 33-year-old primigravida via cesarean delivery due to failure to progress and late decelerations seen on fetal heart tracing. Apgar scores were 8 and 9, but examination shows an infant with excessive drooling and coughing. Cardiac, respiratory, and abdominal examinations are otherwise normal at rest. When the infant attempts to breastfeed, however, several bouts of coughing and perioral cyanosis develop with oxygen saturation of 85% on room air. Which of the following is the most likely cause of this patient's condition?

- A. Atresia of small intestine
- B. Collapse of supraglottic structures during respiration
- C. Failure of primitive foregut to separate from airway
- D. Obstruction of posterior nasal passages
- E. Thoracic herniation of abdominal viscera

Submit

https://t.me/USMLEWorldStep1

A 6-hour-old boy is in the newborn nursery with feeding difficulties. The patient was born at 39 weeks gestation to a 33-year-old primigravida via cesarean delivery due to failure to progress and late decelerations seen on fetal heart tracing. Apgar scores were 8 and 9, but examination shows an infant with excessive drooling and coughing. Cardiac, respiratory, and abdominal examinations are otherwise normal at rest. When the infant attempts to breastfeed, however, several bouts of coughing and perioral cyanosis develop with oxygen saturation of 85% on room air. Which of the following is the most likely cause of this patient's condition?

- A. Atresia of small intestine (2%)
- ✗ B. Collapse of supraglottic structures during respiration (5%)
- ✓ C. Failure of primitive foregut to separate from airway (83%)
- D. Obstruction of posterior nasal passages (6%)
- E. Thoracic herniation of abdominal viscera (1%)

Incorrect
Correct answer
C

83%
Answered correctly

03 secs
Time Spent

2023
Version

Explanation

https://t.me/USMLEWorldStep1

Exhibit Display

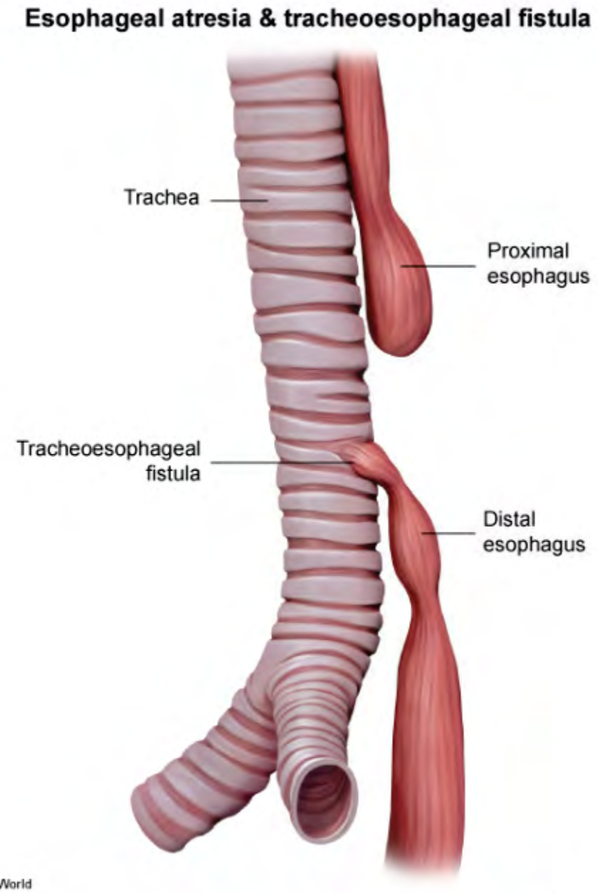

Zoom In | Zoom Out | Reset | New | Existing | My Notebook

https://t.me/USMLEWorldStep1

This infant's presentation is concerning for **tracheoesophageal fistula with esophageal atresia (TEF/EA)**. Normally, the trachea develops from a diverticulum that forms from the **primitive foregut**. The tracheobronchial diverticulum lengthens and separates to form the respiratory tract, while the foregut becomes the esophagus. Failure to separate most commonly leads to esophageal atresia with a remaining fistula between the trachea and esophagus.

Prenatal ultrasounds may demonstrate **polyhydramnios** due to the inability of the fetus to swallow amniotic fluid. After birth, infants typically present with significant **drooling** (due to inability to swallow saliva) and choking, **coughing**, and **cyanosis with feeds** (due to reflux of breastmilk/formula and aspiration into the trachea/lungs). The diagnosis of TEF/EA is confirmed by x-ray showing positioning of the nasogastric tube in the atretic esophageal pouch after an attempt to pass the tube into the stomach. X-ray will also show a **stomach bubble**, which results from air flow from the trachea through the fistula to the distal esophagus.

(Choice A) Atresia of the small intestine is a congenital defect that leads to complete obstruction of the gastrointestinal tract at the site of atresia. Neonates present with abdominal distension and bilious emesis.

(Choice B) Laryngomalacia presents with inspiratory stridor during infancy due to collapse of supraglottic structures during inspiration. Stridor is classically worse in the supine position and improves with upright positioning.

(Choice D) Choanal atresia is characterized by congenital obstruction of the posterior nasal passages. Infants with bilateral choanal atresia can present with upper airway obstruction and cyanosis with feeding, but not excessive drooling and coughing. Inability to pass a nasogastric tube through the nares is suggestive of the diagnosis.

(Choice E) Herniation of abdominal viscera into the thoracic cavity occurs in congenital diaphragmatic hernia. Infants typically exhibit respiratory distress shortly after birth due to pulmonary hypoplasia. The presence of abdominal viscera in the thorax results in a scaphoid abdomen and bowel sounds heard over the chest.

Educational objective:
Tracheoesophageal fistula with esophageal atresia results from failure of the primitive foregut to appropriately divide into separate trachea and esophageal structures. Infants present shortly after birth with excessive

https://t.me/USMLEWorldStep1

Failure to separate most commonly leads to esophageal atresia with a remaining fistula between the trachea and esophagus.

Prenatal ultrasounds may demonstrate **polyhydramnios** due to the inability of the fetus to swallow amniotic fluid. After birth, infants typically present with significant **drooling** (due to inability to swallow saliva) and choking, **coughing**, and **cyanosis with feeds** (due to reflux of breastmilk/formula and aspiration into the trachea/lungs). The diagnosis of TEF/EA is confirmed by x-ray showing positioning of the nasogastric tube in the atretic esophageal pouch after an attempt to pass the tube into the stomach. X-ray will also show a **stomach bubble**, which results from air flow from the trachea through the fistula to the distal esophagus.

(Choice A) Atresia of the small intestine is a congenital defect that leads to complete obstruction of the gastrointestinal tract at the site of atresia. Neonates present with abdominal distension and bilious emesis.

(Choice B) Laryngomalacia presents with inspiratory stridor during infancy due to collapse of supraglottic structures during inspiration. Stridor is classically worse in the supine position and improves with upright positioning.

(Choice D) Choanal atresia is characterized by congenital obstruction of the posterior nasal passages. Infants with bilateral choanal atresia can present with upper airway obstruction and cyanosis with feeding, but not excessive drooling and coughing. Inability to pass a nasogastric tube through the nares is suggestive of the diagnosis.

(Choice E) Herniation of abdominal viscera into the thoracic cavity occurs in congenital diaphragmatic hernia. Infants typically exhibit respiratory distress shortly after birth due to pulmonary hypoplasia. The presence of abdominal viscera in the thorax results in a scaphoid abdomen and bowel sounds heard over the chest.

Educational objective:
Tracheoesophageal fistula with esophageal atresia results from failure of the primitive foregut to appropriately divide into separate trachea and esophageal structures. Infants present shortly after birth with excessive secretions and choking/cyanosis during feeds.

References

- Oesophageal atresia and tracheo-oesophageal fistula.

https://t.me/USMLEWorldStep1

The diagnosis of TEF/EA is confirmed by x-ray showing positioning of the nasogastric tube in the atretic esophageal pouch after an attempt to pass the tube into the stomach. X-ray will also show a **stomach bubble**, which

(Choi
gastro

(Choi
structu
positio

(Choi
with bi
excess
diagno

(Choi
Infants
abdom

Educa
Trache
divide
secret

Refere
- Oe
- Cu
- Tra

Embryo
Subject

Copyright © UWorld. All rights reserved.

Exhibit Display

Choanal atresia

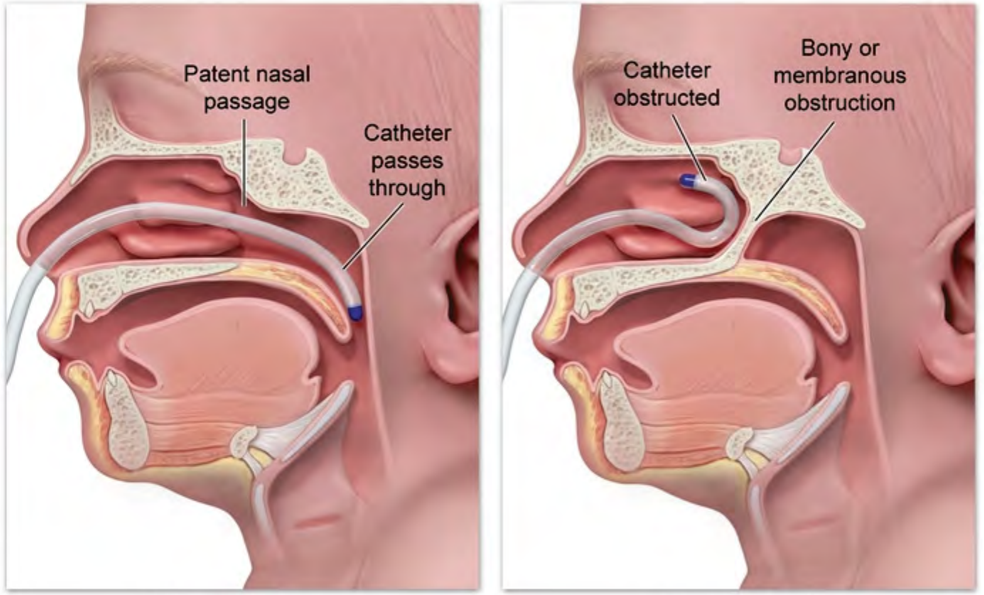

Normal anatomy **Choanal atresia**

©UWorld

Zoom In Zoom Out Reset New | Existing My Notebook

https://t.me/USMLEWorldStep1

A 57-year-old woman is hospitalized with high-grade fevers, chills, and right upper abdominal pain. The patient lives in Wisconsin and has no history of international travel. Her temperature is 40 C (104 F). Physical examination of the abdomen shows rebound tenderness. Laboratory studies show elevated aspartate and alanine aminotransferases. Imaging studies reveal a fluid-filled cavity within the right lobe of the liver as shown below.

Which of the following microorganism/route combinations is most likely to be the cause of this patient's infection?

A. *Chlamydia trachomatis* due to ascending cholangitis

https://t.me/USMLEWorldStep1

A 57-year-old woman is hospitalized with high-grade fevers, chills, and right upper abdominal pain. The patient lives ir
exami
amino

Exhibit Display

Zoom In | Zoom Out | Reset | New | Existing | My Notebook

Which

A. *Chlamydia trachomatis* due to ascending cholangitis

https://t.me/USMLEWorldStep1

Which of the following microorganism/route combinations is most likely to be the cause of this patient's infection?

- A. *Chlamydia trachomatis* due to ascending cholangitis
- B. Cytomegalovirus by direct invasion from a nearby source
- C. *Entamoeba histolytica* due to a penetrating stab wound
- D. *Staphylococcus aureus* by hematogenous route
- E. *Streptococcus pneumoniae* by portal vein

Submit

https://t.me/USMLEWorldStep1

Which of the following microorganism/route combinations is most likely to be the cause of this patient's infection?

- A. *Chlamydia trachomatis* due to ascending cholangitis (7%)
- ✗ B. Cytomegalovirus by direct invasion from a nearby source (6%)
- C. *Entamoeba histolytica* due to a penetrating stab wound (37%)
- ✓ D. *Staphylococcus aureus* by hematogenous route (43%)
- E. *Streptococcus pneumoniae* by portal vein (5%)

Incorrect
Correct answer
D

43%
Answered correctly

14 secs
Time Spent

2023
Version

https://t.me/USMLEWorldStep1

Explanation

Exhibit Display

Hepatic abscess

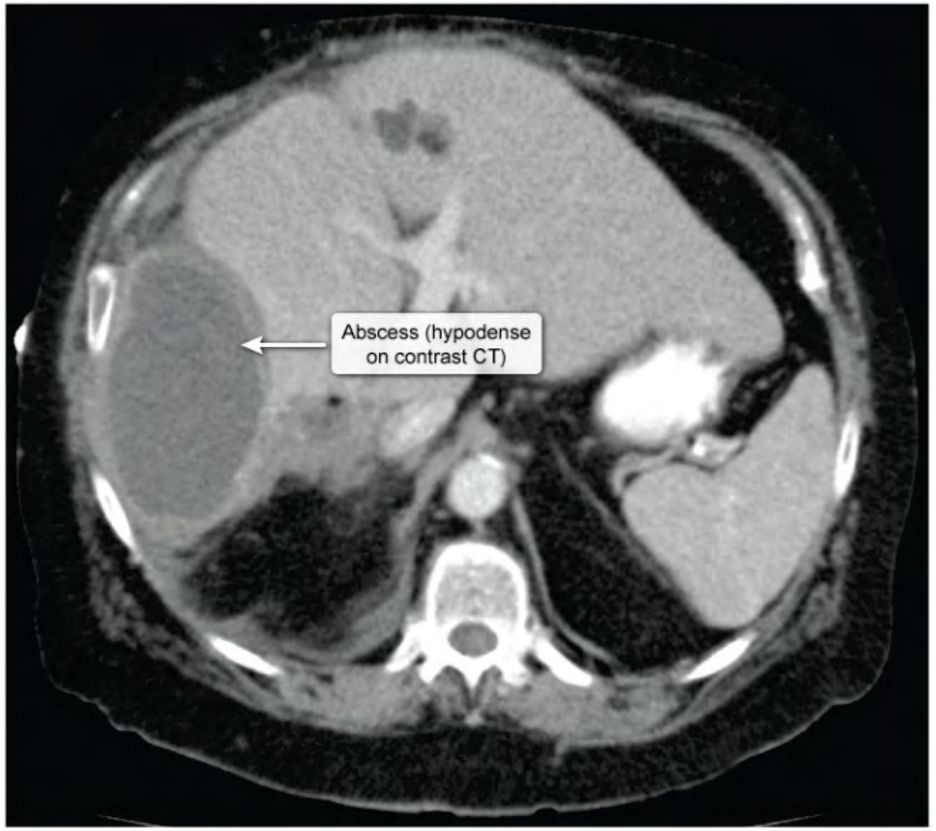

©UWorld

Zoom In | Zoom Out | Reset | New | Existing | My Notebook

The pr
sugge
are usually caused by parasitic infections (eg, *Entamoeba histolytica*, echinococcal). In contrast, hepatic abscesses are uncommon in the United States and are caused by **bacterial infection** in about 80% of cases

https://t.me/USMLEWorldStep1

©UWorld

The presence of a **fluid-filled cavity** in the liver in conjunction with fevers, chills, and right upper abdominal pain is suggestive of a **hepatic abscess**. In developing countries, hepatic abscesses have a relatively high incidence and are usually caused by parasitic infections (eg, *Entamoeba histolytica*, echinococcal). In contrast, hepatic abscesses are uncommon in the United States and are caused by **bacterial infection** in about 80% of cases.

Pyogenic bacteria can gain access to the liver through the following routes:

- **Biliary tract infection** (eg, ascending cholangitis)
- **Portal vein pyemia** (bowel or peritoneal sources)
- Hepatic artery (systemic hematogenous seeding)
- Direct invasion from an adjacent source (eg, peritonitis, cholecystitis)
- Penetrating trauma or injury

The types of organisms causing a hepatic abscess depend on the route of hepatic access. Systemic **hematogenous seeding** of the liver secondary to ***Staphylococcus aureus*** infection at a distant site is the most plausible choice of all the answer options.

(Choice A) Ascending cholangitis is usually caused by enteric gram-negative bacilli (eg, *Escherichia coli*, *Klebsiella*) and enterococci. *Chlamydia trachomatis* is transmitted sexually and is not found in the enteric environment.

(Choice B) Hepatic abscesses that arise by direct invasion from a nearby source are usually enteric gram-negative bacilli and enterococci. Cytomegalovirus can cause hepatitis in the immunosuppressed patient, but it is not associated with the development of a hepatic abscess.

(Choice C) Traumatic penetrating injuries to the abdomen (eg, stab wound) typically result in abscesses that contain mixed aerobic and anaerobic flora. *Entamoeba histolytica* is most often transmitted through foodborne exposure and in areas with poor sanitation. It can cause a hepatic abscess by ascending from the colon through the portal venous system.

(Choice E) *Streptococcus pneumoniae* colonizes the nasopharynx and typically causes disease within the respiratory tract region (eg, pneumonia, otitis media, sinusitis) and meningitis. However, hepatic abscesses due to

https://t.me/USMLEWorldStep1

- Direct invasion from an adjacent source (eg, peritonitis, cholecystitis)
- Penetrating trauma or injury

The types of organisms causing a hepatic abscess depend on the route of hepatic access. Systemic **hematogenous seeding** of the liver secondary to ***Staphylococcus aureus*** infection at a distant site is the most plausible choice of all the answer options.

(Choice A) Ascending cholangitis is usually caused by enteric gram-negative bacilli (eg, *Escherichia coli*, *Klebsiella*) and enterococci. *Chlamydia trachomatis* is transmitted sexually and is not found in the enteric environment.

(Choice B) Hepatic abscesses that arise by direct invasion from a nearby source are usually enteric gram-negative bacilli and enterococci. Cytomegalovirus can cause hepatitis in the immunosuppressed patient, but it is not associated with the development of a hepatic abscess.

(Choice C) Traumatic penetrating injuries to the abdomen (eg, stab wound) typically result in abscesses that contain mixed aerobic and anaerobic flora. *Entamoeba histolytica* is most often transmitted through foodborne exposure and in areas with poor sanitation. It can cause a hepatic abscess by ascending from the colon through the portal venous system.

(Choice E) *Streptococcus pneumoniae* colonizes the nasopharynx and typically causes disease within the respiratory tract region (eg, pneumonia, otitis media, sinusitis) and meningitis. However, hepatic abscesses due to portal vein seeding typically arise from abdominal infectious processes (eg, appendicitis, diverticulitis) and *S pneumoniae* is not an enteric pathogen.

Educational objective:
Staphylococcus aureus can cause hepatic abscesses via hematogenous seeding of the liver. Enteric bacteria (eg, *Escherichia coli*, *Klebsiella*, and enterococci) can cause hepatic abscesses by ascending the biliary tract (ie, ascending cholangitis), portal vein pyemia, or direct invasion from an adjacent area (eg, cholecystitis).

Microbiology	Gastrointestinal & Nutrition	Liver abscess
Subject	System	Topic

https://t.me/USMLEWorldStep1

A 54-year-old woman is evaluated in the clinic for exertional dyspnea and easy fatigability. The patient has no chest pain, cough, or wheezing. She does not use tobacco, alcohol, or recreational drugs. On physical examination, her gait is unstable when her eyes are closed and there is impaired vibratory sensation in the lower extremities. Marked pallor of the conjunctivae, nail beds, and palms is present. Which of the following laboratory tests would help confirm the most likely diagnosis in this patient?

- A. Erythrocyte glucose-6-phosphate dehydrogenase activity
- B. Erythrocyte glutathione reductase activity
- C. Erythrocytic pyruvate kinase activity
- D. Erythrocyte transketolase activity
- E. Serum methylmalonic acid level
- F. Serum protoporphyrin level

Submit

https://t.me/USMLEWorldStep1

A 54-year-old woman is evaluated in the clinic for exertional dyspnea and easy fatigability. The patient has no chest pain, cough, or wheezing. She does not use tobacco, alcohol, or recreational drugs. On physical examination, her gait is unstable when her eyes are closed and there is impaired vibratory sensation in the lower extremities. Marked pallor of the conjunctivae, nail beds, and palms is present. Which of the following laboratory tests would help confirm the most likely diagnosis in this patient?

- A. Erythrocyte glucose-6-phosphate dehydrogenase activity (4%)
- ✕ B. Erythrocyte glutathione reductase activity (5%)
- C. Erythrocytic pyruvate kinase activity (3%)
- D. Erythrocyte transketolase activity (5%)
- ✓ E. Serum methylmalonic acid level (73%)
- F. Serum protoporphyrin level (7%)

Incorrect
Correct answer
E

73%
Answered correctly

04 secs
Time Spent

2023
Version

Explanation

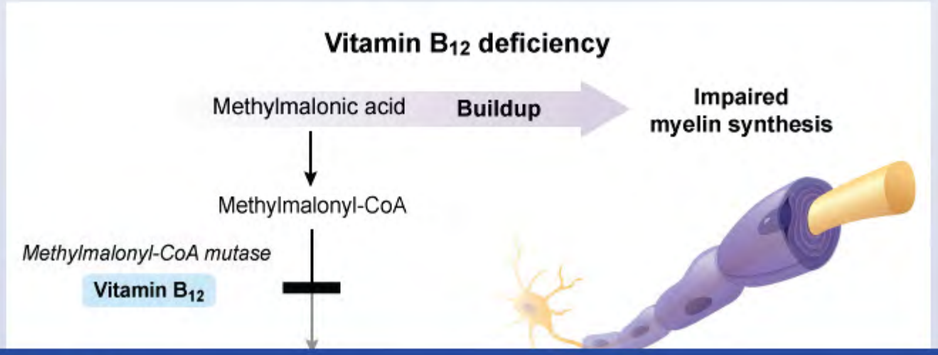

https://t.me/USMLEWorldStep1

F. Serum protoporphyrin level (7%)

Exhibit Display

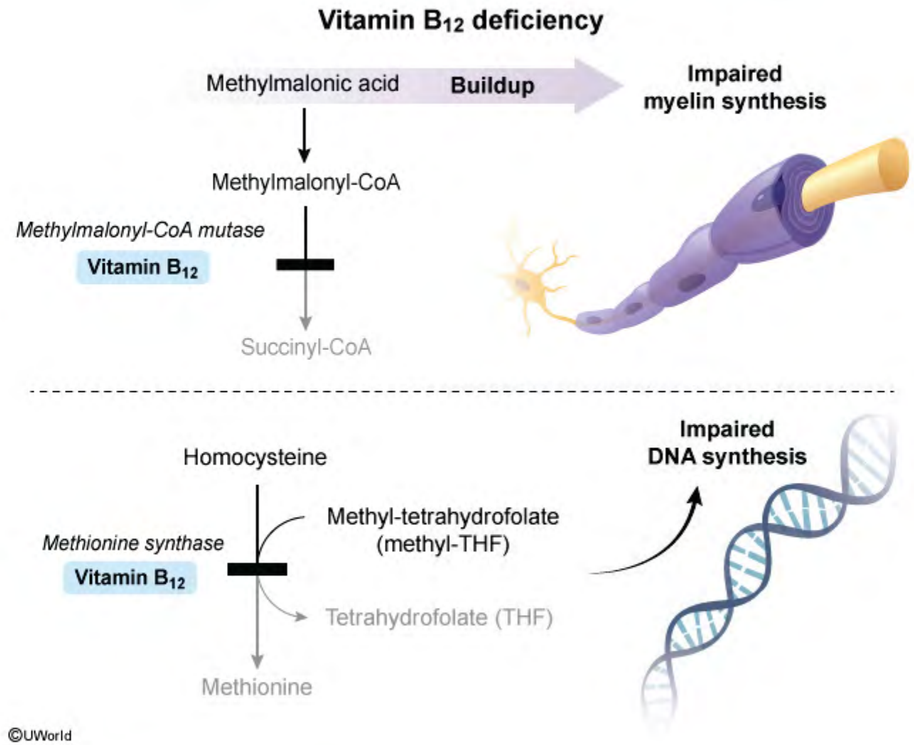

Zoom In | Zoom Out | Reset | New | Existing | My Notebook

This p
are highly suggestive of **vitamin B_{12} deficiency**. The hematologic manifestations of B_{12} deficiency (eg, **megaloblastic anemia**, pancytopenia) are related to impaired DNA synthesis.

https://t.me/USMLEWorldStep1

Methionine

©UWorld

This patient has features of anemia (eg, exertional dyspnea, fatigue, pallor) with associated neurologic deficits that are highly suggestive of **vitamin B_{12} deficiency**. The hematologic manifestations of B_{12} deficiency (eg, **megaloblastic anemia**, pancytopenia) are related to impaired DNA synthesis.

Vitamin B_{12} (hydroxocobalamin) also serves as a cofactor for methylmalonyl-CoA mutase (converts methylmalonyl-CoA to succinyl-CoA) and methionine synthase (converts homocysteine and folic acid to methionine). B_{12} deficiency consequently results in **elevated** levels of serum **methylmalonic acid and homocysteine**. Increased methylmalonic acid levels can disrupt myelin synthesis and result in **subacute combined degeneration** of the dorsal columns (eg, loss of proprioception/vibration, Romberg sign) and lateral corticospinal tract (eg, spastic muscle weakness, hyperreflexia). Axonal degeneration of peripheral nerves can also be seen.

(Choice A) Glucose-6-phosphate dehydrogenase deficiency (G6PD) leads to acute hemolytic anemia in response to oxidative stress. Neurologic manifestations are not present in G6PD-associated anemia.

(Choice B) Erythrocyte glutathione reductase activity may be decreased in patients with vitamin B_2 (riboflavin) deficiency because glutathione reductase uses bound FAD (derived from vitamin B_2) and NADPH as cofactors to reduce disulfide bonds. Vitamin B_2 deficiency typically presents with normocytic anemia and inflammation of the lips (cheilosis), mouth (stomatitis), and/or tongue (glossitis).

(Choice C) Pyruvate kinase generates ATP through the conversion of phosphoenolpyruvate to pyruvate. Pyruvate kinase deficiency is an autosomal recessive condition that typically presents with congenital hemolytic anemia due to impaired glycolytic ATP generation.

(Choice D) Transketolase is an enzyme of the hexose monophosphate pathway that utilizes thiamine (vitamin B_1) as a coenzyme. Erythrocyte transketolase activity is decreased in thiamine deficiency, which causes Wernicke-Korsakoff syndrome and beriberi.

(Choice F) Serum protoporphyrin levels are increased in iron deficiency anemia, lead poisoning, and erythropoietic protoporphyria. Lead poisoning can cause sideroblastic anemia and peripheral neuropathy, but other characteristic features (eg, abdominal/musculoskeletal pain, cognitive impairment, nephropathy) are not

https://t.me/USMLEWorldStep1

CoA to succinyl-CoA) and methionine synthase (converts homocysteine and folic acid to methionine). B_{12} deficiency consequently results in **elevated** levels of serum **methylmalonic acid and homocysteine**. Increased methylmalonic acid levels can disrupt myelin synthesis and result in **subacute combined degeneration** of the dorsal columns (eg, loss of proprioception/vibration, Romberg sign) and lateral corticospinal tract (eg, spastic muscle weakness, hyperreflexia). Axonal degeneration of peripheral nerves can also be seen.

(Choice A) Glucose-6-phosphate dehydrogenase deficiency (G6PD) leads to acute hemolytic anemia in response to oxidative stress. Neurologic manifestations are not present in G6PD-associated anemia.

(Choice B) Erythrocyte glutathione reductase activity may be decreased in patients with vitamin B_2 (riboflavin) deficiency because glutathione reductase uses bound FAD (derived from vitamin B_2) and NADPH as cofactors to reduce disulfide bonds. Vitamin B_2 deficiency typically presents with normocytic anemia and inflammation of the lips (cheilosis), mouth (stomatitis), and/or tongue (glossitis).

(Choice C) Pyruvate kinase generates ATP through the conversion of phosphoenolpyruvate to pyruvate. Pyruvate kinase deficiency is an autosomal recessive condition that typically presents with congenital hemolytic anemia due to impaired glycolytic ATP generation.

(Choice D) Transketolase is an enzyme of the hexose monophosphate pathway that utilizes thiamine (vitamin B_1) as a coenzyme. Erythrocyte transketolase activity is decreased in thiamine deficiency, which causes Wernicke-Korsakoff syndrome and beriberi.

(Choice F) Serum protoporphyrin levels are increased in iron deficiency anemia, lead poisoning, and erythropoietic protoporphyria. Lead poisoning can cause sideroblastic anemia and peripheral neuropathy, but other characteristic features (eg, abdominal/musculoskeletal pain, cognitive impairment, nephropathy) are not evident in this patient.

Educational objective:
Vitamin B_{12} deficiency often presents with megaloblastic anemia (impaired DNA synthesis) and neurologic deficits (impaired myelin synthesis). Characteristic neurologic findings include subacute combined degeneration of the dorsal columns and lateral corticospinal tract. Elevations in methylmalonic acid and homocysteine levels occur due to decreased metabolism of these molecules.

https://t.me/USMLEWorldStep1

A 5-month-old boy is being evaluated for poor weight gain since birth. He is noted to have bulky and greasy stools. A jejunal biopsy shows the findings seen in the slide below.

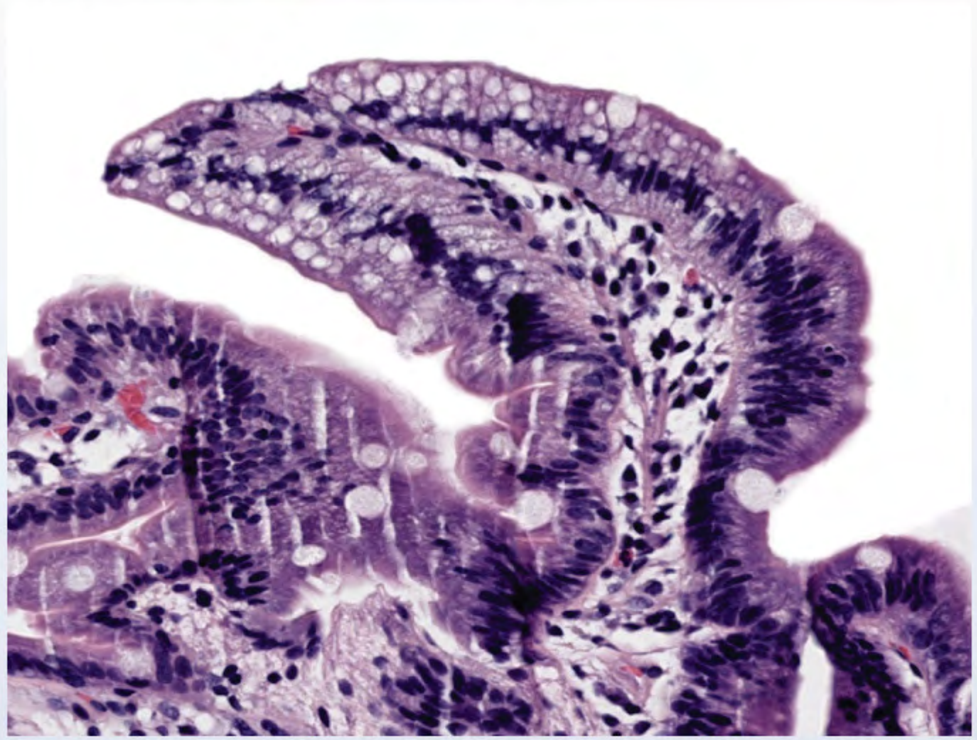

Which of the following is the most likely diagnosis?

- A. Abetalipoproteinemia
- B. Chronic pancreatitis
- C. Crohn disease
- D. Lactase deficiency
- E. Whipple disease

https://t.me/USMLEWorldStep1

A 5-month-old boy is being evaluated for poor weight gain since birth. He is noted to have bulky and greasy stools.

Exhibit Display

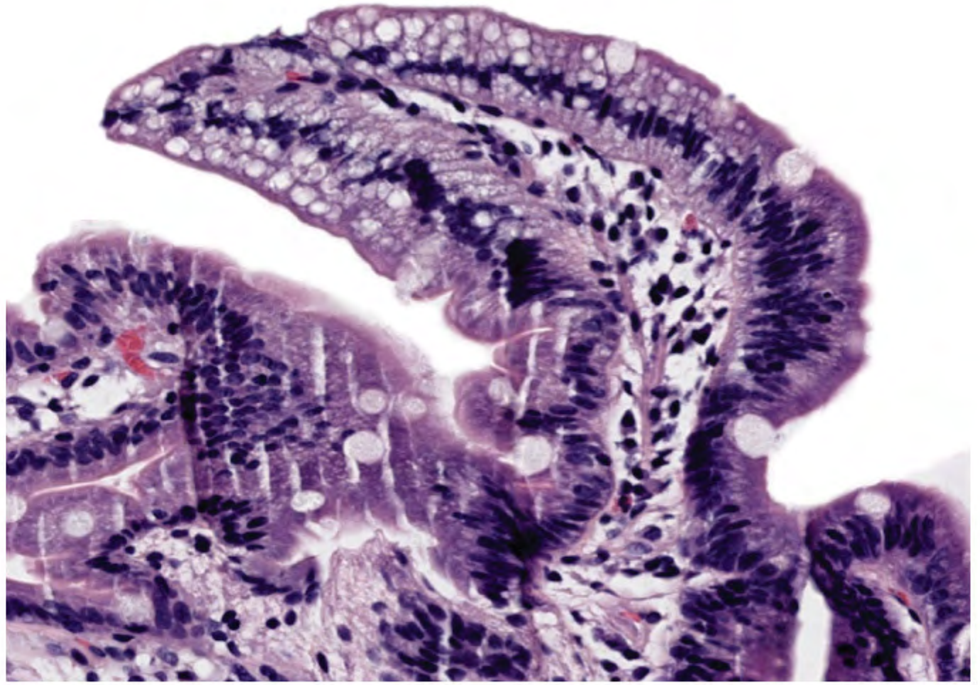

Zoom In | Zoom Out | Reset | New | Existing | My Notebook

Which

E. Whipple disease

https://t.me/USMLEWorldStep1

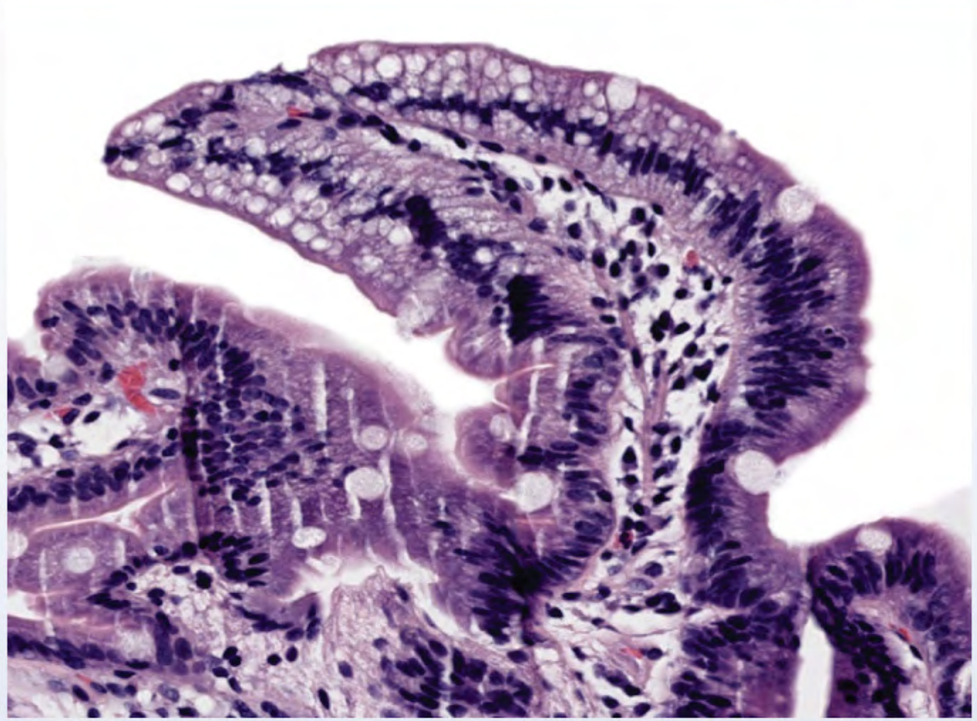

Which of the following is the most likely diagnosis?

- A. Abetalipoproteinemia
- B. Chronic pancreatitis
- C. Crohn disease
- D. Lactase deficiency
- E. Whipple disease
- F. Zollinger-Ellison syndrome

Submit

https://t.me/USMLEWorldStep1

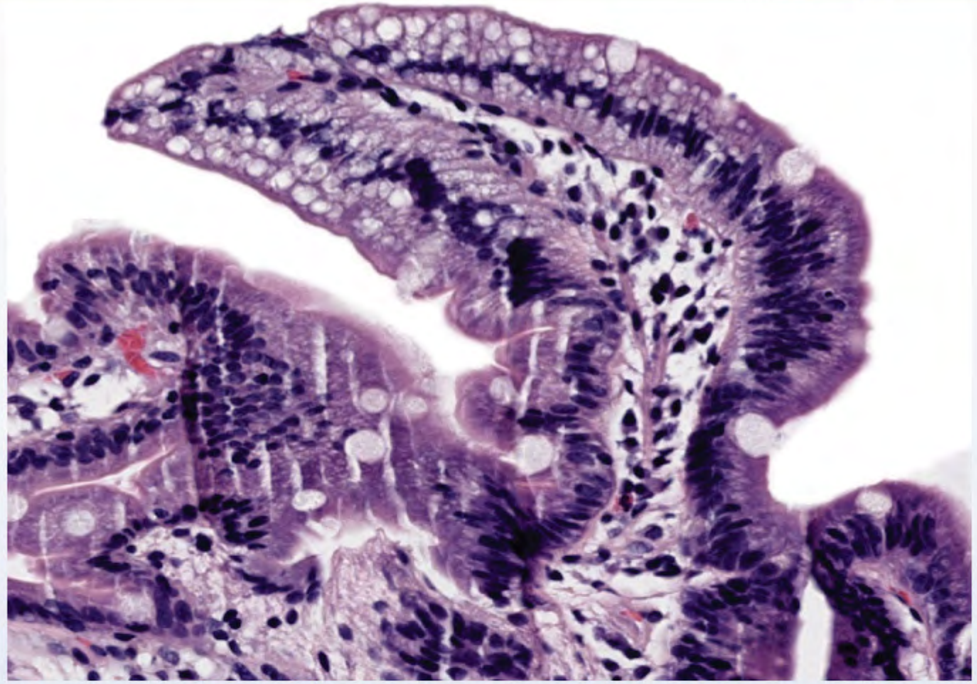

Which of the following is the most likely diagnosis?

- ✓ A. Abetalipoproteinemia (40%)
- B. Chronic pancreatitis (5%)
- ✗ C. Crohn disease (6%)
- D. Lactase deficiency (17%)
- E. Whipple disease (26%)
- F. Zollinger-Ellison syndrome (3%)

Incorrect
Correct answer
A

40%
Answered correctly

25 secs
Time Spent

2023
Version

https://t.me/USMLEWorldStep1

Incorrect
Correct answer
A

40%
Answered correctly

25 secs
Time Spent

2023
Version

Exhibit Display

Abetalipoproteinemia

*Most prominent at tips of villi.

©UWorld

Zoom In | Zoom Out | Reset | New | Existing | My Notebook

The sl… **cytoplasm** which is more prominent at the tips of the villi. These findings occur due to **accumulation of lipids** in

https://t.me/USMLEWorldStep1

The slide above shows normal intestinal mucosal architecture, but the enterocytes contain **clear or foamy cytoplasm** which is more prominent at the tips of the villi. These findings occur due to **accumulation of lipids** in the absorptive cells of the intestinal epithelium and are typical of **abetalipoproteinemia**, a disease caused by impaired formation of apolipoprotein B (apoB)-containing lipoproteins.

Dietary lipids are normally processed in small-bowel enterocytes and secreted as chylomicrons; endogenously produced lipids are secreted from hepatocytes as very low-density lipoprotein (VLDL). Chylomicron and VLDL particles are synthesized within the endoplasmic reticulum as lipids accumulate around apolipoprotein B (ApoB). ApoB-100 is found in VLDL, and apoB-48 (a truncated version without the LDL receptor ligand) is present in chylomicrons. During the synthesis of apoB-containing lipoproteins, **microsomal triglyceride transfer protein** (MTP) functions as a chaperone protein necessary for proper folding of apoB and also participates in the transfer of lipids to newly formed chylomicrons and VLDL particles.

Abetalipoproteinemia is most commonly caused by an autosomal recessive, **loss-of-function mutation** in the ***MTP* gene**. It manifests during the first year of life with symptoms of **malabsorption** (eg, abdominal distention, foul-smelling stool). Laboratory studies show very low plasma triglyceride and cholesterol levels; chylomicrons, VLDLs, and apoB are entirely absent from the blood. Poor lipid absorption causes deficiency of fat-soluble vitamins (particularly vitamin E) and essential fatty acids. This results in red blood cells with abnormal membranes and thorny projections called **acanthocytes** as well as multiple **neurologic abnormalities** (eg, progressive ataxia, retinitis pigmentosa).

(Choices B, D, and F) No abnormalities are found on light microscopy of the small intestine in chronic pancreatitis or lactase deficiency. In Zollinger-Ellison syndrome, the small intestine may show ulcerations due to gastrin production by a neuroendocrine tumor (ie, gastrinoma).

(Choice C) Light microscopy in Crohn disease shows chronic inflammation of all layers of the intestinal wall and noncaseating granulomas.

(Choice E) The characteristic microscopic finding in Whipple disease is distended macrophages in the lamina propria of the small intestine. Macrophages contain PAS-positive and diastase-resistant granules and rod-shaped *Tropheryma whipplei* bacilli.

Educational objective:

https://t.me/USMLEWorldStep1

chylomicrons. During the synthesis of apoB-containing lipoproteins, **microsomal triglyceride transfer protein**
(MTP)
of lipid

Abetal
MTP g
foul-sr
VLDLs
vitami
and th
retiniti

(Choi
or lact
produc

(Choi
nonca

(Choi
propri
Trophe

Educa
Abetal
chylon
the cir
cytopla

Patholo
Subject

Copyright © UWorld. All rights reserved.

Exhibit Display

Crohn disease

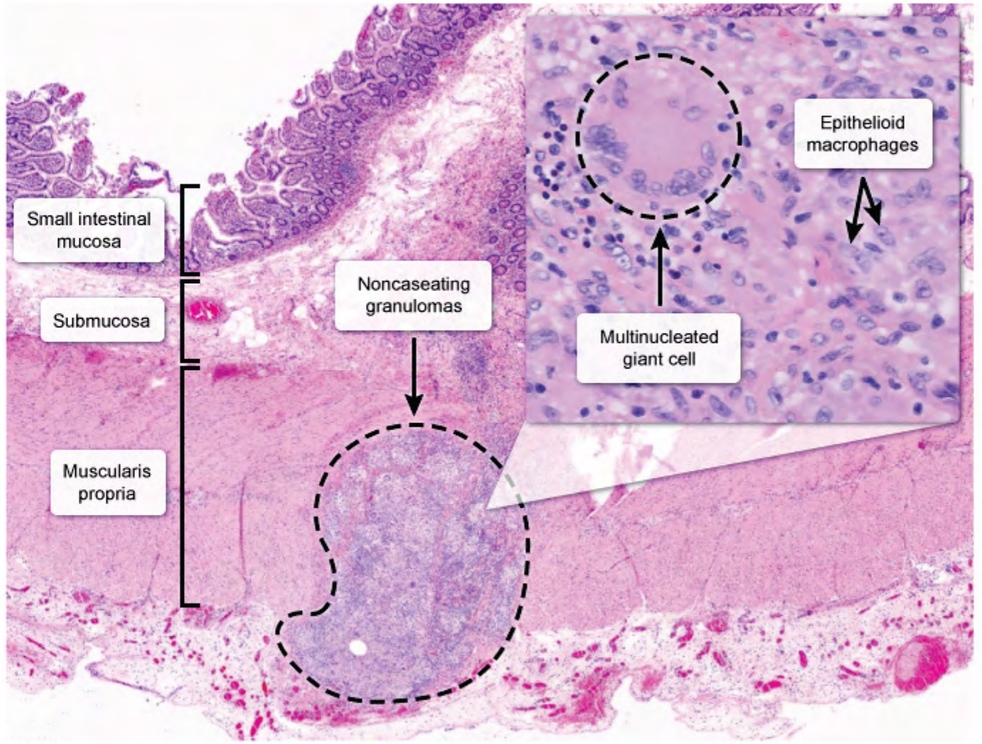

Zoom In | Zoom Out | Reset | New | Existing | My Notebook

https://t.me/USMLEWorldStep1

chylomicrons. During the synthesis of apoB-containing lipoproteins, **microsomal triglyceride transfer protein** (MTP) of lipid

Abetal
MTP g
foul-sr
VLDLs
vitami
and th
retiniti

(Choi
or lact
produc

(Choi
nonca

(Choi
propria
Trophe

Educa
Abetal
chylon
the cir
cytopla

Patholog
Subject

Exhibit Display

Whipple disease

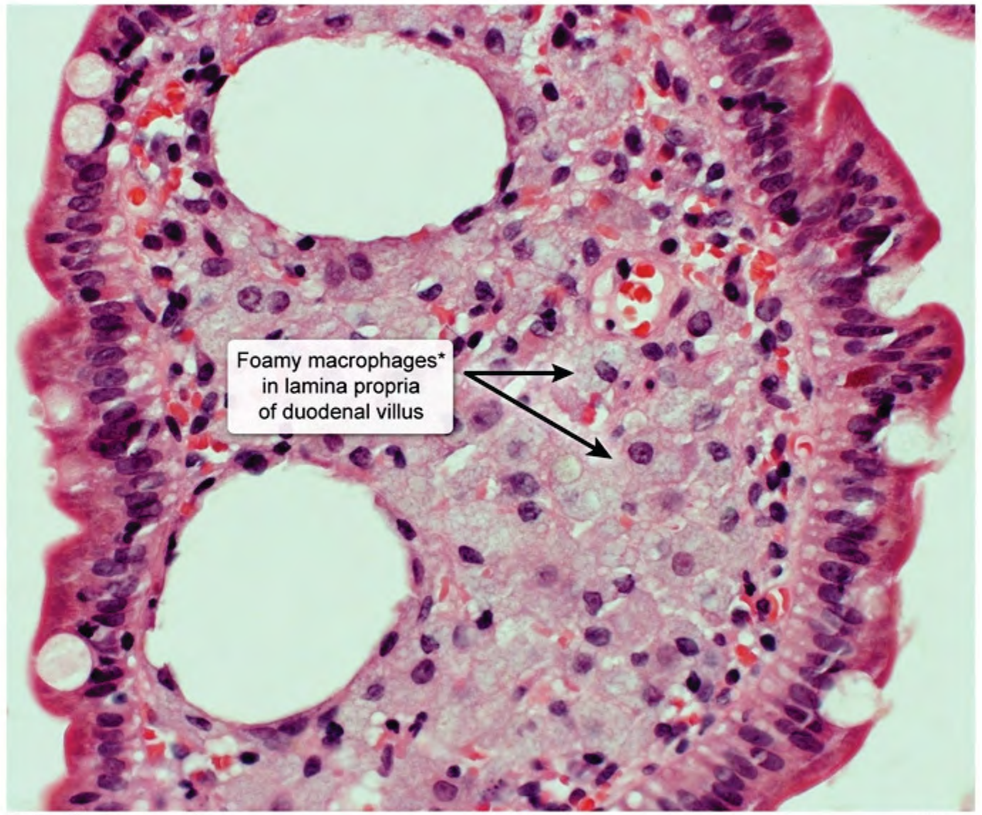

*Contain *Tropheryma whipplei*

©UWorld

Zoom In Zoom Out Reset New | Existing My Notebook

Copyright © UWorld. All rights reserved.

https://t.me/USMLEWorldStep1

A new medication, drug A, is being developed for the treatment of peptic ulcer disease. During initial testing, gastric acid secretion in experimental animals is stimulated by vagal stimulation, histamine infusion, or gastrin infusion. Before the stimulus is administered, the animals are divided into 2 groups, one group receives pretreatment with drug A, and the second one serves as the control and is given an injection of an equivalent volume of normal saline. The effects of the drug on hydrochloric acid (HCl) output by the stomach mucosa are recorded and shown in the graphs below.

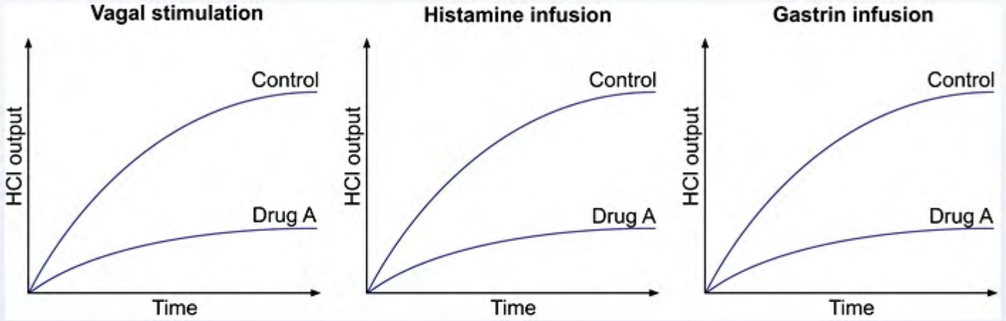

Drug A is most similar to which of the following medications?

- A. Atropine
- B. Bethanechol
- C. Cimetidine
- D. Lansoprazole
- E. Sucralfate

Submit

https://t.me/USMLEWorldStep1

A new medication, drug A, is being developed for the treatment of peptic ulcer disease. During initial testing,
gastric
infusio
pretrea
volum
record

Drug A

Sub

Exhibit Display

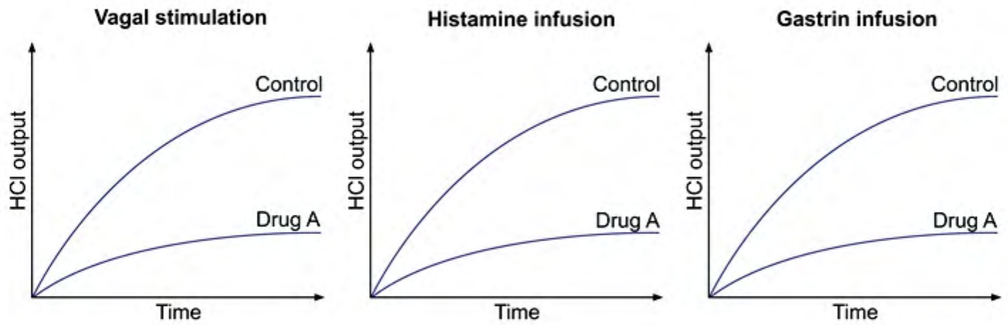

Zoom In Zoom Out Reset New | Existing My Notebook

https://t.me/USMLEWorldStep1

A new medication, drug A, is being developed for the treatment of peptic ulcer disease. During initial testing, gastric acid secretion in experimental animals is stimulated by vagal stimulation, histamine infusion, or gastrin infusion. Before the stimulus is administered, the animals are divided into 2 groups, one group receives pretreatment with drug A, and the second one serves as the control and is given an injection of an equivalent volume of normal saline. The effects of the drug on hydrochloric acid (HCl) output by the stomach mucosa are recorded and shown in the graphs below.

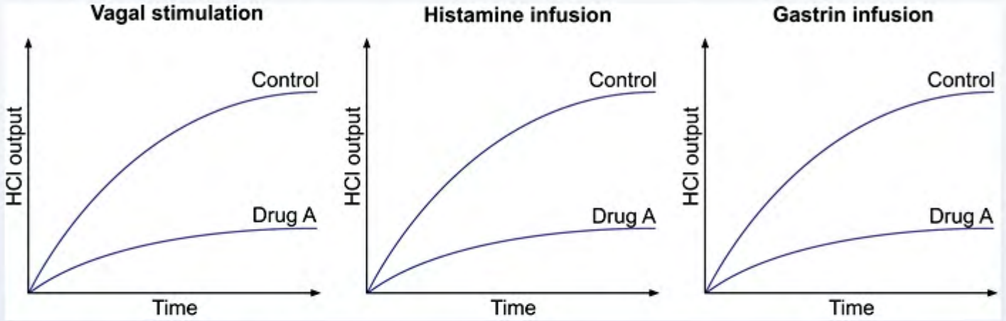

Drug A is most similar to which of the following medications?

- A. Atropine (10%)
- ✗ B. Bethanechol (2%)
- C. Cimetidine (10%)
- ✓ D. Lansoprazole (73%)
- E. Sucralfate (2%)

Incorrect
Correct answer
D

73%
Answered correctly

10 secs
Time Spent

2023
Version

Explanation

https://t.me/USMLEWorldStep1

✓ D. Lansoprazole (73%)

Exhibit Display

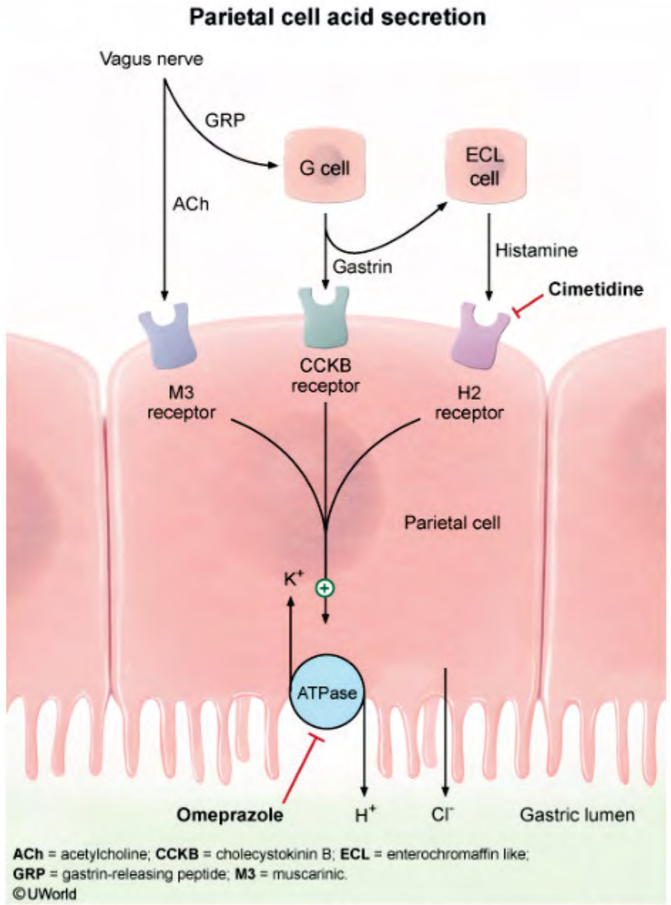

Zoom In | Zoom Out | Reset | New | Existing | My Notebook

https://t.me/USMLEWorldStep1

©UWorld

Gastric **parietal cells** secrete **hydrochloric acid** (HCl) in response to 3 major stimulants: histamine, vagal output, and gastrin.

1. **Histamine** is released from enterochromaffin-like (ECL) cells and binds to H2 receptors on the basolateral parietal cell membrane.
2. Vagal stimulation causes **acetylcholine** release, which directly stimulates HCl secretion by binding to parietal cell muscarinic (M3) receptors. In addition, vagal stimulation indirectly promotes HCl secretion via gastrin-releasing peptide (GRP), which stimulates gastrin release from G cells.
3. G cells also release **gastrin** in response to protein-rich meals. Gastrin primarily stimulates HCl secretion by binding to the CCK_B receptor on ECL cells (promotes histamine release). It also directly binds to the CCK_B receptor on parietal cells, but this mechanism is less significant for acid secretion.

The **final common pathway** for HCl secretion is the **H^+/K^+-ATPase proton pump**, located on the apical membrane of the parietal cell. Based on the graphs shown above, drug A inhibits gastric acid secretion in response to all 3 major stimulants. Therefore, drug A is most similar to a proton pump inhibitor (eg, **lansoprazole**, omeprazole) as it is likely inhibiting the H^+/K^+-ATPase proton pump.

(Choice A) Atropine is a nonselective antimuscarinic agent often used to produce mydriasis/cycloplegia or reverse bradycardia. Atropine may reduce gastric acid secretion in response to vagal stimulation by blocking parietal cell M3 receptors; however, it would not significantly decrease acid secretion during histamine or gastrin infusion.

(Choice B) Bethanechol is a cholinomimetic muscarinic agonist used to treat ileus and urinary retention. Bethanechol would promote gastric acid secretion by stimulating parietal cell M3 receptors.

(Choice C) Cimetidine treats gastroesophageal reflux and peptic ulcer disease by blocking parietal cell H2 receptors. Although H2 receptor blockade would reduce gastric acid secretion in response to histamine or gastrin infusion, it would not significantly reduce acid secretion in response to vagal stimulation.

(Choice E) Sucralfate may promote peptic ulcer healing by binding to the base of mucosal ulcers and providing physical protection against gastric acid; however, it does not inhibit gastric acid secretion.

Educational objective:

https://t.me/USMLEWorldStep1

1. **Histamine** is released from enterochromaffin-like (ECL) cells and binds to H2 receptors on the basolateral parietal cell membrane.
2. Vagal stimulation causes **acetylcholine** release, which directly stimulates HCl secretion by binding to parietal cell muscarinic (M3) receptors. In addition, vagal stimulation indirectly promotes HCl secretion via gastrin-releasing peptide (GRP), which stimulates gastrin release from G cells.
3. G cells also release **gastrin** in response to protein-rich meals. Gastrin primarily stimulates HCl secretion by binding to the CCK_B receptor on ECL cells (promotes histamine release). It also directly binds to the CCK_B receptor on parietal cells, but this mechanism is less significant for acid secretion.

The **final common pathway** for HCl secretion is the **H^+/K^+-ATPase proton pump**, located on the apical membrane of the parietal cell. Based on the graphs shown above, drug A inhibits gastric acid secretion in response to all 3 major stimulants. Therefore, drug A is most similar to a proton pump inhibitor (eg, **lansoprazole**, omeprazole) as it is likely inhibiting the H^+/K^+-ATPase proton pump.

(Choice A) Atropine is a nonselective antimuscarinic agent often used to produce mydriasis/cycloplegia or reverse bradycardia. Atropine may reduce gastric acid secretion in response to vagal stimulation by blocking parietal cell M3 receptors; however, it would not significantly decrease acid secretion during histamine or gastrin infusion.

(Choice B) Bethanechol is a cholinomimetic muscarinic agonist used to treat ileus and urinary retention. Bethanechol would promote gastric acid secretion by stimulating parietal cell M3 receptors.

(Choice C) Cimetidine treats gastroesophageal reflux and peptic ulcer disease by blocking parietal cell H2 receptors. Although H2 receptor blockade would reduce gastric acid secretion in response to histamine or gastrin infusion, it would not significantly reduce acid secretion in response to vagal stimulation.

(Choice E) Sucralfate may promote peptic ulcer healing by binding to the base of mucosal ulcers and providing physical protection against gastric acid; however, it does not inhibit gastric acid secretion.

Educational objective:
Proton pump inhibitors (eg, omeprazole, lansoprazole) block the final common pathway of gastric acid secretion from parietal cells, which is stimulated by acetylcholine, histamine, and gastrin.

References

https://t.me/USMLEWorldStep1

A 65-year-old man is evaluated in the clinic due to several months of abdominal pain and vomiting. The pain starts 2 to 3 hours after meals, is characterized as crampy, and is often associated with bilious vomiting. Lately, the patient has been tolerating only liquids and has consequently lost 12 lbs in the past 4 months. On physical examination, he has mild epigastric tenderness on deep palpation. Contrast-enhanced CT scan of the abdomen shows an irregular mass in the third portion of the duodenum that is infiltrating beyond the gut wall. If this mass continues to enlarge, which of the following structures is most likely to be compromised in this patient?

- A. Common bile duct
- B. Gastroduodenal artery
- C. Portal vein
- D. Superior mesenteric artery
- E. Ureter

Submit

https://t.me/USMLEWorldStep1

A 65-year-old man is evaluated in the clinic due to several months of abdominal pain and vomiting. The pain starts 2 to 3 hours after meals, is characterized as crampy, and is often associated with bilious vomiting. Lately, the patient has been tolerating only liquids and has consequently lost 12 lbs in the past 4 months. On physical examination, he has mild epigastric tenderness on deep palpation. Contrast-enhanced CT scan of the abdomen shows an irregular mass in the third portion of the duodenum that is infiltrating beyond the gut wall. If this mass continues to enlarge, which of the following structures is most likely to be compromised in this patient?

- A. Common bile duct (12%)
- ✗ B. Gastroduodenal artery (18%)
- C. Portal vein (6%)
- ✓ D. Superior mesenteric artery (58%)
- E. Ureter (3%)

Incorrect
Correct answer
D

58%
Answered correctly

03 secs
Time Spent

2023
Version

Explanation

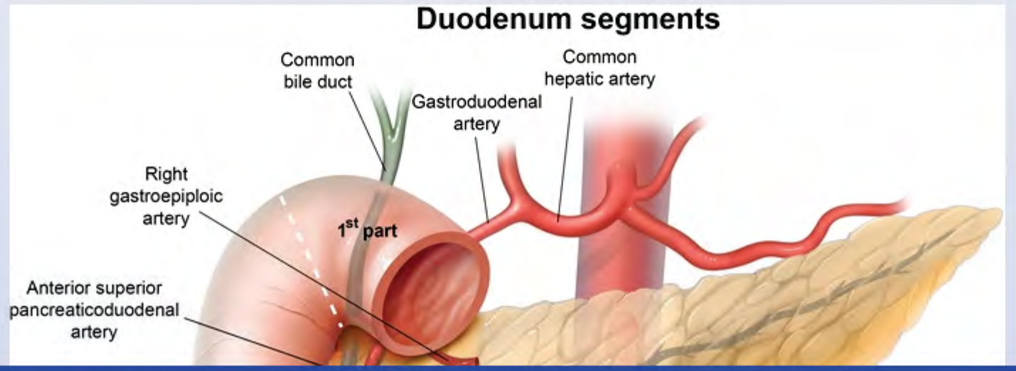

https://t.me/USMLEWorldStep1

A 65-year-old man is evaluated in the clinic due to several months of abdominal pain and vomiting. The pain starts
2 to 3
patien
exami
shows
contin

Exhibit Display

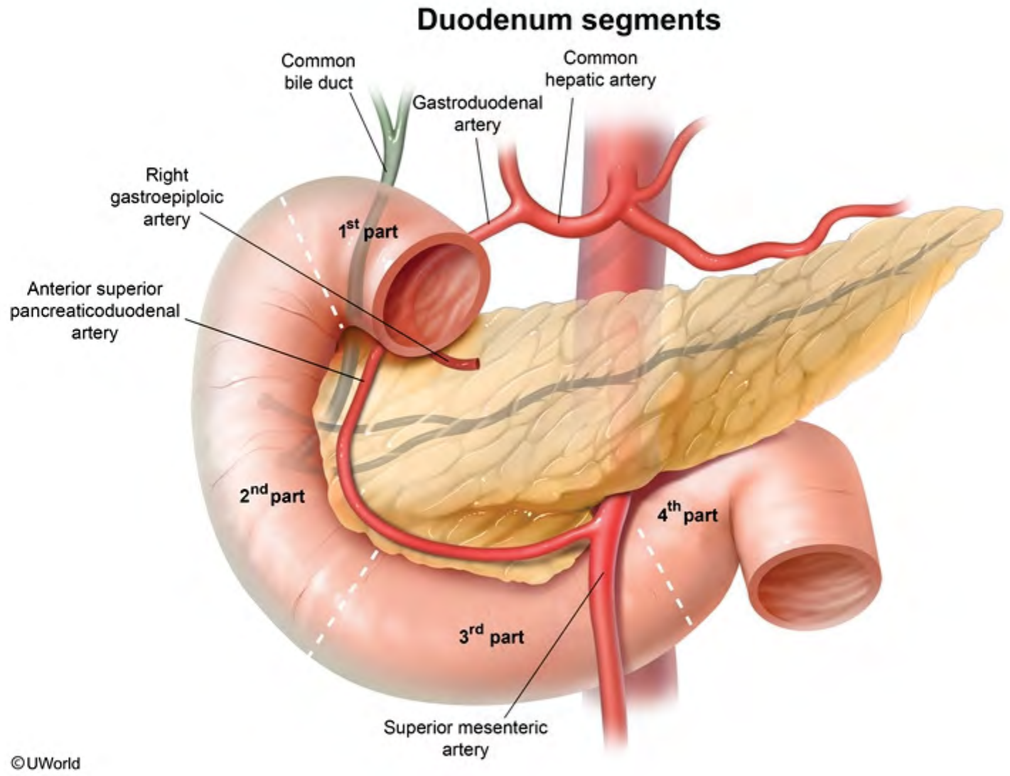

Zoom In | Zoom Out | Reset | New | Existing | My Notebook

Inco
Corre
D

Expl

pancreaticoduodenal artery

https://t.me/USMLEWorldStep1

The first part of the duodenum emerges from the pylorus of the stomach and is horizontally oriented over the first lumbar vertebra. It is the only part of the duodenum that is not retroperitoneal. The second part of the duodenum courses inferiorly from the level of L1 to L3. This part of the duodenum is in close relation to the head of the pancreas and contains the ampulla of Vater, the site where pancreatic and common bile duct secretions are released.

The **third part** of the **duodenum** courses horizontally over L3, the abdominal aorta, and the inferior vena cava. It is in close association with the uncinate process of the pancreas and the **superior mesenteric artery** and vein. Small bowel malignancies are rare; if they occur in the third part of the duodenum, anterior tumor invasion could compromise the superior mesenteric vessels. The fourth part of the duodenum courses superiorly and to the left of the L2 and L3 vertebrae and becomes the jejunum past the ligament of Treitz.

(Choice A) The common bile duct is formed when the common hepatic duct and cystic duct join in the porta hepatis region of the hepatoduodenal ligament. The common bile duct courses inferiorly, posterior to the first part of the duodenum and within the head of the pancreas, to drain into the second part of the duodenum.

(Choice B) The gastroduodenal artery arises from the common hepatic artery and courses inferiorly, posterior to the first part of the duodenum, where it then splits into the anterior superior pancreaticoduodenal artery and the right gastroepiploic artery. Peptic ulcers involving the posterior duodenal bulb can erode into the gastroduodenal artery and cause bleeding.

(Choice C) The portal vein is formed by the union of the superior mesenteric and splenic veins in the retroperitoneum. It is located posterior to the pancreas at the level of the first lumbar vertebra and makes no contact with the duodenum.

(Choice E) The left ureter has no relation to the duodenum. The right ureter courses retroperitoneally, posterior to the second part of the duodenum, for a short length.

Educational objective:
The third part of the duodenum courses horizontally across the abdominal aorta and inferior vena cava at the level of the third lumbar vertebra. The superior mesenteric vessels lie anterior to the duodenum at this location.

https://t.me/USMLEWorldStep1

courses inferiorly from the level of L1 to L3. This part of the duodenum is in close relation to the head of the pancreas and contains the ampulla of Vater, the site where pancreatic and common bile duct secretions are released.

The **third part** of the **duodenum** courses horizontally over L3, the abdominal aorta, and the inferior vena cava. It is in close association with the uncinate process of the pancreas and the **superior mesenteric artery** and vein. Small bowel malignancies are rare; if they occur in the third part of the duodenum, anterior tumor invasion could compromise the superior mesenteric vessels. The fourth part of the duodenum courses superiorly and to the left of the L2 and L3 vertebrae and becomes the jejunum past the ligament of Treitz.

(Choice A) The common bile duct is formed when the common hepatic duct and cystic duct join in the porta hepatis region of the hepatoduodenal ligament. The common bile duct courses inferiorly, posterior to the first part of the duodenum and within the head of the pancreas, to drain into the second part of the duodenum.

(Choice B) The gastroduodenal artery arises from the common hepatic artery and courses inferiorly, posterior to the first part of the duodenum, where it then splits into the anterior superior pancreaticoduodenal artery and the right gastroepiploic artery. Peptic ulcers involving the posterior duodenal bulb can erode into the gastroduodenal artery and cause bleeding.

(Choice C) The portal vein is formed by the union of the superior mesenteric and splenic veins in the retroperitoneum. It is located posterior to the pancreas at the level of the first lumbar vertebra and makes no contact with the duodenum.

(Choice E) The left ureter has no relation to the duodenum. The right ureter courses retroperitoneally, posterior to the second part of the duodenum, for a short length.

Educational objective:
The third part of the duodenum courses horizontally across the abdominal aorta and inferior vena cava at the level of the third lumbar vertebra. The superior mesenteric vessels lie anterior to the duodenum at this location.

References

- Upper gastrointestinal bleeding due to superior mesenteric artery to duodenum fistula: rare complication of metastatic lung carcinoma.

https://t.me/USMLEWorldStep1

A 58-year-old man with a history of chronic liver disease secondary to hepatitis C infection comes to the office due to progressive fatigue and abdominal discomfort. He has no other medical conditions, and a recent colonoscopy was normal. Physical examination shows ascites and jaundice. Ultrasonography of the abdomen reveals a solid mass within the liver parenchyma. Surgical resection of the liver lesion is performed. Microscopy reveals large cells with prominent nucleoli arranged in thickened plates as shown below.

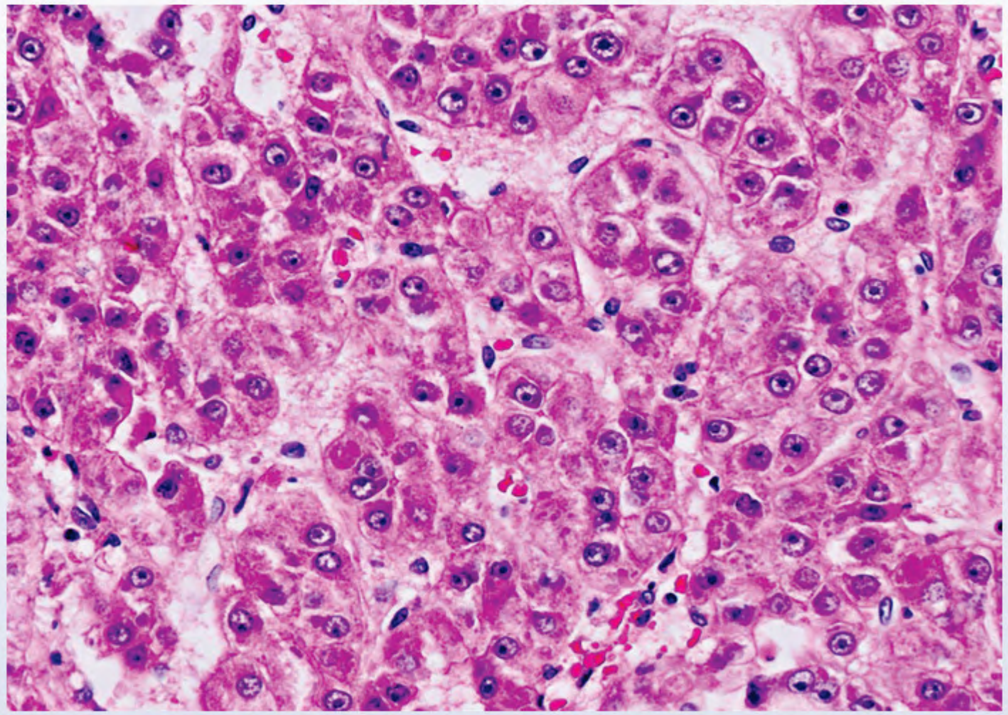

Which of the following serum markers would be most useful for monitoring this patient for disease recurrence?

- A. 5-Hydroxyindoleacetic acid
- B. Alpha-fetoprotein
- C. CA 125

https://t.me/USMLEWorldStep1

A 58-year-old man with a history of chronic liver disease secondary to hepatitis C infection comes to the office due to prog
was n
mass
cells w

Exhibit Display

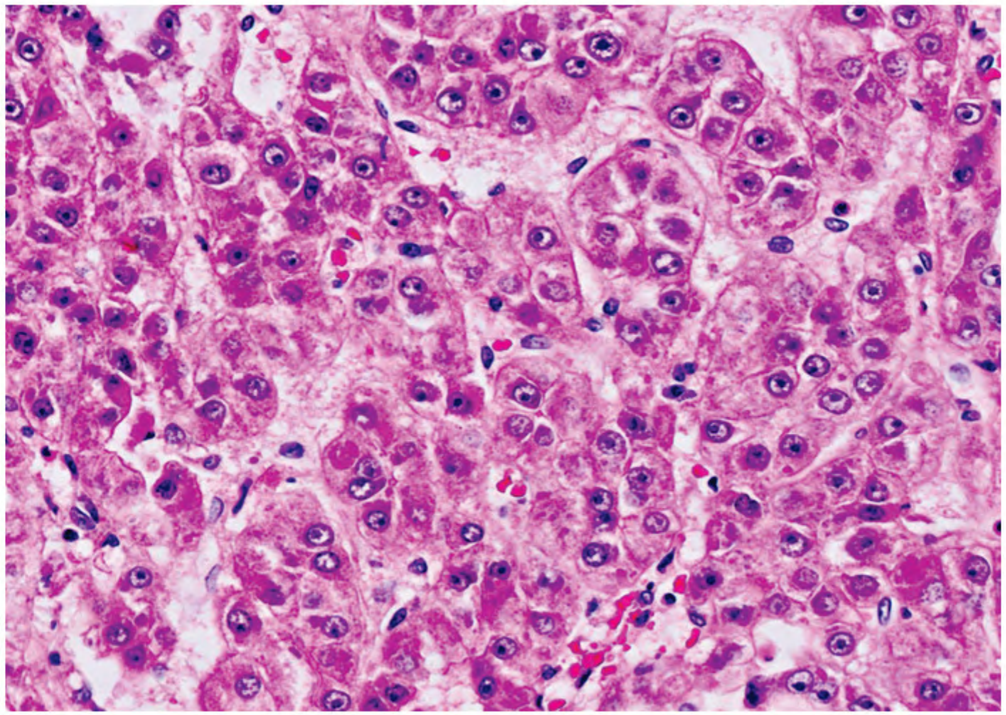

Zoom In | Zoom Out | Reset | New | Existing | My Notebook

Which

C. CA 125

https://t.me/USMLEWorldStep1

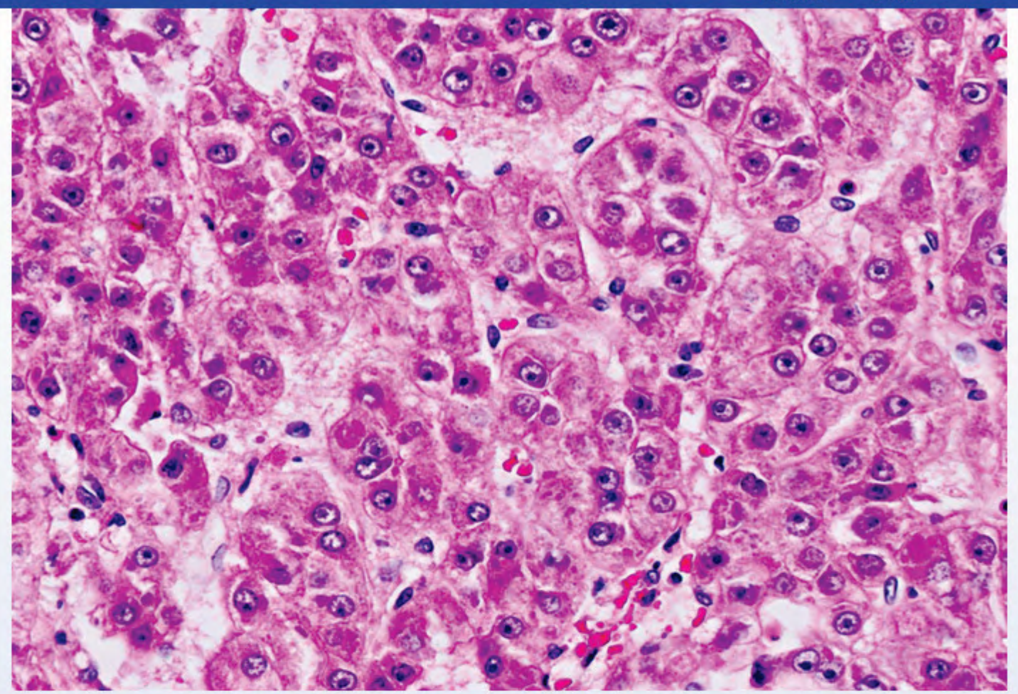

Which of the following serum markers would be most useful for monitoring this patient for disease recurrence?

- A. 5-Hydroxyindoleacetic acid
- B. Alpha-fetoprotein
- C. CA 125
- D. CA 19-9
- E. Carcinoembryonic antigen
- F. Human chorionic gonadotropin

Submit

https://t.me/USMLEWorldStep1

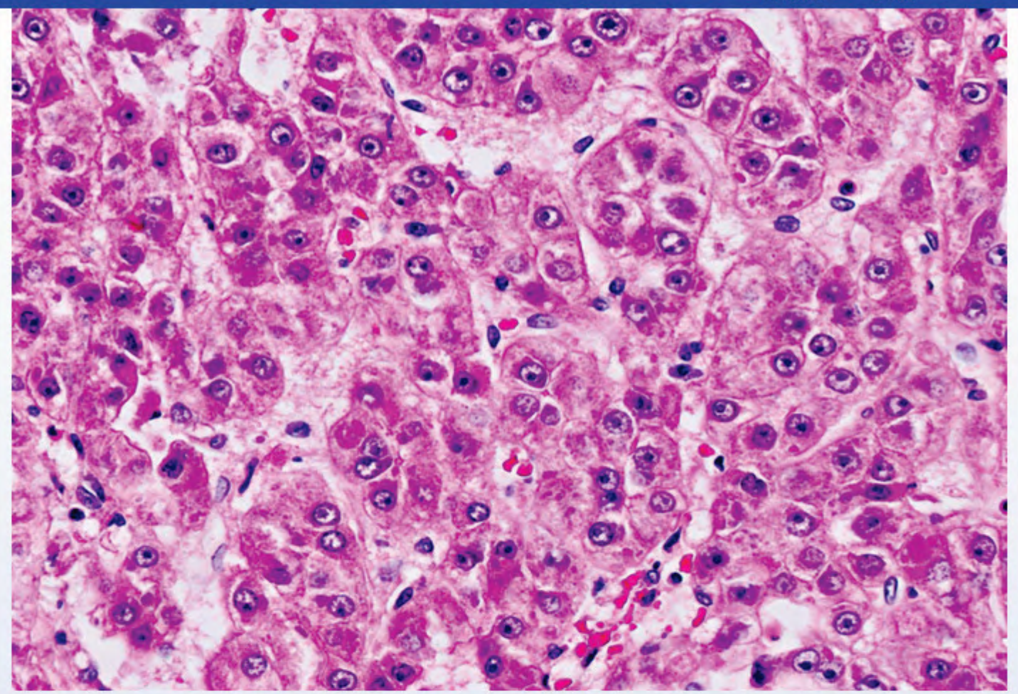

Which of the following serum markers would be most useful for monitoring this patient for disease recurrence?

- A. 5-Hydroxyindoleacetic acid (5%)
- ✓ B. Alpha-fetoprotein (67%)
- C. CA 125 (6%)
- D. CA 19-9 (7%)
- E. Carcinoembryonic antigen (12%)
- F. Human chorionic gonadotropin (0%)

Correct

67% Answered correctly

16 secs Time Spent

2023 Version

https://t.me/USMLEWorldStep1

Explanation

Common serum tumor markers	
Marker	**Tumor associations**
Alpha-fetoprotein	• Hepatocellular carcinoma • Germ cell
CA 19-9	• Pancreatic
CA 125	• Ovarian
Carcinoembryonic antigen	• Gastrointestinal (eg, colorectal)
Human chorionic gonadotropin	• Choriocarcinoma • Germ cell
Prostate-specific antigen	• Prostate

Hepatocellular carcinoma (HCC) occurs in up to 25% of patients with chronic **hepatitis C virus** (HCV). HCV increases hepatocyte turnover and generates local proinflammatory cytokines, which causes hepatocyte damage and fibrosis. Over time, damaged hepatocytes can proliferate into dysplastic nodules and undergo malignant transformation into HCC.

Suspicion for HCC is often raised when patients with chronic HCV develop **worsened underlying cirrhotic symptoms** such as fatigue, ascites, variceal bleeding, abdominal discomfort, or jaundice. Abdominal imaging will show a liver mass; biopsy usually reveals abnormal thickened plates, solid sheets, or gland-like structures of malignant hepatocytes with a variable degree of cytologic atypia (eg, pleomorphism, high nuclear-to-cytoplasmic ratio).

Serum **alpha-fetoprotein** (AFP) level is often used to aid diagnosis and screen for disease recurrence following

https://t.me/USMLEWorldStep1

antigen

Hepatocellular carcinoma (HCC) occurs in up to 25% of patients with chronic **hepatitis C virus** (HCV). HCV increases hepatocyte turnover and generates local proinflammatory cytokines, which causes hepatocyte damage and fibrosis. Over time, damaged hepatocytes can proliferate into dysplastic nodules and undergo malignant transformation into HCC.

Suspicion for HCC is often raised when patients with chronic HCV develop **worsened underlying cirrhotic symptoms** such as fatigue, ascites, variceal bleeding, abdominal discomfort, or jaundice. Abdominal imaging will show a liver mass; biopsy usually reveals abnormal thickened plates, solid sheets, or gland-like structures of malignant hepatocytes with a variable degree of cytologic atypia (eg, pleomorphism, high nuclear-to-cytoplasmic ratio).

Serum **alpha-fetoprotein** (AFP) level is often used to aid diagnosis and screen for disease recurrence following treatment. AFP is a glycoprotein produced by the fetal liver and yolk sac during gestation. Although levels of AFP are often mildly or moderately elevated in patients with chronic liver disease, dramatic elevations or **sudden rises** in AFP should prompt an investigation for HCC. AFP levels do not correlate with the size or stage of the tumor and are not elevated in all cases of HCC.

(Choice A) 5-Hydroxyindoleacetic acid is the major breakdown product of serotonin. Elevated urine levels are seen in carcinoid tumors and certain neuroendocrine tumors.

(Choice C) CA 125 is a serum marker associated with ovarian cancer. It may also be elevated in other malignancies (eg, endometrial) and certain benign conditions (eg, endometriosis).

(Choice D) CA 19-9 is primarily used as a marker for pancreatic cancer or other tumors of the biliary tract.

(Choice E) Carcinoembryonic antigen is a serum marker that is primarily used to monitor response to treatment in patients with colorectal cancer. This patient's clinical features (ie, chronic hepatitis C, negative colonoscopy) are consistent with HCC rather than colorectal cancer.

(Choice F) Human chorionic gonadotropin is elevated in choriocarcinoma and may also be elevated in germ cell tumors (eg, testicular). However, it is most commonly used as a marker for pregnancy.

Educational objective:

https://t.me/USMLEWorldStep1

and fibrosis. Over time, damaged hepatocytes can proliferate into dysplastic nodules and undergo malignant transformation into HCC.

Suspicion for HCC is often raised when patients with chronic HCV develop **worsened underlying cirrhotic symptoms** such as fatigue, ascites, variceal bleeding, abdominal discomfort, or jaundice. Abdominal imaging will show a liver mass; biopsy usually reveals abnormal thickened plates, solid sheets, or gland-like structures of malignant hepatocytes with a variable degree of cytologic atypia (eg, pleomorphism, high nuclear-to-cytoplasmic ratio).

Serum **alpha-fetoprotein** (AFP) level is often used to aid diagnosis and screen for disease recurrence following treatment. AFP is a glycoprotein produced by the fetal liver and yolk sac during gestation. Although levels of AFP are often mildly or moderately elevated in patients with chronic liver disease, dramatic elevations or **sudden rises** in AFP should prompt an investigation for HCC. AFP levels do not correlate with the size or stage of the tumor and are not elevated in all cases of HCC.

(Choice A) 5-Hydroxyindoleacetic acid is the major breakdown product of serotonin. Elevated urine levels are seen in carcinoid tumors and certain neuroendocrine tumors.

(Choice C) CA 125 is a serum marker associated with ovarian cancer. It may also be elevated in other malignancies (eg, endometrial) and certain benign conditions (eg, endometriosis).

(Choice D) CA 19-9 is primarily used as a marker for pancreatic cancer or other tumors of the biliary tract.

(Choice E) Carcinoembryonic antigen is a serum marker that is primarily used to monitor response to treatment in patients with colorectal cancer. This patient's clinical features (ie, chronic hepatitis C, negative colonoscopy) are consistent with HCC rather than colorectal cancer.

(Choice F) Human chorionic gonadotropin is elevated in choriocarcinoma and may also be elevated in germ cell tumors (eg, testicular). However, it is most commonly used as a marker for pregnancy.

Educational objective:
Alpha-fetoprotein is a serum tumor marker that is often moderately elevated in patients with chronic viral hepatitis. However, it can be strikingly elevated in those with hepatocellular carcinoma, and a sudden rise can be a sign that a patient with chronic liver disease is harboring hepatocellular carcinoma.

https://t.me/USMLEWorldStep1

Human chorionic gonadotropin	• Germ cell

Exhibit Display

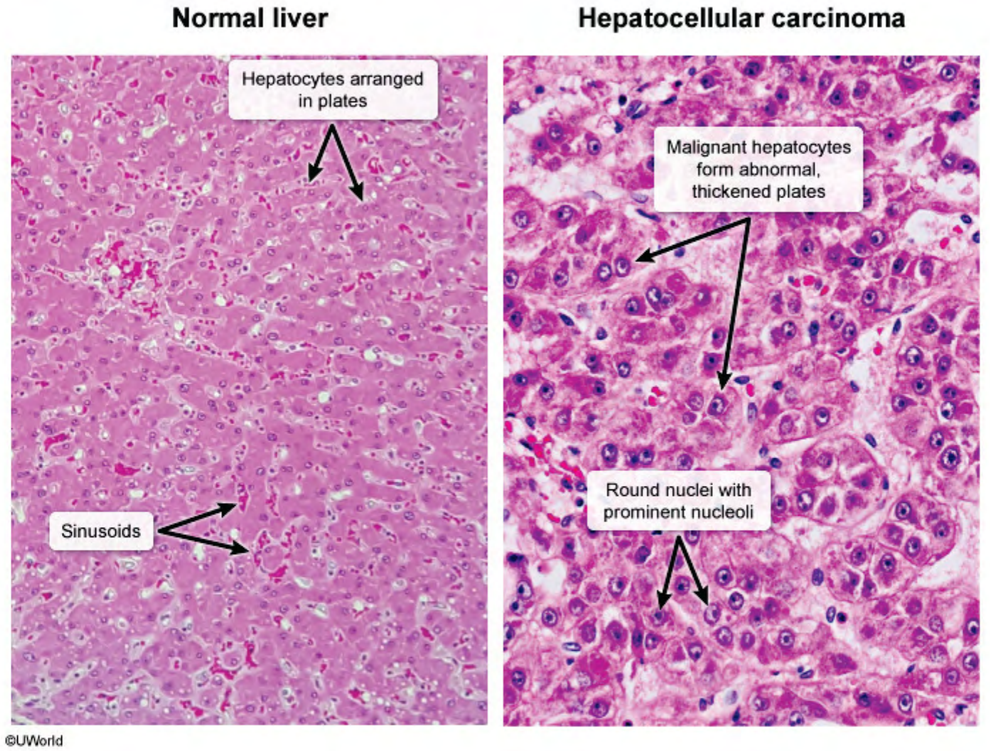

Zoom In | Zoom Out | Reset | New | Existing | My Notebook

consistent with HCC rather than colorectal cancer.

https://t.me/USMLEWorldStep1

A 72-year-old man comes to the office for evaluation of constipation. His stools have been hard and pelletlike for as long as he can remember. The patient has a bowel movement every 3-4 days and frequently strains when using the bathroom. He has had associated abdominal discomfort but no hematochezia, melena, vomiting, or unexpected weight changes. The symptoms have not improved despite fiber supplementation. Vital signs are within normal limits. The abdomen is mildly distended with decreased bowel sounds. In addition to increasing water consumption, the patient is advised to try bisacodyl for constipation. What is the primary mechanism of action of this medication?

- A. Decreases surface tension of stool
- B. Draws water into the stool by creating an osmotic gradient
- C. Draws water into the stool by directly activating chloride channels
- D. Improves peristalsis by blocking mu-receptors
- E. Improves peristalsis by stimulating enteric nerves

Submit

https://t.me/USMLEWorldStep1

A 72-year-old man comes to the office for evaluation of constipation. His stools have been hard and pelletlike for as long as he can remember. The patient has a bowel movement every 3-4 days and frequently strains when using the bathroom. He has had associated abdominal discomfort but no hematochezia, melena, vomiting, or unexpected weight changes. The symptoms have not improved despite fiber supplementation. Vital signs are within normal limits. The abdomen is mildly distended with decreased bowel sounds. In addition to increasing water consumption, the patient is advised to try bisacodyl for constipation. What is the primary mechanism of action of this medication?

- A. Decreases surface tension of stool (12%)
- B. Draws water into the stool by creating an osmotic gradient (40%)
- ✗ C. Draws water into the stool by directly activating chloride channels (9%)
- D. Improves peristalsis by blocking mu-receptors (10%)
- ✓ E. Improves peristalsis by stimulating enteric nerves (27%)

Incorrect
Correct answer
E

27%
Answered correctly

03 secs
Time Spent

2023
Version

Explanation

Commonly used medications for constipation	
Bulk-forming laxatives (eg, fiber supplements)	• Binds luminal water to decrease consistency of stool • Side effects: flatulence, abdominal distension
Osmotic laxatives (eg, polyethylene glycol, magnesium hydroxide, lactulose)	• Osmotically active agent that draws water into the lumen • Side effects: electrolyte disturbances, bloating

https://t.me/USMLEWorldStep1

Commonly used medications for constipation	
Bulk-forming laxatives (eg, fiber supplements)	• Binds luminal water to decrease consistency of stool • Side effects: flatulence, abdominal distension
Osmotic laxatives (eg, polyethylene glycol, magnesium hydroxide, lactulose)	• Osmotically active agent that draws water into the lumen • Side effects: electrolyte disturbances, bloating
Surfactant (eg, docusate)	• Decreases stool surface tension, enabling water to enter stool • Side effects: rare
Stimulant laxatives (eg, bisacodyl, senna)	• Activates enteric nerves in myenteric plexus to stimulate peristalsis • Side effects: abdominal cramping, electrolyte disturbances
Chloride channel agonist (eg, lubiprostone)	• Causes chloride efflux into intestinal lumen, which is followed by sodium and water • Side effects: headache, nausea
Peripherally acting μ-opioid receptor antagonists (eg, methylnaltrexone)	• Counteracts inhibitory effect of opioids on peristalsis • Side effects: rare (does not cause opiate withdrawal)
*All constipation medications can cause diarrhea at high doses.	

Bisacodyl is a **stimulant laxative** that is commonly used to treat constipation and neurogenic bowel; it is also indicated for bowel preparation prior to endoscopic procedures (eg, colonoscopy).

Bisacodyl is hydrolyzed in the colon to its active form, which directly **stimulates the enteric nerves** within the colonic myenteric plexus, thereby **increasing peristalsis** and enhancing colonic motility. It also has some minor secretory effects in the small intestine, where it increases production of cyclic AMP, indirectly increasing secretion

https://t.me/USMLEWorldStep1

antagonists (eg, methylnaltrexone)	• Side effects: rare (does not cause opiate withdrawal)
*All constipation medications can cause diarrhea at high doses.	

Bisacodyl is a **stimulant laxative** that is commonly used to treat constipation and neurogenic bowel; it is also indicated for bowel preparation prior to endoscopic procedures (eg, colonoscopy).

Bisacodyl is hydrolyzed in the colon to its active form, which directly **stimulates the enteric nerves** within the colonic myenteric plexus, thereby **increasing peristalsis** and enhancing colonic motility. It also has some minor secretory effects in the small intestine, where it increases production of cyclic AMP, indirectly increasing secretion of chloride and bicarbonate while inhibiting sodium resorption. Side effects include diarrhea, mild abdominal cramping, and electrolyte disturbances (eg, hypokalemia). Other stimulant laxatives include senna and castor oil.

(Choice A) Docusate reduces the surface tension of stool, enabling water and fat to enter and soften it.

(Choice B) Magnesium hydroxide, polyethylene glycol, and lactulose are osmotically active agents that are poorly absorbed by the intestines. These medications draw water into the intestinal lumen, thereby softening stool and making it easier to pass.

(Choice C) Lubiprostone is an agonist of the ClC-2 chloride channel located on the apical membrane of the intestine, which increases chloride secretion into the intestinal lumen. Sodium and water follow chloride into the lumen, resulting in increased intestinal fluid content.

(Choice D) Methylnaltrexone is a mu-opioid receptor antagonist designed to treat opioid-induced constipation. It does not cross the blood-brain barrier, which allows it to be used without inducing opiate-withdrawal symptoms.

Educational objective:
Bisacodyl is a commonly used stimulant laxative that stimulates the enteric neurons within the colonic myenteric plexus, thereby increasing peristaltic activity and enhancing colonic motility.

References

- Management of constipation in older adults.
- Treatment of chronic constipation: current pharmacologic approaches and future directions.

https://t.me/USMLEWorldStep1

A 44-year-old man with a history of heavy alcohol consumption comes to the emergency department with a nosebleed after getting into a fight while intoxicated. Continuous local pressure is applied and his bleeding resolves within 30 minutes. A detailed physical examination is performed after the bleeding subsides and shows distended paraumbilical veins, ascites, and a flapping hand tremor on wrist extension. Which of the following laboratory findings would be most indicative of a poor prognosis for this patient?

- A. High aspartate aminotransferase
- B. High fibrinogen levels
- C. High gamma glutamyl transferase
- D. Prolonged bleeding time
- E. Prolonged prothrombin time

Submit

https://t.me/USMLEWorldStep1

A 44-year-old man with a history of heavy alcohol consumption comes to the emergency department with a nosebleed after getting into a fight while intoxicated. Continuous local pressure is applied and his bleeding resolves within 30 minutes. A detailed physical examination is performed after the bleeding subsides and shows distended paraumbilical veins, ascites, and a flapping hand tremor on wrist extension. Which of the following laboratory findings would be most indicative of a poor prognosis for this patient?

- A. High aspartate aminotransferase (19%)
- ✗ B. High fibrinogen levels (3%)
- C. High gamma glutamyl transferase (14%)
- D. Prolonged bleeding time (5%)
- ✓ E. Prolonged prothrombin time (56%)

Incorrect
Correct answer
E

56%
Answered correctly

03 secs
Time Spent

2023
Version

Explanation

Laboratory abnormalities in cirrhosis	
Indicators of liver function	**Impaired biosynthetic capacity** • Elevated PT • Hypoalbuminemia **Impaired transport and metabolic capacity** • Elevated bilirubin
	Markers of hepatocyte injury

https://t.me/USMLEWorldStep1

Explanation

Laboratory abnormalities in cirrhosis	
Indicators of liver function	**Impaired biosynthetic capacity** • Elevated PT • Hypoalbuminemia **Impaired transport and metabolic capacity** • Elevated bilirubin
Indicators of liver injury	**Markers of hepatocyte injury** • Elevated aspartate aminotransferase (SGOT) & alanine aminotransferase (SGPT); SGOT usually >SGPT **Markers of cholestasis** • Elevated alkaline phosphatase • Elevated γ-glutamyl transpeptidase
Other	• Thrombocytopenia (due to splenic sequestration of platelets)

This patient has clinical findings consistent with alcohol-induced cirrhosis, namely signs of portal hypertension (ascites/caput medusa) and hepatic encephalopathy (asterixis). Alcohol-associated hepatic injury evolves through the stages of steatosis (reversible), hepatitis (reversible), and cirrhosis (irreversible).

Laboratory findings in cirrhosis reflect both hepatocellular/biliary injury and loss of hepatic function. Hepatocyte injury causes a release of intracellular enzymes and an increase in serum transaminases; biliary injury is reflected by increases in alkaline phosphatase and gamma-glutamyl transpeptidase (GGT). Although these laboratory studies are indicative of ongoing hepatobiliary injury, they do not provide information on the liver's functional reserve, a key determinant of prognosis in patients with cirrhosis. Serum albumin levels and prothrombin time (PT) are better indicators of the liver's biosynthetic function, and its ability to transport and metabolize organic anions is

https://t.me/USMLEWorldStep1

	• Elevated γ-glutamyl transpeptidase
Other	• Thrombocytopenia (due to splenic sequestration of platelets)

This patient has clinical findings consistent with alcohol-induced cirrhosis, namely signs of portal hypertension (ascites/caput medusa) and hepatic encephalopathy (asterixis). Alcohol-associated hepatic injury evolves through the stages of steatosis (reversible), hepatitis (reversible), and cirrhosis (irreversible).

Laboratory findings in cirrhosis reflect both hepatocellular/biliary injury and loss of hepatic function. Hepatocyte injury causes a release of intracellular enzymes and an increase in serum transaminases; biliary injury is reflected by increases in alkaline phosphatase and gamma-glutamyl transpeptidase (GGT). Although these laboratory studies are indicative of ongoing hepatobiliary injury, they do not provide information on the liver's functional reserve, a key determinant of prognosis in patients with cirrhosis. Serum albumin levels and prothrombin time (PT) are better indicators of the liver's biosynthetic function, and its ability to transport and metabolize organic anions is reflected by the serum bilirubin level. Hypoalbuminemia, elevated bilirubin levels, and prolonged PT are signs of inadequate liver function (eg, liver failure) and indicate a poor prognosis in cirrhotic patients. For this reason, they are included in multiple scoring systems used to assess the severity of liver failure and need for transplantation.

(Choice A) A high aspartate aminotransferase (AST) indicates hepatocellular injury and release of intracellular enzymes into the blood. AST is classically elevated to more than 2 times the level of alanine aminotransferase in alcohol-associated liver disease. Transaminase elevations do not reflect liver function and do not predict outcomes; these enzymes can be transiently elevated by a number of self-limited processes.

(Choice B) Fibrinogen is a coagulation factor and an acute phase protein. Liver fibrinogen synthesis is increased in response to infection or acute inflammation and diminished in liver failure. Therefore, low fibrinogen levels would be expected in liver failure.

(Choice C) When the alkaline phosphatase is elevated, serum GGT measurements can differentiate whether the cause is biliary disease or an alternate cause such as bone disease. GGT elevations are more specific for biliary injury.

(Choice D) The bleeding time is a measure of platelet function (not liver synthetic function) and is often prolonged in severe alcohol-related liver disease, although with a fair degree of variance. Thrombocytopenia develops with

https://t.me/USMLEWorldStep1

reserve, a key determinant of prognosis in patients with cirrhosis. Serum albumin levels and prothrombin time (PT) are better indicators of the liver's biosynthetic function, and its ability to transport and metabolize organic anions is reflected by the serum bilirubin level. Hypoalbuminemia, elevated bilirubin levels, and prolonged PT are signs of inadequate liver function (eg, liver failure) and indicate a poor prognosis in cirrhotic patients. For this reason, they are included in multiple scoring systems used to assess the severity of liver failure and need for transplantation.

(Choice A) A high aspartate aminotransferase (AST) indicates hepatocellular injury and release of intracellular enzymes into the blood. AST is classically elevated to more than 2 times the level of alanine aminotransferase in alcohol-associated liver disease. Transaminase elevations do not reflect liver function and do not predict outcomes; these enzymes can be transiently elevated by a number of self-limited processes.

(Choice B) Fibrinogen is a coagulation factor and an acute phase protein. Liver fibrinogen synthesis is increased in response to infection or acute inflammation and diminished in liver failure. Therefore, low fibrinogen levels would be expected in liver failure.

(Choice C) When the alkaline phosphatase is elevated, serum GGT measurements can differentiate whether the cause is biliary disease or an alternate cause such as bone disease. GGT elevations are more specific for biliary injury.

(Choice D) The bleeding time is a measure of platelet function (not liver synthetic function) and is often prolonged in severe alcohol-related liver disease, although with a fair degree of variance. Thrombocytopenia develops with chronic alcohol use due to both direct toxic effects of alcohol on the bone marrow as well as splenic sequestration of platelets.

Educational objective:
Increased aspartate aminotransferase and alanine aminotransferase are indicators of hepatocellular damage, and increased alkaline phosphatase and gamma-glutamyl transpeptidase indicate biliary injury. Serum albumin levels, bilirubin levels, and prothrombin time are reflective of liver function and are of greatest prognostic significance in patients with cirrhosis.

Pathology	Gastrointestinal & Nutrition	Cirrhosis
Subject	System	Topic

https://t.me/USMLEWorldStep1

Indicators of liver injury

Exhibit Display

Clinical features of cirrhosis	
Symptoms	• Nonspecific symptoms (eg, anorexia, fatigue, muscle cramps) • Jaundice & pruritus • Upper gastrointestinal bleeding • Encephalopathy (eg, confusion, sleep disturbances) • Women: Amenorrhea, irregular menses, anovulation • Men: Hypogonadism (eg, decreased libido, erectile dysfunction, loss of axillary & pubic hair)
Physical examination	• Skin: Telangiectasias, caput medusae • Breast: Gynecomastia (usually bilateral but can be unilateral) • Abdomen: Ascites, firm or nodular liver, splenomegaly • Genitourinary: Testicular atrophy • Extremities: Palmar erythema, Muehrcke &/or Terry nails, Dupuytren contracture, clubbing

New | Existing | My Notebook

This p
(ascite
the sta

Labora
injury
by incr
studies
reserv
are be
reflect
inadeq
are inc

(Choi
enzym
alcoho
outcor

(Choi
in resp
be exp

(Choi cause is biliary disease or an alternate cause such as bone disease. GGT elevations are more specific for biliary

https://t.me/USMLEWorldStep1

A 62-year-old man comes to the emergency department due to acute-onset constipation. His last bowel movement was 4 days ago; before that time, his stools were always regular. Review of systems is positive for dry cough, increasing low back pain, a 9-kg (20-lb) weight loss in the past month, and increasing difficulty with urination. He has smoked 2 packs of cigarettes daily for 30 years. Vital signs are within normal limits. Point tenderness is elicited with palpation over the lower spine. Bilateral lower extremity weakness is present, and sensation is impaired in the perineal region. Chest x-ray reveals a right lung mass. Dysfunction of which of the following nerves best explains this patient's constipation?

- A. Greater splanchnic nerve
- B. Ilioinguinal nerve
- C. Lesser splanchnic nerve
- D. Pelvic splanchnic nerves
- E. Vagus nerve

Submit

https://t.me/USMLEWorldStep1

A 62-year-old man comes to the emergency department due to acute-onset constipation. His last bowel movement was 4 days ago; before that time, his stools were always regular. Review of systems is positive for dry cough, increasing low back pain, a 9-kg (20-lb) weight loss in the past month, and increasing difficulty with urination. He has smoked 2 packs of cigarettes daily for 30 years. Vital signs are within normal limits. Point tenderness is elicited with palpation over the lower spine. Bilateral lower extremity weakness is present, and sensation is impaired in the perineal region. Chest x-ray reveals a right lung mass. Dysfunction of which of the following nerves best explains this patient's constipation?

- A. Greater splanchnic nerve (4%)
- ✗ B. Ilioinguinal nerve (9%)
- C. Lesser splanchnic nerve (6%)
- ✓ D. Pelvic splanchnic nerves (63%)
- E. Vagus nerve (15%)

Incorrect
Correct answer
D

63%
Answered correctly

03 secs
Time Spent

2023
Version

Explanation

This patient with a lung mass has progressive low back pain, bilateral lower extremity weakness, bowel/bladder dysfunction, and impaired perineal sensation; this presentation is highly concerning for **cauda equina syndrome**. The cauda equina is formed from lumbosacral nerve roots which can be compressed by **epidural metastasis** (most commonly from lung cancer), trauma, or disc herniation. The symptoms of cauda equina syndrome result from disruption of nerve roots to the sciatic nerve (eg, lower extremity weakness, radicular low back pain), pudendal nerve (eg, saddle anesthesia), and/or pelvic splanchnic nerves.

The **pelvic splanchnic nerves** (S2-S4) provide **parasympathetic** innervation to the hindgut, bladder, and urinary

https://t.me/USMLEWorldStep1

This patient with a lung mass has progressive low back pain, bilateral lower extremity weakness, bowel/bladder dysfunction, and impaired perineal sensation; this presentation is highly concerning for **cauda equina syndrome**. The cauda equina is formed from lumbosacral nerve roots which can be compressed by **epidural metastasis** (most commonly from lung cancer), trauma, or disc herniation. The symptoms of cauda equina syndrome result from disruption of nerve roots to the sciatic nerve (eg, lower extremity weakness, radicular low back pain), pudendal nerve (eg, saddle anesthesia), and/or pelvic splanchnic nerves.

The **pelvic splanchnic nerves** (S2-S4) provide **parasympathetic** innervation to the hindgut, bladder, and urinary sphincters that promotes peristalsis, bladder emptying, and pelvic floor relaxation during defecation. **Constipation** and **difficulty urinating** are prominent symptoms in cauda equina syndrome due to loss of parasympathetic input to the bowel and bladder.

(Choices A and C) The greater splanchnic nerve (T5-T10) and lesser splanchnic nerve (T9-T12) provide sympathetic innervation to the foregut and midgut, respectively. In contrast to the parasympathetic nervous system, the sympathetic nervous system inhibits the gastrointestinal tract by slowing peristalsis. Disruption of these nerves can lead to increased gut motility, not constipation.

(Choice B) The ilioinguinal nerve (L1) provides sensation to the superior medial thigh and part of the genitals, as well as motor innervation to the transverse abdominus and oblique abdominal musculature. Although it can be affected in cauda equina syndrome, it does not provide sympathetic or parasympathetic innervation to the gastrointestinal system.

(Choice E) The vagus nerve (CN X) originates in the medulla and provides parasympathetic innervation to the proximal gastrointestinal tract, ending at the level of the splenic flexure. Impairment of the vagus nerve is more likely to cause delayed gastric emptying and would not be caused by a lumbosacral spinal cord lesion.

Educational objective:
The pelvic splanchnic nerves (S2-S4) provide parasympathetic innervation to the bowel and bladder, and their impairment in cauda equina syndrome can cause constipation and difficulty urinating. Other signs of cauda equina syndrome include radicular low back pain and leg weakness (sciatic nerve) as well as saddle anesthesia (pudendal, ilioinguinal nerves).

https://t.me/USMLEWorldStep1

Correct answer
D

Answered correctly

Time Spent

Version

Exhibit Display

Expl

This p
dysfun
The ca
(most
from d
puden

The **p**
sphinc
and **di**
to the

(Choi
sympa
systen
these

(Choi
well as
affecte
gastro

(Choi
proxim
likely t

Educational objective:
The pelvic splanchnic nerves (S2-S4) provide parasympathetic innervation to the bowel and bladder, and their

Relation of spinal nerve roots to vertebrae

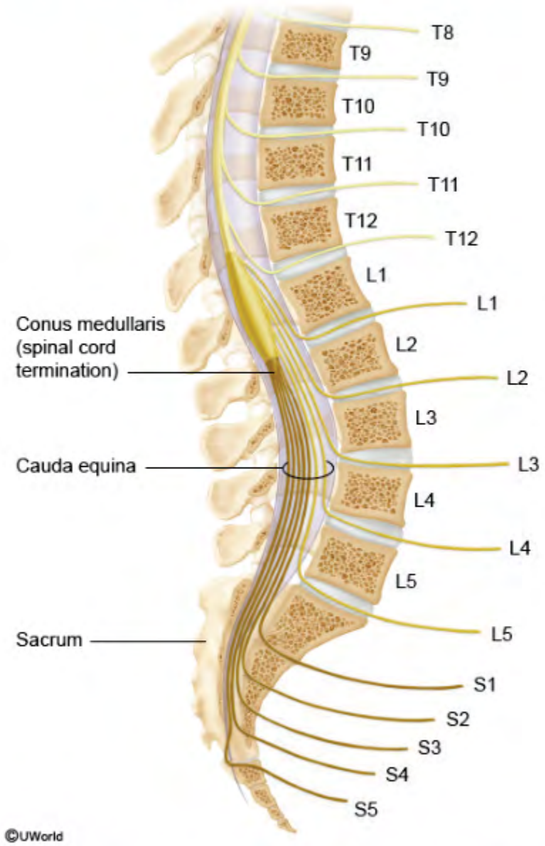

Zoom In | Zoom Out | Reset | New | Existing | My Notebook

https://t.me/USMLEWorldStep1

A 38-year-old woman comes to the office due to jaundice, nausea, and abdominal discomfort. Vital signs are within normal limits. Scleral icterus and hepatomegaly are present. Laboratory results are as follows:

Liver function studies	
Total bilirubin	4.7 mg/dL
Alkaline phosphatase	110 U/L
Aspartate aminotransferase (SGOT)	791 U/L
Alanine aminotransferase (SGPT)	634 U/L

Anti–smooth muscle antibody titers are elevated. Which of the following histologic findings is most likely to be seen on biopsy of this patient's liver?

- A. Ground-glass hepatocytes with central ballooning degeneration
- B. Hepatic steatosis and ballooning degeneration
- C. Hepatocyte necrosis with portal infiltration of neutrophils
- D. Periductal fibrosis and luminal obliteration of biliary ducts
- E. Portal and periportal lymphoplasmacytic cell infiltration

Submit

https://t.me/USMLEWorldStep1

A 38-year-old woman comes to the office due to jaundice, nausea, and abdominal discomfort. Vital signs are within normal limits. Scleral icterus and hepatomegaly are present. Laboratory results are as follows:

Liver function studies	
Total bilirubin	4.7 mg/dL
Alkaline phosphatase	110 U/L
Aspartate aminotransferase (SGOT)	791 U/L
Alanine aminotransferase (SGPT)	634 U/L

Anti–smooth muscle antibody titers are elevated. Which of the following histologic findings is most likely to be seen on biopsy of this patient's liver?

- A. Ground-glass hepatocytes with central ballooning degeneration (5%)
- ✗ B. Hepatic steatosis and ballooning degeneration (6%)
- C. Hepatocyte necrosis with portal infiltration of neutrophils (9%)
- D. Periductal fibrosis and luminal obliteration of biliary ducts (35%)
- ✓ E. Portal and periportal lymphoplasmacytic cell infiltration (41%)

Incorrect
Correct answer
E

41%
Answered correctly

03 secs
Time Spent

2023
Version

Explanation

This patient with jaundice, hepatomegaly, elevated transaminases, and high anti–smooth muscle antibody titers most likely has **autoimmune hepatitis** (AIH). AIH occurs most commonly in women with other autoimmune conditions (eg, type 1 diabetes mellitus). It is often asymptomatic but may present with fatigue, weight loss,

https://t.me/USMLEWorldStep1

Explanation

This patient with jaundice, hepatomegaly, elevated transaminases, and high anti–smooth muscle antibody titers most likely has **autoimmune hepatitis** (AIH). AIH occurs most commonly in women with other autoimmune conditions (eg, type 1 diabetes mellitus). It is often asymptomatic but may present with fatigue, weight loss, nausea, and/or signs of acute hepatitis (eg, jaundice, abdominal discomfort). Characteristic laboratory abnormalities include a **hepatocellular pattern** of liver injury (ie, predominant transaminase elevation with normal alkaline phosphatase and variable bilirubin) and the formation of a variety of autoantibodies, particularly **anti–smooth muscle**, which is highly specific for AIH. Hypergammaglobulinemia is also typical.

The pathogenesis of AIH is incompletely understood but likely involves exposure to an environmental trigger in genetically predisposed patients, leading to regulatory T-cell dysfunction. It ultimately results in loss of self-tolerance, with an **immune response against hepatic antigens**. This is demonstrated histologically by **lymphocyte and plasma cell** infiltration of **portal and periportal** regions of the liver.

(Choice A) Chronic hepatitis B is characterized histologically by ground-glass hepatocytes, which result from the accumulation of hepatitis B surface antigen within their cytoplasm, as well as central balloon degeneration, which reflects hepatocytes undergoing apoptosis.

(Choice B) Hepatic steatosis (ie, lipid accumulation in the cytoplasm of hepatocytes) and ballooning degeneration most commonly occur in alcohol-induced hepatitis and nonalcoholic fatty liver disease. Elevated anti–smooth muscle antibody titers do not occur.

(Choice C) Acetaminophen overdose can lead to hepatic inflammation and necrosis with neutrophilic infiltration (unlike AIH, which is characterized by lymphoplasmocytic infiltrates). Patients often have vomiting, diaphoresis, and confusion.

(Choice D) Primary sclerosing cholangitis causes periductal fibrosis and luminal obliteration of the biliary ducts, which can lead to cholestasis. High alkaline phosphatase levels and near-normal aminotransferases are expected.

Educational objective:
Autoimmune hepatitis results from an immune response against hepatic antigens, leading to a lymphoplasmacytic infiltrate in the portal and periportal regions of the liver. Manifestations include fatigue, weight loss, nausea, and/or

https://t.me/USMLEWorldStep1

most likely has **autoimmune hepatitis** (AIH). AIH occurs most commonly in women with other autoimmune conditions (eg, type 1 diabetes mellitus). It is often asymptomatic but may present with fatigue, weight loss, nausea, and/or signs of acute hepatitis (eg, jaundice, abdominal discomfort). Characteristic laboratory abnormalities include a **hepatocellular pattern** of liver injury (ie, predominant transaminase elevation with normal alkaline phosphatase and variable bilirubin) and the formation of a variety of autoantibodies, particularly **anti–smooth muscle**, which is highly specific for AIH. Hypergammaglobulinemia is also typical.

The pathogenesis of AIH is incompletely understood but likely involves exposure to an environmental trigger in genetically predisposed patients, leading to regulatory T-cell dysfunction. It ultimately results in loss of self-tolerance, with an **immune response against hepatic antigens**. This is demonstrated histologically by **lymphocyte and plasma cell** infiltration of **portal and periportal** regions of the liver.

(Choice A) Chronic hepatitis B is characterized histologically by ground-glass hepatocytes, which result from the accumulation of hepatitis B surface antigen within their cytoplasm, as well as central balloon degeneration, which reflects hepatocytes undergoing apoptosis.

(Choice B) Hepatic steatosis (ie, lipid accumulation in the cytoplasm of hepatocytes) and ballooning degeneration most commonly occur in alcohol-induced hepatitis and nonalcoholic fatty liver disease. Elevated anti–smooth muscle antibody titers do not occur.

(Choice C) Acetaminophen overdose can lead to hepatic inflammation and necrosis with neutrophilic infiltration (unlike AIH, which is characterized by lymphoplasmocytic infiltrates). Patients often have vomiting, diaphoresis, and confusion.

(Choice D) Primary sclerosing cholangitis causes periductal fibrosis and luminal obliteration of the biliary ducts, which can lead to cholestasis. High alkaline phosphatase levels and near-normal aminotransferases are expected.

Educational objective:
Autoimmune hepatitis results from an immune response against hepatic antigens, leading to a lymphoplasmacytic infiltrate in the portal and periportal regions of the liver. Manifestations include fatigue, weight loss, nausea, and/or signs of acute hepatitis (eg, jaundice, abdominal discomfort). Characteristic laboratory abnormalities include a hepatocellular pattern of liver injury, anti–smooth muscle autoantibodies, and hypergammaglobulinemia.

https://t.me/USMLEWorldStep1

A 65-year-old woman has had several months of progressive fatigue, diminished appetite, and unintentional weight loss. The patient has no chronic medical conditions. She has not received medical care in many years and has not had recommended cancer screening. The patient suddenly dies while undergoing evaluation. Autopsy reveals abnormal liver findings, as shown in the exhibit below.

Microscopic evaluation of the lesions reveals neoplastic cells. Which of the following is the most likely cause of this patient's liver lesions?

- A. Lymphatic spread of a malignancy
- B. Malignancy metastasizing via the hepatic veins
- C. Malignancy spreading through the portal circulation
- D. Primary neoplastic transformation of hepatocytes
- E. Transcoelomic spread of a malignancy

Submit

https://t.me/USMLEWorldStep1

A 65-year-old woman has had several months of progressive fatigue, diminished appetite, and unintentional weight loss. T
not ha
abnorr

Exhibit Display

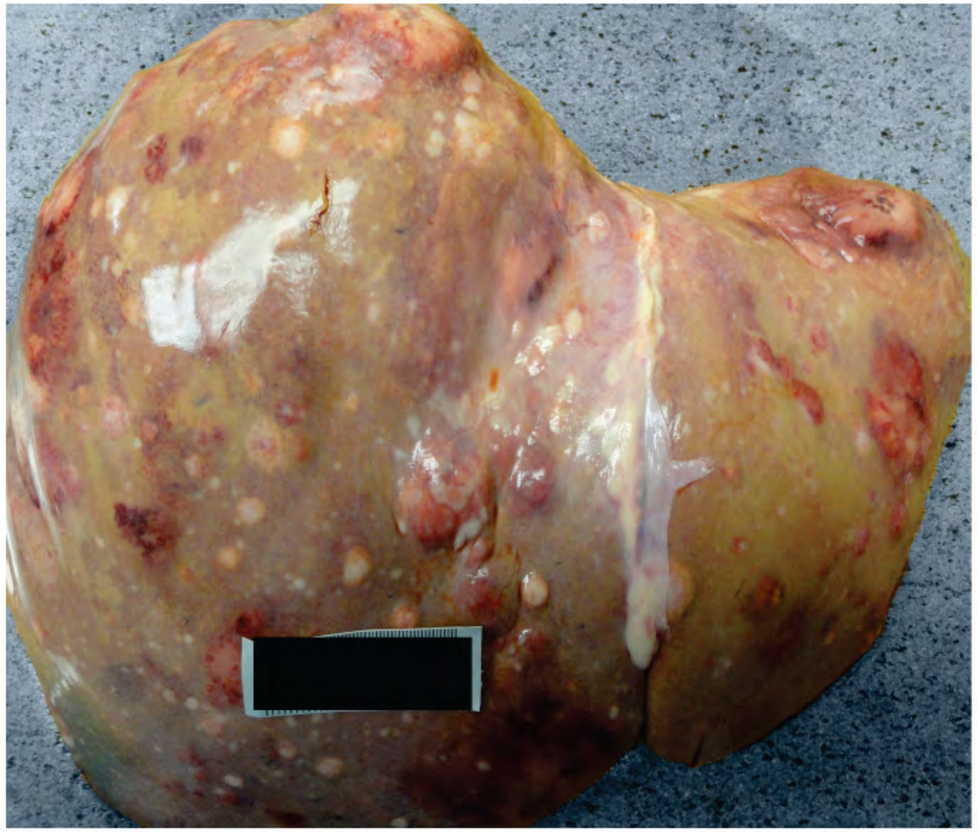

Zoom In | Zoom Out | Reset | New | Existing | My Notebook

Micros
this pa

A. Lymphatic spread of a malignancy

https://t.me/USMLEWorldStep1

Microscopic evaluation of the lesions reveals neoplastic cells. Which of the following is the most likely cause of this patient's liver lesions?

- A. Lymphatic spread of a malignancy (11%)
- ✕ B. Malignancy metastasizing via the hepatic veins (12%)
- ✓ C. Malignancy spreading through the portal circulation (67%)
- D. Primary neoplastic transformation of hepatocytes (4%)
- E. Transcoelomic spread of a malignancy (4%)

Incorrect
Correct answer
C

67%
Answered correctly

37 secs
Time Spent

2023
Version

https://t.me/USMLEWorldStep1

Incorrect
Correct answer
C

67%
Answered correctly

37 secs
Time Spent

2023
Version

Expl

Exhibit Display

Metastatic colorectal carcinoma to liver

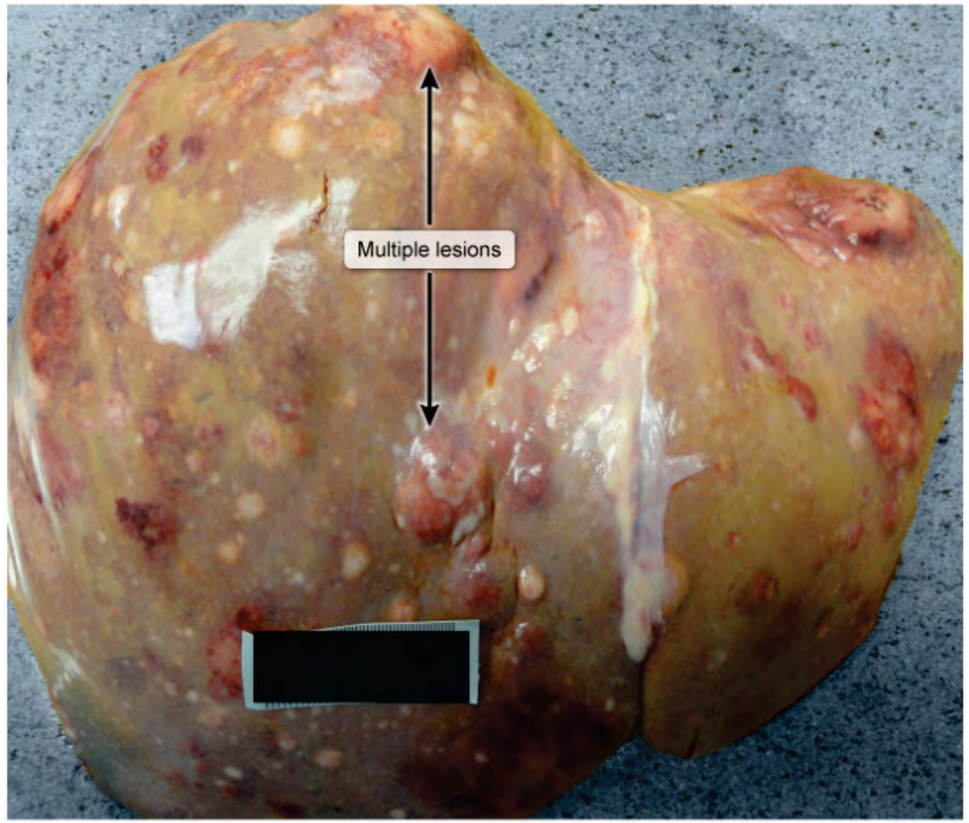

©UWorld

Zoom In | Zoom Out | Reset | New | Existing | My Notebook

Liver neoplasms are most often due to **metastases** from distant tumors rather than primary liver cancer (eg,

https://t.me/USMLEWorldStep1

©UWorld

Liver neoplasms are most often due to **metastases** from distant tumors rather than primary liver cancer (eg, hepatocellular carcinoma). Metastatic disease to the liver is particularly likely when **multiple tumors** are present (as seen in this case) and there is no history of underlying hepatic disease such as alcohol-induced cirrhosis or hepatitis C. The liver is vulnerable to the metastatic spread of cancer due to the following anatomic considerations:

- The presence of **fenestrated hepatic sinusoidal epithelium**, which allows tumor cells to easily pass from the bloodstream through to the parenchyma.
- **Dual blood supply** from the portal and systemic circulation, which increases the likelihood of circulating tumor cells depositing in the liver.

The most common cause of liver metastases is **colorectal cancer**, which spreads directly from the colon or superior rectum through the **portal venous system** to the liver. This patient, who has not received recommended cancer screening (eg, colonoscopy), likely developed hepatic metastases from colorectal cancer. Gastric and pancreatic cancers also frequently spread through the portal system to the liver.

(Choice A) Lymphatic spread of tumor cells is a common mechanism of metastases, but it is not the primary source of most metastatic liver lesions.

(Choice B) Tumors (eg, breast, lung, melanoma) can spread to the liver through the systemic circulation via the hepatic artery (rather than the portal circulation). The hepatic vein drains out of the liver; it does not bring blood into the liver.

(Choice D) Primary hepatic cancer is thirtyfold less common than metastatic disease. Most primary lesions are solitary tumors and arise in individuals with underlying liver disease. This patient, who did not have recommended cancer screening (eg, colonoscopy) and has multiple liver tumors, most likely has metastatic disease.

(Choice E) Although gastrointestinal cancers can spread to the peritoneum and then invade the liver, this is much less common than hematogenous dissemination through the portal system. Metastasis through the peritoneal space most commonly occurs with ovarian cancer and gastric (Krukenberg) tumors.

Educational objective:
Most hepatic neoplasms are due to metastatic disease from a distant site. Colorectal cancer is the most common

https://t.me/USMLEWorldStep1

(as seen in this case) and there is no history of underlying hepatic disease such as alcohol-induced cirrhosis or hepatitis C. The liver is vulnerable to the metastatic spread of cancer due to the following anatomic considerations:

- The presence of **fenestrated hepatic sinusoidal epithelium**, which allows tumor cells to easily pass from the bloodstream through to the parenchyma.
- **Dual blood supply** from the portal and systemic circulation, which increases the likelihood of circulating tumor cells depositing in the liver.

The most common cause of liver metastases is **colorectal cancer**, which spreads directly from the colon or superior rectum through the **portal venous system** to the liver. This patient, who has not received recommended cancer screening (eg, colonoscopy), likely developed hepatic metastases from colorectal cancer. Gastric and pancreatic cancers also frequently spread through the portal system to the liver.

(Choice A) Lymphatic spread of tumor cells is a common mechanism of metastases, but it is not the primary source of most metastatic liver lesions.

(Choice B) Tumors (eg, breast, lung, melanoma) can spread to the liver through the systemic circulation via the hepatic artery (rather than the portal circulation). The hepatic vein drains out of the liver; it does not bring blood into the liver.

(Choice D) Primary hepatic cancer is thirtyfold less common than metastatic disease. Most primary lesions are solitary tumors and arise in individuals with underlying liver disease. This patient, who did not have recommended cancer screening (eg, colonoscopy) and has multiple liver tumors, most likely has metastatic disease.

(Choice E) Although gastrointestinal cancers can spread to the peritoneum and then invade the liver, this is much less common than hematogenous dissemination through the portal system. Metastasis through the peritoneal space most commonly occurs with ovarian cancer and gastric (Krukenberg) tumors.

Educational objective:
Most hepatic neoplasms are due to metastatic disease from a distant site. Colorectal cancer is the most common cause of hepatic metastases due to direct blood flow from the colon (and superior rectum) to the liver via the portal venous circulation.

https://t.me/USMLEWorldStep1

A 37-year-old man comes to the emergency department due to worsening fatigue and a prolonged history of abdominal pain. He has had no surgeries and takes no medications. Examination shows mucosal pallor and epigastric tenderness on deep palpation. Blood samples are obtained for testing. Laboratory results are as follows:

Hemoglobin	8.2 g/dL
Mean corpuscular volume	110 μm^3
Folate	10 ng/mL (normal: 2.5-20)
Vitamin B_{12}	90 pg/mL (normal: 200-800)
Gastrin	168 pg/mL (normal: 0-180)
Intrinsic factor–blocking antibody	negative

CT scan of the abdomen reveals atrophy of the pancreas with multiple calcifications. A primary impairment in which of the following steps of cobalamin absorption is the most likely cause of this patient's anemia?

- A. Acid-mediated release of cobalamin from an animal protein
- B. Cobalamin binding to transcobalamin II
- C. Enzyme-mediated cleavage of cobalamin from R protein
- D. Production of intrinsic factor

Submit

https://t.me/USMLEWorldStep1

A 37-year-old man comes to the emergency department due to worsening fatigue and a prolonged history of abdominal pain. He has had no surgeries and takes no medications. Examination shows mucosal pallor and epigastric tenderness on deep palpation. Blood samples are obtained for testing. Laboratory results are as follows:

Hemoglobin	8.2 g/dL
Mean corpuscular volume	110 μm^3
Folate	10 ng/mL (normal: 2.5-20)
Vitamin B_{12}	90 pg/mL (normal: 200-800)
Gastrin	168 pg/mL (normal: 0-180)
Intrinsic factor–blocking antibody	negative

CT scan of the abdomen reveals atrophy of the pancreas with multiple calcifications. A primary impairment in which of the following steps of cobalamin absorption is the most likely cause of this patient's anemia?

- A. Acid-mediated release of cobalamin from an animal protein (5%)
- ✗ B. Cobalamin binding to transcobalamin II (8%)
- ✓ C. Enzyme-mediated cleavage of cobalamin from R protein (68%)
- D. Production of intrinsic factor (17%)

Incorrect
Correct answer
C

68%
Answered correctly

03 secs
Time Spent

2023
Version

Explanation

Vitamin B_{12} absorption

https://t.me/USMLEWorldStep1

D. Production of intrinsic factor (17%)

Exhibit Display

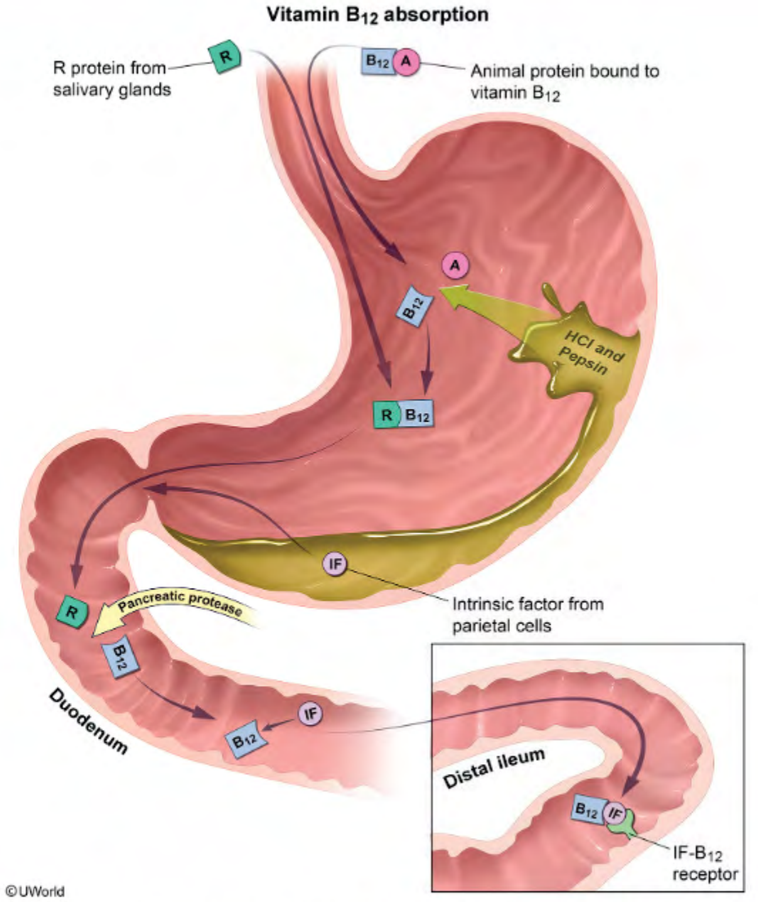

Zoom In | Zoom Out | Reset | New | Existing | My Notebook

parietal cells

https://t.me/USMLEWorldStep1

This patient with a prolonged history of **epigastric abdominal pain** has developed fatigue due to anemia from vitamin B_{12} (ie cobalamin) deficiency. This history, combined with imaging findings of pancreatic atrophy and calcifications, is consistent with **chronic pancreatitis**, a progressive inflammatory disease that ultimately leads to pancreatic fibrosis.

In chronic pancreatitis, acinar cell destruction leads to decreased secretion of pancreatic proteolytic enzymes (eg, **exocrine insufficiency**). This not only affects protein and fat absorption, which can cause weight loss and steatorrhea, but also may lead to **vitamin B_{12} deficiency**. Pancreatic proteolytic enzymes are needed to **release** vitamin B_{12} from the **vitamin B_{12}–R protein complex** (R protein is also known as transcobalamin I or haptocorrin), a necessary step that enables vitamin B_{12} to bind intrinsic factor, which ultimately facilitates terminal ileal absorption. Chronic pancreatitis may also lead to islet cell destruction and cause diabetes mellitus (eg, endocrine insufficiency).

(Choice A) Long-term use of a proton pump inhibitor (PPI) may cause vitamin B_{12} deficiency due to the inhibition of gastric acid secretion, which is needed to release vitamin B_{12} from animal proteins. This patient does not use a PPI; furthermore, hypergastrinemia (ie, elevated serum gastrin) is expected in the setting of decreased gastric acid secretion.

(Choice B) Transcobalamin II is a carrier protein that transports vitamin B_{12} in the circulation after terminal ileal absorption. Transcobalamin II deficiency is a rare genetic condition that presents in infancy with failure to thrive and megaloblastic anemia.

(Choice D) Pernicious anemia is an autoimmune condition that causes parietal cell destruction, decreased intrinsic factor production, and vitamin B_{12} deficiency. Hypergastrinemia is expected because parietal cell destruction leads to decreased gastric acid secretion. This patient is also younger than most individuals with pernicious anemia, which is usually diagnosed later in life (median age 70-80).

Educational objective:
Chronic pancreatitis may cause vitamin B_{12} deficiency due to decreased production of pancreatic proteolytic enzymes (eg, exocrine insufficiency), which are needed to release vitamin B_{12} from R protein. Other manifestations of chronic pancreatitis include chronic epigastric pain, weight loss, and steatorrhea.

https://t.me/USMLEWorldStep1

A 21-year-old man comes to the emergency department due to abdominal pain, nausea, and vomiting. The patient started having vague periumbilical pain in the morning. Over the next several hours, the pain became more severe, sharper, and localized to the right lower abdominal quadrant. Temperature is 38.3 C (100.9 F), blood pressure is 132/84 mm Hg, pulse is 102/min, and respirations are 12/min. Physical examination shows maximal tenderness in the right lower abdomen two-thirds of the distance from the umbilicus to the anterior superior iliac spine. Bowel sounds are decreased. Laboratory studies reveal a leukocyte count of 16,000/mm^3. The change in this patient's pain characteristics is most likely explained by which of the following?

- A. Involvement of the obturator internus muscle
- B. Inflammation of the psoas major muscle
- C. Stimulation of the cecal nerve endings
- D. Irritation of the parietal peritoneum
- E. Retrocecal orientation of the appendix

Submit

https://t.me/USMLEWorldStep1

A 21-year-old man comes to the emergency department due to abdominal pain, nausea, and vomiting. The patient started having vague periumbilical pain in the morning. Over the next several hours, the pain became more severe, sharper, and localized to the right lower abdominal quadrant. Temperature is 38.3 C (100.9 F), blood pressure is 132/84 mm Hg, pulse is 102/min, and respirations are 12/min. Physical examination shows maximal tenderness in the right lower abdomen two-thirds of the distance from the umbilicus to the anterior superior iliac spine. Bowel sounds are decreased. Laboratory studies reveal a leukocyte count of 16,000/mm^3. The change in this patient's pain characteristics is most likely explained by which of the following?

- A. Involvement of the obturator internus muscle (1%)
- ✗ B. Inflammation of the psoas major muscle (8%)
- C. Stimulation of the cecal nerve endings (7%)
- ✓ D. Irritation of the parietal peritoneum (69%)
- E. Retrocecal orientation of the appendix (13%)

Incorrect
Correct answer
D

69%
Answered correctly

03 secs
Time Spent

2023
Version

Explanation

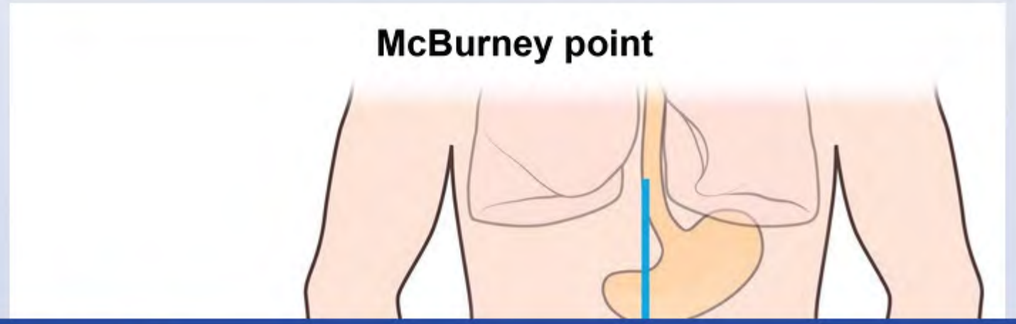

https://t.me/USMLEWorldStep1

Correct answer
D

Answered correctly
Time Spent
Version

Exhibit Display

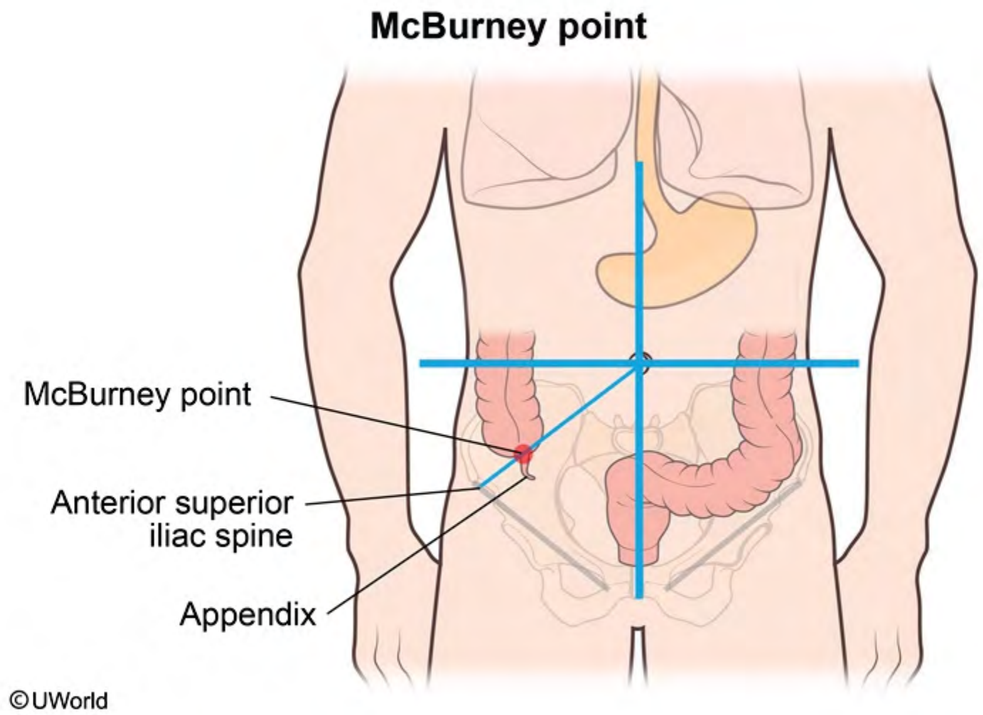

Zoom In | Zoom Out | Reset | New | Existing | My Notebook

This p
and sc
distens
nervou
cramp
activation of the autonomic nervous system. In contrast, somatic pain is usually due to irritation of the parietal peritoneum and is well localized, more severe, and worsened with deep inspiration or pushing on the abdominal

https://t.me/USMLEWorldStep1

©UWorld

This patient's presentation is concerning for **appendicitis**, which can cause both visceral (vague, nonlocalized) and somatic (sharp, well-localized) abdominal pain. **Visceral abdominal pain** is most often due to luminal distension and stretching of smooth muscle and is carried by general visceral afferent fibers of the autonomic nervous system. The pain typically occurs in the **midline** region and is **poorly localized** and of a dull, constant, or cramping quality. Patients with visceral pain also commonly develop nausea, vomiting, or sweating due to activation of the autonomic nervous system. In contrast, somatic pain is usually due to irritation of the parietal peritoneum and is well localized, more severe, and worsened with deep inspiration or pushing on the abdominal wall.

The afferent pain fibers for the appendix, proximal colon (including the cecum), and overlying visceral peritoneum cross through the superior mesenteric plexus and enter the spinal cord at the T10 level to produce vague, referred pain at the umbilicus **(Choice C)**. As the appendix becomes more inflamed, it irritates the **parietal peritoneum** and abdominal wall and causes a **more severe somatic pain** that **shifts** from the umbilical region to the **McBurney point** (two-thirds of the distance from the umbilicus to the anterior superior iliac spine). With peritoneal irritation, the abdominal wall becomes very sensitive to gentle palpation or sudden release of pressure (ie, rebound tenderness).

The appendix is usually located 2 cm beneath the ileocecal valve in the right lower quadrant. Depending on its orientation, there can be additional clinical findings. A pelvic appendix lies against the right obturator internus muscle, causing right lower quadrant pain with internal rotation of the right hip **(Choice A)**. Patients with a retrocecal appendix may not have significant right lower quadrant tenderness because the inflamed appendix does not contact the anterior parietal peritoneum, and the cecum (distended with gas) acts as a cushion that blocks the examiner's hand. However, the inflamed appendix will lie against the right psoas muscle, causing pain with hip extension **(Choices B and E)**.

Educational objective:
Appendicitis causes dull visceral pain at the umbilicus due to afferent pain fibers entering at the T10 level in the spinal cord. Progressive inflammation in the appendix irritates the parietal peritoneum and abdominal wall to cause more severe somatic pain shifting from the umbilicus to McBurney's point (two-thirds of the distance from

https://t.me/USMLEWorldStep1

and somatic (sharp, well-localized) abdominal pain. **Visceral abdominal pain** is most often due to luminal distension and stretching of smooth muscle and is carried by general visceral afferent fibers of the autonomic nervous system. The pain typically occurs in the **midline** region and is **poorly localized** and of a dull, constant, or cramping quality. Patients with visceral pain also commonly develop nausea, vomiting, or sweating due to activation of the autonomic nervous system. In contrast, somatic pain is usually due to irritation of the parietal peritoneum and is well localized, more severe, and worsened with deep inspiration or pushing on the abdominal wall.

The afferent pain fibers for the appendix, proximal colon (including the cecum), and overlying visceral peritoneum cross through the superior mesenteric plexus and enter the spinal cord at the T10 level to produce vague, referred pain at the umbilicus **(Choice C)**. As the appendix becomes more inflamed, it irritates the **parietal peritoneum** and abdominal wall and causes a **more severe somatic pain** that **shifts** from the umbilical region to the **McBurney point** (two-thirds of the distance from the umbilicus to the anterior superior iliac spine). With peritoneal irritation, the abdominal wall becomes very sensitive to gentle palpation or sudden release of pressure (ie, rebound tenderness).

The appendix is usually located 2 cm beneath the ileocecal valve in the right lower quadrant. Depending on its orientation, there can be additional clinical findings. A pelvic appendix lies against the right obturator internus muscle, causing right lower quadrant pain with internal rotation of the right hip **(Choice A)**. Patients with a retrocecal appendix may not have significant right lower quadrant tenderness because the inflamed appendix does not contact the anterior parietal peritoneum, and the cecum (distended with gas) acts as a cushion that blocks the examiner's hand. However, the inflamed appendix will lie against the right psoas muscle, causing pain with hip extension **(Choices B and E)**.

Educational objective:
Appendicitis causes dull visceral pain at the umbilicus due to afferent pain fibers entering at the T10 level in the spinal cord. Progressive inflammation in the appendix irritates the parietal peritoneum and abdominal wall to cause more severe somatic pain shifting from the umbilicus to McBurney's point (two-thirds of the distance from the umbilicus to the anterior superior iliac spine).

Anatomy	Gastrointestinal & Nutrition	Appendicitis
Subject	System	Topic

https://t.me/USMLEWorldStep1

A 42-year-old woman comes to the office due to a 2-month history of an intermittent burning sensation in her chest with an occasional simultaneous acidic taste at the back of her throat. The symptoms occur soon after she eats a meal. The patient has no shortness of breath, lightheadedness, nausea, vomiting, or weight loss. She has no other medical conditions. The patient has smoked a pack of cigarettes daily for the last 10 years but does not use alcohol. Family history is unremarkable. Vital signs are within normal limits. BMI is 32 kg/m^2. Physical examination shows no abnormalities. Urine pregnancy test is negative. Smoking cessation is discussed, and a medication is prescribed for treatment of her symptoms. The patient returns in 2 weeks for a follow-up visit and reports near-complete resolution of her symptoms. Which of the following is the most likely mechanism of action of this drug?

- A. Blockade of gastrin receptors
- B. Creation of a cytoprotective layer in the stomach
- C. Inhibition of H^+/K^+ ATPase activity
- D. Inhibition of synthesis of gastrin
- E. Prostaglandin-mediated inhibition of acid secretion

Submit

https://t.me/USMLEWorldStep1

A 42-year-old woman comes to the office due to a 2-month history of an intermittent burning sensation in her chest with an occasional simultaneous acidic taste at the back of her throat. The symptoms occur soon after she eats a meal. The patient has no shortness of breath, lightheadedness, nausea, vomiting, or weight loss. She has no other medical conditions. The patient has smoked a pack of cigarettes daily for the last 10 years but does not use alcohol. Family history is unremarkable. Vital signs are within normal limits. BMI is 32 kg/m^2. Physical examination shows no abnormalities. Urine pregnancy test is negative. Smoking cessation is discussed, and a medication is prescribed for treatment of her symptoms. The patient returns in 2 weeks for a follow-up visit and reports near-complete resolution of her symptoms. Which of the following is the most likely mechanism of action of this drug?

- A. Blockade of gastrin receptors (0%)
- ✗ B. Creation of a cytoprotective layer in the stomach (0%)
- ✓ C. Inhibition of H^+/K^+ ATPase activity (95%)
- D. Inhibition of synthesis of gastrin (0%)
- E. Prostaglandin-mediated inhibition of acid secretion (1%)

Incorrect
Correct answer
C

95%
Answered correctly

04 secs
Time Spent

2023
Version

Explanation

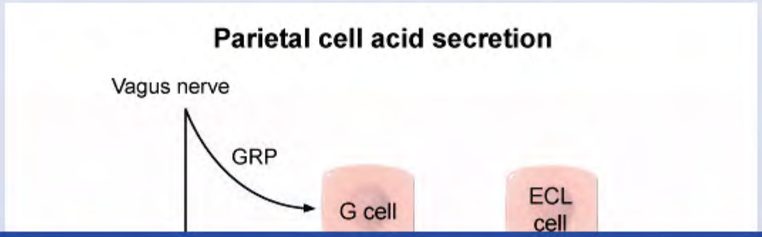

https://t.me/USMLEWorldStep1

C. Inhibition of H+/K+ ATPase activity (95%)

Exhibit Display

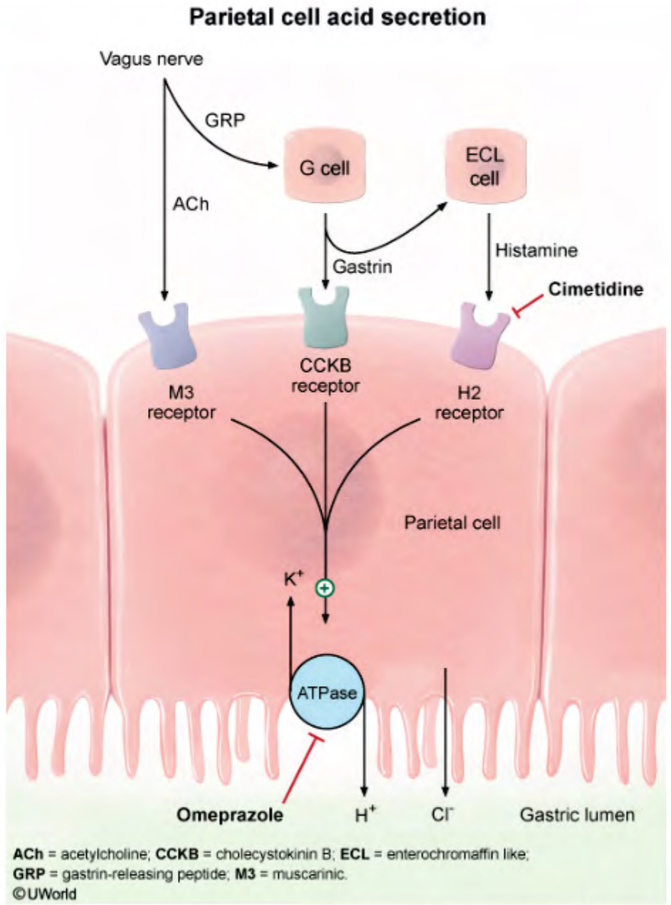

Zoom In | Zoom Out | Reset | New | Existing | My Notebook

https://t.me/USMLEWorldStep1

GRP = gastrin-releasing peptide; **M3** = muscarinic.
©UWorld

This patient's heartburn is likely related to gastroesophageal reflux disease (GERD), a common disorder that occurs when gastric acid refluxes into the esophagus. Management consists of lifestyle and dietary modifications (eg, weight loss, avoidance of tobacco) as well as medications that suppress gastric acid secretion.

Proton pump inhibitors (PPIs) (eg, pantoprazole, omeprazole) are the most effective inhibitors of gastric acid secretion. They bind to and irreversibly **inhibit the H^+/K^+ ATPase** on parietal cells. Side effects are related to elevated gastric pH and include an increased risk of *Clostridioides difficile* and nutritional deficiencies (eg, calcium, magnesium, iron).

Although less potent than PPIs, **histamine 2 receptor antagonists** (eg, famotidine, cimetidine) are also used as first-line therapy for GERD. They inhibit gastric acid secretion by targeting histamine receptors on parietal cells. These medications are less side effect–prone than PPIs; however, they have a slower onset of action, and tachyphylaxis is common.

(Choice A) Gastrin, a hormone released from G cells, binds to cholecystokinin (CCK) B receptors and stimulates gastric acid secretion both directly (through binding on parietal cells) and indirectly (through binding on enterochromaffin-like cells to increase histamine release). CCK receptor antagonists are not routinely used in clinical practice.

(Choice B) Sucralfate forms a viscous paste in the stomach, providing a cytoprotective layer that prevents the diffusion of gastric acid. It is less effective than PPIs and is typically used as an adjunctive medication for peptic ulcer disease.

(Choice D) Octreotide is a somatostatin analogue that inhibits gastrin synthesis (as well as many other gastrointestinal hormones). It is sometimes used in Zollinger-Ellison syndrome, but is not routinely used for GERD.

(Choice E) Misoprostol is a prostaglandin E1 analogue that binds prostaglandin receptors on parietal cells, reducing gastric acid production and inducing secretion of mucus and bicarbonate. Misoprostol can be used to prevent NSAID–induced gastric ulcers, but is less helpful for treating GERD; its significant uterotonic effects (eg, uterine contractions, cervical ripening) also limit its use in women of childbearing age.

Educational objective:

https://t.me/USMLEWorldStep1

elevated gastric pH and include an increased risk of *Clostridioides difficile* and nutritional deficiencies (eg, calcium, magnesium, iron).

Although less potent than PPIs, **histamine 2 receptor antagonists** (eg, famotidine, cimetidine) are also used as first-line therapy for GERD. They inhibit gastric acid secretion by targeting histamine receptors on parietal cells. These medications are less side effect–prone than PPIs; however, they have a slower onset of action, and tachyphylaxis is common.

(Choice A) Gastrin, a hormone released from G cells, binds to cholecystokinin (CCK) B receptors and stimulates gastric acid secretion both directly (through binding on parietal cells) and indirectly (through binding on enterochromaffin-like cells to increase histamine release). CCK receptor antagonists are not routinely used in clinical practice.

(Choice B) Sucralfate forms a viscous paste in the stomach, providing a cytoprotective layer that prevents the diffusion of gastric acid. It is less effective than PPIs and is typically used as an adjunctive medication for peptic ulcer disease.

(Choice D) Octreotide is a somatostatin analogue that inhibits gastrin synthesis (as well as many other gastrointestinal hormones). It is sometimes used in Zollinger-Ellison syndrome, but is not routinely used for GERD.

(Choice E) Misoprostol is a prostaglandin E1 analogue that binds prostaglandin receptors on parietal cells, reducing gastric acid production and inducing secretion of mucus and bicarbonate. Misoprostol can be used to prevent NSAID–induced gastric ulcers, but is less helpful for treating GERD; its significant uterotonic effects (eg, uterine contractions, cervical ripening) also limit its use in women of childbearing age.

Educational objective:
Management of gastroesophageal reflux disease includes lifestyle and dietary modifications (eg, weight loss, tobacco avoidance) and medications such as proton pump inhibitors (PPIs) (eg, pantoprazole, omeprazole) or histamine 2 receptor antagonists (eg, famotidine). PPIs irreversibly inhibit the H^+/K^+ ATPase on parietal cells, which decreases gastric acid secretion.

Pharmacology	Gastrointestinal & Nutrition	Gastroesophageal reflux disease
Subject	System	Topic

https://t.me/USMLEWorldStep1

A 73-year-old man comes to the clinic with epigastric pain that starts 30-40 minutes after meals and does not respond to antacids. The pain is non-radiating and is graded 6/10 in intensity. The patient has lost more than 4.5 kg (10 lb) over the last few months, which he attributes to eating less due to his fear of the pain. He has no vomiting, diarrhea, or urinary symptoms. His past medical history is significant for hypertension, hyperlipidemia, coronary artery bypass grafting, and right-sided carotid endarterectomy. He has smoked a pack of cigarettes daily for 32 years. Upper gastrointestinal endoscopy shows no abnormalities. The underlying pathophysiology of this patient's disease process is most similar to which of the following conditions?

- A. Aortic dissection
- B. Diffuse esophageal spasm
- C. Peptic ulcer disease
- D. Pulmonary embolism
- E. Stable angina

Submit

https://t.me/USMLEWorldStep1

A 73-year-old man comes to the clinic with epigastric pain that starts 30-40 minutes after meals and does not respond to antacids. The pain is non-radiating and is graded 6/10 in intensity. The patient has lost more than 4.5 kg (10 lb) over the last few months, which he attributes to eating less due to his fear of the pain. He has no vomiting, diarrhea, or urinary symptoms. His past medical history is significant for hypertension, hyperlipidemia, coronary artery bypass grafting, and right-sided carotid endarterectomy. He has smoked a pack of cigarettes daily for 32 years. Upper gastrointestinal endoscopy shows no abnormalities. The underlying pathophysiology of this patient's disease process is most similar to which of the following conditions?

- A. Aortic dissection (2%)
- ✗ B. Diffuse esophageal spasm (9%)
- C. Peptic ulcer disease (35%)
- D. Pulmonary embolism (3%)
- ✓ E. Stable angina (49%)

Incorrect
Correct answer
E

49%
Answered correctly

03 secs
Time Spent

2023
Version

Explanation

This patient's **postprandial epigastric pain** and associated **food aversion/weight loss** in the setting of generalized atherosclerosis (eg, coronary and carotid artery disease) is consistent with **chronic mesenteric ischemia**.

When atherosclerosis involves the mesenteric arteries, the bowel can suffer from **diminished blood supply**. Intestinal hypoperfusion, which can be very painful, is especially pronounced within an hour after meals when more blood is needed for the digestion/absorption of nutrients (intestinal angina). This is **analogous to stable cardiac angina**, chest pain that occurs with physical exertion due to increased myocardial oxygen demand. The diagnosis

https://t.me/USMLEWorldStep1

This patient's **postprandial epigastric pain** and associated **food aversion/weight loss** in the setting of generalized atherosclerosis (eg, coronary and carotid artery disease) is consistent with **chronic mesenteric ischemia**.

When atherosclerosis involves the mesenteric arteries, the bowel can suffer from **diminished blood supply**. Intestinal hypoperfusion, which can be very painful, is especially pronounced within an hour after meals when more blood is needed for the digestion/absorption of nutrients (intestinal angina). This is **analogous to stable cardiac angina**, chest pain that occurs with physical exertion due to increased myocardial oxygen demand. The diagnosis can be made with duplex ultrasonography or angiography showing high-grade stenosis in the celiac and mesenteric arteries.

(Choice A) Aortic dissection results from an aortic intimal tear with formation of a false lumen that can propagate and obstruct the vessels branching off the aorta (eg, renal, splanchnic, spinal, lower limb). A similar process would be more likely to cause acute end-organ damage (eg, cerebral infarction) rather than chronic, episodic ischemia.

(Choice B) Diffuse esophageal spasm is a motility disorder characterized by episodic, painful, non-propulsive esophageal smooth muscle contraction. Biliary colic is similar to esophageal spasm in that gallbladder contraction against an obstructed cystic duct results in postprandial epigastric pain.

(Choice C) Peptic ulcer disease is characterized by gastrointestinal erosions/ulcerations and is typically due to *Helicobacter pylori* infection or nonsteroidal anti-inflammatory drug use. This patient's pain did not respond to antacids and his upper endoscopy is normal, so he is unlikely to have a condition associated with peptic ulcers.

(Choice D) Pulmonary embolism is often due to an embolic blood clot lodging in the branches of the pulmonary artery, resulting in acute pulmonary ischemia/infarction. A similar pathogenesis accounts for acute mesenteric ischemia, which can occur with superior mesenteric artery embolism. This condition is more likely to cause sudden, severe abdominal pain rather than recurrent postprandial abdominal pain with food aversion.

Educational objective:
Chronic mesenteric ischemia is characterized by atherosclerosis of the mesenteric arteries, resulting in diminished blood flow to the intestine after meals. This causes postprandial epigastric pain (intestinal angina) with associated food aversion/weight loss. Its pathogenesis is similar to angina pectoris.

https://t.me/USMLEWorldStep1

ischemia.

When atherosclerosis involves the mesenteric arteries, the bowel can suffer from **diminished blood supply**. Intestinal hypoperfusion, which can be very painful, is especially pronounced within an hour after meals when more blood is needed for the digestion/absorption of nutrients (intestinal angina). This is **analogous to stable cardiac angina**, chest pain that occurs with physical exertion due to increased myocardial oxygen demand. The diagnosis can be made with duplex ultrasonography or angiography showing high-grade stenosis in the celiac and mesenteric arteries.

(Choice A) Aortic dissection results from an aortic intimal tear with formation of a false lumen that can propagate and obstruct the vessels branching off the aorta (eg, renal, splanchnic, spinal, lower limb). A similar process would be more likely to cause acute end-organ damage (eg, cerebral infarction) rather than chronic, episodic ischemia.

(Choice B) Diffuse esophageal spasm is a motility disorder characterized by episodic, painful, non-propulsive esophageal smooth muscle contraction. Biliary colic is similar to esophageal spasm in that gallbladder contraction against an obstructed cystic duct results in postprandial epigastric pain.

(Choice C) Peptic ulcer disease is characterized by gastrointestinal erosions/ulcerations and is typically due to *Helicobacter pylori* infection or nonsteroidal anti-inflammatory drug use. This patient's pain did not respond to antacids and his upper endoscopy is normal, so he is unlikely to have a condition associated with peptic ulcers.

(Choice D) Pulmonary embolism is often due to an embolic blood clot lodging in the branches of the pulmonary artery, resulting in acute pulmonary ischemia/infarction. A similar pathogenesis accounts for acute mesenteric ischemia, which can occur with superior mesenteric artery embolism. This condition is more likely to cause sudden, severe abdominal pain rather than recurrent postprandial abdominal pain with food aversion.

Educational objective:
Chronic mesenteric ischemia is characterized by atherosclerosis of the mesenteric arteries, resulting in diminished blood flow to the intestine after meals. This causes postprandial epigastric pain (intestinal angina) with associated food aversion/weight loss. Its pathogenesis is similar to angina pectoris.

References

- Chronic mesenteric ischemia: diagnosis and management.

https://t.me/USMLEWorldStep1

A 53-year-old man who has not seen a physician in years presents to your office complaining of abdominal distention. He states "Last month my stomach started to swell up and it hasn't gotten any better". He has no other medical problems. The patient admits to drinking 10-12 beers a day for the last 20 years. His temperature is 36.7 C (98 F), blood pressure is 116/72 mm Hg, pulse is 78/min and respirations are 20/min. On examination his abdomen is distended with engorged paraumbilical veins. There is also palmar erythema and multiple spider angiomas are present. You decided to place him on a low-salt diet and start therapy with furosemide and spironolactone, with subsequent improvement of his abdominal distention. Before beginning this patient's treatment, which of the following structures labeled on the image below is expected to have an increased pressure?

- A. A
- B. B

https://t.me/USMLEWorldStep1

C (98 F), blood pressure is 116/72 mm Hg, pulse is 78/min and respirations are 20/min. On examination his abdomen is distended with engorged paraumbilical veins. There is also palmar erythema and multiple spider angiomas are present. You decided to place him on a low-salt diet and start therapy with furosemide and spironolactone, with subsequent improvement of his abdominal distention. Before beginning this patient's treatment, which of the following structures labeled on the image below is expected to have an increased pressure?

- A. A
- B. B
- C. C
- D. D

https://t.me/USMLEWorldStep1

angiomas are present. You decided to place him on a low-salt diet and start therapy with furosemide and spironolactone, with subsequent improvement of his abdominal distention. Before beginning this patient's treatment, which of the following structures labeled on the image below is expected to have an increased pressure?

- A. A (3%)
- ✗ B. B (18%)
- ✓ C. C (71%)
- D. D (5%)

Incorrect
Correct answer
C

71%
Answered correctly

10 secs
Time Spent

2023
Version

https://t.me/USMLEWorldStep1

Incorrect
Correct answer
C

71%
Answered correctly

10 secs
Time Spent

2023
Version

Exhibit Display

Abdominal CT anatomy

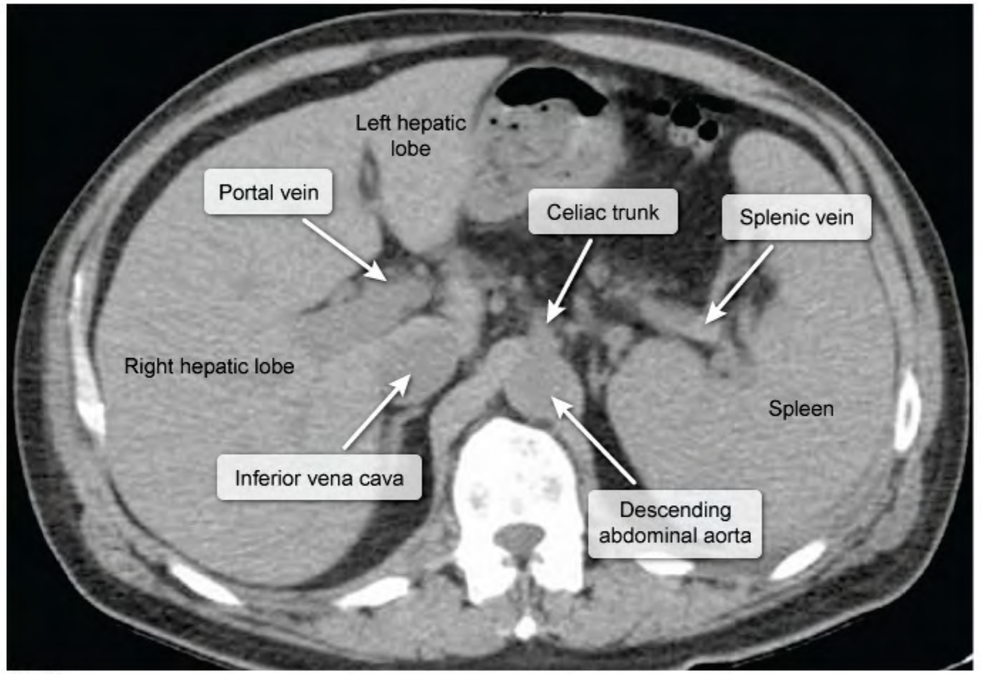

©UWorld

Zoom In | Zoom Out | Reset | New | Existing | My Notebook

Expl

The pa
cirrhos
numbe
portal blood has an increasingly difficult time passing through the liver because the vasculature becomes compromised by the progressive fibrosis, causing portal hypertension. Of the structures identified on the image

https://t.me/USMLEWorldStep1

The patient described in the question stem is likely suffering from alcohol-induced cirrhosis, a form of micronodular cirrhosis associated with hepatocyte death followed by fine fibrosis of the liver. As cirrhosis worsens and the number of functioning hepatocytes decreases, the functional ability of the liver diminishes. In advanced disease, portal blood has an increasingly difficult time passing through the liver because the vasculature becomes compromised by the progressive fibrosis, causing portal hypertension. Of the structures identified on the image above, only the portal and splenic veins are part of the portal venous system. In this patient, high pressure would be expected throughout the portal system, including the superior mesenteric, portal, and splenic veins. The effects of prolonged portal hypertension include varices at the four sites of portocaval anastomoses (esophagus, rectum, umbilicus, and retroperitoneal), as well as ascites.

The pathogenesis of ascites in patients with cirrhosis is complex. In addition to mechanical compromise of portal vein flow by fibrotic tissue, vasoactive agents also play a role by causing dilatation of the splanchnic arterial vasculature and further intrahepatic vasoconstriction. These processes result in increased portal vein hydrostatic pressure leading to ascitic fluid formation, as well as decreased systemic perfusion pressure. The kidney senses the decreased perfusion pressure (accentuated by renal vasoconstriction in hepatorenal syndrome) and responds with avid retention of sodium and water, thus promoting further increase in ascitic fluid formation. Treatment of ascites secondary to cirrhosis involves restriction of sodium intake combined with diuretics. The most commonly prescribed initial therapy is a combination of furosemide and spironolactone.

(Choice A) The descending abdominal aorta will have elevated pressures in patients with systemic hypertension.

(Choice B) The inferior vena cava experiences increased pressure in cases of heart failure. This patient does not present with the typical symptoms associated with heart failure, such as lower extremity edema and shortness of breath.

(Choice D) The celiac trunk emerges from the aorta at this level (T12 / L1).

Educational objective:
The portal vein can be identified on cross-sectional scans lying medial to (or just within) the right lobe of the liver and anterior to the inferior vena cava. The pressure in the portal system is elevated in liver cirrhosis.

Anatomy Gastrointestinal & Nutrition Portal hypertension

https://t.me/USMLEWorldStep1

A 2-year-old boy who attends daycare is brought to the emergency department due to diarrhea, fatigue, and abdominal cramps. The parents also state that he has foul-smelling, frothy stools. The boy is admitted for rehydration and subsequently diagnosed with giardiasis, which is treated with metronidazole. He improves and is discharged home. One week after discharge, the boy is seen by the primary health care provider for recurrent symptoms of frothy, loose stools and abdominal bloating and cramping. Which of the following steps of this pathway is most likely impaired in this patient?

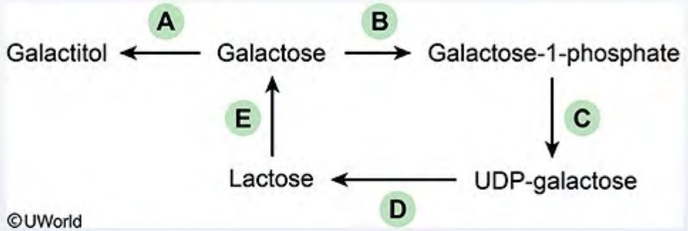

- A. A
- B. B
- C. C
- D. D
- E. E

Submit

https://t.me/USMLEWorldStep1

A 2-year-old boy who attends daycare is brought to the emergency department due to diarrhea, fatigue, and
abdom
rehydr
discha
sympt
pathw

Exhibit Display

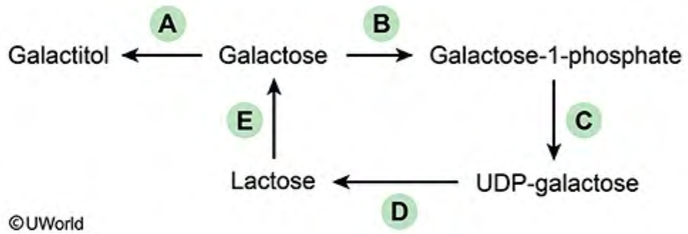

Zoom In Zoom Out Reset New | Existing My Notebook

Sub

https://t.me/USMLEWorldStep1

A 2-year-old boy who attends daycare is brought to the emergency department due to diarrhea, fatigue, and abdominal cramps. The parents also state that he has foul-smelling, frothy stools. The boy is admitted for rehydration and subsequently diagnosed with giardiasis, which is treated with metronidazole. He improves and is discharged home. One week after discharge, the boy is seen by the primary health care provider for recurrent symptoms of frothy, loose stools and abdominal bloating and cramping. Which of the following steps of this pathway is most likely impaired in this patient?

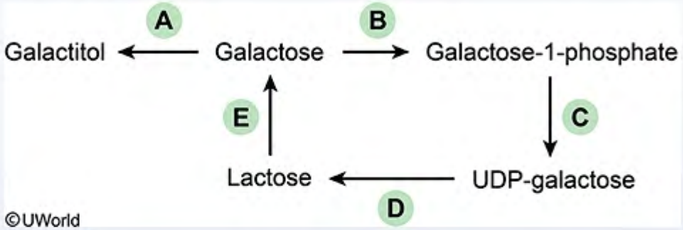

- A. A (1%)
- ✕ B. B (8%)
- C. C (9%)
- D. D (4%)
- ✓ E. E (75%)

Incorrect
Correct answer
E

75%
Answered correctly

10 secs
Time Spent

2023
Version

Explanation

https://t.me/USMLEWorldStep1

A. A (1%)

Exhibit Display

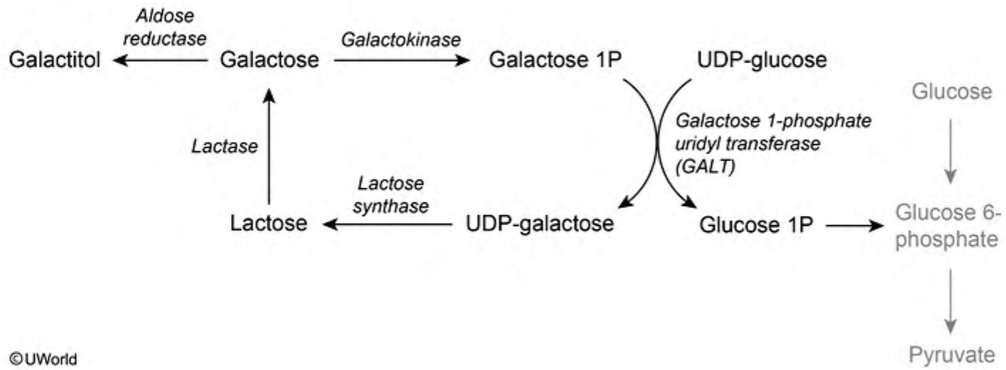

Zoom In | Zoom Out | Reset | New | Existing | My Notebook

Lactos
galact
intole
is ferm
bloati

Lactose intolerance can be either primary or secondary. Primary lactose intolerance is due to a genetically regulated reduction of lactase production, and its incidence increases with age. **Secondary** or acquired lactose

https://t.me/USMLEWorldStep1

©UWorld

Pyruvate

Lactose is a disaccharide present in milk and other dairy products that is normally hydrolyzed into glucose and galactose by lactase, a brush border enzyme concentrated in epithelial cells of the small intestine. **Lactose intolerance** is due to **decreased or absent lactase**. Malabsorbed lactose then enters the large intestine where it is fermented by bacteria, causing the clinical features of lactose intolerance: **diarrhea**, **flatulence**, and **abdominal bloating and cramping**.

Lactose intolerance can be either primary or secondary. Primary lactose intolerance is due to a genetically regulated reduction of lactase production, and its incidence increases with age. **Secondary** or acquired lactose intolerance can be due to **inflammation** (eg, celiac disease) or **infection** (eg, giardiasis) of the small intestine, both of which cause cellular damage to the intestinal lining. The damaged cells slough off and are replaced by immature cells with low lactase concentrations, resulting in a decreased ability to convert lactose to galactose. Secondary lactose intolerance is common after giardial infections.

(Choices A, B, and C) Galactose-1-phosphate uridyl transferase (GALT) deficiency causes the most severe and most common form of galactosemia. Symptoms occur within the first few days of life after initiation of breastfeeding or formula and include vomiting, jaundice, hepatomegaly, and lethargy. Excess galactose is converted to galactitol by aldose reductase, resulting in cataracts from excess galactitol deposition in the lens. Galactokinase deficiency is a less common type of galactosemia, causing cataract formation only.

(Choice D) Lactose synthase converts UDP-galactose to lactose within the mammary glands during milk formation. Deficiency of this enzyme does not result in lactose malabsorption.

Educational objective:
Secondary lactase deficiency can occur after inflammatory (eg, celiac disease) or infectious (eg, giardiasis) processes damage the microvilli of the small intestines. Clinical presentation includes abdominal distension and cramping, flatulence, and diarrhea.

References

- Lactose intolerance.
- Lactose intolerance in infants, children, and adolescents.
- Lactose malabsorption

https://t.me/USMLEWorldStep1

A 30-year-old man with a year-long history of heartburn comes to the office due to worsening substernal burning. The symptoms are particularly intense at night. Recently, the patient has also started noticing pain with swallowing food, although there is no sensation of food getting stuck in his throat. The patient initially treated himself with over-the-counter calcium carbonate antacid, but the treatment has become less effective recently. He has no other chronic medical conditions. Recent HIV testing was negative. The patient takes no other medications. He drinks 2 or 3 beers each evening and smokes a pack of cigarettes daily. BMI is 34 kg/m^2. Vital signs are within normal limits. Physical examination reveals no abnormalities. An esophagogastroduodenoscopy is planned. This patient's recent worsening of symptoms is most likely related to which of the following?

- A. Columnar metaplasia
- B. Erosive esophagitis
- C. Herpes simplex infection
- D. Malignancy
- E. Stricture

Submit

https://t.me/USMLEWorldStep1

A 30-year-old man with a year-long history of heartburn comes to the office due to worsening substernal burning. The symptoms are particularly intense at night. Recently, the patient has also started noticing pain with swallowing food, although there is no sensation of food getting stuck in his throat. The patient initially treated himself with over-the-counter calcium carbonate antacid, but the treatment has become less effective recently. He has no other chronic medical conditions. Recent HIV testing was negative. The patient takes no other medications. He drinks 2 or 3 beers each evening and smokes a pack of cigarettes daily. BMI is 34 kg/m^2. Vital signs are within normal limits. Physical examination reveals no abnormalities. An esophagogastroduodenoscopy is planned. This patient's recent worsening of symptoms is most likely related to which of the following?

- A. Columnar metaplasia
- ✓ B. Erosive esophagitis
- C. Herpes simplex infection
- D. Malignancy
- E. Stricture

Correct | Collecting Statistics | 04 secs Time Spent | 2023 Version

Explanation

Gastroesophageal reflux disease	
Pathophysiology	• Decreased tone or excessive transient relaxation of LES • Anatomic disruption to gastroesophageal junction (eg, hiatal hernia) • ↑ Risk with obesity, pregnancy, smoking, alcohol intake
	• Regurgitation of acidic material in mouth

https://t.me/USMLEWorldStep1

Explanation

Gastroesophageal reflux disease	
Pathophysiology	• Decreased tone or excessive transient relaxation of LES • Anatomic disruption to gastroesophageal junction (eg, hiatal hernia) • ↑ Risk with obesity, pregnancy, smoking, alcohol intake
Manifestations	• Regurgitation of acidic material in mouth • **Heartburn** • Odynophagia (often indicates reflux esophagitis) • Extraesophageal symptoms (eg, cough, laryngitis, wheezing)
Complications	• Erosive esophagitis • Strictures • Barrett esophagus → adenocarcinoma
Initial treatment	• Lifestyle (eg, weight loss) & dietary changes • H2R blocker or proton pump inhibitor
H2R = histamine 2 receptor; **LES** = lower esophageal sphincter.	

Gastroesophageal reflux disease (GERD) is caused by the retrograde flow of acidic stomach contents through the lower esophageal sphincter into the esophagus. Patients with GERD typically experience postprandial **substernal burning** pain or reflux (**regurgitation** of acid and/or undigested foods).

Although uncomplicated GERD is not associated with significant esophageal mucosal injury, prolonged epithelial exposure to highly acidic secretions can result in epithelial damage and complications, such as:

- **Erosive esophageal disease** with development of esophageal ulcers, which is often marked by a **worsening** of baseline GERD symptoms and the development of **odynophagia** (painful swallowing).
- Barrett esophagus, characterized by the replacement of normal stratified squamous epithelium with metaplastic columnar epithelium in the distal esophagus. This metaplastic change results from long-standing

https://t.me/USMLEWorldStep1

	• Odynophagia (often indicates reflux esophagitis) • Extraesophageal symptoms (eg, cough, laryngitis, wheezing)
Complications	• Erosive esophagitis • Strictures • Barrett esophagus → adenocarcinoma
Initial treatment	• Lifestyle (eg, weight loss) & dietary changes • H2R blocker or proton pump inhibitor
H2R = histamine 2 receptor; **LES** = lower esophageal sphincter.	

Gastroesophageal reflux disease (GERD) is caused by the retrograde flow of acidic stomach contents through the lower esophageal sphincter into the esophagus. Patients with GERD typically experience postprandial **substernal burning** pain or reflux (**regurgitation** of acid and/or undigested foods).

Although uncomplicated GERD is not associated with significant esophageal mucosal injury, prolonged epithelial exposure to highly acidic secretions can result in epithelial damage and complications, such as:

- **Erosive esophageal disease** with development of esophageal ulcers, which is often marked by a **worsening** of baseline GERD symptoms and the development of **odynophagia** (painful swallowing).
- Barrett esophagus, characterized by the replacement of normal stratified squamous epithelium with metaplastic columnar epithelium in the distal esophagus. This metaplastic change results from long-standing GERD, but typically does not produce any new symptoms (eg, no odynophagia) **(Choice A)**.
- Esophageal stricture, which typically develops in the setting of a healing esophageal ulcer when collagen fibers contract and cause narrowing of the esophageal lumen. Strictures are associated with a sensation of food getting stuck in the esophagus but do not cause odynophagia (as no active ulceration is present) **(Choice E)**.

(Choice C) Infectious esophagitis presents with odynophagia and can be caused by a number of pathogens, including cytomegalovirus, Candida, and herpes simplex virus. However, it usually develops in immunocompromised patients (eg, HIV, corticosteroid therapy); this patient's odynophagia is more likely the result of erosive esophagitis secondary to chronic GERD.

https://t.me/USMLEWorldStep1

the lower esophageal sphincter into the esophagus. Patients with GERD typically experience postprandial **substernal burning** pain or reflux (**regurgitation** of acid and/or undigested foods).

Although uncomplicated GERD is not associated with significant esophageal mucosal injury, prolonged epithelial exposure to highly acidic secretions can result in epithelial damage and complications, such as:

- **Erosive esophageal disease** with development of esophageal ulcers, which is often marked by a **worsening** of baseline GERD symptoms and the development of **odynophagia** (painful swallowing).
- Barrett esophagus, characterized by the replacement of normal stratified squamous epithelium with metaplastic columnar epithelium in the distal esophagus. This metaplastic change results from long-standing GERD, but typically does not produce any new symptoms (eg, no odynophagia) **(Choice A)**.
- Esophageal stricture, which typically develops in the setting of a healing esophageal ulcer when collagen fibers contract and cause narrowing of the esophageal lumen. Strictures are associated with a sensation of food getting stuck in the esophagus but do not cause odynophagia (as no active ulceration is present) **(Choice E)**.

(Choice C) Infectious esophagitis presents with odynophagia and can be caused by a number of pathogens, including cytomegalovirus, Candida, and herpes simplex virus. However, it usually develops in immunocompromised patients (eg, HIV, corticosteroid therapy); this patient's odynophagia is more likely the result of erosive esophagitis secondary to chronic GERD.

(Choice D) Although this patient has risk factors for esophageal adenocarcinoma (ie, GERD, tobacco use) and squamous cell carcinoma (ie, alcohol and tobacco use), accompanying symptoms such as weight loss and dysphagia (caused by mechanical obstruction of food by the tumor) are expected. This patient's young age, relatively short duration of GERD, and presence of odynophagia and heartburn as sole symptoms make malignancy less likely.

Educational objective:
New-onset odynophagia in the setting of gastroesophageal reflux disease should raise suspicion for erosive esophagitis (eg, esophageal ulcers).

References

https://t.me/USMLEWorldStep1

A 32-year-old man comes to the office due to a substernal burning sensation that has been occurring intermittently over the last 6 months. The sensation worsens with spicy and fatty meals and is associated with food regurgitation and a sour taste in the back of the throat. He has no projectile vomiting, dysphagia, or unexpected weight loss. Medical history is significant for cystic fibrosis complicated by pancreatic insufficiency, for which the patient takes pancreatic enzyme replacement therapy with all meals. Vital signs are within normal limits. The abdomen is soft and nontender. He is prescribed omeprazole with subsequent improvement in his gastroesophageal reflux symptoms. In this patient, absorption of which of the following nutrients will likely improve due to initiation of this new medication?

- A. Amino acids
- B. Calcium
- C. Dietary fat
- D. Iron
- E. Magnesium

Submit

https://t.me/USMLEWorldStep1

A 32-year-old man comes to the office due to a substernal burning sensation that has been occurring intermittently over the last 6 months. The sensation worsens with spicy and fatty meals and is associated with food regurgitation and a sour taste in the back of the throat. He has no projectile vomiting, dysphagia, or unexpected weight loss. Medical history is significant for cystic fibrosis complicated by pancreatic insufficiency, for which the patient takes pancreatic enzyme replacement therapy with all meals. Vital signs are within normal limits. The abdomen is soft and nontender. He is prescribed omeprazole with subsequent improvement in his gastroesophageal reflux symptoms. In this patient, absorption of which of the following nutrients will likely improve due to initiation of this new medication?

- A. Amino acids (22%)
- ✗ B. Calcium (13%)
- ✓ C. Dietary fat (35%)
- D. Iron (19%)
- E. Magnesium (8%)

Incorrect
Correct answer
C

35%
Answered correctly

03 secs
Time Spent

2023
Version

Explanation

Proton pump inhibitors	
Mechanism of action	• Irreversible inhibition of parietal cell hydrogen-potassium-ATPase
Common uses	• Gastroesophageal reflux disease • Peptic ulcer disease
	• Malabsorption of calcium, iron, magnesium & vitamin B_{12}

https://t.me/USMLEWorldStep1

Explanation

Proton pump inhibitors	
Mechanism of action	• Irreversible inhibition of parietal cell hydrogen-potassium-ATPase
Common uses	• Gastroesophageal reflux disease • Peptic ulcer disease
Adverse effects	• Malabsorption of calcium, iron, magnesium & vitamin B_{12} ◦ Enhances fat absorption in patients given pancreatic enzyme replacement therapy • Increases risk of infection (eg, *Clostridioides* [formerly *Clostridium*] *difficile*, pneumonia) • Osteoporosis, chronic kidney disease, SIBO
SIBO = small intestinal bacterial overgrowth.	

This patient with heartburn and regurgitation has the classic manifestations of gastroesophageal reflux disease, a common disorder that occurs when gastric acid refluxes into the esophagus. The mainstay of therapy is gastric acid suppression, usually with **proton pump inhibitors** (PPIs) (eg, pantoprazole, omeprazole).

PPIs irreversibly inhibit the hydrogen-potassium-ATPase pump found in parietal cells, thereby inhibiting hydrochloric acid secretion into the stomach lumen. Although this effectively raises the stomach pH and prevents gastric acid irritation of the esophagus, the acidic environment of the stomach is necessary to absorb certain nutrients. Therefore, common adverse effects of PPIs include malabsorption of calcium, iron, magnesium, and vitamin B_{12} **(Choices B, D, and E)**.

Patients with **pancreatic insufficiency** (eg, cystic fibrosis, chronic pancreatitis) cannot synthesize the pancreatic enzymes required for digestion of protein, fat, and carbohydrates. As such, the condition is managed with pancreatic enzyme replacements, which contain varying amounts of lipase, amylase, and protease. Unlike amylase and protease, which are activated by the low pH of the stomach, **lipase**, which plays a vital role in fat

https://t.me/USMLEWorldStep1

SIBO = small intestinal bacterial overgrowth.

This patient with heartburn and regurgitation has the classic manifestations of gastroesophageal reflux disease, a common disorder that occurs when gastric acid refluxes into the esophagus. The mainstay of therapy is gastric acid suppression, usually with **proton pump inhibitors** (PPIs) (eg, pantoprazole, omeprazole).

PPIs irreversibly inhibit the hydrogen-potassium-ATPase pump found in parietal cells, thereby inhibiting hydrochloric acid secretion into the stomach lumen. Although this effectively raises the stomach pH and prevents gastric acid irritation of the esophagus, the acidic environment of the stomach is necessary to absorb certain nutrients. Therefore, common adverse effects of PPIs include malabsorption of calcium, iron, magnesium, and vitamin B_{12} **(Choices B, D, and E)**.

Patients with **pancreatic insufficiency** (eg, cystic fibrosis, chronic pancreatitis) cannot synthesize the pancreatic enzymes required for digestion of protein, fat, and carbohydrates. As such, the condition is managed with pancreatic enzyme replacements, which contain varying amounts of lipase, amylase, and protease. Unlike amylase and protease, which are activated by the low pH of the stomach, **lipase**, which plays a vital role in fat digestion, is **inactivated by the acidic environment** of the stomach. Therefore, by decreasing gastric hydrochloric acid production, **PPI use increases lipase activity** (ie, it prevents exogenous lipase from being denatured as it passes through the stomach), **enhancing fat absorption** in patients dependent on pancreatic enzyme replacement therapy.

(Choice A) Protein digestion of amino acids requires the activity of a protease known as pepsin, which is more active at low pH. Although one might expect the elevated stomach pH to inhibit protein absorption, chronic PPI use has not been associated with protein malabsorption (likely due to functional overlap with pancreatic and enteric proteases).

Educational objective:
Proton pump inhibitors (PPI) prevent the hydrogen-potassium-ATPase pump found in parietal cells from releasing hydrochloric acid into the stomach lumen. Chronic PPI use protects exogenously administered lipase and enhances fat absorption in patients dependent on pancreatic enzyme replacement therapy.

References

https://t.me/USMLEWorldStep1

SIBO = small intestinal bacterial overgrowth.

Exhibit Display

Parietal cell acid secretion

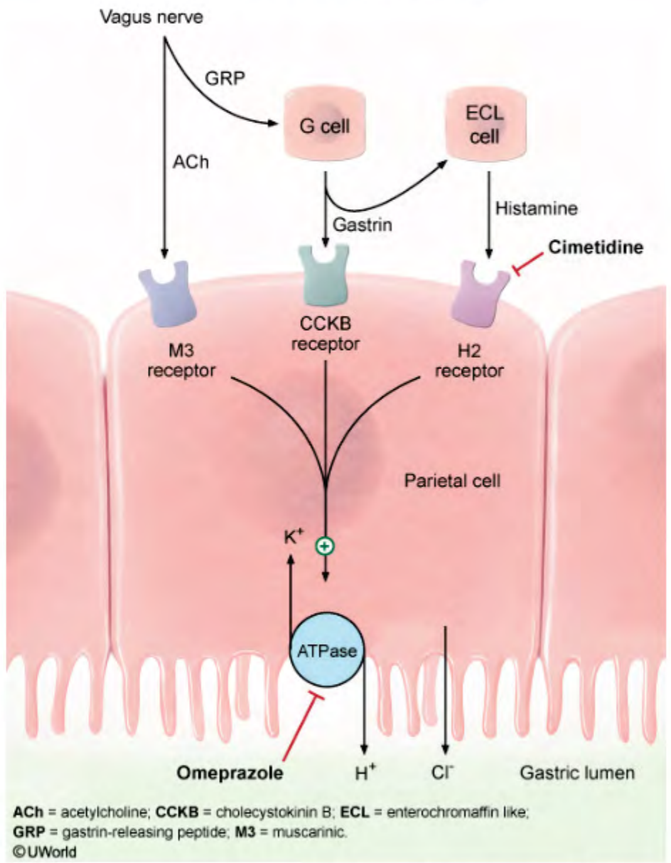

ACh = acetylcholine; **CCKB** = cholecystokinin B; **ECL** = enterochromaffin like; **GRP** = gastrin-releasing peptide; **M3** = muscarinic.
©UWorld

Zoom In | Zoom Out | Reset | New | Existing | My Notebook

This p
comm
acid su

PPIs i
hydroc
gastric
nutrien
vitami

Patien
enzym
pancre
amyla
digesti
hydroc
denatu
enzym

(Choi
active
has no
protea

Educa
Proton
hydroc
enhances fat absorption in patients dependent on pancreatic enzyme replacement therapy.

References

https://t.me/USMLEWorldStep1

A 2-day-old boy is evaluated in the newborn nursery due to vomiting. He was born at term to a 30-year-old primigravida via spontaneous vaginal delivery. The patient initially tolerated formula after birth. However, the past 2 feeding attempts resulted in bilious emesis. Cardiopulmonary examination is unremarkable. Abdominal examination shows distension with active bowel sounds. There is no hepatosplenomegaly. Digital rectal examination results in a forceful expulsion of gas. Which of the following processes was most likely impaired during embryologic development of this patient's gastrointestinal system?

- A. Cell migration
- B. Obliteration
- C. Recanalization
- D. Rotation
- E. Vascularization

Submit

https://t.me/USMLEWorldStep1

A 2-day-old boy is evaluated in the newborn nursery due to vomiting. He was born at term to a 30-year-old primigravida via spontaneous vaginal delivery. The patient initially tolerated formula after birth. However, the past 2 feeding attempts resulted in bilious emesis. Cardiopulmonary examination is unremarkable. Abdominal examination shows distension with active bowel sounds. There is no hepatosplenomegaly. Digital rectal examination results in a forceful expulsion of gas. Which of the following processes was most likely impaired during embryologic development of this patient's gastrointestinal system?

- ✓ A. Cell migration (64%)
- ✗ B. Obliteration (3%)
- C. Recanalization (18%)
- D. Rotation (11%)
- E. Vascularization (1%)

Incorrect
Correct answer
A

64%
Answered correctly

03 secs
Time Spent

2023
Version

Explanation

https://t.me/USMLEWorldStep1

A 2-day-old boy is evaluated in the newborn nursery due to vomiting. He was born at term to a 30-year-old primig
2 feed
exami
exami
during

Inco
Corre
A

Expl

Exhibit Display

Hirschsprung disease

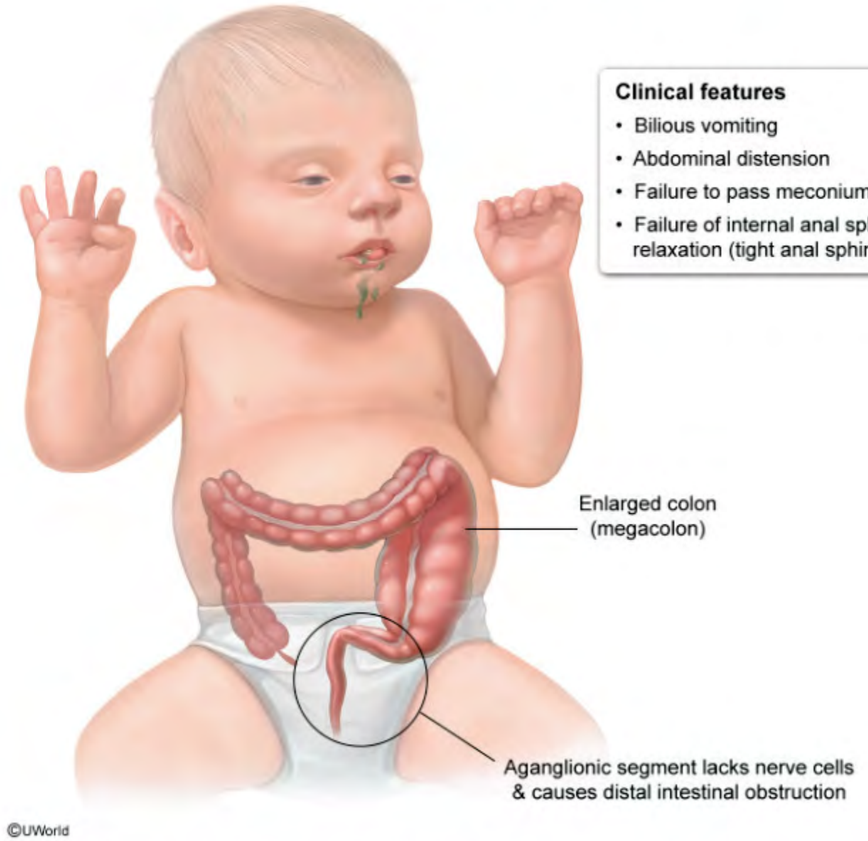

Zoom In | Zoom Out | Reset | New | Existing | My Notebook

• Failure of internal anal sphincter relaxation (tight anal sphincter)

https://t.me/USMLEWorldStep1

Hirschsprung disease (HD). During normal embryogenesis, neural crest cells migrate craniocaudally and provide parasympathetic innervation to the bowel. HD is a congenital disorder caused by **failure of neural crest cell migration**. The affected distal colon segment, usually confined to the **rectosigmoid** region, lacks innervation by ganglion cells (derived from neural crest cells) and is therefore **unable to relax**.

The contracted rectosigmoid colon prevents passage of gas and stool, and affected patients commonly **do not pass meconium** by 48 hours of life. Newborns with HD may also show signs of distal intestinal obstruction, as in this patient with poor feeding, bilious emesis, and abdominal distension. Increased rectal tone is typical, and **forceful expulsion of gas and/or stool** ("squirt sign") may occur with digital rectal examination due to temporary relief of the impaction.

Supportive radiographic findings of HD on contrast enema include an abrupt transition zone between the **narrow aganglionic segment** and the dilated proximal colon (ie, megacolon) due to stool retention. The absence of ganglia on rectal suction biopsy confirms the diagnosis.

(Choices B and E) Meckel diverticulum, which is caused by lack of physiologic obliteration of the vitelline duct, usually presents with painless rectal bleeding; less commonly, signs of bowel obstruction can occur (eg, due to intussusception). Congenital vascular malformations (eg, hemangioma) affecting the gastrointestinal tract would also cause recurrent rectal bleeding. Both conditions rarely present in the newborn period, and neither causes an abnormal rectal examination.

(Choices C and D) Failure of physiologic bowel recanalization causes duodenal atresia, which typically presents in newborns with bilious emesis after feeding due to proximal bowel obstruction. Patients with intestinal malrotation may also exhibit signs of bowel obstruction. However, rectal examination would not produce forceful expulsion of gas in either condition.

Educational objective:
Hirschsprung disease is a congenital disorder caused by failure of normal craniocaudal migration of neural crest cells during embryogenesis. The affected colon segment (eg, rectosigmoid) lacks ganglionic innervation and is unable to relax, resulting in obstruction with failure to pass meconium and bilious emesis. Forceful expulsion of gas and stool on rectal examination is typical.

https://t.me/USMLEWorldStep1

Hirschsprung disease (HD). During normal embryogenesis, neural crest cells migrate craniocaudally and provide

parasy
migra
gangli

The co
pass
this pa
forcef
relief c

Suppo
agang
gangli

(Choi
usuall
intuss
also c
abnor

(Choi
in new
malrot
expuls

Educa
Hirsch
cells d
unable
gas and stool on rectal examination is typical.

Exhibit Display

Hirschsprung disease

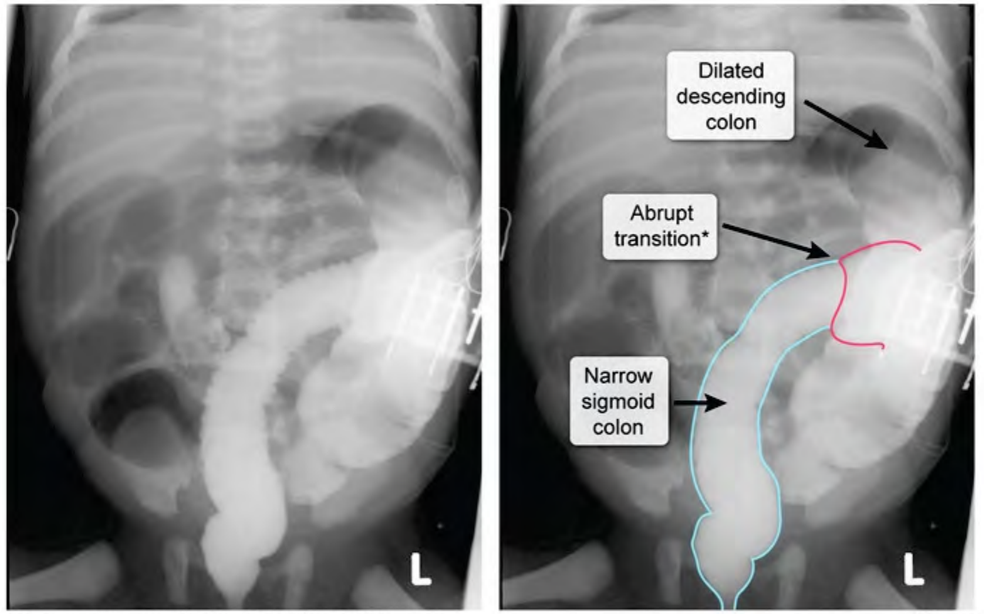

*Between narrow, aganglionic colon & dilated proximal colon.

©UWorld

Zoom In | Zoom Out | Reset | New | Existing | My Notebook

https://t.me/USMLEWorldStep1

An 18-month-old boy is brought to the office due to abnormal limb movements and delay in achieving motor milestones. He is unable to pull up to stand or walk and recently developed stiffness in the extremities. Birth history is remarkable for readmission at age 1 week for severe, persistent jaundice due to RhD incompatibility, which required intensive phototherapy and exchange transfusion. On examination, the patient exhibits a limited upward gaze and dystonic extremity movement. MRI of the head would most likely reveal abnormal signal in which of the following areas?

- A. Basal ganglia
- B. Corpus callosum
- C. Lateral temporal cortex
- D. Mammillary bodies
- E. Occipital cortex

Submit

https://t.me/USMLEWorldStep1

An 18-month-old boy is brought to the office due to abnormal limb movements and delay in achieving motor milestones. He is unable to pull up to stand or walk and recently developed stiffness in the extremities. Birth history is remarkable for readmission at age 1 week for severe, persistent jaundice due to RhD incompatibility, which required intensive phototherapy and exchange transfusion. On examination, the patient exhibits a limited upward gaze and dystonic extremity movement. MRI of the head would most likely reveal abnormal signal in which of the following areas?

- ✓ A. Basal ganglia (81%)
- ✗ B. Corpus callosum (5%)
- C. Lateral temporal cortex (3%)
- D. Mammillary bodies (6%)
- E. Occipital cortex (2%)

Incorrect
Correct answer
A

81%
Answered correctly

04 secs
Time Spent

2023
Version

Explanation

Bilirubin-induced neurologic dysfunction	
Pathophysiology	• Excess levels of free, unconjugated bilirubin cross the blood-brain barrier • Bilirubin deposits in basal ganglia & brainstem nuclei • Neuronal damage, necrosis & atrophy
Risk factors	• Prematurity • Hemolysis (eg, glucose-6-phosphate dehydrogenase deficiency) • Birth trauma (eg, cephalohematoma)

https://t.me/USMLEWorldStep1

Bilirubin-induced neurologic dysfunction	
Pathophysiology	• Excess levels of free, unconjugated bilirubin cross the blood-brain barrier • Bilirubin deposits in basal ganglia & brainstem nuclei • Neuronal damage, necrosis & atrophy
Risk factors	• Prematurity • Hemolysis (eg, glucose-6-phosphate dehydrogenase deficiency) • Birth trauma (eg, cephalohematoma) • Exclusive breastfeeding with excessive weight loss
Clinical features	• Acute encephalopathy: hypertonia, irritability, apnea, seizures • Chronic encephalopathy: sensorineural hearing loss, choreoathetoid movements, upward gaze palsy

This child with a history of severe neonatal jaundice has dystonic movements and gaze abnormalities, findings concerning for **bilirubin-induced neurologic dysfunction** (BIND).

Unconjugated bilirubin, a by-product of red blood cell destruction, is normally increased in all newborns and is bound to plasma albumin, preventing it from crossing the immature neonatal **blood-brain barrier**. However, the bilirubin concentration can dramatically rise (total bilirubin >30 mg/dL), usually in the setting of an underlying hemolytic condition (eg, RhD incompatibility, glucose-6-phosphate dehydrogenase deficiency), and can exceed the albumin binding capacity. If this happens, the **excess bilirubin** remains **unbound** and can pass beyond the blood-brain barrier. This neurotoxic bilirubin preferentially deposits in the basal ganglia and **brainstem nuclei**.

Initial symptoms of acute BIND occur in the neonatal period and are often subtle (eg, poor feeding) but may include inconsolability, change in tone, and apnea. Patients with prolonged, severe hyperbilirubinemia or delayed/inadequate treatment are at risk for chronic BIND (previously referred to as kernicterus), which typically develops after infancy and is irreversible. Destruction of neurons in the basal ganglia leads to **abnormal movements** (eg, **chorea, dystonia**). Similarly, **upward gaze palsy** and **sensorineural hearing loss** occur due to neuronal destruction in the gray matter of visual and auditory brainstem nuclei, respectively. Developmental delay, as seen in this patient, is also typical.

https://t.me/USMLEWorldStep1

This child with a history of severe neonatal jaundice has dystonic movements and gaze abnormalities, findings concerning for **bilirubin-induced neurologic dysfunction** (BIND).

Unconjugated bilirubin, a by-product of red blood cell destruction, is normally increased in all newborns and is bound to plasma albumin, preventing it from crossing the immature neonatal **blood-brain barrier**. However, the bilirubin concentration can dramatically rise (total bilirubin >30 mg/dL), usually in the setting of an underlying hemolytic condition (eg, RhD incompatibility, glucose-6-phosphate dehydrogenase deficiency), and can exceed the albumin binding capacity. If this happens, the **excess bilirubin** remains **unbound** and can pass beyond the blood-brain barrier. This neurotoxic bilirubin preferentially deposits in the basal ganglia and **brainstem nuclei**.

Initial symptoms of acute BIND occur in the neonatal period and are often subtle (eg, poor feeding) but may include inconsolability, change in tone, and apnea. Patients with prolonged, severe hyperbilirubinemia or delayed/inadequate treatment are at risk for chronic BIND (previously referred to as kernicterus), which typically develops after infancy and is irreversible. Destruction of neurons in the basal ganglia leads to **abnormal movements** (eg, **chorea, dystonia**). Similarly, **upward gaze palsy** and **sensorineural hearing loss** occur due to neuronal destruction in the gray matter of visual and auditory brainstem nuclei, respectively. Developmental delay, as seen in this patient, is also typical.

(Choice B) Abnormalities of the corpus callosum (eg, agenesis, dysgenesis) often cause gross motor delay. However, dystonia and gaze abnormalities would not be expected, and bilirubin deposition does not occur in the corpus callosum.

(Choice C) Damage to the lateral temporal cortex, which is typically spared in BIND, usually affects receptive speech (ie, Wernicke area), and gross motor delays would not be seen.

(Choice D) Thiamine deficiency in adults with Wernicke-Korsakoff syndrome is associated with mammillary body damage that causes memory impairment, not motor dysfunction. BIND is not associated with damage to this area.

(Choice E) Occipital lobe damage, which does not occur in BIND, can lead to cortical blindness but does not explain this patient's abnormal movements and tone.

Educational objective:
Excess unconjugated bilirubin in the neonatal period, often caused by increased hemolysis, can cross the blood-brain barrier and deposit in the basal ganglia and brainstem nuclei. If inadequately treated, this can lead to

https://t.me/USMLEWorldStep1

bound to plasma albumin, preventing it from crossing the immature neonatal **blood-brain barrier**. However, the bilirubin concentration can dramatically rise (total bilirubin >30 mg/dL), usually in the setting of an underlying hemolytic condition (eg, RhD incompatibility, glucose-6-phosphate dehydrogenase deficiency), and can exceed the albumin binding capacity. If this happens, the **excess bilirubin** remains **unbound** and can pass beyond the blood-brain barrier. This neurotoxic bilirubin preferentially deposits in the basal ganglia and **brainstem nuclei**.

Initial symptoms of acute BIND occur in the neonatal period and are often subtle (eg, poor feeding) but may include inconsolability, change in tone, and apnea. Patients with prolonged, severe hyperbilirubinemia or delayed/inadequate treatment are at risk for chronic BIND (previously referred to as kernicterus), which typically develops after infancy and is irreversible. Destruction of neurons in the basal ganglia leads to **abnormal movements** (eg, **chorea, dystonia**). Similarly, **upward gaze palsy** and **sensorineural hearing loss** occur due to neuronal destruction in the gray matter of visual and auditory brainstem nuclei, respectively. Developmental delay, as seen in this patient, is also typical.

(Choice B) Abnormalities of the corpus callosum (eg, agenesis, dysgenesis) often cause gross motor delay. However, dystonia and gaze abnormalities would not be expected, and bilirubin deposition does not occur in the corpus callosum.

(Choice C) Damage to the lateral temporal cortex, which is typically spared in BIND, usually affects receptive speech (ie, Wernicke area), and gross motor delays would not be seen.

(Choice D) Thiamine deficiency in adults with Wernicke-Korsakoff syndrome is associated with mammillary body damage that causes memory impairment, not motor dysfunction. BIND is not associated with damage to this area.

(Choice E) Occipital lobe damage, which does not occur in BIND, can lead to cortical blindness but does not explain this patient's abnormal movements and tone.

Educational objective:
Excess unconjugated bilirubin in the neonatal period, often caused by increased hemolysis, can cross the blood-brain barrier and deposit in the basal ganglia and brainstem nuclei. If inadequately treated, this can lead to chronic, irreversible neurologic dysfunction, including abnormal movements (eg, chorea, dystonia) and impaired vision and hearing.

References

https://t.me/USMLEWorldStep1

- Acute encephalopathy: hypertonia, irritability, apnea, seizures
- Chronic encephalopathy: sensorineural hearing loss, choreoathetoid

Clinical features

Exhibit Display

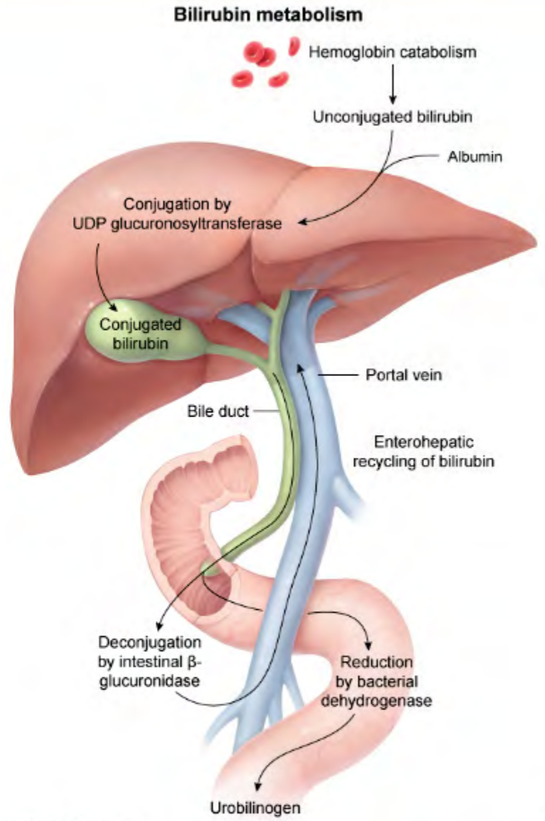

Zoom In | Zoom Out | Reset | New | Existing | My Notebook

This c
concer

Uncon
bound
bilirubi
hemol
album
brain b

Initial s
incons
delaye
develo
mover
neuron
as see

(Choic
Howev
corpus

(Choic
speech

(Choice D) Thiamine deficiency in adults with Wernicke-Korsakoff syndrome is associated with mammillary body damage that causes memory impairment, not motor dysfunction. BIND is not associated with damage to this area.

(Choice E) Occipital lobe damage, which does not occur in BIND, can lead to cortical blindness but does not explain this patient's abnormal movements and tone.

https://t.me/USMLEWorldStep1

Clinical features	• Acute encephalopathy: hypertonia, irritability, apnea, seizures • Chronic encephalopathy: sensorineural hearing loss, choreoathetoid

Exhibit Display

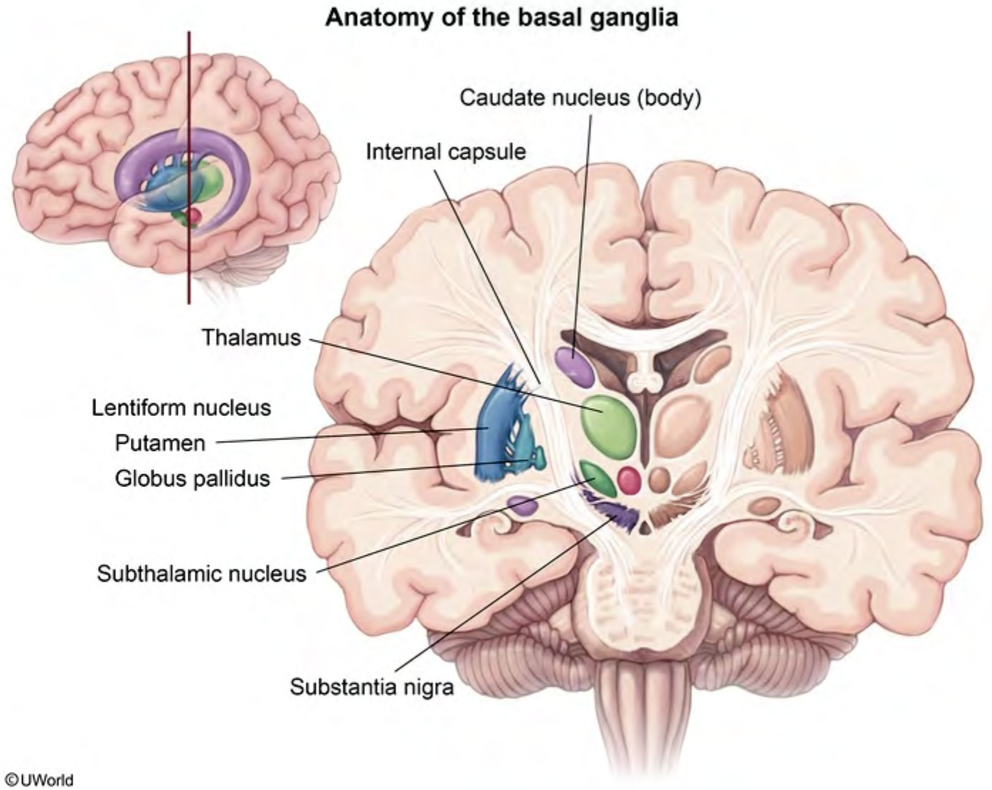

Zoom In | Zoom Out | Reset | New | Existing | My Notebook

This cl
concer

Uncon
bound
bilirubi
hemol
album
brain b

Initial s
incons
delaye
develo
mover
neuron
as see

(Choi
Howev
corpus

(Choi
speech

(Choi
damag

(Choice E) Occipital lobe damage, which does not occur in BIND, can lead to cortical blindness but does not explain this patient's abnormal movements and tone.

https://t.me/USMLEWorldStep1

Clinical features	• Acute encephalopathy: hypertonia, irritability, apnea, seizures • Chronic encephalopathy: sensorineural hearing loss, choreoathetoid

Exhibit Display

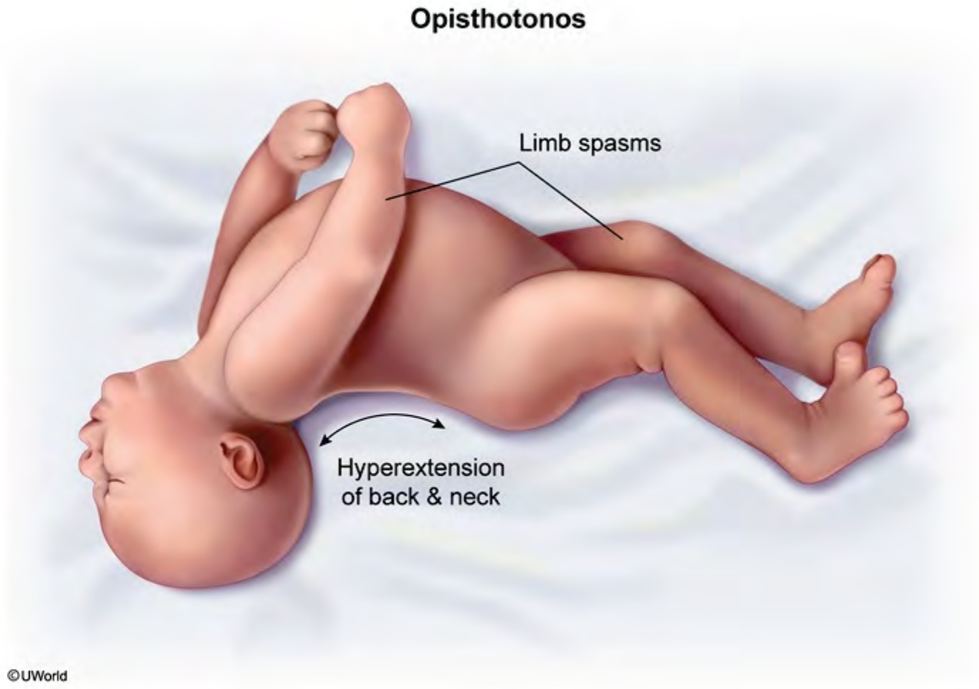

Zoom In | Zoom Out | Reset | New | Existing | My Notebook

This c
concer

Uncon
bound
bilirubi
hemol
album
brain b

Initial s
incons
delaye
develo
mover
neuron
as see

(Choic
Howev
corpus

(Choic
speech

(Choic
damag

(Choice E) Occipital lobe damage, which does not occur in BIND, can lead to cortical blindness but does not explain this patient's abnormal movements and tone.

https://t.me/USMLEWorldStep1

This child with a history of severe neonatal jaundice has dystonic movements and gaze abnormalities, findings concerning for **bilirubin-induced neurologic dysfunction** (BIND).

Uncon
bound
bilirubi
hemol
album
brain b

Initial s
incons
delaye
develo
mover
neuron
as see

(Choi
Howev
corpus

(Choi
speech

(Choi
damag

(Choi
explai

Educa

Excess unconjugated bilirubin in the neonatal period, often caused by increased hemolysis, can cross the blood-brain barrier and deposit in the basal ganglia and brainstem nuclei. If inadequately treated, this can lead to

Exhibit Display

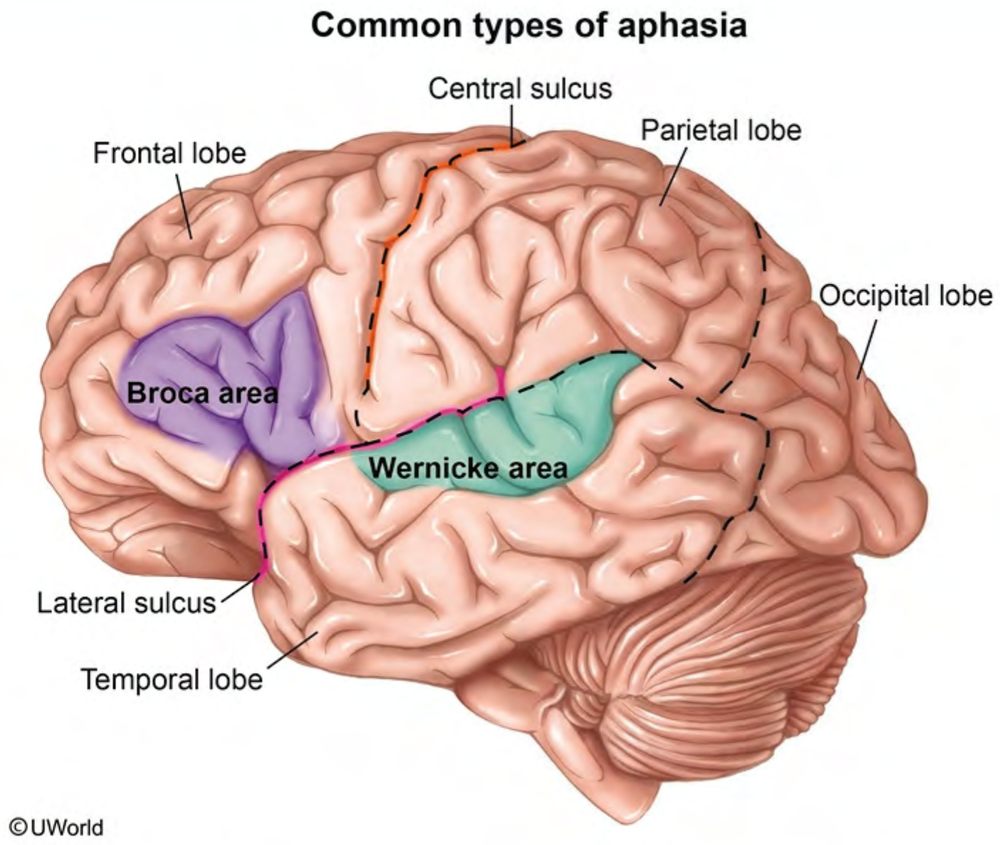

Zoom In | Zoom Out | Reset | New | Existing | My Notebook

https://t.me/USMLEWorldStep1

This child with a history of severe neonatal jaundice has dystonic movements and gaze abnormalities, findings concerning for **bilirubin-induced neurologic dysfunction** (BIND).

Uncon
bound
bilirubi
hemol
album
brain b

Initial s
incons
delaye
develo
mover
neuron
as see

(Choi
Howev
corpus

(Choi
speech

(Choi
damag

(Choi
explai

Educa

Excess unconjugated bilirubin in the neonatal period, often caused by increased hemolysis, can cross the blood-brain barrier and deposit in the basal ganglia and brainstem nuclei. If inadequately treated, this can lead to

Exhibit Display

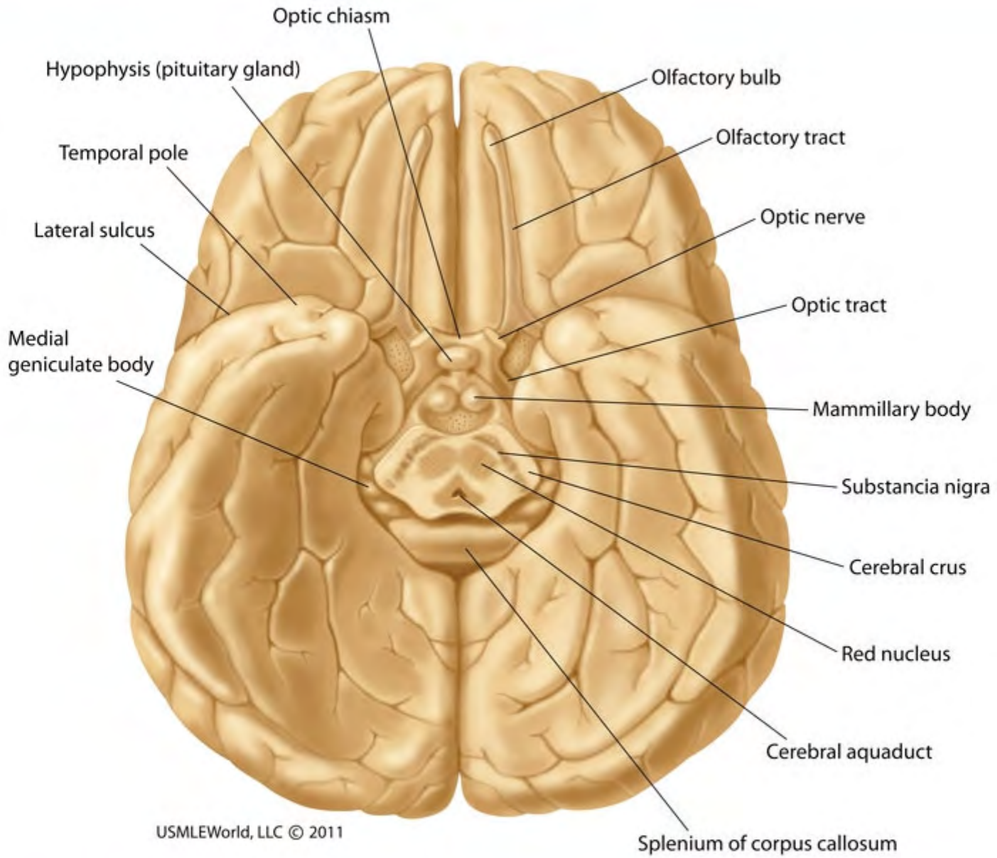

Zoom In | Zoom Out | Reset | New | Existing | My Notebook

https://t.me/USMLEWorldStep1

A 30-year-old man comes to the emergency department with a 4-day history of progressively worsening abdominal pain and bloody diarrhea. He was started on mesalamine therapy 6 months ago after being diagnosed with ulcerative colitis but has been noncompliant with treatment. His temperature is 38.8 C (102 F), blood pressure is 100/70 mm Hg, and pulse is 130/min. The patient is lethargic and has dry mucous membranes. There is marked abdominal distension and tenderness without rebound or guarding. Rectal examination shows guaiac-positive, maroon-colored, liquid stool. Which of the following is the best next step in this patient's workup?

- A. Abdominal ultrasonography
- B. Barium enema
- C. Colonoscopy
- D. Plain abdominal x-ray
- E. Small-bowel contrast study

Submit

https://t.me/USMLEWorldStep1

A 30-year-old man comes to the emergency department with a 4-day history of progressively worsening abdominal pain and bloody diarrhea. He was started on mesalamine therapy 6 months ago after being diagnosed with ulcerative colitis but has been noncompliant with treatment. His temperature is 38.8 C (102 F), blood pressure is 100/70 mm Hg, and pulse is 130/min. The patient is lethargic and has dry mucous membranes. There is marked abdominal distension and tenderness without rebound or guarding. Rectal examination shows guaiac-positive, maroon-colored, liquid stool. Which of the following is the best next step in this patient's workup?

- A. Abdominal ultrasonography (10%)
- ✗ B. Barium enema (8%)
- C. Colonoscopy (42%)
- ✓ D. Plain abdominal x-ray (35%)
- E. Small-bowel contrast study (4%)

Incorrect
Correct answer
D

35%
Answered correctly

03 secs
Time Spent

2023
Version

Explanation

Toxic megacolon

https://t.me/USMLEWorldStep1

A 30-year-old man comes to the emergency department with a 4-day history of progressively worsening abdominal pain a
ulcera
100/7
abdom
maroo

Inco
Corre
D

Expl

Exhibit Display

Toxic megacolon

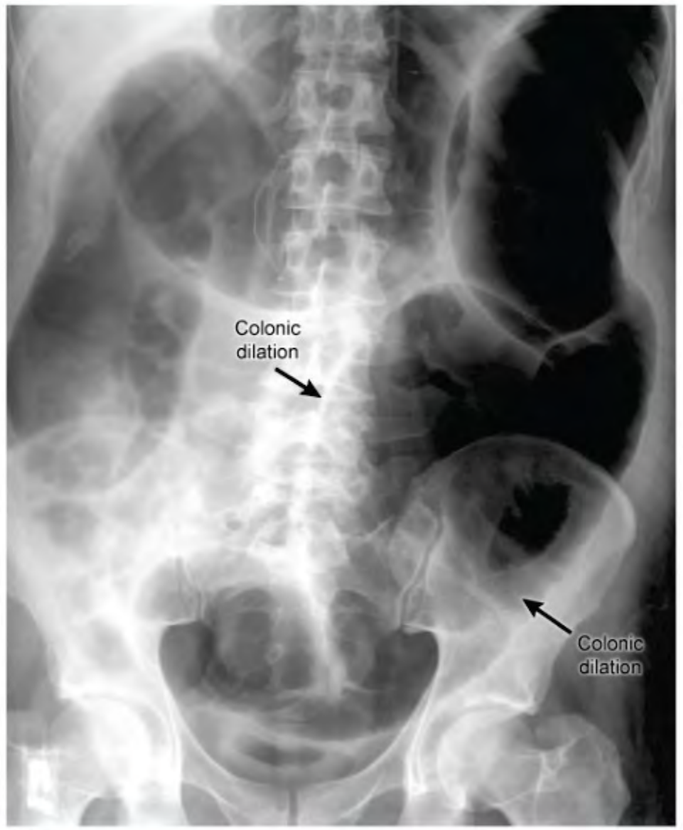

©UWorld

Zoom In | Zoom Out | Reset | New | Existing | My Notebook

https://t.me/USMLEWorldStep1

This patient with abdominal pain/distension, bloody diarrhea, fever, and signs of shock (eg, hypotension, tachycardia) in the setting of untreated ulcerative colitis likely has **toxic megacolon**. This is a common life-threatening complication of inflammatory bowel disease and is seen more frequently in **ulcerative colitis** than in Crohn disease. Toxic megacolon can also be associated with *Clostridium difficile* infection and other forms of infectious colitis.

Severe, occasionally transmural inflammation causes release of inflammatory mediators, bacterial products, and increased nitric oxide, which contribute to colonic smooth muscle paralysis. Rapid colonic distension ensues, thinning the intestinal wall and making it prone to perforation. Plain **abdominal x-ray** is the preferred diagnostic imaging study as it may show **colonic dilation** (as seen above) with multiple air-fluid levels (not seen in this image). Free air may also be visualized in the setting of intestinal rupture, which presents with generalized peritonitis (eg, abdominal rebound tenderness/guarding).

(Choice A) Abdominal ultrasonography is not typically performed to diagnose toxic megacolon. It is usually obtained in patients with acute right upper quadrant abdominal pain (eg, due to cholecystitis, ascending cholangitis) or suspected nephrolithiasis. It is also helpful in the setting of acute abdominal trauma to identify intraperitoneal free fluid.

(Choices B and C) Barium enema and colonoscopy are normally contraindicated in patients with suspected toxic megacolon as these may cause perforation.

(Choice E) Small-bowel contrast studies can be useful in the evaluation of small-bowel obstruction (eg, abdominal pain/distension, nausea, vomiting). However, this patient's history of untreated ulcerative colitis and bloody diarrhea is more consistent with toxic megacolon, which involves the large intestine.

Educational objective:
Toxic megacolon is a well-recognized complication of ulcerative colitis. Patients typically present with abdominal pain/distension, bloody diarrhea, fever, and signs of shock. Plain abdominal x-ray is the preferred diagnostic imaging study. Barium contrast studies and colonoscopy are contraindicated due to the risk of perforation.

References

- Toxic megacolon.

https://t.me/USMLEWorldStep1

A 48-year-old man comes to the emergency department due to 3 days of progressively worsening retrosternal burning chest pain, dysphagia, and odynophagia. His medical problems include hypertension and end-stage renal disease. He underwent cadaveric renal allograft transplantation 8 months ago. The patient's temperature is 38.3 C (101 F), blood pressure is 130/80 mm Hg, and pulse is 94/min. His BMI is 31 kg/m^2. The oral mucosa is pink and moist without ulcerations. Cardiopulmonary examination is normal. The abdomen is soft with mild epigastric tenderness. The patient's leukocyte count is 4,200/mm^3. An esophagogastroduodenoscopy demonstrates linear, shallow ulcerations in the lower esophagus. Which of the following is most likely to be seen on esophageal biopsy?

- A. Enlarged cells with intranuclear inclusions
- B. Metaplastic columnar epithelium
- C. Mucosal tear without acute inflammation
- D. Urease-producing organisms
- E. Yeast with polysaccharide capsule

Submit

https://t.me/USMLEWorldStep1

A 48-year-old man comes to the emergency department due to 3 days of progressively worsening retrosternal burning chest pain, dysphagia, and odynophagia. His medical problems include hypertension and end-stage renal disease. He underwent cadaveric renal allograft transplantation 8 months ago. The patient's temperature is 38.3 C (101 F), blood pressure is 130/80 mm Hg, and pulse is 94/min. His BMI is 31 kg/m^2. The oral mucosa is pink and moist without ulcerations. Cardiopulmonary examination is normal. The abdomen is soft with mild epigastric tenderness. The patient's leukocyte count is 4,200/mm^3. An esophagogastroduodenoscopy demonstrates linear, shallow ulcerations in the lower esophagus. Which of the following is most likely to be seen on esophageal biopsy?

- ✓ A. Enlarged cells with intranuclear inclusions (74%)
- ✗ B. Metaplastic columnar epithelium (9%)
- C. Mucosal tear without acute inflammation (8%)
- D. Urease-producing organisms (3%)
- E. Yeast with polysaccharide capsule (3%)

Incorrect
Correct answer
A

74%
Answered correctly

04 secs
Time Spent

2023
Version

Explanation

This patient's presentation suggests **cytomegalovirus (CMV) esophagitis**, which can occur in immunocompromised patients (eg, HIV, transplant, on immunosuppressant drugs). CMV can be transmitted to **transplant recipients** from the donor organ, or infection can occur subsequently due to chronic immunosuppression. Patients can be asymptomatic or develop a viral prodrome (eg, fever, malaise, myalgias) before organ involvement (eg, esophagitis, pneumonitis, colitis).

CMV esophagitis usually presents with **odynophagia** (pain with swallowing) or **dysphagia** (difficulty swallowing)

https://t.me/USMLEWorldStep1

Explanation

This patient's presentation suggests **cytomegalovirus (CMV) esophagitis**, which can occur in immunocompromised patients (eg, HIV, transplant, on immunosuppressant drugs). CMV can be transmitted to **transplant recipients** from the donor organ, or infection can occur subsequently due to chronic immunosuppression. Patients can be asymptomatic or develop a viral prodrome (eg, fever, malaise, myalgias) before organ involvement (eg, esophagitis, pneumonitis, colitis).

CMV esophagitis usually presents with **odynophagia** (pain with swallowing) or **dysphagia** (difficulty swallowing) that can be accompanied by fever or burning chest pain. Endoscopy typically shows **linear and shallow ulcerations** in the lower esophagus that sometimes diffusely involve the esophagus. Tissue biopsy usually shows enlarged cells with basophilic or eosinophilic **intranuclear inclusion bodies**.

(Choice B) Metaplastic columnar epithelium is seen in Barrett esophagus, which is usually due to prolonged gastroesophageal reflux disease (GERD). Histology typically shows tongue-like projections of columnar epithelium with goblet cells (ie, intestinal metaplasia) extending from the distal esophagus to the gastroesophageal junction. The absence of chronic GERD symptoms in this patient makes this less likely.

(Choice C) A Mallory-Weiss tear typically presents with hematemesis in association with chest or epigastric pain after repeated retching or vomiting; histology will show a mucosal tear without acute inflammation.

(Choice D) *Helicobacter pylori* is a urease-producing organism that can be associated with gastritis and gastric or duodenal ulcers. It usually does not cause significant esophageal disease.

(Choice E) *Cryptococcus neoformans* is a yeast with a polysaccharide capsule. Although disseminated cryptococcosis can occur in immunocompromised patients and involve almost any organ, localized esophageal involvement is more characteristic of *Candida* (a yeast without a polysaccharide capsule).

Educational objective:
Cytomegalovirus esophagitis can occur in transplant patients and usually presents with odynophagia or dysphagia that can be accompanied by fever or burning chest pain. Endoscopy typically shows linear and shallow ulcerations in the lower esophagus, and histology usually shows enlarged cells with intranuclear inclusions.

https://t.me/USMLEWorldStep1

Explanation

Exhibit Display

Cytomegalovirus

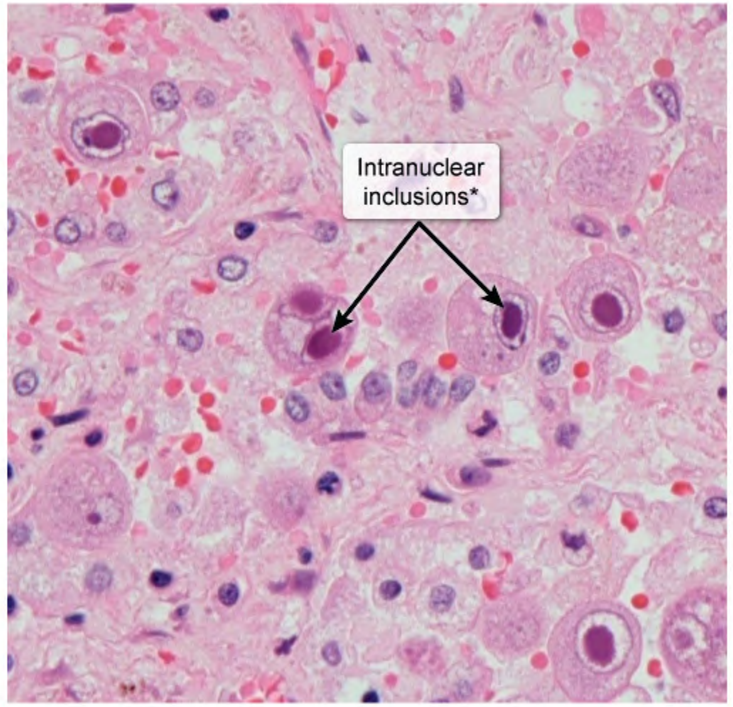

*"Owl's eye" appearance

©UWorld

Zoom In | Zoom Out | Reset | New | Existing | My Notebook

This p
immun
transp
immun
before

CMV e
that ca
ulcera
enlarg

(Choi
gastro
with g
The ab

(Choi
after re

(Choi
duode

(Choi
crypto
involve

Educa
Cytom
that ca
in the lower esophagus, and histology usually shows enlarged cells with intranuclear inclusions.

https://t.me/USMLEWorldStep1

Explanation

Exhibit Display

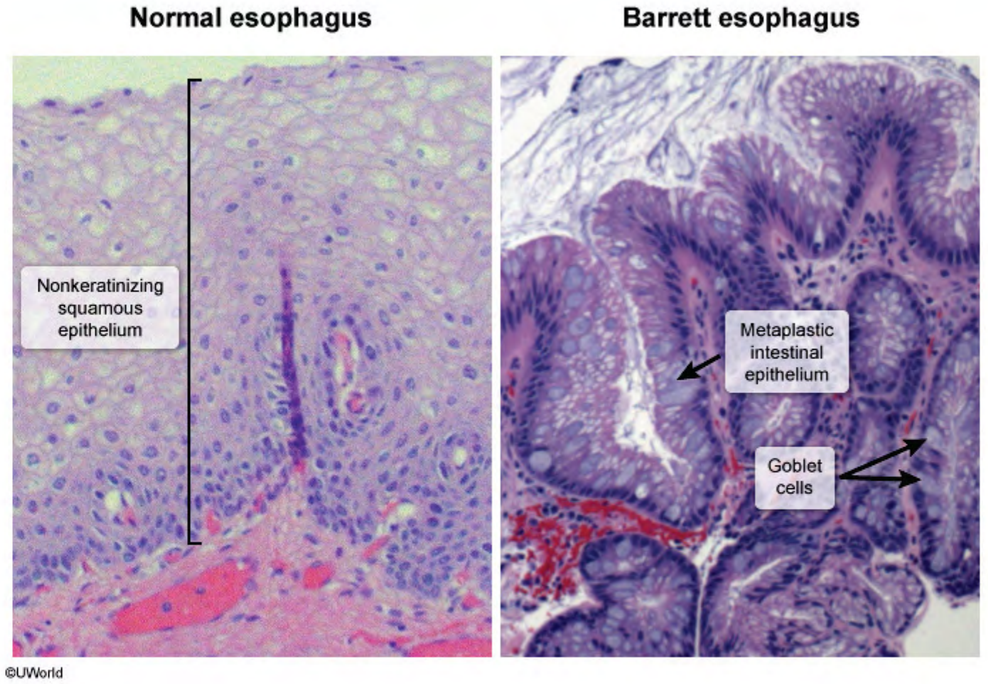

Zoom In | Zoom Out | Reset | New | Existing | My Notebook

This p
immun
transp
immun
before

CMV e
that ca
ulcera
enlarg

(Choi
gastro
with g
The ab

(Choi
after re

(Choi
duode

(Choi
crypto
involve

Educa

Cytomegalovirus esophagitis can occur in transplant patients and usually presents with odynophagia or dysphagia that can be accompanied by fever or burning chest pain. Endoscopy typically shows linear and shallow ulcerations in the lower esophagus, and histology usually shows enlarged cells with intranuclear inclusions.

https://t.me/USMLEWorldStep1

Explanation

Exhibit Display

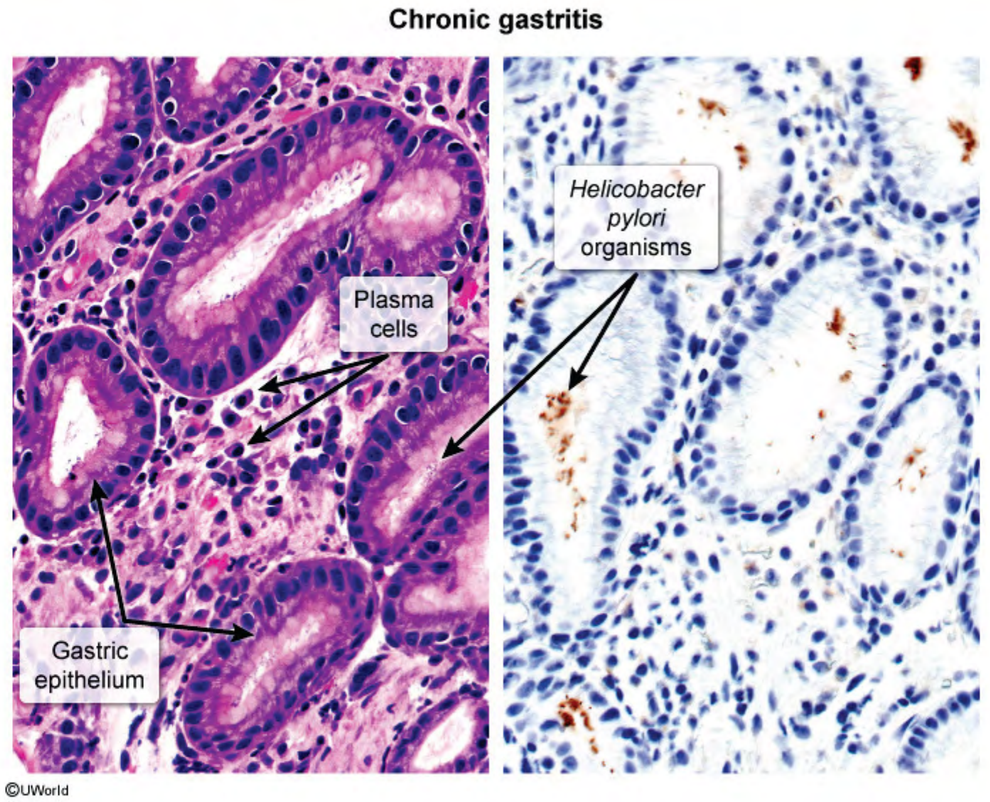

Zoom In | Zoom Out | Reset | New | Existing | My Notebook

This p
immun
transp
immun
before

CMV e
that ca
ulcera
enlarg

(Choi
gastro
with g
The ab

(Choi
after re

(Choi
duode

(Choi
crypto
involve

Educa

Cytomegalovirus esophagitis can occur in transplant patients and usually presents with odynophagia or dysphagia that can be accompanied by fever or burning chest pain. Endoscopy typically shows linear and shallow ulcerations in the lower esophagus, and histology usually shows enlarged cells with intranuclear inclusions.

https://t.me/USMLEWorldStep1

Explanation

Exhibit Display

Cryptococcus

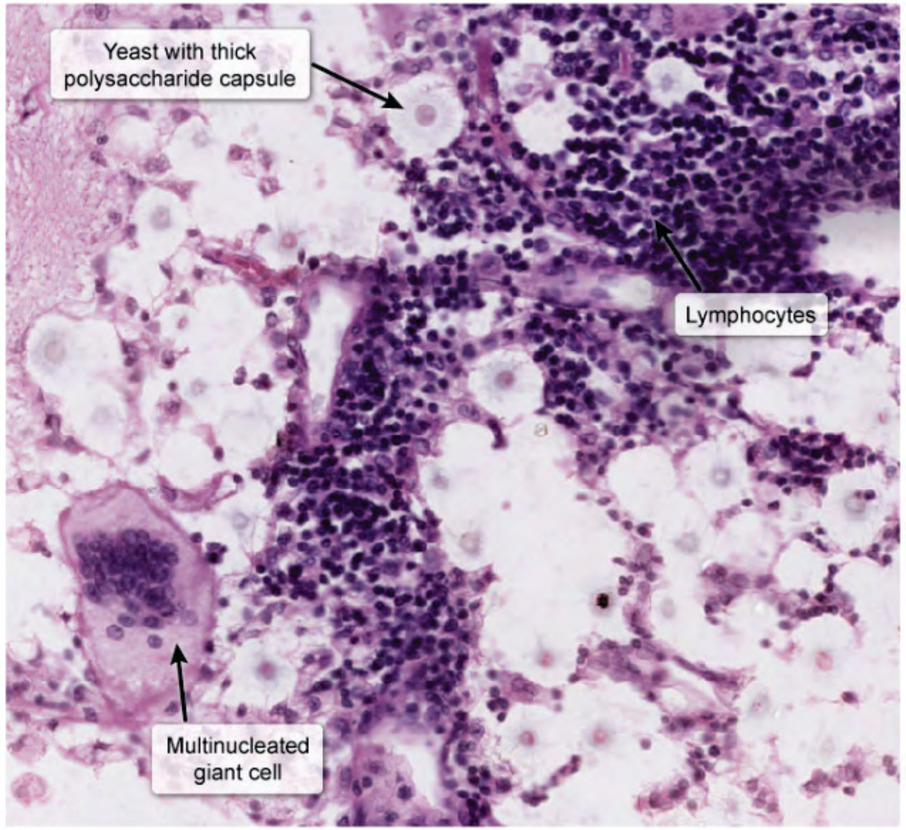

Zoom In | Zoom Out | Reset | New | Existing | My Notebook

This p
immun
transp
immun
before

CMV e
that ca
ulcera
enlarg

(Choi
gastro
with g
The ab

(Choi
after re

(Choi
duode

(Choi
crypto
involve

Educa
Cytom
that ca
in the lower esophagus, and histology usually shows enlarged cells with intranuclear inclusions.

https://t.me/USMLEWorldStep1

A 45-year-old woman comes to the office due to a 6-month history of abdominal bloating, excessive flatulence, and watery diarrhea. Past medical history is significant for long-standing type 1 diabetes mellitus managed with insulin. Vital signs are normal. Abdominal examination shows no abnormalities. Jejunal aspirate is obtained during upper gastrointestinal endoscopy by placing a sterile catheter; culture of the aspirate reveals >10,000 colony-forming units/mL of *Bacteroides* species. Which of the following is the most likely cause of this patient's current symptoms?

- A. Excessive bile acid synthesis
- B. Excessive gastric acid production
- C. Excessive pancreatic proteolytic enzyme secretion
- D. Impaired migrating motor complex function
- E. Spasm of the ileocecal valve

Submit

https://t.me/USMLEWorldStep1

A 45-year-old woman comes to the office due to a 6-month history of abdominal bloating, excessive flatulence, and watery diarrhea. Past medical history is significant for long-standing type 1 diabetes mellitus managed with insulin. Vital signs are normal. Abdominal examination shows no abnormalities. Jejunal aspirate is obtained during upper gastrointestinal endoscopy by placing a sterile catheter; culture of the aspirate reveals >10,000 colony-forming units/mL of *Bacteroides* species. Which of the following is the most likely cause of this patient's current symptoms?

- A. Excessive bile acid synthesis (9%)
- ✗ B. Excessive gastric acid production (6%)
- C. Excessive pancreatic proteolytic enzyme secretion (18%)
- ✓ D. Impaired migrating motor complex function (54%)
- E. Spasm of the ileocecal valve (11%)

Incorrect
Correct answer
D

54%
Answered correctly

03 secs
Time Spent

2023
Version

Explanation

Small intestinal bacterial overgrowth	
Protective mechanisms	**Pathophysiologic predispositions**
Gastric acid, pancreaticobiliary secretions • Direct antimicrobial effects • Detergent effects (bile acids)	• Proton pump inhibitor use • Achlorhydria (eg, atrophic gastritis) • Decreased secretion of proteolytic enzyme (eg, chronic pancreatitis)
Intestinal motility	• Opioids

https://t.me/USMLEWorldStep1

Small intestinal bacterial overgrowth	
Protective mechanisms	**Pathophysiologic predispositions**
Gastric acid, pancreaticobiliary secretions • Direct antimicrobial effects • Detergent effects (bile acids)	• Proton pump inhibitor use • Achlorhydria (eg, atrophic gastritis) • Decreased secretion of proteolytic enzyme (eg, chronic pancreatitis)
Intestinal motility • Movement of pathogens out of small bowel	• Opioids • Diabetes mellitus • Scleroderma
Intact ileocecal valve • Prevention of reflux of colonic flora	• Ileocecal resection
Mucosal immune response • Intestinal secretion of immunoglobulins	• IgA deficiency • Combined variable immunodeficiency • HIV

This patient has **small intestinal bacterial overgrowth** (SIBO), which presents with excessive intestinal gas (ie, bloating, flatulence) and diarrhea. Diagnosis is sometimes confirmed by quantitative culture of jejunal fluid; normal small intestine bacterial load is <1,000 colony-forming unit/mL. SIBO is caused by excessive bacterial proliferation in the small intestine, resulting in mucosal injury and fermentation of dietary carbohydrates.

In normal individuals, **migrating motor complexes** cause intestinal peristalsis, which clears bacteria and reduces the reflux of colonic organisms into the small bowel. Patients with **impaired gut motility** (eg, long-standing **diabetes mellitus** with autonomic neuropathy) are at increased risk for SIBO, as are patients with anatomic (eg, bowel adhesions, intestinal blind loops from surgery) or fibrotic (eg, scleroderma, prior radiotherapy) disruptions of intestinal flow.

Other patient factors contributing to SIBO include the following:

- Pancreatobiliary dysfunction: Bile acids have a detergent effect that disrupts bacterial membranes and

https://t.me/USMLEWorldStep1

Mucosal immune response • Intestinal secretion of immunoglobulins	• IgA deficiency • Combined variable immunodeficiency • HIV

This patient has **small intestinal bacterial overgrowth** (SIBO), which presents with excessive intestinal gas (ie, bloating, flatulence) and diarrhea. Diagnosis is sometimes confirmed by quantitative culture of jejunal fluid; normal small intestine bacterial load is <1,000 colony-forming unit/mL. SIBO is caused by excessive bacterial proliferation in the small intestine, resulting in mucosal injury and fermentation of dietary carbohydrates.

In normal individuals, **migrating motor complexes** cause intestinal peristalsis, which clears bacteria and reduces the reflux of colonic organisms into the small bowel. Patients with **impaired gut motility** (eg, long-standing **diabetes mellitus** with autonomic neuropathy) are at increased risk for SIBO, as are patients with anatomic (eg, bowel adhesions, intestinal blind loops from surgery) or fibrotic (eg, scleroderma, prior radiotherapy) disruptions of intestinal flow.

Other patient factors contributing to SIBO include the following:

- Pancreatobiliary dysfunction: Bile acids have a detergent effect that disrupts bacterial membranes and increases exposure of organisms in ingested food particles to residual acid and proteolytic enzymes, which further deter growth. Lack of these protective factors (eg, chronic pancreatitis) increases the risk for SIBO **(Choices A and C)**.
- Reduced gastric acid: Residual gastric acid impairs bacterial growth in the proximal small bowel. Achlorhydria from either atrophic gastritis or chronic proton pump inhibitor therapy predisposes to SIBO **(Choice B)**.
- Blind gut loops/pouches: Blind-ended gut segments (eg, Roux-en-Y gastric bypass surgery) provide a protected environment for bacterial proliferation.
- Impaired enteric immunity: Secretory IgA and innate inflammatory mechanisms inhibit bacterial growth in the small bowel. Immunodeficiency states increase the risk for SIBO.

(Choice E) The ileocecal valve prevents the reflux of colonic flora into the small intestine; mechanical disruption (eg, surgical resection) or functional incompetence can increase the risk for SIBO. Spasm of the valve would not

https://t.me/USMLEWorldStep1

diabetes mellitus with autonomic neuropathy) are at increased risk for SIBO, as are patients with anatomic (eg, bowel adhesions, intestinal blind loops from surgery) or fibrotic (eg, scleroderma, prior radiotherapy) disruptions of intestinal flow.

Other patient factors contributing to SIBO include the following:

- Pancreatobiliary dysfunction: Bile acids have a detergent effect that disrupts bacterial membranes and increases exposure of organisms in ingested food particles to residual acid and proteolytic enzymes, which further deter growth. Lack of these protective factors (eg, chronic pancreatitis) increases the risk for SIBO **(Choices A and C)**.
- Reduced gastric acid: Residual gastric acid impairs bacterial growth in the proximal small bowel. Achlorhydria from either atrophic gastritis or chronic proton pump inhibitor therapy predisposes to SIBO **(Choice B)**.
- Blind gut loops/pouches: Blind-ended gut segments (eg, Roux-en-Y gastric bypass surgery) provide a protected environment for bacterial proliferation.
- Impaired enteric immunity: Secretory IgA and innate inflammatory mechanisms inhibit bacterial growth in the small bowel. Immunodeficiency states increase the risk for SIBO.

(Choice E) The ileocecal valve prevents the reflux of colonic flora into the small intestine; mechanical disruption (eg, surgical resection) or functional incompetence can increase the risk for SIBO. Spasm of the valve would not increase SIBO risk.

Educational objective:
Small intestinal bacterial overgrowth is caused by bacterial proliferation in the small intestine. In normal individuals, intestinal peristalsis clears bacteria and reduces the reflux of colonic organisms into the small bowel; however, patients with impaired gut motility have an increased risk for bacterial overgrowth.

References

- Small intestinal bacterial overgrowth: a primary care review.

Physiology Gastrointestinal & Nutrition Small intestinal bacterial overgrowth

https://t.me/USMLEWorldStep1

A 4-day-old newborn is brought to the office for a 2-day history of progressive jaundice. He was born at term following an uncomplicated vaginal delivery. The patient has been breastfed since birth. Vital signs are normal. Examination shows scleral icterus and jaundice from the face to the upper abdomen. Laboratory results are as follows:

Complete blood count	
Hematocrit	52%
Reticulocytes	1%
Liver function studies	
Total bilirubin	10.3 mg/dL
Direct bilirubin	0.3 mg/dL
Aspartate aminotransferase (SGOT)	18 U/L
Alanine aminotransferase (SGPT)	24 U/L

Which of the following is the most likely explanation for these findings?

- A. $CD8^+$ T-lymphocyte–mediated hepatocellular injury
- B. Decreased beta-glucuronidase activity
- C. Deficiency of erythrocyte glucose-6-phosphate dehydrogenase
- D. Decreased UDP glucuronosyltransferase activity
- E. Fibrous obliteration of the extrahepatic biliary tree

Submit

https://t.me/USMLEWorldStep1

A 4-day-old newborn is brought to the office for a 2-day history of progressive jaundice. He was born at term following an uncomplicated vaginal delivery. The patient has been breastfed since birth. Vital signs are normal. Examination shows scleral icterus and jaundice from the face to the upper abdomen. Laboratory results are as follows:

Complete blood count	
Hematocrit	52%
Reticulocytes	1%
Liver function studies	
Total bilirubin	10.3 mg/dL
Direct bilirubin	0.3 mg/dL
Aspartate aminotransferase (SGOT)	18 U/L
Alanine aminotransferase (SGPT)	24 U/L

Which of the following is the most likely explanation for these findings?

- A. $CD8^+$ T-lymphocyte–mediated hepatocellular injury (0%)
- ✗ B. Decreased beta-glucuronidase activity (10%)
- C. Deficiency of erythrocyte glucose-6-phosphate dehydrogenase (4%)
- ✓ D. Decreased UDP glucuronosyltransferase activity (82%)
- E. Fibrous obliteration of the extrahepatic biliary tree (2%)

Incorrect
Correct answer
D

82%
Answered correctly

04 secs
Time Spent

2023
Version

https://t.me/USMLEWorldStep1

Exhibit Display

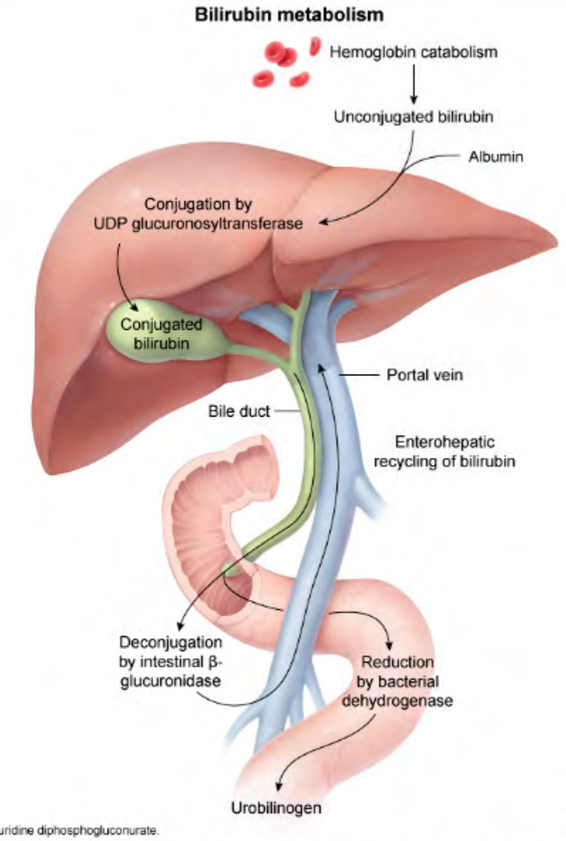

Zoom In | Zoom Out | Reset | New | Existing | My Notebook

Enterohepatic
recycling of bilirubin

https://t.me/USMLEWorldStep1

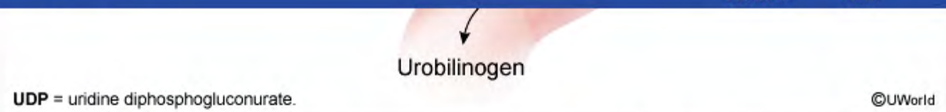

UDP = uridine diphosphogluconurate.

©UWorld

This neonate most likely has **benign neonatal hyperbilirubinemia**, a **physiologic** condition characterized by an **elevated indirect bilirubin** level that peaks at **age 2-5 days**.

The pathophysiology of benign neonatal hyperbilirubinemia includes the following:

- ↑ **Bilirubin production:** Fetal red blood cells (RBCs) are increased in number and have a shorter life span compared to RBCs in children and adults. Physiologic breakdown of these RBCs causes excess production of indirect bilirubin.
- ↓ **Bilirubin clearance:** Physiologically **decreased** levels of hepatic uridine diphosphogluconurate **(UDP) glucuronosyltransferase** in newborns results in decreased bilirubin conjugation and excretion into the bile.
- ↑ **Enterohepatic circulation:** Normally, bilirubin in the intestines is reduced by bacterial enzymes to allow for excretion through urine and stool. In the newborn, lack of bacterial enzymes due to relative gut sterility results in an increased bilirubin concentration remaining in the intestines. This excess bilirubin is deconjugated by intestinal beta-glucuronidase and then reabsorbed via the enterohepatic circulation **(Choice B)**.

Benign neonatal hyperbilirubinemia is typically asymptomatic except for scleral icterus and jaundice. The resolution of benign neonatal hyperbilirubinemia is expected by age 1-2 weeks as UDP glucuronosyltransferase activity and gut bacteria increase, allowing increased bilirubin clearance and excretion.

(Choice A) Viral hepatitis (eg, hepatitis B or C) results in $CD8^+$ T-lymphocyte–mediated hepatocellular injury and jaundice. However, vertical transmission of hepatitis viruses does not cause symptoms in the neonatal period. Moreover, once the patient is symptomatic, transaminases would be elevated.

(Choice C) Glucose-6-phosphate dehydrogenase deficiency can present with jaundice and indirect hyperbilirubinemia in the early neonatal period. However, because hemolysis contributes to the pathophysiology of jaundice in this condition, the hematocrit would be decreased and the reticulocyte count would be elevated.

(Choice E) Biliary atresia is characterized by fibrous obliteration of the extrahepatic biliary tree and typically presents with jaundice in the first 2 months of life. However, direct bilirubin is elevated due to biliary tract

https://t.me/USMLEWorldStep1

- ↑ **Bilirubin production:** Fetal red blood cells (RBCs) are increased in number and have a shorter life span compared to RBCs in children and adults. Physiologic breakdown of these RBCs causes excess production of indirect bilirubin.
- ↓ **Bilirubin clearance:** Physiologically **decreased** levels of hepatic uridine diphosphogluconurate **(UDP) glucuronosyltransferase** in newborns results in decreased bilirubin conjugation and excretion into the bile.
- ↑ **Enterohepatic circulation:** Normally, bilirubin in the intestines is reduced by bacterial enzymes to allow for excretion through urine and stool. In the newborn, lack of bacterial enzymes due to relative gut sterility results in an increased bilirubin concentration remaining in the intestines. This excess bilirubin is deconjugated by intestinal beta-glucuronidase and then reabsorbed via the enterohepatic circulation **(Choice B)**.

Benign neonatal hyperbilirubinemia is typically asymptomatic except for scleral icterus and jaundice. The resolution of benign neonatal hyperbilirubinemia is expected by age 1-2 weeks as UDP glucuronosyltransferase activity and gut bacteria increase, allowing increased bilirubin clearance and excretion.

(Choice A) Viral hepatitis (eg, hepatitis B or C) results in $CD8^+$ T-lymphocyte–mediated hepatocellular injury and jaundice. However, vertical transmission of hepatitis viruses does not cause symptoms in the neonatal period. Moreover, once the patient is symptomatic, transaminases would be elevated.

(Choice C) Glucose-6-phosphate dehydrogenase deficiency can present with jaundice and indirect hyperbilirubinemia in the early neonatal period. However, because hemolysis contributes to the pathophysiology of jaundice in this condition, the hematocrit would be decreased and the reticulocyte count would be elevated.

(Choice E) Biliary atresia is characterized by fibrous obliteration of the extrahepatic biliary tree and typically presents with jaundice in the first 2 months of life. However, direct bilirubin is elevated due to biliary tract obstruction. In addition, patients often have acholic stools and dark urine.

Educational objective:
Benign neonatal hyperbilirubinemia presents with jaundice and elevated indirect bilirubin levels that peak at age 2-5 days. Pathophysiology includes impaired bilirubin clearance by the liver due to decreased hepatic UDP glucuronosyltransferase, an enzyme responsible for bilirubin conjugation.

References

https://t.me/USMLEWorldStep1

This neonate most likely has **benign neonatal hyperbilirubinemia**, a **physiologic** condition characterized by an **elevated indirect bilirubin** level that peaks at **age 2-5 days**.

The pa

- ↑ c o
- ↓ g
- ↑ e in in

Benign resolu activity

(Choi jaundi Moreo

(Choi hyperb jaundi

(Choi preser obstru

Educational objective:
Benign neonatal hyperbilirubinemia presents with jaundice and elevated indirect bilirubin levels that peak at age 2-

Exhibit Display

Neonatal jaundice

Yellow discoloration of the skin (due to bilirubin deposition)

©UWorld

Zoom In | Zoom Out | Reset | New | Existing | My Notebook

https://t.me/USMLEWorldStep1

This neonate most likely has **benign neonatal hyperbilirubinemia**, a **physiologic** condition characterized by an **elevated indirect bilirubin** level that peaks at **age 2-5 days**.

The pa

- ↑ c o
- ↓ g
- ↑ e in in

Benign resolu activity

(Choi jaundi Moreo

(Choi hyperb jaundi

(Choi preser obstru

Educational objective:

Benign neonatal hyperbilirubinemia presents with jaundice and elevated indirect bilirubin levels that peak at age 2-

Exhibit Display

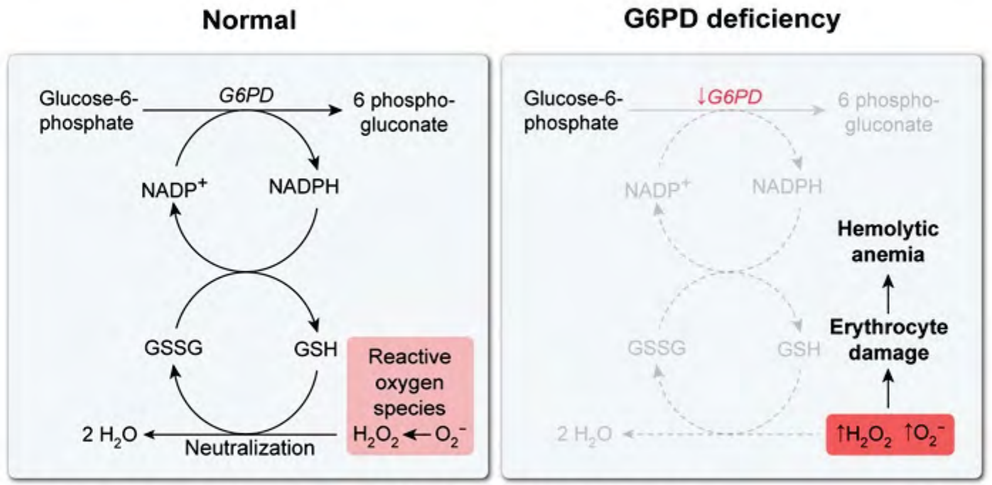

G6PD = glucose-6-phosphate dehydrogenase; **GSH** = glutathione; **GSSG** = glutathione disulfide. ©UWorld

Zoom In | Zoom Out | Reset | New | Existing | My Notebook

https://t.me/USMLEWorldStep1

This neonate most likely has **benign neonatal hyperbilirubinemia**, a **physiologic** condition characterized by an **elevated indirect bilirubin** level that peaks at **age 2-5 days**.

The pa

- ↑ c o
- ↓ g
- ↑ e in in

Benign resolu activity

(Choi jaundi Moreo

(Choi hyperb jaundi

(Choi preser obstru

Educational objective:

Benign neonatal hyperbilirubinemia presents with jaundice and elevated indirect bilirubin levels that peak at age 2-

Exhibit Display

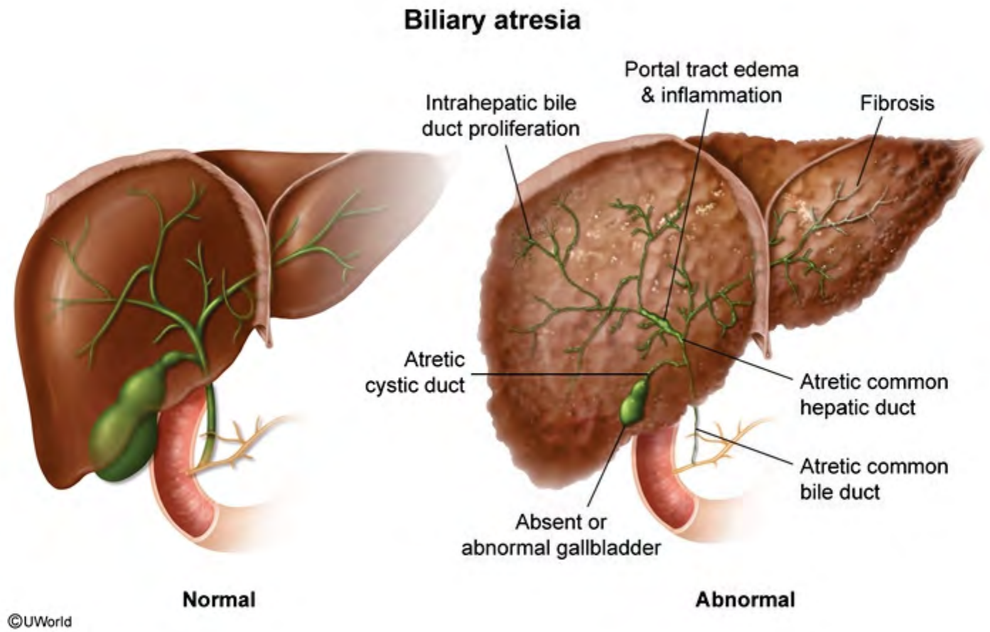

Zoom In | Zoom Out | Reset | New | Existing | My Notebook

https://t.me/USMLEWorldStep1

Rats exposed to high concentrations of carbon tetrachloride suffer rapid and extensive liver damage. Light microscopic examination of affected liver specimens shows fatty change and hepatocyte necrosis. These changes are the result of:

- A. Hypoperfusion
- B. Hypoxia
- C. Abnormal signal transduction
- D. Free radical injury
- E. Mitochondrial dysfunction

Submit

https://t.me/USMLEWorldStep1

Rats exposed to high concentrations of carbon tetrachloride suffer rapid and extensive liver damage. Light microscopic examination of affected liver specimens shows fatty change and hepatocyte necrosis. These changes are the result of:

- A. Hypoperfusion (1%)
- ✗ B. Hypoxia (3%)
- C. Abnormal signal transduction (2%)
- ✓ D. Free radical injury (73%)
- E. Mitochondrial dysfunction (19%)

Incorrect
Correct answer
D

73%
Answered correctly

04 secs
Time Spent

2023
Version

Explanation

Carbon tetrachloride (CCl_4) causes free radical injury. Like many other toxic substances, CCl_4 is oxidized by the P450 oxidase system in the liver. The result is the formation of the free radical CCl_3, which reacts with structural lipids of cell membranes. The result is lipid degradation and hydrogen peroxide (H_2O_2) formation. This process is called **lipid peroxidation**. The peroxides go on to form new radicals, continuing the vicious circle of lipid degradation. Carbon tetrachloride cell injury develops rapidly and leads to swelling of the endoplasmic reticulum, destruction of mitochondria, and increased permeability of cell membranes. These processes culminate in hepatocyte necrosis.

(Choices A and B) Hypoperfusion and hypoxia lead to tissue ischemia and necrosis. Carbon tetrachloride does not affect tissue oxygenation.

(Choice C) Abnormal signal transduction is a mechanism of oncogenesis, as occurs with mutations of the *Ras* proto-oncogene. This mutation increases cell sensitivity to mitogenic influences.

https://t.me/USMLEWorldStep1

D. Free radical injury (73%)

E. Mitochondrial dysfunction (19%)

Incorrect
Correct answer
D

73%
Answered correctly

04 secs
Time Spent

2023
Version

Explanation

Carbon tetrachloride (CCl_4) causes free radical injury. Like many other toxic substances, CCl_4 is oxidized by the P450 oxidase system in the liver. The result is the formation of the free radical CCl_3, which reacts with structural lipids of cell membranes. The result is lipid degradation and hydrogen peroxide (H_2O_2) formation. This process is called **lipid peroxidation**. The peroxides go on to form new radicals, continuing the vicious circle of lipid degradation. Carbon tetrachloride cell injury develops rapidly and leads to swelling of the endoplasmic reticulum, destruction of mitochondria, and increased permeability of cell membranes. These processes culminate in hepatocyte necrosis.

(Choices A and B) Hypoperfusion and hypoxia lead to tissue ischemia and necrosis. Carbon tetrachloride does not affect tissue oxygenation.

(Choice C) Abnormal signal transduction is a mechanism of oncogenesis, as occurs with mutations of the *Ras* proto-oncogene. This mutation increases cell sensitivity to mitogenic influences.

(Choice E) Mitochondrial dysfunction occurs in CCl_4 intoxication as a result of free radical injury.

Educational Objective:
The P450 microsomal oxidase system plays an important role in detoxification. In carbon tetrachloride poisoning, however, it produces free radicals that start a vicious cycle of hepatic injury.

Pathology	Gastrointestinal & Nutrition	Acute liver failure
Subject	System	Topic

Copyright © UWorld. All rights reserved.

https://t.me/USMLEWorldStep1

A 65-year-old man with a history of chronic gastroesophageal reflux comes to the clinic due to dysphagia. The patient has had difficulty swallowing foods such as steak or hard-boiled eggs but is able to drink hot tea and coffee without any issues. Increasing the frequency of his proton pump inhibitor to twice daily did not improve symptoms. He has also lost 6.8 kg (15 lb) over the past 4 months. The patient has a history of hypertension, hyperlipidemia, and osteoarthritis. Medications include amlodipine, atorvastatin, and ibuprofen as needed. He drinks 2 or 3 glasses of wine with dinner most nights but does not use tobacco or illicit drugs. Vital signs are within normal limits. BMI is 32 kg/m^2. Physical examination is unremarkable. Esophagogastroduodenoscopy reveals a 4-cm mass surrounded by a large segment of discolored mucosa in the lower half of the esophagus. Esophagogastrectomy results are shown in the image below:

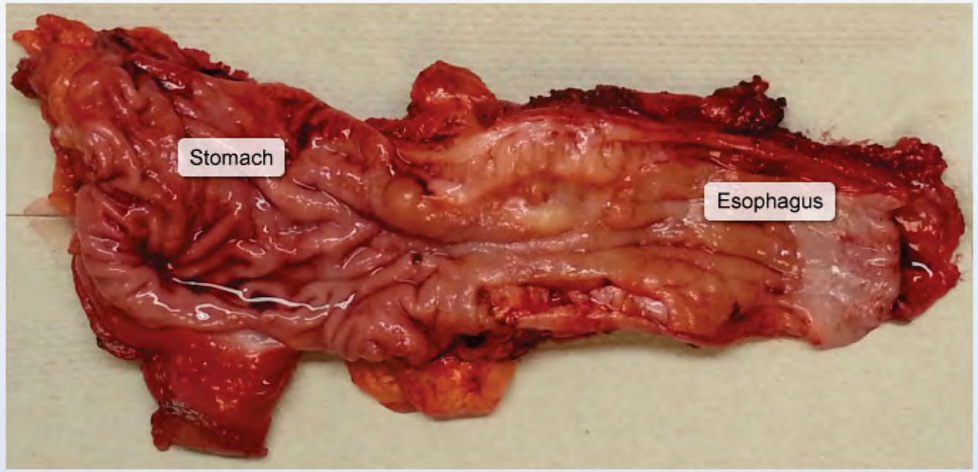

Which of the following is the most likely predisposing factor for this patient's esophageal disease?

- A. Alcohol use
- B. Chronic nonsteroidal anti-inflammatory drug use
- C. *Helicobacter pylori* infection
- D. Obesity

https://t.me/USMLEWorldStep1

He has also lost 6.8 kg (15 lb) over the past 4 months. The patient has a history of hypertension, hyperlipidemia, and osteoarthritis. Medications include amlodipine, atorvastatin, and ibuprofen as needed. He drinks 2 or 3 glasses of wine with dinner most nights but does not use tobacco or illicit drugs. Vital signs are within normal limits. BMI is 32 kg/m^2. Physical examination is unremarkable. Esophagogastroduodenoscopy reveals a 4-cm mass surrounded by a large segment of discolored mucosa in the lower half of the esophagus. Esophagogastrectomy results are shown in the image below:

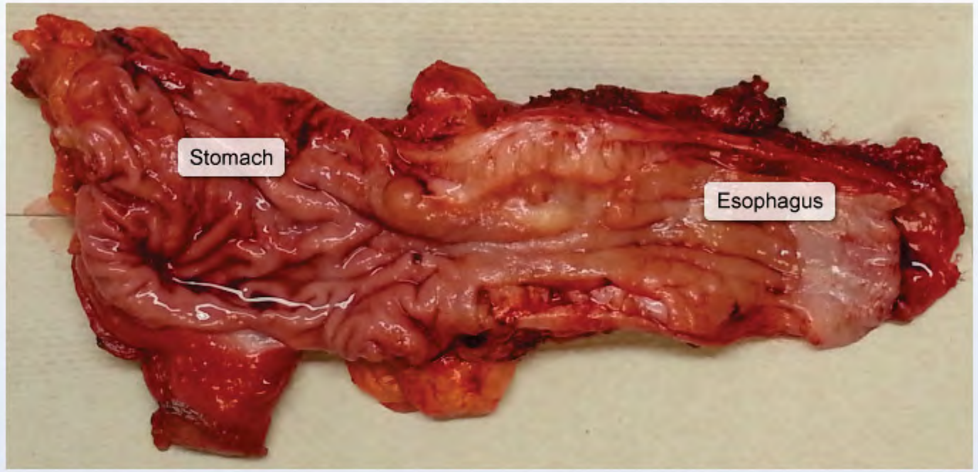

Which of the following is the most likely predisposing factor for this patient's esophageal disease?

- A. Alcohol use
- B. Chronic nonsteroidal anti-inflammatory drug use
- C. *Helicobacter pylori* infection
- D. Obesity
- E. Repeated thermal injury

Submit

https://t.me/USMLEWorldStep1

He has also lost 6.8 kg (15 lb) over the past 4 months. The patient has a history of hypertension, hyperlipidemia, and osteoarthritis. Medications include amlodipine, atorvastatin, and ibuprofen as needed. He drinks 2 or 3 glasses of wine with dinner most nights but does not use tobacco or illicit drugs. Vital signs are within normal limits. BMI is 32 kg/m^2. Physical examination is unremarkable. Esophagogastroduodenoscopy reveals a 4-cm mass surrounded by a large segment of discolored mucosa in the lower half of the esophagus. Esophagogastrectomy results are shown in the image below:

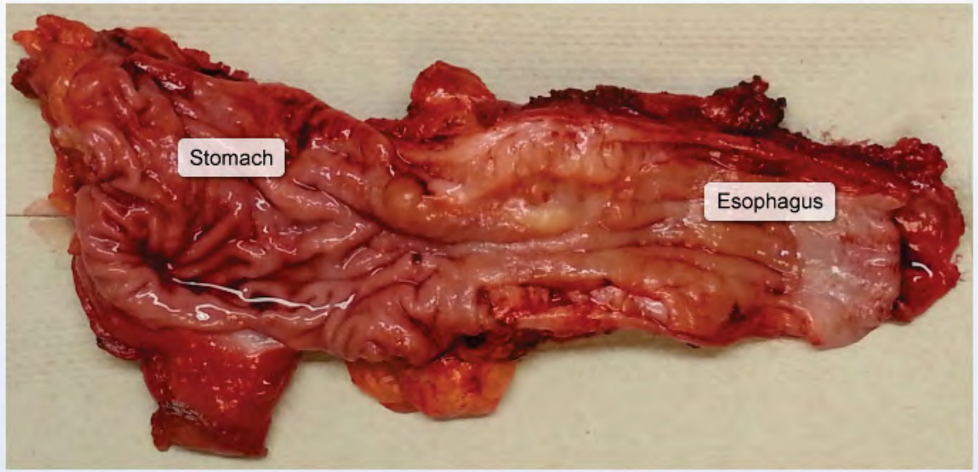

Which of the following is the most likely predisposing factor for this patient's esophageal disease?

- A. Alcohol use (24%)
- B. Chronic nonsteroidal anti-inflammatory drug use (8%)
- ✗ C. *Helicobacter pylori* infection (16%)
- ✓ D. Obesity (39%)
- E. Repeated thermal injury (11%)

Incorrect
Correct answer
D

39%
Answered correctly

45 secs
Time Spent

2023
Version

https://t.me/USMLEWorldStep1

✓ ○ D. Obesity (39%)

Exhibit Display

Esophageal adenocarcinoma

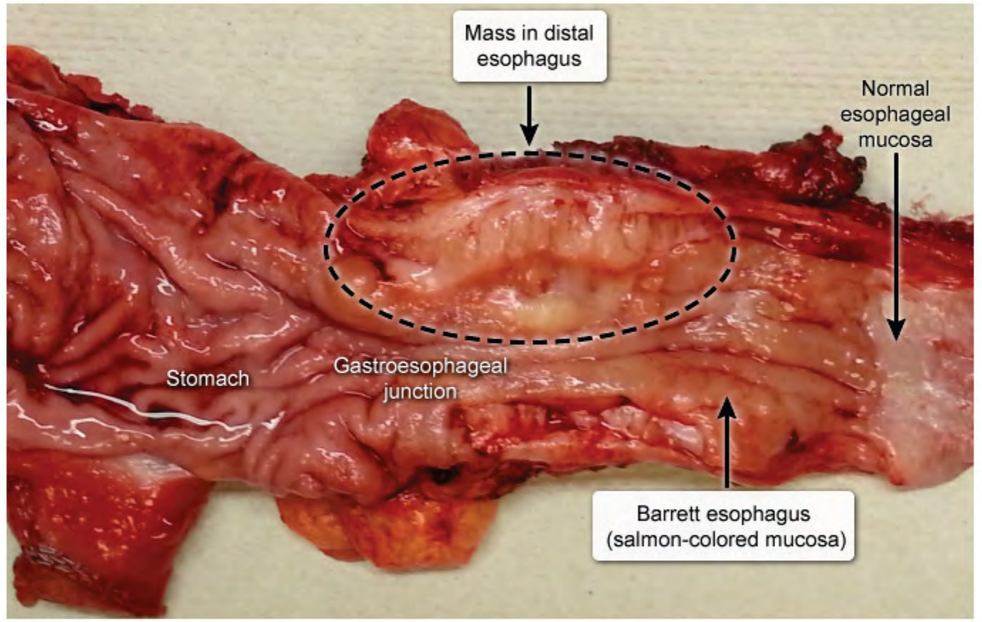

©UWorld

Zoom In | Zoom Out | Reset | New | Existing | My Notebook

This p
loss, and a mass in his lower esophagus, raising strong suspicion for **esophageal adenocarcinoma**. Most cases of esophageal adenocarcinoma arise in the setting of **Barrett esophagus**, a metaplastic condition whereby the

https://t.me/USMLEWorldStep1

©UWorld

This patient with chronic gastroesophageal reflux disease (GERD) now has dysphagia with solid foods, weight loss, and a mass in his lower esophagus, raising strong suspicion for **esophageal adenocarcinoma**. Most cases of esophageal adenocarcinoma arise in the setting of **Barrett esophagus**, a metaplastic condition whereby the normal stratified squamous epithelium in the distal esophagus is replaced with intestine-like columnar cells in response to chronic acidic damage. Although these metaplastic columnar cells are better suited to handle the presence of acid in the distal esophagus, they are also much more likely to become dysplastic and undergo malignant transformation into esophageal adenocarcinoma.

Major risk factors for esophageal adenocarcinoma are similar to those that promote Barrett esophagus and include:

- **Chronic GERD**
- **Obesity** - increases intragastric pressure, frequency of lower esophageal sphincter relaxation, and rates of hiatal hernia, which promote GERD
- Smoking
- Use of medications that lower esophageal sphincter pressure (eg, nitroglycerin)
- Consumption of foods containing nitroso compounds (eg, processed meats)

(Choice A) Alcohol is a risk factor for esophageal squamous cell carcinoma, which typically arises in the mid-esophagus from areas of esophageal squamous dysplasia. Alcohol does not appear to increase the risk of Barrett esophagus, and wine may be protective.

(Choice B) Aspirin and other nonsteroidal anti-inflammatory drugs may be protective against esophageal cancer, especially in the setting of Barrett esophagus. These drugs may also be protective against colorectal cancer.

(Choice C) *Helicobacter pylori* is an important risk factor for gastric adenocarcinoma and gastric mucosa–associated lymphoid tissue; it does not appear to increase risk for esophageal adenocarcinoma.

(Choice E) Thermal injury due to drinking hot beverages may increase the risk of esophageal squamous cell

https://t.me/USMLEWorldStep1

response to chronic acidic damage. Although these metaplastic columnar cells are better suited to handle the presence of acid in the distal esophagus, they are also much more likely to become dysplastic and undergo malignant transformation into esophageal adenocarcinoma.

Major risk factors for esophageal adenocarcinoma are similar to those that promote Barrett esophagus and include:

- **Chronic GERD**
- **Obesity** - increases intragastric pressure, frequency of lower esophageal sphincter relaxation, and rates of hiatal hernia, which promote GERD
- Smoking
- Use of medications that lower esophageal sphincter pressure (eg, nitroglycerin)
- Consumption of foods containing nitroso compounds (eg, processed meats)

(Choice A) Alcohol is a risk factor for esophageal squamous cell carcinoma, which typically arises in the mid-esophagus from areas of esophageal squamous dysplasia. Alcohol does not appear to increase the risk of Barrett esophagus, and wine may be protective.

(Choice B) Aspirin and other nonsteroidal anti-inflammatory drugs may be protective against esophageal cancer, especially in the setting of Barrett esophagus. These drugs may also be protective against colorectal cancer.

(Choice C) *Helicobacter pylori* is an important risk factor for gastric adenocarcinoma and gastric mucosa–associated lymphoid tissue; it does not appear to increase risk for esophageal adenocarcinoma.

(Choice E) Thermal injury due to drinking hot beverages may increase the risk of esophageal squamous cell carcinoma but is not clearly associated with esophageal adenocarcinoma.

Educational objective:
Esophageal adenocarcinoma usually occurs in the distal esophagus due to underlying Barrett esophagus. Long-standing gastroesophageal reflux disease is the most important risk factor. Obesity, smoking, use of medications that lower esophageal sphincter pressure, and consumption of foods containing nitroso compounds also increase the risk.

https://t.me/USMLEWorldStep1

Exhibit Display

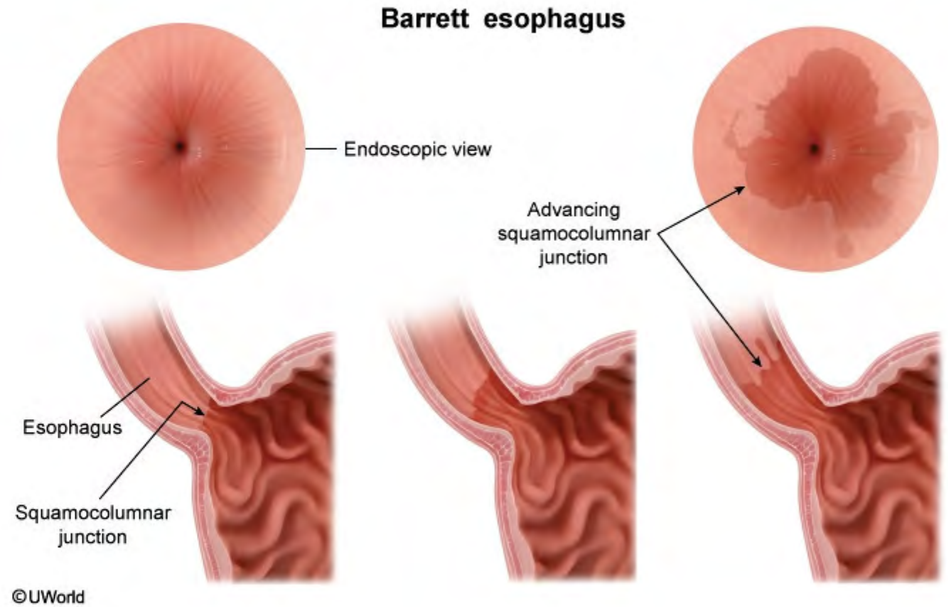

Zoom In | Zoom Out | Reset | New | Existing | My Notebook

This p
loss, a
of eso
norma
respor
preser
malign

Major
includ

- C
- C
  h
- S
- U
- C

(Choi
esoph
esoph

(Choi
especi

(Choi
associated lymphoid tissue; it does not appear to increase risk for esophageal adenocarcinoma.

(Choice E) Thermal injury due to drinking hot beverages may increase the risk of esophageal squamous cell

https://t.me/USMLEWorldStep1

A 45-year-old woman is brought to the emergency department with severe abdominal pain, fever, and confusion. The patient's husband reports that, yesterday, she began to have worsening right-sided abdominal pain associated with nausea and several episodes of vomiting. This morning, she has been slow to respond and is confused about where she is. The patient has a history of depression and takes sertraline. Temperature is 39.5 C (103.1 F), blood pressure is 88/50 mm Hg, pulse is 104/min, and respirations are 26/min. She appears ill and confused, and the sclera are icteric. Abdominal examination demonstrates significant tenderness with guarding in the right upper quadrant. Which of the following is the most likely underlying cause of this patient's current condition?

- A. Acinar cell dysfunction and necrosis
- B. Calculous obstruction of the common bile duct
- C. Extensive hepatic formation of noncaseating granulomas
- D. Immune-mediated destruction of hepatocytes
- E. Medication overdose with hepatic failure
- F. Neoplastic mass in the pancreatic tail

Submit

https://t.me/USMLEWorldStep1

A 45-year-old woman is brought to the emergency department with severe abdominal pain, fever, and confusion. The patient's husband reports that, yesterday, she began to have worsening right-sided abdominal pain associated with nausea and several episodes of vomiting. This morning, she has been slow to respond and is confused about where she is. The patient has a history of depression and takes sertraline. Temperature is 39.5 C (103.1 F), blood pressure is 88/50 mm Hg, pulse is 104/min, and respirations are 26/min. She appears ill and confused, and the sclera are icteric. Abdominal examination demonstrates significant tenderness with guarding in the right upper quadrant. Which of the following is the most likely underlying cause of this patient's current condition?

- A. Acinar cell dysfunction and necrosis (4%)
- ✓ B. Calculous obstruction of the common bile duct (57%)
- C. Extensive hepatic formation of noncaseating granulomas (1%)
- D. Immune-mediated destruction of hepatocytes (6%)
- E. Medication overdose with hepatic failure (29%)
- F. Neoplastic mass in the pancreatic tail (0%)

Correct

57% Answered correctly

03 secs Time Spent

2023 Version

Explanation

Acute cholangitis	
Etiology	• Ascending infection due to biliary obstruction ◦ Obstructive gallstone ◦ Malignancy (eg, cholangiocarcinoma, pancreatic head cancer) ◦ Stricture (eg, primary sclerosing cholangitis)

https://t.me/USMLEWorldStep1

Explanation

Acute cholangitis	
Etiology	• Ascending infection due to biliary obstruction ◦ Obstructive gallstone ◦ Malignancy (eg, cholangiocarcinoma, pancreatic head cancer) ◦ Stricture (eg, primary sclerosing cholangitis) ◦ Biliary stent blockage
Clinical presentation	• Fever, jaundice, RUQ pain (Charcot triad) • ± Hypotension, altered mental status (Reynolds pentad)
Laboratory results	• Cholestatic liver function test ◦ ↑ Alkaline phosphatase, bilirubin ◦ ± Mildly elevated transaminases • Leukocytosis
Imaging	• Biliary dilation on abdominal imaging
RUQ = right upper quadrant.	

This patient with fever, right upper quadrant (RUQ) pain, jaundice, confusion, and hypotension has **acute cholangitis (AC)**. AC is a life-threatening infection that typically develops in the setting of **biliary obstruction**, which enables bacteria to proliferate within the biliary tree. Obstruction can occur in a variety of settings (eg, malignant biliary obstruction, biliary stricture) but is most commonly caused by a **calculous obstruction of the common bile duct** (ie, choledocholithiasis).

AC is characterized by **fever**, **RUQ pain**, and **jaundice** (Charcot triad); **hypotension** and **altered mental status** (Reynold pentad) occur in severe cases. Laboratory findings include leukocytosis, direct hyperbilirubinemia, and elevated alkaline phosphatase. Abdominal imaging (eg, ultrasound) demonstrates common bile duct dilation, possibly with evidence of an obstructing stone. Management includes antibiotics, intravenous fluid resuscitation,

https://t.me/USMLEWorldStep1

Imaging	• Biliary dilation on abdominal imaging
RUQ = right upper quadrant.	

This patient with fever, right upper quadrant (RUQ) pain, jaundice, confusion, and hypotension has **acute cholangitis (AC)**. AC is a life-threatening infection that typically develops in the setting of **biliary obstruction**, which enables bacteria to proliferate within the biliary tree. Obstruction can occur in a variety of settings (eg, malignant biliary obstruction, biliary stricture) but is most commonly caused by a **calculous obstruction of the common bile duct** (ie, choledocholithiasis).

AC is characterized by **fever**, **RUQ pain**, and **jaundice** (Charcot triad); **hypotension** and **altered mental status** (Reynold pentad) occur in severe cases. Laboratory findings include leukocytosis, direct hyperbilirubinemia, and elevated alkaline phosphatase. Abdominal imaging (eg, ultrasound) demonstrates common bile duct dilation, possibly with evidence of an obstructing stone. Management includes antibiotics, intravenous fluid resuscitation, and endoscopic or percutaneous techniques to relieve the biliary obstruction.

(Choice A) Acute pancreatitis is characterized by acinar cell dysfunction and necrosis. Although patients can develop fever and hypotension, typical manifestations include epigastric pain radiating into the back, nausea/vomiting, and elevated lipase. Jaundice is unexpected unless a gallstone obstructs both the common bile and the pancreatic ducts, resulting in simultaneous AC.

(Choice C) Hepatic sarcoidosis, which causes extensive noncaseating granuloma formation in the liver, can present with cholestasis (eg, elevated alkaline phosphatase, jaundice, pruritus) and hepatomegaly. However, sepsis, hypotension, and confusion are unexpected, and most patients have evidence of systemic sarcoidosis (eg, hilar adenopathy, cough).

(Choice D) Autoimmune hepatitis causes immune-mediated hepatocyte destruction and usually presents with asymptomatic transaminitis or the insidious onset of fatigue and anorexia. Fever, tachycardia, and hypotension are unexpected and more consistent with infection due to AC.

(Choice E) Acetaminophen overdose can cause RUQ pain, jaundice, vomiting, and confusion, typically around 72 hours after ingestion. However, fever is atypical and more consistent with AC.

(Choice F) Although a mass in the pancreatic head can cause biliary obstruction, pancreatic tail masses are not

https://t.me/USMLEWorldStep1

elevated alkaline phosphatase. Abdominal imaging (eg, ultrasound) demonstrates common bile duct dilation, possibly with evidence of an obstructing stone. Management includes antibiotics, intravenous fluid resuscitation, and endoscopic or percutaneous techniques to relieve the biliary obstruction.

(Choice A) Acute pancreatitis is characterized by acinar cell dysfunction and necrosis. Although patients can develop fever and hypotension, typical manifestations include epigastric pain radiating into the back, nausea/vomiting, and elevated lipase. Jaundice is unexpected unless a gallstone obstructs both the common bile and the pancreatic ducts, resulting in simultaneous AC.

(Choice C) Hepatic sarcoidosis, which causes extensive noncaseating granuloma formation in the liver, can present with cholestasis (eg, elevated alkaline phosphatase, jaundice, pruritus) and hepatomegaly. However, sepsis, hypotension, and confusion are unexpected, and most patients have evidence of systemic sarcoidosis (eg, hilar adenopathy, cough).

(Choice D) Autoimmune hepatitis causes immune-mediated hepatocyte destruction and usually presents with asymptomatic transaminitis or the insidious onset of fatigue and anorexia. Fever, tachycardia, and hypotension are unexpected and more consistent with infection due to AC.

(Choice E) Acetaminophen overdose can cause RUQ pain, jaundice, vomiting, and confusion, typically around 72 hours after ingestion. However, fever is atypical and more consistent with AC.

(Choice F) Although a mass in the pancreatic head can cause biliary obstruction, pancreatic tail masses are not located near the biliary tree and therefore are not usually associated with AC. They more commonly present with epigastric abdominal pain and weight loss.

Educational objective:
Acute cholangitis is a life-threatening infection characterized by fever, right upper quadrant pain, and jaundice (Charcot triad); hypotension and altered mental status (Reynold pentad) occur in severe cases. Acute cholangitis typically develops in the setting of biliary obstruction; common etiologies include gallstones, malignancy, and strictures.

Pathology	Gastrointestinal & Nutrition	Cholangitis
Subject	System	Topic

https://t.me/USMLEWorldStep1

A 56-year-old man comes to the office for evaluation of upper abdominal pain occurring with meals for the past month. The symptoms improve when he is fasting. The patient has a history of coronary artery disease and osteoarthritis. Current medications include aspirin, simvastatin, and acetaminophen as needed. He drinks 1 or 2 beers daily but does not use tobacco or recreational drugs. Upper endoscopy reveals a gastric ulcer with a smooth, rounded border and an exudative base. A biopsy specimen of the ulcer is placed into a solution containing urea and phenol red, a pH indicator. Thirty minutes later, the solution has turned pink, indicating a pH increase. This test result suggests that which of the following processes is occurring?

- A. Clonal proliferation of glandular cells
- B. Cyclooxygenase inhibition leading to mucosal damage
- C. Enzymatic production of ammonia
- D. Gastrin hypersecretion leading to acid overproduction
- E. Parietal cell destruction due to autoimmune disease

Submit

https://t.me/USMLEWorldStep1

A 56-year-old man comes to the office for evaluation of upper abdominal pain occurring with meals for the past month. The symptoms improve when he is fasting. The patient has a history of coronary artery disease and osteoarthritis. Current medications include aspirin, simvastatin, and acetaminophen as needed. He drinks 1 or 2 beers daily but does not use tobacco or recreational drugs. Upper endoscopy reveals a gastric ulcer with a smooth, rounded border and an exudative base. A biopsy specimen of the ulcer is placed into a solution containing urea and phenol red, a pH indicator. Thirty minutes later, the solution has turned pink, indicating a pH increase. This test result suggests that which of the following processes is occurring?

- A. Clonal proliferation of glandular cells (2%)
- ✗ B. Cyclooxygenase inhibition leading to mucosal damage (13%)
- ✓ C. Enzymatic production of ammonia (68%)
- D. Gastrin hypersecretion leading to acid overproduction (11%)
- E. Parietal cell destruction due to autoimmune disease (4%)

Incorrect
Correct answer
C

68%
Answered correctly

03 secs
Time Spent

2023
Version

Explanation

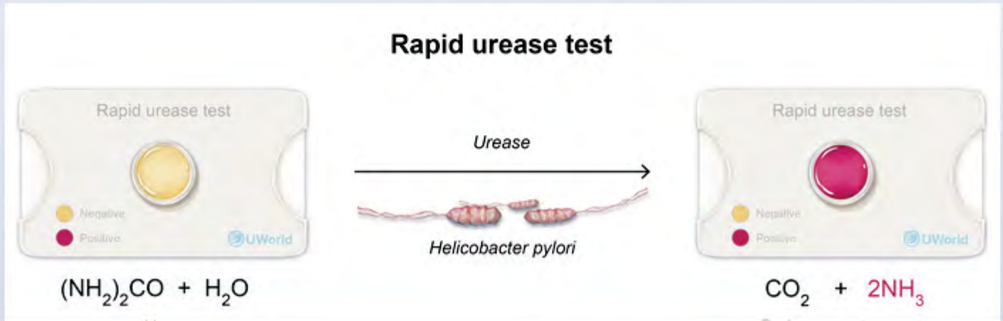

https://t.me/USMLEWorldStep1

E. Parietal cell destruction due to autoimmune disease (4%)

Exhibit Display

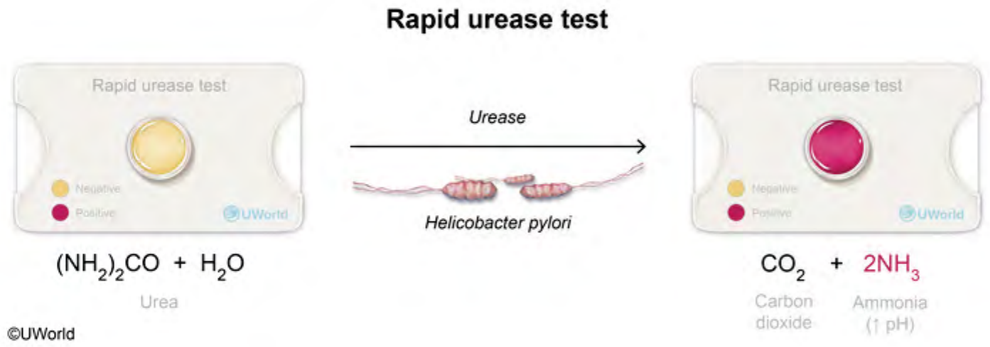

Zoom In | Zoom Out | Reset | New | Existing | My Notebook

Helico
endos
urease

The ra
splits g
in the
and a
indicat

(Choi
therefo
not cause a color change on rapid urease testing.

https://t.me/USMLEWorldStep1

Helicobacter pylori infection is a common cause of **peptic ulcers**. Biopsy specimens are often obtained during endoscopy for direct tissue diagnosis. In contrast to the time-intensive task of culturing the bacteria, the rapid urease test can be used to quickly diagnose an active infection.

The rapid urease test is an indirect test for *H pylori* based on bacterial production of the enzyme **urease**, which splits gastric **urea into ammonia** and CO_2. In vivo, this process increases local pH and facilitates bacterial survival in the acidic stomach environment. During the test, biopsy specimens are exposed to a solution containing urea and a pH indicator such as phenol red, which changes color from yellow to pink at alkaline pH. A color change indicates the presence of bacterial urease and confirms active *H pylori* infection.

(Choice A) Gastric adenocarcinoma (ie, clonal proliferation of glandular cells) can present as a gastric ulcer; therefore, gastric ulcers should be biopsied to rule out malignancy. However, specimens from malignant ulcers do not cause a color change on rapid urease testing.

(Choice B) Nonsteroidal anti-inflammatory drugs (NSAIDs) (eg, aspirin, ibuprofen) are another common cause of peptic ulcers due to their inhibition of the enzyme cyclooxygenase, which is responsible for the synthesis of gastroprotective prostaglandins. However, urease would not be present in an NSAID-induced ulcer.

(Choice D) In Zollinger-Ellison syndrome, gastrin hypersecretion leads to overproduction of gastric acid and formation of peptic ulcers. In the human body, *H pylori* also appears to induce acid production (eg, gastrin hypersecretion); however, the urease test detects bacterial urease, which causes the color change (ie, pH rise is from ammonia generation).

(Choice E) Autoimmune gastritis is due to T-cell–mediated destruction of parietal cells. Patients are typically asymptomatic, but prolonged disease leads to pernicious anemia (B_{12} deficiency due to intrinsic factor destruction) characterized by megaloblastic anemia and neurologic dysfunction. Gastric pH is increased due to loss of parietal cells, but ulcers do not occur in this condition, and the urease test would be negative.

Educational objective:
Helicobacter pylori produces the enzyme urease, which splits urea into CO_2 and ammonia and neutralizes the local acidic gastric pH. Active infection can be confirmed through rapid urease testing, in which a biopsy specimen of gastric mucosa is evaluated in the presence of urea and a pH indicator. Evidence of alkalization (due to ammonia formation) confirms the diagnosis.

https://t.me/USMLEWorldStep1

The rapid urease test is an indirect test for *H pylori* based on bacterial production of the enzyme **urease**, which splits gastric **urea into ammonia** and CO_2. In vivo, this process increases local pH and facilitates bacterial survival in the acidic stomach environment. During the test, biopsy specimens are exposed to a solution containing urea and a pH indicator such as phenol red, which changes color from yellow to pink at alkaline pH. A color change indicates the presence of bacterial urease and confirms active *H pylori* infection.

(Choice A) Gastric adenocarcinoma (ie, clonal proliferation of glandular cells) can present as a gastric ulcer; therefore, gastric ulcers should be biopsied to rule out malignancy. However, specimens from malignant ulcers do not cause a color change on rapid urease testing.

(Choice B) Nonsteroidal anti-inflammatory drugs (NSAIDs) (eg, aspirin, ibuprofen) are another common cause of peptic ulcers due to their inhibition of the enzyme cyclooxygenase, which is responsible for the synthesis of gastroprotective prostaglandins. However, urease would not be present in an NSAID-induced ulcer.

(Choice D) In Zollinger-Ellison syndrome, gastrin hypersecretion leads to overproduction of gastric acid and formation of peptic ulcers. In the human body, *H pylori* also appears to induce acid production (eg, gastrin hypersecretion); however, the urease test detects bacterial urease, which causes the color change (ie, pH rise is from ammonia generation).

(Choice E) Autoimmune gastritis is due to T-cell–mediated destruction of parietal cells. Patients are typically asymptomatic, but prolonged disease leads to pernicious anemia (B_{12} deficiency due to intrinsic factor destruction) characterized by megaloblastic anemia and neurologic dysfunction. Gastric pH is increased due to loss of parietal cells, but ulcers do not occur in this condition, and the urease test would be negative.

Educational objective:

Helicobacter pylori produces the enzyme urease, which splits urea into CO_2 and ammonia and neutralizes the local acidic gastric pH. Active infection can be confirmed through rapid urease testing, in which a biopsy specimen of gastric mucosa is evaluated in the presence of urea and a pH indicator. Evidence of alkalization (due to ammonia formation) confirms the diagnosis.

References

- Diagnosis of Helicobacter pylori using the rapid urease test.

https://t.me/USMLEWorldStep1

A 5-week-old boy is brought to the emergency department after having tonic-clonic movements of his left upper and lower extremity that lasted approximately 3 minutes. The patient was born at 38 weeks gestation to a 23-year-old primigravid woman. The mother received normal prenatal care, took prenatal vitamins, and had a healthy diet during pregnancy. The infant's newborn screen was positive for cystic fibrosis, and confirmatory testing is pending. The infant has been breastfeeding exclusively. He has never taken any medications and has received no vaccinations. On examination, the infant is postictal. A CT scan of the head shows a right-sided intracranial hemorrhage. Which of the following is the most likely cause of this infant's presentation?

- A. Failure of amino acid hydroxylation
- B. Failure of fatty-acid oxidation
- C. Failure of rhodopsin production
- D. Impaired gamma carboxylation
- E. Ineffective erythropoiesis
- F. Reduced activation of intranuclear receptors

Submit

https://t.me/USMLEWorldStep1

A 5-week-old boy is brought to the emergency department after having tonic-clonic movements of his left upper and lower extremity that lasted approximately 3 minutes. The patient was born at 38 weeks gestation to a 23-year-old primigravid woman. The mother received normal prenatal care, took prenatal vitamins, and had a healthy diet during pregnancy. The infant's newborn screen was positive for cystic fibrosis, and confirmatory testing is pending. The infant has been breastfeeding exclusively. He has never taken any medications and has received no vaccinations. On examination, the infant is postictal. A CT scan of the head shows a right-sided intracranial hemorrhage. Which of the following is the most likely cause of this infant's presentation?

- A. Failure of amino acid hydroxylation (11%)
- ✗ B. Failure of fatty-acid oxidation (16%)
- C. Failure of rhodopsin production (3%)
- ✓ D. Impaired gamma carboxylation (57%)
- E. Ineffective erythropoiesis (3%)
- F. Reduced activation of intranuclear receptors (8%)

Incorrect
Correct answer
D

57%
Answered correctly

03 secs
Time Spent

2023
Version

Explanation

Infantile vitamin K–deficient bleeding	
Pathophysiology	• Low vitamin K stores (poor placental transfer, sterile gut, low content in breast milk) • Inefficient vitamin K use by immature liver
	• Classically presents on day 2-7 of life*

https://t.me/USMLEWorldStep1

Explanation

Infantile vitamin K–deficient bleeding	
Pathophysiology	• Low vitamin K stores (poor placental transfer, sterile gut, low content in breast milk) • Inefficient vitamin K use by immature liver
Clinical features	• Classically presents on day 2-7 of life* • Easy bruising • Umbilical, mucosal & gastrointestinal bleeding • Intracranial hemorrhage
Laboratory findings	• ↑ PT • ↑ PTT (if severe) • Normal platelet count
Prevention	• Intramuscular vitamin K at birth
*Can occur up to age 6 months.	

This infant has a right-sided intracranial hemorrhage causing contralateral seizure activity. In an infant who has not received any medications, the most likely cause of bleeding is **vitamin K deficiency**. Newborns physiologically have low vitamin K stores due to poor transplacental transfer and inefficient use by the liver. Additional risk factors include exclusive breastfeeding, due to the low vitamin K content of breast milk, and **cystic fibrosis** (CF), due to malabsorption of **fat-soluble vitamins** (A, D, E, K).

Vitamin K is an essential cofactor for **gamma-glutamyl carboxylase**, an enzyme that carboxylates **coagulation factors II, VII, IX, and X**. Carboxylation allows for the creation of calcium-binding sites, which attract clotting factors to negatively charged phospholipids on platelets and endothelial cells, which is necessary for efficient coagulation. Vitamin K deficiency leads to impaired clotting factor activity.

Newborns who do not receive routine **vitamin K prophylaxis** at birth are at greatest risk for vitamin K–deficient

https://t.me/USMLEWorldStep1

*Can occur up to age 6 months.

This infant has a right-sided intracranial hemorrhage causing contralateral seizure activity. In an infant who has not received any medications, the most likely cause of bleeding is **vitamin K deficiency**. Newborns physiologically have low vitamin K stores due to poor transplacental transfer and inefficient use by the liver. Additional risk factors include exclusive breastfeeding, due to the low vitamin K content of breast milk, and **cystic fibrosis** (CF), due to malabsorption of **fat-soluble vitamins** (A, D, E, K).

Vitamin K is an essential cofactor for **gamma-glutamyl carboxylase**, an enzyme that carboxylates **coagulation factors II, VII, IX, and X**. Carboxylation allows for the creation of calcium-binding sites, which attract clotting factors to negatively charged phospholipids on platelets and endothelial cells, which is necessary for efficient coagulation. Vitamin K deficiency leads to impaired clotting factor activity.

Newborns who do not receive routine **vitamin K prophylaxis** at birth are at greatest risk for vitamin K–deficient bleeding. Lack of functioning coagulation factors predisposes to **life-threatening bleeding**, such as **intracranial hemorrhage** and profuse bleeding from the gastrointestinal tract, umbilicus, and surgical sites.

(Choice A) Vitamin C (ascorbic acid) deficiency results in defective collagen synthesis due to failure of hydroxylation of proline and lysine. Mucosal bleeding and skin bruising are typical and occur in severely malnourished individuals and those who misuse drugs or alcohol. Breast milk provides adequate ascorbic acid.

(Choice B) Vitamin B_3 (niacin) deficiency results in failure of formation of nicotinamide adenine dinucleotide (NAD) and nicotinamide adenine dinucleotide phosphate (NADP), which are required for fatty-acid oxidation and synthesis, respectively. Niacin deficiency presents with pellagra (ie, dermatitis, diarrhea, dementia), not intracranial hemorrhage.

(Choices C and F) Patients with CF are at risk for deficiency of vitamins A and D. Vitamin A deficiency impairs rhodopsin formation and leads to night blindness and xerophthalmia, not bleeding. Reduced activation of intranuclear receptors occurs in vitamin D deficiency. Although vitamin D is poorly absorbed from breast milk, deficiency causes rickets (eg, craniotabes), not bleeding diathesis.

(Choice E) Erythropoiesis requires folate, deficiency of which leads to megaloblastic anemia, not hemorrhage.

Educational objective:

https://t.me/USMLEWorldStep1

Vitamin K is an essential cofactor for **gamma-glutamyl carboxylase**, an enzyme that carboxylates **coagulation factors II, VII, IX, and X**. Carboxylation allows for the creation of calcium-binding sites, which attract clotting factors to negatively charged phospholipids on platelets and endothelial cells, which is necessary for efficient coagulation. Vitamin K deficiency leads to impaired clotting factor activity.

Newborns who do not receive routine **vitamin K prophylaxis** at birth are at greatest risk for vitamin K–deficient bleeding. Lack of functioning coagulation factors predisposes to **life-threatening bleeding**, such as **intracranial hemorrhage** and profuse bleeding from the gastrointestinal tract, umbilicus, and surgical sites.

(Choice A) Vitamin C (ascorbic acid) deficiency results in defective collagen synthesis due to failure of hydroxylation of proline and lysine. Mucosal bleeding and skin bruising are typical and occur in severely malnourished individuals and those who misuse drugs or alcohol. Breast milk provides adequate ascorbic acid.

(Choice B) Vitamin B_3 (niacin) deficiency results in failure of formation of nicotinamide adenine dinucleotide (NAD) and nicotinamide adenine dinucleotide phosphate (NADP), which are required for fatty-acid oxidation and synthesis, respectively. Niacin deficiency presents with pellagra (ie, dermatitis, diarrhea, dementia), not intracranial hemorrhage.

(Choices C and F) Patients with CF are at risk for deficiency of vitamins A and D. Vitamin A deficiency impairs rhodopsin formation and leads to night blindness and xerophthalmia, not bleeding. Reduced activation of intranuclear receptors occurs in vitamin D deficiency. Although vitamin D is poorly absorbed from breast milk, deficiency causes rickets (eg, craniotabes), not bleeding diathesis.

(Choice E) Erythropoiesis requires folate, deficiency of which leads to megaloblastic anemia, not hemorrhage.

Educational objective:
Vitamin K is necessary for carboxylation of coagulation factors II, VII, IX, and X. Newborns who do not receive prophylactic supplementation are at risk for life-threatening bleeding (eg, intracranial hemorrhage). Patients with cystic fibrosis are also at increased risk for vitamin K deficiency due to malabsorption of fat-soluble vitamins.

Pathology	Gastrointestinal & Nutrition	Vitamin k deficiency
Subject	System	Topic

Copyright © UWorld. All rights reserved.

https://t.me/USMLEWorldStep1

A 36-year-old immigrant from Peru comes to the office due to difficulty swallowing liquids. He also has difficulty belching. Eating slowly and extending the neck partially relieves his symptoms. The patient has had no fever, weight loss, chest pain, cough, dyspnea, or neurologic symptoms. He has no chronic medical problems and takes no medications. He has been an active smoker for the last 18 years but does not use alcohol or illicit drugs. The patient is afebrile with normal vital signs. BMI is 24 kg/m^2. On examination, the abdomen is soft, nondistended, and nontender, with no masses or organomegaly. Bowel sounds are normal. Other examination findings are unremarkable. Barium swallow shows a dilated esophagus, and manometry confirms absent peristalsis in the smooth muscle portion of the esophagus. If this patient's symptoms are caused by an infection, which of the following organisms is the most likely cause?

- A. *Candida albicans*
- B. *Clostridium botulinum*
- C. Cytomegalovirus
- D. *Helicobacter pylori*
- E. *Schistosoma mansoni*
- F. *Trypanosoma cruzi*

Submit

https://t.me/USMLEWorldStep1

A 36-year-old immigrant from Peru comes to the office due to difficulty swallowing liquids. He also has difficulty belching. Eating slowly and extending the neck partially relieves his symptoms. The patient has had no fever, weight loss, chest pain, cough, dyspnea, or neurologic symptoms. He has no chronic medical problems and takes no medications. He has been an active smoker for the last 18 years but does not use alcohol or illicit drugs. The patient is afebrile with normal vital signs. BMI is 24 kg/m^2. On examination, the abdomen is soft, nondistended, and nontender, with no masses or organomegaly. Bowel sounds are normal. Other examination findings are unremarkable. Barium swallow shows a dilated esophagus, and manometry confirms absent peristalsis in the smooth muscle portion of the esophagus. If this patient's symptoms are caused by an infection, which of the following organisms is the most likely cause?

- A. *Candida albicans* (0%)
- ✗ B. *Clostridium botulinum* (8%)
- C. Cytomegalovirus (2%)
- D. *Helicobacter pylori* (2%)
- E. *Schistosoma mansoni* (1%)
- ✓ F. *Trypanosoma cruzi* (84%)

Incorrect
Correct answer
F

84%
Answered correctly

03 secs
Time Spent

2023
Version

Explanation

Chagas disease	
Epidemiology	• Caused by protozoan *Trypanosoma cruzi* • Vector: triatomine ("kissing") bug

https://t.me/USMLEWorldStep1

Chagas disease	
Epidemiology	• Caused by protozoan *Trypanosoma cruzi* • Vector: triatomine ("kissing") bug • Endemic in Central & South America
Cardiac manifestations	• Dilated cardiomyopathy with biventricular failure • Apical wall thinning with aneurysm ± mural thrombus • Ventricular arrhythmias
Gastrointestinal manifestations	• Megaesophagus (secondary achalasia) • Megacolon

This patient who presents with dysphagia and a dilated esophagus has **achalasia**, which is characterized by the absence of distal esophageal peristalsis and incomplete relaxation of a hypertensive lower esophageal sphincter. It is most often a primary disorder; however, in a patient from Central or South America, **secondary** achalasia due to **Chagas disease** should be suspected.

Chagas disease is caused by chronic infection with *Trypanosoma cruzi*, a slender C- or U-shaped flagellated parasite with darkly staining nucleus and kinetoplast. Parasitosis-related inflammation and immune-mediated cross-reactivity between the parasite and the enteric ganglia lead to destruction of the submucosal (Meissner) and myenteric (Auerbach) plexus. Denervation results in uncoordinated smooth muscle activity, increased esophageal tone, and incomplete lower esophageal relaxation. Mechanical dilation (due to obstructed liquids and solids) proximal to the functional obstruction manifests as **megaesophagus**.

Patients classically experience dysphagia progressing from solids to liquids, odynophagia (due to food impaction), difficulty belching, regurgitation, and malnutrition. Other manifestations of Chagas disease can include nonischemic **cardiomyopathy** and megacolon. In addition, patients are at higher risk for esophageal cancer.

(Choices A and C) Immunocompromised patients (eg, advanced HIV) can develop infectious esophagitis. *Candida albicans* causes exudative esophagitis, usually with concurrent oral thrush. Cytomegalovirus causes

https://t.me/USMLEWorldStep1

myenteric (Auerbach) plexus. Denervation results in uncoordinated smooth muscle activity, increased esophageal tone, and incomplete lower esophageal relaxation. Mechanical dilation (due to obstructed liquids and solids) proximal to the functional obstruction manifests as **megaesophagus**.

Patients classically experience dysphagia progressing from solids to liquids, odynophagia (due to food impaction), difficulty belching, regurgitation, and malnutrition. Other manifestations of Chagas disease can include nonischemic **cardiomyopathy** and megacolon. In addition, patients are at higher risk for esophageal cancer.

(Choices A and C) Immunocompromised patients (eg, advanced HIV) can develop infectious esophagitis. *Candida albicans* causes exudative esophagitis, usually with concurrent oral thrush. Cytomegalovirus causes ulcerative esophagitis in the distal esophagus. Dysphagia and odynophagia are common with these disorders, but esophageal dilation and motility abnormalities are unexpected, and occurrence in immunocompetent patients is rare.

(Choice B) *Clostridium botulinum* causes botulism, a paralytic disease resulting from neurotoxins that inhibit the release of acetylcholine from presynaptic nerve terminals. Patients develop cranial nerve dysfunction and descending muscular weakness.

(Choice D) *Helicobacter pylori* causes gastritis and peptic ulcer. Typical manifestations include epigastric pain and nausea; however, *H pylori* does not usually cause esophageal disorders and is unlikely to cause esophageal dilation or absent peristalsis.

(Choice E) *Schistosoma mansoni* is a parasite found in sub-Saharan Africa, the Middle East, South America, and the Caribbean that causes intestinal or hepatic schistosomiasis; this results in gastrointestinal illness (diarrhea, abdominal pain) or portal hypertension and cirrhosis, respectively.

Educational objective:
Chagas disease is caused by a chronic infection by *Trypanosoma cruzi* and causes secondary achalasia due to destruction of the submucosal (Meissner) and myenteric (Auerbach) plexus. Other manifestations can include nonischemic cardiomyopathy and megacolon.

Microbiology	Gastrointestinal & Nutrition	Achalasia
Subject	System	Topic

https://t.me/USMLEWorldStep1

Epidemiology	• Caused by protozoan *Trypanosoma cruzi* • Vector: triatomine ("kissing") bug

Exhibit Display

Trypanosoma cruzi

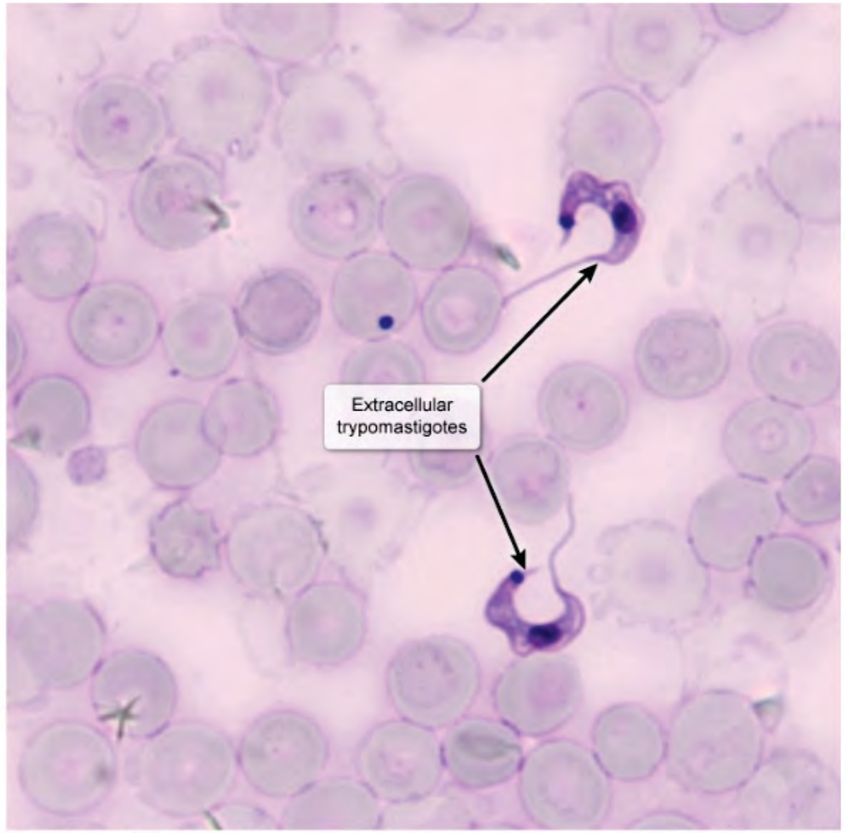

Peripheral blood smear – Giemsa stain

©UWorld

Zoom In | Zoom Out | Reset | New | Existing | My Notebook

This p
absen
It is m
to **Cha**

Chaga
parasi
cross-
myent
tone, a
proxim

Patien
difficul
nonisc

(Choi
Candi
ulcera
esoph
rare.

https://t.me/USMLEWorldStep1

A 42-year-old man comes to the office due to numbness and tingling in both legs and difficulty walking for the past several months. He has also noticed that he tires more easily with physical activity. Temperature is 36.8 C (98.2 F), blood pressure is 122/86 mm Hg, pulse is 76 /min, and respirations are 14/min. Physical examination shows conjunctival pallor and loss of vibration and position sensation in the bilateral lower extremities with associated gait ataxia. The remainder of the examination is within normal limits. Which of the following findings is most likely to be present on further questioning of the patient?

- A. Ongoing treatment for latent tuberculosis
- B. Strict vegan diet for the past 6 years
- C. Total gastrectomy 8 months ago
- D. Use of an antiepileptic drug for the past 3 months
- E. Working indoors most of the time

Submit

https://t.me/USMLEWorldStep1

A 42-year-old man comes to the office due to numbness and tingling in both legs and difficulty walking for the past several months. He has also noticed that he tires more easily with physical activity. Temperature is 36.8 C (98.2 F), blood pressure is 122/86 mm Hg, pulse is 76 /min, and respirations are 14/min. Physical examination shows conjunctival pallor and loss of vibration and position sensation in the bilateral lower extremities with associated gait ataxia. The remainder of the examination is within normal limits. Which of the following findings is most likely to be present on further questioning of the patient?

- A. Ongoing treatment for latent tuberculosis (5%)
- ✓ B. Strict vegan diet for the past 6 years (63%)
- C. Total gastrectomy 8 months ago (26%)
- D. Use of an antiepileptic drug for the past 3 months (3%)
- E. Working indoors most of the time (0%)

Correct

63% Answered correctly

02 mins, 45 secs Time Spent

2023 Version

Explanation

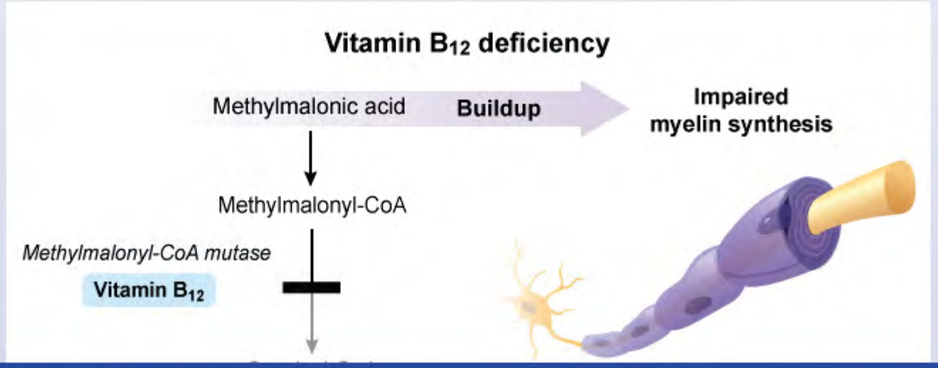

https://t.me/USMLEWorldStep1

- A. Ongoing treatment for latent tuberculosis (5%)
- ✓ B. Strict vegan diet for the past 6 years (63%)
- C. Total gastrectomy 8 months ago (26%)
- D. Use of an antiepileptic drug for the past 3 months (3%)
- E. Working indoors most of the time (0%)

Correct

63% Answered correctly

02 mins, 45 secs Time Spent

2023 Version

Explanation

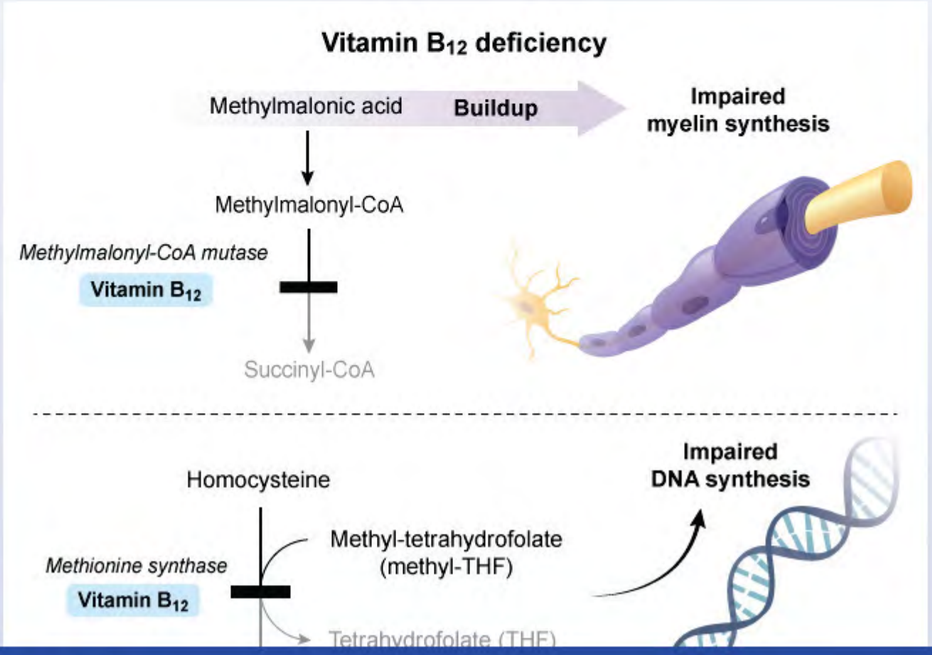

https://t.me/USMLEWorldStep1

A. Ongoing treatment for latent tuberculosis (5%)

Exhibit Display

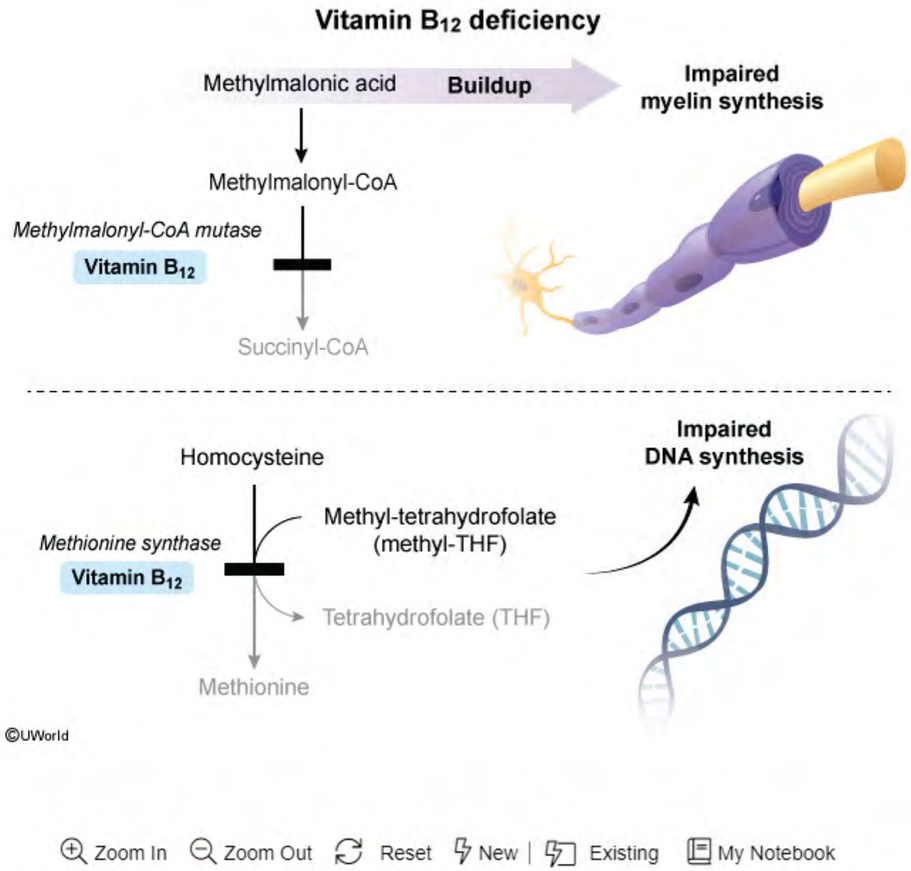

Zoom In | Zoom Out | Reset | New | Existing | My Notebook

Vitamin B_{12}

Tetrahydrofolate (THF)

https://t.me/USMLEWorldStep1

Methionine

©UWorld

This patient most likely has deficiency of **vitamin B_{12}** (cobalamin), a water-soluble vitamin obtained solely from the diet, specifically **animal products** such as meat, dairy, and fish. Vitamin B_{12} cannot be obtained directly from plant products, placing **strict vegans** at risk for **dietary deficiency**, particularly those who do not eat vitamin B_{12}–fortified foods; without supplementation, patients with impaired intrinsic factor production (eg, pernicious anemia, total gastrectomy) also inevitably develop deficiency.

The liver can store approximately 1,000 times the daily vitamin B_{12} requirement; deficiency develops only after the **complete absence of intake** or absorption for **3-4 years**, making a long-standing (ie, 6 years) vegan diet consistent with this patient's presentation, in contrast to a recent (ie, 8 months) gastrectomy **(Choice C)**.

Development of anemia and severe, potentially irreversible neurologic damage can result from vitamin B_{12} deficiency. Red blood cell synthesis relies on vitamin B_{12}–dependent recycling of folate; deficiency of either vitamin results in megaloblastic anemia. Impaired myelin synthesis, specifically in the dorsal and lateral columns, results in **subacute combined degeneration** of the spinal cord. This condition is progressive and begins as a symmetric neuropathy consisting of paresthesia and weakness. Ongoing deficiency leads to loss of vibration and position sensation with development of an ataxic gait. The longer the deficiency is untreated, the less likely the neurologic deficits can be reversed.

(Choice A) Isoniazid is often used to treat latent tuberculosis infection. It impairs the availability of vitamin B_6, which can result in peripheral neuropathy in high risk patients (eg, pregnancy, HIV, diabetes mellitus); anemia (eg, conjunctival pallor) would be unexpected.

(Choice D) Phenytoin, an antiepileptic drug used to treat focal and generalized seizures, may result in folate deficiency and development of megaloblastic anemia. Phenytoin can also cause peripheral neuropathy, but this adverse effect usually occurs only with chronic therapy (>1 year).

(Choice E) Vitamin D deficiency can develop over several months due to inadequate dietary intake and minimal sunlight exposure. This deficiency presents as rickets in children and osteomalacia or osteoporosis in adults.

Educational objective:

Vitamin B_{12} is obtained through the diet solely from animal sources, which places strict vegans at risk for dietary

https://t.me/USMLEWorldStep1

diet, specifically **animal products** such as meat, dairy, and fish. Vitamin B_{12} cannot be obtained directly from plant products, placing **strict vegans** at risk for **dietary deficiency**, particularly those who do not eat vitamin B_{12}–fortified foods; without supplementation, patients with impaired intrinsic factor production (eg, pernicious anemia, total gastrectomy) also inevitably develop deficiency.

The liver can store approximately 1,000 times the daily vitamin B_{12} requirement; deficiency develops only after the **complete absence of intake** or absorption for **3-4 years**, making a long-standing (ie, 6 years) vegan diet consistent with this patient's presentation, in contrast to a recent (ie, 8 months) gastrectomy **(Choice C)**.

Development of anemia and severe, potentially irreversible neurologic damage can result from vitamin B_{12} deficiency. Red blood cell synthesis relies on vitamin B_{12}–dependent recycling of folate; deficiency of either vitamin results in megaloblastic anemia. Impaired myelin synthesis, specifically in the dorsal and lateral columns, results in **subacute combined degeneration** of the spinal cord. This condition is progressive and begins as a symmetric neuropathy consisting of paresthesia and weakness. Ongoing deficiency leads to loss of vibration and position sensation with development of an ataxic gait. The longer the deficiency is untreated, the less likely the neurologic deficits can be reversed.

(Choice A) Isoniazid is often used to treat latent tuberculosis infection. It impairs the availability of vitamin B_6, which can result in peripheral neuropathy in high risk patients (eg, pregnancy, HIV, diabetes mellitus); anemia (eg, conjunctival pallor) would be unexpected.

(Choice D) Phenytoin, an antiepileptic drug used to treat focal and generalized seizures, may result in folate deficiency and development of megaloblastic anemia. Phenytoin can also cause peripheral neuropathy, but this adverse effect usually occurs only with chronic therapy (>1 year).

(Choice E) Vitamin D deficiency can develop over several months due to inadequate dietary intake and minimal sunlight exposure. This deficiency presents as rickets in children and osteomalacia or osteoporosis in adults.

Educational objective:
Vitamin B_{12} is obtained through the diet solely from animal sources, which places strict vegans at risk for dietary deficiency. This deficiency takes years to develop due to the large hepatic vitamin B_{12} reserve, and presents with megaloblastic anemia and potentially irreversible neurologic deficits (eg, paresthesia, weakness, ataxic gait).

https://t.me/USMLEWorldStep1

Impaired
DNA synthesis

Exhibit Display

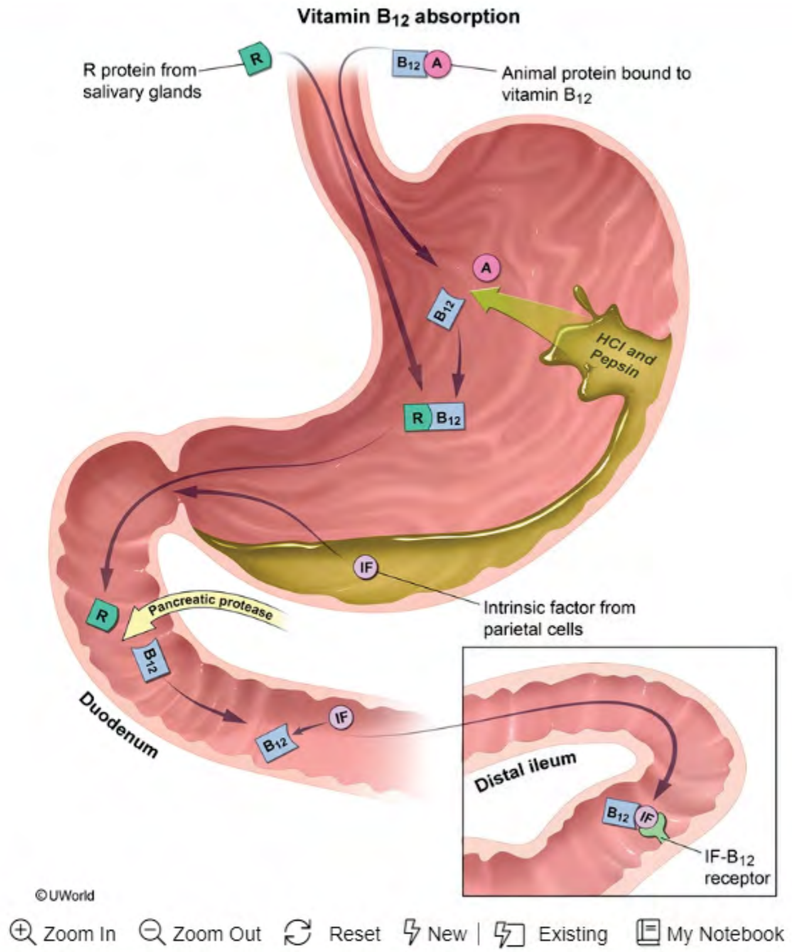

Zoom In | Zoom Out | Reset | New | Existing | My Notebook

This p
diet, s
produc
foods;
gastre

The liv
compl
consis

Develo
deficie
results
in **sub**
neurop
sensat
deficits

(Choi
which
conjunctival pallor) would be unexpected.

https://t.me/USMLEWorldStep1

Impaired

This p
diet, s
produc
foods;
gastre

The liv
compl
consis

Develo
deficie
results
in **sub**
neurop
sensat
deficits

(Choi
which
conjunctival pallor) would be unexpected.

Exhibit Display

Megaloblastic anemia

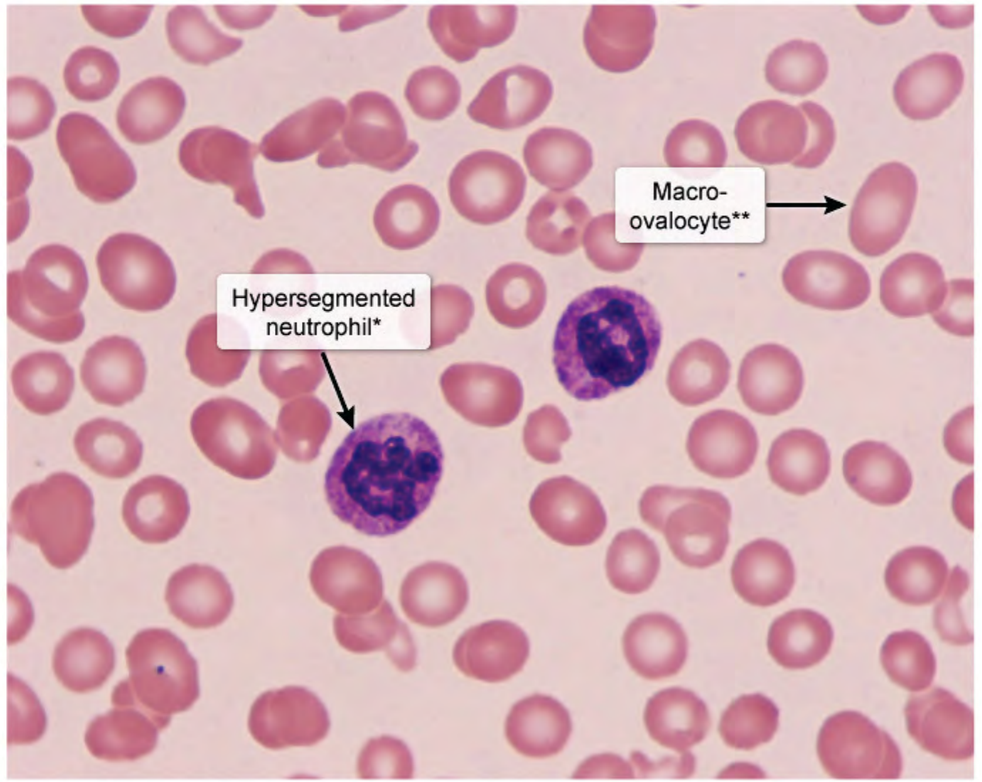

*≥ 6 nuclear lobes
**Large, oval red blood cell

©UWorld

Zoom In | Zoom Out | Reset | New | Existing | My Notebook

https://t.me/USMLEWorldStep1

A 72-year-old man comes to the office due to constipation. His stools have become increasingly hard, small-volume, and difficult to pass. This has been associated with bloating but not vomiting. Symptoms have not improved despite fiber supplementation, polyethylene glycol, and bisacodyl. The patient was recently diagnosed with metastatic pancreatic cancer and was prescribed palliative chemotherapy 2 months ago. His cancer causes severe abdominal pain, which requires high-dose oxycodone to control. Vital signs are within normal limits. The abdomen is mildly distended with decreased bowel sounds. Which of the following medications acts as a μ-opioid receptor antagonist that could alleviate this patient's constipation without inducing withdrawal symptoms?

- A. Diphenoxylate
- B. Loperamide
- C. Lubiprostone
- D. Methylnaltrexone
- E. Naloxone

Submit

https://t.me/USMLEWorldStep1

A 72-year-old man comes to the office due to constipation. His stools have become increasingly hard, small-volume, and difficult to pass. This has been associated with bloating but not vomiting. Symptoms have not improved despite fiber supplementation, polyethylene glycol, and bisacodyl. The patient was recently diagnosed with metastatic pancreatic cancer and was prescribed palliative chemotherapy 2 months ago. His cancer causes severe abdominal pain, which requires high-dose oxycodone to control. Vital signs are within normal limits. The abdomen is mildly distended with decreased bowel sounds. Which of the following medications acts as a μ-opioid receptor antagonist that could alleviate this patient's constipation without inducing withdrawal symptoms?

- A. Diphenoxylate
- B. Loperamide
- C. Lubiprostone
- D. Methylnaltrexone
- E. Naloxone

Submit

https://t.me/USMLEWorldStep1

A 72-year-old man comes to the office due to constipation. His stools have become increasingly hard, small-volume, and difficult to pass. This has been associated with bloating but not vomiting. Symptoms have not improved despite fiber supplementation, polyethylene glycol, and bisacodyl. The patient was recently diagnosed with metastatic pancreatic cancer and was prescribed palliative chemotherapy 2 months ago. His cancer causes severe abdominal pain, which requires high-dose oxycodone to control. Vital signs are within normal limits. The abdomen is mildly distended with decreased bowel sounds. Which of the following medications acts as a μ-opioid receptor antagonist that could alleviate this patient's constipation without inducing withdrawal symptoms?

- A. Diphenoxylate (10%)
- ✗ B. Loperamide (32%)
- C. Lubiprostone (7%)
- ✓ D. Methylnaltrexone (40%)
- E. Naloxone (8%)

Incorrect
Correct answer
D

40%
Answered correctly

41 secs
Time Spent

2023
Version

Explanation

Anticonstipation agents	
Bulk-forming laxatives (eg, fiber supplements)	• Binds luminal water to decrease consistency of stool • Side effects: flatulence, abdominal distension
Osmotic laxatives (eg, polyethylene glycol, magnesium hydroxide, lactulose)	• Osmotically active agent that draws water into the lumen • Side effects: electrolyte disturbances, bloating

https://t.me/USMLEWorldStep1

Anticonstipation agents	
Bulk-forming laxatives (eg, fiber supplements)	• Binds luminal water to decrease consistency of stool • Side effects: flatulence, abdominal distension
Osmotic laxatives (eg, polyethylene glycol, magnesium hydroxide, lactulose)	• Osmotically active agent that draws water into the lumen • Side effects: electrolyte disturbances, bloating
Surfactant (eg, docusate)	• Decreases stool surface tension, enabling water to enter stool • Side effects: rare
Stimulant laxatives (eg, bisacodyl, senna)	• Activates enteric nerves in myenteric plexus to stimulate peristalsis • Side effects: abdominal cramping, electrolyte disturbances
Chloride channel agonist (eg, lubiprostone)	• Causes chloride efflux into intestinal lumen, which is followed by sodium and water • Side effects: headache, nausea
Peripherally acting μ-opioid receptor antagonists (eg, methylnaltrexone)	• Counteracts inhibitory effect of opioids on peristalsis • Side effects: rare (does not cause opiate withdrawal)
*All constipation medications can cause diarrhea at high doses.	

This patient has **opioid-induced constipation** (OIC). Opiates (eg, oxycodone) exert their analgesic effects by binding to opiate receptors in the central and peripheral nervous systems, reducing nociceptive transmission and the perception of pain. Constipation, the most common side effect of opiate therapy, occurs due to the activation of **μ-opiate receptors** in the gastrointestinal tract. This results in decreased intestinal peristaltic activity and inhibition of ion and fluid secretion, leading to desiccated, pellet-like stool. Unlike many other opiate side effects, tolerance

https://t.me/USMLEWorldStep1

This patient has **opioid-induced constipation** (OIC). Opiates (eg, oxycodone) exert their analgesic effects by binding to opiate receptors in the central and peripheral nervous systems, reducing nociceptive transmission and the perception of pain. Constipation, the most common side effect of opiate therapy, occurs due to the activation of **μ-opiate receptors** in the gastrointestinal tract. This results in decreased intestinal peristaltic activity and inhibition of ion and fluid secretion, leading to desiccated, pellet-like stool. Unlike many other opiate side effects, tolerance to constipation does not readily occur. Therefore, all patients on opiate therapy should be considered for prophylactic laxative therapy (eg, docusate, polyethylene glycol, bisacodyl).

Those with refractory OIC may benefit from **methylnaltrexone**, a peripherally acting **μ-opioid receptor antagonist** that reverses the anti-peristaltic effect of opiates. It does not cross the blood-brain barrier; therefore, it **does not induce** opiate-related **withdrawal symptoms**, allowing for treatment of OIC without disrupting analgesic effects.

(Choices A and B) Diphenoxylate and loperamide are both opiate-based medications designed to inhibit peristalsis in the gastrointestinal tract. These medications are used to treat diarrhea and would worsen this patient's constipation.

(Choice C) Lubiprostone is a chloride channel agonist that increases intestinal secretions. Although it is not a μ-opioid receptor antagonist, it can be used to treat OIC and would not put patients at risk for opiate-related withdrawal.

(Choice E) Naloxone is also an opioid receptor antagonist; however, unlike methylnaltrexone, naloxone crosses the blood-brain barrier. It induces symptoms of withdrawal and reversal of analgesia and is used to treat acute opioid toxicity (eg, respiratory depression, somnolence).

Educational objective:
Constipation is the most common side effect of opiate therapy and occurs due to the binding of μ-opioid receptors in the gastrointestinal tract, which decreases intestinal motility and inhibits ion and fluid secretion. Methylnaltrexone, a peripherally acting μ-opioid receptor antagonist that does not cross the blood-brain barrier, can alleviate opioid-induced constipation without inducing opiate-related withdrawal symptoms.

References

https://t.me/USMLEWorldStep1

A 79-year-old woman is brought to the emergency department from the nursing home due to explosive diarrhea. Laboratory studies show leukocytosis, and results from a stool specimen return positive for *Clostridioides difficile*. Three days later, one of the nurses who cared for the patient at the nursing home is admitted with diarrhea and is found to have *C difficile* infection. However, the other nurses who also took care of the patient are asymptomatic and do not develop the infection. If all the nurses were similarly exposed to *C difficile*, which of the following is the most likely reason that the asymptomatic nurses did not develop the infection?

- A. Adequate pancreatic enzyme secretion
- B. Intact cell-mediated immunity
- C. Preformed antispore immunoglobulins
- D. Preserved intestinal microbiome
- E. Rapid gastrointestinal transit and expulsion of spores

Submit

https://t.me/USMLEWorldStep1

A 79-year-old woman is brought to the emergency department from the nursing home due to explosive diarrhea. Laboratory studies show leukocytosis, and results from a stool specimen return positive for *Clostridioides difficile*. Three days later, one of the nurses who cared for the patient at the nursing home is admitted with diarrhea and is found to have *C difficile* infection. However, the other nurses who also took care of the patient are asymptomatic and do not develop the infection. If all the nurses were similarly exposed to *C difficile*, which of the following is the most likely reason that the asymptomatic nurses did not develop the infection?

- A. Adequate pancreatic enzyme secretion (0%)
- ✕ B. Intact cell-mediated immunity (5%)
- C. Preformed antispore immunoglobulins (6%)
- ✓ D. Preserved intestinal microbiome (81%)
- E. Rapid gastrointestinal transit and expulsion of spores (5%)

Incorrect
Correct answer
D

81%
Answered correctly

04 secs
Time Spent

2023
Version

Explanation

Over 400 types of bacteria inhabit the healthy human gastrointestinal tract as part of the normal **intestinal microbiome**. In healthy individuals, a very small percentage of these are aerobes (eg, *Pseudomonas*), approximately 10% are facultative anaerobes (eg, *Escherichia coli, Klebsiella, Lactobacillus, Bacillus*), and the majority are strict anaerobes (eg, *Bacteroides, Fusobacterium*). These intestinal bacteria effectively **suppress overgrowth of *Clostridioides difficile*** and other potentially pathogenic bacteria by competing for nutrients and adhesion sites within the gut.

Alteration of the intestinal microbiome can lead to overgrowth of pathogenic strains and symptomatic *C difficile* infection (CDI). This most commonly occurs due to **antibiotic therapy** but can also be caused by **gastric acid**

https://t.me/USMLEWorldStep1

Over 400 types of bacteria inhabit the healthy human gastrointestinal tract as part of the normal **intestinal microbiome**. In healthy individuals, a very small percentage of these are aerobes (eg, *Pseudomonas*), approximately 10% are facultative anaerobes (eg, *Escherichia coli, Klebsiella, Lactobacillus, Bacillus*), and the majority are strict anaerobes (eg, *Bacteroides, Fusobacterium*). These intestinal bacteria effectively **suppress overgrowth of *Clostridioides difficile*** and other potentially pathogenic bacteria by competing for nutrients and adhesion sites within the gut.

Alteration of the intestinal microbiome can lead to overgrowth of pathogenic strains and symptomatic *C difficile* infection (CDI). This most commonly occurs due to **antibiotic therapy** but can also be caused by **gastric acid suppression** (eg, proton pump inhibitor use). *C difficile* causes disease by releasing 2 toxins that damage the mucosal lining of the large intestine, leading to diarrhea (toxin A) and necrosis (toxin B) with pseudomembrane formation.

(Choice A) Increased risk of CDI is seen with proton pump inhibitor use, suggesting that gastric acidity may have a protective role. However, there is no association between pancreatic enzyme secretion and CDI.

(Choice B) Cell-mediated immunity is not essential for prevention of CDI, but it is required to eradicate infections with intracellular agents that avoid the humoral (antibody) immune response (eg, *Legionella, Neisseria gonorrhoeae, Listeria monocytogenes*, viruses, *Leishmania*).

(Choice C) Individuals usually develop serum antibodies against *C difficile* toxins, not spores (the inactive, dormant form of the bacteria).

(Choice E) Rapid gastrointestinal transit is rarely effective at "washing away" pathogenic diarrhea-causing organisms as they are well adapted to adhering to the gut mucosa in the setting of voluminous diarrhea.

Educational objective:
Alteration of the normal intestinal microbial flora (eg, antibiotic therapy, gastric acid suppression) can allow overgrowth of pathogenic strains of *Clostridioides difficile*, which produce enterotoxin (toxin A) and cytotoxin (toxin B). Clinical disease can range from transient diarrhea to severe pseudomembranous colitis.

References

- The host immune response to Clostridium difficile infection.

https://t.me/USMLEWorldStep1

Over 400 types of bacteria inhabit the healthy human gastrointestinal tract as part of the normal **intestinal microbiome**. In healthy individuals, a very small percentage of these are aerobes (eg, *Pseudomonas*), approximately 10% are facultative anaerobes (eg, *Escherichia coli, Klebsiella, Lactobacillus, Bacillus*), and the majority are strict anaerobes (eg, *Bacteroides, Fusobacterium*). These intestinal bacteria effectively **suppress overgrowth of *Clostridioides difficile*** and other potentially pathogenic bacteria by competing for nutrients and adhesion sites within the gut.

Alteration of the intestinal microbiome can lead to overgrowth of pathogenic strains and symptomatic *C difficile* infection (CDI). This most commonly occurs due to **antibiotic therapy** but can also be caused by **gastric acid suppression** (eg, proton pump inhibitor use). *C difficile* causes disease by releasing 2 toxins that damage the mucosal lining of the large intestine, leading to diarrhea (toxin A) and necrosis (toxin B) with pseudomembrane formation.

(Choice A) Increased risk of CDI is seen with proton pump inhibitor use, suggesting that gastric acidity may have a protective role. However, there is no association between pancreatic enzyme secretion and CDI.

(Choice B) Cell-mediated immunity is not essential for prevention of CDI, but it is required to eradicate infections with intracellular agents that avoid the humoral (antibody) immune response (eg, *Legionella, Neisseria gonorrhoeae, Listeria monocytogenes*, viruses, *Leishmania*).

(Choice C) Individuals usually develop serum antibodies against *C difficile* toxins, not spores (the inactive, dormant form of the bacteria).

(Choice E) Rapid gastrointestinal transit is rarely effective at "washing away" pathogenic diarrhea-causing organisms as they are well adapted to adhering to the gut mucosa in the setting of voluminous diarrhea.

Educational objective:
Alteration of the normal intestinal microbial flora (eg, antibiotic therapy, gastric acid suppression) can allow overgrowth of pathogenic strains of *Clostridioides difficile*, which produce enterotoxin (toxin A) and cytotoxin (toxin B). Clinical disease can range from transient diarrhea to severe pseudomembranous colitis.

References

- The host immune response to Clostridium difficile infection.

https://t.me/USMLEWorldStep1

A 34-year-old woman is found dead in her apartment. An autopsy examination is performed. A ruptured plaque in the proximal anterior descending artery with an overlying occlusive thrombus is found. Incidentally, a 4-cm hepatic mass in the right lobe of the liver is also found. Grossly, the mass is well demarcated from the surrounding liver tissue and appears nodular with a central, gray-white, depressed stellate scar from which fibrous septa radiate to the periphery. The rest of the liver is normal. No additional abnormalities are noted on autopsy. Which of the following is the most likely diagnosis of this patient's liver lesion?

- A. Focal nodular hyperplasia
- B. Hepatic hemangioma
- C. Hepatocellular adenoma
- D. Hepatocellular carcinoma

Submit

https://t.me/USMLEWorldStep1

A 34-year-old woman is found dead in her apartment. An autopsy examination is performed. A ruptured plaque in the proximal anterior descending artery with an overlying occlusive thrombus is found. Incidentally, a 4-cm hepatic mass in the right lobe of the liver is also found. Grossly, the mass is well demarcated from the surrounding liver tissue and appears nodular with a central, gray-white, depressed stellate scar from which fibrous septa radiate to the periphery. The rest of the liver is normal. No additional abnormalities are noted on autopsy. Which of the following is the most likely diagnosis of this patient's liver lesion?

- ✓ A. Focal nodular hyperplasia (49%)
- ✗ B. Hepatic hemangioma (10%)
- C. Hepatocellular adenoma (27%)
- D. Hepatocellular carcinoma (12%)

Incorrect
Correct answer
A

49%
Answered correctly

03 secs
Time Spent

2023
Version

Explanation

This patient's incidentally found liver mass is characteristic of **focal nodular hyperplasia** (FNH), a nonneoplastic lesion that most commonly occurs in **young women**. FNH is thought to result from a hepatic vascular abnormality causing localized hyperperfusion with a secondary hyperplastic response. It grossly appears as a well-circumscribed, solitary mass with a characteristic **central stellate scar** from which fibrous septa radiate to the periphery. On microscopic examination, the fibrous septa—which enclose abnormally large, thick-walled arterial branches—divide the lesion into **nodules** composed of plates of normal-appearing hepatocytes.

FNH is **benign** and typically does not enlarge, undergo malignant transformation, or rupture; therefore, most cases do not require treatment. These lesions are usually **asymptomatic** and discovered incidentally during autopsy examination or abdominal imaging for a different condition.

https://t.me/USMLEWorldStep1

Explanation

This patient's incidentally found liver mass is characteristic of **focal nodular hyperplasia** (FNH), a nonneoplastic lesion that most commonly occurs in **young women**. FNH is thought to result from a hepatic vascular abnormality causing localized hyperperfusion with a secondary hyperplastic response. It grossly appears as a well-circumscribed, solitary mass with a characteristic **central stellate scar** from which fibrous septa radiate to the periphery. On microscopic examination, the fibrous septa—which enclose abnormally large, thick-walled arterial branches—divide the lesion into **nodules** composed of plates of normal-appearing hepatocytes.

FNH is **benign** and typically does not enlarge, undergo malignant transformation, or rupture; therefore, most cases do not require treatment. These lesions are usually **asymptomatic** and discovered incidentally during autopsy examination or abdominal imaging for a different condition.

(Choice B) Hepatic hemangioma is the most common benign hepatic lesion but typically appears as a well-circumscribed, red-brown, spongy subcapsular mass with areas of hemorrhage. Histopathology shows cavernous vascular compartments lined by endothelial cells and filled with red blood cells.

(Choice C) Hepatocellular adenoma is a benign liver lesion that is strongly associated with oral contraceptive use that may undergo malignant transformation or rupture. Although it can also be discovered incidentally, a hepatocellular adenoma usually appears as a well-circumscribed, solitary mass *without a central scar*. Histopathology typically shows hepatocytes without atypia and an absence of normal hepatic architecture (no portal structures or bile ducts).

(Choice D) Hepatocellular carcinoma (HCC) is a malignant liver tumor that usually develops in older patients in the setting of underlying chronic liver disease (eg, chronic viral hepatitis, alcohol-induced cirrhosis), and patients are often symptomatic at presentation (eg, abdominal pain, elevated liver function tests). HCC can have variable appearances on gross examination (eg, solitary or multiple tan, yellow, or green masses); however, the background liver parenchyma is usually cirrhotic.

Educational objective:
Focal nodular hyperplasia is a benign liver lesion marked by a central stellate scar with radiating fibrous septa that microscopically contain abnormally large, thick-walled arteries. It usually arises in asymptomatic young women,

https://t.me/USMLEWorldStep1

lesion that most commonly occurs in **young women**. FNH is thought to result from a hepatic vascular abnormality causing localized hyperperfusion with a secondary hyperplastic response. It grossly appears as a well-circumscribed, solitary mass with a characteristic **central stellate scar** from which fibrous septa radiate to the periphery. On microscopic examination, the fibrous septa—which enclose abnormally large, thick-walled arterial branches—divide the lesion into **nodules** composed of plates of normal-appearing hepatocytes.

FNH is **benign** and typically does not enlarge, undergo malignant transformation, or rupture; therefore, most cases do not require treatment. These lesions are usually **asymptomatic** and discovered incidentally during autopsy examination or abdominal imaging for a different condition.

(Choice B) Hepatic hemangioma is the most common benign hepatic lesion but typically appears as a well-circumscribed, red-brown, spongy subcapsular mass with areas of hemorrhage. Histopathology shows cavernous vascular compartments lined by endothelial cells and filled with red blood cells.

(Choice C) Hepatocellular adenoma is a benign liver lesion that is strongly associated with oral contraceptive use that may undergo malignant transformation or rupture. Although it can also be discovered incidentally, a hepatocellular adenoma usually appears as a well-circumscribed, solitary mass *without a central scar*. Histopathology typically shows hepatocytes without atypia and an absence of normal hepatic architecture (no portal structures or bile ducts).

(Choice D) Hepatocellular carcinoma (HCC) is a malignant liver tumor that usually develops in older patients in the setting of underlying chronic liver disease (eg, chronic viral hepatitis, alcohol-induced cirrhosis), and patients are often symptomatic at presentation (eg, abdominal pain, elevated liver function tests). HCC can have variable appearances on gross examination (eg, solitary or multiple tan, yellow, or green masses); however, the background liver parenchyma is usually cirrhotic.

Educational objective:
Focal nodular hyperplasia is a benign liver lesion marked by a central stellate scar with radiating fibrous septa that microscopically contain abnormally large, thick-walled arteries. It usually arises in asymptomatic young women, and most cases are found incidentally.

Pathology	Gastrointestinal & Nutrition	Focal nodular hyperplasia
Subject	System	Topic

https://t.me/USMLEWorldStep1

Incorrect
Correct answer
A

49%
03 secs
2023

Exhibit Display

Focal nodular hyperplasia

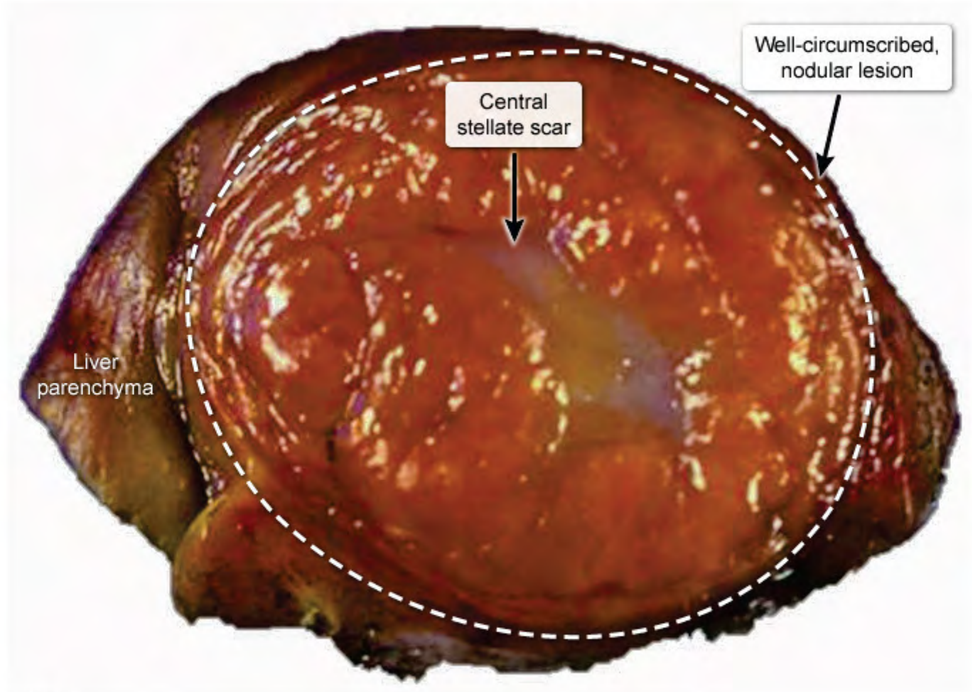

©UWorld

Zoom In | Zoom Out | Reset | New | Existing | My Notebook

Expl

This p
lesion
causin
circum
periph
branch

FNH is
do not
exami

(Choi
circum
vascul

(Choi
that m
hepato
Histop
portal

(Choi
the se
are oft
appearances on gross examination (eg, solitary or multiple tan, yellow, or green masses); however, the background liver parenchyma is usually cirrhotic.

https://t.me/USMLEWorldStep1

Incorrect
Correct answer
A

49%
03 secs
2023

Exhibit Display

Focal nodular hyperplasia

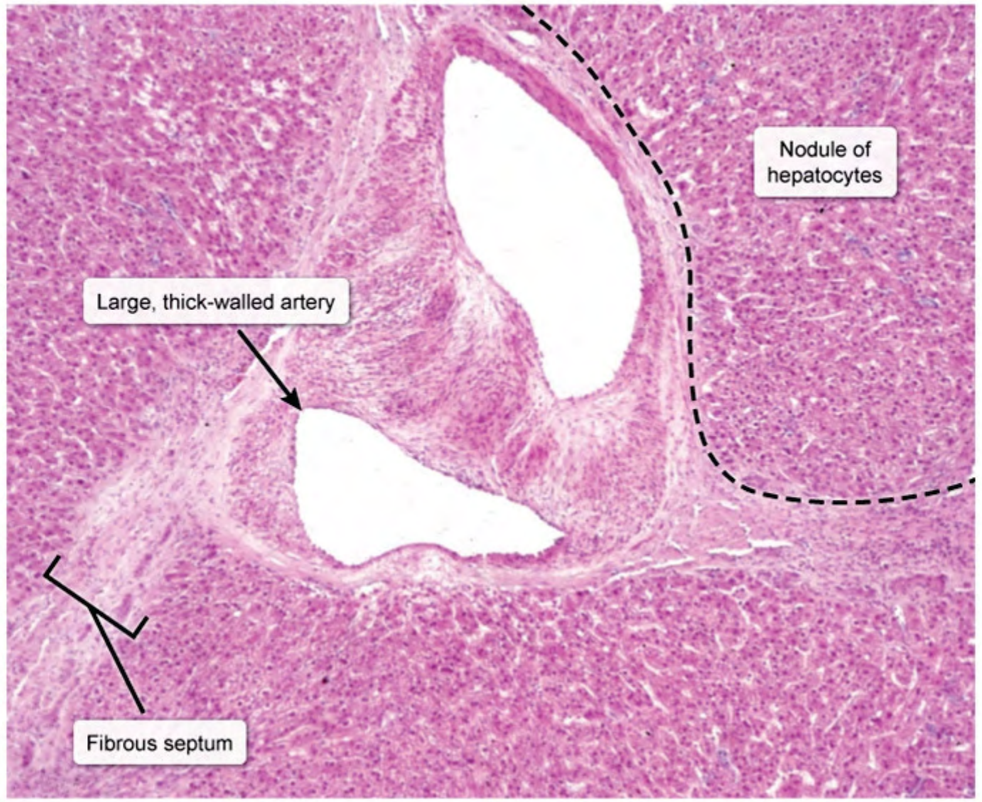

Zoom In | Zoom Out | Reset | New | Existing | My Notebook

Expl

This p
lesion
causin
circum
periph
branch

FNH is
do not
exami

(Choi
circum
vascul

(Choi
that m
hepato
Histop
portal

(Choi
the se
are oft
appearances on gross examination (eg, solitary or multiple tan, yellow, or green masses); however, the background liver parenchyma is usually cirrhotic.

https://t.me/USMLEWorldStep1

Incorrect
Correct answer
A

49%
03 secs
2023

Expl

This p
lesion
causin
circum
periph
branch

FNH is
do not
exami

(Choi
circum
vascul

(Choi
that m
hepato
Histop
portal

(Choi
the se
are oft
appearances on gross examination (eg, solitary or multiple tan, yellow, or green masses); however, the background liver parenchyma is usually cirrhotic.

Exhibit Display

Hepatic cavernous hemangioma

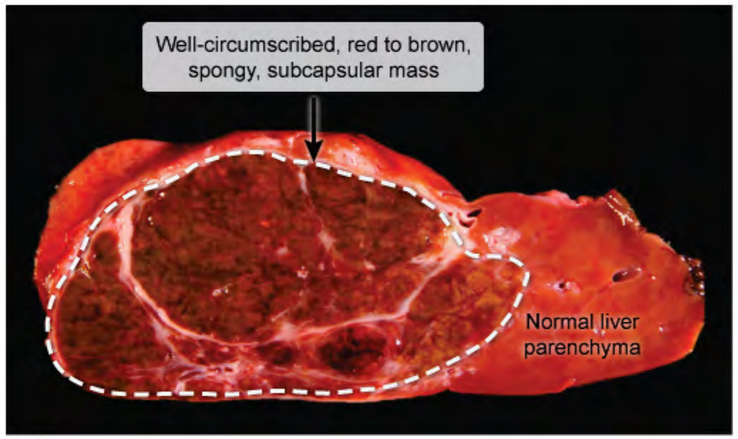

©UWorld

Zoom In
Zoom Out
Reset
New | Existing
My Notebook

https://t.me/USMLEWorldStep1

Incorrect
Correct answer
A

49%
03 secs
2023

Exhibit Display

Hepatic cavernous hemangioma

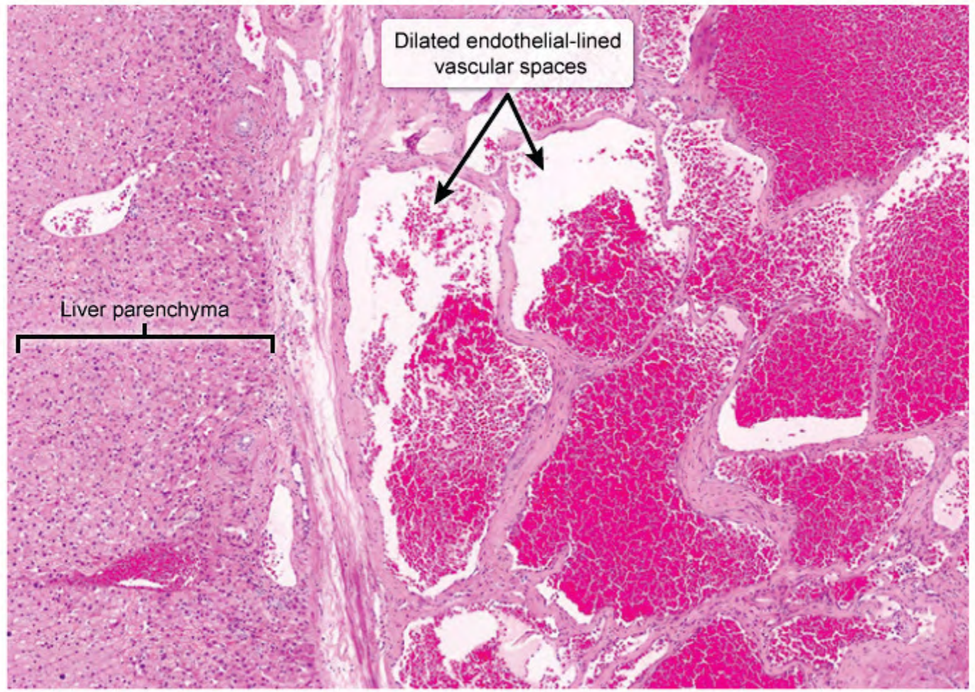

©UWorld

Zoom In | Zoom Out | Reset | New | Existing | My Notebook

Expl

This p
lesion
causin
circum
periph
branch

FNH is
do not
exami

(Choi
circum
vascul

(Choi
that m
hepato
Histop
portal

(Choi
the se
are oft
appearances on gross examination (eg, solitary or multiple tan, yellow, or green masses); however, the background liver parenchyma is usually cirrhotic.

https://t.me/USMLEWorldStep1

Incorrect
Correct answer
A

49%
03 secs
2023

Exhibit Display

Hepatocellular adenoma

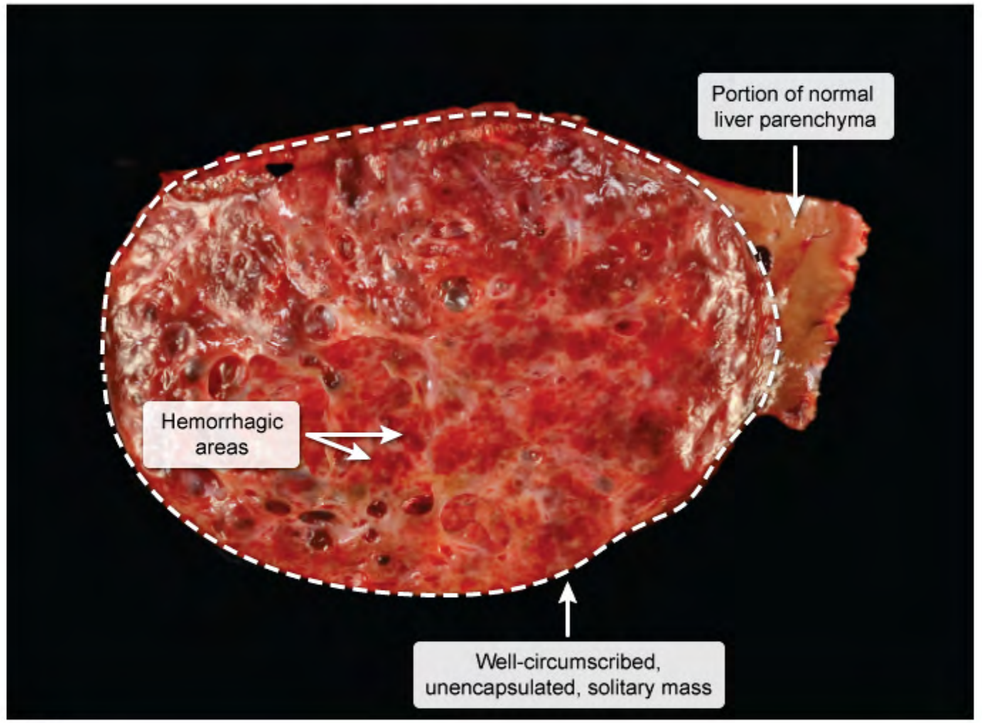

©UWorld

Zoom In | Zoom Out | Reset | New | Existing | My Notebook

Expl

This p
lesion
causin
circum
periph
branch

FNH is
do not
exami

(Choi
circum
vascul

(Choi
that m
hepato
Histop
portal

(Choi
the se
are oft
appearances on gross examination (eg, solitary or multiple tan, yellow, or green masses); however, the background liver parenchyma is usually cirrhotic.

https://t.me/USMLEWorldStep1

Explanation

Exhibit Display

Hepatocellular adenoma

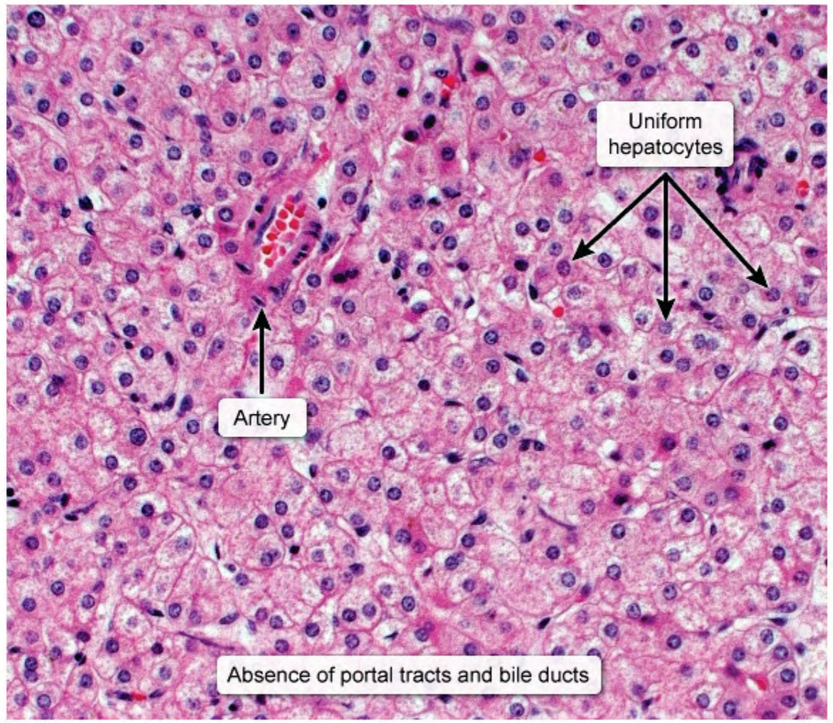

©UWorld

Zoom In | Zoom Out | Reset | New | Existing | My Notebook

This p
lesion
causin
circum
periph
branch

FNH is
do not
exami

(Choi
circum
vascul

(Choi
that m
hepato
Histop
portal

(Choi
the se
are oft
appea
backgr

Educa
Focal nodular hyperplasia is a benign liver lesion marked by a central stellate scar with radiating fibrous septa that microscopically contain abnormally large, thick-walled arteries. It usually arises in asymptomatic young women,

https://t.me/USMLEWorldStep1

Explanation

Exhibit Display

Hepatocellular adenoma

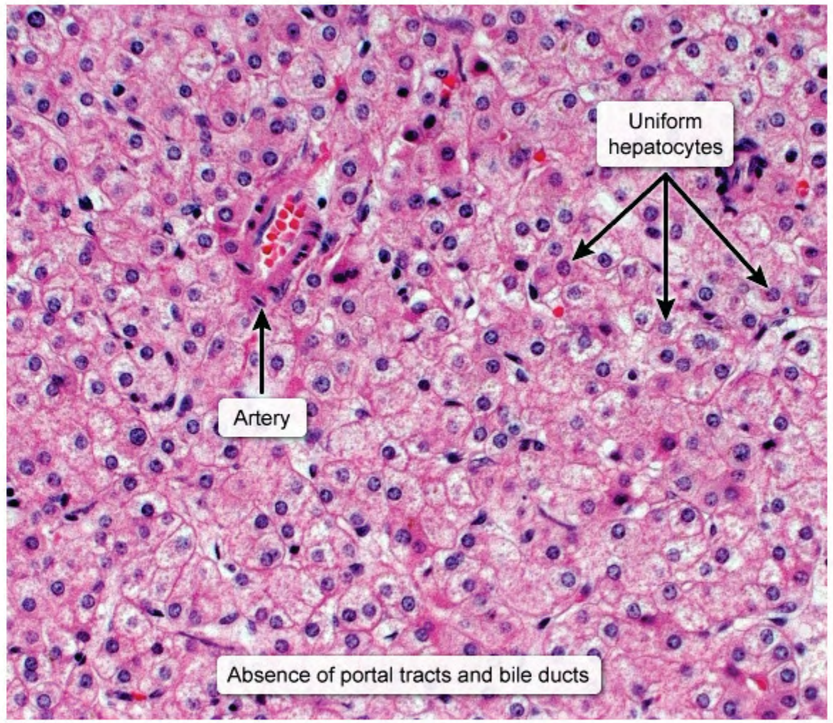

©UWorld

Zoom In | Zoom Out | Reset | New | Existing | My Notebook

This p
lesion
causin
circum
periph
branch

FNH is
do not
exami

(Choi
circum
vascul

(Choi
that m
hepato
Histop
portal

(Choi
the se
are oft
appea
backgr

Educa
Focal nodular hyperplasia is a benign liver lesion marked by a central stellate scar with radiating fibrous septa that microscopically contain abnormally large, thick-walled arteries. It usually arises in asymptomatic young women,

https://t.me/USMLEWorldStep1

Explanation

This p
lesion
causin
circum
periph
branch

FNH is
do not
exami

(Choi
circum
vascul

(Choi
that m
hepato
Histop
portal

(Choi
the se
are oft
appea
backg

Educa
Focal nodular hyperplasia is a benign liver lesion marked by a central stellate scar with radiating fibrous septa that microscopically contain abnormally large, thick-walled arteries. It usually arises in asymptomatic young women,

Exhibit Display

Hepatocellular carcinoma



©UWorld

Zoom In | Zoom Out | Reset | New | Existing | My Notebook

https://t.me/USMLEWorldStep1

A 54-year-old man comes to the office due to epigastric pain and unexpected weight loss. Medical and family history are unremarkable. Vital signs are within normal limits. The abdomen is tender to palpation over the epigastrium. Abdominal CT demonstrates a multinodular mass in the pancreas, which is subsequently biopsied. The histologic specimen is shown in the image below:

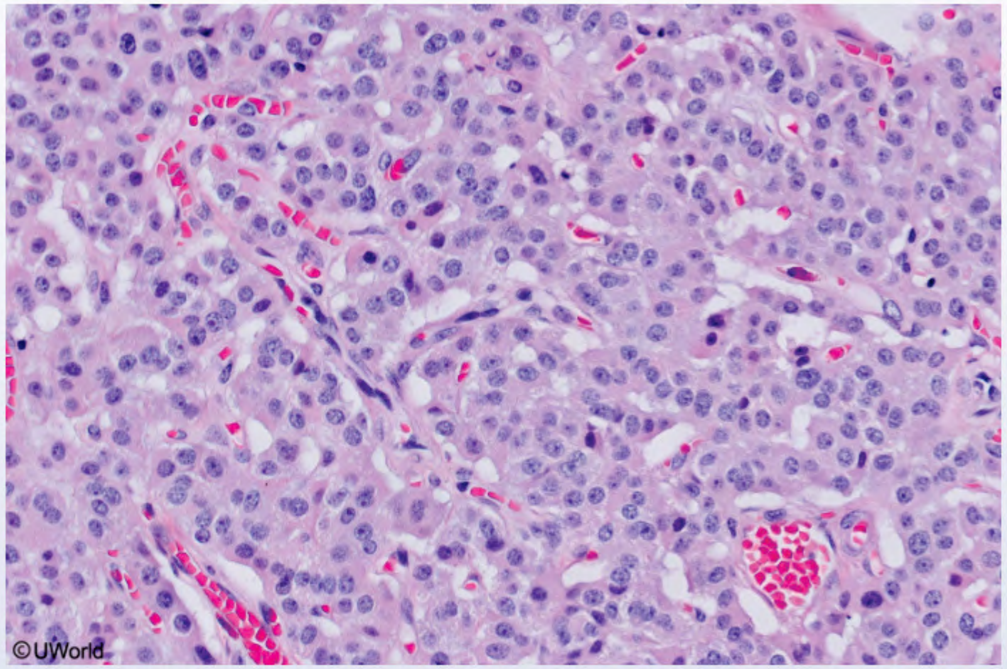

Immunohistochemical staining for synaptophysin and chromogranin A is diffusely positive. Which of the following is the most likely diagnosis?

- A. Ductal adenocarcinoma of the pancreas
- B. Metastatic colonic adenocarcinoma
- C. Metastatic melanoma
- D. Neuroendocrine tumor of the pancreas

https://t.me/USMLEWorldStep1

A 54-year-old man comes to the office due to epigastric pain and unexpected weight loss. Medical and family history
epigas
The hi

Exhibit Display

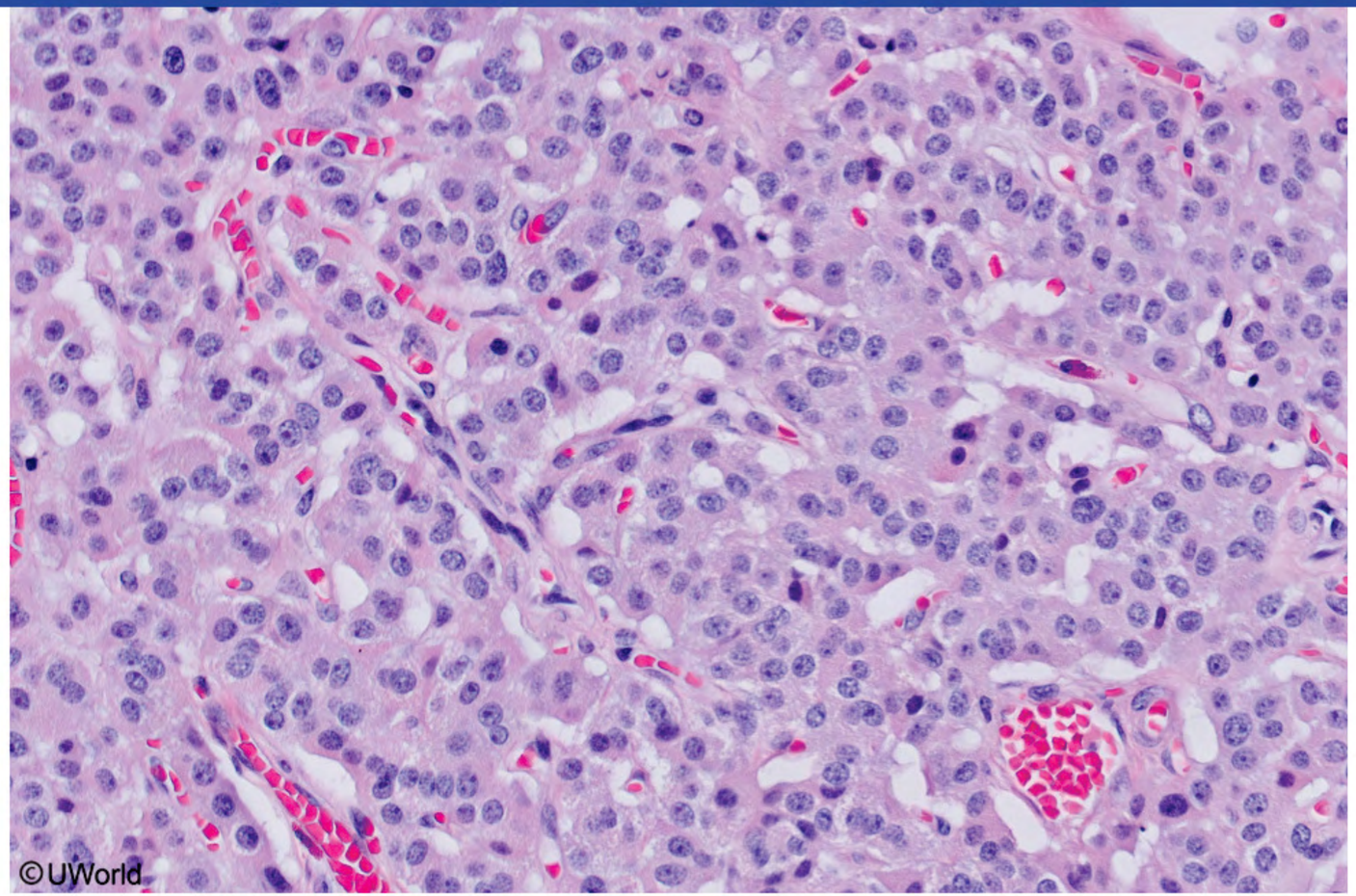

Zoom In | Zoom Out | Reset | New | Existing | My Notebook

Immur
the mo

D. Neuroendocrine tumor of the pancreas

https://t.me/USMLEWorldStep1

The histologic specimen is shown in the image below:

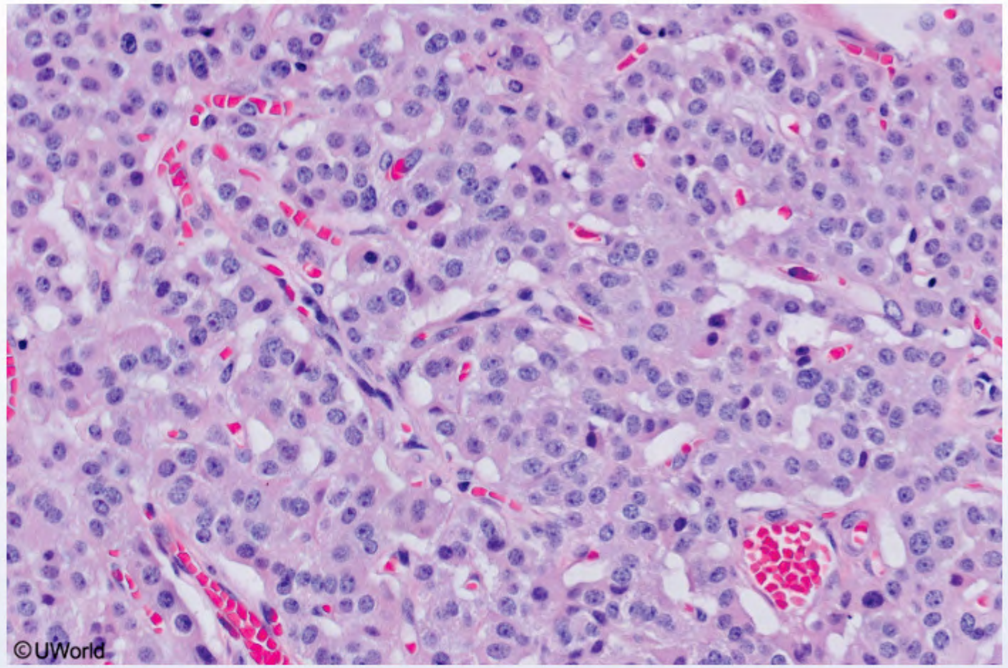

Immunohistochemical staining for synaptophysin and chromogranin A is diffusely positive. Which of the following is the most likely diagnosis?

- A. Ductal adenocarcinoma of the pancreas
- B. Metastatic colonic adenocarcinoma
- C. Metastatic melanoma
- D. Neuroendocrine tumor of the pancreas
- E. Schwannoma

Submit

https://t.me/USMLEWorldStep1

The histologic specimen is shown in the image below:

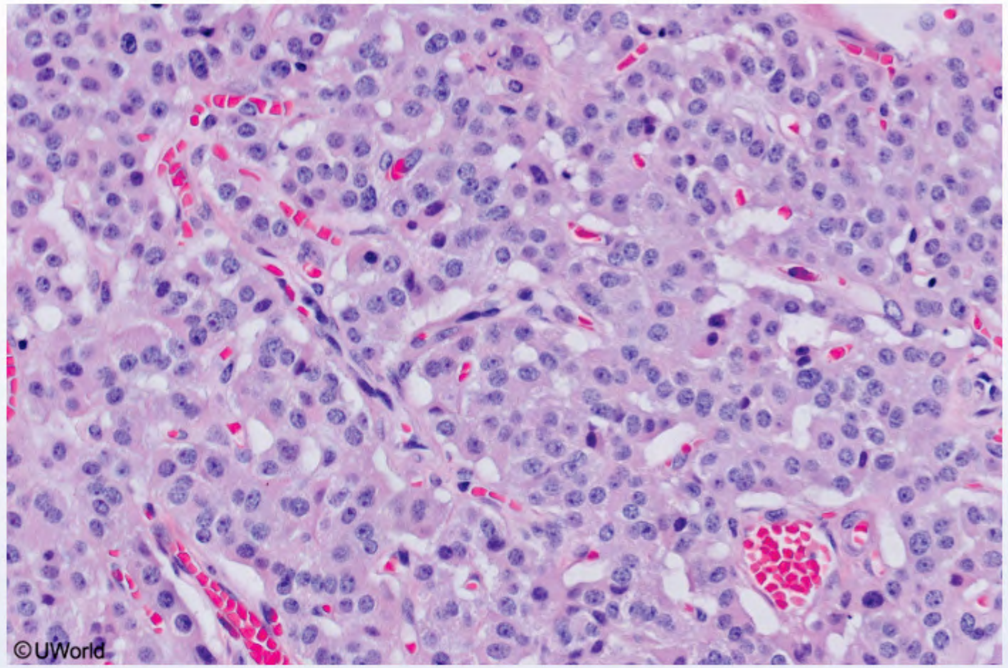

Immunohistochemical staining for synaptophysin and chromogranin A is diffusely positive. Which of the following is the most likely diagnosis?

- A. Ductal adenocarcinoma of the pancreas (10%)
- ✗ B. Metastatic colonic adenocarcinoma (2%)
- C. Metastatic melanoma (2%)
- ✓ D. Neuroendocrine tumor of the pancreas (82%)
- E. Schwannoma (1%)

Incorrect
Correct answer
D

82%
Answered correctly

15 secs
Time Spent

2023
Version

https://t.me/USMLEWorldStep1

Incorrect
Correct answer
D

82%
Answered correctly

15 secs
Time Spent

2023
Version

Explanation

This patient has a **pancreatic neuroendocrine tumor** (PanNET), a neoplasm derived from pancreatic islet cells. Although functional PanNETs can secrete peptide hormones and cause specific clinical syndromes (eg, insulinoma, gastrinoma, glucagonoma, VIPoma), others do not and are classified as **nonfunctional**. Nonfunctional PanNETs, as seen in this patient, tend to present with symptoms related to tumor enlargement and metastasis (eg, **epigastric pain**, **weight loss**, jaundice, palpable mass).

Both functional and nonfunctional PanNETs are typically characterized by a well-circumscribed lesion composed of uniform tumor cells with an **organoid architecture** (eg, nested, glandular, ribbon, or pseudorosette arrangement). The cells have round nuclei with characteristic stippled (ie, **salt and pepper**) chromatin, as well as granular cytoplasm. Immunohistochemical staining for **synaptophysin** (protein in neuroendocrine synaptic vesicles) and **chromogranin A** (protein found within neuroendocrine secretory granules) often shows positive cytoplasmic staining and aids in making the diagnosis.

(Choice A) Pancreatic ductal adenocarcinoma is characterized by haphazardly arranged, infiltrative glands composed of pleomorphic cells and surrounded by dense stromal fibrosis (ie, desmoplasia); synaptophysin and chromogranin A staining is negative.

(Choice B) Colonic adenocarcinoma most commonly metastasizes to the liver and lungs, bone, and CNS; isolated involvement of the pancreas is rare. Biopsies may reveal mucin production or glandular formation, and synaptophysin and chromogranin A staining would not be diffusely positive.

(Choice C) Metastatic melanoma is characterized by atypical cells that often have prominent nucleoli and may contain intracellular brown-black pigment (ie, melanin granules). The cells stain positive for S100 (a protein expressed by neural crest–derived cells), HMB-45 (a monoclonal antibody that binds to immature melanosomes), and SOX10 (a transcription factor found in neural crest–derived cells).

(Choice E) Schwannomas are peripheral nerve tumors characterized by densely (Antoni type A) or loosely (Antoni

https://t.me/USMLEWorldStep1

Both functional and nonfunctional PanNETs are typically characterized by a well-circumscribed lesion composed of uniform tumor cells with an **organoid architecture** (eg, nested, glandular, ribbon, or pseudorosette arrangement). The cells have round nuclei with characteristic stippled (ie, **salt and pepper**) chromatin, as well as granular cytoplasm. Immunohistochemical staining for **synaptophysin** (protein in neuroendocrine synaptic vesicles) and **chromogranin A** (protein found within neuroendocrine secretory granules) often shows positive cytoplasmic staining and aids in making the diagnosis.

(Choice A) Pancreatic ductal adenocarcinoma is characterized by haphazardly arranged, infiltrative glands composed of pleomorphic cells and surrounded by dense stromal fibrosis (ie, desmoplasia); synaptophysin and chromogranin A staining is negative.

(Choice B) Colonic adenocarcinoma most commonly metastasizes to the liver and lungs, bone, and CNS; isolated involvement of the pancreas is rare. Biopsies may reveal mucin production or glandular formation, and synaptophysin and chromogranin A staining would not be diffusely positive.

(Choice C) Metastatic melanoma is characterized by atypical cells that often have prominent nucleoli and may contain intracellular brown-black pigment (ie, melanin granules). The cells stain positive for S100 (a protein expressed by neural crest–derived cells), HMB-45 (a monoclonal antibody that binds to immature melanosomes), and SOX10 (a transcription factor found in neural crest–derived cells).

(Choice E) Schwannomas are peripheral nerve tumors characterized by densely (Antoni type A) or loosely (Antoni type B) arranged spindle-shaped cells that may show nuclear palisading (ie, Verocay bodies). These tumors almost always express S100 due to their embryonic neural crest origins; SOX10 may also be identified. Schwannomas do not express synaptophysin or chromogranin A.

Educational objective:
Functional (eg, insulinoma, gastrinoma, glucagonoma, VIPoma) and nonfunctional pancreatic neuroendocrine tumors are histologically characterized by uniform tumor cells with an organoid architecture (eg, nested, glandular, ribbon, or pseudorosette arrangement). The cells have characteristic salt-and-pepper chromatin, as well as granular cytoplasm, and stain positive for synaptophysin and chromogranin A.

References

https://t.me/USMLEWorldStep1

Incorrect
Correct answer
D

82%
Answered correctly

15 secs
Time Spent

2023
Version

Exhibit Display

Pancreatic neuroendocrine tumor

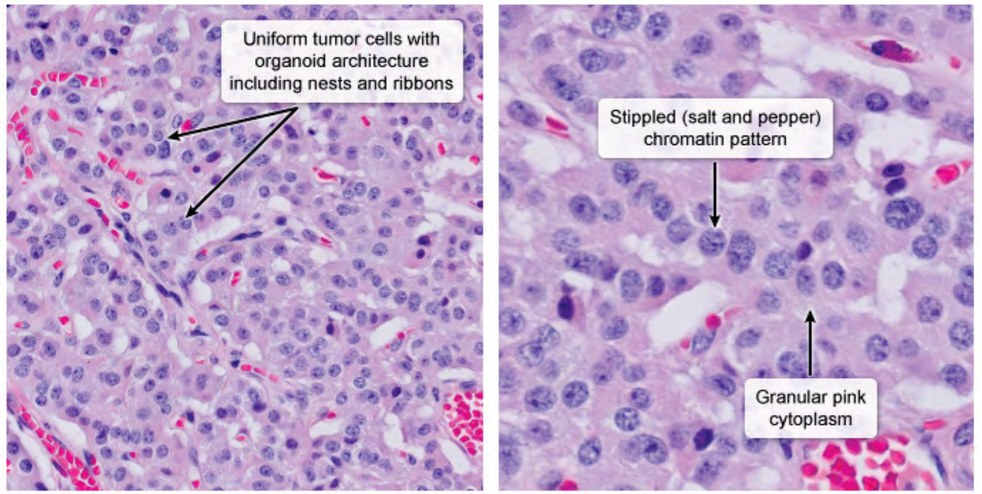

©UWorld

Zoom In | Zoom Out | Reset | New | Existing | My Notebook

Expl

This p
Althou
insulin
Nonfu
metas

Both f
uniform
The ce
cytopla
chrom
stainin

(Choi
compo
chrom

(Choi
involve
synapt

(Choi
contai
expres
and SOX10 (a transcription factor found in neural crest–derived cells).

(Choice E) Schwannomas are peripheral nerve tumors characterized by densely (Antoni type A) or loosely (Antoni

https://t.me/USMLEWorldStep1

Incorrect
Correct answer
D

82%
Answered correctly

15 secs
Time Spent

2023
Version

Exhibit Display

Pancreatic neuroendocrine tumor

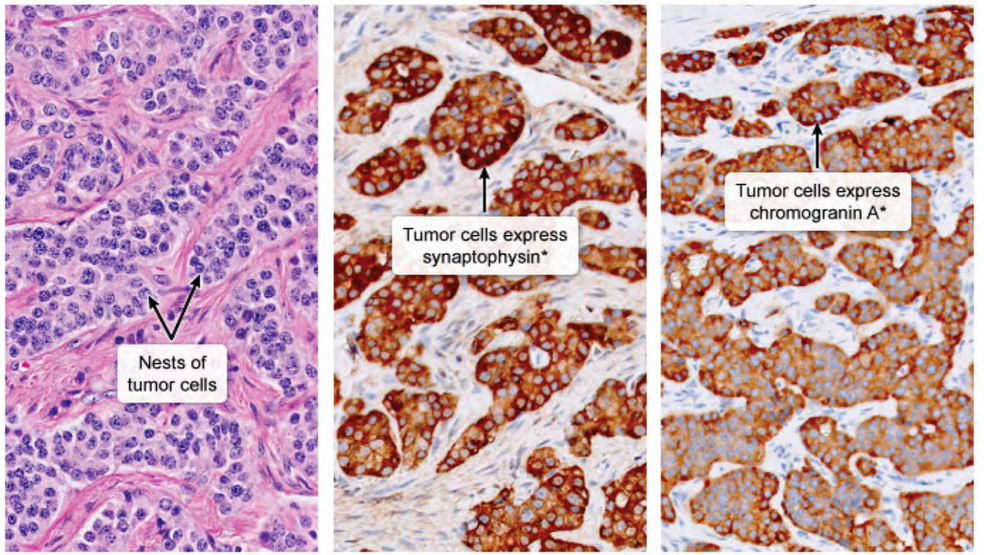

*Marker of neuroendocrine differentiation.

©UWorld

Zoom In | Zoom Out | Reset | New | Existing | My Notebook

Expl

This p
Althou
insulin
Nonfu
metas

Both f
uniform
The ce
cytopla
chrom
stainin

(Choi
compo
chrom

(Choi
involve
synapt

(Choi
contai
expres
and SOX10 (a transcription factor found in neural crest–derived cells).

(Choice E) Schwannomas are peripheral nerve tumors characterized by densely (Antoni type A) or loosely (Antoni

https://t.me/USMLEWorldStep1

Incorrect
Correct answer
D

82%
Answered correctly

15 secs
Time Spent

2023
Version

Exhibit Display

Pancreatic ductal adenocarcinoma

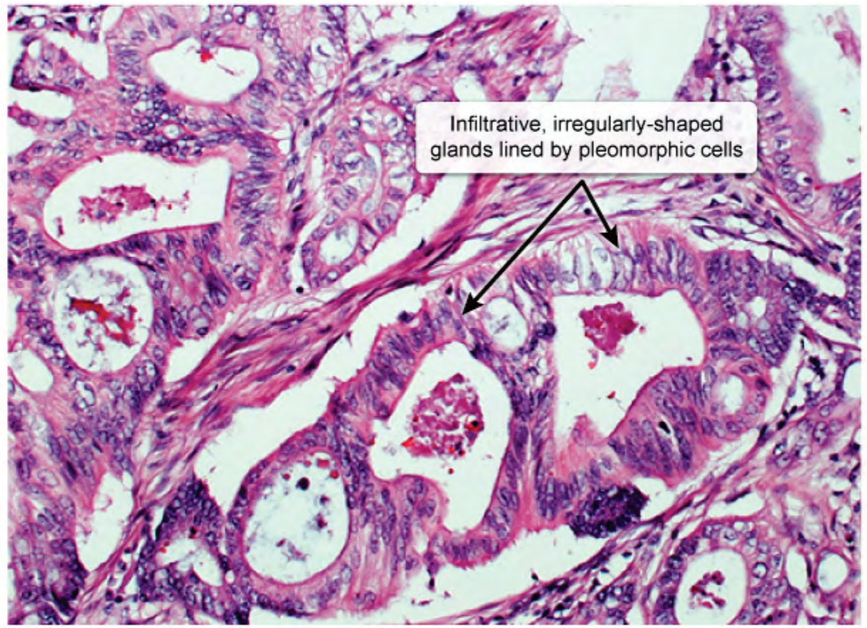

©UWorld

Zoom In | Zoom Out | Reset | New | Existing | My Notebook

Expl

This p
Althou
insulin
Nonfu
metas

Both f
uniform
The ce
cytopla
chrom
stainin

(Choi
compo
chrom

(Choi
involve
synap

(Choi
contai
expres
and SOX10 (a transcription factor found in neural crest–derived cells).

(Choice E) Schwannomas are peripheral nerve tumors characterized by densely (Antoni type A) or loosely (Antoni

https://t.me/USMLEWorldStep1

Incorrect
Correct answer
D

82%
Answered correctly

15 secs
Time Spent

2023
Version

Exhibit Display

Colonic adenocarcinoma with mucinous differentiation

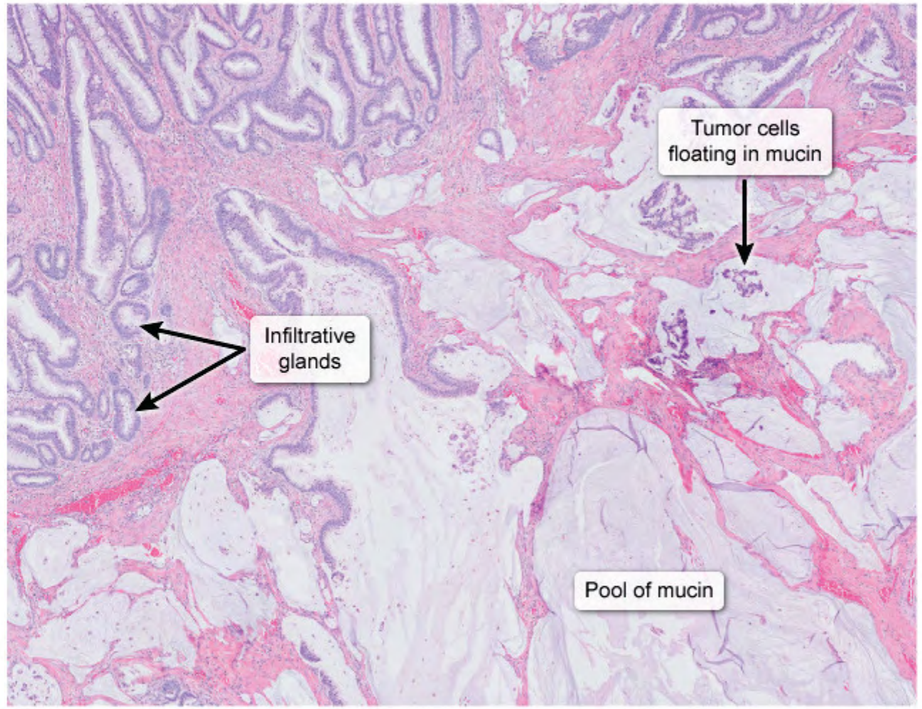

©UWorld

Zoom In | Zoom Out | Reset | New | Existing | My Notebook

Expl

This p
Althou
insulin
Nonfu
metas

Both f
uniform
The ce
cytopla
chrom
stainin

(Choi
compo
chrom

(Choi
involve
synapt

(Choi
contai
expres
and SOX10 (a transcription factor found in neural crest–derived cells).

(Choice E) Schwannomas are peripheral nerve tumors characterized by densely (Antoni type A) or loosely (Antoni

https://t.me/USMLEWorldStep1

Explanation

Exhibit Display

Melanoma

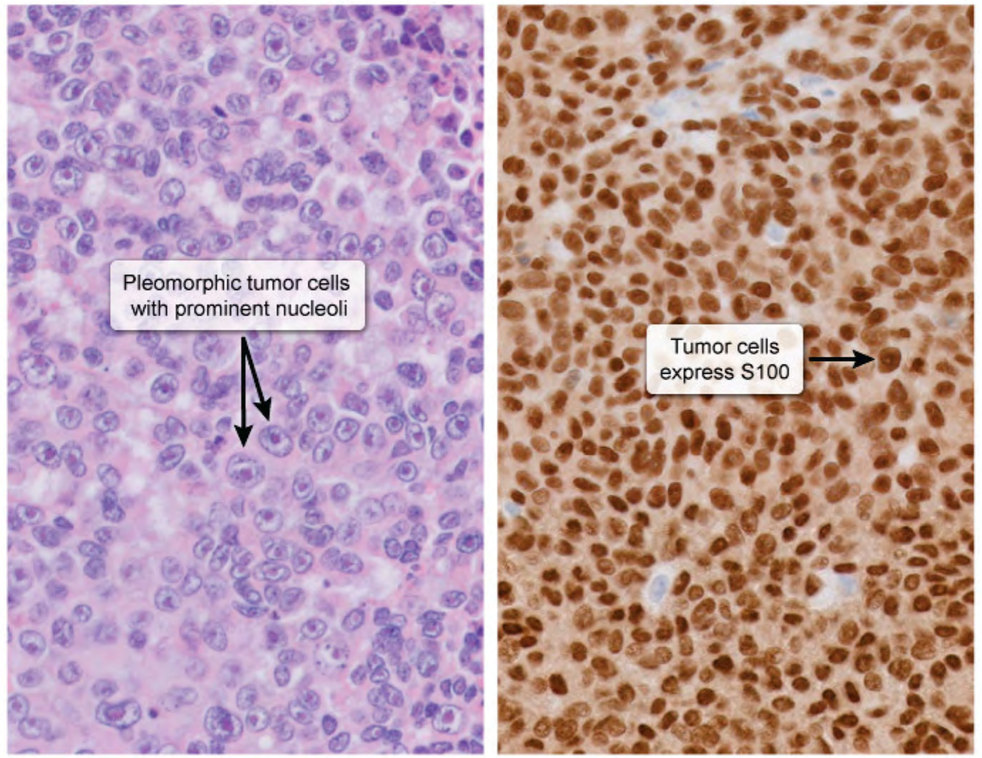

H&E stain

S100 stain (marker of neural crest origin)

©UWorld

Zoom In | Zoom Out | Reset | New | Existing | My Notebook

This p
Althou
insulin
Nonfu
metas

Both f
uniform
The ce
cytopla
chrom
stainin

(Choi
compo
chrom

(Choi
involve
synapt

(Choi
contai
expres
and S

(Choi
type B
almost always express S100 due to their embryonic neural crest origins; SOX10 may also be identified.
Schwannomas do not express synaptophysin or chromogranin A.

https://t.me/USMLEWorldStep1

Although functional PanNETs can secrete peptide hormones and cause specific clinical syndromes (eg, insulinoma, gastrinoma, glucagonoma, VIPoma), others do not and are classified as **nonfunctional**.

Nonfu
metas

Both f
uniform
The ce
cytopla
chrom
stainin

(Choi
compo
chrom

(Choi
involve
synapt

(Choi
contai
expres
and S

(Choi
type B
almost
Schwa

Educa
Functional (eg, insulinoma, gastrinoma, glucagonoma, VIPoma) and nonfunctional pancreatic neuroendocrine tumors are histologically characterized by uniform tumor cells with an organoid architecture (eg, nested, glandular,

Exhibit Display

Schwannoma

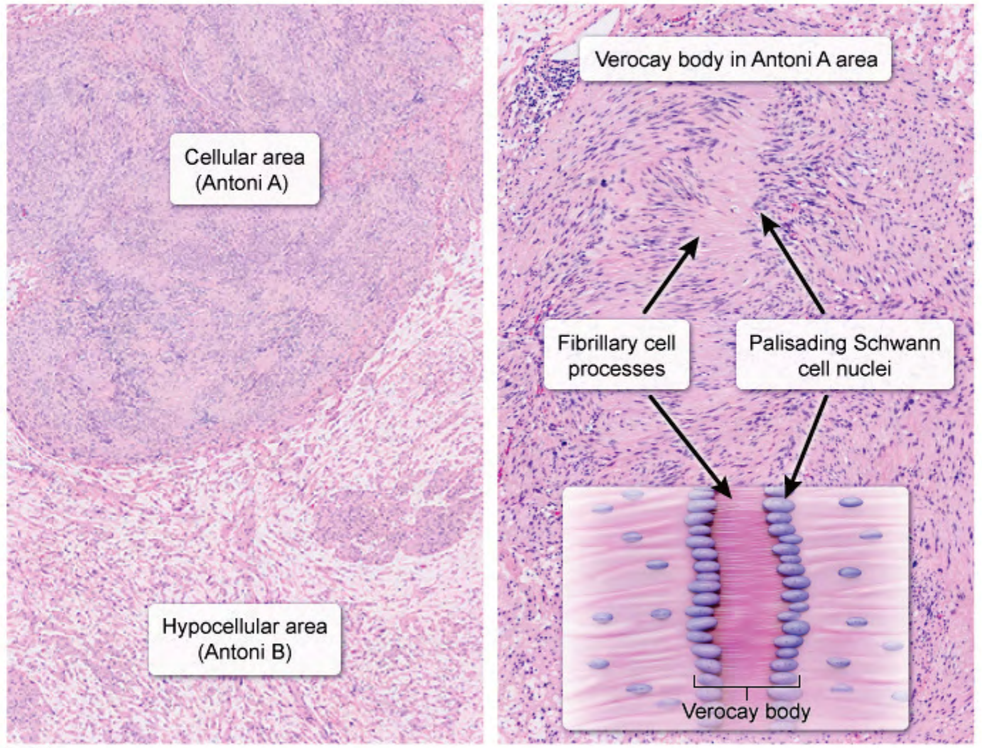

©UWorld

Zoom In | Zoom Out | Reset | New | Existing | My Notebook

https://t.me/USMLEWorldStep1

A 64-year-old man comes to the office due to acute-onset right upper quadrant abdominal pain, nausea, and vomiting. The patient had an extensive small bowel resection due to bowel ischemia a year ago and has been receiving total parenteral nutrition since then. His other medical problems include atrial fibrillation and hypertension. Examination shows right upper quadrant tenderness on deep palpation. Initial laboratory studies show moderate leukocytosis with normal hepatic transaminase, amylase, and lipase levels. Abdominal ultrasonography reveals gallstones and edema of the gallbladder wall. Review of prior records indicates that he had no gallstones noted on abdominal imaging performed prior to the bowel resection. Which of the following is most likely responsible for the development of gallstones in this patient?

- A. Decreased cholecystokinin release due to lack of enteral stimulation
- B. Decreased cholesterol conversion to bile acids due to liver dysfunction
- C. High cholesterol content of the nutritional fluids
- D. Inadequate supplementation of essential fatty acids
- E. Increased gastrin release in response to parenteral amino acids

Submit

https://t.me/USMLEWorldStep1

A 64-year-old man comes to the office due to acute-onset right upper quadrant abdominal pain, nausea, and vomiting. The patient had an extensive small bowel resection due to bowel ischemia a year ago and has been receiving total parenteral nutrition since then. His other medical problems include atrial fibrillation and hypertension. Examination shows right upper quadrant tenderness on deep palpation. Initial laboratory studies show moderate leukocytosis with normal hepatic transaminase, amylase, and lipase levels. Abdominal ultrasonography reveals gallstones and edema of the gallbladder wall. Review of prior records indicates that he had no gallstones noted on abdominal imaging performed prior to the bowel resection. Which of the following is most likely responsible for the development of gallstones in this patient?

- ✓ A. Decreased cholecystokinin release due to lack of enteral stimulation (84%)
- B. Decreased cholesterol conversion to bile acids due to liver dysfunction (3%)
- C. High cholesterol content of the nutritional fluids (7%)
- D. Inadequate supplementation of essential fatty acids (3%)
- E. Increased gastrin release in response to parenteral amino acids (0%)

Correct

84% Answered correctly

04 secs Time Spent

2023 Version

Explanation

Pathogenesis of cholesterol gallstones

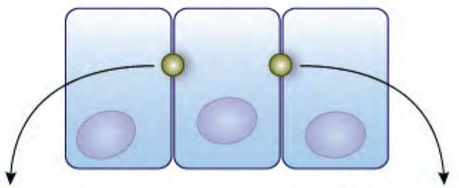

Normal levels of ↑ Cholesterol

https://t.me/USMLEWorldStep1

A 64-year-old man comes to the office due to acute-onset right upper quadrant abdominal pain, nausea, and vomiti
receivi
hypert
show
ultrasc
had nc
most li

Cor

Expl

Exhibit Display

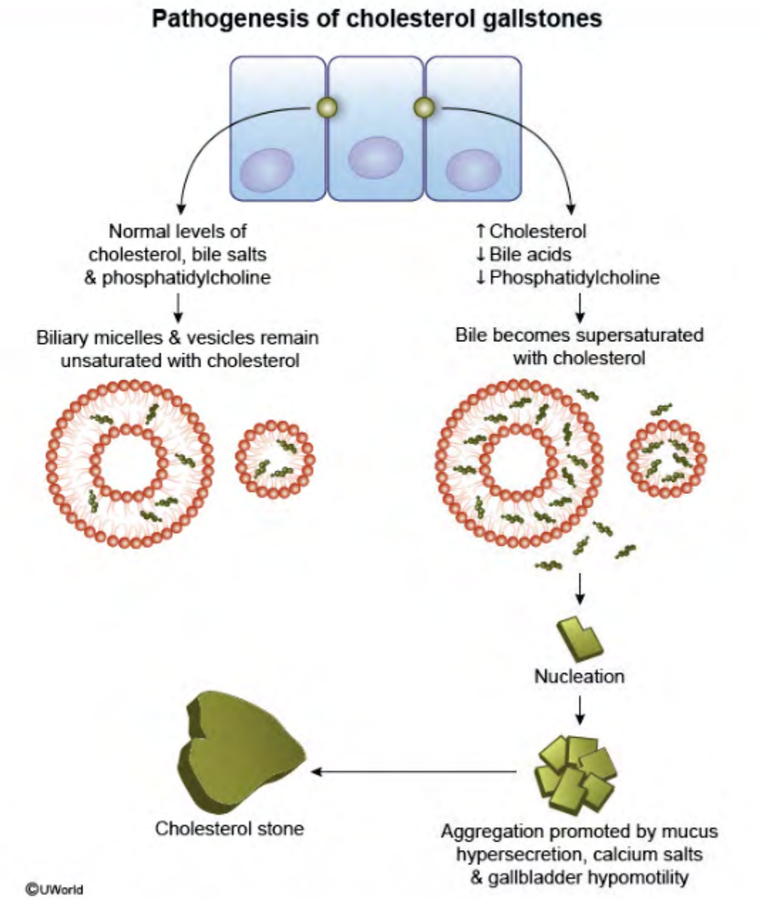

Zoom In | Zoom Out | Reset | New | Existing | My Notebook

https://t.me/USMLEWorldStep1

Cholesterol is secreted in bile, where it is solubilized by bile salts and phosphatidylcholine. If there is more cholesterol than can be dissolved by the bile salts, the cholesterol will precipitate into insoluble crystals, leading to the formation of **gallstones**. Risk factors for gallstone formation include obesity or rapid weight loss, female sex, glucose intolerance, and hypomotility of the gallbladder (eg, pregnancy, prolonged fasting).

A prolonged course of **total parenteral nutrition** (TPN) is often complicated by gallstones. In normal individuals, enteral passage of fat and amino acids into the duodenum triggers release of cholecystokinin (CCK), leading to contraction of the gallbladder. The absence of normal enteral stimulation in patients receiving TPN leads to **decreased CCK release** and subsequent **biliary stasis**. In addition, patients with extensive resection of the ileum can have disruption to the normal enterohepatic circulation of bile acids, leading to inadequate solubilization of biliary cholesterol and formation of cholesterol crystals.

(Choice B) Advanced liver disease can impair cholesterol conversion to bile acids due to the diminished synthetic ability of injured hepatocytes, leading to supersaturation of the bile with cholesterol. This contributes to the increased risk of gallstones seen in cirrhotic individuals but would be unlikely in this patient with no evidence of hepatocellular dysfunction.

(Choice C) TPN preparations contain glucose, amino acids, and fats based on the individual patient's needs, with additional electrolytes, vitamins, minerals, and trace elements in carefully calculated amounts. Serum triglyceride levels may rise on TPN, but TPN does not contain significant amounts of cholesterol, and serum cholesterol levels do not usually change significantly.

(Choice D) Deficient supplementation of essential fatty acids in TPN is associated with a number of clinical complications, including dermatitis, alopecia, neuropathy, visual disturbances, and ataxia. Gallstones are not related.

(Choice E) Digested peptides and free amino acids in the gastric lumen are a major stimulus for gastrin release, so parenteral nutrition typically results in decreased (not increased) gastrin levels. Moreover, gastrin is not a significant factor in the formation of gallstones.

https://t.me/USMLEWorldStep1

A prolonged course of **total parenteral nutrition** (TPN) is often complicated by gallstones. In normal individuals, enteral passage of fat and amino acids into the duodenum triggers release of cholecystokinin (CCK), leading to contraction of the gallbladder. The absence of normal enteral stimulation in patients receiving TPN leads to **decreased CCK release** and subsequent **biliary stasis**. In addition, patients with extensive resection of the ileum can have disruption to the normal enterohepatic circulation of bile acids, leading to inadequate solubilization of biliary cholesterol and formation of cholesterol crystals.

(Choice B) Advanced liver disease can impair cholesterol conversion to bile acids due to the diminished synthetic ability of injured hepatocytes, leading to supersaturation of the bile with cholesterol. This contributes to the increased risk of gallstones seen in cirrhotic individuals but would be unlikely in this patient with no evidence of hepatocellular dysfunction.

(Choice C) TPN preparations contain glucose, amino acids, and fats based on the individual patient's needs, with additional electrolytes, vitamins, minerals, and trace elements in carefully calculated amounts. Serum triglyceride levels may rise on TPN, but TPN does not contain significant amounts of cholesterol, and serum cholesterol levels do not usually change significantly.

(Choice D) Deficient supplementation of essential fatty acids in TPN is associated with a number of clinical complications, including dermatitis, alopecia, neuropathy, visual disturbances, and ataxia. Gallstones are not related.

(Choice E) Digested peptides and free amino acids in the gastric lumen are a major stimulus for gastrin release, so parenteral nutrition typically results in decreased (not increased) gastrin levels. Moreover, gastrin is not a significant factor in the formation of gallstones.

Educational objective:
The absence of normal enteral stimulation in patients receiving total parenteral nutrition leads to decreased cholecystokinin release, biliary stasis, and increased risk of gallstones. Resection of the ileum can also increase the risk of gallstones due to disruption of normal enterohepatic circulation of bile acids.

Pathophysiology	Gastrointestinal & Nutrition	Gallstone disease
Subject	System	Topic

https://t.me/USMLEWorldStep1

A 55-year-old man comes to the office due to recurrent abdominal discomfort. He also has bloating, a feeling of fullness, and indigestion. Vital signs are within normal limits, and abdominal examination is unremarkable. Fecal occult blood testing is positive. Gastrointestinal endoscopic procedures are performed and confirm the presence of an ulcer. The patient is told that the ulcer itself is very unlikely to be malignant based on its location. Which of the following is the most likely site of this patient's gastrointestinal ulcer?

- A. Duodenum
- B. Esophagus
- C. Rectum
- D. Sigmoid colon
- E. Stomach

Submit

https://t.me/USMLEWorldStep1

A 55-year-old man comes to the office due to recurrent abdominal discomfort. He also has bloating, a feeling of fullness, and indigestion. Vital signs are within normal limits, and abdominal examination is unremarkable. Fecal occult blood testing is positive. Gastrointestinal endoscopic procedures are performed and confirm the presence of an ulcer. The patient is told that the ulcer itself is very unlikely to be malignant based on its location. Which of the following is the most likely site of this patient's gastrointestinal ulcer?

- ✓ A. Duodenum (80%)
- B. Esophagus (1%)
- C. Rectum (1%)
- D. Sigmoid colon (2%)
- E. Stomach (13%)

Correct

80%
Answered correctly

08 secs
Time Spent

2023
Version

Explanation

Peptic ulcers

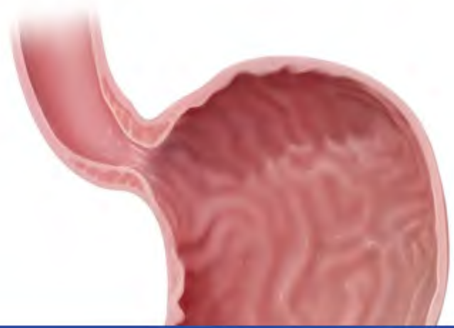

https://t.me/USMLEWorldStep1

Peptic ulcers

Exhibit Display

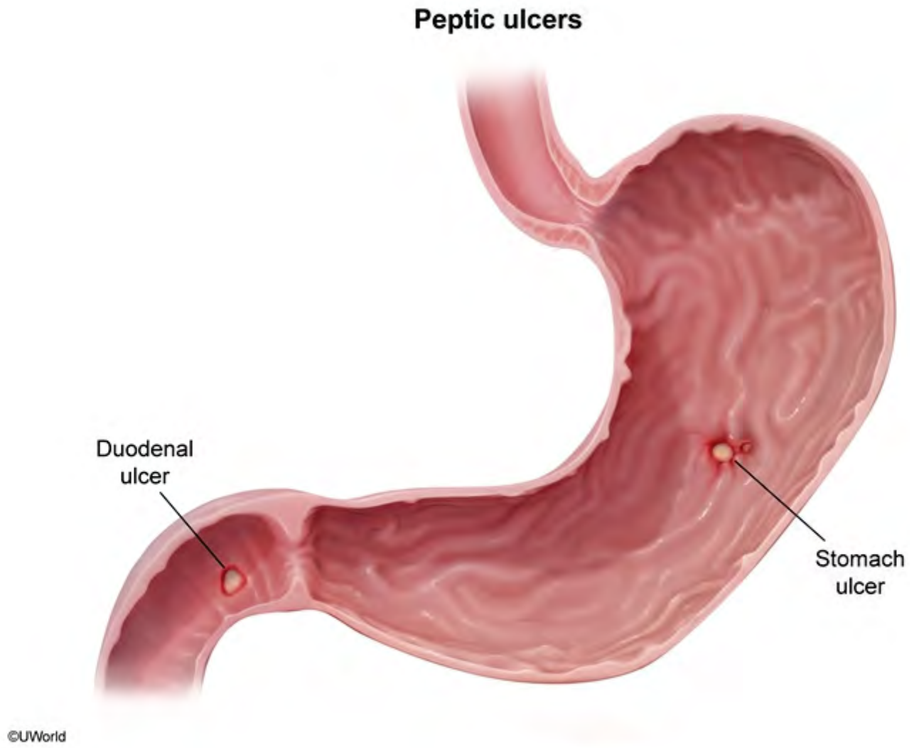

Zoom In | Zoom Out | Reset | New | Existing | My Notebook

Gastro
mucos
areas
gastro
occult

Almos
drugs
howev
islet ce

Conversely, gastric ulcers (located within the stomach) can be malignant (eg, gastric adenocarcinoma) and must be biopsied for confirmation **(Choice E)**. Gastric ulcers caused by *H pylori* infection are associated with an

https://t.me/USMLEWorldStep1

©UWorld

Gastrointestinal ulcers are defined as breaches of the alimentary tract mucosa that extend through the muscularis mucosae into the submucosa (or beyond). Those specifically designated as **peptic ulcers** are chronic lesions in areas exposed to acid/peptic juices, most commonly in the proximal duodenum, antral stomach, and gastroesophageal junction. Patients may present with epigastric discomfort, early satiety, and a positive fecal occult blood test.

Almost all peptic ulcers are due to either ***Helicobacter pylori*** infection or use of **nonsteroidal anti-inflammatory drugs (NSAIDs)**. The vast majority (>95%) of duodenal ulcers occur within the first part of the duodenum; however, multiple or refractory ulcers beyond the duodenal bulb may be seen in patients with gastrinoma (non-beta islet cell tumor of the pancreas). **Duodenal ulcers** are very **rarely malignant** and do not require biopsy. Conversely, gastric ulcers (located within the stomach) can be malignant (eg, gastric adenocarcinoma) and must be biopsied for confirmation **(Choice E)**. Gastric ulcers caused by *H pylori* infection are associated with an increased risk of gastric cancer, but duodenal ulcers related to this infection do not lead to a higher risk of duodenal carcinoma.

(Choice B) Esophageal adenocarcinoma can appear as an ulcerated/exophytic lesion in the lower third of the esophagus and typically results from Barrett esophagus, chronic gastroesophageal reflux disease, obesity, and/or smoking. Esophageal squamous cell carcinoma appears as plaque-like thickening of the mucosa in the upper two-thirds of the esophagus that may become ulcerated. Major risk factors include smoking, alcohol consumption, and caustic injury.

(Choices C and D) Carcinomas of the distal colon tend to be annular lesions that result in "napkin-ring" constriction of the bowel, with heaped-up edges and an ulcerated central region. Risk factors include advanced age, hereditary (eg, familial adenomatous polyposis) or sporadic colon cancer in the family, and inflammatory bowel disease.

Educational objective:
Duodenal ulcers are not associated with an increased risk of carcinoma in the same location. In contrast, ulcers located in the esophagus, stomach (gastric), and colon may be malignant, and biopsy is required.

References

https://t.me/USMLEWorldStep1

A 24-year-old woman comes to the office due to recurrent bloody diarrhea and right-sided abdominal pain. She has had these symptoms intermittently for several years but has not sought medical attention until now. Colonoscopy shows evidence of inflammation and dysplasia. The patient is started on appropriate medical therapy but her symptoms fail to respond adequately. She subsequently undergoes a colectomy of the involved region; findings are shown in the image.

The intestinal wall appears thickened. Which of the following is the most likely diagnosis?

- A. Amoebic dysentery
- B. Collagenous microscopic colitis
- C. Crohn disease
- D. Graft-versus-host disease
- E. Pseudomembranous colitis
- F. Ulcerative colitis

Submit

https://t.me/USMLEWorldStep1

A 24-year-old woman comes to the office due to recurrent bloody diarrhea and right-sided abdominal pain. She has ha
Colon
but he
finding

The in

F. Ulcerative colitis

Exhibit Display

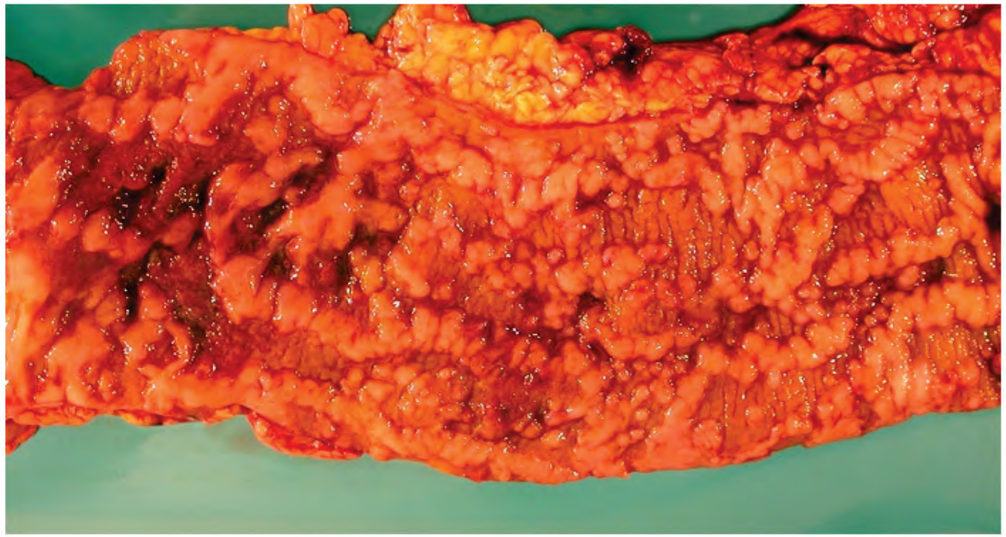

Zoom In Zoom Out Reset New | Existing My Notebook

https://t.me/USMLEWorldStep1

Colonoscopy shows evidence of inflammation and dysplasia. The patient is started on appropriate medical therapy but her symptoms fail to respond adequately. She subsequently undergoes a colectomy of the involved region; findings are shown in the image.

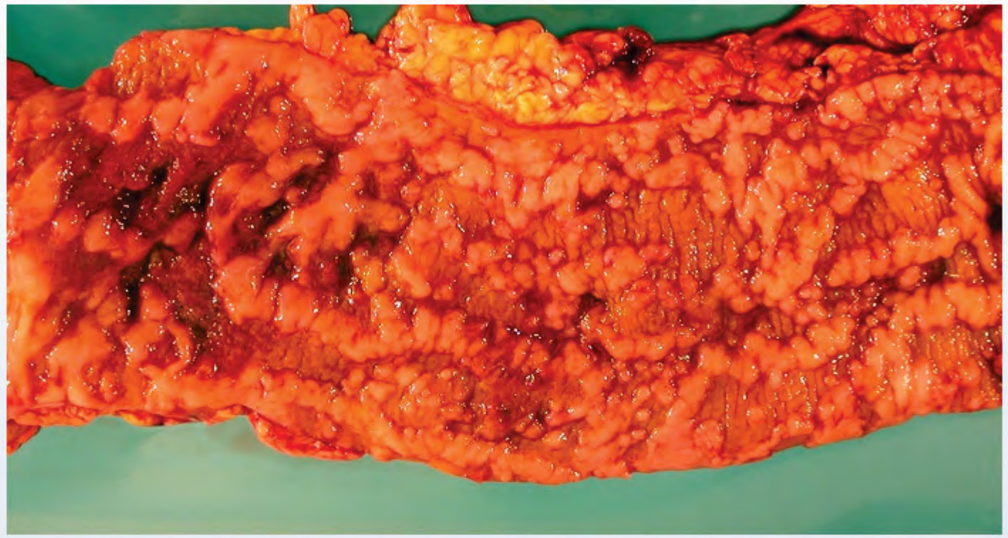

The intestinal wall appears thickened. Which of the following is the most likely diagnosis?

- A. Amoebic dysentery (0%)
- B. Collagenous microscopic colitis (2%)
- ✓ C. Crohn disease (60%)
- D. Graft-versus-host disease (0%)
- E. Pseudomembranous colitis (2%)
- F. Ulcerative colitis (35%)

Correct

60% Answered correctly

23 secs Time Spent

2023 Version

https://t.me/USMLEWorldStep1

Correct

60%
Answered correctly

23 secs
Time Spent

2023
Version

Exhibit Display

Expl

Crohn disease

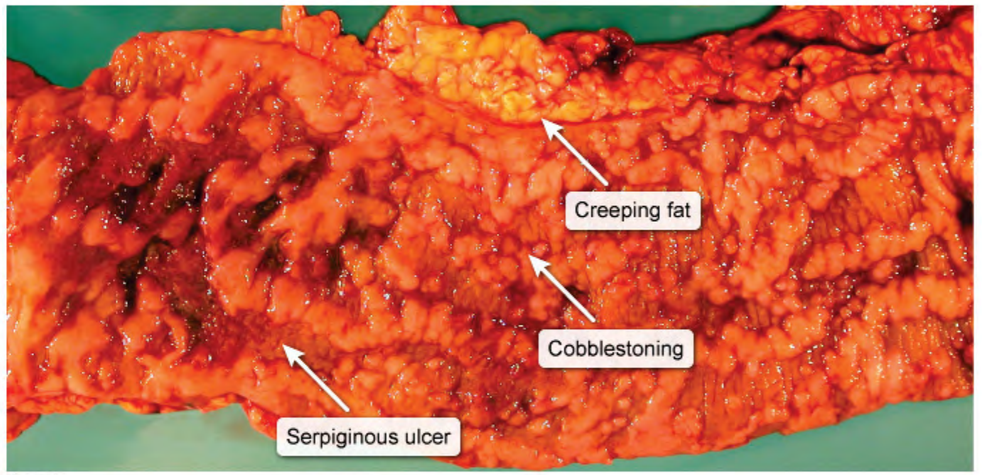

©UWorld

Zoom In | Zoom Out | Reset | New | Existing | My Notebook

Crohn
throug
pain, c
patien
of the
segme

- S
- **Cobblestone** appearance – serpiginous (ie, wavy, snakelike) depressed ulcerations that separate elevated islands of healthy tissue (giving the mucosa an appearance of a cobblestone street)

https://t.me/USMLEWorldStep1



©UWorld

Crohn disease (CD) is an inflammatory bowel disease characterized by patchy inflammation that can occur throughout the entire gastrointestinal (GI) tract; patients commonly complain of relapsing and remitting abdominal pain, diarrhea (with or without blood), and weight loss. CD typically involves the ileum; however, up to 20% of patients have only colonic involvement. Unlike ulcerative colitis, which is characterized by continuous inflammation of the colon limited to the mucosa and submucosa, inflammation in CD is **transmural** (full thickness) and **segmental** in nature. This leads to recognizable manifestations on gross pathology, including:

- Skip lesions – sharply delineated ulcerations surrounded by normal bowel
- **Cobblestone** appearance – serpiginous (ie, wavy, snakelike) depressed ulcerations that separate elevated islands of healthy tissue (giving the mucosa an appearance of a cobblestone street)
- **Bowel wall thickening** – due to inflammation involving all layers of the bowel wall leading to edema, hypertrophy of the muscularis mucosa, and fibrosis
- **Creeping fat** – mesenteric fat becomes wrapped around the bowel, possibly in response to intestinal bacteria translocation

In addition, the transmural inflammation frequently leads to complications such as abscesses, **strictures**, and **fistulas**.

(Choice A) Amoebic dysentery caused by *Entamoeba histolytica* causes hematochezia, abdominal pain, and ulcerations; however, the ulcers are classically flask-shaped and smaller than those seen with inflammatory bowel disease.

(Choice B) Collagenous colitis can cause chronic watery diarrhea (>5-10 episodes daily) but is commonly seen in middle-aged women and is not associated with bleeding, ulcerations, inflammation, or abdominal pain.

(Choice D) Graft-versus-host disease of the GI tract can cause abdominal pain and ulcerations, but it typically causes severe diarrhea (up to 10 L daily) and occurs as a complication of allogeneic stem cell transplant.

(Choice E) Pseudomembranous colitis occurs from *Clostridioides difficile* infection (CDI). It causes abdominal

https://t.me/USMLEWorldStep1

hypertrophy of the muscularis mucosa, and fibrosis

- **Creeping fat** – mesenteric fat becomes wrapped around the bowel, possibly in response to intestinal bacteria translocation

In addition, the transmural inflammation frequently leads to complications such as abscesses, **strictures**, and **fistulas**.

(Choice A) Amoebic dysentery caused by *Entamoeba histolytica* causes hematochezia, abdominal pain, and ulcerations; however, the ulcers are classically flask-shaped and smaller than those seen with inflammatory bowel disease.

(Choice B) Collagenous colitis can cause chronic watery diarrhea (>5-10 episodes daily) but is commonly seen in middle-aged women and is not associated with bleeding, ulcerations, inflammation, or abdominal pain.

(Choice D) Graft-versus-host disease of the GI tract can cause abdominal pain and ulcerations, but it typically causes severe diarrhea (up to 10 L daily) and occurs as a complication of allogeneic stem cell transplant.

(Choice E) Pseudomembranous colitis occurs from *Clostridioides difficile* infection (CDI). It causes abdominal pain and diarrhea that can result in toxic megacolon. A white/yellow, patchy pseudomembrane, composed of inflammatory cells, fibrin, and cellular debris, is often visualized. In addition, CDI is typically associated with recent antibiotic use.

(Choice F) Ulcerative colitis is characterized by contiguous inflammation that extends from the rectum. Ulcerations are shallow and involve only the mucosa and submucosa; pseudopolyps (areas of inflamed mucosa and/or granulation tissue that appear polyp-like due to surrounding ulcerations) are seen; bowel wall thickening is not as prominent as with CD.

Educational objective:
Crohn disease is an inflammatory bowel disease characterized by patchy inflammation that can occur throughout the entire gastrointestinal tract. Gross pathology demonstrates skip lesions, cobblestoning of the mucosa, bowel wall thickening, and creeping fat.

Pathology Gastrointestinal & Nutrition Inflammatory bowel disease

https://t.me/USMLEWorldStep1

Exhibit Display

Crohn
throug
pain, d
patien
of the
segm

- S
- **C**
  is
- **B**
  h
- **C**
  tr

In add
fistula

(Choi
ulcera
diseas

(Choi
middle

(Choi
cause

Crohn disease

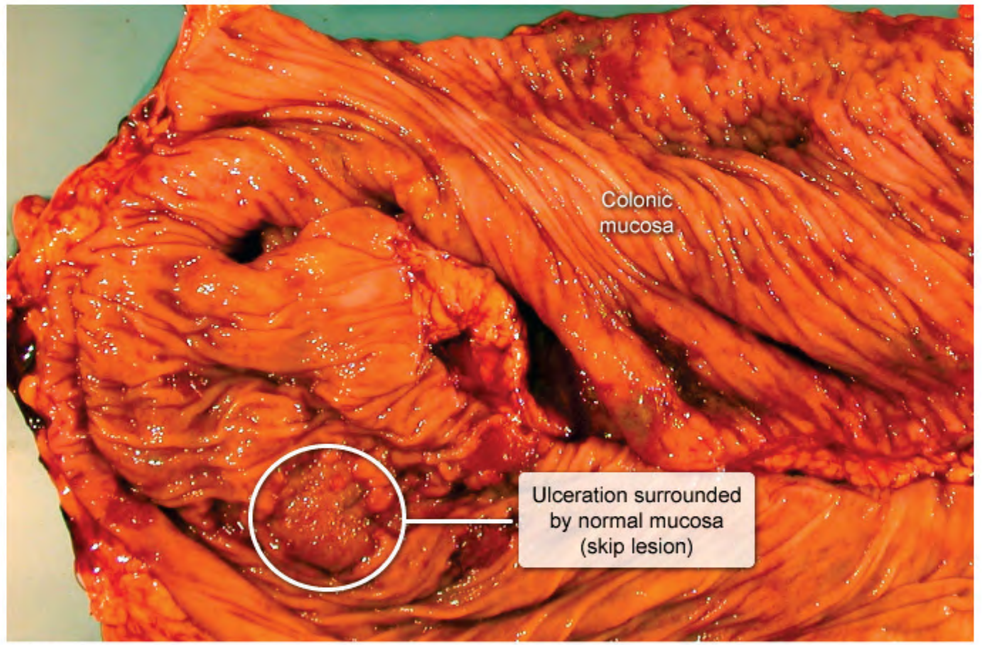

©UWorld

Zoom In | Zoom Out | Reset | New | Existing | My Notebook

(Choice E) Pseudomembranous colitis occurs from *Clostridioides difficile* infection (CDI). It causes abdominal

https://t.me/USMLEWorldStep1

- **Cobblestone** appearance – serpiginous (ie, wavy, snakelike) depressed ulcerations that separate elevated
- **B**
- **C**

In add
fistula

(Choi
ulcera
diseas

(Choi
middle

(Choi
cause

(Choi
pain a
inflam
antibio

(Choi
Ulcera
and/or
not as prominent as with CD.

Educational objective:
Crohn disease is an inflammatory bowel disease characterized by patchy inflammation that can occur throughout

Exhibit Display

Pseudomembranous colitis

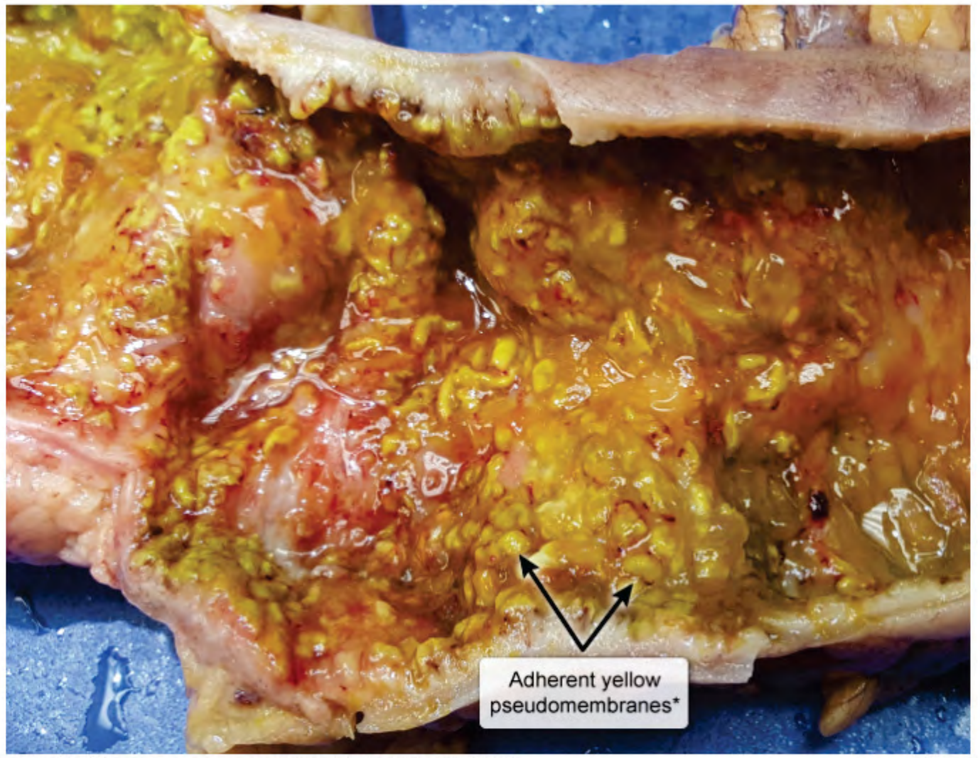

*Fibrin and inflammatory debris associated with *Clostridioides difficile*.

©UWorld

Zoom In | Zoom Out | Reset | New | Existing | My Notebook

https://t.me/USMLEWorldStep1

translocation

In add
fistula

(Choi
ulcera
diseas

(Choi
middle

(Choi
cause

(Choi
pain a
inflam
antibio

(Choi
Ulcera
and/or
not as

Educa
Crohn
the en
wall th

Pathol
Subject

Exhibit Display

Ulcerative colitis

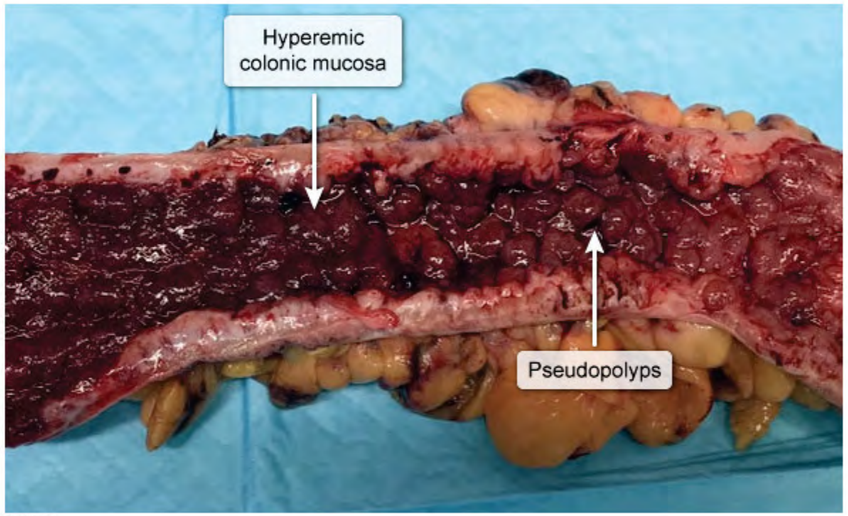

©UWorld

Zoom In | Zoom Out | Reset | New | Existing | My Notebook

Copyright © UWorld. All rights reserved.

https://t.me/USMLEWorldStep1

A 46-year-old man comes to the emergency department due to severe anal pain. He has a history of chronic constipation and on several occasions has noticed streaks of blood on the tissue paper after wiping. He has no abdominal pain, nausea, vomiting, or weight loss and has no family history of malignancy. His temperature is 36.7 C (98 F). On examination, there are several large, purplish-blue sacs bulging into the anal canal, one of which originates below the dentate line and is extremely tender. Excision of the tender lesion under local anesthesia is planned. The anesthetic agent most likely blocks sensory impulses carried by which of the following structures?

- A. Ilioinguinal nerve
- B. Inferior gluteal nerve
- C. Inferior hypogastric plexus
- D. Pelvic splanchnic nerves
- E. Pudendal nerve

Submit

https://t.me/USMLEWorldStep1

A 46-year-old man comes to the emergency department due to severe anal pain. He has a history of chronic constipation and on several occasions has noticed streaks of blood on the tissue paper after wiping. He has no abdominal pain, nausea, vomiting, or weight loss and has no family history of malignancy. His temperature is 36.7 C (98 F). On examination, there are several large, purplish-blue sacs bulging into the anal canal, one of which originates below the dentate line and is extremely tender. Excision of the tender lesion under local anesthesia is planned. The anesthetic agent most likely blocks sensory impulses carried by which of the following structures?

- ✗ A. Ilioinguinal nerve (3%)
- B. Inferior gluteal nerve (5%)
- C. Inferior hypogastric plexus (3%)
- D. Pelvic splanchnic nerves (5%)
- ✓ E. Pudendal nerve (83%)

Incorrect
Correct answer
E

83%
Answered correctly

04 secs
Time Spent

2023
Version

Explanation

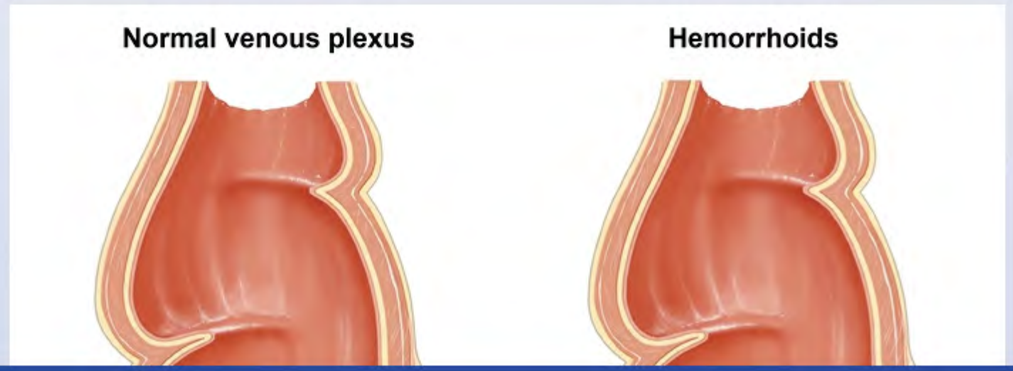

https://t.me/USMLEWorldStep1

A 46-year-old man comes to the emergency department due to severe anal pain. He has a history of chronic
consti
abdom
C (98
origina
planne

Inco
Corre
E

Expl

Exhibit Display

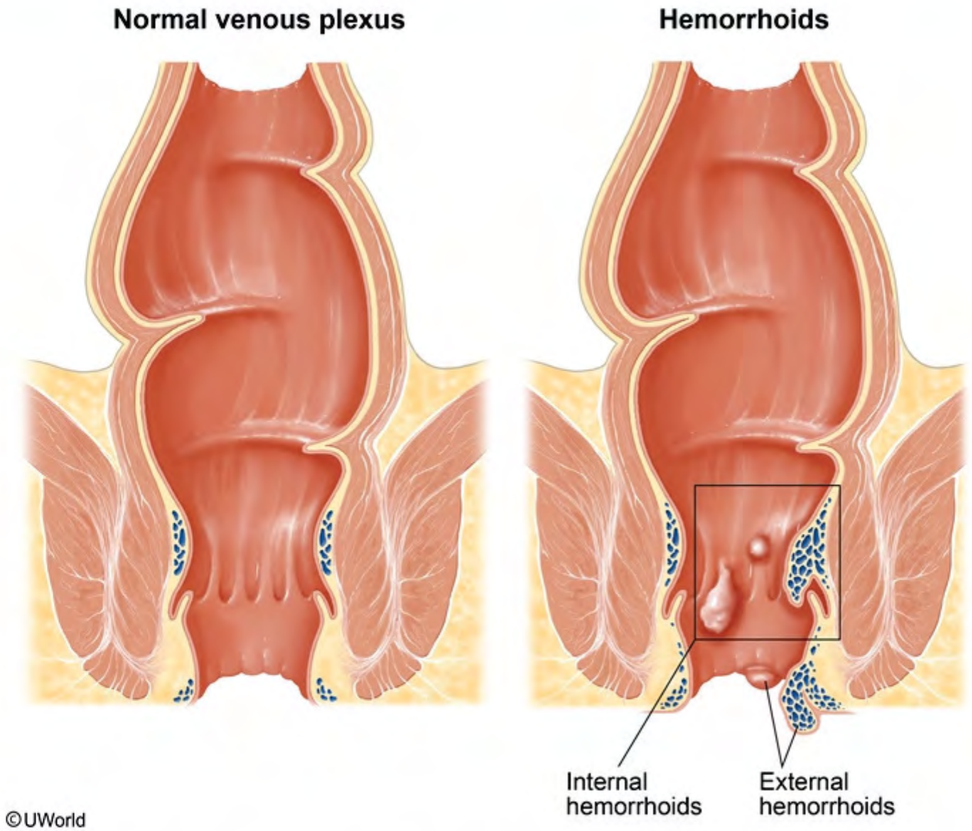

Zoom In Zoom Out Reset New | Existing My Notebook

https://t.me/USMLEWorldStep1

This patient has both internal and **external hemorrhoids**, which each have a distinct epithelial lining and innervation. Internal hemorrhoids originate above the dentate line and are covered by columnar epithelium. They have autonomic innervation from the inferior hypogastric plexus, which is only sensitive to stretch and not pain, temperature, or touch.

External hemorrhoids, which originate below the dentate line, are covered by modified squamous epithelium and have cutaneous (somatic) nervous innervation from the inferior rectal nerve, a branch of the pudendal nerve. **Branches** of the **pudendal nerve** supply the perineum and external genitalia in males and females and are very sensitive to touch, temperature, and **pain**. External hemorrhoids are generally asymptomatic but can become exquisitely painful if they thrombose, as in this case.

(Choice A) The ilioinguinal nerve is mostly sensory, derived from L1, and carries sensation from skin of the upper and medial part of the thigh, the root of the penis and upper part of the scrotum in males, and the mons pubis and labia majora in females.

(Choice B) The inferior gluteal nerve, composed of branches of L5, S1, and S2, is the main nerve supplying motor functions to the gluteus maximus muscle.

(Choice C) The inferior hypogastric plexus, which has both sympathetic and parasympathetic components, innervates the internal pelvic viscera but not the external perirectal area.

(Choice D) The pelvic splanchnic nerves are derived from S2, S3, and S4 and provide parasympathetic innervation to the pelvic and genital organs.

Educational objective:
External hemorrhoids, which originate below the dentate line, are covered by modified squamous epithelium and have cutaneous (somatic) nervous innervation from the inferior rectal nerve, a branch of the pudendal nerve.

References

- Hemorrhoids.
- Hemorrhoids.

Anatomy Gastrointestinal & Nutrition Hemorrhoids

https://t.me/USMLEWorldStep1

This patient has both internal and **external hemorrhoids**, which each have a distinct epithelial lining and innervation. Internal hemorrhoids originate above the dentate line and are covered by columnar epithelium. They have autonomic innervation from the inferior hypogastric plexus, which is only sensitive to stretch and not pain, temperature, or touch.

External hemorrhoids, which originate below the dentate line, are covered by modified squamous epithelium and have cutaneous (somatic) nervous innervation from the inferior rectal nerve, a branch of the pudendal nerve. **Branches** of the **pudendal nerve** supply the perineum and external genitalia in males and females and are very sensitive to touch, temperature, and **pain**. External hemorrhoids are generally asymptomatic but can become exquisitely painful if they thrombose, as in this case.

(Choice A) The ilioinguinal nerve is mostly sensory, derived from L1, and carries sensation from skin of the upper and medial part of the thigh, the root of the penis and upper part of the scrotum in males, and the mons pubis and labia majora in females.

(Choice B) The inferior gluteal nerve, composed of branches of L5, S1, and S2, is the main nerve supplying motor functions to the gluteus maximus muscle.

(Choice C) The inferior hypogastric plexus, which has both sympathetic and parasympathetic components, innervates the internal pelvic viscera but not the external perirectal area.

(Choice D) The pelvic splanchnic nerves are derived from S2, S3, and S4 and provide parasympathetic innervation to the pelvic and genital organs.

Educational objective:
External hemorrhoids, which originate below the dentate line, are covered by modified squamous epithelium and have cutaneous (somatic) nervous innervation from the inferior rectal nerve, a branch of the pudendal nerve.

References

- Hemorrhoids

https://t.me/USMLEWorldStep1

A 23-year-old-man is brought to the emergency department after he was stabbed in the right upper quadrant of the abdomen. His blood pressure is 70/42 mm Hg, pulse is 135/min, and respirations are 26/min; pulse oximetry shows oxygen saturation of 95% on room air. Physical examination shows a stab wound 2 cm inferior to the right costal margin. The patient's abdomen is firm and distended. Focused assessment with sonography for trauma (FAST) is positive for blood in the right upper quadrant. He is taken for immediate laparotomy, and approximately 1 liter of blood is evacuated from the peritoneal cavity. Brisk, nonpulsatile bleeding is seen emanating from behind the liver. The surgeon occludes the hepatoduodenal ligament, but the patient continues to hemorrhage. Which of the following structures is the most likely source of this patient's bleeding?

- A. Common bile duct
- B. Cystic artery
- C. Hepatic artery
- D. Inferior vena cava
- E. Portal vein

Submit

https://t.me/USMLEWorldStep1

A 23-year-old-man is brought to the emergency department after he was stabbed in the right upper quadrant of the abdomen. His blood pressure is 70/42 mm Hg, pulse is 135/min, and respirations are 26/min; pulse oximetry shows oxygen saturation of 95% on room air. Physical examination shows a stab wound 2 cm inferior to the right costal margin. The patient's abdomen is firm and distended. Focused assessment with sonography for trauma (FAST) is positive for blood in the right upper quadrant. He is taken for immediate laparotomy, and approximately 1 liter of blood is evacuated from the peritoneal cavity. Brisk, nonpulsatile bleeding is seen emanating from behind the liver. The surgeon occludes the hepatoduodenal ligament, but the patient continues to hemorrhage. Which of the following structures is the most likely source of this patient's bleeding?

- A. Common bile duct (0%)
- ✗ B. Cystic artery (9%)
- C. Hepatic artery (6%)
- ✓ D. Inferior vena cava (65%)
- E. Portal vein (17%)

Incorrect
Correct answer
D

65%
Answered correctly

04 secs
Time Spent

2023
Version

Explanation

https://t.me/USMLEWorldStep1

A 23-year-old man is brought to the emergency department after he was stabbed in the right upper quadrant of the abdom
shows
costal
(FAST
liter of
the live
the fol

Exhibit Display

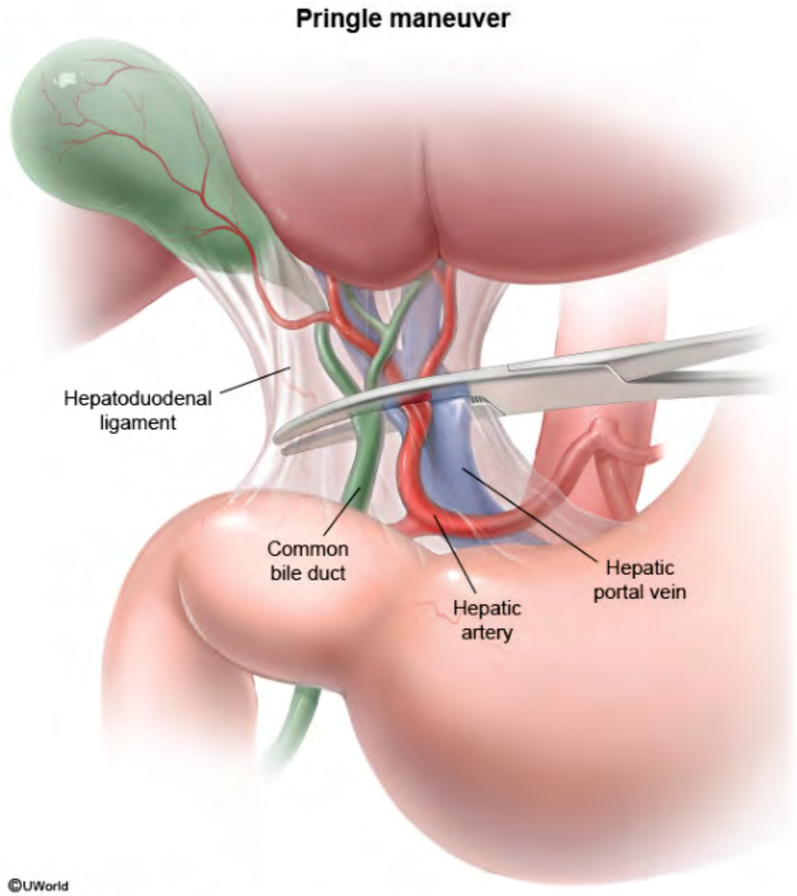

Zoom In Zoom Out Reset New | Existing My Notebook

Incc
Corre
D

Expl

https://t.me/USMLEWorldStep1

The **portal triad** runs through the **hepatoduodenal ligament** and is composed of the hepatic artery, portal vein, and common bile duct. In the setting of traumatic liver injury with persistent bleeding, **occlusion** of the hepatoduodenal ligament can be performed to identify the vascular source (ie, the Pringle maneuver). If liver **bleeding does not cease** when the portal triad is occluded, it is likely that there has been injury to the **inferior vena cava** or hepatic veins. Although the inferior vena cava is a retroperitoneal structure, penetrating trauma can disrupt tissue barriers, facilitating bleeding into the peritoneal compartment.

(Choice A) The common bile duct makes up one-third of the portal triad. Damage to the biliary ducts can cause biliary leakage and bile peritonitis.

(Choice B) The cystic artery most commonly arises from the right hepatic artery and would be devascularized following portal triad occlusion. In addition, arterial bleeding is usually pulsatile whereas venous bleeding is nonpulsatile.

(Choices C and E) The hepatic artery and portal vein are part of the portal triad; occlusion of the hepatoduodenal ligament would cause the bleeding to stop if either of these vessels is the source.

Educational objective:
Occlusion of the portal triad can be used to distinguish the source of right upper quadrant bleeding. If the bleeding subsides following occlusion, the source is likely to be the hepatic artery or portal vein. If hepatic bleeding persists after occlusion, the inferior vena cava or hepatic veins are likely to be injured.

References

- Vascular control during hepatectomy: review of methods and results.
- Emergency strategies and trends in the management of liver trauma.

Anatomy	Gastrointestinal & Nutrition	Penetrating abdominal trauma
Subject	System	Topic

Copyright © UWorld. All rights reserved.

https://t.me/USMLEWorldStep1

A 45-year-old woman comes to the office due to several months of episodic right upper quadrant abdominal pain associated with nausea. The pain is often brought on by fatty meals and subsides in 1-2 hours. The patient has no fever, vomiting, diarrhea, melena, or bright red blood per rectum. Her BMI is 31.2 kg/m^2. Physical examination is unremarkable. A cholecystokinin stimulation test is performed and shows slow and incomplete gallbladder emptying. This patient is most likely to have which of the following pathologic findings?

- A. Biliary sludge
- B. Black pigment stones
- C. Brown pigment stones
- D. Cystine stones
- E. Uric acid stones

Submit

https://t.me/USMLEWorldStep1

A 45-year-old woman comes to the office due to several months of episodic right upper quadrant abdominal pain associated with nausea. The pain is often brought on by fatty meals and subsides in 1-2 hours. The patient has no fever, vomiting, diarrhea, melena, or bright red blood per rectum. Her BMI is 31.2 kg/m^2. Physical examination is unremarkable. A cholecystokinin stimulation test is performed and shows slow and incomplete gallbladder emptying. This patient is most likely to have which of the following pathologic findings?

- ✓ A. Biliary sludge (50%)
- ✗ B. Black pigment stones (16%)
- C. Brown pigment stones (30%)
- D. Cystine stones (1%)
- E. Uric acid stones (0%)

Incorrect
Correct answer
A

50%
Answered correctly

03 secs
Time Spent

2023
Version

Explanation

https://t.me/USMLEWorldStep1

A 45-year-old woman comes to the office due to several months of episodic right upper quadrant abdominal pain
associ
no fev
is unre
empty

Exhibit Display

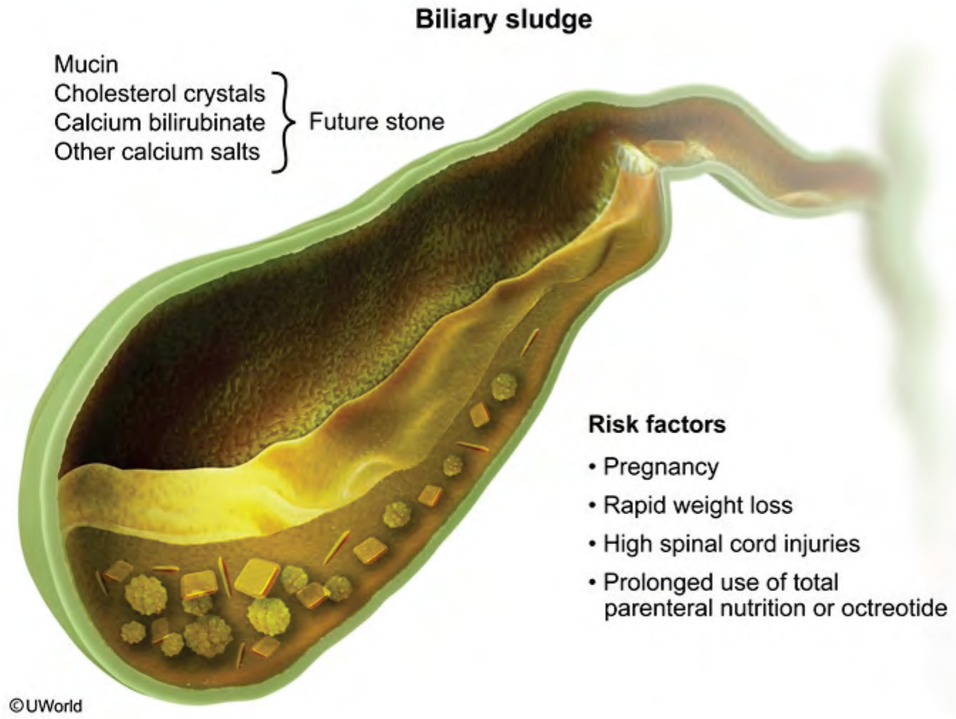

Zoom In Zoom Out Reset New | Existing My Notebook

https://t.me/USMLEWorldStep1

parenteral nutrition or octreotide

©UWorld

This patient's slow/incomplete gallbladder emptying in response to cholecystokinin stimulation is consistent with **gallbladder hypomotility**. The gallbladder functions to actively absorb water from bile; conditions that cause gallbladder hypomotility result in excessive dehydration of bile. This promotes the precipitation and accumulation of particulate material (eg, cholesterol monohydrate crystals, calcium bilirubinate, mucus) in bile, forming viscous **biliary sludge**. Sludge formation may be asymptomatic or cause biliary colic (right upper quadrant abdominal pain associated with nausea) and is a known precursor to stone formation (particularly cholesterol stones). Complications such as acute cholecystitis and cholangitis can also occur in patients with biliary sludge.

(Choices B and C) Pigment gallstones can be brown or black and arise from conditions that increase the amount of unconjugated bilirubin in bile. Brown pigment stones are associated with biliary tract infections (microbes producing β-glucuronidases), whereas black stones occur with chronic hemolytic anemias (eg, sickle cell disease) and increased enterohepatic cycling of bilirubin (eg, Crohn disease, which also decreases enterohepatic cycling of bile acids). This patient has no risk factors for pigment stones, and her gallbladder dysmotility makes biliary sludge a more likely diagnosis.

(Choice D) Cystinuria is an autosomal recessive condition characterized by a defect in an amino acid transporter gene, resulting in elevated urinary cystine concentrations. Patients typically present with cystine kidney stones during childhood or adolescence.

(Choice E) Individuals with high serum uric acid levels are at increased risk of developing uric acid kidney stones. Hyperuricemia can be caused by uric acid underexcretion (eg, thiazide diuretics) or overproduction (eg, tumor lysis syndrome).

Educational objective:
The gallbladder functions to actively absorb water from bile. Gallbladder hypomotility causes the bile to become concentrated, promoting precipitation and accumulation of particulate material. This forms a viscous biliary sludge that can cause transient bile duct obstruction (biliary colic) and promote cholesterol gallstone formation.

References

https://t.me/USMLEWorldStep1

A 15-year-old boy is brought to the clinic for a follow-up appointment. Since early childhood, the boy has had recurrent episodes of pancreatitis requiring hospitalization. The patient has not been hospitalized since before his last follow-up appointment a few months ago. However, he has been feeling more tired recently and states he has not been taking his prescribed medications. Family history is notable for recurrent pancreatitis in a sibling. Neurologic examination shows hyporeflexia and decreased proprioception in the lower extremities. Laboratory studies show mild hemolytic anemia. This patient's presentation is most likely due to a deficiency of which of the following?

- A. Niacin
- B. Riboflavin
- C. Thiamine
- D. Vitamin A
- E. Vitamin E
- F. Vitamin K

Submit

https://t.me/USMLEWorldStep1

A 15-year-old boy is brought to the clinic for a follow-up appointment. Since early childhood, the boy has had recurrent episodes of pancreatitis requiring hospitalization. The patient has not been hospitalized since before his last follow-up appointment a few months ago. However, he has been feeling more tired recently and states he has not been taking his prescribed medications. Family history is notable for recurrent pancreatitis in a sibling. Neurologic examination shows hyporeflexia and decreased proprioception in the lower extremities. Laboratory studies show mild hemolytic anemia. This patient's presentation is most likely due to a deficiency of which of the following?

- ✗ A. Niacin (5%)
- B. Riboflavin (5%)
- C. Thiamine (15%)
- D. Vitamin A (3%)
- ✓ E. Vitamin E (63%)
- F. Vitamin K (6%)

Incorrect
Correct answer
E

63%
Answered correctly

09 secs
Time Spent

2023
Version

Explanation

Fat-soluble vitamin deficiency	
Vitamin	**Clinical features**
Vitamin A	• Night blindness • Dry eyes, Bitot spots • Hyperkeratosis

https://t.me/USMLEWorldStep1

Explanation

Fat-soluble vitamin deficiency	
Vitamin	**Clinical features**
Vitamin A	• Night blindness • Dry eyes, Bitot spots • Hyperkeratosis
Vitamin D	• Myalgias, bone pain, fractures • Rickets, osteomalacia
Vitamin E	• Ataxia, polyneuropathy • Myopathy • Hemolytic anemia
Vitamin K	• Bleeding diathesis

Patients with recurrent pancreatitis (eg, hereditary, cystic fibrosis) are at risk for **exocrine pancreatic insufficiency**, or decreased secretion of pancreatic enzymes that are involved in the digestion of fat (most important), carbohydrates, and protein. Without enzyme replacement (eg, lipase), patients often develop chronic **fat malabsorption** and deficiencies of fat-soluble vitamins (A, D, E, and K). In this case, the patient's neurologic and hematologic findings are most consistent with **vitamin E deficiency**.

Vitamin E primarily serves as a free radical scavenger to protect fatty acids from oxidation; deficiency predisposes cell membranes to **oxidative injury**. The cells that are most susceptible include **neurons** with long axons (due to large membrane surface area) and **erythrocytes** (due to high oxygen exposure). Therefore, the most common clinical manifestations of vitamin E deficiency are:

- Neuromuscular disease: Involvement of the dorsal column in the spinal cord is associated with the **loss of proprioception** and vibratory sense. Spinocerebellar tract degeneration causes **ataxia**, and peripheral nerve dysfunction results in motor and sensory loss and **hyporeflexia**. Skeletal myopathy can also contribute to

https://t.me/USMLEWorldStep1

	• Hemolytic anemia
Vitamin K	• Bleeding diathesis

Patients with recurrent pancreatitis (eg, hereditary, cystic fibrosis) are at risk for **exocrine pancreatic insufficiency**, or decreased secretion of pancreatic enzymes that are involved in the digestion of fat (most important), carbohydrates, and protein. Without enzyme replacement (eg, lipase), patients often develop chronic **fat malabsorption** and deficiencies of fat-soluble vitamins (A, D, E, and K). In this case, the patient's neurologic and hematologic findings are most consistent with **vitamin E deficiency**.

Vitamin E primarily serves as a free radical scavenger to protect fatty acids from oxidation; deficiency predisposes cell membranes to **oxidative injury**. The cells that are most susceptible include **neurons** with long axons (due to large membrane surface area) and **erythrocytes** (due to high oxygen exposure). Therefore, the most common clinical manifestations of vitamin E deficiency are:

- Neuromuscular disease: Involvement of the dorsal column in the spinal cord is associated with the **loss of proprioception** and vibratory sense. Spinocerebellar tract degeneration causes **ataxia**, and peripheral nerve dysfunction results in motor and sensory loss and **hyporeflexia**. Skeletal myopathy can also contribute to muscle weakness.
- Hemolysis: Erythrocyte fragility and a shortened red blood cell lifespan result in **hemolytic anemia**, which can present with fatigue, as seen in this patient.

(Choices A, B, and C) Niacin (vitamin B_3), riboflavin (vitamin B_2), and thiamine (vitamin B_1) are water soluble and unaffected by fat malabsorption, making deficiency unlikely in this patient who has risk factors for exocrine pancreatic insufficiency. Moreover, the clinical findings of these vitamin deficiencies are inconsistent with this patient's presentation: Niacin deficiency causes pellagra (eg, dermatitis, diarrhea, dementia), riboflavin deficiency manifests with a normocytic anemia and mucosal changes (eg, stomatitis, cheilitis, glossitis), and thiamine deficiency is characterized by beriberi and Wernicke-Korsakoff syndrome.

(Choice D) In contrast to this patient's presentation, vitamin A deficiency manifests with night blindness, dry eyes (xerophthalmia), and hyperkeratosis (thickened, dry skin).

(Choice E) Vitamin K is necessary for hepatic synthesis of clotting factors II, VII, IX, and X. Deficiency presents

https://t.me/USMLEWorldStep1

large membrane surface area) and **erythrocytes** (due to high oxygen exposure). Therefore, the most common clinical manifestations of vitamin E deficiency are:

- Neuromuscular disease: Involvement of the dorsal column in the spinal cord is associated with the **loss of proprioception** and vibratory sense. Spinocerebellar tract degeneration causes **ataxia**, and peripheral nerve dysfunction results in motor and sensory loss and **hyporeflexia**. Skeletal myopathy can also contribute to muscle weakness.
- Hemolysis: Erythrocyte fragility and a shortened red blood cell lifespan result in **hemolytic anemia**, which can present with fatigue, as seen in this patient.

(Choices A, B, and C) Niacin (vitamin B_3), riboflavin (vitamin B_2), and thiamine (vitamin B_1) are water soluble and unaffected by fat malabsorption, making deficiency unlikely in this patient who has risk factors for exocrine pancreatic insufficiency. Moreover, the clinical findings of these vitamin deficiencies are inconsistent with this patient's presentation: Niacin deficiency causes pellagra (eg, dermatitis, diarrhea, dementia), riboflavin deficiency manifests with a normocytic anemia and mucosal changes (eg, stomatitis, cheilitis, glossitis), and thiamine deficiency is characterized by beriberi and Wernicke-Korsakoff syndrome.

(Choice D) In contrast to this patient's presentation, vitamin A deficiency manifests with night blindness, dry eyes (xerophthalmia), and hyperkeratosis (thickened, dry skin).

(Choice F) Vitamin K is necessary for hepatic synthesis of clotting factors II, VII, IX, and X. Deficiency presents with easy bleeding and bruising, not seen in this patient.

Educational objective:
Vitamin E is a fat-soluble vitamin, and deficiency can occur in individuals with fat malabsorption due to recurrent pancreatitis. Vitamin E deficiency is associated with increased susceptibility of the neuronal and erythrocyte membranes to oxidative stress. Clinical manifestations include decreased proprioception, ataxia, peripheral neuropathy (eg, hyporeflexia), and hemolytic anemia.

References

- Vitamin E supplementation in people with cystic fibrosis.

https://t.me/USMLEWorldStep1

A 16-year-old boy is brought to the office by his parents due to tremors and difficulty walking. Over the past year, his school performance has declined, and he has been moodier and more impulsive. His parents also note that he has been sleeping more than usual and has had a poor appetite for the past 2 months. Approximately 3 weeks ago, the patient developed a tremor in both hands that is most prominent when he reaches for an object or tries to write. The tremor has worsened significantly over the past week, and he has developed an unsteady, broad-based gait. Laboratory studies reveal elevated serum transaminases and 24-hour urinary copper excretion. The patient is prescribed penicillamine therapy. This medication primarily works through which of the following mechanisms?

- A. Decreasing intestinal absorption of copper
- B. Increasing urinary excretion of copper
- C. Repletion of intracellular glutathione
- D. Stimulation of defective gene expression
- E. Stimulation of canalicular transport proteins

Submit

https://t.me/USMLEWorldStep1

A 16-year-old boy is brought to the office by his parents due to tremors and difficulty walking. Over the past year, his school performance has declined, and he has been moodier and more impulsive. His parents also note that he has been sleeping more than usual and has had a poor appetite for the past 2 months. Approximately 3 weeks ago, the patient developed a tremor in both hands that is most prominent when he reaches for an object or tries to write. The tremor has worsened significantly over the past week, and he has developed an unsteady, broad-based gait. Laboratory studies reveal elevated serum transaminases and 24-hour urinary copper excretion. The patient is prescribed penicillamine therapy. This medication primarily works through which of the following mechanisms?

- ✗ A. Decreasing intestinal absorption of copper (37%)
- ✓ B. Increasing urinary excretion of copper (56%)
- C. Repletion of intracellular glutathione (1%)
- D. Stimulation of defective gene expression (0%)
- E. Stimulation of canalicular transport proteins (3%)

Incorrect
Correct answer
B

56%
Answered correctly

03 secs
Time Spent

2023
Version

Explanation

Wilson disease	
Pathogenesis	• Autosomal recessive mutation of *ATP7B* → hepatic copper accumulation → leak from damaged hepatocytes → deposits in tissues (eg, basal ganglia, cornea)
	• Hepatic (acute liver failure, chronic hepatitis,

https://t.me/USMLEWorldStep1

Wilson disease	
Pathogenesis	• Autosomal recessive mutation of *ATP7B* → hepatic copper accumulation → leak from damaged hepatocytes → deposits in tissues (eg, basal ganglia, cornea)
Clinical findings	• Hepatic (acute liver failure, chronic hepatitis, cirrhosis) • Neurologic (parkinsonism, gait disturbance, dysarthria) • Psychiatric (depression, personality changes, psychosis)
Diagnosis	• ↓ Ceruloplasmin & ↑ urinary copper excretion • Kayser-Fleischer rings on slit-lamp examination • ↑ Copper content on liver biopsy
Treatment	• Chelators (eg, D-penicillamine, trientine) • Zinc (interferes with copper absorption)

This patient has **Wilson disease**, an autosomal recessive disorder characterized by excessive copper deposition in the liver, basal ganglia, and cornea.

Copper is an essential nutrient that is absorbed in the intestines, metabolized by hepatocytes, and excreted in the bile. Pathogenesis of Wilson disease involves impaired hepatocellular copper transport, which results in **decreased biliary excretion of copper**. The resultant increase in intracellular copper causes oxidative stress and apoptosis of hepatocytes, which leads to liver dysfunction (eg, elevated transaminases, liver failure). Excess copper is then released into the bloodstream and deposited into extrahepatic tissues, causing neurologic (eg, tremor, ataxia) and psychiatric symptoms (eg, impulsivity, depressive symptoms). Although renal excretion of

https://t.me/USMLEWorldStep1

This patient has **Wilson disease**, an autosomal recessive disorder characterized by excessive copper deposition in the liver, basal ganglia, and cornea.

Copper is an essential nutrient that is absorbed in the intestines, metabolized by hepatocytes, and excreted in the bile. Pathogenesis of Wilson disease involves impaired hepatocellular copper transport, which results in **decreased biliary excretion of copper**. The resultant increase in intracellular copper causes oxidative stress and apoptosis of hepatocytes, which leads to liver dysfunction (eg, elevated transaminases, liver failure). Excess copper is then released into the bloodstream and deposited into extrahepatic tissues, causing neurologic (eg, tremor, ataxia) and psychiatric symptoms (eg, impulsivity, depressive symptoms). Although renal excretion of copper in healthy patients is extremely low, the relative increase in serum copper in Wilson disease results in increased urinary excretion of copper, as seen in this patient.

First-line treatment of Wilson disease is with **penicillamine**, a **copper chelating agent**. Penicillamine binds free copper as well as reduces copper bound to other proteins. This reduction preferentially increases affinity of copper to the chelating agent. The chelator-copper complex is soluble, thereby **increasing urinary copper excretion**.

(Choice A) Zinc decreases intestinal absorption of copper and can be used in conjunction with penicillamine to treat Wilson disease.

(Choice C) Acetaminophen overdose causes hepatotoxicity via depletion of intracellular glutathione, which can be reversed with N-acetylcysteine treatment.

(Choices D and E) Gene therapy could theoretically improve or cure Wilson disease by transferring a functional copper transport protein gene into hepatocytes. This would restore their ability to transport excess copper into secretory vesicles, promoting exocytosis of copper into the bile canaliculi.

Educational objective:
Penicillamine, a first-line treatment for Wilson disease, is a copper chelating agent that increases the urinary excretion of copper.

References

- Clinical management of Wilson disease.

https://t.me/USMLEWorldStep1

This patient has **Wilson disease**, an autosomal recessive disorder characterized by excessive copper deposition in the

Exhibit Display

Copper metabolism and Wilson disease

Normal copper metabolism

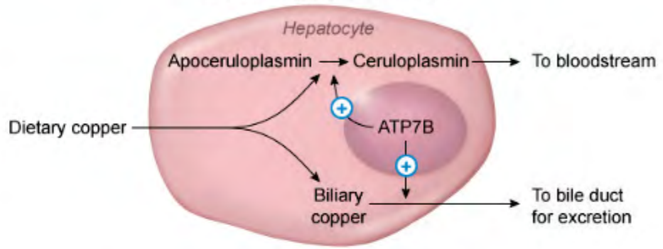

Impaired copper metabolism in Wilson disease

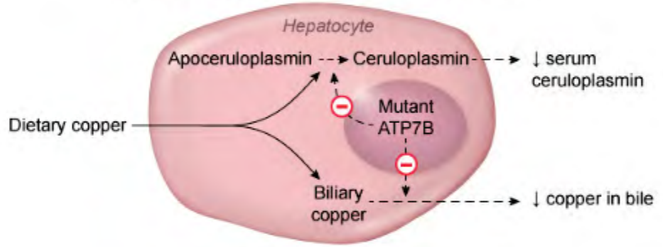

↑ hepatocellular copper
↓
Oxidative stress, necrosis & apoptosis
↓
Release of free copper into bloodstream
↓
Extrahepatic copper deposition

©UWorld

Zoom In | Zoom Out | Reset | New | Existing | My Notebook

References

- Clinical management of Wilson disease.

https://t.me/USMLEWorldStep1

A 52-year-old man is brought to the emergency department due to repeated vomiting that began 2 hours ago. His vomit is dark brown and has a granular consistency. The patient has a history of dyspepsia, for which he takes over-the-counter antacids as needed and degenerative knee arthritis, for which he takes naproxen regularly. He drinks 2-3 beers daily. Temperature is 36.7 C (98 F), blood pressure is 114/62 mm Hg, pulse is 102/min, and respirations are 14/min. Physical examination reveals mild epigastric tenderness with no rebound or guarding. Hemoglobin is 9 g/dL. Endoscopy shows a deep, bleeding ulcer on the posterior wall of the duodenal bulb. This patient's ulcer has most likely penetrated which of the following arteries?

- A. Common hepatic
- B. Gastroduodenal
- C. Inferior pancreaticoduodenal
- D. Left gastroepiploic
- E. Right gastric
- F. Splenic
- G. Superior mesenteric

Submit

https://t.me/USMLEWorldStep1

A 52-year-old man is brought to the emergency department due to repeated vomiting that began 2 hours ago. His vomit is dark brown and has a granular consistency. The patient has a history of dyspepsia, for which he takes over-the-counter antacids as needed and degenerative knee arthritis, for which he takes naproxen regularly. He drinks 2-3 beers daily. Temperature is 36.7 C (98 F), blood pressure is 114/62 mm Hg, pulse is 102/min, and respirations are 14/min. Physical examination reveals mild epigastric tenderness with no rebound or guarding. Hemoglobin is 9 g/dL. Endoscopy shows a deep, bleeding ulcer on the posterior wall of the duodenal bulb. This patient's ulcer has most likely penetrated which of the following arteries?

- A. Common hepatic (1%)
- ✓ B. Gastroduodenal (78%)
- ✗ C. Inferior pancreaticoduodenal (10%)
- D. Left gastroepiploic (2%)
- E. Right gastric (3%)
- F. Splenic (1%)
- G. Superior mesenteric (1%)

Incorrect
Correct answer
B

78%
Answered correctly

03 secs
Time Spent

2023
Version

Explanation

Duodenal ulcers and surrounding anatomy

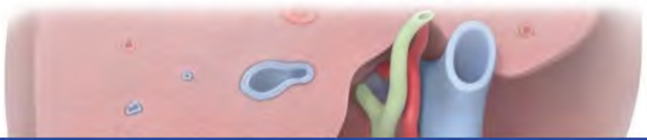

https://t.me/USMLEWorldStep1

patient's ulcer has most likely penetrated which of the following arteries?

Exhibit Display

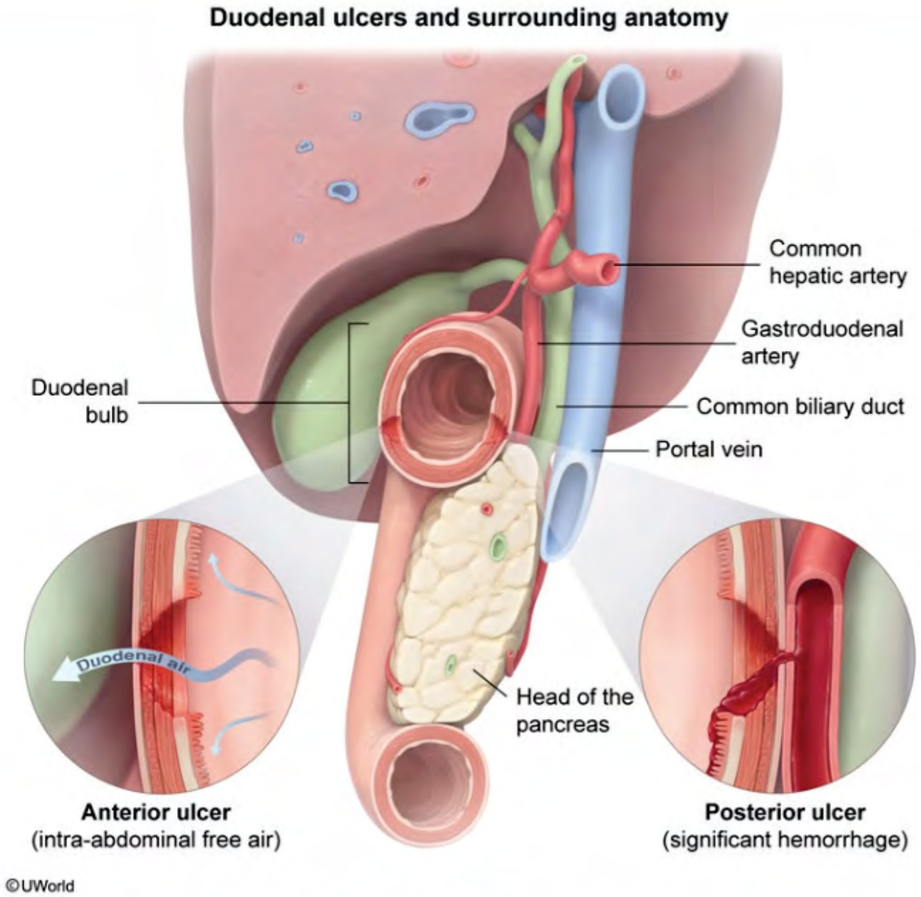

Zoom In | Zoom Out | Reset | New | Existing | My Notebook

Duodenal bulb — Common biliary duct

https://t.me/USMLEWorldStep1

Bleeding peptic ulcer disease should be considered in patients who develop acute epigastric pain, unstable vital signs, or hematemesis, particularly in the setting of prior dyspepsia. Most peptic ulcers are caused by *Helicobacter pylori* infection or nonsteroidal anti-inflammatory drug use; other risk factors include smoking, older age, and glucocorticoid use.

Duodenal ulcers are more common than gastric ulcers and tend to occur anteriorly. Ulcers located on the anterior wall of the duodenal bulb are more prone to perforation; those on the posterior wall are more likely to cause hemorrhage. These complications are explained by the relationship of the duodenal bulb to adjacent organs. The duodenal bulb is approximately 5 cm long, beginning at the pylorus and ending at the neck of the gallbladder. The gallbladder and liver lie anterior to the duodenal bulb within the intraperitoneal space; the gastroduodenal artery, common biliary duct, and portal vein are posterior to the bulb; and the head of the pancreas is located inferiorly.

When an ulcer penetrates the **posterior duodenal wall**, it is likely to erode into the gastroduodenal artery, which perfuses both the pylorus and the proximal part of the duodenum. Damage to the gastroduodenal artery can cause significant **upper gastrointestinal bleeding**.

(Choice A) The common hepatic artery arises from the celiac trunk and bifurcates into the proper hepatic and gastroduodenal arteries. It passes superior to the duodenal bulb.

(Choice C) The inferior pancreaticoduodenal artery is a branch of the superior mesenteric artery. It supplies blood to the lower duodenum and to the head of the pancreas. This artery has no close relation to the duodenal bulb.

(Choices D, E, and F) The left gastroepiploic and right gastric arteries supply blood to the greater and lesser curves of the stomach, respectively. The short gastric arteries arise off the splenic artery and supply the upper portions of the greater curvature. These vessels do not lie in close proximity to the duodenal bulb.

(Choice G) The superior mesenteric artery lies anterior to the transverse part of the duodenum. It arises from the anterior surface of the abdominal aorta and supplies the intestine from the duodenum to the proximal two-thirds of the transverse colon.

Educational objective:
The gastroduodenal artery lies along the posterior wall of the duodenal bulb and is likely to be eroded by posterior duodenal ulcers. Ulceration into the gastroduodenal artery can be a source of life-threatening hemorrhage.

https://t.me/USMLEWorldStep1

glucocorticoid use.

Duodenal ulcers are more common than gastric ulcers and tend to occur anteriorly. Ulcers located on the anterior wall of the duodenal bulb are more prone to perforation; those on the posterior wall are more likely to cause hemorrhage. These complications are explained by the relationship of the duodenal bulb to adjacent organs. The duodenal bulb is approximately 5 cm long, beginning at the pylorus and ending at the neck of the gallbladder. The gallbladder and liver lie anterior to the duodenal bulb within the intraperitoneal space; the gastroduodenal artery, common biliary duct, and portal vein are posterior to the bulb; and the head of the pancreas is located inferiorly.

When an ulcer penetrates the **posterior duodenal wall**, it is likely to erode into the gastroduodenal artery, which perfuses both the pylorus and the proximal part of the duodenum. Damage to the gastroduodenal artery can cause significant **upper gastrointestinal bleeding**.

(Choice A) The common hepatic artery arises from the celiac trunk and bifurcates into the proper hepatic and gastroduodenal arteries. It passes superior to the duodenal bulb.

(Choice C) The inferior pancreaticoduodenal artery is a branch of the superior mesenteric artery. It supplies blood to the lower duodenum and to the head of the pancreas. This artery has no close relation to the duodenal bulb.

(Choices D, E, and F) The left gastroepiploic and right gastric arteries supply blood to the greater and lesser curves of the stomach, respectively. The short gastric arteries arise off the splenic artery and supply the upper portions of the greater curvature. These vessels do not lie in close proximity to the duodenal bulb.

(Choice G) The superior mesenteric artery lies anterior to the transverse part of the duodenum. It arises from the anterior surface of the abdominal aorta and supplies the intestine from the duodenum to the proximal two-thirds of the transverse colon.

Educational objective:
The gastroduodenal artery lies along the posterior wall of the duodenal bulb and is likely to be eroded by posterior duodenal ulcers. Ulceration into the gastroduodenal artery can be a source of life-threatening hemorrhage.

Anatomy	Gastrointestinal & Nutrition	Peptic ulcer disease
Subject	System	Topic

Copyright © UWorld. All rights reserved.

https://t.me/USMLEWorldStep1

Bleeding peptic ulcer disease should be considered in patients who develop acute epigastric pain, unstable vital signs, *pylori* i glucoc

Duode wall of hemor duode gallbla comm

When perfus cause

(Choi gastro

(Choi to the

(Choi curves portion

(Choi anteric the tra

Educa

The gastroduodenal artery lies along the posterior wall of the duodenal bulb and is likely to be eroded by posterior duodenal ulcers. Ulceration into the gastroduodenal artery can be a source of life-threatening hemorrhage.

Exhibit Display

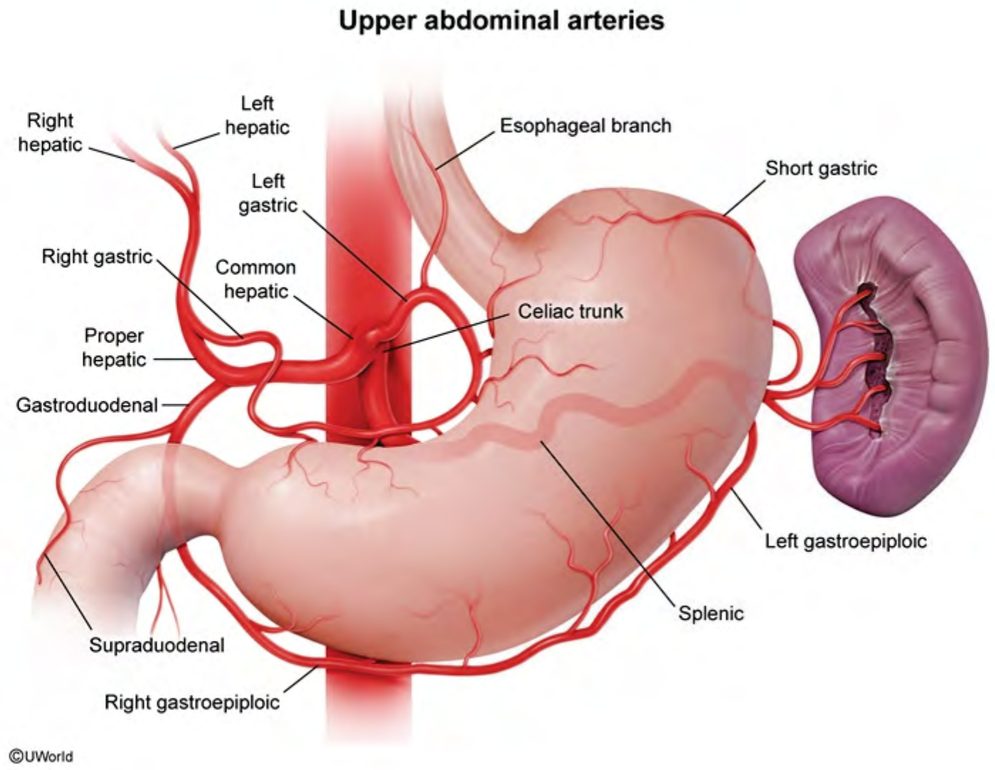

Zoom In | Zoom Out | Reset | New | Existing | My Notebook

https://t.me/USMLEWorldStep1

A 32-year-old man comes to the office due to fever, jaundice, vomiting, and decreased appetite for the past 5 days. He recently returned home from South America and reports that a couple of his travel companions have had similar symptoms. The patient does not use alcohol, tobacco, or illicit drugs and has no relevant family history. Temperature is 38.8 C (101.8 F), blood pressure is 125/80 mm Hg, pulse is 85/min. Scleral icterus and hepatomegaly are present. Laboratory results are as follows:

Complete blood count	
Hemoglobin	14.9 g/dL
Platelets	389,000/mm^3
Leukocytes	15,000/mm^3
Liver function studies	
Total bilirubin	3.9 mg/dL
Alkaline phosphatase	185 U/L
Aspartate aminotransferase (SGOT)	2,410 U/L
Alanine aminotransferase (SGPT)	3,500 U/L

Which of the following pathophysiologic events is most likely occurring in this patient?

- A. Accumulation of misfolded protein within hepatocytes
- B. CD8$^+$ T-cell response against affected hepatocytes
- C. Neutrophilic infiltration of the liver
- D. Periportal lymphoplasmacytic infiltration
- E. Transformation of hepatic stellate cells into myofibroblasts

Submit

https://t.me/USMLEWorldStep1

A 32-year-old man comes to the office due to fever, jaundice, vomiting, and decreased appetite for the past 5 days. He recently returned home from South America and reports that a couple of his travel companions have had similar symptoms. The patient does not use alcohol, tobacco, or illicit drugs and has no relevant family history. Temperature is 38.8 C (101.8 F), blood pressure is 125/80 mm Hg, pulse is 85/min. Scleral icterus and hepatomegaly are present. Laboratory results are as follows:

Complete blood count	
Hemoglobin	14.9 g/dL
Platelets	389,000/mm^3
Leukocytes	15,000/mm^3
Liver function studies	
Total bilirubin	3.9 mg/dL
Alkaline phosphatase	185 U/L
Aspartate aminotransferase (SGOT)	2,410 U/L
Alanine aminotransferase (SGPT)	3,500 U/L

Which of the following pathophysiologic events is most likely occurring in this patient?

- ✗ A. Accumulation of misfolded protein within hepatocytes (0%)
- ✓ B. CD8$^+$ T-cell response against affected hepatocytes (70%)
- C. Neutrophilic infiltration of the liver (10%)
- D. Periportal lymphoplasmacytic infiltration (16%)
- E. Transformation of hepatic stellate cells into myofibroblasts (1%)

Incorrect

https://t.me/USMLEWorldStep1

Hepatitis A	
Clinical presentation	• Fever, nausea, right upper quadrant pain • Jaundice, hepatomegaly
Diagnostic testing	• Elevated liver transaminases (>1,000 U/L) • Anti–hepatitis A serology
Pathology	• $CD8^+$ lymphocytes & NK cell response; upregulation of IFN-γ • Microscopic: mononuclear periportal infiltrates, ballooning degeneration of hepatocytes, focal necrosis

IFN-γ = interferon-gamma; **NK** = natural killer.

This patient has **hepatitis A**, a fecal-orally transmitted virus often linked to undercooked shellfish and unsanitary water supplies. Individuals at increased risk include those traveling to endemic areas (eg, South America), homeless shelter residents, and men who have sex with men. Typical manifestations include **fever**, **jaundice, hepatomegaly,** and leukocytosis. **Liver aminotransferase levels** (eg, alanine aminotransferase [ALT], aspartate aminotransferase [AST]) are dramatically elevated with levels often >1,000 U/L.

Hepatitis A triggers a robust **$CD8^+$ lymphocytic and natural killer cell response** to clear infected hepatocytes; the resulting hepatocellular damage is **self-limited**, with complete resolution within 2-3 months. Biopsy is not usually necessary for diagnosis, but typically shows a mononuclear periportal infiltrate; ballooning degeneration of hepatocytes and focal necrosis are also sometimes seen in the periportal parenchyma.

(Choice A) Alpha-1 antitrypsin (AAT) deficiency causes liver disease characterized by intracytoplasmic accumulation of a misfolded and abnormally polymerized AAT protein. However, the onset of symptoms is chronic, fever is not present, and aminotransferase elevations are generally <1,000 U/L. Also, pulmonary symptoms (eg, dyspnea, cough) are common because AAT deficiency also causes early-onset emphysema.

(Choice C) Histologic findings in alcohol-induced liver disease include lobular neutrophilic infiltrates, steatosis, ballooning of hepatocytes, and formation of Mallory-Denk bodies (eg, cytoplasmic eosinophilic inclusions within hepatocytes). However, aminotransferase elevations are modest and rarely exceed 300 U/L, usually with an

https://t.me/USMLEWorldStep1

homeless shelter residents, and men who have sex with men. Typical manifestations include **fever**, **jaundice, hepatomegaly,** and leukocytosis. **Liver aminotransferase levels** (eg, alanine aminotransferase [ALT], aspartate aminotransferase [AST]) are dramatically elevated with levels often >1,000 U/L.

Hepatitis A triggers a robust **$CD8^+$ lymphocytic and natural killer cell response** to clear infected hepatocytes; the resulting hepatocellular damage is **self-limited**, with complete resolution within 2-3 months. Biopsy is not usually necessary for diagnosis, but typically shows a mononuclear periportal infiltrate; ballooning degeneration of hepatocytes and focal necrosis are also sometimes seen in the periportal parenchyma.

(Choice A) Alpha-1 antitrypsin (AAT) deficiency causes liver disease characterized by intracytoplasmic accumulation of a misfolded and abnormally polymerized AAT protein. However, the onset of symptoms is chronic, fever is not present, and aminotransferase elevations are generally <1,000 U/L. Also, pulmonary symptoms (eg, dyspnea, cough) are common because AAT deficiency also causes early-onset emphysema.

(Choice C) Histologic findings in alcohol-induced liver disease include lobular neutrophilic infiltrates, steatosis, ballooning of hepatocytes, and formation of Mallory-Denk bodies (eg, cytoplasmic eosinophilic inclusions within hepatocytes). However, aminotransferase elevations are modest and rarely exceed 300 U/L, usually with an AST/ALT ratio >2:1, which is not present in this patient.

(Choice D) Lymphoplasmacytic infiltration is characteristic of autoimmune hepatitis. However, multiple people would not be affected with similar symptoms (as in this case) and fever is uncommon.

(Choice E) Chronic hepatic injury due to a variety of causes is associated with stellate cell activation and transformation into collagen-producing myofibroblasts, leading to hepatic fibrosis and cirrhosis. However, although acute hepatic injury in hepatitis A infection may be severe, chronic infection with progression to cirrhosis is rare.

Educational objective:
Hepatitis A presents with fever, jaundice, hepatomegaly, leukocytosis, and aminotransferase levels >1,000 U/L. It triggers a robust $CD8^+$ lymphocytic response to clear infected hepatocytes. The resulting hepatocellular damage is self-limited, with complete resolution within 2-3 months.

Pathology	Gastrointestinal & Nutrition	Hepatitis a
Subject	System	Topic

https://t.me/USMLEWorldStep1

Pathology	• $CD8^+$ lymphocytes & NK cell response; upregulation of IFN-γ • Microscopic: mononuclear periportal infiltrates, ballooning degeneration of hepatocytes
IFN	

Exhibit Display

Acute hepatitis

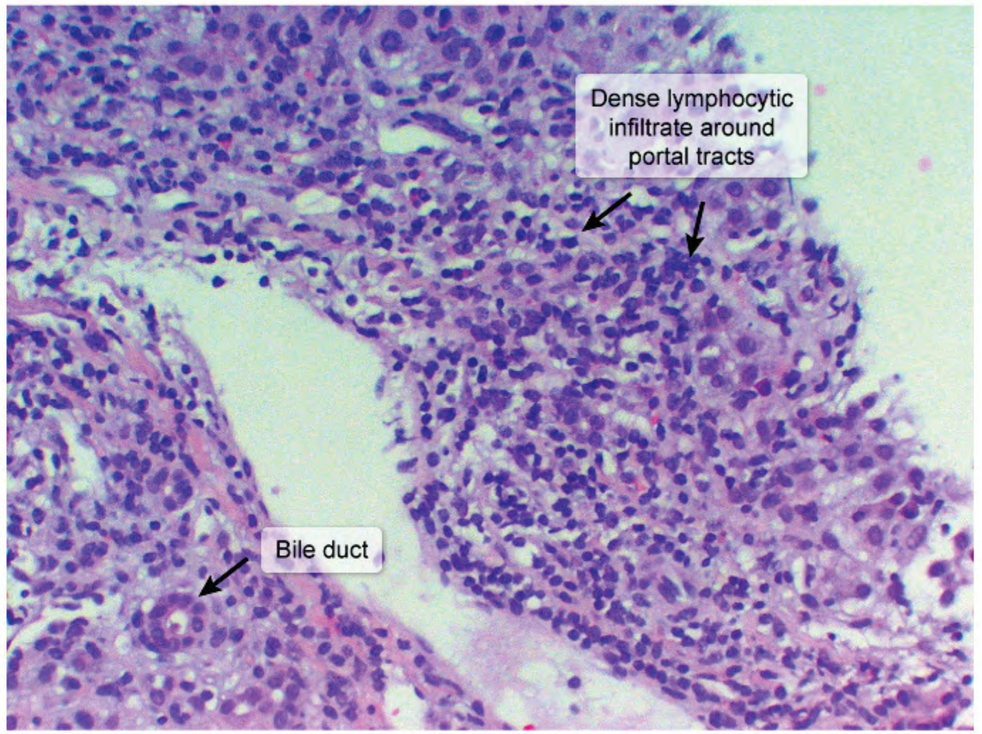

©UWorld

Zoom In | Zoom Out | Reset | New | Existing | My Notebook

This p
water
homel
hepat
amino

Hepati
resulti
neces
hepato

(Choi
accum
fever i
dyspn

(Choi
balloo
hepato
AST/A

(Choi
would

(Choi
transfo

acute hepatic injury in hepatitis A infection may be severe, chronic infection with progression to cirrhosis is rare.

https://t.me/USMLEWorldStep1

Pathology	• $CD8^+$ lymphocytes & NK cell response; upregulation of IFN-γ • Microscopic: mononuclear periportal infiltrates, ballooning degeneration of hepatocytes
IFN	

Exhibit Display

Alpha-1 antitrypsin deficiency

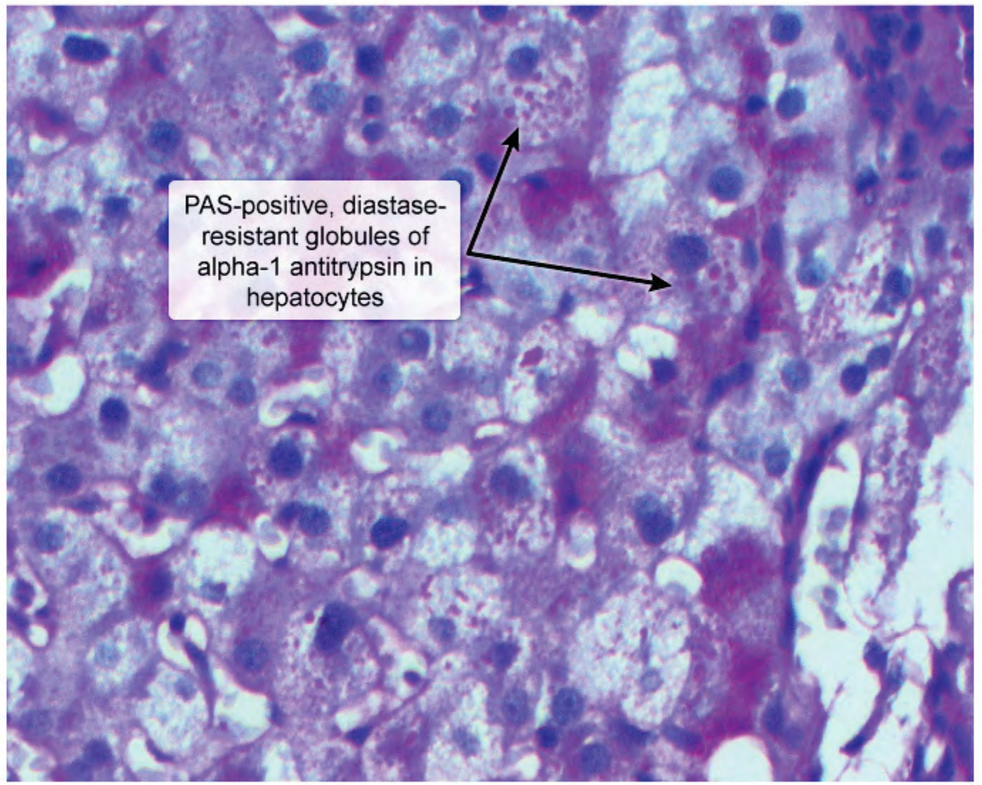

Periodic acid-Schiff (PAS) stain with diastase digestion

©UWorld

Zoom In | Zoom Out | Reset | New | Existing | My Notebook

This p
water
homel
hepat
amino

Hepati
resulti
neces
hepato

(Choi
accum
fever i
dyspn

(Choi
balloo
hepato
AST/A

(Choi
would

(Choi
transfo

acute hepatic injury in hepatitis A infection may be severe, chronic infection with progression to cirrhosis is rare.

https://t.me/USMLEWorldStep1

Pathology	• $CD8^+$ lymphocytes & NK cell response; upregulation of IFN-γ • Microscopic: mononuclear periportal infiltrates, ballooning degeneration of hepatocytes
IFN	

Exhibit Display

Alcoholic liver disease

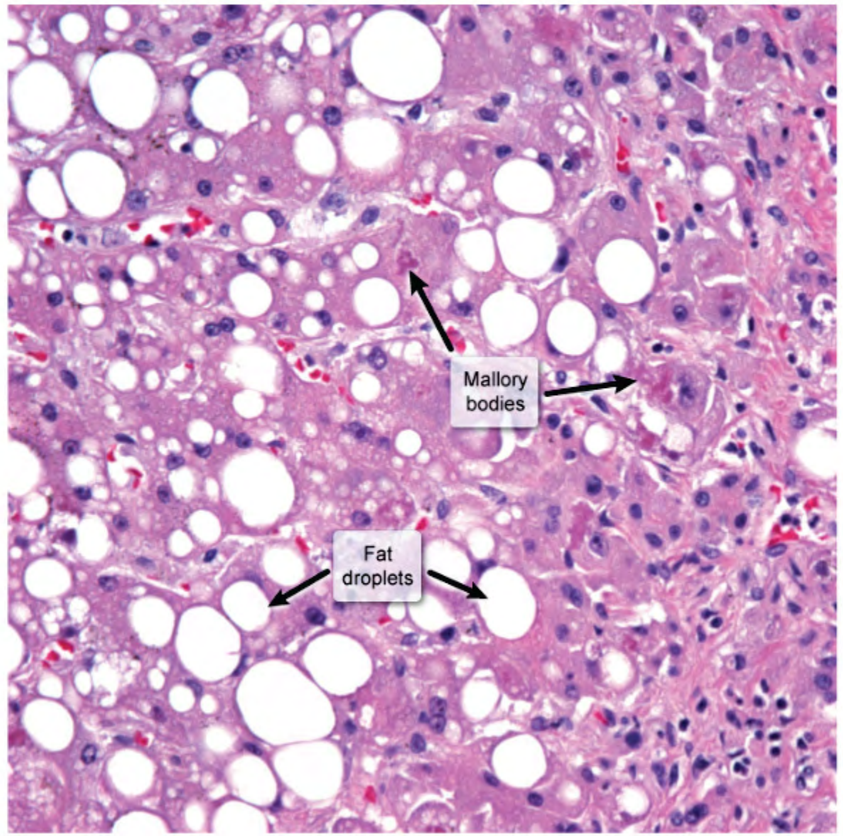

Zoom In | Zoom Out | Reset | New | Existing | My Notebook

This p
water
homel
hepat
amino

Hepati
resulti
neces
hepato

(Choi
accum
fever i
dyspn

(Choi
balloo
hepato
AST/A

(Choi
would

(Choi
transfo

acute hepatic injury in hepatitis A infection may be severe, chronic infection with progression to cirrhosis is rare.

https://t.me/USMLEWorldStep1

IFN-γ = interferon-gamma; **NK** = natural killer.

This p
water
homel
hepat
amino

Hepati
resulti
neces
hepato

(Choi
accum
fever i
dyspn

(Choi
balloo
hepato
AST/A

(Choi
would

(Choi
transfo
acute

Educa
Hepati

triggers a robust CD8+ lymphocytic response to clear infected hepatocytes. The resulting hepatocellular damage is

Exhibit Display

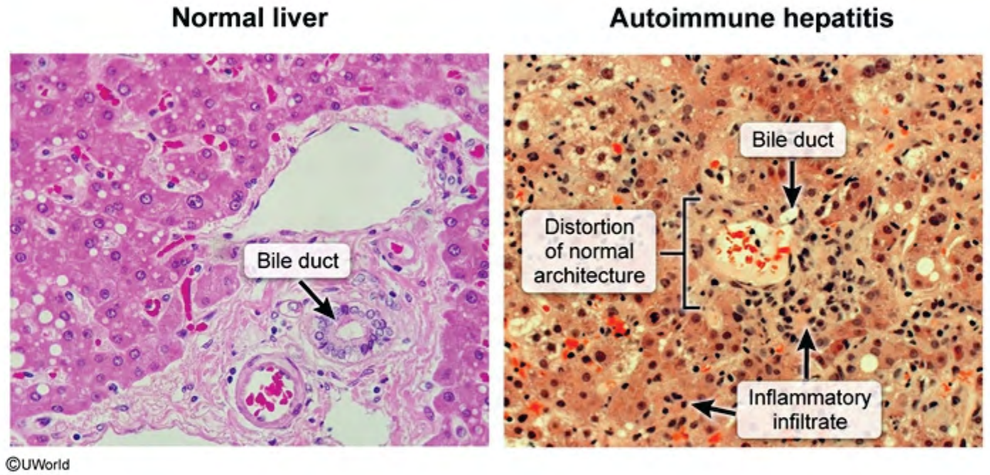

Zoom In | Zoom Out | Reset | New | Existing | My Notebook

https://t.me/USMLEWorldStep1

A 3-month-old boy is evaluated for fussiness and abdominal distension. A contrast study is performed and shown in the image below:

Which of the following is the most likely cause of this patient's condition?

A. Absent innervation of the paravertebral ganglia

B. Disruption in small bowel recanalization

https://t.me/USMLEWorldStep1

A 3-month-old boy is evaluated for fussiness and abdominal distension. A contrast study is performed and shown in the

Exhibit Display

Zoom In | Zoom Out | Reset | New | Existing | My Notebook

Which

A. Absent innervation of the paravertebral ganglia

B. Disruption in small bowel recanalization

https://t.me/USMLEWorldStep1

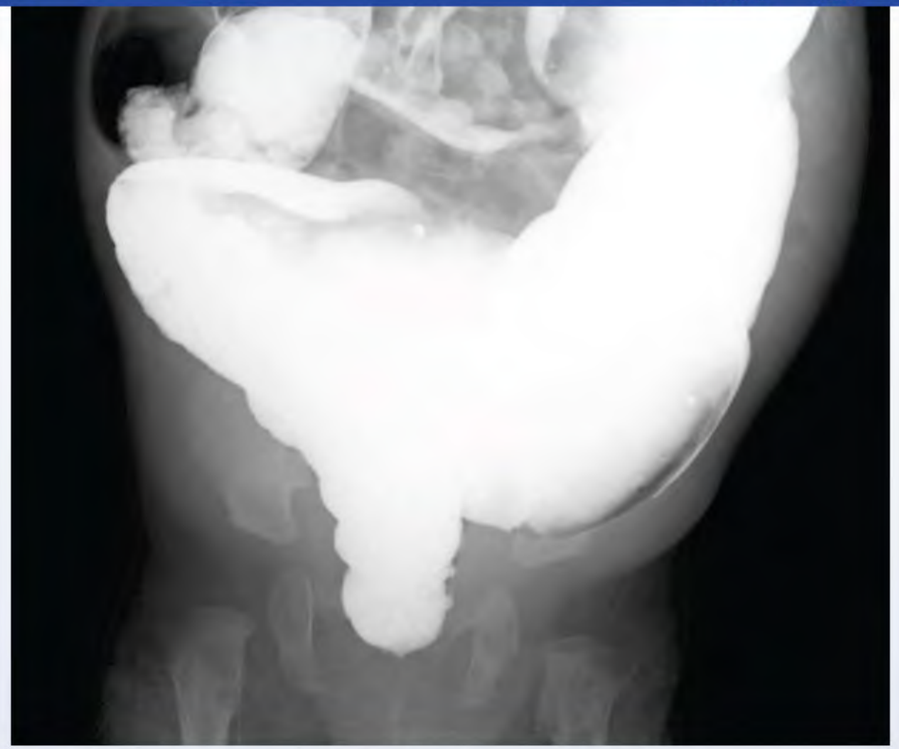

Which of the following is the most likely cause of this patient's condition?

- A. Absent innervation of the paravertebral ganglia
- B. Disruption in small bowel recanalization
- C. Incomplete rotation of the intestines
- D. Intestinal compression by the superior mesenteric artery
- E. Lack of myenteric ganglion cells

Submit

https://t.me/USMLEWorldStep1

Which of the following is the most likely cause of this patient's condition?

- A. Absent innervation of the paravertebral ganglia (3%)
- ✗ B. Disruption in small bowel recanalization (4%)
- C. Incomplete rotation of the intestines (21%)
- D. Intestinal compression by the superior mesenteric artery (3%)
- ✓ E. Lack of myenteric ganglion cells (67%)

Incorrect
Correct answer
E

67%
Answered correctly

14 secs
Time Spent

2023
Version

https://t.me/USMLEWorldStep1

Which of the following is the most likely cause of this patient's condition?

Exhibit Display

Hirschsprung disease

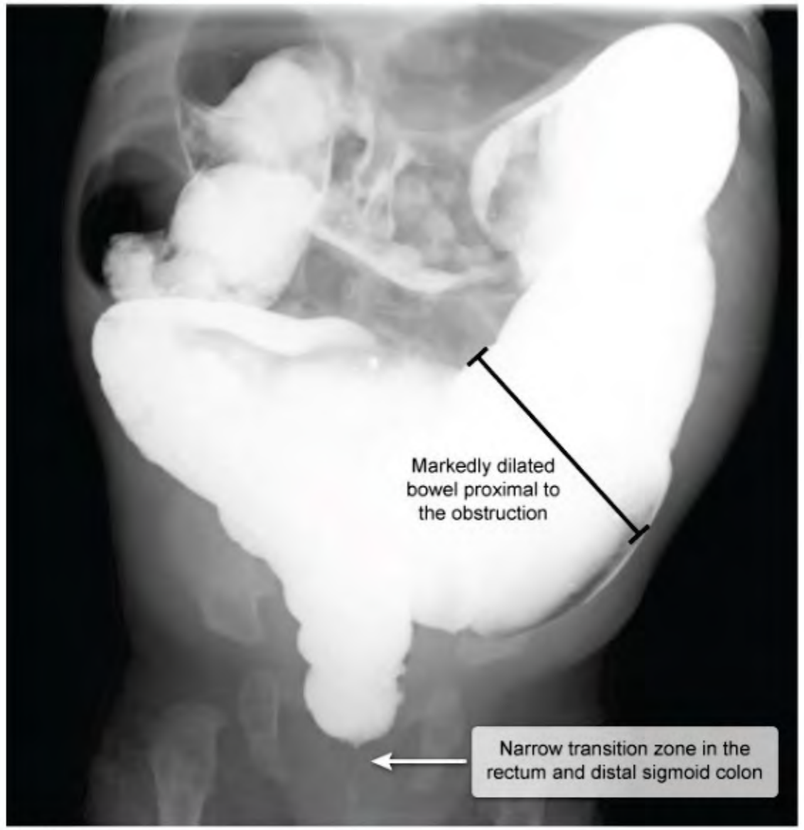

©UWorld

Zoom In | Zoom Out | Reset | New | Existing | My Notebook

Inco
Corre
E

Expl

https://t.me/USMLEWorldStep1

©UWorld

This patient's contrast enema shows an abrupt **transition zone** between the **narrow rectosigmoid** segment and the dilated descending colon (ie, megacolon). This finding is characteristic of **Hirschsprung disease** (HD), a congenital disorder caused by disrupted migration of neural crest cells to the intestinal wall during embryogenesis. Neural crest cells normally migrate in a craniocaudal direction and give rise to ganglion cells of the submucosal (Meissner) and myenteric (Auerbach) plexus in the colon. Abnormal migration results in the absence of parasympathetic innervation of the distal rectosigmoid segment.

Without parasympathetic innervation, the **aganglionic colonic segment** is unable to relax (ie, chronically contracted and narrowed), making stool difficult to pass. Presentation in the neonatal period with delayed passage of meconium (>48 hr after birth) is classic, but infants with short aganglionic segments may have fussiness due to **infrequent stooling**/chronic constipation. The buildup of stool causes **abdominal distension** and **dilation** of the histologically normal colon proximal to the obstruction.

Diagnosis of HD is confirmed by the absence of ganglia on rectal suction biopsy. Treatment is with surgical resection of the aganglionic segment.

(Choice A) Paravertebral ganglia lie adjacent to the vertebrae and are involved in sympathetic nervous signaling; paravertebral ganglia are not affected by HD.

(Choice B) Disruption of small bowel recanalization is the cause of duodenal atresia, which presents in the first 1-2 days of life with bilious emesis. Imaging would show a dilated stomach and proximal duodenum. In addition, microcolon (not a dilated colon) would be expected on barium enema.

(Choice C) Malrotation (incomplete rotation of the intestines) often presents in infancy with bilious vomiting and abdominal distension. Contrast studies show right-sided jejunal loops and may reveal a corkscrew duodenum if malrotation is complicated by volvulus (intestinal torsion). Colonic dilation would not be seen.

(Choice D) Superior mesenteric artery (SMA) syndrome causes bowel obstruction due to external duodenal compression by the SMA. Abdominal pain and distension are typical, but barium enema would not show a rectosigmoid transition zone; instead, oral contrast studies would show absence of barium beyond the duodenum.

https://t.me/USMLEWorldStep1

(Meissner) and myenteric (Auerbach) plexus in the colon. Abnormal migration results in the absence of parasympathetic innervation of the distal rectosigmoid segment.

Without parasympathetic innervation, the **aganglionic colonic segment** is unable to relax (ie, chronically contracted and narrowed), making stool difficult to pass. Presentation in the neonatal period with delayed passage of meconium (>48 hr after birth) is classic, but infants with short aganglionic segments may have fussiness due to **infrequent stooling**/chronic constipation. The buildup of stool causes **abdominal distension** and **dilation** of the histologically normal colon proximal to the obstruction.

Diagnosis of HD is confirmed by the absence of ganglia on rectal suction biopsy. Treatment is with surgical resection of the aganglionic segment.

(Choice A) Paravertebral ganglia lie adjacent to the vertebrae and are involved in sympathetic nervous signaling; paravertebral ganglia are not affected by HD.

(Choice B) Disruption of small bowel recanalization is the cause of duodenal atresia, which presents in the first 1-2 days of life with bilious emesis. Imaging would show a dilated stomach and proximal duodenum. In addition, microcolon (not a dilated colon) would be expected on barium enema.

(Choice C) Malrotation (incomplete rotation of the intestines) often presents in infancy with bilious vomiting and abdominal distension. Contrast studies show right-sided jejunal loops and may reveal a corkscrew duodenum if malrotation is complicated by volvulus (intestinal torsion). Colonic dilation would not be seen.

(Choice D) Superior mesenteric artery (SMA) syndrome causes bowel obstruction due to external duodenal compression by the SMA. Abdominal pain and distension are typical, but barium enema would not show a rectosigmoid transition zone; instead, oral contrast studies would show absence of barium beyond the duodenum.

Educational objective:
Hirschsprung disease is characterized by absent submucosal and myenteric ganglion cells in the distal colon. Contrast enema classically shows a narrowed aganglionic segment (most commonly rectosigmoid) with an abrupt transition zone to the dilated, histologically normal proximal colon.

Pathology	Gastrointestinal & Nutrition	Hirschsprung's disease
Subject	System	Topic

https://t.me/USMLEWorldStep1

the dilated descending colon (ie, megacolon). This finding is characteristic of **Hirschsprung disease** (HD), a
congen
Neura
(Meiss
parasy

Withou
contra
of mec
infreq
histolo

Diagn
resect

(Choi
parave

(Choi
2 days
microc

(Choi
abdom
malrot

(Choi
compr
rectos

Educa
Hirsch

Contrast enema classically shows a narrowed aganglionic segment (most commonly rectosigmoid) with an abrupt

Exhibit Display

Duodenal atresia

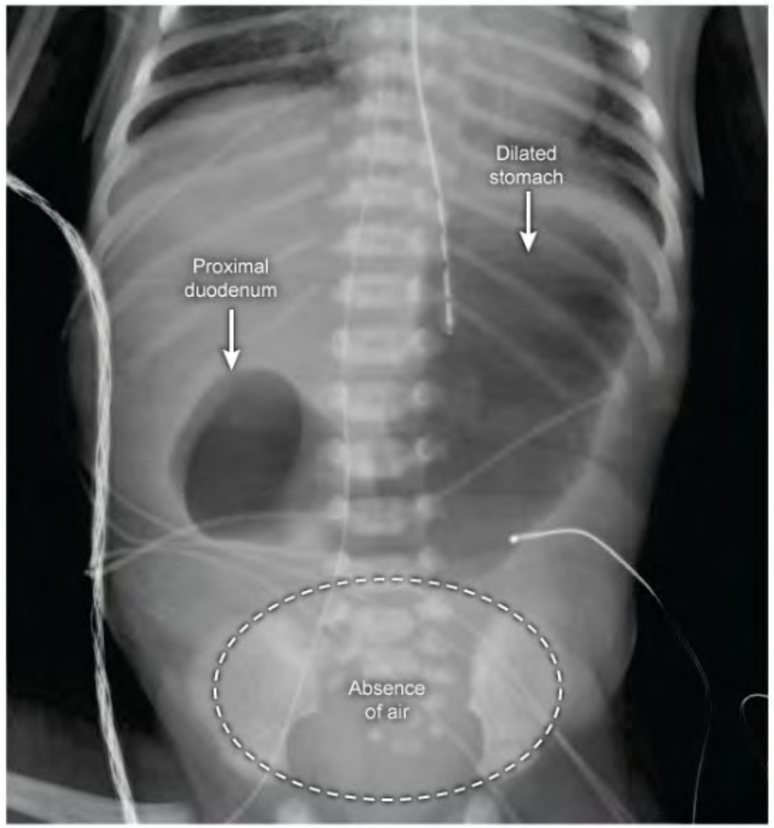

©UWorld

Zoom In | Zoom Out | Reset | New | Existing | My Notebook

https://t.me/USMLEWorldStep1

(Meissner) and myenteric (Auerbach) plexus in the colon. Abnormal migration results in the absence of parasympathetic innervation of the distal rectosigmoid segment.

Exhibit Display

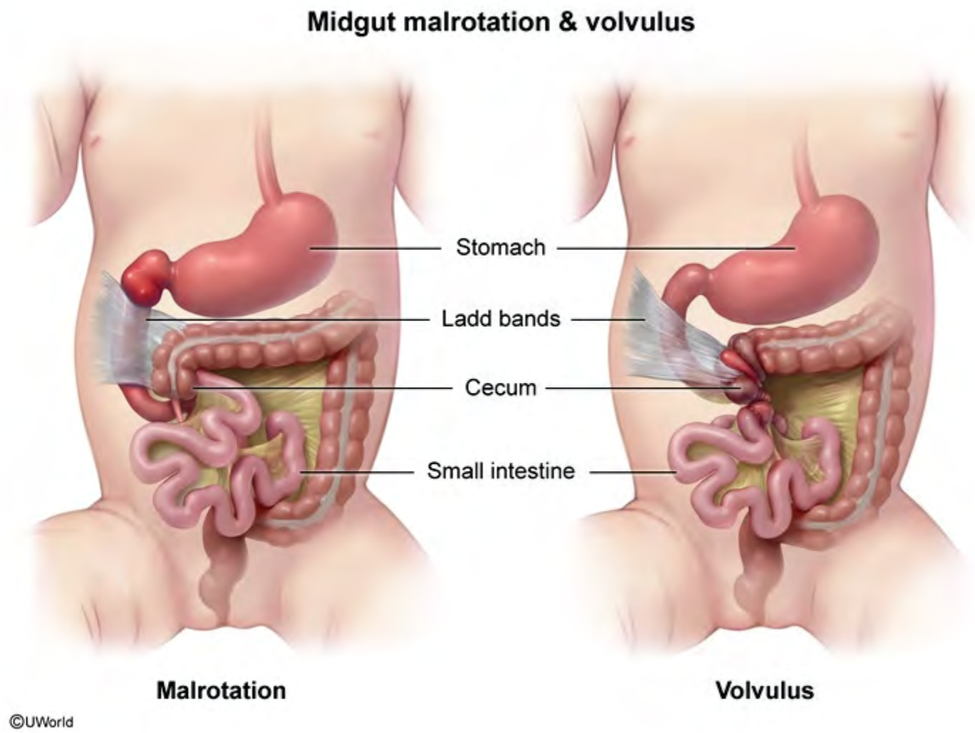

Zoom In | Zoom Out | Reset | New | Existing | My Notebook

Withou
contra
of mec
infreq
histolc

Diagnc
resect

(Choic
parave

(Choic
2 days
microc

(Choic
abdom
malrot

(Choic
compr
rectos

Educa
Hirsch
Contra
transition zone to the dilated, histologically normal proximal colon.

Pathology
Subject

Gastrointestinal & Nutrition
System

Hirschsprung's disease
Topic

https://t.me/USMLEWorldStep1

(Meissner) and myenteric (Auerbach) plexus in the colon. Abnormal migration results in the absence of parasympathetic innervation of the distal rectosigmoid segment.

Exhibit Display

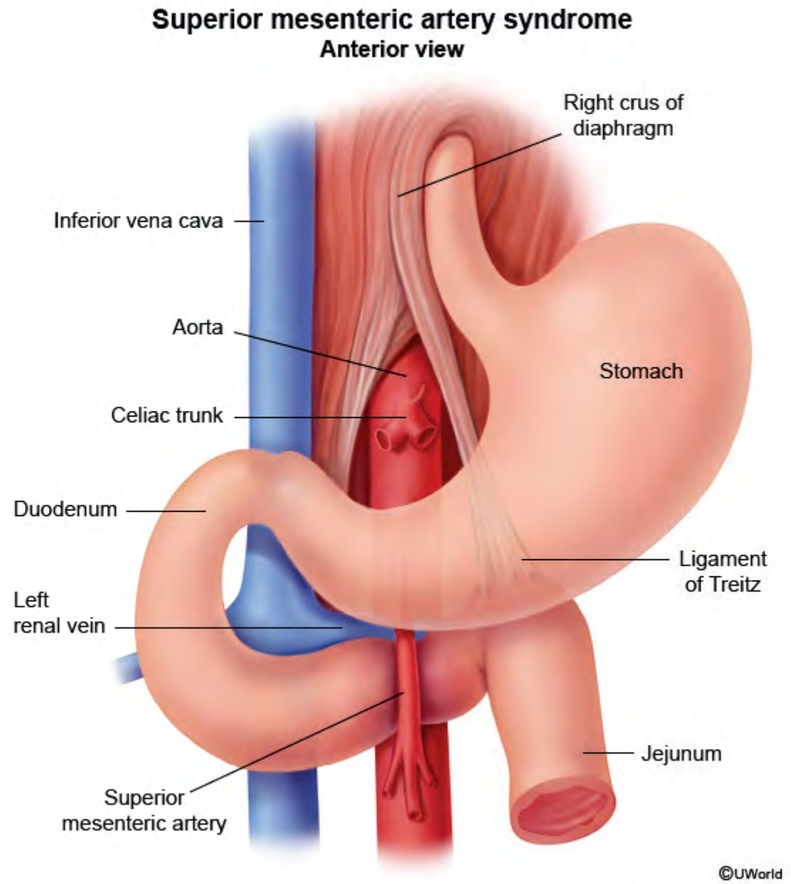

Zoom In | Zoom Out | Reset | New | Existing | My Notebook

Pathology (Subject) | Gastrointestinal & Nutrition (System) | Hirschsprung's disease (Topic)

https://t.me/USMLEWorldStep1

A 73-year-old woman is brought to the clinic by her niece due to a 10-day history of abdominal pain and loss of appetite. The patient does not like "going to the doctor" and has not been seen by a physician in many years. Frequent loose stools and loss of appetite have been present since the pain began. Family history is significant for colon cancer in a maternal aunt. Temperature is 37.8 C (100 F) and pulse is 98/min. Abdominal examination is significant for tenderness on deep palpation of the left lower quadrant, along with an appreciable mass. There is no inguinal lymphadenopathy. White blood cell count is 15,000/mm^3. Which of the following is the most likely cause of the abdominal pain in this patient?

- A. Acute diverticulitis
- B. Colon cancer
- C. Incarcerated direct inguinal hernia
- D. Ischemic colitis
- E. Tubo-ovarian abscess
- F. Ulcerative colitis

Submit

https://t.me/USMLEWorldStep1

A 73-year-old woman is brought to the clinic by her niece due to a 10-day history of abdominal pain and loss of appetite. The patient does not like "going to the doctor" and has not been seen by a physician in many years. Frequent loose stools and loss of appetite have been present since the pain began. Family history is significant for colon cancer in a maternal aunt. Temperature is 37.8 C (100 F) and pulse is 98/min. Abdominal examination is significant for tenderness on deep palpation of the left lower quadrant, along with an appreciable mass. There is no inguinal lymphadenopathy. White blood cell count is 15,000/mm^3. Which of the following is the most likely cause of the abdominal pain in this patient?

- ✓ A. Acute diverticulitis (66%)
- ✗ B. Colon cancer (14%)
- C. Incarcerated direct inguinal hernia (4%)
- D. Ischemic colitis (5%)
- E. Tubo-ovarian abscess (5%)
- F. Ulcerative colitis (2%)

Incorrect
Correct answer
A

66%
Answered correctly

04 secs
Time Spent

2023
Version

Explanation

Acute diverticulitis	
Pathogenesis	• Trapped food particles & ↑ intracolonic pressure that cause microperforation of colonic diverticula
Clinical	• Abdominal pain (usually left lower quadrant) • Nausea, vomiting, change in bowel habits

https://t.me/USMLEWorldStep1

Explanation

Acute diverticulitis	
Pathogenesis	• Trapped food particles & ↑ intracolonic pressure that cause microperforation of colonic diverticula
Clinical presentation	• Abdominal pain (usually left lower quadrant) • Nausea, vomiting, change in bowel habits • Tenderness ± palpable mass • Leukocytosis
Diagnosis	• Abdominal CT scan (oral & intravenous contrast)

This patient with abdominal pain, leukocytosis, low-grade fever, and a mass palpated in the left lower quadrant likely has acute diverticulitis. Diverticulitis is characterized by inflammation of colonic diverticula (ie, herniated outpouchings of the colonic mucosa and submucosa through the muscularis mucosae) and is caused by trapped food particles and elevated intraluminal pressure within a diverticulum, resulting in microperforation. The risk increases with age (particularly in those age ≥60).

Patients commonly present with constant **abdominal pain**, classically in the **left lower quadrant**, signifying sigmoid colon involvement. Other symptoms include nausea, vomiting, and changes in bowel habits (constipation or diarrhea). Patients often have low-grade **fever**, and examination may reveal **lower abdominal tenderness** and, often, a **palpable mass** due to inflammation or abscess formation. Mild leukocytosis is a common laboratory finding; occult blood may be present, but gross hematochezia is rare.

(Choice B) Colon cancer may present with abdominal pain. However, a tumor large enough to palpate on examination suggests extensive disease and would typically be associated with more chronic symptoms (eg, weight loss). The leukocytosis and short duration of symptoms in this patient are more consistent with diverticulitis.

(Choice C) Incarcerated direct inguinal hernias cause a palpable mass; however, the mass would typically be in the groin, not the abdomen. In addition, unless the hernia is strangulated, leukocytosis and fevers are unexpected.

https://t.me/USMLEWorldStep1

likely has acute diverticulitis. Diverticulitis is characterized by inflammation of colonic diverticula (ie, herniated outpouchings of the colonic mucosa and submucosa through the muscularis mucosae) and is caused by trapped food particles and elevated intraluminal pressure within a diverticulum, resulting in microperforation. The risk increases with age (particularly in those age ≥60).

Patients commonly present with constant **abdominal pain**, classically in the **left lower quadrant**, signifying sigmoid colon involvement. Other symptoms include nausea, vomiting, and changes in bowel habits (constipation or diarrhea). Patients often have low-grade **fever**, and examination may reveal **lower abdominal tenderness** and, often, a **palpable mass** due to inflammation or abscess formation. Mild leukocytosis is a common laboratory finding; occult blood may be present, but gross hematochezia is rare.

(Choice B) Colon cancer may present with abdominal pain. However, a tumor large enough to palpate on examination suggests extensive disease and would typically be associated with more chronic symptoms (eg, weight loss). The leukocytosis and short duration of symptoms in this patient are more consistent with diverticulitis.

(Choice C) Incarcerated direct inguinal hernias cause a palpable mass; however, the mass would typically be in the groin, not the abdomen. In addition, unless the hernia is strangulated, leukocytosis and fevers are unexpected.

(Choice D) Ischemic colitis is a common cause of abdominal pain in an older patient; however, it typically presents with hematochezia and postprandial pain in patients with ischemic risk factors (eg, hypertension, diabetes).

(Choice E) Tubo-ovarian abscess can cause abdominal pain and leukocytosis; however, patients typically have vaginal discharge, and a mass (if present) is located in the pelvis, not the abdomen. Tubo-ovarian abscesses typically occur in the setting of pelvic inflammatory disease, which is far more common in patients age <40.

(Choice F) Ulcerative colitis often presents with abdominal pain and diarrhea; however, hematochezia is common. In addition, patients are typically diagnosed at age 20-40.

Educational objective:
Diverticulitis is characterized by inflammation of colonic diverticula. Patients have abdominal pain, nausea, vomiting, and changes in bowel habits. Low-grade fever and leukocytosis are common, and physical examination may demonstrate a tender mass in the left lower quadrant.

References

https://t.me/USMLEWorldStep1

The mother of a 2-year-old boy calls the office for guidance regarding his recent illness. He has passed 4-6 stools daily over the last 2 days. The feces are liquid and contain no blood or mucus. His highest temperature reading at home was 37.8 C (100 F). He is eating, drinking, and being playful as usual. The patient has no prior medical problems and is up to date with vaccinations. He recently began going to day care. The mother is advised to bring the patient to the office for further evaluation. While awaiting medical evaluation, which of the following oral fluids is most effective to prevent dehydration in this patient?

- A. Chicken broth with added salt
- B. Diluted cow's milk
- C. Filtered water with no added solutes
- D. Noncarbonated sports drinks
- E. Sodium-glucose solution
- F. Sugary fruit juices

Submit

https://t.me/USMLEWorldStep1

The mother of a 2-year-old boy calls the office for guidance regarding his recent illness. He has passed 4-6 stools daily over the last 2 days. The feces are liquid and contain no blood or mucus. His highest temperature reading at home was 37.8 C (100 F). He is eating, drinking, and being playful as usual. The patient has no prior medical problems and is up to date with vaccinations. He recently began going to day care. The mother is advised to bring the patient to the office for further evaluation. While awaiting medical evaluation, which of the following oral fluids is most effective to prevent dehydration in this patient?

- A. Chicken broth with added salt (8%)
- ✗ B. Diluted cow's milk (0%)
- C. Filtered water with no added solutes (10%)
- D. Noncarbonated sports drinks (21%)
- ✓ E. Sodium-glucose solution (58%)
- F. Sugary fruit juices (0%)

Incorrect
Correct answer
E

58%
Answered correctly

03 secs
Time Spent

2023
Version

Explanation

Humans consume approximately 2 L of fluid each day and secrete an additional 7 L of fluid from upper digestive organs (eg, salivary glands, stomach, pancreas, gallbladder). Nearly all of this fluid is reabsorbed from the gastrointestinal lumen by the small intestine epithelium. The **osmotic gradient** for water reabsorption is largely established by the **active cotransport of sodium** into the apical end of enterocytes coupled with chloride, glucose, or amino acids. Sodium is then transported out of the basolateral end of the enterocyte (sodium/potassium ATPase), which pulls water down its osmotic gradient from the gastrointestinal lumen through the tight junctions between enterocytes and into the lamina propria (and ultimately the bloodstream).

https://t.me/USMLEWorldStep1

Humans consume approximately 2 L of fluid each day and secrete an additional 7 L of fluid from upper digestive organs (eg, salivary glands, stomach, pancreas, gallbladder). Nearly all of this fluid is reabsorbed from the gastrointestinal lumen by the small intestine epithelium. The **osmotic gradient** for water reabsorption is largely established by the **active cotransport of sodium** into the apical end of enterocytes coupled with chloride, glucose, or amino acids. Sodium is then transported out of the basolateral end of the enterocyte (sodium/potassium ATPase), which pulls water down its osmotic gradient from the gastrointestinal lumen through the tight junctions between enterocytes and into the lamina propria (and ultimately the bloodstream).

This young patient who recently began going to day care likely has **acute infectious diarrhea** of a viral etiology (eg, rotavirus, norovirus). Infections that target the small intestine cause watery diarrhea by blocking the active transport of sodium chloride into the enterocyte or by increasing chloride excretion into the gastrointestinal lumen (mediated by elevated intracellular cyclic AMP, cyclic GMP, or calcium). In this setting, oral rehydration with a hypotonic, **equimolar sodium-glucose solution** maximizes water and sodium reabsorption by the remaining functional enterocytes, and is the most effective oral therapy for maintaining volume and electrolyte status in children with acute infectious diarrhea.

(Choice A) Chicken broth with added salt is a hyperosmolar solution that can cause hypernatremia and is, therefore, not recommended.

(Choice B) Diluted or undiluted cow's milk is not an effective rehydration solution during acute diarrhea due to impaired digestion of milk components, which can promote osmotic diarrhea.

(Choice C) Filtered water alone is not usually sufficient to prevent dehydration in patients with acute infectious diarrhea due to the increased solute load in the gastrointestinal lumen, which causes most of the free water to be retained in the intestine and excreted in the feces.

(Choices D and F) Although sports drinks and sugary fruit juices contain glucose, they often have significantly lower sodium concentrations and high osmolality. This ultimately reduces water reabsorption and may promote osmotic diarrhea.

Educational objective:

https://t.me/USMLEWorldStep1

gastrointestinal lumen by the small intestine epithelium. The **osmotic gradient** for water reabsorption is largely established by the **active cotransport of sodium** into the apical end of enterocytes coupled with chloride, glucose, or amino acids. Sodium is then transported out of the basolateral end of the enterocyte (sodium/potassium ATPase), which pulls water down its osmotic gradient from the gastrointestinal lumen through the tight junctions between enterocytes and into the lamina propria (and ultimately the bloodstream).

This young patient who recently began going to day care likely has **acute infectious diarrhea** of a viral etiology (eg, rotavirus, norovirus). Infections that target the small intestine cause watery diarrhea by blocking the active transport of sodium chloride into the enterocyte or by increasing chloride excretion into the gastrointestinal lumen (mediated by elevated intracellular cyclic AMP, cyclic GMP, or calcium). In this setting, oral rehydration with a hypotonic, **equimolar sodium-glucose solution** maximizes water and sodium reabsorption by the remaining functional enterocytes, and is the most effective oral therapy for maintaining volume and electrolyte status in children with acute infectious diarrhea.

(Choice A) Chicken broth with added salt is a hyperosmolar solution that can cause hypernatremia and is, therefore, not recommended.

(Choice B) Diluted or undiluted cow's milk is not an effective rehydration solution during acute diarrhea due to impaired digestion of milk components, which can promote osmotic diarrhea.

(Choice C) Filtered water alone is not usually sufficient to prevent dehydration in patients with acute infectious diarrhea due to the increased solute load in the gastrointestinal lumen, which causes most of the free water to be retained in the intestine and excreted in the feces.

(Choices D and F) Although sports drinks and sugary fruit juices contain glucose, they often have significantly lower sodium concentrations and high osmolality. This ultimately reduces water reabsorption and may promote osmotic diarrhea.

Educational objective:
Children with watery diarrhea should be treated with oral rehydration solutions containing hypotonic, equimolar concentrations of sodium and glucose to help prevent dehydration and electrolyte abnormalities.

References

https://t.me/USMLEWorldStep1

A 32-year-old man comes to the clinic for peptic ulcer disease follow-up. The patient has received several months of proton pump inhibitor therapy without significant improvement in his epigastric discomfort. He does not use nonsteroidal anti-inflammatory drugs, tobacco, or alcohol. *Helicobacter pylori* testing is negative. The patient undergoes a partial gastrectomy for refractory peptic ulcer disease. The pathologist receives the tissue and notes significant enlargement of the gastric rugal folds on gross examination. Microscopy of the gastric mucosa reveals parietal cell hyperplasia. Which of the following stimuli is the most likely cause of parietal cell proliferation in this patient?

- A. Acetylcholine
- B. Gastrin
- C. Secretin
- D. Serotonin
- E. Somatostatin
- F. Transforming growth factor alpha

Submit

https://t.me/USMLEWorldStep1

A 32-year-old man comes to the clinic for peptic ulcer disease follow-up. The patient has received several months of proton pump inhibitor therapy without significant improvement in his epigastric discomfort. He does not use nonsteroidal anti-inflammatory drugs, tobacco, or alcohol. *Helicobacter pylori* testing is negative. The patient undergoes a partial gastrectomy for refractory peptic ulcer disease. The pathologist receives the tissue and notes significant enlargement of the gastric rugal folds on gross examination. Microscopy of the gastric mucosa reveals parietal cell hyperplasia. Which of the following stimuli is the most likely cause of parietal cell proliferation in this patient?

- A. Acetylcholine (7%)
- ✓ B. Gastrin (82%)
- C. Secretin (3%)
- D. Serotonin (0%)
- E. Somatostatin (1%)
- F. Transforming growth factor alpha (3%)

Correct | 82% Answered correctly | 03 secs Time Spent | 2023 Version

Explanation

Parietal cells are located in the gastric glands of the fundus and body of the stomach. They can be spotted easily due to their eosinophilic cytoplasm on H&E stain. These cells have abundant mitochondria and an intracellular tubulovesicular system that allows them to secrete large quantities of gastric acid (HCl) and intrinsic factor.

Parietal cells are influenced by a number of substances. Histamine, acetylcholine, and gastrin increase gastric acid secretion, but prostaglandins inhibit it. **Gastrin** not only stimulates **HCl secretion**, but it also has a **trophic effect** on parietal cells. In patients with Zollinger-Ellison syndrome (such as this patient), gastrin hypersecretion

https://t.me/USMLEWorldStep1

Explanation

Parietal cells are located in the gastric glands of the fundus and body of the stomach. They can be spotted easily due to their eosinophilic cytoplasm on H&E stain. These cells have abundant mitochondria and an intracellular tubulovesicular system that allows them to secrete large quantities of gastric acid (HCl) and intrinsic factor.

Parietal cells are influenced by a number of substances. Histamine, acetylcholine, and gastrin increase gastric acid secretion, but prostaglandins inhibit it. **Gastrin** not only stimulates **HCl secretion**, but it also has a **trophic effect** on parietal cells. In patients with Zollinger-Ellison syndrome (such as this patient), gastrin hypersecretion induces **parietal cell hyperplasia**, causing visible **enlargement of gastric folds** on endoscopy. The increased gastric acid secretion induced by excess gastrin also causes peptic ulcer disease, heartburn, and diarrhea.

(Choice A) Acetylcholine is a universal neurotransmitter that is present in parasympathetic postganglionic synapses and in all autonomic preganglionic synapses. Cholinergic receptors are divided into muscarinic (located in smooth muscle and glands) and nicotinic (found at the neuromuscular junction). Acetylcholine stimulates parietal cell acid secretion but is not typically associated with parietal cell hyperplasia or gastric fold enlargement.

(Choice C) Secretin is produced by S cells of the small intestine. It increases bicarbonate production by the pancreas and leads to the secretion of watery, alkaline pancreatic juice. This substance also inhibits gastric acid secretion and stimulates pyloric sphincter contraction.

(Choice D) Serotonin (5HT) is primarily found in enterochromaffin cells of the gastrointestinal (GI) tract, the central nervous system, and platelets. In the GI tract, it helps to regulate intestinal secretions and peristalsis.

(Choice E) Somatostatin (growth hormone-inhibiting hormone) is secreted by D cells of pancreatic islets and GI mucosa. It has multiple inhibitory effects over the GI tract, including decreasing motility, gastrin secretion, pancreatic endocrine/exocrine secretion, and absorption of nutrients.

(Choice F) Transforming growth factor alpha (TGF-α) is a potent stimulator of epithelial growth and is secreted by carcinomas, macrophages, and epithelial cells. Menetrier disease is associated with overproduction of TGF-α, resulting in mucosal-cell hyperplasia with gastric fold enlargement. However, the condition causes hypoplasia of parietal/chief cells, resulting in glandular atrophy with reduced gastric acid secretion.

https://t.me/USMLEWorldStep1

due to their eosinophilic cytoplasm on H&E stain. These cells have abundant mitochondria and an intracellular tubulovesicular system that allows them to secrete large quantities of gastric acid (HCl) and intrinsic factor.

Parietal cells are influenced by a number of substances. Histamine, acetylcholine, and gastrin increase gastric acid secretion, but prostaglandins inhibit it. **Gastrin** not only stimulates **HCl secretion**, but it also has a **trophic effect** on parietal cells. In patients with Zollinger-Ellison syndrome (such as this patient), gastrin hypersecretion induces **parietal cell hyperplasia**, causing visible **enlargement of gastric folds** on endoscopy. The increased gastric acid secretion induced by excess gastrin also causes peptic ulcer disease, heartburn, and diarrhea.

(Choice A) Acetylcholine is a universal neurotransmitter that is present in parasympathetic postganglionic synapses and in all autonomic preganglionic synapses. Cholinergic receptors are divided into muscarinic (located in smooth muscle and glands) and nicotinic (found at the neuromuscular junction). Acetylcholine stimulates parietal cell acid secretion but is not typically associated with parietal cell hyperplasia or gastric fold enlargement.

(Choice C) Secretin is produced by S cells of the small intestine. It increases bicarbonate production by the pancreas and leads to the secretion of watery, alkaline pancreatic juice. This substance also inhibits gastric acid secretion and stimulates pyloric sphincter contraction.

(Choice D) Serotonin (5HT) is primarily found in enterochromaffin cells of the gastrointestinal (GI) tract, the central nervous system, and platelets. In the GI tract, it helps to regulate intestinal secretions and peristalsis.

(Choice E) Somatostatin (growth hormone-inhibiting hormone) is secreted by D cells of pancreatic islets and GI mucosa. It has multiple inhibitory effects over the GI tract, including decreasing motility, gastrin secretion, pancreatic endocrine/exocrine secretion, and absorption of nutrients.

(Choice F) Transforming growth factor alpha (TGF-α) is a potent stimulator of epithelial growth and is secreted by carcinomas, macrophages, and epithelial cells. Menetrier disease is associated with overproduction of TGF-α, resulting in mucosal-cell hyperplasia with gastric fold enlargement. However, the condition causes hypoplasia of parietal/chief cells, resulting in glandular atrophy with reduced gastric acid secretion.

Educational objective:
Patients with Zollinger-Ellison syndrome develop peptic ulcer disease and parietal cell hyperplasia with gastric fold enlargement due to gastrin hypersecretion.

https://t.me/USMLEWorldStep1

A mass resected from the liver of a 32-year-old woman has the morphology demonstrated on the slide below.

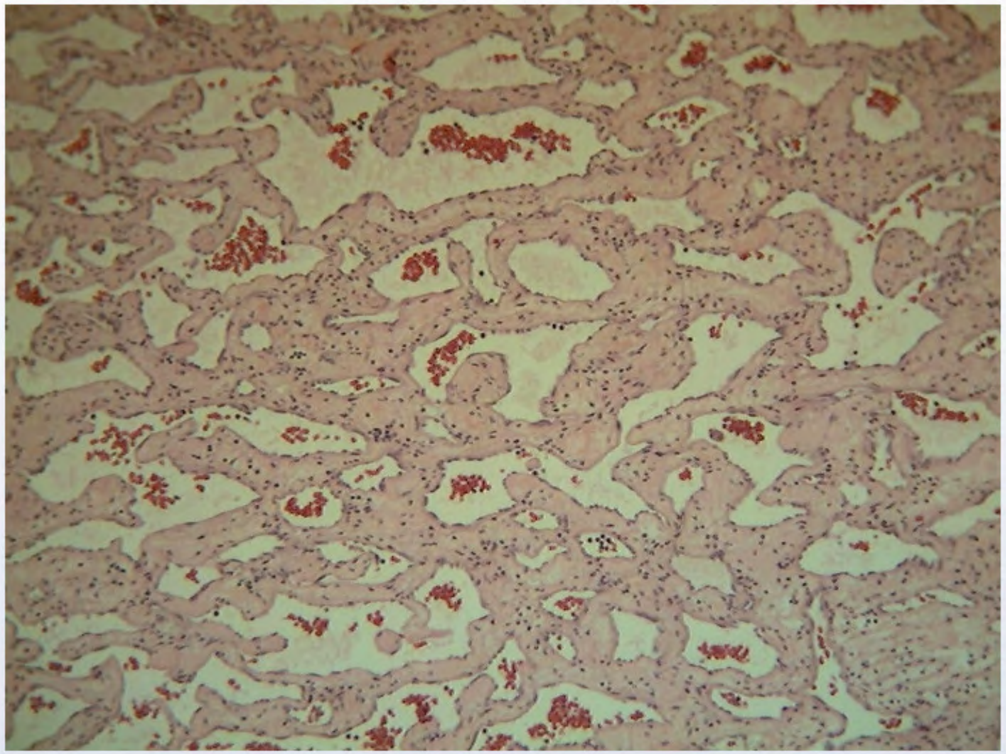

Which of the following is the most accurate statement concerning this patient's condition?

- A. Malignant transformation is a rule
- B. It is the most common benign liver tumor
- C. It can regress upon oral contraceptive discontinuation
- D. It is strongly associated with hemochromatosis
- E. Biopsy is indicated to confirm the diagnosis

https://t.me/USMLEWorldStep1

A mass resected from the liver of a 32-year-old woman has the morphology demonstrated on the slide below.

Exhibit Display

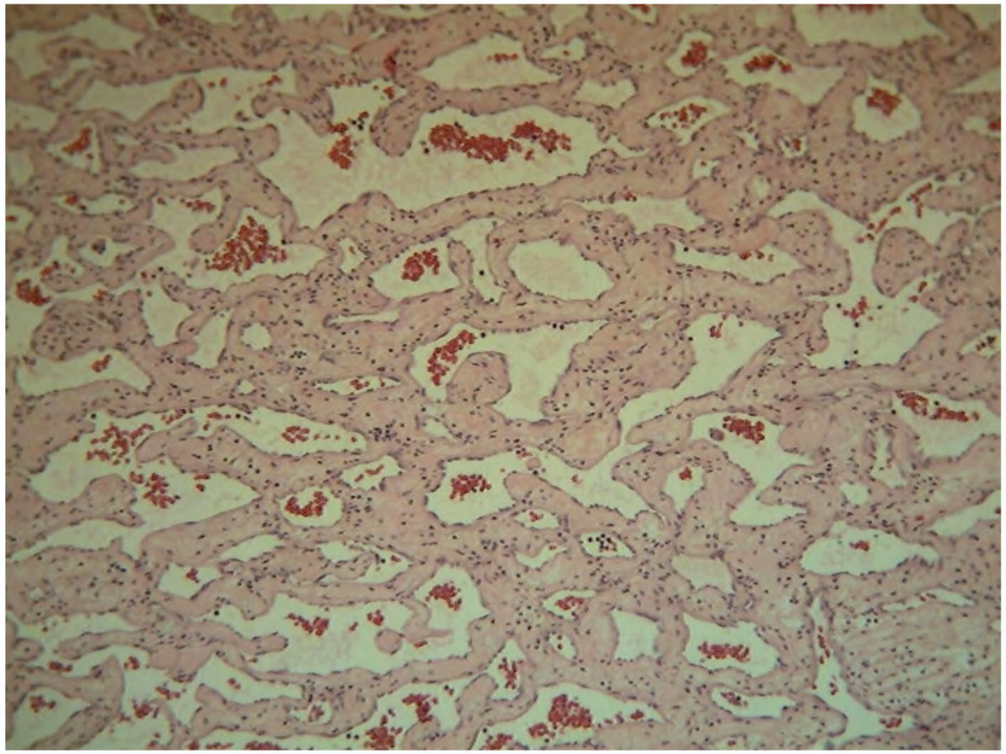

Zoom In Zoom Out Reset New | Existing My Notebook

Which

E. Biopsy is indicated to confirm the diagnosis

https://t.me/USMLEWorldStep1

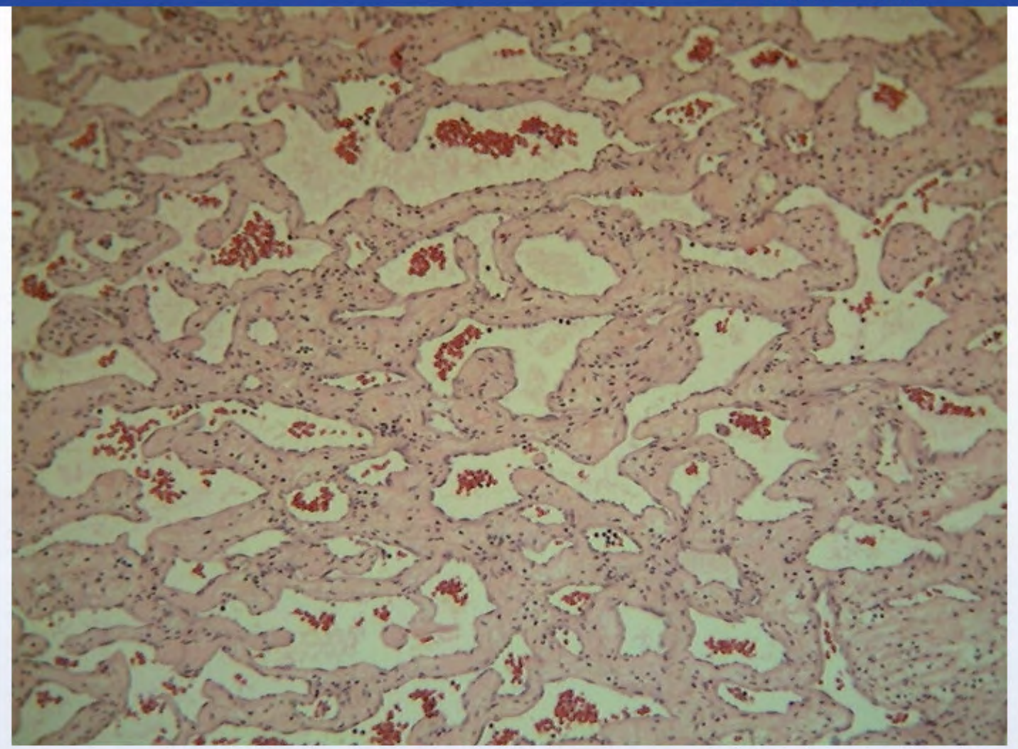

Which of the following is the most accurate statement concerning this patient's condition?

- A. Malignant transformation is a rule (5%)
- ✓ B. It is the most common benign liver tumor (35%)
- ✗ C. It can regress upon oral contraceptive discontinuation (32%)
- D. It is strongly associated with hemochromatosis (16%)
- E. Biopsy is indicated to confirm the diagnosis (10%)

Incorrect
Correct answer
B

35%
Answered correctly

14 secs
Time Spent

2023
Version

https://t.me/USMLEWorldStep1

D. It is strongly associated with hemochromatosis (16%)

Inco
Corre
B

Expl

Exhibit Display

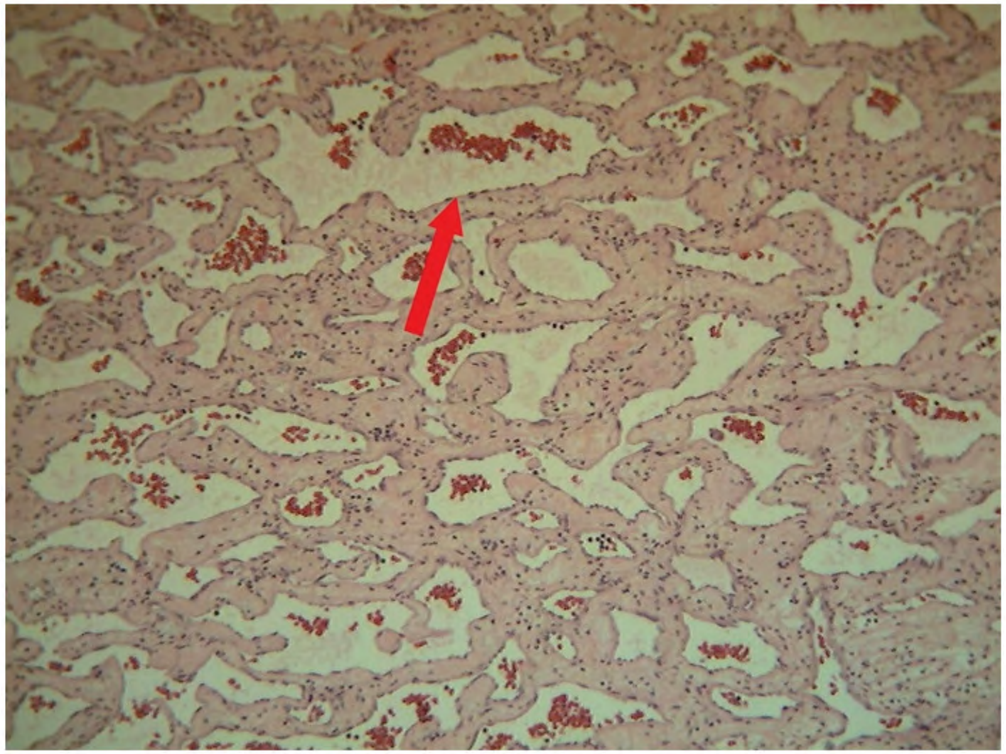

Zoom In | Zoom Out | Reset | New | Existing | My Notebook

Cavernous hemangioma is the most common benign liver tumor, typically presenting in adults 30-50 years of age.

These benign tumors are thought to be congenital malformations that enlarge by ectasia, not hyperplasia or

https://t.me/USMLEWorldStep1

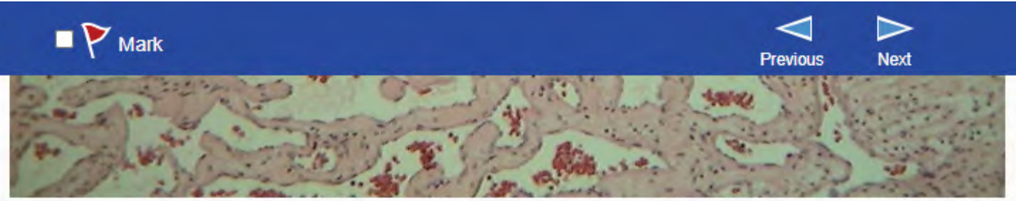

Cavernous hemangioma is the most common benign liver tumor, typically presenting in adults 30-50 years of age. These benign tumors are thought to be congenital malformations that enlarge by ectasia, not hyperplasia or hypertrophy. Hemangiomas may occur singly or in multiples and are well-circumscribed masses of spongy consistency, typically measuring less than 5 cm in width. Microscopically, these tumors consist of cavernous, blood-filled vascular spaces of variable size lined by a single epithelial layer (arrow). Collagenous scars or fibrous nodules may be seen in association with thrombosis. Most patients are asymptomatic, although some will complain of abdominal pain and right upper quadrant fullness. Prognosis is usually excellent, with surgical resection an option for those patients who are symptomatic or who have compression of adjacent structures.

(Choice A) On rare occasion, giant hemangiomas are found to be malignant vascular tumors. The vast majority of hemangiomas are benign lesions, however.

(Choice C) Hepatic adenomas can regress with the discontinuation of oral contraceptives, but hemangiomas are not similarly affected.

(Choice D) Hepatocellular carcinoma (not hemangioma) can be associated with hemochromatosis.

(Choice E) Biopsy of a suspected hemangioma is not advisable, as the procedure has been known to cause fatal hemorrhage and is of low diagnostic yield.

Educational objective:
Cavernous hemangioma is the most common benign liver tumor. Microscopically, these tumors consist of cavernous, blood-filled vascular spaces of variable size lined by a single epithelial layer. The biopsy of a suspected hemangioma is not advisable, as the procedure has been known to cause fatal hemorrhage and is of low diagnostic yield.

Pathology	Gastrointestinal & Nutrition	Hemangioma
Subject	System	Topic

Copyright © UWorld. All rights reserved.

https://t.me/USMLEWorldStep1

Exhibit Display

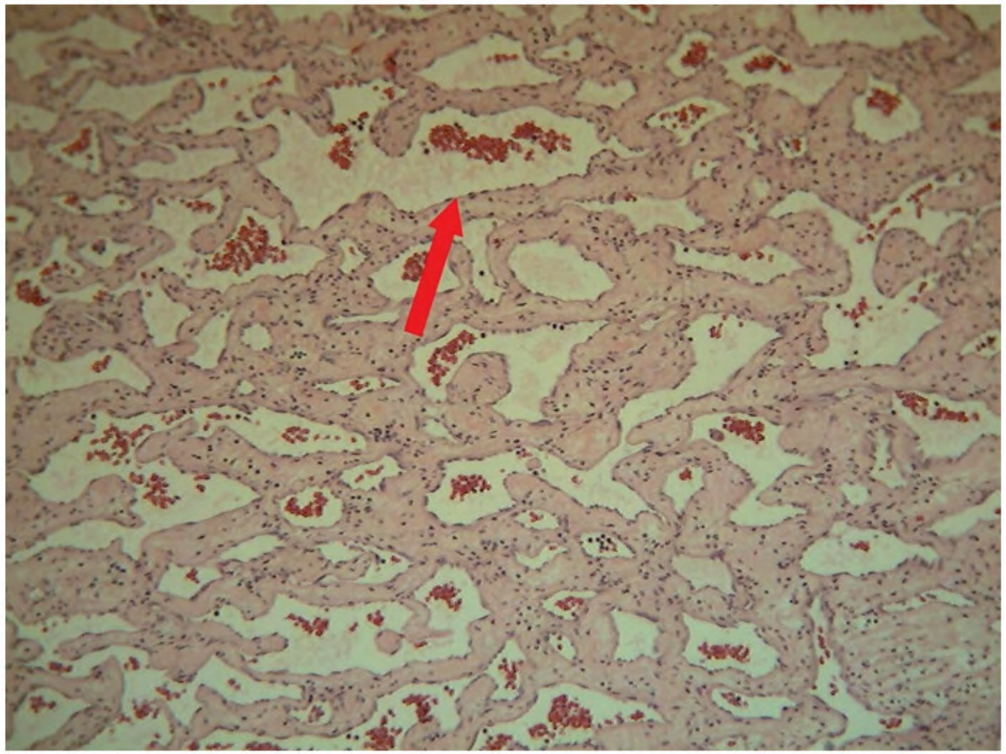

Zoom In | Zoom Out | Reset | New | Existing | My Notebook

Caver
These
hypert
consis
blood-
nodule
compl
resect

(Choi
hemar

(Choice C) Hepatic adenomas can regress with the discontinuation of oral contraceptives, but hemangiomas are

https://t.me/USMLEWorldStep1

Exhibit Display

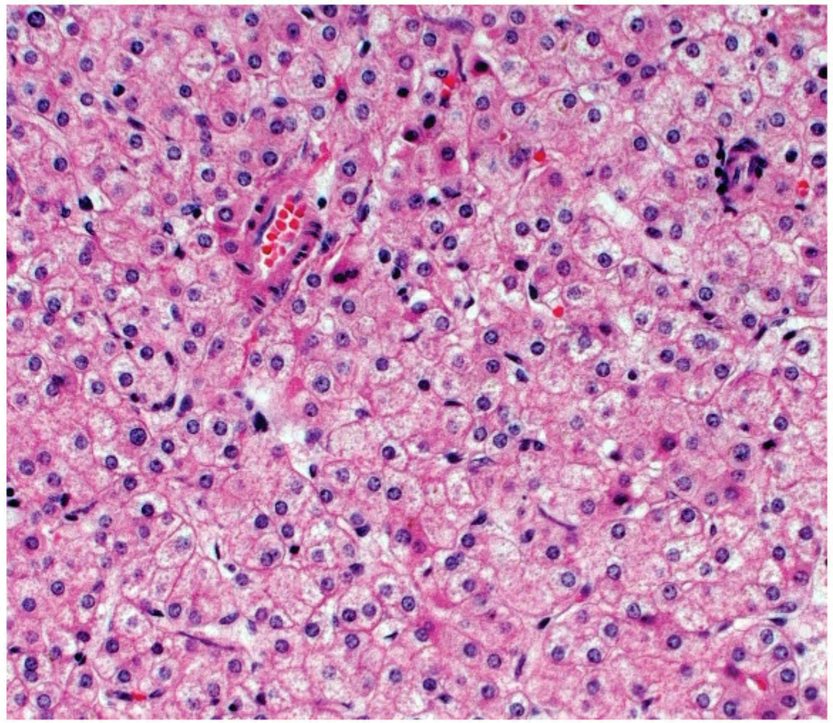

Zoom In | Zoom Out | Reset | New | Existing | My Notebook

Caver
These
hypert
consis
blood-
nodule
compl
resect

(Choi
hemar

(Choi
not sir

(Choi

(Choi
hemor

Educa
Caver
caverr
suspe
low di

Pathol
Subject

Copyright © UWorld. All rights reserved.

https://t.me/USMLEWorldStep1

Exhibit Display

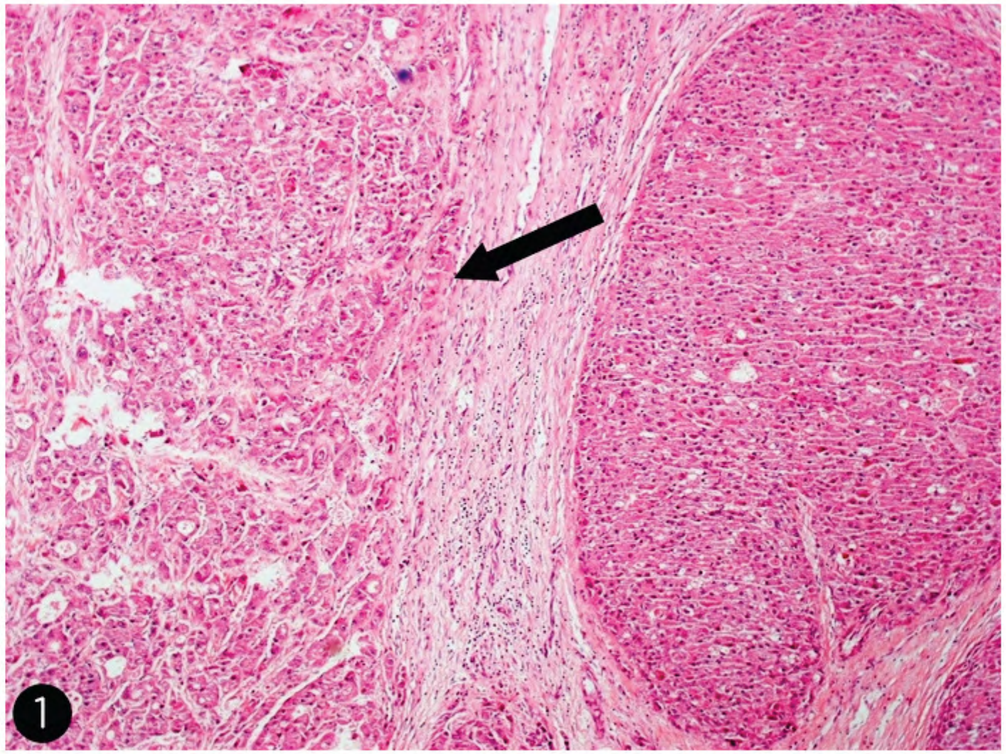

Zoom In | Zoom Out | Reset | New | Existing | My Notebook

Caver
These
hypert
consis
blood-
nodule
compl
resect

(Choi
hemar

(Choi
not sir

(Choi

(Choi
hemor

Educa
Caver
caverr
suspe
low di

Pathol
Subject

Copyright © UWorld. All rights reserved.

https://t.me/USMLEWorldStep1

A 38-year-old woman comes to the hospital with 4 hours of abdominal pain, nausea, and vomiting. The pain started in the periumbilical area and is now localized to the right lower quadrant. Temperature is 38.3 C (100.9 F). On examination, the patient has right lower quadrant tenderness with guarding. An appendectomy is performed, and light microscopy of the appendix shows transmural neutrophilic inflammation, consistent with the diagnosis of acute appendicitis. Further microscopic evaluation reveals abnormal islands of cells, as shown in the image below.

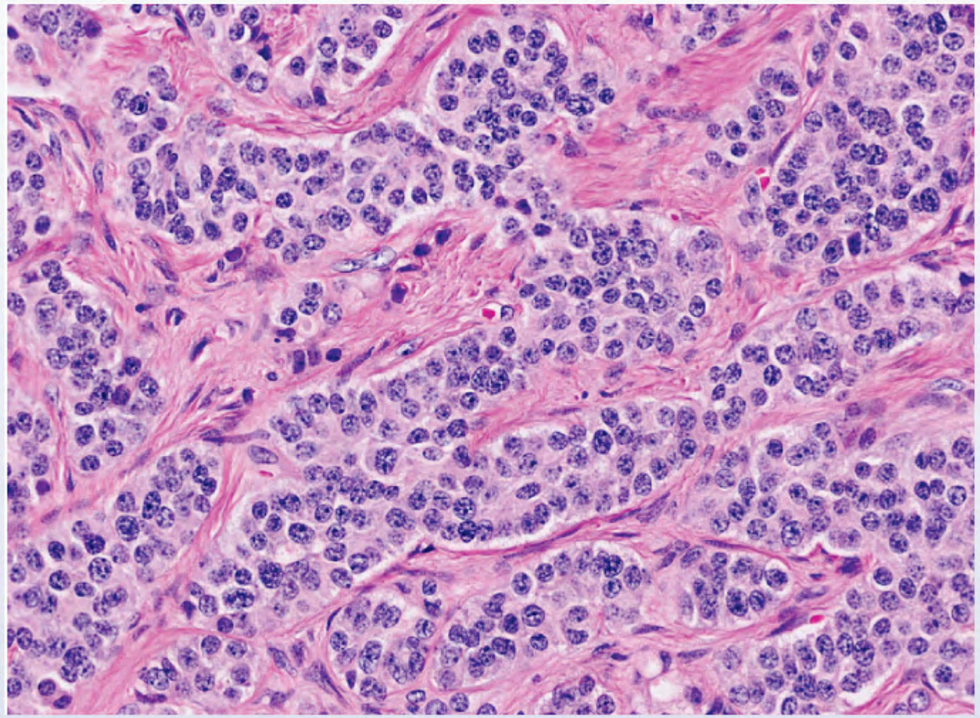

This lesion is most likely derived from which of the following?

- A. Endothelial cells
- B. Fibroblasts
- C. Hematopoietic cells

https://t.me/USMLEWorldStep1

A 38-year-old woman comes to the hospital with 4 hours of abdominal pain, nausea, and vomiting. The pain
started
On ex
and lig
acute

Exhibit Display

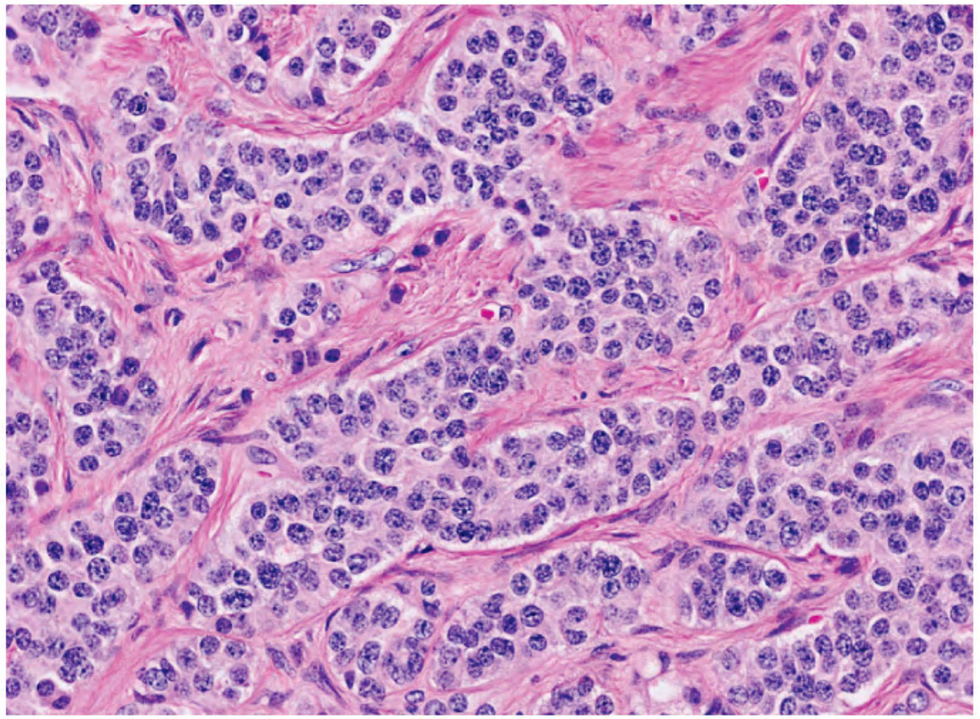

Zoom In Zoom Out Reset New | Existing My Notebook

This le

C. Hematopoietic cells

https://t.me/USMLEWorldStep1

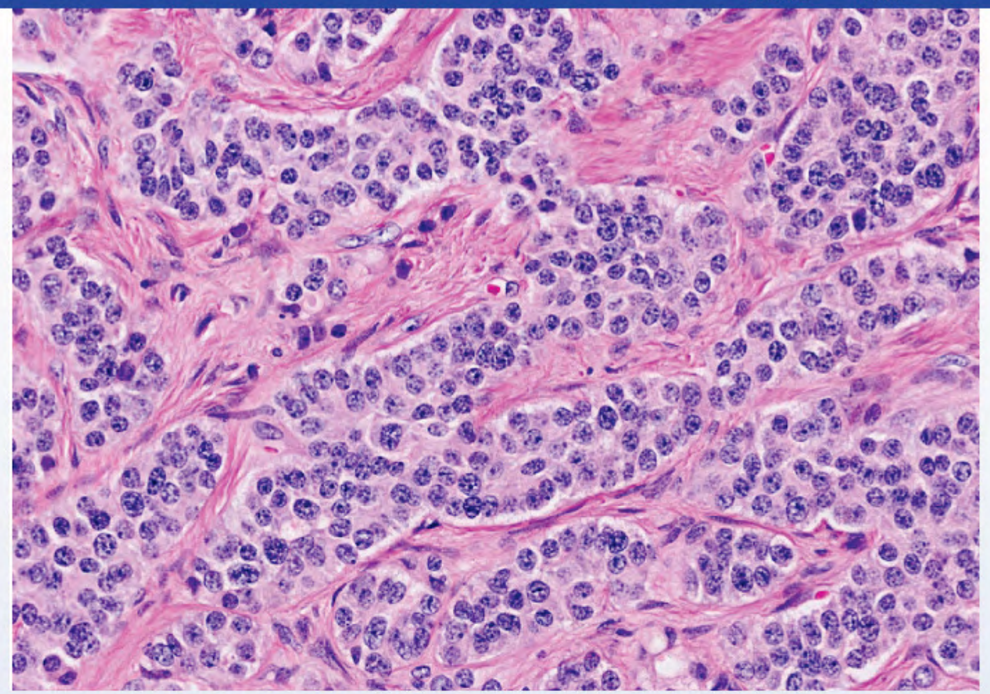

This lesion is most likely derived from which of the following?

- A. Endothelial cells
- B. Fibroblasts
- C. Hematopoietic cells
- D. Intestinal epithelial cells
- E. Neuroendocrine cells
- F. Smooth muscle cells

Submit

https://t.me/USMLEWorldStep1

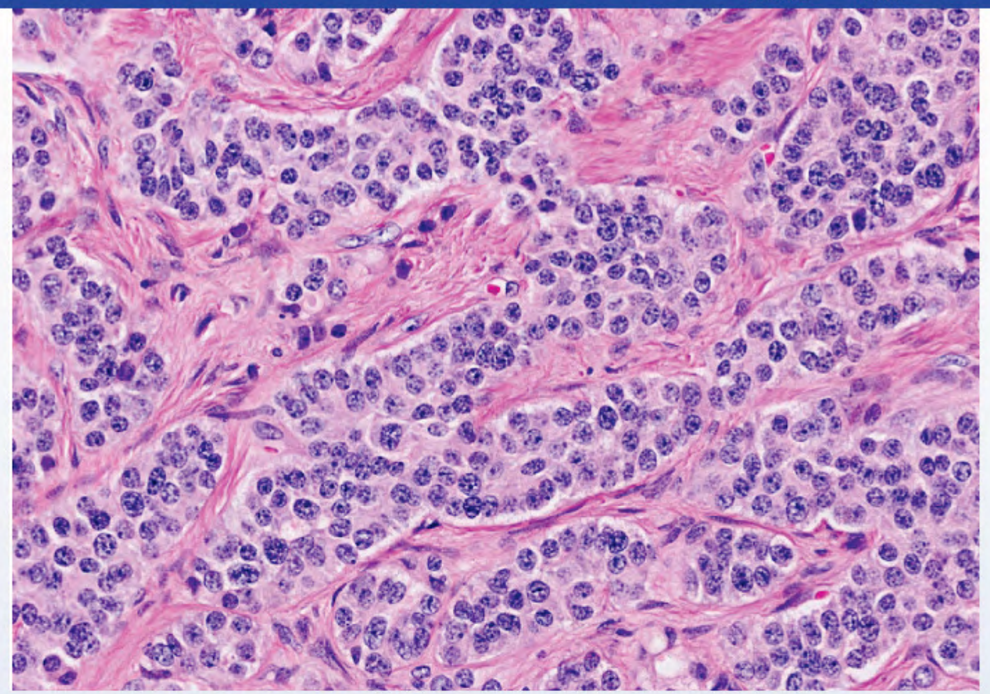

This lesion is most likely derived from which of the following?

- A. Endothelial cells (4%)
- B. Fibroblasts (18%)
- C. Hematopoietic cells (11%)
- D. Intestinal epithelial cells (11%)
- ✓ E. Neuroendocrine cells (47%)
- F. Smooth muscle cells (4%)

Correct

47%
Answered correctly

14 secs
Time Spent

2023
Version

https://t.me/USMLEWorldStep1

Explanation

Histopathology of this patient's appendix shows a well-differentiated neuroendocrine tumor (WDNET) (ie, **carcinoid tumor**). WDNETs are derived from **neuroendocrine cells** and often arise in the gastrointestinal tract (eg, small intestine, rectum, appendix).

Microscopically, WDNETs can show a variety of architectural patterns (eg, islands, nests, trabeculae) and are composed of uniform tumor cells with round nuclei, **salt and pepper chromatin**, and eosinophilic (ie, pink) cytoplasm. The cytoplasm contains dense-core neurosecretory granules seen using electron microscopy, with secretory products such as vasoactive molecules (eg, **serotonin**) and hormones (eg, gastrin).

WDNETs are the most common appendiceal tumors and are usually **incidentally found** at the distal tip of the appendix in patients who have undergone appendectomy for unrelated reasons. However, tumors at the base can obstruct the lumen, causing **appendicitis**. The majority of appendiceal WDNETs follow an **indolent** clinical course, but larger tumors can metastasize. In rare cases, metastasis to the liver can result in carcinoid syndrome (eg, flushing, diarrhea, bronchospasm).

(Choice A) Endothelial cells can give rise to vascular tumors such as angiosarcoma, which typically involves the skin, breast, or liver. Histopathology often shows infiltrative vascular structures lined by atypical (eg, large, hyperchromatic) endothelial cells.

(Choice B) Desmoid tumor (ie, deep fibromatosis) is a benign but locally invasive fibroblastic tumor that can slowly infiltrate the abdominal cavity, causing nausea and intestinal obstruction. However, histopathology shows long fascicles of uniform, spindle-shaped fibroblasts in a collagen-rich stroma.

(Choice C) Abnormal proliferation of hematopoietic cells can lead to a variety of myeloid and lymphoid neoplasms (eg, Burkitt lymphoma). Although it may involve the appendix and cause abdominal pain, the histopathology of Burkitt lymphoma involves sheets of basophilic lymphoid cells with scattered, benign macrophages (ie, "starry sky" appearance).

(Choice D) Intestinal epithelial cells can give rise to adenocarcinoma. Appendiceal adenocarcinoma can present with symptoms of acute appendicitis, but the histopathology often shows infiltrative glands and/or mucin.

https://t.me/USMLEWorldStep1

composed of uniform tumor cells with round nuclei, **salt and pepper chromatin**, and eosinophilic (ie, pink) cytoplasm. The cytoplasm contains dense-core neurosecretory granules seen using electron microscopy, with secretory products such as vasoactive molecules (eg, **serotonin**) and hormones (eg, gastrin).

WDNETs are the most common appendiceal tumors and are usually **incidentally found** at the distal tip of the appendix in patients who have undergone appendectomy for unrelated reasons. However, tumors at the base can obstruct the lumen, causing **appendicitis**. The majority of appendiceal WDNETs follow an **indolent** clinical course, but larger tumors can metastasize. In rare cases, metastasis to the liver can result in carcinoid syndrome (eg, flushing, diarrhea, bronchospasm).

(Choice A) Endothelial cells can give rise to vascular tumors such as angiosarcoma, which typically involves the skin, breast, or liver. Histopathology often shows infiltrative vascular structures lined by atypical (eg, large, hyperchromatic) endothelial cells.

(Choice B) Desmoid tumor (ie, deep fibromatosis) is a benign but locally invasive fibroblastic tumor that can slowly infiltrate the abdominal cavity, causing nausea and intestinal obstruction. However, histopathology shows long fascicles of uniform, spindle-shaped fibroblasts in a collagen-rich stroma.

(Choice C) Abnormal proliferation of hematopoietic cells can lead to a variety of myeloid and lymphoid neoplasms (eg, Burkitt lymphoma). Although it may involve the appendix and cause abdominal pain, the histopathology of Burkitt lymphoma involves sheets of basophilic lymphoid cells with scattered, benign macrophages (ie, "starry sky" appearance).

(Choice D) Intestinal epithelial cells can give rise to adenocarcinoma. Appendiceal adenocarcinoma can present with symptoms of acute appendicitis, but the histopathology often shows infiltrative glands and/or mucin.

(Choice F) Leiomyomas are benign smooth muscle tumors that typically involve the gynecologic tract (eg, uterine mass). Histopathology shows bundles of uniform cells with spindle-shaped nuclei and pink cytoplasm.

Educational objective:
Well-differentiated neuroendocrine tumors (ie, carcinoid tumors) arise from neuroendocrine cells and are composed of uniform tumor cells with round nuclei, salt and pepper chromatin, and eosinophilic cytoplasm. Although most are found incidentally (ie, asymptomatic), some may obstruct the lumen, causing acute appendicitis.

https://t.me/USMLEWorldStep1

Explanation

Exhibit Display

Well-differentiated neuroendocrine (carcinoid) tumor

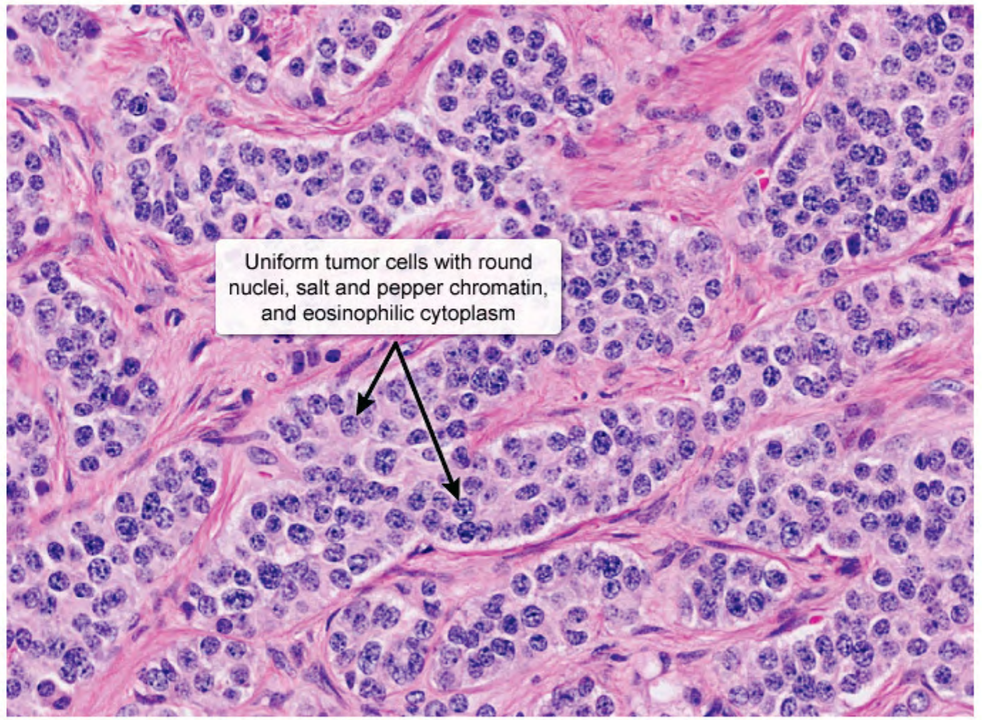

©UWorld

Zoom In | Zoom Out | Reset | New | Existing | My Notebook

Histop
carcin
(eg, sr

Micros
compo
cytopl
secret

WDNE
appen
obstru
course
(eg, flu

(Choi
skin, b
hyperc

(Choi
slowly
long fa

(Choi
(eg, Bu
Burkitt
appea

(Choi
with symptoms of acute appendicitis, but the histopathology often shows infiltrative glands and/or mucin.

https://t.me/USMLEWorldStep1

Explanation

Exhibit Display

Hepatic angiosarcoma

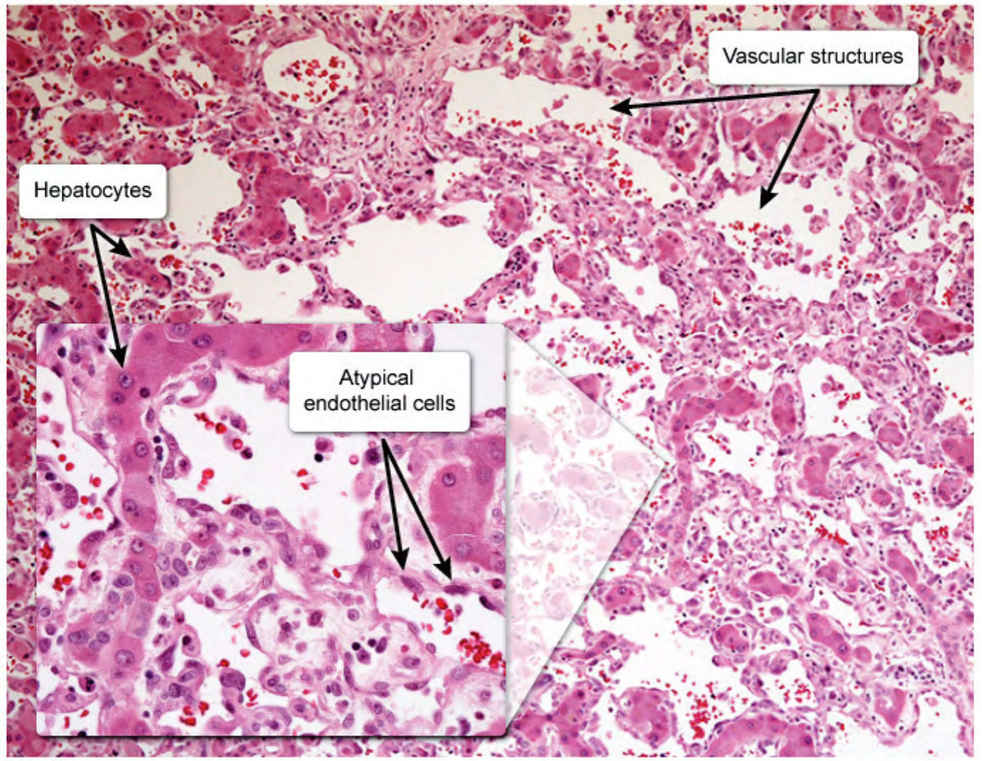

©UWorld

Zoom In Zoom Out Reset New | Existing My Notebook

Histop
carcin
(eg, sr

Micros
compo
cytopl
secret

WDNE
appen
obstru
course
(eg, flu

(Choi
skin, b
hyperc

(Choi
slowly
long fa

(Choi
(eg, Bu
Burkitt
appea

(Choi
with symptoms of acute appendicitis, but the histopathology often shows infiltrative glands and/or mucin.

https://t.me/USMLEWorldStep1

Explanation

Exhibit Display

Deep fibromatosis (desmoid tumor)

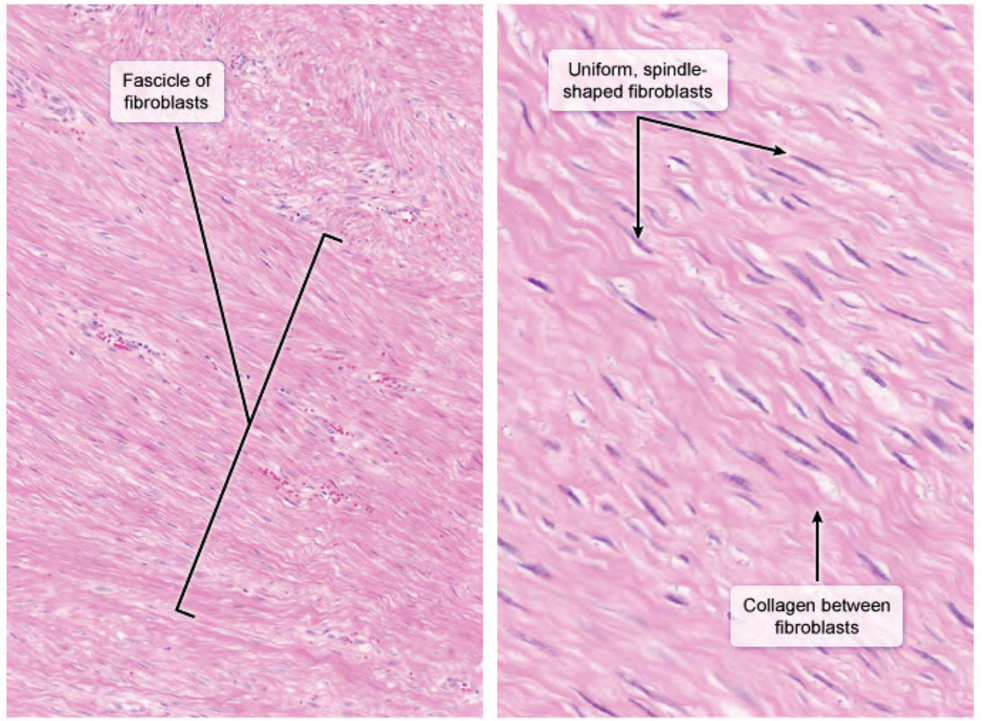

©UWorld

Zoom In | Zoom Out | Reset | New | Existing | My Notebook

Histop
carcin
(eg, sr
Micros
compo
cytopl
secret
WDNE
appen
obstru
course
(eg, flu
(Choi
skin, b
hyperc
(Choi
slowly
long fa
(Choi
(eg, Bu
Burkitt
appea
(Choi
with symptoms of acute appendicitis, but the histopathology often shows infiltrative glands and/or mucin.

https://t.me/USMLEWorldStep1

Explanation

Exhibit Display

Burkitt lymphoma

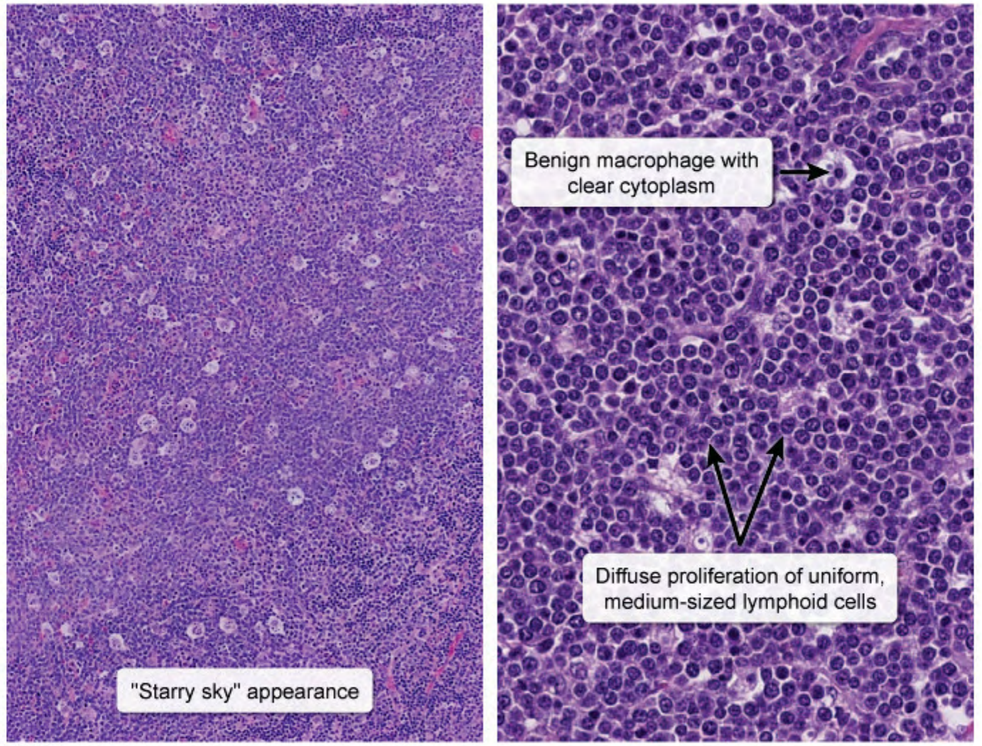

©UWorld

Zoom In | Zoom Out | Reset | New | Existing | My Notebook

Histop
carcin
(eg, sr
Micros
compo
cytopl
secret
WDNE
appen
obstru
course
(eg, flu
(Choi
skin, b
hyperc
(Choi
slowly
long fa
(Choi
(eg, Bu
Burkitt
appea
(Choi
with symptoms of acute appendicitis, but the histopathology often shows infiltrative glands and/or mucin.

https://t.me/USMLEWorldStep1

Explanation

Exhibit Display

Mucinous adenocarcinoma of the appendix

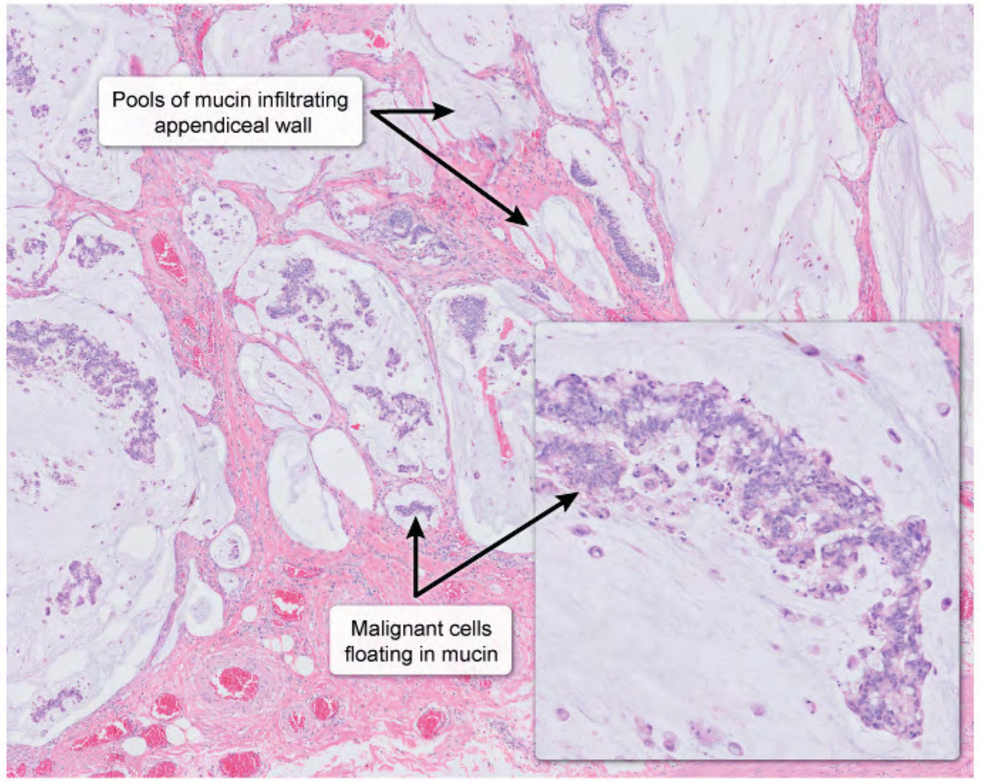

©UWorld

Zoom In | Zoom Out | Reset | New | Existing | My Notebook

Histop
carcin
(eg, sr

Micros
compo
cytopl
secret

WDNE
appen
obstru
course
(eg, flu

(Choi
skin, b
hyperc

(Choi
slowly
long fa

(Choi
(eg, Bu
Burkitt
appea

(Choi
with symptoms of acute appendicitis, but the histopathology often shows infiltrative glands and/or mucin.

https://t.me/USMLEWorldStep1

carcinoid tumor). WDNETs are derived from **neuroendocrine cells** and often arise in the gastrointestinal tract (eg, small intestine, rectum, appendix).

Micros
compo
cytopl
secret

WDNE
appen
obstru
course
(eg, flu

(Choi
skin, b
hyperc

(Choi
slowly
long fa

(Choi
(eg, B
Burkitt
appea

(Choi
with sy

(Choi
mass)

Educational objective:

Exhibit Display

Mucinous adenocarcinoma of the appendix

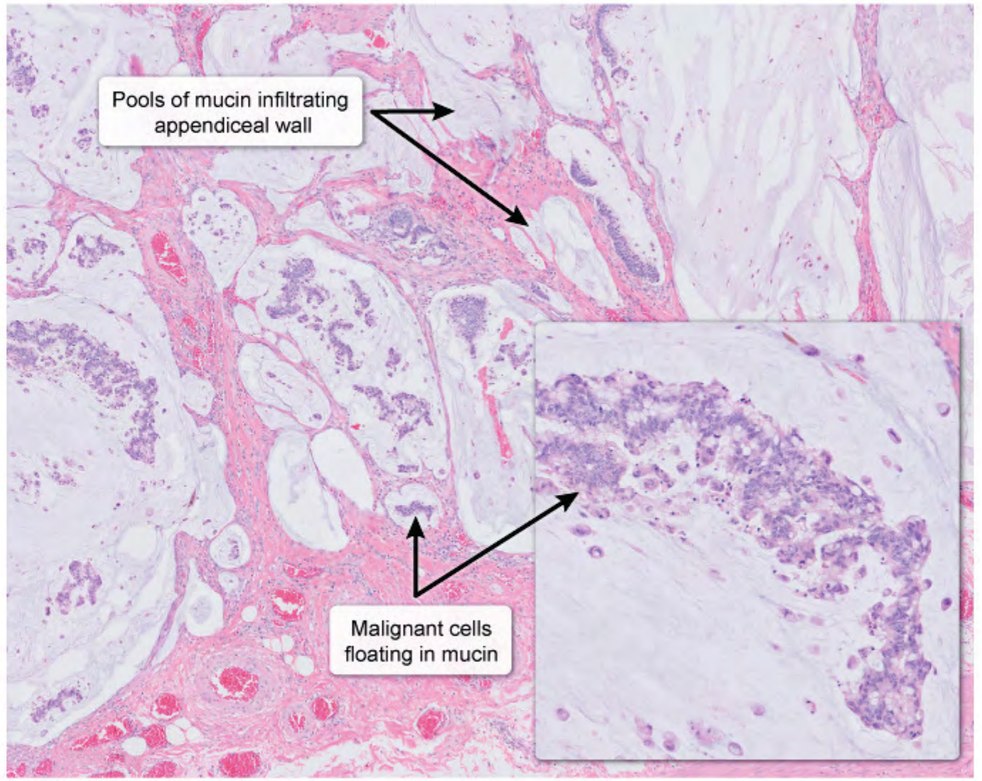

©UWorld

Zoom In Zoom Out Reset New | Existing My Notebook

https://t.me/USMLEWorldStep1

carcinoid tumor). WDNETs are derived from **neuroendocrine cells** and often arise in the gastrointestinal tract (eg, small intestine, rectum, appendix).

Micros
compo
cytopl
secret

WDNE
appen
obstru
course
(eg, flu

(Choi
skin, b
hyperc

(Choi
slowly
long fa

(Choi
(eg, B
Burkitt
appea

(Choi
with sy

(Choi
mass)

Educational objective:

Exhibit Display

Leiomyoma

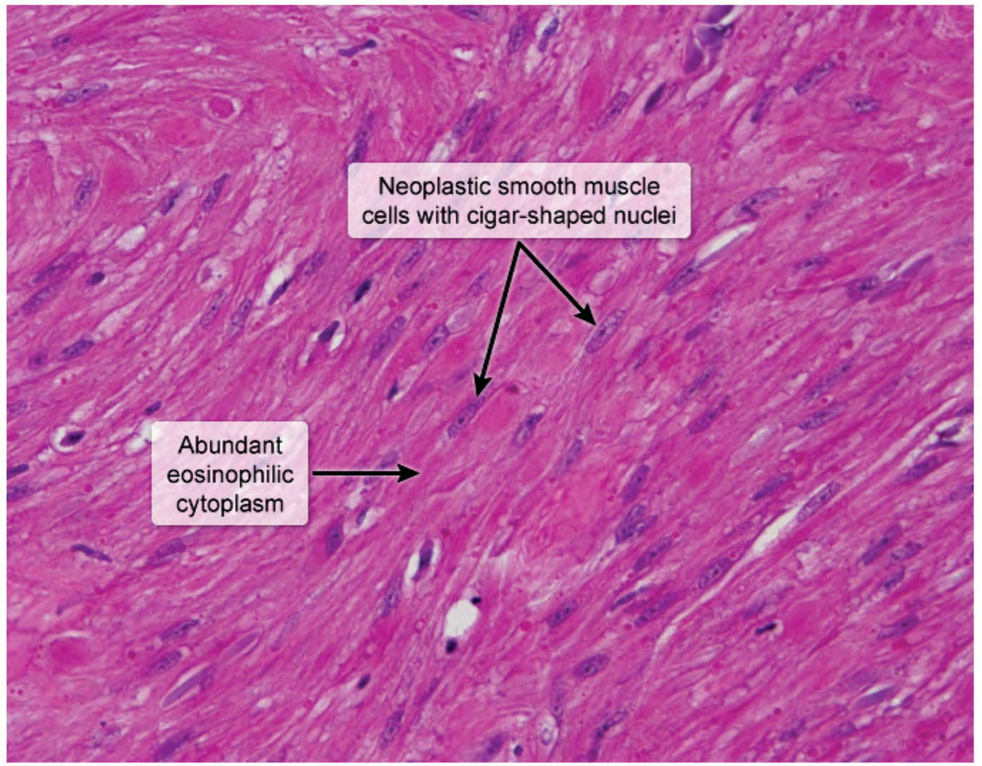

©UWorld

Zoom In | Zoom Out | Reset | New | Existing | My Notebook

https://t.me/USMLEWorldStep1

A 35-year-old man comes to the emergency department due to persistent abdominal pain. Yesterday, during a soccer game, he collided with another player while running at full speed. The patient had abdominal pain at the time but did not seek care until this morning when the pain seemed to worsen. It is suspected that he has an injury involving an organ that is supplied by an artery of the foregut although the organ itself is not a foregut derivative. Which of the following organs is most likely to be injured in this patient?

- A. A
- B. B
- C. C
- D. D
- E. E

Submit

https://t.me/USMLEWorldStep1

A 35-year-old man comes to the emergency department due to persistent abdominal pain. Yesterday, during a
socce
time b
involvi
Which

Exhibit Display

Zoom In | Zoom Out | Reset | New | Existing | My Notebook

D. D

https://t.me/USMLEWorldStep1

involving an organ that is supplied by an artery of the foregut although the organ itself is not a foregut derivative.
Which of the following organs is most likely to be injured in this patient?

- A. A (12%)
- B. B (6%)
- ✗ C. C (6%)
- D. D (13%)
- ✓ E. E (62%)

Incorrect
Correct answer
E

62%
Answered correctly

08 secs
Time Spent

2023
Version

https://t.me/USMLEWorldStep1

D. D (13%)

Exhibit Display

Normal abdominal CT scan

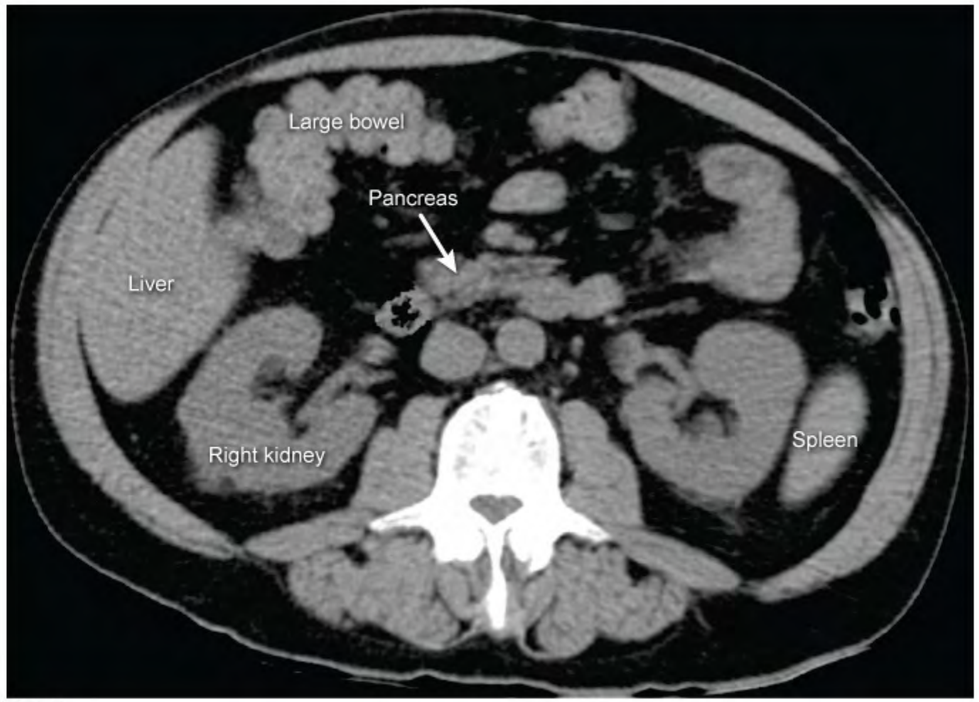

©UWorld

Zoom In | Zoom Out | Reset | New | Existing | My Notebook

Organ damage from **blunt abdominal trauma** (eg, collision while running at full speed) most commonly involves

https://t.me/USMLEWorldStep1

involving an organ that is supplied by an artery of the foregut although the organ itself is not a foregut derivative.
Which of the following organs is most likely to be injured in this patient?

- A. A (12%)
- B. B (6%)
- ✗ C. C (6%)
- D. D (13%)
- ✓ E. E (62%)

Incorrect
Correct answer
E

62%
Answered correctly

08 secs
Time Spent

2023
Version

https://t.me/USMLEWorldStep1

©UWorld

Organ damage from **blunt abdominal trauma** (eg, collision while running at full speed) most commonly involves the **spleen and liver** and less commonly the kidneys. In this case, the affected organ is the spleen.

The spleen is an intraperitoneal **organ derived** from the **mesoderm** of the dorsal mesentery. However, the spleen is unique in that its **blood supply** originates from a **foregut derivative** (the splenic artery from the celiac trunk). Venous return from the spleen courses through the splenic vein to the portal circulation rather than to the systemic circulation.

By convention, CT scans are presented such that the patient's left is on the reader's right (imagine that the patient is supine with the feet directed toward the viewer). This patient's cross-sectional image represents a relatively caudal (lower) abdominal view that includes the kidneys; therefore, only the tail of the spleen is visible.

(Choices A and D) The liver and pancreas are endoderm-derived structures of the foregut and both receive arterial blood supply from branches of the celiac trunk: the proper hepatic artery supplies the liver and the superior and inferior pancreaticoduodenal arteries supply the pancreas.

(Choice B) Like the spleen, the kidneys are derived from the mesoderm. However, the kidneys are retroperitoneal and supplied by the renal arteries (from the abdominal aorta), which do not perfuse the foregut.

(Choice C) The first two-thirds of the transverse colon is derived from the midgut and supplied by the superior mesenteric artery. The last one-third of the transverse colon arises from the hindgut and is supplied by branches of the inferior mesenteric artery.

Educational objective:
The spleen is of mesodermal origin (dorsal mesentery), but its blood supply (splenic artery) is derived from the major foregut vessel, the celiac trunk.

References

- Embryonic origins of spleen asymmetry.

Embryology	Gastrointestinal & Nutrition	Spleen rupture
Subject	System	Topic

https://t.me/USMLEWorldStep1

©UWorld

Organ
the **sp**

The sp
is uniq
Venou
circula

By cor
is supi
cauda

(Choi
arteria
and in

(Choi
retrope

(Choi
meser
the inf

Educa
The sp
major

Refere
- Em

Embryol
Subject
System
Topic

Exhibit Display

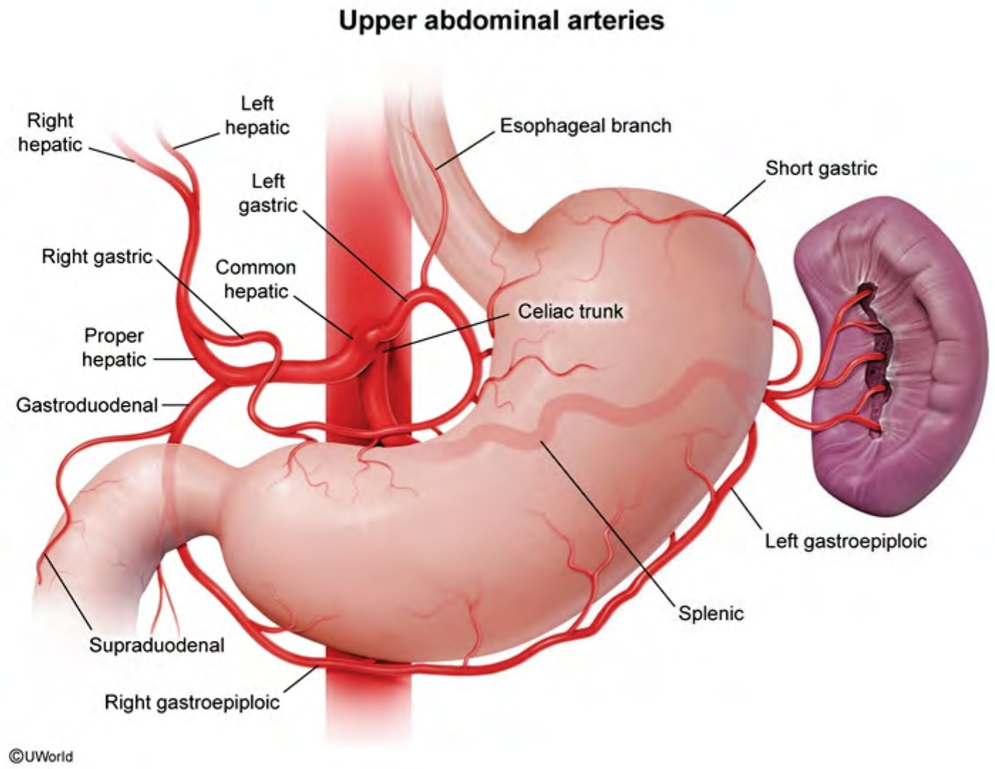

Zoom In | Zoom Out | Reset | New | Existing | My Notebook

https://t.me/USMLEWorldStep1

©UWorld

Organ
the **sp**

The sp
is uniq
Venou
circula

By cor
is supi
cauda

(Choi
arteria
and in

(Choi
retrope

(Choi
meser
the inf

Educa
The sp
major

Refere
- Em

Exhibit Display

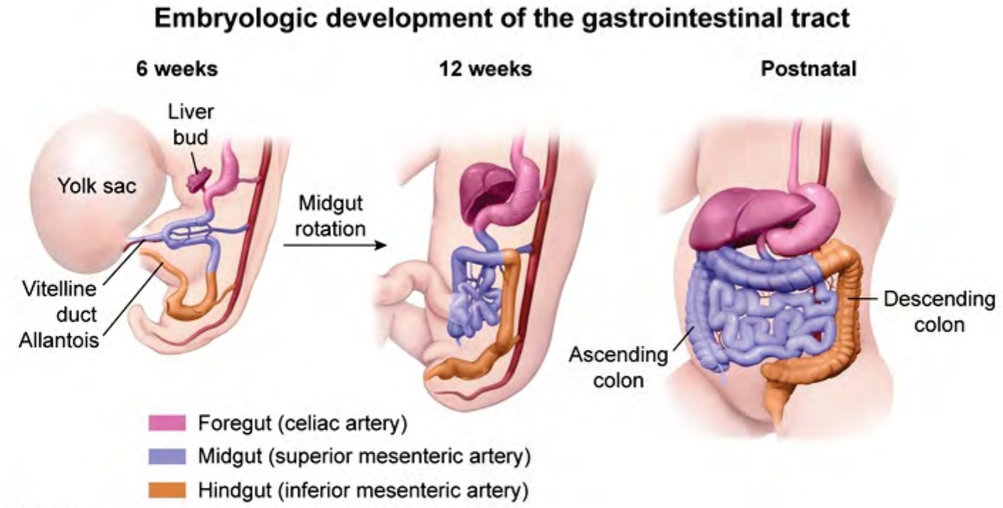

Zoom In | Zoom Out | Reset | New | Existing | My Notebook

Embryology
Subject

Gastrointestinal & Nutrition
System

Spleen rupture
Topic

https://t.me/USMLEWorldStep1

Organ damage from **blunt abdominal trauma** (eg, collision while running at full speed) most commonly involves the **sp**

The sp
is uniq
Venou
circula

By cor
is supi
cauda

(Choi
arteria
and in

(Choi
retrope

(Choi
meser
the inf

Educa
The sp
major

Refere
- Em

Exhibit Display

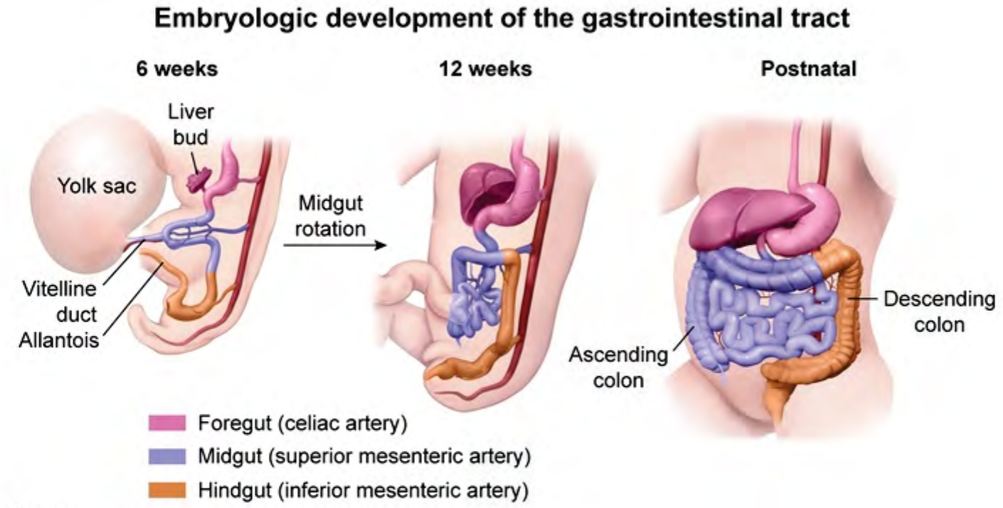

Zoom In | Zoom Out | Reset | New | Existing | My Notebook

Embryology
Subject

Gastrointestinal & Nutrition
System

Spleen rupture
Topic

Copyright © UWorld. All rights reserved.

https://t.me/USMLEWorldStep1

A 54-year-old man comes to the office due to increasing pain in the right upper quadrant, nausea, and unintentional weight loss. Vitals signs are within normal limits. BMI is 21 kg/m^2. The patient appears cachectic and there is scleral icterus. The liver is palpable 3 cm below the right costal margin. No ascites is present. Laboratory studies reveal elevated bilirubin and alkaline phosphatase. Contrast CT scan of the abdomen demonstrates moderately dilated right and left intrahepatic bile ducts, with a vague area of delayed enhancement at their convergence. Biopsy of the lesion reveals columnar cells with hyperchromatic oval nuclei with prominent nucleoli arranged in glandular structures; mucin production with surrounding desmoplastic reaction is present. Which of the following is the most likely diagnosis?

- A. Cholangiocarcinoma
- B. Focal nodular hyperplasia
- C. Hepatic adenoma
- D. Hepatocellular carcinoma
- E. Metastatic colon cancer

Submit

https://t.me/USMLEWorldStep1

A 54-year-old man comes to the office due to increasing pain in the right upper quadrant, nausea, and unintentional weight loss. Vitals signs are within normal limits. BMI is 21 kg/m^2. The patient appears cachectic and there is scleral icterus. The liver is palpable 3 cm below the right costal margin. No ascites is present. Laboratory studies reveal elevated bilirubin and alkaline phosphatase. Contrast CT scan of the abdomen demonstrates moderately dilated right and left intrahepatic bile ducts, with a vague area of delayed enhancement at their convergence. Biopsy of the lesion reveals columnar cells with hyperchromatic oval nuclei with prominent nucleoli arranged in glandular structures; mucin production with surrounding desmoplastic reaction is present. Which of the following is the most likely diagnosis?

- ✓ A. Cholangiocarcinoma (59%)
- B. Focal nodular hyperplasia (2%)
- ✗ C. Hepatic adenoma (7%)
- D. Hepatocellular carcinoma (8%)
- E. Metastatic colon cancer (21%)

Incorrect
Correct answer
A

59%
Answered correctly

06 secs
Time Spent

2023
Version

Explanation

Cholangiocarcinoma	
Epidemiology	• Associated with primary sclerosing cholangitis
Clinical presentation	• Often clinically silent until advanced • Nausea, weight loss, RUQ pain • Jaundice, hepatomegaly, ± palpable gallbladder (Courvoisier sign)

https://t.me/USMLEWorldStep1

Explanation

Cholangiocarcinoma	
Epidemiology	• Associated with primary sclerosing cholangitis
Clinical presentation	• Often clinically silent until advanced • Nausea, weight loss, RUQ pain • Jaundice, hepatomegaly, ± palpable gallbladder (Courvoisier sign)
Laboratory abnormalities	• Cholestatic pattern of liver injury (↑↑ alkaline phosphatase, hyperbilirubinemia)
Imaging	• Bile duct dilation in the absence of obstructing gallstone
Histology	• Adenocarcinoma with cuboidal or columnar cells with prominent nucleoli arranged in glandular structures • + Mucin production, + desmoplasmic response
RUQ = right upper quadrant.	

This patient with weight loss, pain in the right upper quadrant (RUQ), and jaundice has radiographic and histologic findings consistent with **cholangiocarcinoma**, a malignancy of the bile duct epithelium. It is associated with primary sclerosing cholangitis; however, it may occur sporadically.

Cholangiocarcinoma is often clinically silent until late in the disease course, when the tumor obstructs bile drainage, leading to a characteristic **cholestatic pattern** of liver injury (elevated alkaline phosphatase, hyperbilirubinemia). Progressive weight loss, **RUQ pain**, **jaundice**, and **hepatomegaly** are typical, and occasionally, the gallbladder is palpable (Courvoisier sign).

Intraductal malignancies are often difficult to visualize radiographically but usually demonstrates **dilated bile ducts** in the absence of an obstructing gallstone. The most frequently involved site is at the **confluence of the right and left hepatic bile ducts** (Klatskin tumors), which may be visible as nonunion of the bile ducts (as in this patient).
Most cholangiocarcinomas are **adenocarcinomas** characterized histologically by columnar epithelial cells with

https://t.me/USMLEWorldStep1

This patient with weight loss, pain in the right upper quadrant (RUQ), and jaundice has radiographic and histologic findings consistent with **cholangiocarcinoma**, a malignancy of the bile duct epithelium. It is associated with primary sclerosing cholangitis; however, it may occur sporadically.

Cholangiocarcinoma is often clinically silent until late in the disease course, when the tumor obstructs bile drainage, leading to a characteristic **cholestatic pattern** of liver injury (elevated alkaline phosphatase, hyperbilirubinemia). Progressive weight loss, **RUQ pain**, **jaundice**, and **hepatomegaly** are typical, and occasionally, the gallbladder is palpable (Courvoisier sign).

Intraductal malignancies are often difficult to visualize radiographically but usually demonstrates **dilated bile ducts** in the absence of an obstructing gallstone. The most frequently involved site is at the **confluence of the right and left hepatic bile ducts** (Klatskin tumors), which may be visible as nonunion of the bile ducts (as in this patient). Most cholangiocarcinomas are **adenocarcinomas** characterized histologically by columnar epithelial cells with prominent nucleoli arranged in **glandular structures** with **mucin** production and significant desmoplasia (reactive fibrous tissue surrounding a malignant mass).

(Choice B) Focal nodular hyperplasia is a *benign*, nonencapsulated liver tumor that typically occurs in women. It is characterized by fibrous septa encasing normal hepatocytes and a central stellate scar, which is visible both histologically and radiographically.

(Choice C) Hepatic adenomas are *benign* lesions that develop most commonly in women taking oral contraceptives. Jaundice and weight loss are unexpected, and an abdominal CT scan usually demonstrates a solitary lesion in the hepatic parenchyma, not the biliary tree. Histology reveals relatively uniform hepatocytes arranged in thin cell plates without atypia.

(Choice D) Hepatocellular carcinoma is a malignant liver mass that most often develops in patients with cirrhosis. Microscopy demonstrates polygonal cells with abundant eosinophilic cytoplasm and prominent nucleoli.

(Choice E) Metastatic colon cancer is characterized by adenocarcinoma with gland formation; however, it usually causes multiple hepatic masses, which are not seen on this patient's CT scan. In addition, the location of the mass at the bifurcation of the common hepatic duct is characteristic of cholangiocarcinoma.

Educational objective:

https://t.me/USMLEWorldStep1

occasionally, the gallbladder is palpable (Courvoisier sign).

Intraductal malignancies are often difficult to visualize radiographically but usually demonstrates **dilated bile ducts** in the absence of an obstructing gallstone. The most frequently involved site is at the **confluence of the right and left hepatic bile ducts** (Klatskin tumors), which may be visible as nonunion of the bile ducts (as in this patient). Most cholangiocarcinomas are **adenocarcinomas** characterized histologically by columnar epithelial cells with prominent nucleoli arranged in **glandular structures** with **mucin** production and significant desmoplasia (reactive fibrous tissue surrounding a malignant mass).

(Choice B) Focal nodular hyperplasia is a *benign*, nonencapsulated liver tumor that typically occurs in women. It is characterized by fibrous septa encasing normal hepatocytes and a central stellate scar, which is visible both histologically and radiographically.

(Choice C) Hepatic adenomas are *benign* lesions that develop most commonly in women taking oral contraceptives. Jaundice and weight loss are unexpected, and an abdominal CT scan usually demonstrates a solitary lesion in the hepatic parenchyma, not the biliary tree. Histology reveals relatively uniform hepatocytes arranged in thin cell plates without atypia.

(Choice D) Hepatocellular carcinoma is a malignant liver mass that most often develops in patients with cirrhosis. Microscopy demonstrates polygonal cells with abundant eosinophilic cytoplasm and prominent nucleoli.

(Choice E) Metastatic colon cancer is characterized by adenocarcinoma with gland formation; however, it usually causes multiple hepatic masses, which are not seen on this patient's CT scan. In addition, the location of the mass at the bifurcation of the common hepatic duct is characteristic of cholangiocarcinoma.

Educational objective:
Cholangiocarcinoma is a malignancy of the bile duct epithelium that eventually obstructs biliary drainage, resulting in cholestasis (elevated alkaline phosphatase, hyperbilirubinemia) with jaundice, weight loss, pain in the right upper quadrant, and hepatomegaly. Imaging often demonstrates dilated bile ducts in the absence of an obstructive gallstone, and biopsy reveals an adenocarcinoma with columnar cells, mucin production, and a significant desmoplastic reaction.

References

https://t.me/USMLEWorldStep1

This patient with weight loss, pain in the right upper quadrant (RUQ), and jaundice has radiographic and histologic findin
primar

Cholar
draina
hyperb
occasi

Intradu
in the
left he
Most c
promir
fibrous

(Choi
is char
histolo

(Choi
contra
solitary
arrang

(Choi
Micros

(Choi
cause
at the bifurcation of the common hepatic duct is characteristic of cholangiocarcinoma.

Educational objective:

Exhibit Display

Cholangiocarcinoma

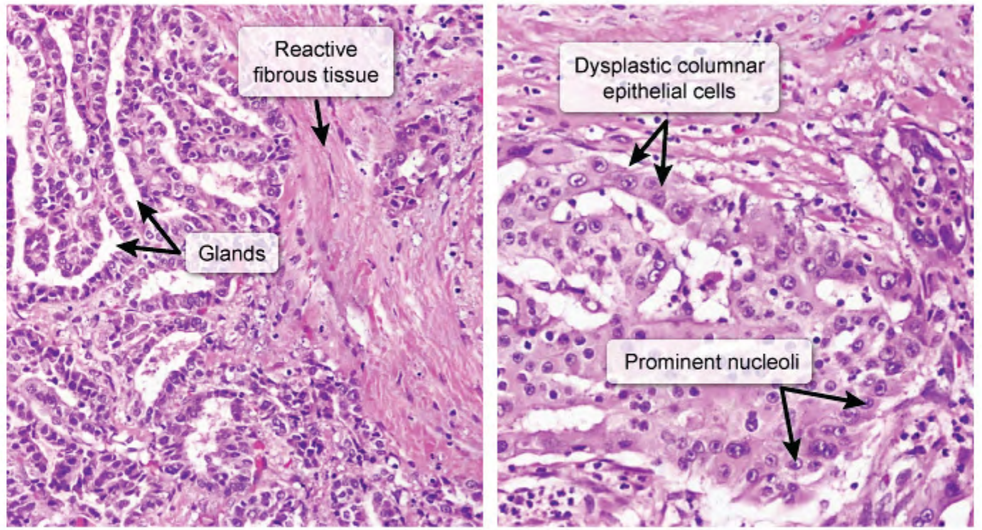

©UWorld

Zoom In | Zoom Out | Reset | New | Existing | My Notebook

https://t.me/USMLEWorldStep1

This patient with weight loss, pain in the right upper quadrant (RUQ), and jaundice has radiographic and histologic findin
primar

Cholar
draina
hyperb
occasi

Intradu
in the
left he
Most c
promir
fibrous

(Choi
is char
histolo

(Choi
contra
solitary
arrang

(Choi
Micros

(Choi
cause
at the bifurcation of the common hepatic duct is characteristic of cholangiocarcinoma.

Educational objective:

Exhibit Display

Focal nodular hyperplasia

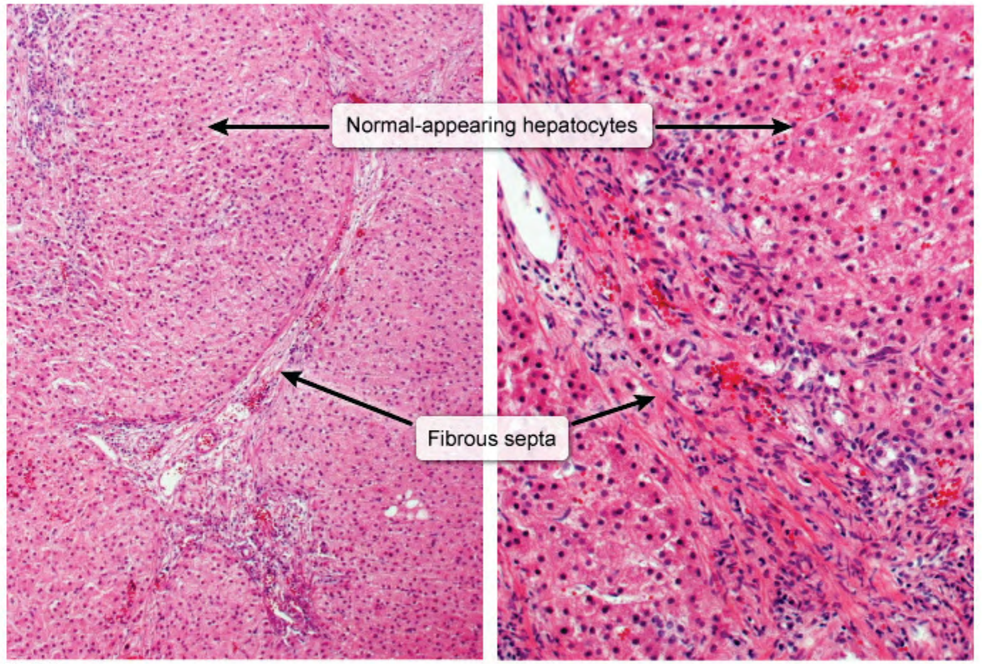

©UWorld

Zoom In | Zoom Out | Reset | New | Existing | My Notebook

https://t.me/USMLEWorldStep1

This patient with weight loss, pain in the right upper quadrant (RUQ), and jaundice has radiographic and histologic findin
primar

Cholar
draina
hyperb
occasi

Intradu
in the
left he
Most c
promir
fibrous

(Choi
is char
histolo

(Choi
contra
solitary
arrang

(Choi
Micros

(Choi
cause
at the bifurcation of the common hepatic duct is characteristic of cholangiocarcinoma.

Educational objective:

Exhibit Display

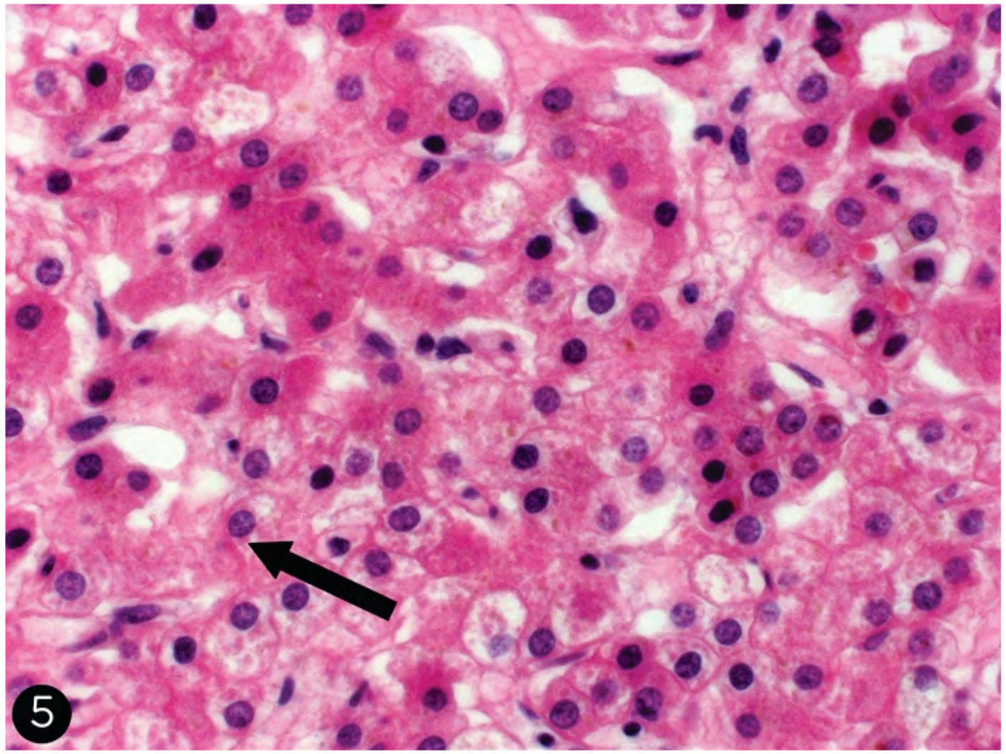

Zoom In
Zoom Out
Reset
New
Existing
My Notebook

https://t.me/USMLEWorldStep1

This patient with weight loss, pain in the right upper quadrant (RUQ), and jaundice has radiographic and histologic findin
primar

Cholar
draina
hyperb
occasi

Intradu
in the
left he
Most c
promir
fibrous

(Choi
is char
histolo

(Choi
contra
solitary
arrang

(Choi
Micros

(Choi
cause
at the bifurcation of the common hepatic duct is characteristic of cholangiocarcinoma.

Educational objective:

Exhibit Display

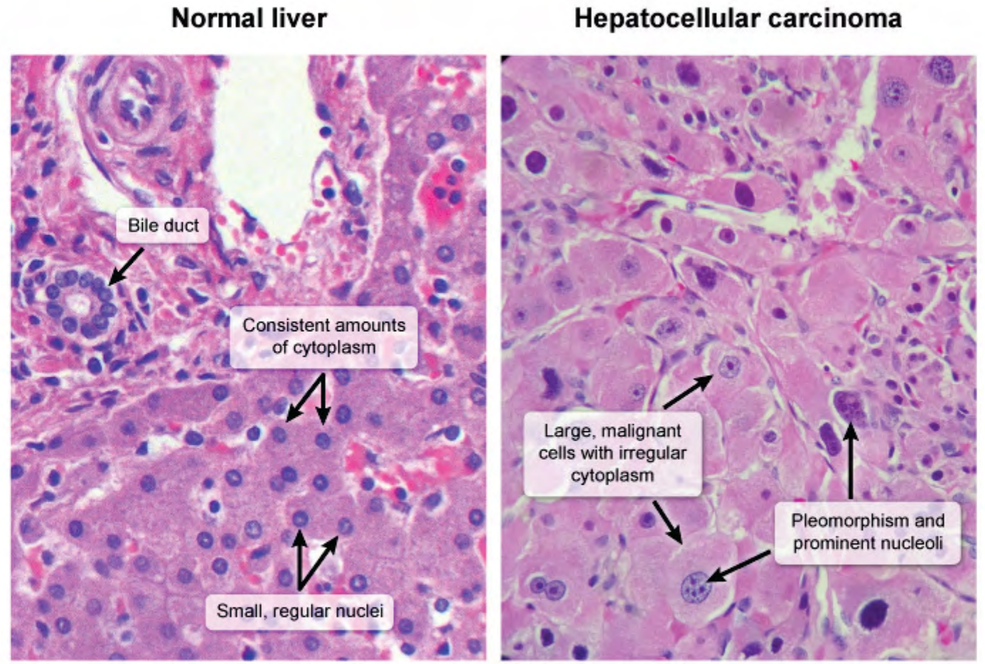

Zoom In | Zoom Out | Reset | New | Existing | My Notebook

https://t.me/USMLEWorldStep1

Cholangiocarcinoma is often clinically silent until late in the disease course, when the tumor obstructs bile
draina
hyperb
occasi

Intradu
in the
left he
Most
promir
fibrous

(Choi
is char
histolo

(Choi
contra
solitary
arrang

(Choi
Micros

(Choi
causes
at the

Educa
Cholar
in cholestasis (elevated alkaline phosphatase, hyperbilirubinemia) with jaundice, weight loss, pain in the right upper
quadrant, and hepatomegaly. Imaging often demonstrates dilated bile ducts in the absence of an obstructive

Exhibit Display

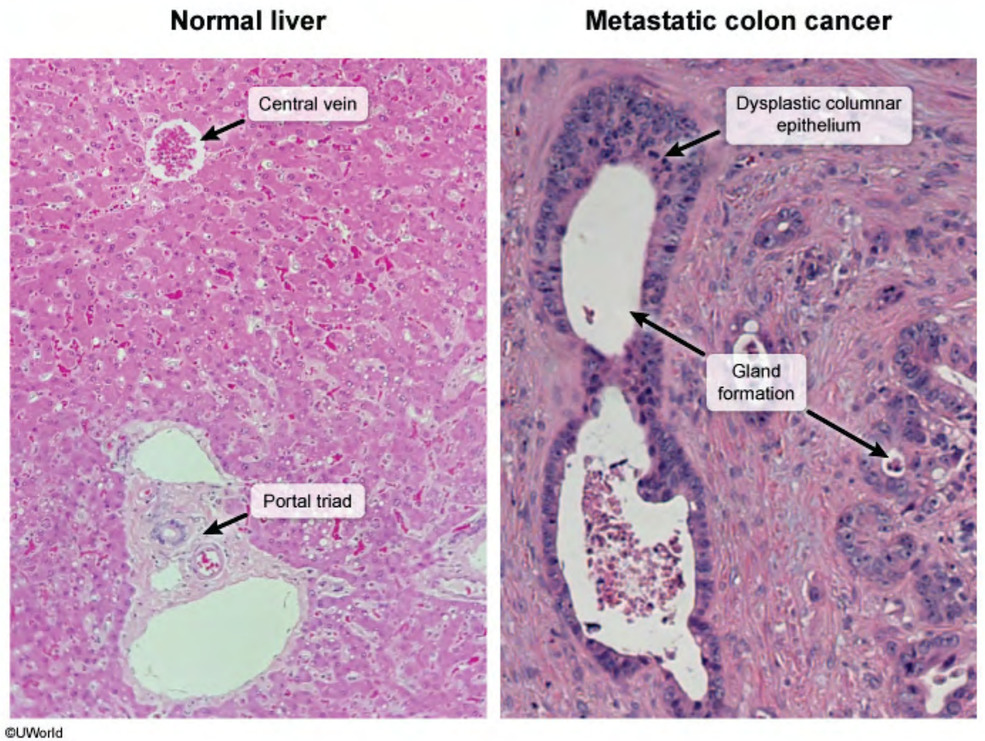

Zoom In Zoom Out Reset New | Existing My Notebook

https://t.me/USMLEWorldStep1

A 75-year-old hospitalized man is evaluated for abdominal pain and fever. The patient was admitted 2 weeks ago due to necrotizing fasciitis of the gluteal region and severe sepsis. He has been treated with surgical debridements, intravenous antibiotics, and fluids. For the past 2 days, the patient has had right upper quadrant abdominal pain, nausea, and recurrent fever. He has a history of hypertension, type 2 diabetes mellitus, and chronic obstructive pulmonary disease. His temperature is 38.8 C (102 F). Physical examination shows marked tenderness over the right subcostal area. Leukocyte count is 18,000/mm^3 compared to 9,600/mm^3 2 days ago. Laparoscopic surgery is planned. Which of the following will most likely be found during this patient's surgery?

- A. Choledochal cyst
- B. Fibrotic and shrunken gallbladder
- C. Fluke infection of the biliary tree
- D. Inflamed and enlarged gallbladder
- E. Pigment gallstones
- F. Porcelain gallbladder

Submit

https://t.me/USMLEWorldStep1

A 75-year-old hospitalized man is evaluated for abdominal pain and fever. The patient was admitted 2 weeks ago due to necrotizing fasciitis of the gluteal region and severe sepsis. He has been treated with surgical debridements, intravenous antibiotics, and fluids. For the past 2 days, the patient has had right upper quadrant abdominal pain, nausea, and recurrent fever. He has a history of hypertension, type 2 diabetes mellitus, and chronic obstructive pulmonary disease. His temperature is 38.8 C (102 F). Physical examination shows marked tenderness over the right subcostal area. Leukocyte count is 18,000/mm^3 compared to 9,600/mm^3 2 days ago. Laparoscopic surgery is planned. Which of the following will most likely be found during this patient's surgery?

- ✗ A. Choledochal cyst (2%)
- B. Fibrotic and shrunken gallbladder (1%)
- C. Fluke infection of the biliary tree (6%)
- ✓ D. Inflamed and enlarged gallbladder (71%)
- E. Pigment gallstones (13%)
- F. Porcelain gallbladder (4%)

Incorrect
Correct answer
D

71%
Answered correctly

15 secs
Time Spent

2023
Version

Explanation

This patient likely has acute **acalculous cholecystitis**, an acute inflammation of the gallbladder in the absence of gallstones. Acalculous cholecystitis most commonly occurs in **critically ill** patients (eg, those with sepsis, severe burns, trauma, immunosuppression) and is associated with high mortality. The condition is thought to arise secondary to gallbladder stasis and **ischemia**, which cause inflammation of and injury to the gallbladder wall.

Clinical manifestations may be subtle, especially in those who are sedated or intubated. **Fever, right upper quadrant pain**, a positive Murphy's sign, **leukocytosis**, and mild elevations in liver function tests are often

https://t.me/USMLEWorldStep1

Explanation

This patient likely has acute **acalculous cholecystitis**, an acute inflammation of the gallbladder in the absence of gallstones. Acalculous cholecystitis most commonly occurs in **critically ill** patients (eg, those with sepsis, severe burns, trauma, immunosuppression) and is associated with high mortality. The condition is thought to arise secondary to gallbladder stasis and **ischemia**, which cause inflammation of and injury to the gallbladder wall.

Clinical manifestations may be subtle, especially in those who are sedated or intubated. **Fever, right upper quadrant pain**, a positive Murphy's sign, **leukocytosis**, and mild elevations in liver function tests are often present. Physical examination may demonstrate jaundice and a palpable right upper quadrant mass. The diagnostic study of choice is an ultrasound, which may show signs of acute cholecystitis (eg, an edematous and enlarged gallbladder) and **no gallstones**.

(Choice A) Choledochal cysts are congenital dilations of the common bile duct that typically present during childhood (age <10) with recurrent abdominal pain and jaundice.

(Choice B) Chronic cholecystitis results from repeated mild attacks of acute cholecystitis, which leads to thickening of the gallbladder wall. Ultrasound typically demonstrates a shrunken, fibrosed gallbladder.

(Choice C) Liver fluke infection usually affects individuals from endemic areas (eg, Southeast Asia) and presents acutely with fever, right upper quadrant pain, jaundice, and eosinophilia. Infection of the biliary tree is associated with the formation of brown pigment gallstones, not acute acalculous cholecystitis.

(Choice E) Pigment gallstones are categorized as black (typically secondary to intravascular hemolysis) or brown (typically secondary to biliary infection). These gallstones are associated with acute calculous cholecystitis, not acute acalculous cholecystitis.

(Choice F) Porcelain gallbladder is usually found incidentally on abdominal radiograph as a rim of calcium deposits outlining the gallbladder. The condition is associated with chronic cholecystitis and may increase the risk of gallbladder carcinoma.

Educational objective:
Acute acalculous cholecystitis is an acute inflammation of the gallbladder in the absence of gallstones. It typically

https://t.me/USMLEWorldStep1

gallstones. Acalculous cholecystitis most commonly occurs in **critically ill** patients (eg, those with sepsis, severe burns, trauma, immunosuppression) and is associated with high mortality. The condition is thought to arise secondary to gallbladder stasis and **ischemia**, which cause inflammation of and injury to the gallbladder wall.

Clinical manifestations may be subtle, especially in those who are sedated or intubated. **Fever, right upper quadrant pain**, a positive Murphy's sign, **leukocytosis**, and mild elevations in liver function tests are often present. Physical examination may demonstrate jaundice and a palpable right upper quadrant mass. The diagnostic study of choice is an ultrasound, which may show signs of acute cholecystitis (eg, an edematous and enlarged gallbladder) and **no gallstones**.

(Choice A) Choledochal cysts are congenital dilations of the common bile duct that typically present during childhood (age <10) with recurrent abdominal pain and jaundice.

(Choice B) Chronic cholecystitis results from repeated mild attacks of acute cholecystitis, which leads to thickening of the gallbladder wall. Ultrasound typically demonstrates a shrunken, fibrosed gallbladder.

(Choice C) Liver fluke infection usually affects individuals from endemic areas (eg, Southeast Asia) and presents acutely with fever, right upper quadrant pain, jaundice, and eosinophilia. Infection of the biliary tree is associated with the formation of brown pigment gallstones, not acute acalculous cholecystitis.

(Choice E) Pigment gallstones are categorized as black (typically secondary to intravascular hemolysis) or brown (typically secondary to biliary infection). These gallstones are associated with acute calculous cholecystitis, not acute acalculous cholecystitis.

(Choice F) Porcelain gallbladder is usually found incidentally on abdominal radiograph as a rim of calcium deposits outlining the gallbladder. The condition is associated with chronic cholecystitis and may increase the risk of gallbladder carcinoma.

Educational objective:
Acute acalculous cholecystitis is an acute inflammation of the gallbladder in the absence of gallstones. It typically occurs in critically ill patients (eg, those with sepsis, severe burns, trauma, immunosuppression) due to gallbladder stasis and ischemia. Clinical findings may be subtle and include fever, right upper quadrant pain, and leukocytosis.

References

https://t.me/USMLEWorldStep1

A 21-year-old man comes to the office due to yellow discoloration of his eyes after a hiking trip. The patient had a similar episode 2 years ago after fasting for a couple of days. Vital signs are within normal limits. Examination shows scleral icterus; there is no hepatosplenomegaly. Laboratory findings are as follows:

Hemoglobin	14.8 g/dL
Reticulocyte count	0.5%
Albumin	4.2 g/dL
Total bilirubin	2.8 mg/dL
Direct bilirubin	0.2 mg/dL
Alkaline phosphatase	90 U/L
Aspartate aminotransferase (SGOT)	20 U/L
Alanine aminotransferase (SGPT)	22 U/L

Which of the following is the most likely cause of this patient's jaundice?

- A. Decreased activity of UDP glucuronosyltransferase
- B. Decreased excretion of bilirubin by hepatocytes
- C. Hemolysis due to erythrocyte spectrin deficiency
- D. Intermittent activation of chronic hepatitis C infection
- E. Intermittent obstruction of common bile duct by gallstones

Submit

https://t.me/USMLEWorldStep1

A 21-year-old man comes to the office due to yellow discoloration of his eyes after a hiking trip. The patient had a similar episode 2 years ago after fasting for a couple of days. Vital signs are within normal limits. Examination shows scleral icterus; there is no hepatosplenomegaly. Laboratory findings are as follows:

Hemoglobin	14.8 g/dL
Reticulocyte count	0.5%
Albumin	4.2 g/dL
Total bilirubin	2.8 mg/dL
Direct bilirubin	0.2 mg/dL
Alkaline phosphatase	90 U/L
Aspartate aminotransferase (SGOT)	20 U/L
Alanine aminotransferase (SGPT)	22 U/L

Which of the following is the most likely cause of this patient's jaundice?

✓ A. Decreased activity of UDP glucuronosyltransferase (86%)

B. Decreased excretion of bilirubin by hepatocytes (4%)

✗ C. Hemolysis due to erythrocyte spectrin deficiency (5%)

D. Intermittent activation of chronic hepatitis C infection (0%)

E. Intermittent obstruction of common bile duct by gallstones (2%)

Incorrect
Correct answer
A

86%
Answered correctly

05 secs
Time Spent

2023
Version

Explanation

https://t.me/USMLEWorldStep1

Incorrect
Corre
A

Expl

Exhibit Display

Bilirubin metabolism

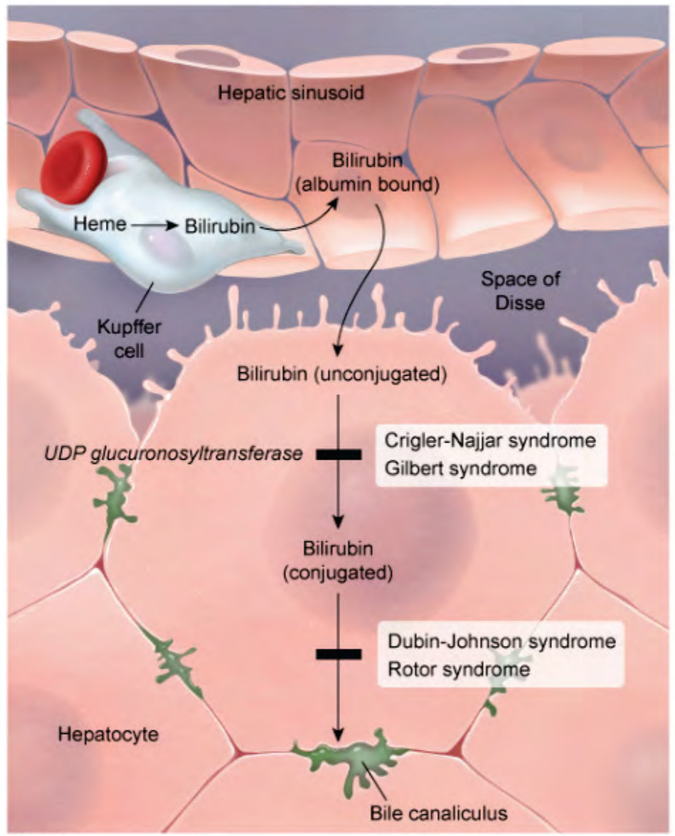

Zoom In | Zoom Out | Reset | New | Existing | My Notebook

Bile canaliculus

https://t.me/USMLEWorldStep1

©UWorld

This patient's isolated elevation in unconjugated bilirubin and history of intermittent scleral icterus with an otherwise normal physical examination are consistent with **Gilbert syndrome**, the most common inherited disorder of bilirubin glucuronidation. In contrast to hepatobiliary disease (eg, cholestasis) in which conjugated bilirubin is elevated due to reflux back into the plasma, **unconjugated hyperbilirubinemia** is typically caused by increased bilirubin production (eg, hemolysis) or **impaired bilirubin conjugation**.

In general, a key component of bilirubin metabolism is the conjugation of bilirubin with glucuronic acid in the liver by UDP glucuronosyltransferase. In Gilbert syndrome, a genetic mutation results in **reduced enzymatic activity** of **UDP glucuronosyltransferase**.

Patients are usually asymptomatic but have **recurrent episodes** of mild unconjugated hyperbilirubinemia causing **scleral icterus** and **jaundice**, usually beginning after puberty. Episodes are typically triggered when production of unconjugated bilirubin is mildly increased, such as with **stress** (eg, fasting, vigorous exertion, illness).

(Choice B) Dubin-Johnson syndrome is a benign, hereditary cause of hyperbilirubinemia that can present with intermittent scleral icterus. However, this condition is due to defective excretion of bilirubin by hepatocytes, which results in conjugated (not unconjugated) hyperbilirubinemia.

(Choice C) Hereditary spherocytosis is characterized by poor red blood cell deformability due to an erythrocyte membrane defect (eg, spectrin, ankyrin) and leads to unconjugated hyperbilirubinemia from chronic hemolysis. Anemia, an elevated reticulocyte count, and splenomegaly would be expected.

(Choice D) Inflammation of the liver due to viral infection (eg, hepatitis C) may cause hyperbilirubinemia, but significant elevations in aminotransferases would be expected.

(Choice E) Choledocholithiasis leading to bile duct obstruction causes an elevation of conjugated (not unconjugated) bilirubin. In addition, alkaline phosphatase and transaminases are typically elevated, and patients usually have right upper quadrant or epigastric pain, nausea, and vomiting.

Educational objective:

Gilbert syndrome is a benign disorder that presents with recurrent scleral icterus and jaundice, typically triggered

https://t.me/USMLEWorldStep1

This patient's isolated elevation in unconjugated bilirubin and history of intermittent scleral icterus with an otherwise normal physical examination are consistent with **Gilbert syndrome**, the most common inherited disorder of bilirubin glucuronidation. In contrast to hepatobiliary disease (eg, cholestasis) in which conjugated bilirubin is elevated due to reflux back into the plasma, **unconjugated hyperbilirubinemia** is typically caused by increased bilirubin production (eg, hemolysis) or **impaired bilirubin conjugation**.

In general, a key component of bilirubin metabolism is the conjugation of bilirubin with glucuronic acid in the liver by UDP glucuronosyltransferase. In Gilbert syndrome, a genetic mutation results in **reduced enzymatic activity** of **UDP glucuronosyltransferase**.

Patients are usually asymptomatic but have **recurrent episodes** of mild unconjugated hyperbilirubinemia causing **scleral icterus** and **jaundice**, usually beginning after puberty. Episodes are typically triggered when production of unconjugated bilirubin is mildly increased, such as with **stress** (eg, fasting, vigorous exertion, illness).

(Choice B) Dubin-Johnson syndrome is a benign, hereditary cause of hyperbilirubinemia that can present with intermittent scleral icterus. However, this condition is due to defective excretion of bilirubin by hepatocytes, which results in conjugated (not unconjugated) hyperbilirubinemia.

(Choice C) Hereditary spherocytosis is characterized by poor red blood cell deformability due to an erythrocyte membrane defect (eg, spectrin, ankyrin) and leads to unconjugated hyperbilirubinemia from chronic hemolysis. Anemia, an elevated reticulocyte count, and splenomegaly would be expected.

(Choice D) Inflammation of the liver due to viral infection (eg, hepatitis C) may cause hyperbilirubinemia, but significant elevations in aminotransferases would be expected.

(Choice E) Choledocholithiasis leading to bile duct obstruction causes an elevation of conjugated (not unconjugated) bilirubin. In addition, alkaline phosphatase and transaminases are typically elevated, and patients usually have right upper quadrant or epigastric pain, nausea, and vomiting.

Educational objective:
Gilbert syndrome is a benign disorder that presents with recurrent scleral icterus and jaundice, typically triggered by stress (eg, fasting, illness). Pathogenesis involves decreased activity of UDP glucuronosyltransferase (impaired bilirubin conjugation), and an isolated mild unconjugated hyperbilirubinemia is typical.

https://t.me/USMLEWorldStep1

normal physical examination are consistent with **Gilbert syndrome**, the most common inherited disorder of bilirubi
elevat
bilirubi

In gen
by UD
of **UDI**

Patien
sclera
uncon

(Choi
interm
results

(Choi
memb
Anemi

(Choi
signifi

(Choi
uncon
usuall

Educa
Gilbert

by stress (eg, fasting, illness). Pathogenesis involves decreased activity of UDP glucuronosyltransferase (impaired bilirubin conjugation), and an isolated mild unconjugated hyperbilirubinemia is typical.

Exhibit Display

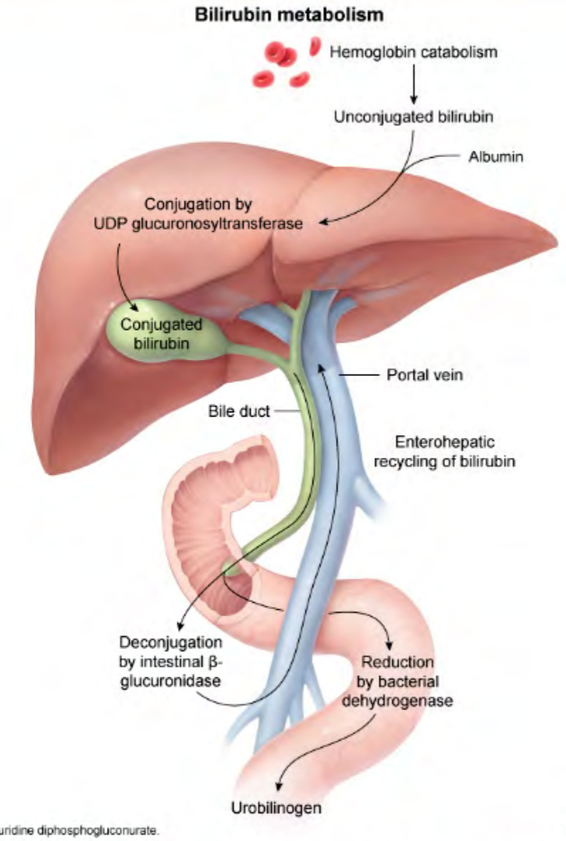

Zoom In | Zoom Out | Reset | New | Existing | My Notebook

https://t.me/USMLEWorldStep1

An 81-year-old woman is brought to the emergency department by a neighbor due to abdominal pain. The pain comes in waves and is associated with nausea and vomiting. The patient is confused and unable to provide additional information. Past medical history is unknown, but she comes with a bag containing medications used in type 2 diabetes mellitus, hypercholesterolemia, hypertension, and dementia. On examination, the patient has a low-grade fever and mild tachycardia. She appears in distress due to pain. Mucous membranes are dry, and there is decreased skin turgor. Abdominal examination shows diffuse tenderness with high-pitched bowel sounds. Imaging of the abdomen reveals a complete small bowel obstruction. The patient undergoes laparotomy with extraction of a hard mass obstructing the ileocecal valve. The cholesterol content of the mass is 85%. Which of the following radiographic findings is most consistent with this patient's clinical presentation?

- A. Air in the biliary tree
- B. Distended bladder
- C. Free air in peritoneal cavity
- D. Heavily calcified arteries
- E. Pancreatic calcifications
- F. Pleural effusion

Submit

https://t.me/USMLEWorldStep1

An 81-year-old woman is brought to the emergency department by a neighbor due to abdominal pain. The pain comes in waves and is associated with nausea and vomiting. The patient is confused and unable to provide additional information. Past medical history is unknown, but she comes with a bag containing medications used in type 2 diabetes mellitus, hypercholesterolemia, hypertension, and dementia. On examination, the patient has a low-grade fever and mild tachycardia. She appears in distress due to pain. Mucous membranes are dry, and there is decreased skin turgor. Abdominal examination shows diffuse tenderness with high-pitched bowel sounds. Imaging of the abdomen reveals a complete small bowel obstruction. The patient undergoes laparotomy with extraction of a hard mass obstructing the ileocecal valve. The cholesterol content of the mass is 85%. Which of the following radiographic findings is most consistent with this patient's clinical presentation?

- ✓ A. Air in the biliary tree (68%)
- B. Distended bladder (1%)
- ✗ C. Free air in peritoneal cavity (8%)
- D. Heavily calcified arteries (6%)
- E. Pancreatic calcifications (13%)
- F. Pleural effusion (0%)

Incorrect
Correct answer
A

68%
Answered correctly

04 secs
Time Spent

2023
Version

Explanation

https://t.me/USMLEWorldStep1

C. Free air in peritoneal cavity (8%)

D. Heavily calcified arteries (6%)

Incc
Corre
A

Expl

Exhibit Display

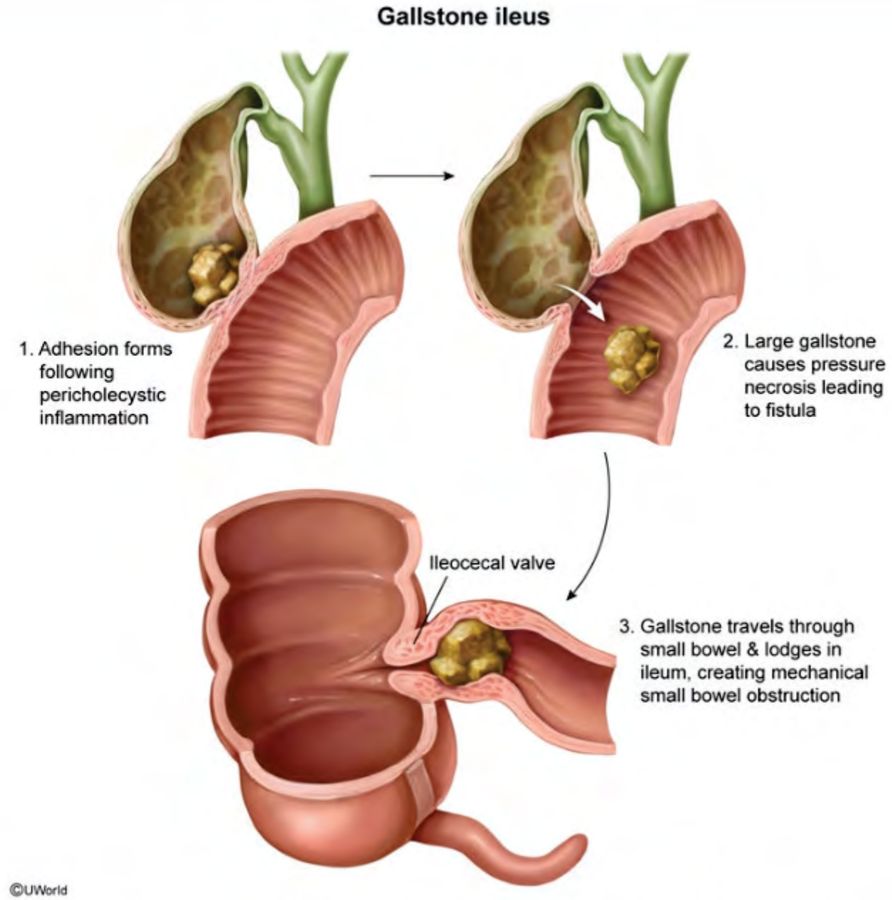

Zoom In | Zoom Out | Reset | New | Existing | My Notebook

3. Gallstone travels through

https://t.me/USMLEWorldStep1

This patient, an older woman with intermittent abdominal pain and a cholesterol-containing mass lodged at the ileocecal valve, has a **gallstone ileus**. Gallstone ileus is not a true ileus (nonmechanical disruption of intestinal motility) but rather a mechanical obstruction that occurs when a large gallstone (usually >2.5 cm in diameter) erodes into the intestinal lumen through a **cholecystoenteric fistula**. As the gallstone travels down the intestine, it intermittently obstructs the lumen, causing episodic symptoms. Eventually, the gallstone may come to rest in the ileum, which has the smallest lumen of the intestinal tract.

Typical symptoms of gallstone ileus include crampy pain, vomiting, and bloating. Examination will show signs of **small bowel obstruction**, such as abdominal distension, tenderness, and high-pitched (tinkling) bowel sounds. Abdominal radiographs may reveal dilated bowel loops with air-fluid levels. Careful inspection may also reveal air in the biliary tree (**pneumobilia**) due to retrograde passage of intestinal gas through the fistula.

(Choice B) Bladder distension due to urinary retention is most often associated with underlying prostatic hyperplasia, anticholinergic medication use, and underlying neurologic impairment.

(Choice C) Air in the peritoneal cavity is suggestive of bowel perforation. Although the bowel wall is disrupted in gallstone ileus, the cholecystoenteric fistula is usually associated with fibrotic adhesions between the biliary tree and the bowel, and there is no free communication with the peritoneal cavity.

(Choice D) Heavily calcified vessels are a sign of chronic atherosclerotic arterial disease. Common intra-abdominal complications in such patients would include intestinal ischemia and abdominal aortic aneurysm.

(Choice E) Pancreatic calcifications are suggestive of chronic pancreatitis, which is most commonly seen in alcohol abuse, cystic fibrosis, or outlet obstruction due to tumor, pseudocysts, or recurrent passage of gallstones.

(Choice F) Pleural effusion may be seen in a broad range of intra-abdominal conditions, such as pancreatitis, esophageal rupture, or chronic hepatic or renal disease.

Educational objective:
Gallstone ileus is a mechanical bowel obstruction caused when a large gallstone erodes into the intestinal lumen. Pneumobilia (air in the biliary tract) is a common finding.

https://t.me/USMLEWorldStep1

A 6-year-old boy with no chronic medical conditions is brought to the emergency department due to confusion and intractable vomiting. His symptoms began a few hours ago and have gradually worsened. The patient's mother reports that he contracted a febrile illness from his younger brother 2 days ago. She gave the patient one tablet of an over-the-counter cold medication yesterday, and his fever resolved. While the mother is speaking, the patient lapses into a coma. If a liver biopsy were performed, light microscopy of the specimen would most likely reveal which of the following?

- A. Apoptosis of hepatocytes
- B. Bile duct destruction
- C. Centrilobular congestion
- D. Microvesicular steatosis
- E. Periportal inflammatory infiltration

Submit

https://t.me/USMLEWorldStep1

A 6-year-old boy with no chronic medical conditions is brought to the emergency department due to confusion and intractable vomiting. His symptoms began a few hours ago and have gradually worsened. The patient's mother reports that he contracted a febrile illness from his younger brother 2 days ago. She gave the patient one tablet of an over-the-counter cold medication yesterday, and his fever resolved. While the mother is speaking, the patient lapses into a coma. If a liver biopsy were performed, light microscopy of the specimen would most likely reveal which of the following?

- A. Apoptosis of hepatocytes (28%)
- ✗ B. Bile duct destruction (0%)
- C. Centrilobular congestion (8%)
- ✓ D. Microvesicular steatosis (50%)
- E. Periportal inflammatory infiltration (11%)

Incorrect
Correct answer
D

50%
Answered correctly

03 secs
Time Spent

2023
Version

Explanation

Reye syndrome	
Pathophysiology	• Aspirin use in children during viral infection (eg, influenza, varicella) • Mitochondrial toxicity → impaired fatty acid metabolism • Microvesicular fat deposits in the liver • Hepatic dysfunction → hyperammonemia • Diffuse astrocyte swelling (ie, cerebral edema)
	• Acute liver failure

https://t.me/USMLEWorldStep1

Explanation

Reye syndrome	
Pathophysiology	• Aspirin use in children during viral infection (eg, influenza, varicella) • Mitochondrial toxicity → impaired fatty acid metabolism • Microvesicular fat deposits in the liver • Hepatic dysfunction → hyperammonemia • Diffuse astrocyte swelling (ie, cerebral edema)
Clinical features	• Acute liver failure ◦ Hepatomegaly ◦ Elevated transaminases; coagulopathy • Rapidly progressive encephalopathy ◦ Vomiting, lethargy, seizures, coma
Treatment	• Supportive

Children with a **febrile illness** (eg, influenza, varicella) treated with **salicylates** (eg, aspirin) are at risk for developing **Reye syndrome**. It is hypothesized that affected children may have an inborn metabolic error that renders them sensitive to the toxic effects of salicylates, particularly in virus-infected cells. Aspirin in these individuals causes **mitochondrial dysfunction**, which results in **impaired fatty acid metabolism** and the two components of Reye syndrome:

- **Hepatic dysfunction** results from the mitochondrial insult and manifests with hepatomegaly, elevated transaminases, hyperammonemia, and prolonged PT and PTT. Bilirubin is typically normal, and jaundice is rare. Light microscopy of a liver specimen shows **microvesicular steatosis** (ie, small fat vacuoles in the cytoplasm of hepatocytes) without necrosis or inflammation. Electron microscopy findings include swollen mitochondria.

https://t.me/USMLEWorldStep1

Clinical features	• Acute liver failure
	  ◦ Hepatomegaly
	  ◦ Elevated transaminases; coagulopathy
	• Rapidly progressive encephalopathy
	  ◦ Vomiting, lethargy, seizures, coma

Treatment	• Supportive

Children with a **febrile illness** (eg, influenza, varicella) treated with **salicylates** (eg, aspirin) are at risk for developing **Reye syndrome**. It is hypothesized that affected children may have an inborn metabolic error that renders them sensitive to the toxic effects of salicylates, particularly in virus-infected cells. Aspirin in these individuals causes **mitochondrial dysfunction**, which results in **impaired fatty acid metabolism** and the two components of Reye syndrome:

- **Hepatic dysfunction** results from the mitochondrial insult and manifests with hepatomegaly, elevated transaminases, hyperammonemia, and prolonged PT and PTT. Bilirubin is typically normal, and jaundice is rare. Light microscopy of a liver specimen shows **microvesicular steatosis** (ie, small fat vacuoles in the cytoplasm of hepatocytes) without necrosis or inflammation. Electron microscopy findings include swollen mitochondria.

- **Encephalopathy** is attributed to hepatic dysfunction and the toxic effect of hyperammonemia on the CNS, leading to **cerebral edema**. Vomiting and confusion from cerebral swelling can rapidly progress to coma and potentially death.

To avoid the possibility of inducing Reye syndrome, aspirin should not be administered to children except in the management of Kawasaki disease and rheumatologic diseases (eg, juvenile idiopathic arthritis).

(Choices A and E) Apoptosis of hepatocytes and periportal mononuclear inflammatory infiltration are microscopic findings seen in viral hepatitis. In contrast to this patient's presentation, hepatic encephalopathy from viral hepatitis would develop gradually.

(Choice B) Primary biliary cholangitis is characterized by bile duct destruction and periductal granulomatous

https://t.me/USMLEWorldStep1

- **Hepatic dysfunction** results from the mitochondrial insult and manifests with hepatomegaly, elevated transaminases, hyperammonemia, and prolonged PT and PTT. Bilirubin is typically normal, and jaundice is rare. Light microscopy of a liver specimen shows **microvesicular steatosis** (ie, small fat vacuoles in the cytoplasm of hepatocytes) without necrosis or inflammation. Electron microscopy findings include swollen mitochondria.

- **Encephalopathy** is attributed to hepatic dysfunction and the toxic effect of hyperammonemia on the CNS, leading to **cerebral edema**. Vomiting and confusion from cerebral swelling can rapidly progress to coma and potentially death.

To avoid the possibility of inducing Reye syndrome, aspirin should not be administered to children except in the management of Kawasaki disease and rheumatologic diseases (eg, juvenile idiopathic arthritis).

(Choices A and E) Apoptosis of hepatocytes and periportal mononuclear inflammatory infiltration are microscopic findings seen in viral hepatitis. In contrast to this patient's presentation, hepatic encephalopathy from viral hepatitis would develop gradually.

(Choice B) Primary biliary cholangitis is characterized by bile duct destruction and periductal granulomatous inflammation. Hepatic encephalopathy may occur as a late finding of chronic cirrhosis but would not present acutely, as Reye syndrome did in this patient.

(Choice C) In congestive heart failure, which would manifest with peripheral edema rather than rapidly progressive encephalopathy, the liver shows centrilobular congestion and, in some cases, centrilobular necrosis. Centrilobular necrosis can also be seen with acetaminophen toxicity, which is unlikely in this patient who received a single antipyretic tablet.

Educational objective:
Reye syndrome is characterized by liver failure and encephalopathy following salicylate (aspirin) administration in children with a febrile illness. Aspirin-induced mitochondrial dysfunction causes impaired fatty acid metabolism and microvesicular steatosis of the liver.

Pathology	Gastrointestinal & Nutrition	Reye syndrome
Subject	System	Topic

https://t.me/USMLEWorldStep1

A 20-year-old man is evaluated in the clinic due to intermittent episodes of self-resolving jaundice. His symptoms are not provoked by any particular circumstances or events. The patient otherwise feels healthy and has no other symptoms. He does not use tobacco, alcohol, or illicit drugs. Complete blood count is within normal limits. Liver function studies are as follows:

Total protein	6.5 g/dL
Albumin	4 g/dL
Total bilirubin	2.8 mg/dL
Direct bilirubin	2.0 mg/dL
Alkaline phosphatase	90 U/L
Aspartate aminotransferase	28 U/L
Alanine aminotransferase	30 U/L

Liver biopsy shows abundant pigment inclusions in the lysosomes of the otherwise normal hepatocytes. Electron spin resonance spectroscopy reveals that the pigment is composed of polymers of epinephrine metabolites. Which of the following is the most likely cause of this patient's jaundice?

- A. Defective hepatocellular excretion of bilirubin glucuronides
- B. Impaired conjugation of bilirubin
- C. Increased production of catecholamines
- D. Ineffective intramedullary erythropoiesis
- E. Low serum ceruloplasmin

https://t.me/USMLEWorldStep1

symptoms. He does not use tobacco, alcohol, or illicit drugs. Complete blood count is within normal limits. Liver function studies are as follows:

Total protein	6.5 g/dL
Albumin	4 g/dL
Total bilirubin	2.8 mg/dL
Direct bilirubin	2.0 mg/dL
Alkaline phosphatase	90 U/L
Aspartate aminotransferase	28 U/L
Alanine aminotransferase	30 U/L

Liver biopsy shows abundant pigment inclusions in the lysosomes of the otherwise normal hepatocytes. Electron spin resonance spectroscopy reveals that the pigment is composed of polymers of epinephrine metabolites. Which of the following is the most likely cause of this patient's jaundice?

- A. Defective hepatocellular excretion of bilirubin glucuronides
- B. Impaired conjugation of bilirubin
- C. Increased production of catecholamines
- D. Ineffective intramedullary erythropoiesis
- E. Low serum ceruloplasmin

Submit

https://t.me/USMLEWorldStep1

symptoms. He does not use tobacco, alcohol, or illicit drugs. Complete blood count is within normal limits. Liver function studies are as follows:

Total protein	6.5 g/dL
Albumin	4 g/dL
Total bilirubin	2.8 mg/dL
Direct bilirubin	2.0 mg/dL
Alkaline phosphatase	90 U/L
Aspartate aminotransferase	28 U/L
Alanine aminotransferase	30 U/L

Liver biopsy shows abundant pigment inclusions in the lysosomes of the otherwise normal hepatocytes. Electron spin resonance spectroscopy reveals that the pigment is composed of polymers of epinephrine metabolites. Which of the following is the most likely cause of this patient's jaundice?

- ✓ A. Defective hepatocellular excretion of bilirubin glucuronides (61%)
- ✗ B. Impaired conjugation of bilirubin (13%)
- C. Increased production of catecholamines (17%)
- D. Ineffective intramedullary erythropoiesis (1%)
- E. Low serum ceruloplasmin (4%)

Incorrect
Correct answer
A

61%
Answered correctly

07 secs
Time Spent

2023
Version

https://t.me/USMLEWorldStep1

D. Ineffective intramedullary erythropoiesis (1%)

Exhibit Display

Bilirubin metabolism

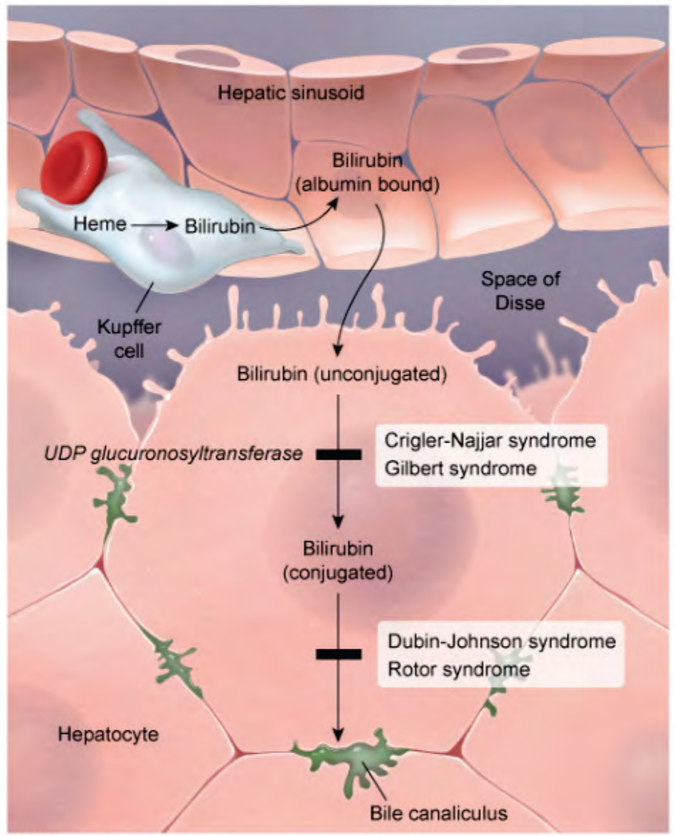

Zoom In | Zoom Out | Reset | New | Existing | My Notebook

https://t.me/USMLEWorldStep1

©UWorld

Dubin-Johnson syndrome is a benign autosomal recessive disorder characterized by defective hepatic **excretion of bilirubin glucuronides** due to a mutation in the canalicular membrane transport protein. Individuals with this condition can develop episodes of **jaundice**, which may only become evident in the context of a trigger (eg, illness, pregnancy, oral contraceptive use). Otherwise, they are usually asymptomatic with a normal physical examination.

Impaired bilirubin excretion may result in **direct (conjugated) hyperbilirubinemia** (eg, usually 2-5 mg/dL), but other routine laboratory tests (eg, complete blood count, liver function studies) are typically normal. Grossly, the liver appears black due to impaired excretion of epinephrine metabolites that accumulate within lysosomes.

(Choice B) Impaired bilirubin conjugation is seen in conditions such as Crigler-Najjar syndrome and Gilbert syndrome and results in indirect (unconjugated) hyperbilirubinemia.

(Choice C) Increased production of catecholamines is not associated with Dubin-Johnson syndrome despite the hepatocyte accumulation of epinephrine metabolites in this condition. Pheochromocytomas are catecholamine-secreting tumors of the adrenal medulla.

(Choice D) Ineffective intramedullary erythropoiesis is seen in conditions such as beta-thalassemia and myelodysplasia, and can result in indirect hyperbilirubinemia.

(Choice E) Low levels of serum ceruloplasmin are seen in Wilson disease, which is typically associated with liver (eg, hepatitis, cirrhosis), psychiatric (eg, depression, personality changes), and neurologic (eg, dysarthria, movement disorder) abnormalities.

Educational objective:
Dubin-Johnson syndrome is a benign disorder characterized by defective hepatic excretion of bilirubin glucuronides across the canalicular membrane, resulting in direct hyperbilirubinemia and jaundice. Grossly, the liver appears black due to impaired excretion of epinephrine metabolites, which histologically appear as dense pigments within lysosomes.

References

- Hyperbilirubinemia syndromes (Gilbert-Meulengracht, Crigler-Najjar, Dubin-Johnson, and Rotor syndrome).

https://t.me/USMLEWorldStep1

A 58-year-old woman comes to the office due to a week of pain with swallowing. Her symptoms have progressively worsened, and now she cannot eat comfortably. The patient has a history of hypertension, osteoporosis, and primary biliary cholangitis progressing to cirrhosis. She underwent a liver transplant 2 years ago and is on immunosuppressive therapy. She does not use tobacco, alcohol, or illicit drugs. Vital signs are within normal limits. The oropharynx is normal in appearance. Cardiopulmonary examination is unremarkable. The patient has epigastric tenderness with no abdominal distension or guarding. Upper endoscopy shows several small esophageal ulcerations with distinct borders located in the middle and lower portions of the esophagus. A biopsy taken at the edge of an ulcer shows giant cells and intranuclear eosinophilic inclusions. Which of the following is the most appropriate treatment for this patient?

- A. Acyclovir
- B. Alendronate
- C. Azithromycin
- D. Fluconazole
- E. Misoprostol
- F. Omeprazole
- G. Tenofovir

Submit

https://t.me/USMLEWorldStep1

A 58-year-old woman comes to the office due to a week of pain with swallowing. Her symptoms have progressively worsened, and now she cannot eat comfortably. The patient has a history of hypertension, osteoporosis, and primary biliary cholangitis progressing to cirrhosis. She underwent a liver transplant 2 years ago and is on immunosuppressive therapy. She does not use tobacco, alcohol, or illicit drugs. Vital signs are within normal limits. The oropharynx is normal in appearance. Cardiopulmonary examination is unremarkable. The patient has epigastric tenderness with no abdominal distension or guarding. Upper endoscopy shows several small esophageal ulcerations with distinct borders located in the middle and lower portions of the esophagus. A biopsy taken at the edge of an ulcer shows giant cells and intranuclear eosinophilic inclusions. Which of the following is the most appropriate treatment for this patient?

- ✓ A. Acyclovir (77%)
- B. Alendronate (0%)
- C. Azithromycin (2%)
- D. Fluconazole (4%)
- E. Misoprostol (1%)
- F. Omeprazole (8%)
- G. Tenofovir (5%)

Correct

77% Answered correctly

05 secs Time Spent

2023 Version

Explanation

Esophagitis in an immunocompromised patient			
Pathogen	**Endoscopic findings**	**Microscopic findings**	**Treatment**

https://t.me/USMLEWorldStep1

Explanation

Esophagitis in an immunocompromised patient			
Pathogen	**Endoscopic findings**	**Microscopic findings**	**Treatment**
Candida albicans	Patches of adherent, grey/white pseudomembranes on erythematous mucosa	Yeast cells & pseudohyphae invading mucosal cells	Fluconazole
HSV	Small vesicles → "punched-out" ulcers	Eosinophilic intranuclear inclusions (Cowdry type A) in multinuclear squamous cells at ulcer margins	Acyclovir
CMV	Large, linear ulcerations	Intranuclear & cytoplasmic inclusions	Ganciclovir
CMV = cytomegalovirus; **HSV** = herpes simplex virus.			

Esophagitis is usually the result of a noninfectious process such as gastroesophageal reflux disease. However, patients with **impaired cell-mediated immunity** (eg, chemotherapy, post-transplantation, AIDS) are also at risk for esophageal infections. The leading causes are *Candida*, cytomegalovirus, and **herpes simplex virus** (HSV).

HSV esophagitis usually presents with significant pain and discomfort with swallowing. Endoscopy typically reveals small vesicles or **punched-out ulcers** (ie, distinct borders) on the esophageal mucosa. Classic HSV findings on biopsy include multinucleated giant cells and **eosinophilic intranuclear inclusion bodies** (Cowdry type A). Treatment with oral **acyclovir** usually resolves the active infection, but latent virus can reactivate in the future, leading to recurrent symptoms.

(Choice B) Alendronate is a bisphosphonate used in the treatment of osteoporosis. Bisphosphonates can cause medication-induced esophagitis and could worsen this patient's symptoms.

(Choice C) Azithromycin can be used as part of the treatment for disseminated mycobacterium avium complex,

https://t.me/USMLEWorldStep1

CMV	Large, linear ulcerations	inclusions	Ganciclovir
CMV = cytomegalovirus; **HSV** = herpes simplex virus.			

Esophagitis is usually the result of a noninfectious process such as gastroesophageal reflux disease. However, patients with **impaired cell-mediated immunity** (eg, chemotherapy, post-transplantation, AIDS) are also at risk for esophageal infections. The leading causes are *Candida*, cytomegalovirus, and **herpes simplex virus** (HSV).

HSV esophagitis usually presents with significant pain and discomfort with swallowing. Endoscopy typically reveals small vesicles or **punched-out ulcers** (ie, distinct borders) on the esophageal mucosa. Classic HSV findings on biopsy include multinucleated giant cells and **eosinophilic intranuclear inclusion bodies** (Cowdry type A). Treatment with oral **acyclovir** usually resolves the active infection, but latent virus can reactivate in the future, leading to recurrent symptoms.

(Choice B) Alendronate is a bisphosphonate used in the treatment of osteoporosis. Bisphosphonates can cause medication-induced esophagitis and could worsen this patient's symptoms.

(Choice C) Azithromycin can be used as part of the treatment for disseminated mycobacterium avium complex, which often involves the gastrointestinal tract. However, this condition usually occurs in those with advanced AIDS; the esophagus is affected less commonly than the intestine; and endoscopy typically reveals whitish-yellow nodules on the mucosa.

(Choice D) Fluconazole is used for candidal esophagitis. Endoscopy would reveal white pseudomembranes on the esophageal mucosa, and histopathology would show yeasts with pseudohyphae.

(Choice E) Misoprostol is a prostaglandin analogue that significantly reduces gastric acid secretion and is sometimes used to prevent ulcers due to nonsteroidal antiinflammatory medication.

(Choice F) Proton pump inhibitors (eg, omeprazole) are used to treat erosive esophagitis from chronic reflux. Erosive esophagitis typically causes irregular ulcers along the esophageal mucosa, and biopsy would demonstrate inflammatory exudates and fibrinoid necrosis.

(Choice G) Tenofovir is an antiviral agent that can be used for HIV and chronic hepatitis B infections. Although tenofovir is an antiviral medication, it is not effective against HSV.

https://t.me/USMLEWorldStep1

HSV esophagitis usually presents with significant pain and discomfort with swallowing. Endoscopy typically reveals small vesicles or **punched-out ulcers** (ie, distinct borders) on the esophageal mucosa. Classic HSV findings on biopsy include multinucleated giant cells and **eosinophilic intranuclear inclusion bodies** (Cowdry type A). Treatment with oral **acyclovir** usually resolves the active infection, but latent virus can reactivate in the future, leading to recurrent symptoms.

(Choice B) Alendronate is a bisphosphonate used in the treatment of osteoporosis. Bisphosphonates can cause medication-induced esophagitis and could worsen this patient's symptoms.

(Choice C) Azithromycin can be used as part of the treatment for disseminated mycobacterium avium complex, which often involves the gastrointestinal tract. However, this condition usually occurs in those with advanced AIDS; the esophagus is affected less commonly than the intestine; and endoscopy typically reveals whitish-yellow nodules on the mucosa.

(Choice D) Fluconazole is used for candidal esophagitis. Endoscopy would reveal white pseudomembranes on the esophageal mucosa, and histopathology would show yeasts with pseudohyphae.

(Choice E) Misoprostol is a prostaglandin analogue that significantly reduces gastric acid secretion and is sometimes used to prevent ulcers due to nonsteroidal antiinflammatory medication.

(Choice F) Proton pump inhibitors (eg, omeprazole) are used to treat erosive esophagitis from chronic reflux. Erosive esophagitis typically causes irregular ulcers along the esophageal mucosa, and biopsy would demonstrate inflammatory exudates and fibrinoid necrosis.

(Choice G) Tenofovir is an antiviral agent that can be used for HIV and chronic hepatitis B infections. Although tenofovir is an antiviral medication, it is not effective against HSV.

Educational objective:
Herpes simplex virus esophagitis is most common in those with impaired cell-mediated immunity. Endoscopy typically reveals small vesicles and "punched-out" ulcers. Findings on biopsy usually include multinucleated giant cells and eosinophilic intranuclear inclusions (Cowdry type A inclusion bodies). Acyclovir is the treatment of choice.

Pathology	Gastrointestinal & Nutrition	Esophagitis
Subject	System	Topic

https://t.me/USMLEWorldStep1

HSV	ulcers	(Cowdry type A) in multinuclear squamous cells at ulcer margins
CM		

Esoph
patien
esoph

HSV e
reveal
finding
type A
future,

(Choi
medica

(Choi
which
the es
nodule

(Choi
the es

(Choi
somet

(Choi
Erosive esophagitis typically causes irregular ulcers along the esophageal mucosa, and biopsy would demonstrate

Exhibit Display

Herpes esophagitis

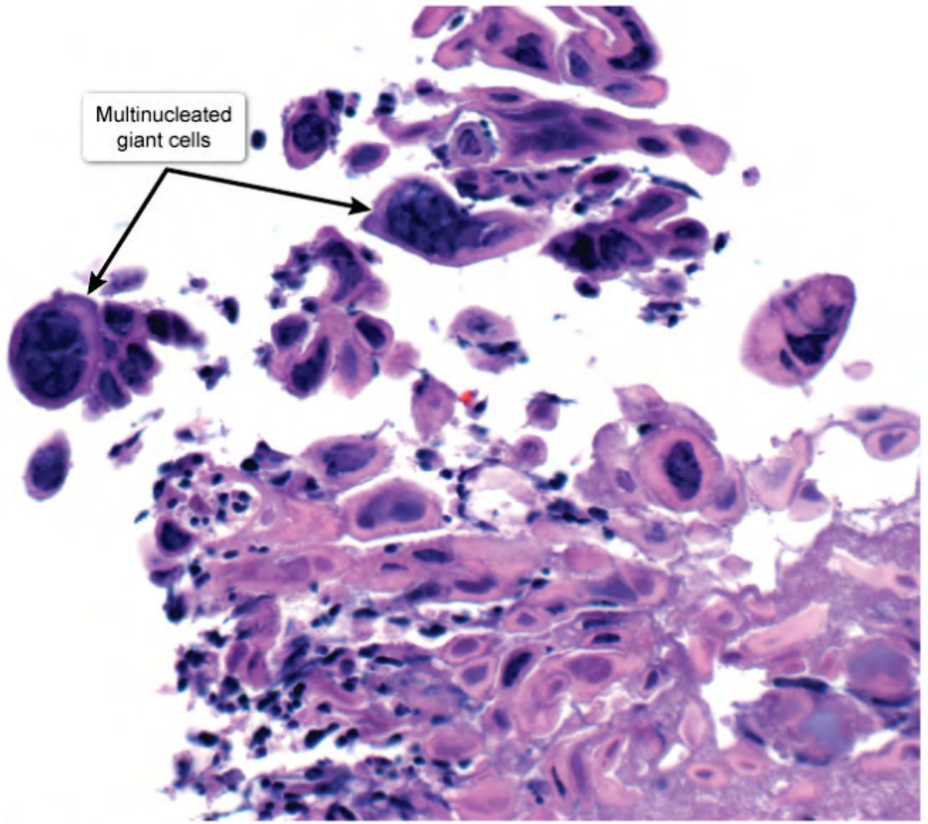

©UWorld

Zoom In | Zoom Out | Reset | New | Existing | My Notebook

https://t.me/USMLEWorldStep1

CMV	Large, linear ulcerations	inclusions	Ganciclovir
CM			

Exhibit Display

Esoph
patien
esoph

HSV e
reveal
finding
type A
future,

(Choi
medic

(Choi
which
the es
nodule

(Choi
the es

(Choi
somet

(Choi
Erosiv
inflam

(Choi
tenofovir is an antiviral medication, it is not effective against HSV.

Candidal esophagitis

©UWorld

Zoom In | Zoom Out | Reset | New | Existing | My Notebook

https://t.me/USMLEWorldStep1

A 43-year-old man comes to the office with a several-month history of fatigue, rash, flushing, and abdominal cramps. His rash is worse with rubbing or scratching, and he has diffuse itching after hot showers. The patient is frequently dizzy and light-headed after prolonged standing and had an episode of syncope while working in the hot sun. He used to be healthy and physically active but has had to reduce his normal activity. The patient does not use tobacco, alcohol, or illicit drugs. Vital signs are normal. Skin examination shows a maculopapular rash. Skin biopsy shows large clusters of mast cells that are positive for KIT (CD 117). Which of the following additional findings are most likely present in this patient?

- A. Bacterial colonization of the stomach
- B. Gastric atrophy
- C. Gastric hypersecretion
- D. Gastric hypomotility
- E. Pancreatic endocrine tumor
- F. Pernicious anemia

Submit

https://t.me/USMLEWorldStep1

A 43-year-old man comes to the office with a several-month history of fatigue, rash, flushing, and abdominal cramps. His rash is worse with rubbing or scratching, and he has diffuse itching after hot showers. The patient is frequently dizzy and light-headed after prolonged standing and had an episode of syncope while working in the hot sun. He used to be healthy and physically active but has had to reduce his normal activity. The patient does not use tobacco, alcohol, or illicit drugs. Vital signs are normal. Skin examination shows a maculopapular rash. Skin biopsy shows large clusters of mast cells that are positive for KIT (CD 117). Which of the following additional findings are most likely present in this patient?

- A. Bacterial colonization of the stomach (3%)
- ✗ B. Gastric atrophy (8%)
- ✓ C. Gastric hypersecretion (32%)
- D. Gastric hypomotility (8%)
- E. Pancreatic endocrine tumor (33%)
- F. Pernicious anemia (14%)

Incorrect
Correct answer
C

32%
Answered correctly

02 mins, 48 secs
Time Spent

2023
Version

Explanation

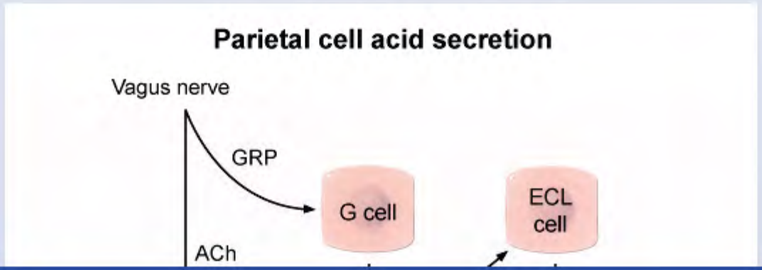

https://t.me/USMLEWorldStep1

A 43-year-old man comes to the office with a several-month history of fatigue, rash, flushing, and abdominal cramp
freque
sun. H
use to
biopsy
finding

Exhibit Display

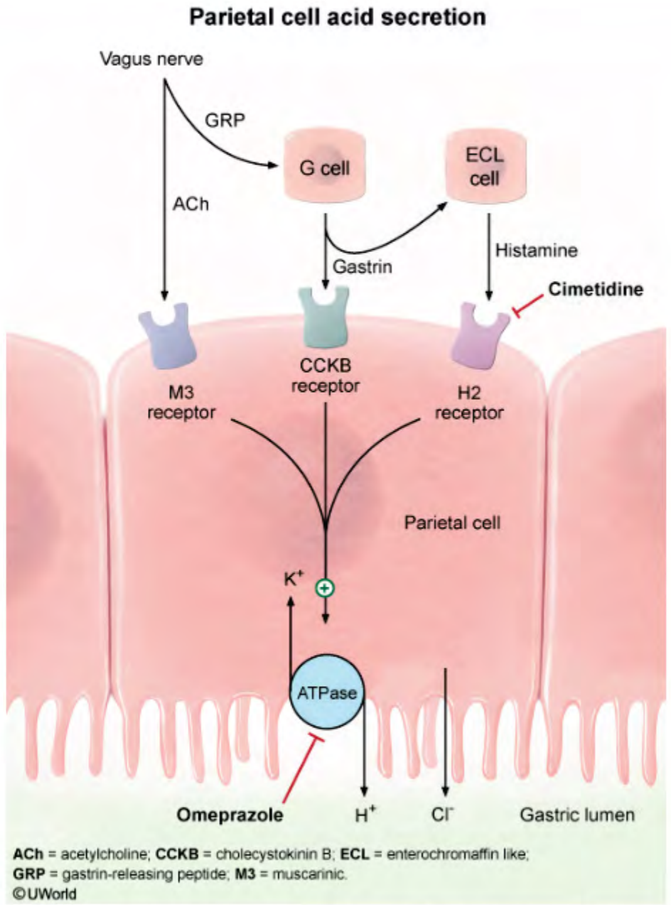

Zoom In | Zoom Out | Reset | New | Existing | My Notebook

https://t.me/USMLEWorldStep1

©UWorld

Gastric acid secretion by parietal cells in the fundus and body of the stomach is stimulated by:

1. **Histamine** binds H_2 receptors and increases intracellular cyclic AMP (cAMP) concentration.
2. **Acetylcholine** binds M_3 muscarinic receptors and leads to an increase in intracellular calcium.
3. **Gastrin** binds to the cholecystokinin B receptor and increases the intracellular calcium concentration. It also stimulates histamine synthesis and release by enterochromaffin-like cells in the stomach.

Intracellular calcium and cAMP activate protein kinases and lead to increased transport of H^+ by H^+/K^+ ATPase into the gastric lumen.

In **systemic mastocytosis**, clonal mast cell proliferation occurs in the bone marrow, skin, and other organs. Mast cell proliferation often is associated with mutations in the **KIT** receptor tyrosine kinase. These cells are characterized by prominent expression of mast cell tryptase. Excessive **histamine** release from degranulation of mast cells mediates many of the symptoms of the disease, such as syncope, flushing, hypotension, pruritus, and urticaria. In addition, histamine induces gastric acid secretion, which can lead to gastric ulceration. The excess acid also inactivates pancreatic and intestinal enzymes, causing diarrhea. Other gastrointestinal symptoms include nausea, vomiting, and abdominal cramps.

(Choices A, B, and F) Gastric mucosal atrophy often results from colonization with *Helicobacter pylori*. It can also be caused by autoimmune gastritis, which may lead to pernicious anemia due to loss of intrinsic factor from parietal cells. Symptoms of atrophic gastritis may include nausea, indigestion, and epigastric discomfort, but this patient's skin symptoms are more consistent with mastocytosis.

(Choice D) Gastric hypomotility (gastroparesis) occurs with diabetes mellitus, uremia, hypothyroidism, and other metabolic disorders. Gastroparesis causes constipation, early satiety, and food stasis with vomiting.

(Choice E) Pancreatic endocrine tumors may secrete gastrin (Zollinger-Ellison syndrome), insulin (hypoglycemia), glucagon (hyperglycemia, rash), somatostatin (diarrhea, cholelithiasis, hyperglycemia), or vasoactive intestinal peptide (watery diarrhea, hypokalemia, achlorhydria). These disorders would not be associated with excess mast cells in the skin.

Educational objective:

https://t.me/USMLEWorldStep1

2. **Acetylcholine** binds M_3 muscarinic receptors and leads to an increase in intracellular calcium.
3. **Gastrin** binds to the cholecystokinin B receptor and increases the intracellular calcium concentration. It also stimulates histamine synthesis and release by enterochromaffin-like cells in the stomach.

Intracellular calcium and cAMP activate protein kinases and lead to increased transport of H^+ by H^+/K^+ ATPase into the gastric lumen.

In **systemic mastocytosis**, clonal mast cell proliferation occurs in the bone marrow, skin, and other organs. Mast cell proliferation often is associated with mutations in the **KIT** receptor tyrosine kinase. These cells are characterized by prominent expression of mast cell tryptase. Excessive **histamine** release from degranulation of mast cells mediates many of the symptoms of the disease, such as syncope, flushing, hypotension, pruritus, and urticaria. In addition, histamine induces gastric acid secretion, which can lead to gastric ulceration. The excess acid also inactivates pancreatic and intestinal enzymes, causing diarrhea. Other gastrointestinal symptoms include nausea, vomiting, and abdominal cramps.

(Choices A, B, and F) Gastric mucosal atrophy often results from colonization with *Helicobacter pylori*. It can also be caused by autoimmune gastritis, which may lead to pernicious anemia due to loss of intrinsic factor from parietal cells. Symptoms of atrophic gastritis may include nausea, indigestion, and epigastric discomfort, but this patient's skin symptoms are more consistent with mastocytosis.

(Choice D) Gastric hypomotility (gastroparesis) occurs with diabetes mellitus, uremia, hypothyroidism, and other metabolic disorders. Gastroparesis causes constipation, early satiety, and food stasis with vomiting.

(Choice E) Pancreatic endocrine tumors may secrete gastrin (Zollinger-Ellison syndrome), insulin (hypoglycemia), glucagon (hyperglycemia, rash), somatostatin (diarrhea, cholelithiasis, hyperglycemia), or vasoactive intestinal peptide (watery diarrhea, hypokalemia, achlorhydria). These disorders would not be associated with excess mast cells in the skin.

Educational objective:
Systemic mastocytosis is characterized by the abnormal proliferation of mast cells and increased histamine release. Histamine causes hypersecretion of gastric acid by parietal cells in the stomach as well as a variety of other symptoms (eg, hypotension, flushing, pruritus).

https://t.me/USMLEWorldStep1

A 23-year-old man is hospitalized with acute pancreatitis that resolves rapidly on fasting. He has suffered 2 similar episodes during the past 2 years. A gallbladder ultrasound obtained during a previous episode was normal. The patient has no other medical problems and takes no medications. He does not consume alcohol. Which of the following tests should be considered during the workup of this patient?

- A. Serum ceruloplasmin
- B. Serum cholesterol
- C. Serum ferritin
- D. Serum triglycerides
- E. Serum uric acid
- F. Urine oxalate

Submit

https://t.me/USMLEWorldStep1

A 23-year-old man is hospitalized with acute pancreatitis that resolves rapidly on fasting. He has suffered 2 similar episodes during the past 2 years. A gallbladder ultrasound obtained during a previous episode was normal. The patient has no other medical problems and takes no medications. He does not consume alcohol. Which of the following tests should be considered during the workup of this patient?

- A. Serum ceruloplasmin (8%)
- ✗ B. Serum cholesterol (15%)
- C. Serum ferritin (5%)
- ✓ D. Serum triglycerides (64%)
- E. Serum uric acid (2%)
- F. Urine oxalate (4%)

Incorrect
Correct answer
D

64%
Answered correctly

06 secs
Time Spent

2023
Version

Explanation

Gallstones and alcohol use are the most common causes of **acute pancreatitis**. Gallstones typically affect middle-aged and older patients (particularly women) unless there is a predisposing condition (eg, young patients with sickle cell disease are at increased risk for bilirubin gallstones). This young male patient does not consume **alcohol** and is unlikely to have **gallstones**, especially considering the negative results of his prior ultrasound. Thus, one of the following **less common causes** of acute pancreatitis likely accounts for his condition:

1. Recent endoscopic retrograde cholangiopancreatography (ERCP) procedure
2. Drugs (eg, azathioprine, sulfasalazine, furosemide, valproic acid)
3. Infections (eg, mumps, Coxsackie virus, *Mycoplasma pneumoniae*)
4. **Hypertriglyceridemia**

https://t.me/USMLEWorldStep1

A 23-year-old man is hospitalized with acute pancreatitis that resolves rapidly on fasting. He has suffered 2 similar episodes during the past 2 years. A gallbladder ultrasound obtained during a previous episode was normal. The patient has no other medical problems and takes no medications. He does not consume alcohol. Which of the following tests should be considered during the workup of this patient?

- A. Serum ceruloplasmin (8%)
- ✗ B. Serum cholesterol (15%)
- C. Serum ferritin (5%)
- ✓ D. Serum triglycerides (64%)
- E. Serum uric acid (2%)
- F. Urine oxalate (4%)

Incorrect
Correct answer
D

64%
Answered correctly

06 secs
Time Spent

2023
Version

Explanation

Gallstones and alcohol use are the most common causes of **acute pancreatitis**. Gallstones typically affect middle-aged and older patients (particularly women) unless there is a predisposing condition (eg, young patients with sickle cell disease are at increased risk for bilirubin gallstones). This young male patient does not consume **alcohol** and is unlikely to have **gallstones**, especially considering the negative results of his prior ultrasound. Thus, one of the following **less common causes** of acute pancreatitis likely accounts for his condition:

1. Recent endoscopic retrograde cholangiopancreatography (ERCP) procedure
2. Drugs (eg, azathioprine, sulfasalazine, furosemide, valproic acid)
3. Infections (eg, mumps, Coxsackie virus, *Mycoplasma pneumoniae*)
4. **Hypertriglyceridemia**

https://t.me/USMLEWorldStep1

Explanation

Gallstones and alcohol use are the most common causes of **acute pancreatitis**. Gallstones typically affect middle-aged and older patients (particularly women) unless there is a predisposing condition (eg, young patients with sickle cell disease are at increased risk for bilirubin gallstones). This young male patient does not consume **alcohol** and is unlikely to have **gallstones**, especially considering the negative results of his prior ultrasound. Thus, one of the following **less common causes** of acute pancreatitis likely accounts for his condition:

1. Recent endoscopic retrograde cholangiopancreatography (ERCP) procedure
2. Drugs (eg, azathioprine, sulfasalazine, furosemide, valproic acid)
3. Infections (eg, mumps, Coxsackie virus, *Mycoplasma pneumoniae*)
4. **Hypertriglyceridemia**
5. Structural abnormalities of the pancreatic duct (strictures, cancer, pancreas divisum) or of the ampullary region (choledochal cyst, stenosis of sphincter of Oddi)
6. Surgery (particularly of the stomach and biliary tract and after cardiac surgery)
7. Hypercalcemia

High levels of circulating triglycerides lead to increased production of free fatty acids within the pancreatic capillaries by pancreatic lipase. Normally, fatty acids exist in serum bound to albumin. However, if serum **triglyceride levels rise to >1000 mg/dL**, the concentration of free fatty acids exceeds the binding capacity of albumin and leads to direct injury to the pancreatic acinar cells. Thus, hypertriglyceridemia causes acute pancreatitis via direct tissue toxicity.

(Choice A) Decreased serum ceruloplasmin and increased hepatic copper content are diagnostic of Wilson disease. Cirrhosis, central nervous system involvement, and Kayser-Fleischer rings are characteristic findings. Wilson disease does not predispose to acute pancreatitis.

(Choice B) Increased serum cholesterol levels predispose to the development of systemic atherosclerosis, putting patients at increased risk for coronary artery disease, peripheral vascular disease, and stroke. In some cases, hypercholesterolemia may increase the risk of cholesterol gallstone formation, but this patient's negative

https://t.me/USMLEWorldStep1

High levels of circulating triglycerides lead to increased production of free fatty acids within the pancreatic capillaries by pancreatic lipase. Normally, fatty acids exist in serum bound to albumin. However, if serum **triglyceride levels rise to >1000 mg/dL**, the concentration of free fatty acids exceeds the binding capacity of albumin and leads to direct injury to the pancreatic acinar cells. Thus, hypertriglyceridemia causes acute pancreatitis via direct tissue toxicity.

(Choice A) Decreased serum ceruloplasmin and increased hepatic copper content are diagnostic of Wilson disease. Cirrhosis, central nervous system involvement, and Kayser-Fleischer rings are characteristic findings. Wilson disease does not predispose to acute pancreatitis.

(Choice B) Increased serum cholesterol levels predispose to the development of systemic atherosclerosis, putting patients at increased risk for coronary artery disease, peripheral vascular disease, and stroke. In some cases, hypercholesterolemia may increase the risk of cholesterol gallstone formation, but this patient's negative gallbladder ultrasound makes this a less likely cause of his pancreatitis.

(Choice C) High concentrations of serum ferritin are found in hemochromatosis. Hemochromatosis can cause cirrhosis, pancreatic fibrosis and subsequent diabetes, cardiomyopathy, and secondary hypogonadism. It does not cause acute pancreatitis.

(Choice E) Hyperuricemia can lead to the formation of uric acid renal calculi and urate nephropathy. There is no association with acute pancreatitis.

(Choice F) Increased concentrations of oxalate in the urine are associated with intestinal malabsorption syndromes (eg, Crohn disease). Calcium oxalate renal stones may form as a result. Hyperoxaluria is not associated with acute pancreatitis.

Educational objective:
Eighty percent of acute pancreatitis cases are caused by gallstones and chronic alcoholism. Less common causes account for the other 20%. Inherited or acquired hypertriglyceridemia can cause acute pancreatitis if the serum level of triglycerides exceeds 1000 mg/dL.

Pathology	Gastrointestinal & Nutrition	Acute pancreatitis
Subject	System	Topic

https://t.me/USMLEWorldStep1

A 32-year-old man comes to the clinic due to several months of fatigue and weight loss. The patient has no significant medical history. He drinks 1 or 2 alcoholic beverages daily and has used intravenous recreational drugs in the past. He is sexually active with his girlfriend. The patient has a maternal aunt with hypothyroidism, but his family history is otherwise unremarkable. Temperature is 36.7 C (98 F), blood pressure is 110/70 mm Hg, pulse is 65/min, and respirations are 18/min. Physical examination is normal. A liver biopsy is obtained, and light microscopy reveals large hepatocytes filled with finely granular, homogeneous, pale pink cytoplasm. Which of the following is the most likely diagnosis?

- A. Alcohol-induced steatohepatitis
- B. Hemochromatosis
- C. Hepatitis B infection
- D. Hepatitis C infection
- E. Nonalcoholic steatohepatitis

Submit

https://t.me/USMLEWorldStep1

A 32-year-old man comes to the clinic due to several months of fatigue and weight loss. The patient has no significant medical history. He drinks 1 or 2 alcoholic beverages daily and has used intravenous recreational drugs in the past. He is sexually active with his girlfriend. The patient has a maternal aunt with hypothyroidism, but his family history is otherwise unremarkable. Temperature is 36.7 C (98 F), blood pressure is 110/70 mm Hg, pulse is 65/min, and respirations are 18/min. Physical examination is normal. A liver biopsy is obtained, and light microscopy reveals large hepatocytes filled with finely granular, homogeneous, pale pink cytoplasm. Which of the following is the most likely diagnosis?

- A. Alcohol-induced steatohepatitis (22%)
- ✗ B. Hemochromatosis (3%)
- ✓ C. Hepatitis B infection (28%)
- D. Hepatitis C infection (35%)
- E. Nonalcoholic steatohepatitis (9%)

Incorrect
Correct answer
C

28%
Answered correctly

03 secs
Time Spent

2023
Version

Explanation

Hepatitis B infection, one of the most common causes of hepatic injury in the United States, is frequently transmitted sexually or via percutaneous inoculation (eg, intravenous drug use). A distinct histopathologic manifestation of chronic infection is the **accumulation of hepatitis B surface antigen** within infected hepatocytes. This results in the appearance of a finely granular, **homogeneous, pale eosinophilic cytoplasm** (ground-glass hepatocytes).

Other nonspecific morphologic changes include hepatocyte necrosis, apoptosis, steatosis, and mononuclear portal inflammation (lymphocytes, macrophages). Acidophil (Councilman) bodies, deeply eosinophilic globules that

https://t.me/USMLEWorldStep1

Hepatitis B infection, one of the most common causes of hepatic injury in the United States, is frequently transmitted sexually or via percutaneous inoculation (eg, intravenous drug use). A distinct histopathologic manifestation of chronic infection is the **accumulation of hepatitis B surface antigen** within infected hepatocytes. This results in the appearance of a finely granular, **homogeneous, pale eosinophilic cytoplasm** (ground-glass hepatocytes).

Other nonspecific morphologic changes include hepatocyte necrosis, apoptosis, steatosis, and mononuclear portal inflammation (lymphocytes, macrophages). Acidophil (Councilman) bodies, deeply eosinophilic globules that represent shrunken apoptotic hepatocytes, can be seen in a variety of liver diseases.

(Choices A and E) Hepatic steatosis is characterized by the accumulation of large and small vesicles of fat within hepatocytes. It can be due to significant alcohol ingestion (>15 drinks/week for men, >10 drinks/week for women) or obesity (nonalcoholic steatohepatitis). Mallory bodies may be seen in alcohol-induced steatohepatitis; they are characterized by clumped, amorphous, eosinophilic intracytoplasmic inclusions made up of tangled intermediate filaments.

(Choice B) Hemochromatosis is characterized by the deposition of iron in the liver, which appears as yellow-brown hemosiderin granules in the cytoplasm. Cirrhosis and portal hypertension can result if the condition is left untreated.

(Choice D) A liver infected with hepatitis C virus commonly has lymphoid aggregates within the portal tracts and focal areas of macrovesicular steatosis; however, ground-glass hepatocytes are more specific for hepatitis B infection.

Educational objective:
Hepatitis B infection causes the hepatocellular cytoplasm to fill with hepatitis B surface antigen. These inclusions are highly specific for hepatitis B infection and have a finely granular, pale eosinophilic, ground-glass appearance.

References

- Liver biopsy findings in chronic hepatitis B.

Pathology Gastrointestinal & Nutrition Hepatitis b

https://t.me/USMLEWorldStep1

Correct answer
C

Answered correctly

Time Spent

Version

Exhibit Display

Expl

Hepat
transm
manife
hepato
(groun

Other
inflam
repres

(Choi
hepato
or obe
charac
filamer

(Choi
brown
untrea

(Choi
focal a
infecti

Educa
Hepati

Chronic hepatitis B

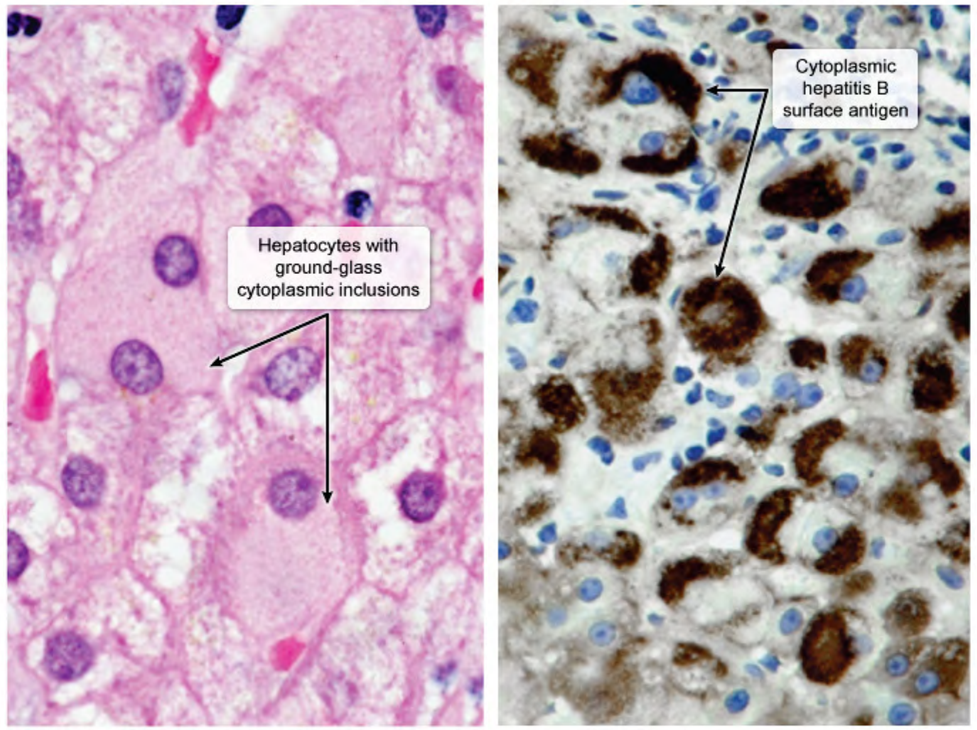

Hematoxylin & eosin stain

Hepatitis B surface antigen stain

©UWorld

Zoom In | Zoom Out | Reset | New | Existing | My Notebook

are highly specific for hepatitis B infection and have a finely granular, pale eosinophilic, ground-glass appearance.

https://t.me/USMLEWorldStep1

Correct answer
C

Answered correctly

Time Spent

Version

Exhibit Display

Expl

Hepat
transm
manife
hepato
(groun

Other
inflam
repres

(Choi
hepato
or obe
charac
filamer

(Choi
brown
untrea

(Choi
focal a
infecti

Educa
Hepati

Chronic hepatitis B

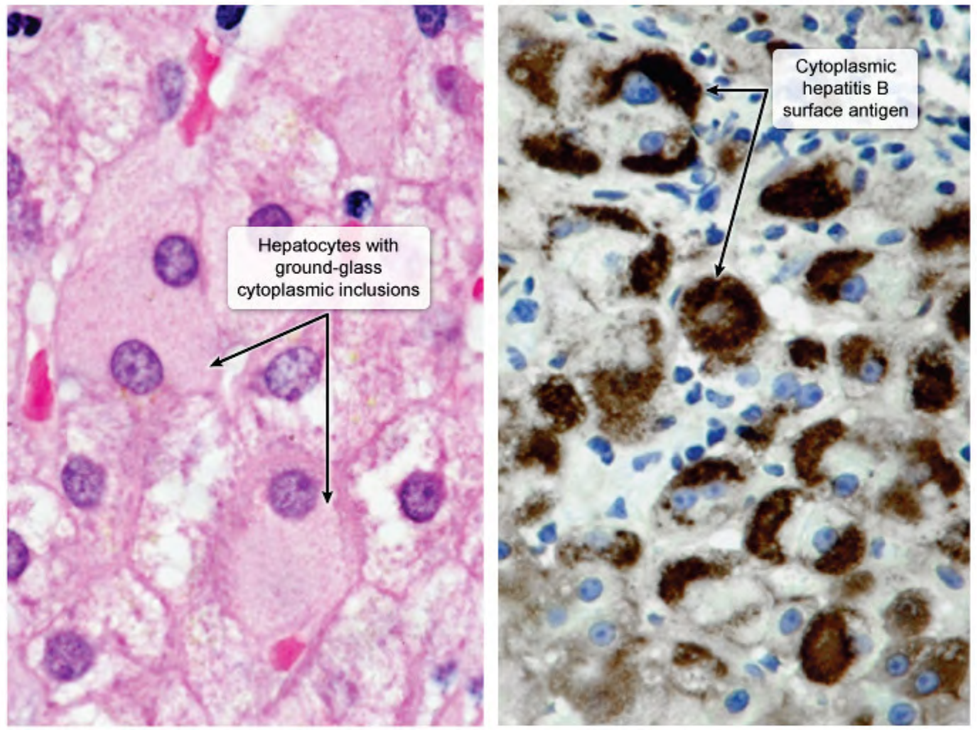

Hematoxylin & eosin stain

Hepatitis B surface antigen stain

©UWorld

Zoom In | Zoom Out | Reset | New | Existing | My Notebook

are highly specific for hepatitis B infection and have a finely granular, pale eosinophilic, ground-glass appearance.

https://t.me/USMLEWorldStep1

Correct answer
C

Answered correctly

Time Spent

Version

Exhibit Display

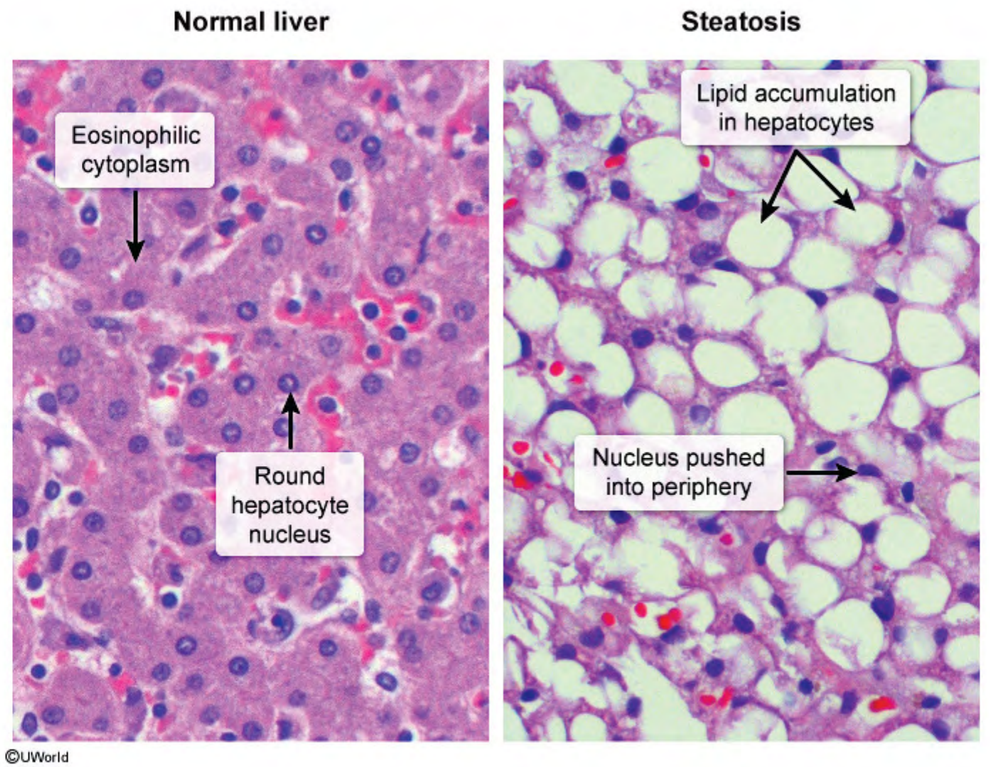

Zoom In Zoom Out Reset New | Existing My Notebook

Hepat
transm
manife
hepato
(groun

Other
inflam
repres

(Choi
hepato
or obe
charac
filamer

(Choi
brown
untrea

(Choi
focal a
infecti

Educa
Hepati
are highly specific for hepatitis B infection and have a finely granular, pale eosinophilic, ground-glass appearance.

https://t.me/USMLEWorldStep1

Correct answer
C

Answered correctly

Time Spent

Version

Exhibit Display

Mallory bodies

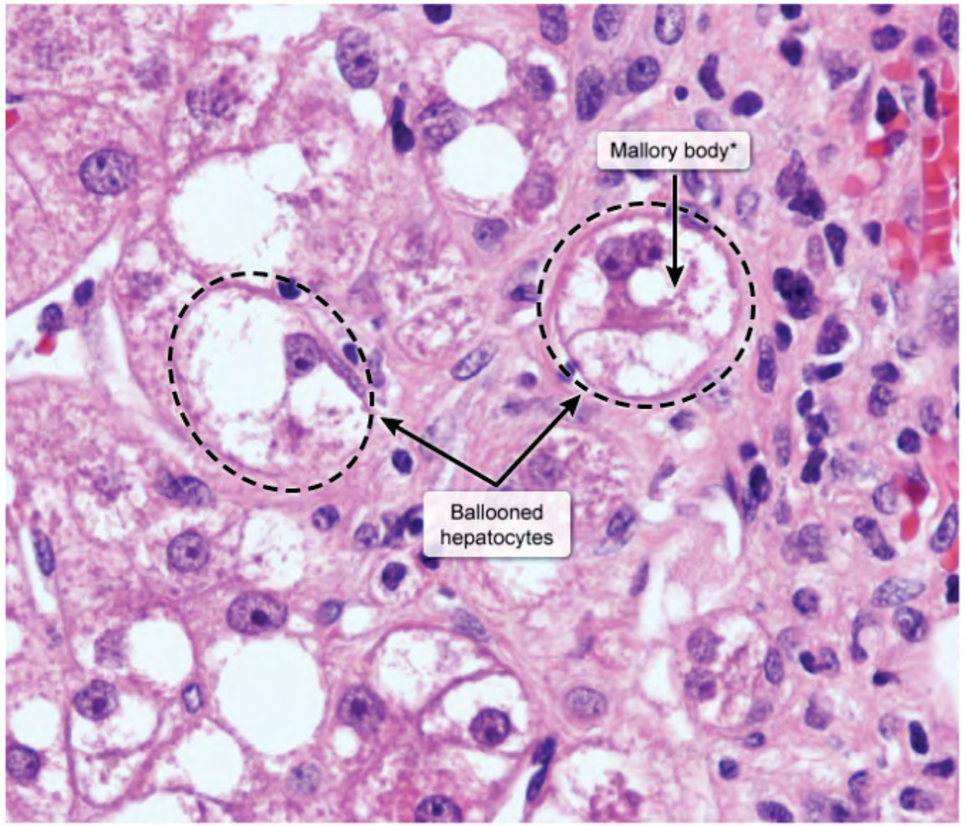

*Eosinophilic clumped intermediate filaments.

©UWorld

Zoom In | Zoom Out | Reset | New | Existing | My Notebook

Expl

Hepat
transm
manife
hepato
(groun

Other
inflam
repres

(Choi
hepato
or obe
charac
filamer

(Choi
brown
untrea

(Choi
focal a
infecti

Educa
Hepati

are highly specific for hepatitis B infection and have a finely granular, pale eosinophilic, ground-glass appearance.

https://t.me/USMLEWorldStep1

Correct answer
C

Answered correctly

Time Spent

Version

Exhibit Display

Expl

Hepat
transm
manife
hepato
(groun

Other
inflam
repres

(Choi
hepato
or obe
charac
filame

(Choi
brown
untrea

(Choi
focal a
infecti

Educa
Hepati
are highly specific for hepatitis B infection and have a finely granular, pale eosinophilic, ground-glass appearance.

Hemochromatosis

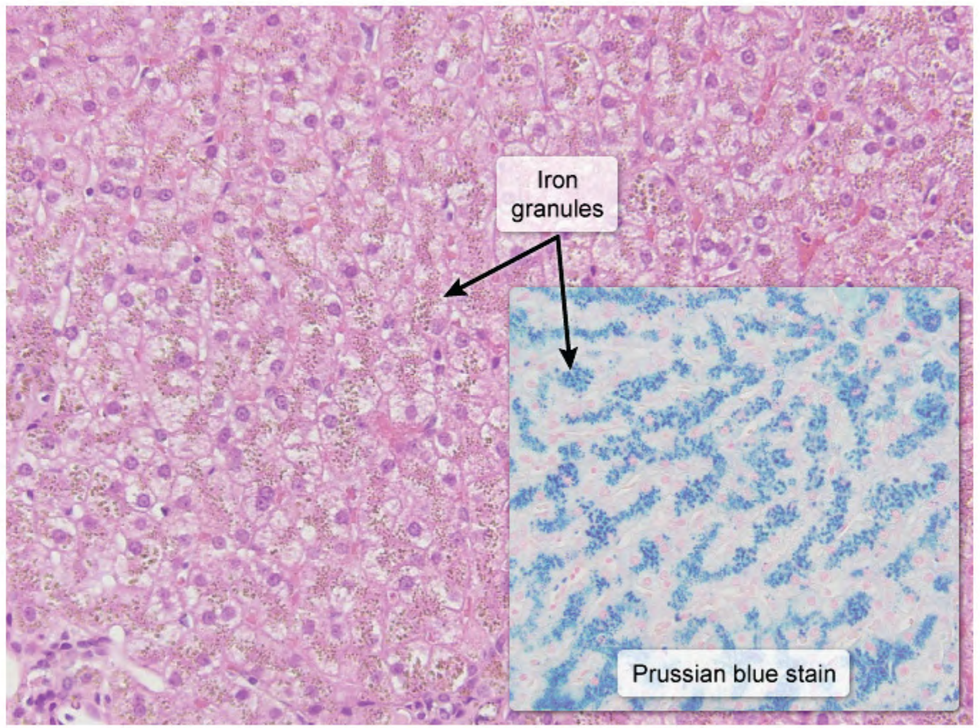

Liver

Zoom In
Zoom Out
Reset
New
Existing
My Notebook

https://t.me/USMLEWorldStep1

A 27-year-old woman undergoes laparotomy for right lower quadrant pain and is found to have an inflamed terminal ileum. The involved segment of the intestine is removed, and the lesion observed on light microscopy is seen in the image.

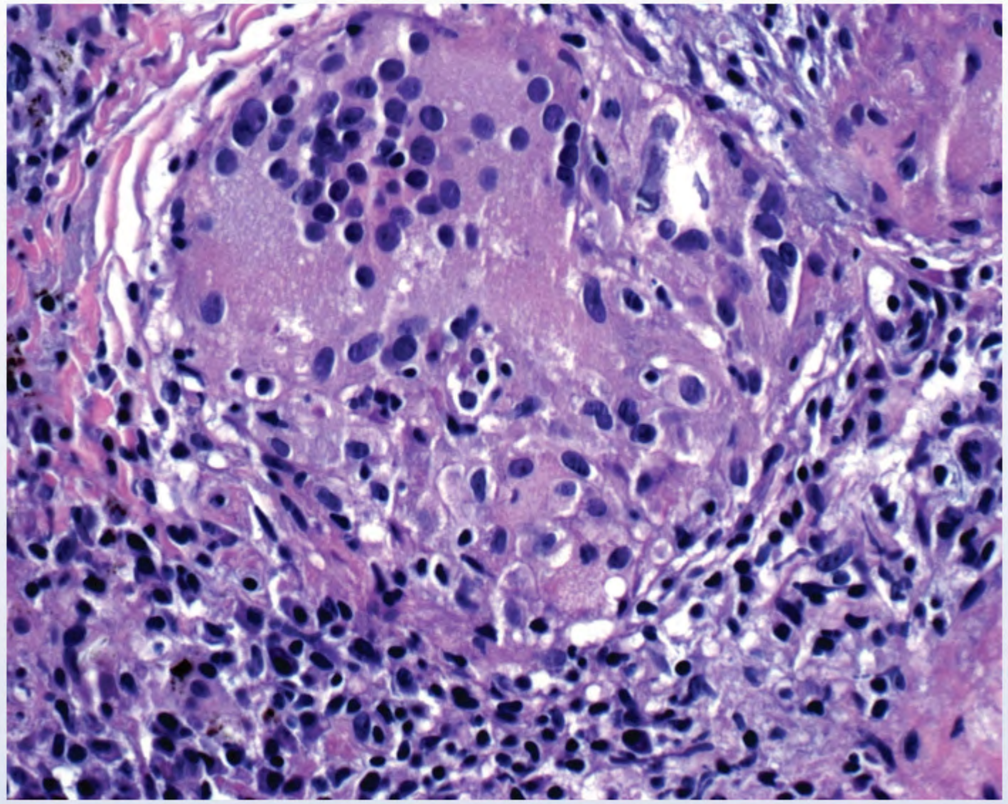

Which of the following cell types most likely mediated the formation of this patient's lesion?

- A. B-lymphocytes
- B. Eosinophils
- C. Neutrophils

https://t.me/USMLEWorldStep1

A 27-year-old woman undergoes laparotomy for right lower quadrant pain and is found to have an inflamed
termin
seen i

Exhibit Display

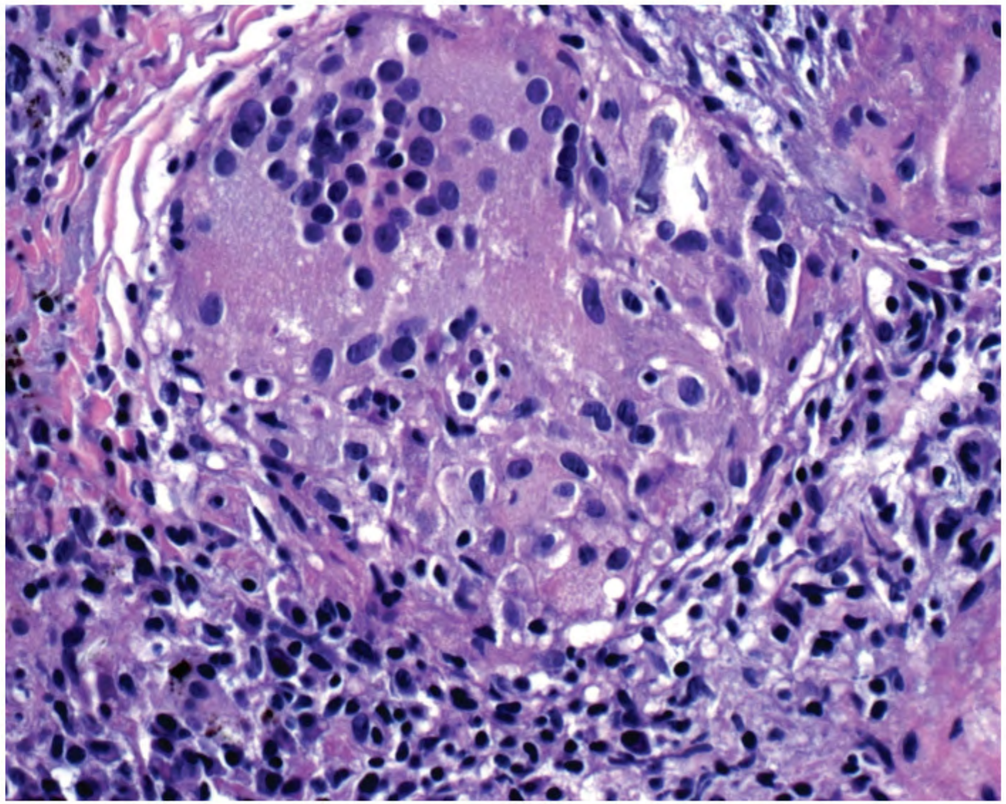

Zoom In | Zoom Out | Reset | New | Existing | My Notebook

Which

C. Neutrophils

https://t.me/USMLEWorldStep1

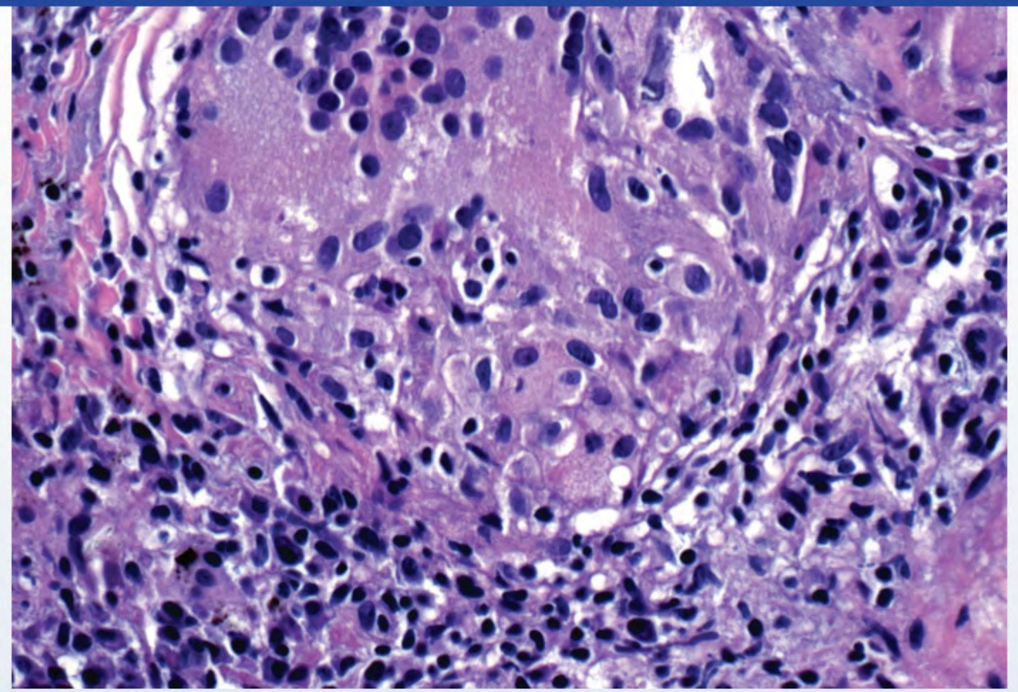

Which of the following cell types most likely mediated the formation of this patient's lesion?

- A. B-lymphocytes
- B. Eosinophils
- C. Neutrophils
- D. Natural killer cells
- E. Th1 cells
- F. Th2 cells

Submit

https://t.me/USMLEWorldStep1

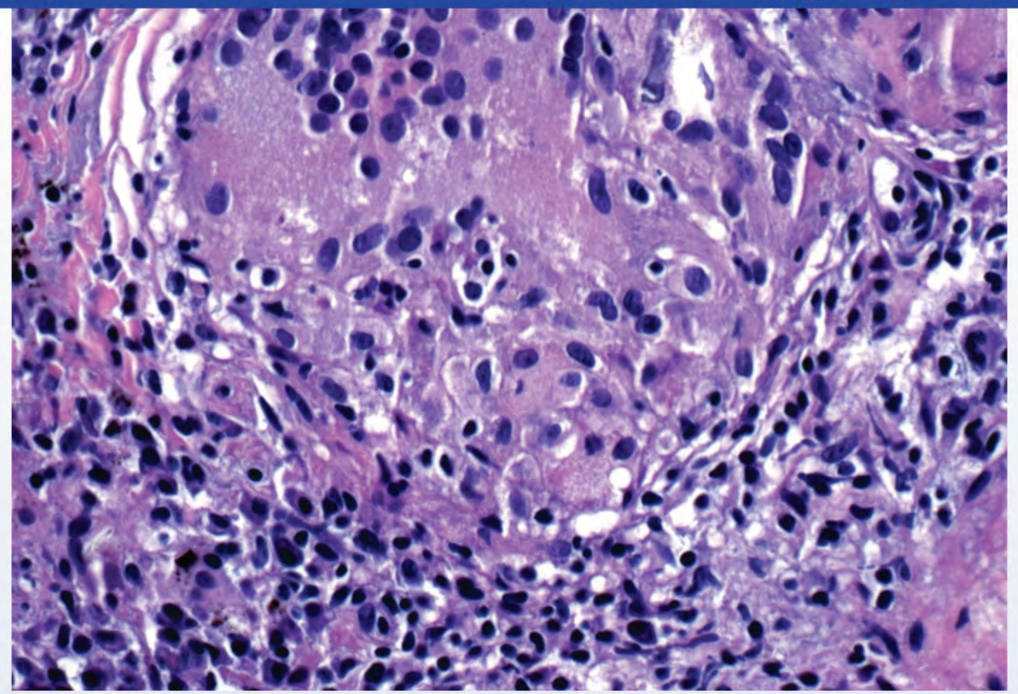

Which of the following cell types most likely mediated the formation of this patient's lesion?

- ✗ A. B-lymphocytes (8%)
- B. Eosinophils (1%)
- C. Neutrophils (8%)
- D. Natural killer cells (0%)
- ✓ E. Th1 cells (71%)
- F. Th2 cells (10%)

Incorrect
Correct answer
E

71%
Answered correctly

23 secs
Time Spent

2023
Version

https://t.me/USMLEWorldStep1

Incorrect
Correct answer
E

71%
Answered correctly

23 secs
Time Spent

2023
Version

Exhibit Display

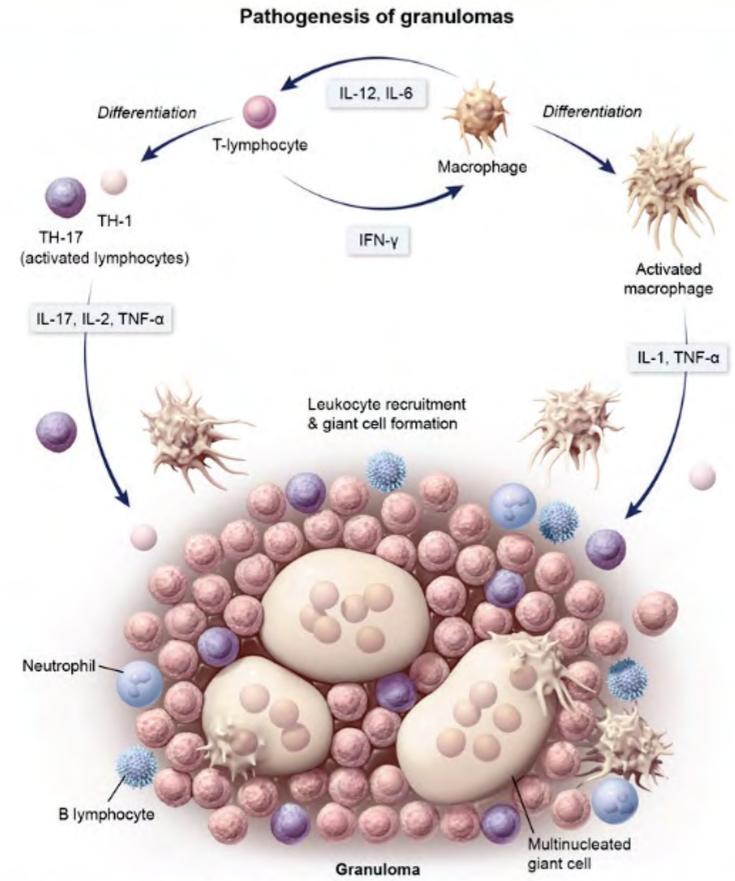

Zoom In | Zoom Out | Reset | New | Existing | My Notebook

https://t.me/USMLEWorldStep1

IFN = interferon; **TH** = T helper; **TNF** = tumor necrosis factor.

©UWorld

This patient has abdominal pain, ileal inflammation, and a noncaseating granuloma on biopsy, all of which are consistent with Crohn disease (CD). Noncaseating granulomas are seen only in a minority of patients with CD but, when present, are highly suggestive of the diagnosis. Microscopically, granulomas contain a large number of epithelioid macrophages that may fuse together to form multinucleated cells (Langhans giant cells), surrounded by a band of lymphocytes.

Granulomas are considered caseating or noncaseating:

- **Caseating**: Central necrosis is present and has a granular, cheesy appearance. Caseating granulomas are typically seen in infectious etiologies (eg, tuberculosis, leprosy, syphilis, cat scratch disease) due to cell death (both macrophage and bacterial) and the release of cellular contents.
- **Noncaseating**: No central necrosis is present. Noncaseating granulomas are typically seen in autoinflammatory conditions (eg, CD, sarcoidosis, common variable immune deficiency).

Granuloma formation is a product of chronic T-lymphocyte and macrophage activation in response to a difficult-to-eradicate antigen (eg, mycobacterium, self-antigens). Macrophages release tumor necrosis factor–alpha and other proinflammatory cytokines (eg, IL-6, IL-1, **IL-12**) that promote macrophage migration and **Th1 cell differentiation**. Th1 cells are thought to be important in granuloma organization; they produce IL-2 and **interferon-gamma**, which promote further T-cell response, **activation of macrophages**, and differentiation of macrophages into giant cells. Th17 cells are a proinflammatory subset of Th1 cells and contribute to the cell injury seen in CD.

(Choice A) B-lymphocytes differentiate into plasma cells and produce antibodies, thereby mediating the immune response to bacterial infection.

(Choice B) Eosinophils mediate defense reactions against certain parasites. They are also implicated in the pathogenesis of hypersensitivity reactions.

(Choice C) The main function of neutrophils is phagocytosis. They play an active role in nonspecific inflammatory processes.

(Choice D) Natural killer (NK) cells provide a nonspecific defense against virus-infected and tumor cells. They are not known to play a role in CD.

https://t.me/USMLEWorldStep1

(both macrophage and bacterial) and the release of cellular contents.

- **Noncaseating**: No central necrosis is present. Noncaseating granulomas are typically seen in autoinflammatory conditions (eg, CD, sarcoidosis, common variable immune deficiency).

Granuloma formation is a product of chronic T-lymphocyte and macrophage activation in response to a difficult-to-eradicate antigen (eg, mycobacterium, self-antigens). Macrophages release tumor necrosis factor–alpha and other proinflammatory cytokines (eg, IL-6, IL-1, **IL-12**) that promote macrophage migration and **Th1 cell differentiation**. Th1 cells are thought to be important in granuloma organization; they produce IL-2 and **interferon-gamma**, which promote further T-cell response, **activation of macrophages**, and differentiation of macrophages into giant cells. Th17 cells are a proinflammatory subset of Th1 cells and contribute to the cell injury seen in CD.

(Choice A) B-lymphocytes differentiate into plasma cells and produce antibodies, thereby mediating the immune response to bacterial infection.

(Choice B) Eosinophils mediate defense reactions against certain parasites. They are also implicated in the pathogenesis of hypersensitivity reactions.

(Choice C) The main function of neutrophils is phagocytosis. They play an active role in nonspecific inflammatory processes.

(Choice D) Natural killer (NK) cells provide a nonspecific defense against virus-infected and tumor cells. They are not known to play a role in CD.

(Choice F) Th2 cells are involved in the pathogenesis of ulcerative colitis. They produce IL-5 and IL-13, which contribute to inflammation and damage of the intestinal mucosa.

Educational objective:
Granulomas are characterized by a large number of epithelioid macrophages that may fuse together to form multinucleated cells (Langhans giant cells) surrounded by a band of lymphocytes. Granuloma formation involves chronic Th1 and macrophage activation in response to a difficult-to-eradicate antigen.

Pathology	Gastrointestinal & Nutrition	Inflammatory bowel disease
Subject	System	Topic

https://t.me/USMLEWorldStep1

B lymphocyte

Exhibit Display

Noncaseating granuloma

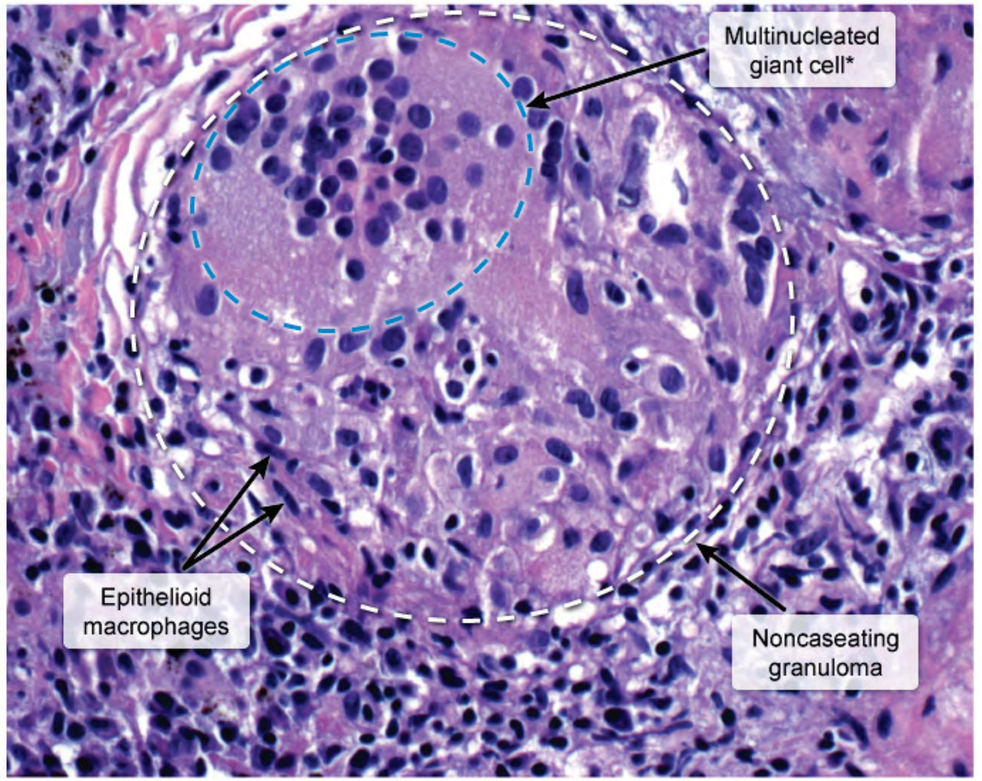

* Formed by fusion of epithelioid macrophages

©UWorld

Zoom In | Zoom Out | Reset | New | Existing | My Notebook

This p
consis
when
epithe
a banc

Granu

- **C**
  ty
  (b
- **N**
  a

Granu
eradic
proinfl
Th1 ce
promo
Th17 c

(Choi
respor

(Choi
pathog

(Choice C) The main function of neutrophils is phagocytosis. They play an active role in nonspecific inflammatory

https://t.me/USMLEWorldStep1

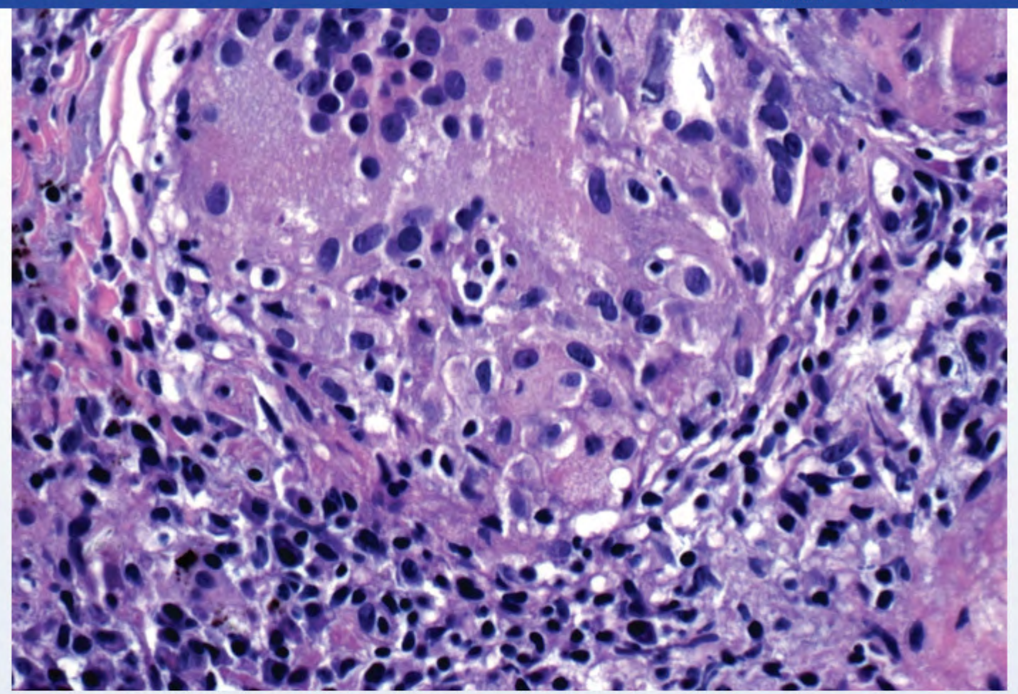

Which of the following cell types most likely mediated the formation of this patient's lesion?

- ✗ A. B-lymphocytes (8%)
- B. Eosinophils (1%)
- C. Neutrophils (8%)
- D. Natural killer cells (0%)
- ✓ E. Th1 cells (71%)
- F. Th2 cells (10%)

Incorrect
Correct answer
E

71%
Answered correctly

23 secs
Time Spent

2023
Version

https://t.me/USMLEWorldStep1

A 45-year-old woman comes to the hospital due to a weeklong history of right upper quadrant pain, anorexia, jaundice, and dark urine. She has not recently traveled outside of the United States. The patient has no chronic medical conditions and takes no medications. She usually drinks 2 or 3 beers a day but has been drinking 8-10 beers daily for the past 6 months. The patient does not use intravenous drugs and is not sexually active. Family history is unremarkable. Temperature is 38.1 C (100.6 F), blood pressure is 122/74 mm Hg, pulse is 98/min and regular, and respirations are 15/min. BMI is 24 kg/m^2. The patient is jaundiced but in no apparent distress. She is oriented to person, place, and date. The liver is enlarged and tender to palpation. There is no splenomegaly. The remainder of the physical examination shows no abnormalities. Laboratory results are as follows:

Liver function studies	
Total bilirubin	10.3 mg/dL
Direct bilirubin	8.2 mg/dL
Alkaline phosphatase	90 U/L
Aspartate aminotransferase (SGOT)	193 U/L
Alanine aminotransferase (SGPT)	62 U/L

If a liver biopsy is performed, which of the following pathologic findings would most likely be identified in this patient?

- A. Granulomatous destruction of interlobular bile ducts
- B. Ground-glass hepatocyte inclusions containing viral antigen
- C. Marked intrahepatic neutrophil infiltration
- D. Portal tract–predominant lymphocytic infiltration

Submit

https://t.me/USMLEWorldStep1

A 45-year-old woman comes to the hospital due to a weeklong history of right upper quadrant pain, anorexia, jaundice, and dark urine. She has not recently traveled outside of the United States. The patient has no chronic medical conditions and takes no medications. She usually drinks 2 or 3 beers a day but has been drinking 8-10 beers daily for the past 6 months. The patient does not use intravenous drugs and is not sexually active. Family history is unremarkable. Temperature is 38.1 C (100.6 F), blood pressure is 122/74 mm Hg, pulse is 98/min and regular, and respirations are 15/min. BMI is 24 kg/m^2. The patient is jaundiced but in no apparent distress. She is oriented to person, place, and date. The liver is enlarged and tender to palpation. There is no splenomegaly. The remainder of the physical examination shows no abnormalities. Laboratory results are as follows:

Liver function studies	
Total bilirubin	10.3 mg/dL
Direct bilirubin	8.2 mg/dL
Alkaline phosphatase	90 U/L
Aspartate aminotransferase (SGOT)	193 U/L
Alanine aminotransferase (SGPT)	62 U/L

If a liver biopsy is performed, which of the following pathologic findings would most likely be identified in this patient?

- ✗ A. Granulomatous destruction of interlobular bile ducts (24%)
- B. Ground-glass hepatocyte inclusions containing viral antigen (5%)
- ✓ C. Marked intrahepatic neutrophil infiltration (43%)
- D. Portal tract–predominant lymphocytic infiltration (25%)

Incorrect
Correct answer
C

43%
Answered correctly

04 secs
Time Spent

2023
Version

https://t.me/USMLEWorldStep1

Alcoholic hepatitis	
Pathophysiology	• Heavy ethanol consumption → intrahepatic oxidative damage → recruitment of neutrophils to the liver
Symptoms	• Fever • Right upper quadrant pain • Jaundice
Histology	• Marked intrahepatic neutrophilic infiltration • Hepatocellular ballooning • Mallory-Denk bodies • Steatosis
Laboratory studies	• Aminotransferase elevations with AST/ALT ratio >2:1 • Direct hyperbilirubinemia • Leukocytosis • PT & PTT elevations (impaired hepatic production of coagulation factors)
ALT = alanine aminotransferase; **AST** = aspartate aminotransferase.	

This patient's fever, right upper quadrant pain, jaundice, and elevated transaminases likely represent **alcoholic hepatitis**. Heavy ethanol consumption causes oxidative damage in the liver, which triggers the release of neutrophil chemotactic factors (eg, **IL-8**, **leukotriene B_4**), leading to marked **intrahepatic neutrophil infiltration**. Other histologic findings include hepatocellular ballooning, Mallory bodies, and steatosis.

Laboratory testing in alcoholic hepatitis typically demonstrates elevated aminotransferases (eg, aspartate aminotransferase [AST], alanine aminotransferase [ALT]) with an **AST/ALT ratio >2:1**. The disproportionate elevation of AST relative to ALT is caused by deficiencies in pyridoxal phosphate (ALT is more sensitive to vitamin B_6 deficiency than AST) and ethanol-induced **mitochondrial damage** (in hepatocytes, large amounts of AST are found in the mitochondria whereas ALT is present only in the cytosol).

https://t.me/USMLEWorldStep1

	• PT & PTT elevations (impaired hepatic production of coagulation factors)
ALT = alanine aminotransferase; **AST** = aspartate aminotransferase.	

This patient's fever, right upper quadrant pain, jaundice, and elevated transaminases likely represent **alcoholic hepatitis**. Heavy ethanol consumption causes oxidative damage in the liver, which triggers the release of neutrophil chemotactic factors (eg, **IL-8**, **leukotriene B_4**), leading to marked **intrahepatic neutrophil infiltration**. Other histologic findings include hepatocellular ballooning, Mallory bodies, and steatosis.

Laboratory testing in alcoholic hepatitis typically demonstrates elevated aminotransferases (eg, aspartate aminotransferase [AST], alanine aminotransferase [ALT]) with an **AST/ALT ratio >2:1**. The disproportionate elevation of AST relative to ALT is caused by deficiencies in pyridoxal phosphate (ALT is more sensitive to vitamin B_6 deficiency than AST) and ethanol-induced **mitochondrial damage** (in hepatocytes, large amounts of AST are found in the mitochondria whereas ALT is present only in the cytosol).

Additional laboratory findings in alcoholic hepatitis include leukocytosis and **direct hyperbilirubinemia**. PT and PTT are often prolonged due to impaired hepatic production of coagulation factors.

(Choice A) Primary biliary cholangitis (PBC) is a chronic inflammatory bile duct disorder. Histopathology shows inflammation and destruction of interlobular bile ducts with occasional granulomatous lesions. This cholestatic disorder causes not only hyperbilirubinemia, but also elevated alkaline phosphatase, which is not present in this patient. Furthermore, PBC does not cause an AST/ALT ratio >2:1.

(Choices B and D) Chronic hepatitis B and C infections can stimulate an immune response against infected hepatocytes characterized by portal tract–predominant lymphocytic infiltration. Ground-glass hepatocytes may also be seen in chronic hepatitis B, representing an intracytoplasmic accumulation of hepatitis B surface antigen. Although chronic viral hepatitis may cause direct hyperbilirubinemia and aminotransferase elevations, ALT is generally higher than AST and an AST/ALT ratio >2:1 is rare.

Educational objective:
Alcoholic hepatitis presents with fever, right upper quadrant pain, and jaundice. Typical laboratory findings include elevated aminotransferases with an AST/ALT ratio >2:1. Histopathology is characterized by marked intrahepatic neutrophil infiltration, hepatocellular ballooning, Mallory bodies, and steatosis.

https://t.me/USMLEWorldStep1

	• PT & PTT elevations (impaired hepatic production of coagulation factors)
AL	

Exhibit Display

Alcoholic hepatitis

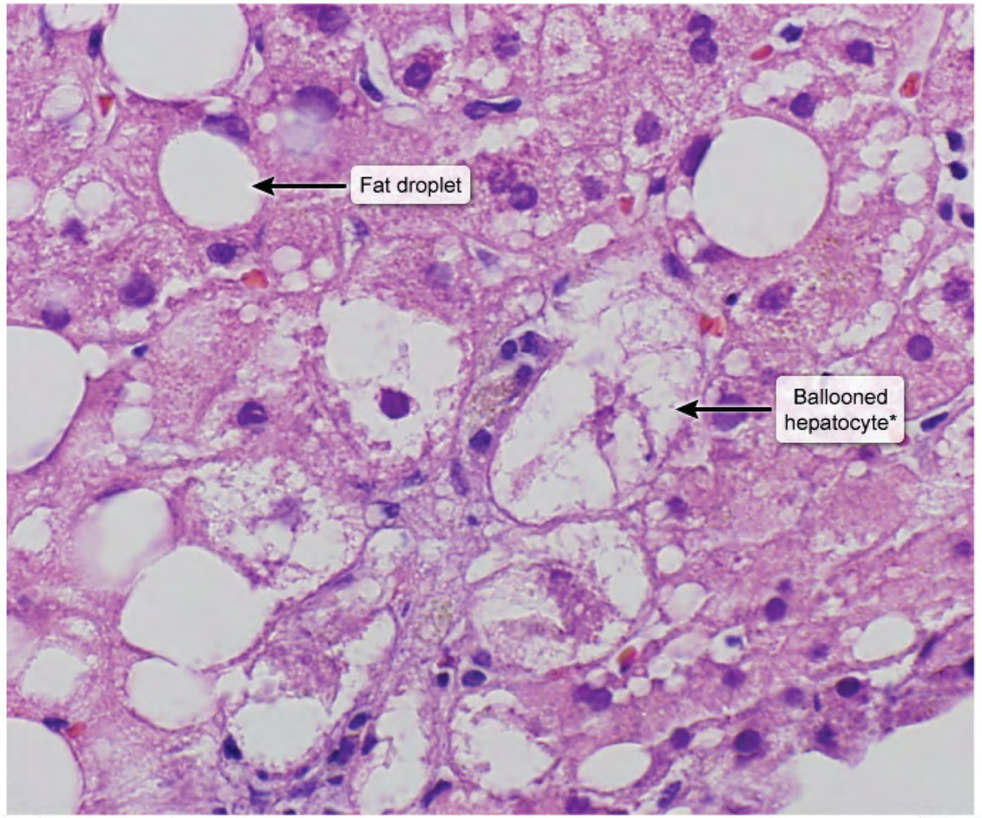

*Swollen cell with cytoplasmic clearing

©UWorld

Zoom In | Zoom Out | Reset | New | Existing | My Notebook

This p
hepati
neutro
Other

Labora
amino
elevati
B_6 defi
found

Additi
PTT a

(Choi
inflam
disord
patien

(Choi
hepato
also b
Althou
genera

Educa
Alcoho
elevat

neutrophil infiltration, hepatocellular ballooning, Mallory bodies, and steatosis.

https://t.me/USMLEWorldStep1

- PT & PTT elevations (impaired hepatic production of coagulation factors)

AL

Exhibit Display

This p
hepat
neutro
Other

Labora
amino
elevati
B_6 defi
found

Additi
PTT a

(Choi
inflam
disord
patien

(Choi
hepat
also b
Althou
genera

Educa
Alcoho
elevat

neutrophil infiltration, hepatocellular ballooning, Mallory bodies, and steatosis.

Mallory bodies

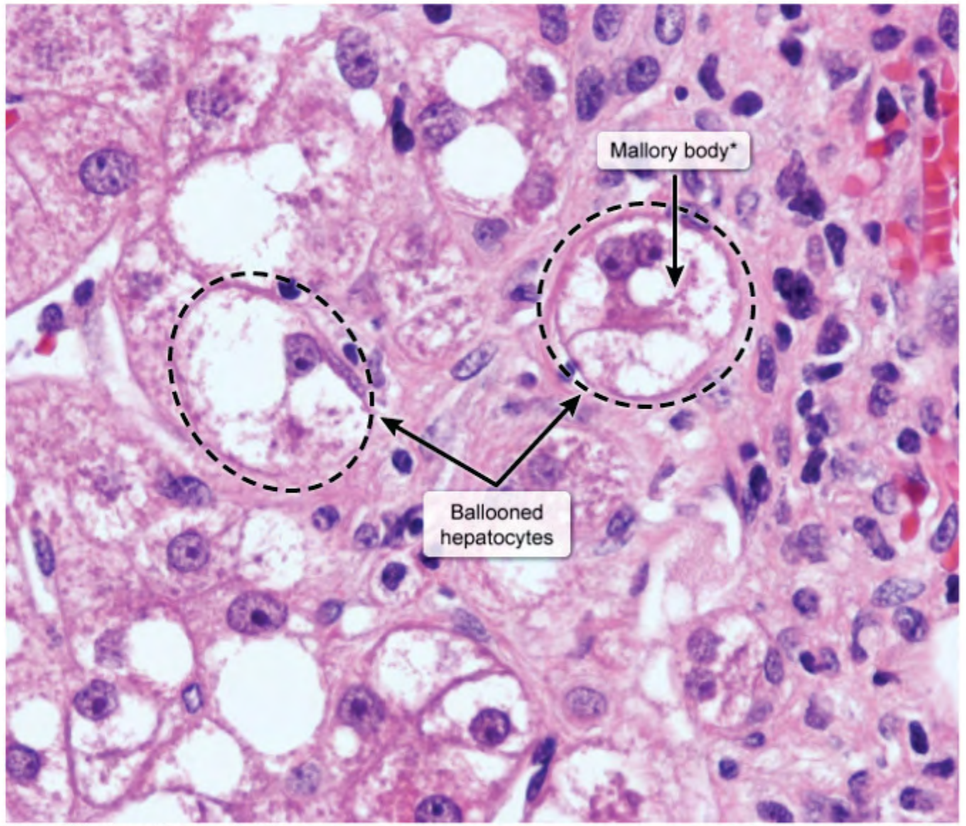

*Eosinophilic clumped intermediate filaments.

©UWorld

Zoom In | Zoom Out | Reset | New | Existing | My Notebook

https://t.me/USMLEWorldStep1

- PT & PTT elevations (impaired hepatic production of coagulation factors)

AL

Exhibit Display

Alcoholic hepatitis

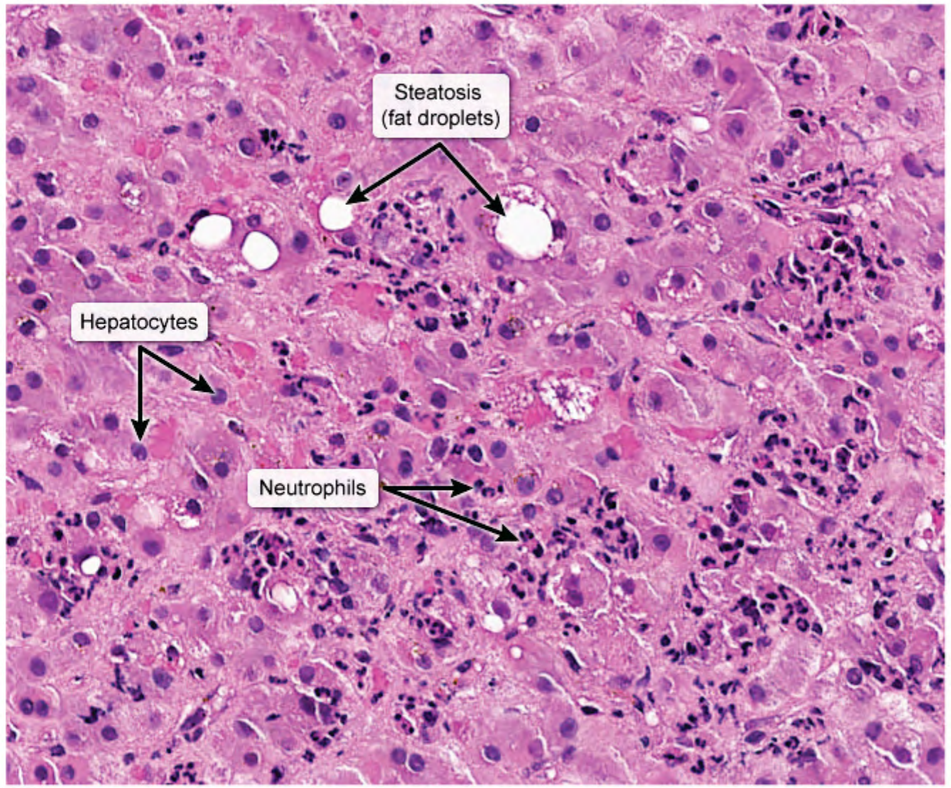

©UWorld

Zoom In | Zoom Out | Reset | New | Existing | My Notebook

This p
hepat
neutro
Other

Labora
amino
elevati
B_6 defi
found

Additic
PTT a

(Choi
inflam
disord
patien

(Choi
hepato
also b
Althou
genera

Educa
Alcoho
elevat

neutrophil infiltration, hepatocellular ballooning, Mallory bodies, and steatosis.

https://t.me/USMLEWorldStep1

	• PT & PTT elevations (impaired hepatic production of coagulation factors)
ALT	

Exhibit Display

This p
hepat
neutro
Other

Labora
amino
elevati
B_6 defi
found

Additi
PTT a

(Choi
inflam
disord
patien

(Choi
hepat
also b
Althou
genera

Educa
Alcoh
elevat

neutrophil infiltration, hepatocellular ballooning, Mallory bodies, and steatosis.

Primary biliary cholangitis

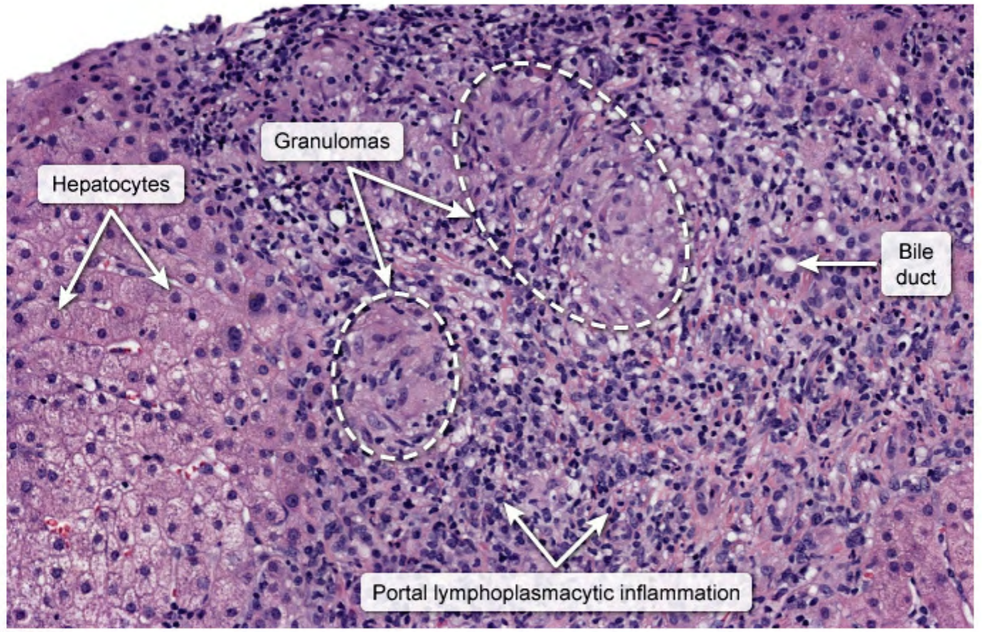

©UWorld

Zoom In | Zoom Out | Reset | New | Existing | My Notebook

https://t.me/USMLEWorldStep1

	• PT & PTT elevations (impaired hepatic production of coagulation factors)
ALT	

Exhibit Display

Chronic hepatitis C with cirrhosis

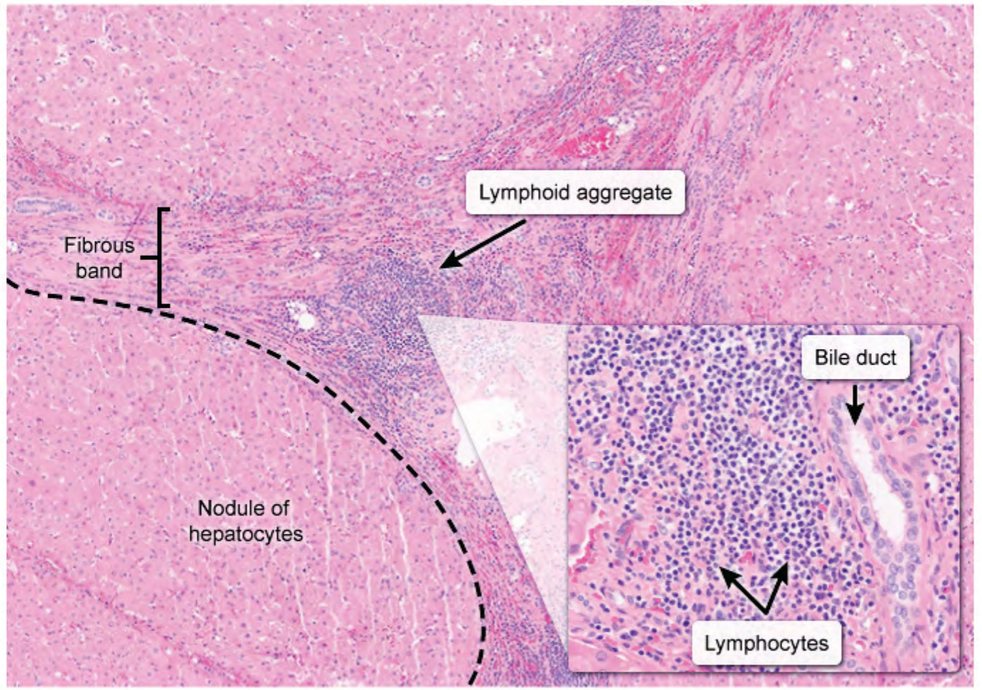

©UWorld

Zoom In | Zoom Out | Reset | New | Existing | My Notebook

This p
hepat
neutro
Other

Labora
amino
elevati
B_6 defi
found

Additi
PTT a

(Choi
inflam
disord
patien

(Choi
hepat
also b
Althou
genera

Educa
Alcoh
elevat

neutrophil infiltration, hepatocellular ballooning, Mallory bodies, and steatosis.

https://t.me/USMLEWorldStep1

- PT & PTT elevations (impaired hepatic production of coagulation factors)

ALT - alanine aminotransferase; **AST** - aspartate aminotransferase

Exhibit Display

This p
hepat
neutro
Other

Labora
amino
elevati
B_6 defi
found

Additi
PTT a

(Choi
inflam
disord
patien

(Choi
hepat
also b
Althou
genera

Educa
Alcoho
elevat

neutrophil infiltration, hepatocellular ballooning, Mallory bodies, and steatosis.

Chronic hepatitis B

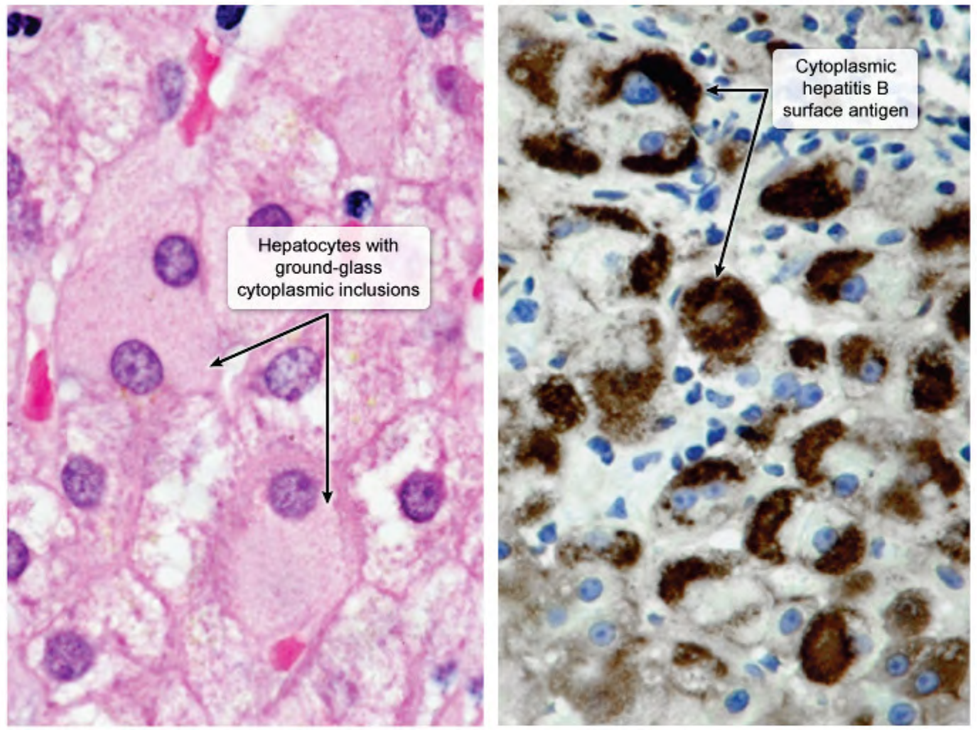

Hematoxylin & eosin stain

Hepatitis B surface antigen stain

©UWorld

Zoom In | Zoom Out | Reset | New | Existing | My Notebook

https://t.me/USMLEWorldStep1

A 60-year-old man is found to have a 5-cm exophytic mass in the ascending colon during a screening colonoscopy. Biopsy of the mass shows adenocarcinoma. The patient has no personal or family history of malignancy or colonic polyps. His medical problems include hypertension, and he does not use tobacco or alcohol. CT scan of the chest and abdomen reveals no metastatic lesions in the lungs or liver. A right colectomy is performed. The presence of which of the following indicates a poor prognosis in this patient?

- A. Abundant, well-formed glands in the tumor
- B. Cytokeratin expression by the malignant cells
- C. Malignant cells invading the lamina propria
- D. Prominent lymphocyte infiltration of the tumor
- E. Tumor cell deposits in the regional lymph nodes

Submit

https://t.me/USMLEWorldStep1

A 60-year-old man is found to have a 5-cm exophytic mass in the ascending colon during a screening colonoscopy. Biopsy of the mass shows adenocarcinoma. The patient has no personal or family history of malignancy or colonic polyps. His medical problems include hypertension, and he does not use tobacco or alcohol. CT scan of the chest and abdomen reveals no metastatic lesions in the lungs or liver. A right colectomy is performed. The presence of which of the following indicates a poor prognosis in this patient?

- A. Abundant, well-formed glands in the tumor (0%)
- ✗ B. Cytokeratin expression by the malignant cells (1%)
- C. Malignant cells invading the lamina propria (22%)
- D. Prominent lymphocyte infiltration of the tumor (0%)
- ✓ E. Tumor cell deposits in the regional lymph nodes (74%)

Incorrect
Correct answer
E

74%
Answered correctly

03 secs
Time Spent

2023
Version

Explanation

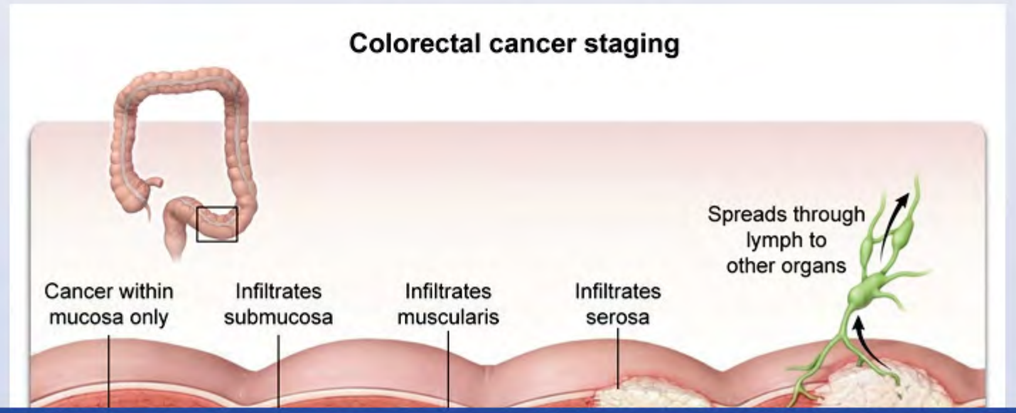

https://t.me/USMLEWorldStep1

A 60-year-old man is found to have a 5-cm exophytic mass in the ascending colon during a screening colonc
malign
alcoho
perfor

Incc
Corre
E

Expl

Exhibit Display

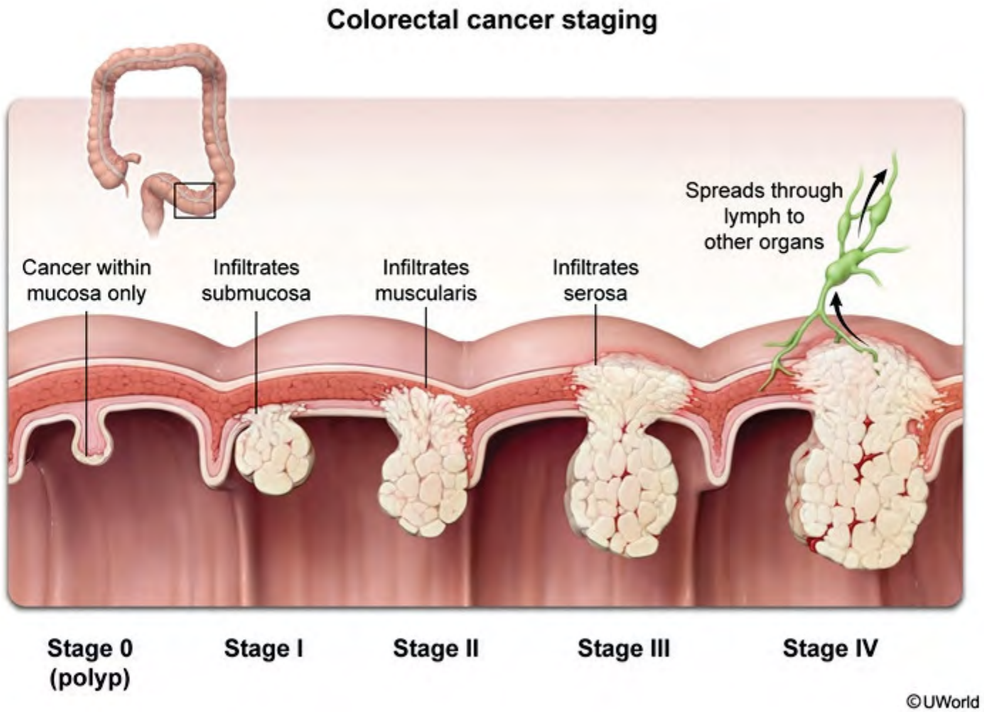

Zoom In Zoom Out Reset New | Existing My Notebook

https://t.me/USMLEWorldStep1

Colorectal cancer staging

Exhibit Display

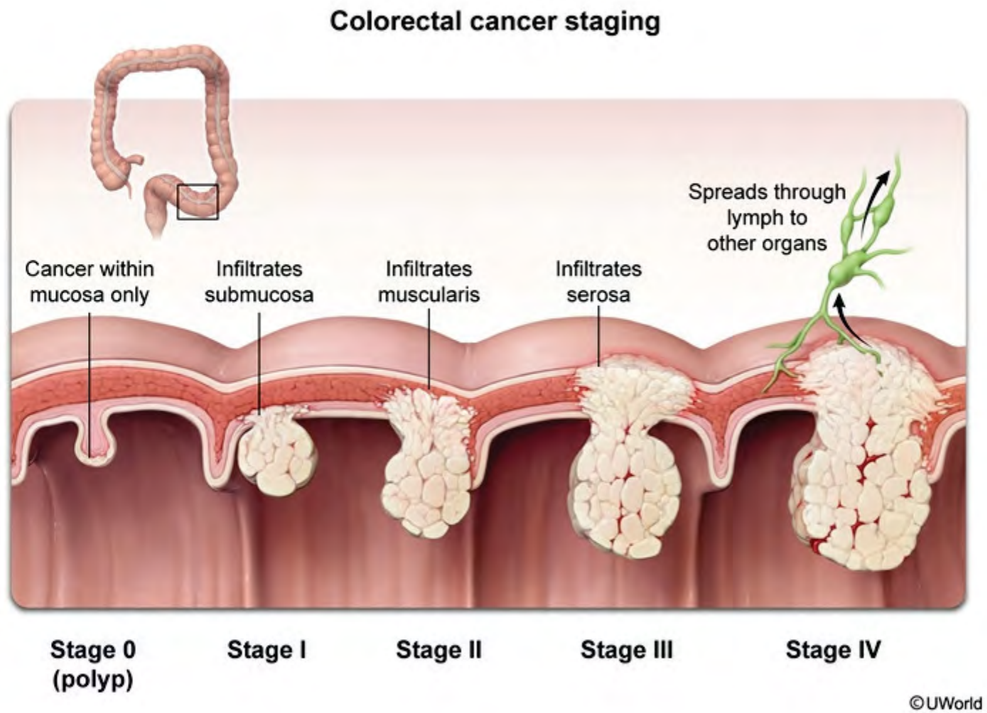

Zoom In | Zoom Out | Reset | New | Existing | My Notebook

The pr
degre
basem
surviva
chann
tumor

The pr
rate of
and, th
lungs,

(Choice A) Tumor grade, the degree of cellular differentiation of tumor cells, also affects prognosis. Well-

https://t.me/USMLEWorldStep1

The **prognosis of colorectal cancer** is most tightly correlated with tumor stage at diagnosis. Stage reflects the **degree of tumor invasion and spread** from the initial site of formation. Colorectal tumors confined to the basement membrane or lamina propria are considered to be carcinoma in situ and have an excellent 5-year survival rate (>90%). Invasion of the tumor into the muscularis propria, the location of the colonic lymphatic channels, is associated with a slightly worse prognosis (5-year survival rate of 70%-80%) due to elevated rates of tumor spread through lymphatics or to adjacent organs.

The prognosis of colon cancer deteriorates when tumor cells are identified in regional lymph nodes (5-year survival rate of 50%-80%). **Lymph node spread** is thought to be one of the strongest predictors of metastatic potential and, therefore, indicates an **increased risk** for incurable, distant disease. Metastatic spread to distant organs (eg, lungs, liver) is associated with the worst 5-year survival rates (<15%).

(Choice A) Tumor grade, the degree of cellular differentiation of tumor cells, also affects prognosis. Well-differentiated (low-grade) colonic tumors have glandular structure and are associated with a better prognosis than poorly differentiated (high-grade) colonic tumors, which appear as sheets or cords of cells with pleomorphism, high mitotic rates, and other signs of significant cellular aberration. Grade is a less important prognostic indicator than stage.

(Choice B) Cytokeratin 20 is a marker of intestinal cell differentiation. Testing for the presence of this structural protein helps confirm that adenocarcinomas are of intestinal origin; it is not a prognostic indicator.

(Choice C) The invasion of colorectal cancer into the lamina propria is considered to be carcinoma in situ because lymphatic channels do not arise until the subsequent layer (muscularis propria). Patients with colorectal tumors confined to the basement membrane or lamina propria have an excellent prognosis.

(Choice D) Cytotoxic T-cell (lymphocytic) invasion of tumor cells is a favorable prognostic indicator as it signifies immune recognition. It is associated with a lower risk of metastases and improved survival.

Educational objective:
Tumor stage (degree of invasion/spread) is the most important prognostic determinant for colorectal cancer. Tumors confined to the basement membrane and lamina propria are early stage and have the best prognosis. Outcomes generally deteriorate as the stage advances: spread of tumor into the muscularis propria → regional lymph nodes → distant sites.

https://t.me/USMLEWorldStep1